

Prolonged exposure to *M. faeni* in strain II guinea-pigs: pulmonary interstitial inflammation

Mark Schuyler, Suja Subramanyan and Medhat O. Hassan

Departments of Medicine and Pathology, Case Western Reserve University and Cleveland VA Medical Center,
Cleveland, Ohio, USA

Received for publication 8 January 1987

Accepted for publication 11 May 1987

Summary. Models of hypersensitivity pneumonitis (HP) should exhibit progression of pulmonary histological abnormalities during continuing challenges. Strain II guinea-pigs were sensitized with *Micropolyspora faeni* and received 2, 4, or 8 weekly intratracheal (i.t.) particulate *M. faeni* challenges. Control animals received normal saline (NS). Four days after the last exposure, randomly selected microscopic fields of lung (200/animal) were judged to be normal or abnormal. If abnormal, the location and nature of the abnormalities were determined.

Compared with NS treated guinea-pigs, those exposed to 2, 4 and 8 weekly *M. faeni* challenges exhibited more extensive ($P < 0.001$) pulmonary histological abnormalities which involved both the intraalveolar and interstitial compartments. More extensive abnormalities in the 8 week group compared with the 4 week group were caused by increased extent of interstitial mononuclear cell infiltration.

The extent of pulmonary interstitial histological abnormalities transiently (four challenges) decreases, but then increases, so that progressive pulmonary inflammation occurs during continuing challenges.

Keywords: experimental hypersensitivity pneumonitis

Hypersensitivity pneumonitis (HP) in humans is characterized by transient pulmonary inflammation that occurs in response to inhalation of the inciting agent. If exposure continues, diffuse pulmonary interstitial fibrosis may result and abnormalities of lung physiology may become permanent (Schuyler & Salvaggio 1984).

Farmers' Lung Disease (FLD), a common example of HP, is caused by inhalation of mouldy hay. The responsible material in mouldy hay is *Micropolyspora faeni*, a thermophilic actinomycete which grows in hay

stored in silos (Pepys *et al.* 1963). Repetitive episodes of FLD cause pulmonary interstitial fibrosis (Emanuel *et al.* 1964; Monkare *et al.* 1985; Seal *et al.* 1968; Smyth *et al.* 1975) in some subjects. The reasons for the occurrence of permanent abnormalities in only a minority of exposed subjects are unknown.

An animal model of disease that demonstrates variability of response would be extremely useful in elucidating reasons for variability of human response. We previously attempted to develop a model of chronic HP by multiple intra-tracheal (i.t.)

Correspondence: Mark Schuyler, MD, Albuquerque VA Medical Center, 2100 Ridgecrest Drive, SE, Albuquerque, New Mexico 87108, USA.

injections of *M. faeni* into rabbits (Schuyler et al., 1983). However, the extent of pulmonary inflammation resolved despite continuing exposure to particulate *M. faeni* antigen.

The reasons for this difference between rabbit and some human response to repeated exposures of *M. faeni* (decreasing rather than increasing extent of histological abnormalities) is unexplained, but could include immunological differences between humans and rabbits. Guinea-pigs more closely resemble humans than do rabbits in their complement system, ability to express some aspects of delayed type hypersensitivity and response to corticosteroids (Batra et al. 1966; Claman 1972). To determine whether the extent of pulmonary histological abnormalities also decreases in guinea-pigs, we extended our studies in a previously described model of HP in strain II guinea-pigs (Schuyler et al. 1982a, b), by increasing the number of antigen challenges up to 11 i.t. injections of *M. faeni*.

We found that, in contrast to rabbits, during a course of weekly challenges, guinea-pigs responded to multiple injections of *M. faeni* with increasing extent of abnormalities and only transient decrease of pulmonary histological abnormalities. In this regard, guinea-pigs resemble those human responses which result in permanent histological changes. However, as in rabbits, pulmonary inflammation was not self-perpetuating. Four weeks after the last of 8 weekly i.t. challenges, pulmonary inflammation had largely resolved.

Thus, this model more closely resembles human HP and presents an opportunity for understanding immunopathogenetic mechanisms.

Materials and methods

Animals. Strain II guinea pigs (350–450 g) were obtained from the National Cancer Institute (NCI, Office of Mammalian Genetics, Ft. Detrick, MD). They were housed in laminar flow hoods with HEPA filtered air and were allowed food (Purina guinea-pig

chow) and water *ad libitum*. Guinea-pigs were housed five to a cage before experimental manipulation and in individual cages thereafter.

Antigen. *M. faeni* was obtained from V. Kurup (Medical School of Wisconsin, Milwaukee, WI). The new designation for *Micropolyspora faeni* is *Faeni rectivirgula* (Kurup & Agre 1983), but we elected to continue to refer to this organism as *M. faeni* to be consistent with past usage. *M. faeni* was inoculated into trypticase soy broth and grown at 52°C for 6 days on a shaking incubator. It was harvested by centrifugation, washed with sterile distilled water three times, cell walls disrupted with a Braun cell homogenizer and lyophilized. This material contained the equivalent of less than 0.2 µg endotoxin per mg *M. faeni* (Schuyler & Schmitt 1984). The lyophilized powder was used for injection. Partially purified antigen for antibody determination was obtained by dialyzing lyophilized powder against phosphate buffered saline for 5 days. After ultra-centrifugation and filtration through a 0.22 µm filter, the dry weight of the supernatant was determined and the material stored at -20°C.

Intratracheal inoculation. Guinea-pigs were anaesthetized with a mixture of ketamine (80 mg/kg) and acepromazine (0.8 mg/kg) administered intramuscularly. The necks were shaved, washed with methanol and hyperextended. Lyophilized *M. faeni* was suspended in sterile pyrogen free normal saline (4 mg/ml) and 3.6 mg/kg *M. faeni* injected into the trachea by percutaneous puncture using sterile procedures; after which the animal was held upright for 1 min.

Animals were sensitized by three i.t. injections of 3.6 mg/kg *M. faeni* administered 2 days apart and injection of 1.6 mg particulate *M. faeni* emulsified in 0.4 ml of complete Freund's adjuvant (Difco, Detroit, MI) into all four footpads on the same day as the first i.t. injection. Seven days after the first i.t. injection, the guinea-pigs received 1.6 mg of *M. faeni* mixed with an equal volume of incom-

plete Freund's adjuvant subcutaneously. Fourteen days thereafter, they were subjected to the first challenge i.t. injection of *M. faeni*. These were continued on a weekly basis for 2, 4, and 8 weeks. Animals received five, seven, or 11 injections (three sensitizing and two challenge; three sensitizing and four challenge; three sensitizing and eight challenge). Some animals were allowed to live for 4 weeks after receiving eight challenge injections. Normal saline treated guinea-pigs received equal volumes of normal saline and Freund's adjuvant and normal saline i.t.

Each group included 7 to 11 animals.

Four days after the last i.t. injection, the guinea-pigs were anaesthetized with (200 mg/kg) pentobarbital, blood obtained from the vena cava and the animal killed by exsanguination. The trachea was cannulated and the lungs inflated with buffered pH 6.9 formalin under 20 cm water pressure for 48–72 h.

Histological studies. After inflation, the lungs were sectioned by sagittal cuts of the upper, middle and lower lobes and a transverse cut of the mediastinal lobe. Random 2 cm × 2.5 cm sections were taken from all lobes (six sections from each guinea-pig), embedded in paraffin, cut in 5 µm thin sections and stained with haematoxylin and eosin. Slides were evaluated without knowledge of treatment. The area covered by an eyepiece grid (0.99 mm × 0.99 mm using × 40 magnification) was judged to be normal or abnormal. If abnormal, the location of the abnormalities were determined to be interstitial, intra-alveolar or peribronchiolar and the type of cellular infiltration noted. An average of 200 fields were evaluated from each guinea-pig (25% of the slide area).

Bronchoalveolar lavage and electron microscopic studies. Some guinea-pig lungs (four naive and eight *M. faeni* challenged (4 days after the second or fourth challenge)) were lavaged 12 times with 20 ml sterile normal saline after exsanguination. Cells were pelleted, washed three times with RPMI-1640,

counted on a haemocytometer and viability determined by trypan blue dye exclusion. The cells were then deposited on slides with a cytocentrifuge, stained with Wright-Giemsa and cell type determined. Aliquots were fixed in Karnovsky's solution, post-fixed in osmium tetroxide and embedded in Spurr. One micrometre thick sections were cut with glass knives, stained with toluidine and examined with a light microscope. Ultrathin sections were cut from selected blocks with a diamond knife, doubly stained with uranyl acetate and lead hydroxide and then examined with a JEOL CX 100 electron microscope.

The lungs were then inflated with Karnovsky's solution under 20 cm water pressure for 48 h, sectioned in an identical manner as the formalin fixed lungs, random 1 × 1 mm³ cubes removed, treated in a similar manner as the lavage and examined ultrastructurally.

Antibody determination. Counterimmunoelectrophoresis was used with dialyzed soluble *M. faeni* antigen and undiluted serum (pH 8.2 barbital buffer, 3 mA, 1 h) (Schuyler *et al.* 1982b). Lines which formed between antigen and serum containing wells could be abolished by absorption of the serum with particulate *M. faeni*.

Statistical analysis. Differences between groups were evaluated using Student's *t*-test (Goldstein 1964).

Results

All guinea-pig lungs were normal on gross examination. Lungs from normal saline treated animals were remarkably free of inflammatory cell infiltration. Only 5.8% of all fields were abnormal. The majority of the abnormalities consisted of minimal interstitial thickening with chronic inflammatory cells (Fig. 1).

Figure 2 indicates the evolution of the extent of histological abnormalities in the

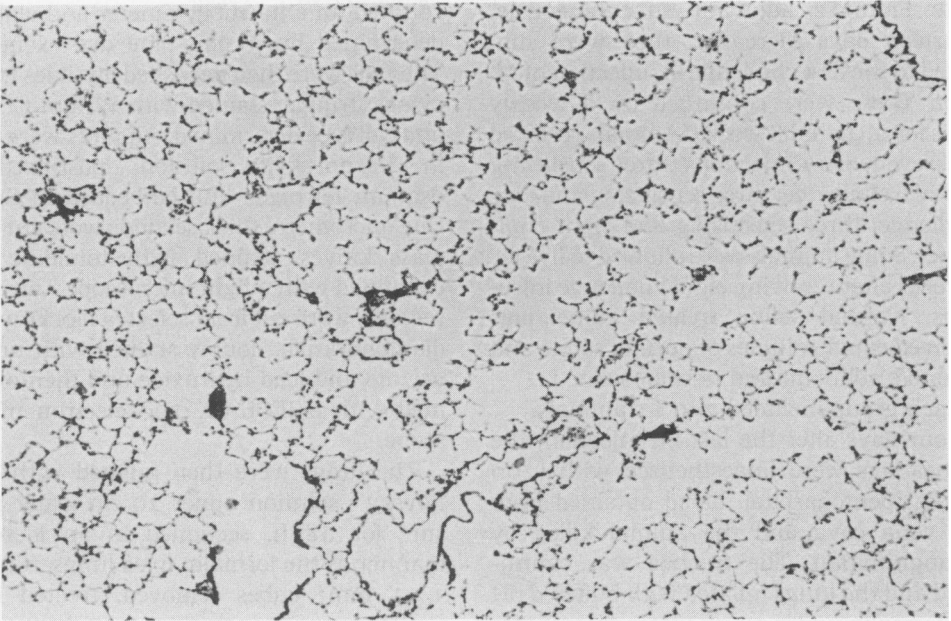


Fig. 1. Guinea-pig lung after sensitization with normal saline in Freund's adjuvant and 11 intratracheal injections of normal saline. There are minimal and scattered areas of focal interstitial inflammation and thickening. H & E, $\times 60$.

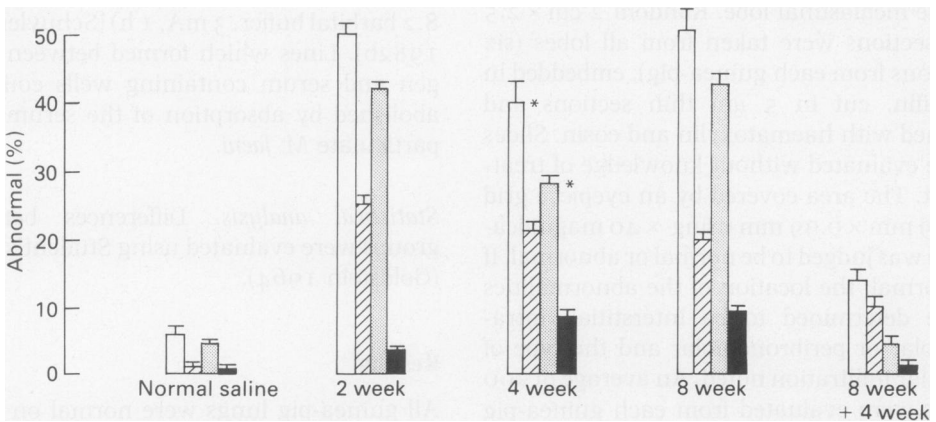


Fig. 2. Extent of pulmonary histological abnormalities. Mean and standard error of the mean. Guinea-pigs were sensitized with *M. faeni* (with Freund's adjuvant and three i.t. injections) and injected i.t. with *M. faeni* weekly. Normal saline animals were sensitized and challenged eight times with equal volumes of normal saline. Each group contained 7 to 11 animals. All values from *M. faeni* treated groups are different ($P < 0.01$) than values from normal saline treated animals. All differences noted below are statistically significant ($P < 0.01$).

Total (□) = per cent Microscopic fields ($0.99 \text{ mm} \times 0.99 \text{ mm}$) abnormal. 4 week $<$ 2 week and 8 week.

Alveolar (▨) = per cent fields with alveolar abnormalities. 2 week $>$ 4 week and 8 week.

Interstitial (▤) = per cent fields with interstitial abnormalities. 4 week $<$ 2 week and 8 week.

Peribronchial (■) = fields with peribronchial abnormalities. 4 week $>$ 2 week.

groups of guinea-pigs. Compared with normal saline treated controls, sensitization and repetitive i.t. injections with *M. faeni* greatly increased the proportion of lung histological fields that were abnormal. Abnormalities were present in both the alveolar and interstitial areas. Peribronchial abnormalities were also prominent.

Lungs from guinea-pigs killed after two challenge i.t. injections of *M. faeni* exhibited both intra-alveolar and interstitial inflammation (Figs 3, 4 and 5). Alveolar macrophages, polymorphonuclear leucocytes and an occasional lymphocyte were present within the alveoli. The interstitial infiltrate consisted of macrophages, lymphocytes, polymorphonuclear leucocytes, and occasional eosinophils. In addition, there were collections of lymphocytes in the peribronchial and peribronchiolar regions.

After four i.t. challenge injections of *M. faeni* there was less intra-alveolar and interstitial inflammation and more extensive peribronchiolar mononuclear cell infiltration,

compared with lungs from animals injected twice with *M. faeni*.

Lungs from guinea-pigs killed after eight challenge i.t. injections of *M. faeni* exhibited more interstitial inflammation (Fig. 6). Alveolar macrophages, polymorphonuclear leucocytes and an occasional lymphocyte were present within the alveoli. The interstitial infiltrate consisted of macrophages, lymphocytes, polymorphonuclear leucocyte and eosinophils. There were no granulomas. In addition, peribronchial and peribronchiolar regions were infiltrated with lymphocytes. Compared with lungs from animals injected four times with *M. faeni* there was more extensive interstitial infiltration with mononuclear cell infiltration and peribronchiolar mononuclear cell infiltration.

Overall, the extent of pulmonary histological abnormalities decreased between 2 and 4 weeks and then increased between 4 and 8 weeks. The decrease at 4 weeks was caused by significant ($P < 0.01$) diminution of abnormalities in both the alveolar and intersti-

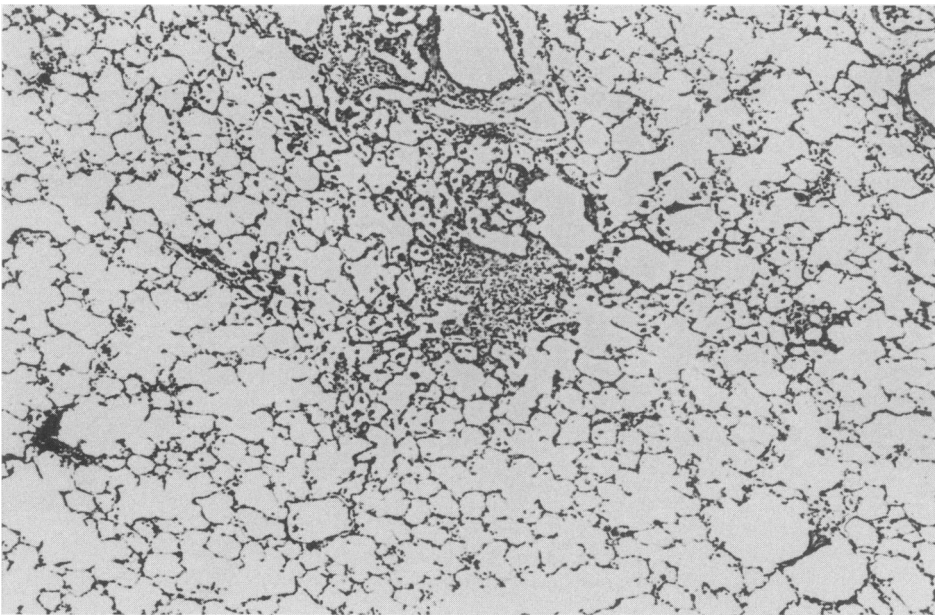


Fig. 3. Guinea-pig lung after sensitization with *M. faeni* in Freund's adjuvant and five intratracheal (three sensitizing and two challenge) injections of *M. faeni*. There is a diffuse inflammatory exudate in both the airspaces and interstitium. H & E, $\times 60$.

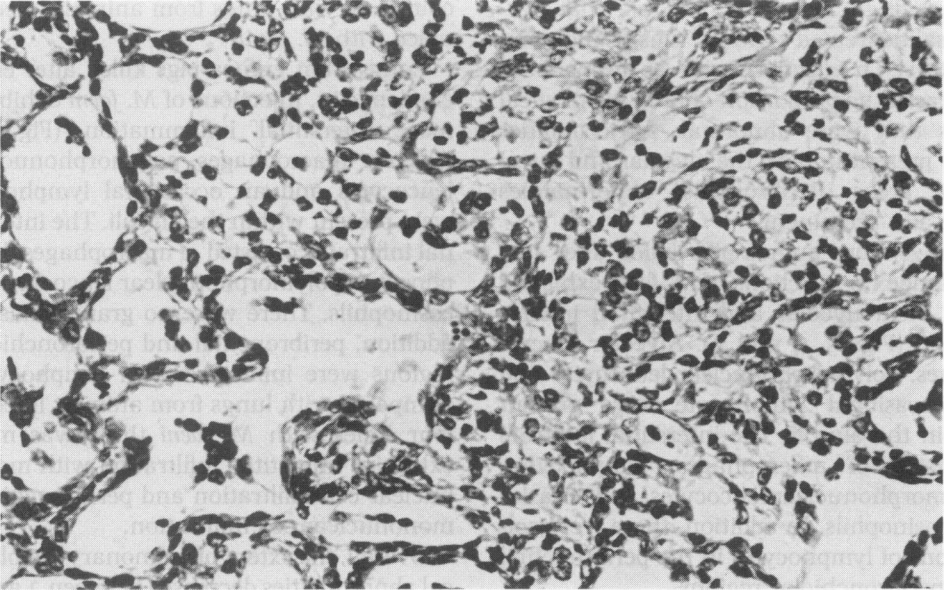


Fig. 4. Guinea-pig lung after sensitization with *M. faeni* in Freund's adjuvant and five intratracheal (three sensitizing and two challenge) injections of *M. faeni*. The exudate in both the airspaces and interstitium is composed of macrophages, neutrophils, lymphocytes and occasional eosinophil. H & E, $\times 360$.

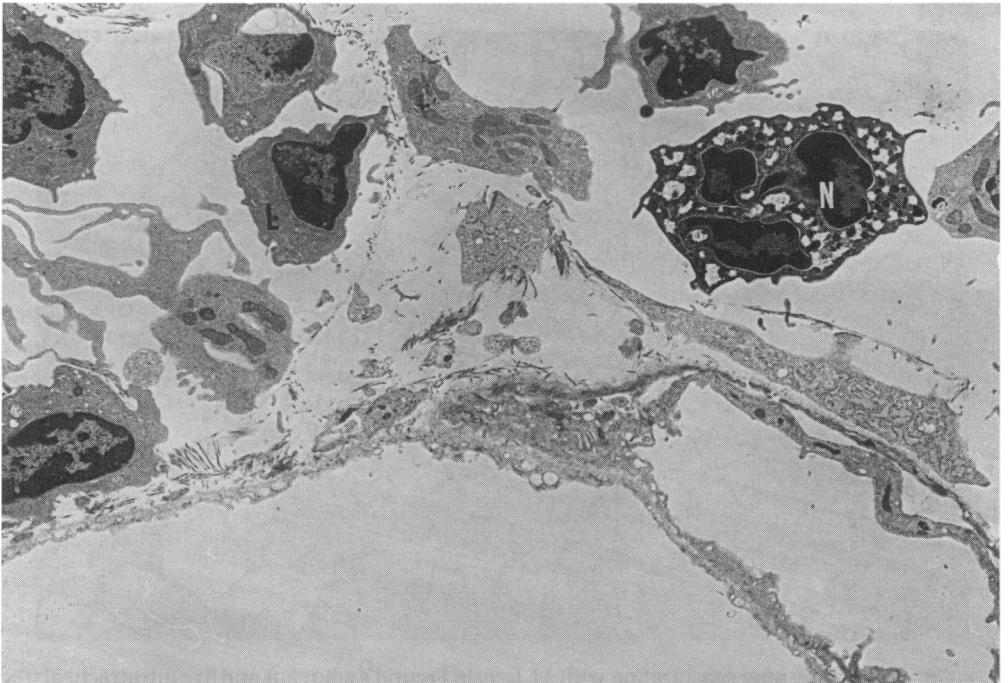


Fig. 5. Electron micrograph of lung after sensitization with *M. faeni* in Freund's adjuvant and five intratracheal (three sensitizing and two challenge) injections of *M. faeni*. $\times 4000$ There is interstitial oedema and infiltration with a mixture of macrophages and lymphocytes. There is no evidence of vasculitis.

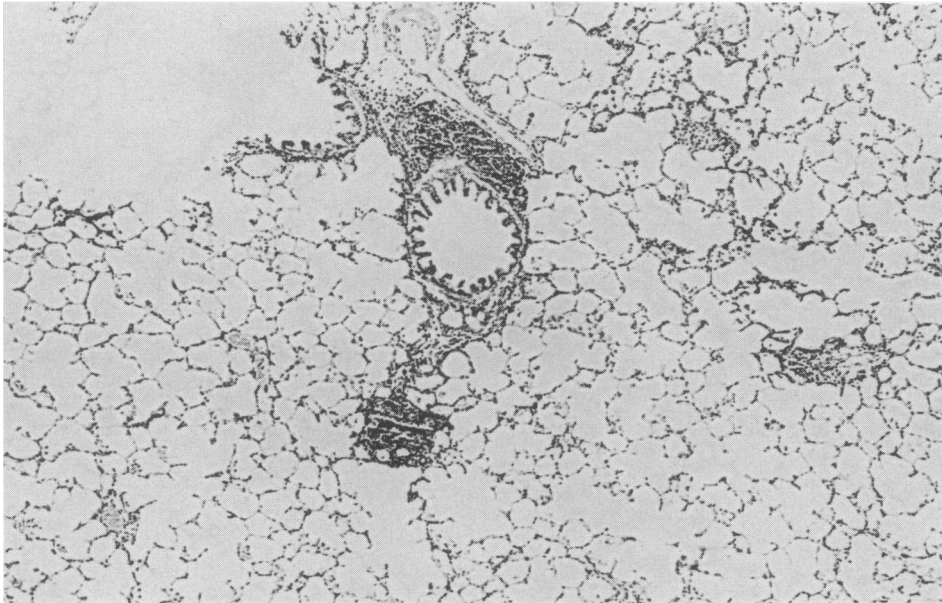


Fig. 6. Guinea-pig lung after sensitization with *M. faeni* in Freund's adjuvant and 11 intratracheal (three sensitizing and eight challenge) injections of *M. faeni*. There is a diffuse inflammatory exudate in both the airspaces and interstitium composed of macrophages, neutrophils, lymphocytes and occasional eosinophil. Compared with Fig. 3, there are more peribronchial abnormalities. H & E, $\times 60$.

tial compartments. The increase at 8 weeks was caused solely by a significant ($P < 0.01$) increase in the interstitial abnormalities. The extent of peribronchial abnormalities increased significantly with two to four challenges and thereafter remained stable.

After cessation of weekly challenge injections and a 4 week rest period, interstitial inflammation resolved almost completely and the extent of alveolar inflammation decreased substantially. The residual abnormalities consisted of scattered foci of alveolar and interstitial chronic inflammation, centered around bronchioles (Fig. 7).

Table 1 indicates the morphometric extent and nature of histological abnormalities in the different groups of guinea-pigs. In all groups there were more microscopic fields with mononuclear cells than polymorphonuclear leucocytes in both the alveolar and interstitial compartments. Perivascular infiltration of lymphocytes occurred in a few

fields in *M. faeni* animals, but there was no evidence of vasculitis.

Bronchoalveolar lavage of naive animals yielded $9.8 \pm 1.4 \times 10^6$ cells (mean \pm s.e.m.), most of which were alveolar macrophages ($91.7\% \pm 0.7\%$) with few lymphocytes ($1.6\% \pm 0.8\%$), polymorphonuclear leucocytes ($1.1\% \pm 0.3\%$) and some eosinophils ($5.7\% \pm 0.4\%$). In contrast, *M. faeni* challenged guinea-pigs had significantly more lavaged cells ($86.8 \pm 20.4 \times 10^6$), lymphocytes ($5.4\% \pm 0.4\%$) and many more polymorphonuclear leucocytes ($45.1\% \pm 3.0\%$). In general, there were no differences between the two *M. faeni* treated groups (Table 1). Eosinophils were present in lavages of both *M. faeni* treated and naive guinea-pigs (Figure 8). Although there were fewer eosinophils in the 2 week group than in the naive group, there was no difference between results at 2 and 4 weeks.

Antibody to *M. faeni* was present in the

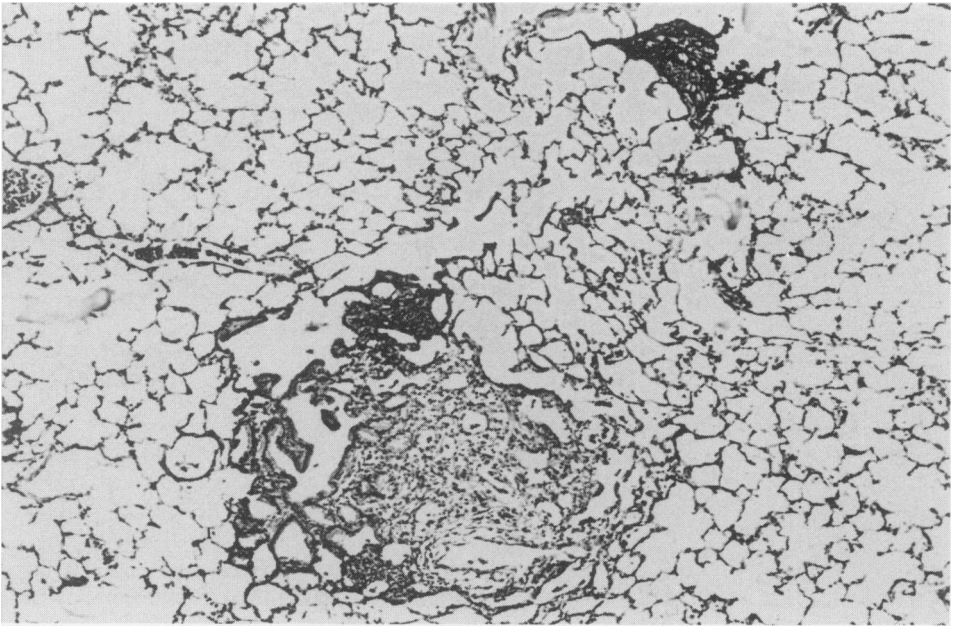


Fig. 7. Guinea-pig lung 4 weeks after sensitization with three *M. faeni* in Freund's adjuvant and the last of 11 intratracheal (three sensitizing and eight challenge) injections of *M. faeni*. Compared with Fig. 6, there are much less extensive abnormalities. Most of the lung is normal with occasional residue of interstitial and intraalveolar infiltration. H & E, $\times 100$.

serum of all *M. faeni* sensitized and no normal saline treated animals.

Discussion

We found that repetitive intra-tracheal injections of *M. faeni* into Strain II guinea-pigs produced widespread pulmonary histological abnormalities. After four challenge injections, there was evidence of decrease of pulmonary inflammation with reduction of both alveolar and interstitial abnormalities. After eight challenges, there was a greater extent of histological abnormalities, caused by an increase in interstitial abnormalities. During the course of challenges, interstitial inflammation decreased from 42% to 28.2% (two challenges vs four challenges) and then increased to 43% (eight challenges). The cells within the interstitial compartment were a mixture of lymphocytes, macrophages, polymorphonuclear leucocytes and

eosinophils. Peribronchial lymphocytic infiltration increased progressively from two to four challenges. The cell type in bronchoalveolar lavage changed from predominantly alveolar macrophages (naive animals) to a mixture of alveolar macrophages, lymphocytes, and polymorphonuclear leucocytes (sensitized and challenged animals). Fournier *et al.* (1985) described similar transient neutrophil alveolitis in humans with hypersensitivity pneumonitis challenged with the relevant antigen.

Pulmonary inflammation in guinea-pigs therefore progresses during repeated exposure (eight challenges) to particulate *M. faeni* antigen. This contrasts with our finding of decreasing pulmonary inflammation in rabbits exposed to the same material (Schuyler *et al.* 1983). The phenomenon of decrease of pulmonary inflammation in rabbits repetitively exposed to antigen is not unique to *M. faeni*. Both Richerson and Willoughby have

Table 1. Extent and characteristics of histological abnormalities

	NS	2 week	4 week	8 week	> 8 week
Abnormal	5.8	51.5*†	39.8*†	51.3*†	13.9*
Alveolar	1.2	25.6*†	21.6*†	20.0*†	9.9*
Interstitial	4.5	42.0*†	28.2*†	43.0*†	4.3
Polysa	0.3	10.6*†	11.4*†	10.0*†	5.4*
Monoa	1.2	21.0*†	16.2*†	15.6*†	9.4*
Polysi	0	2.4*†	3.4*†	2.6*†	0.3
Monoi	4.6	42.0*†	27.9*†	42.9*†	4.3
Peribr	0.3	3.5*†	8.5*†	9.1*†	0.9
Perivsc	0.3	0.7	1.7*†	1.4*	0.0

All groups were sensitized with *M. faeni* in Freund's adjuvant and three sensitizing i.t. injections and challenged with two (2 week), four (4 week), or eight (8 week) i.t. challenge injections of *M. faeni*. > 8 week group was challenged eight times and killed 4 weeks after the last challenge. Each group contained seven to 11 animals. All differences noted below are statistically significant ($P < 0.01$) (student's *t*-test).

* Compared with NS group.

† Compared with > 8 week group.

Numbers = mean values.

Abnormal = Per cent microscopic fields (0.99 × 0.99 mm) abnormal. 4 week < 2 week and 8 week.

Alveolar = Per cent fields with alveolar abnormalities. 2 week > 4 week and 8 week.

Interstitial = Per cent fields with interstitial abnormalities. 4 week < 2 week and 8 week.

Polysa = Per cent fields with polymorphonuclear leucocytes in alveoli.

Monoa = Per cent fields with mononuclear leucocytes in alveoli. 2 week > 4 week and 8 week.

Polysi = Per cent fields with polymorphonuclear leucocytes in interstitium.

Monoi = Per cent fields with mononuclear leucocytes in interstitium. 4 week < 2 week and 8 week.

Peribr = Per cent fields with peribronchial abnormalities. 4 week > 2 week.

Perivsc = Per cent fields with perivascular infiltrates.

Some fields exhibited abnormalities in both the alveolar and interstitial compartments. Therefore, the numerical total of 'Alveolar + Interstitial' may be greater than 'Abnormal'.

demonstrated decreasing inflammatory response of rabbit lung to inhaled soluble antigen (Richerson *et al.* 1978; Willoughby & Willoughby 1977). The reasons for this different response of guinea-pigs and rabbits are unknown, but could include differences

in cell types within the lung (for example eosinophils were present in guinea-pig, but not in rabbit broncho-alveolar lavages) or differences in attributes of lung cells. For instance, alveolar macrophages from *M. faeni* exposed rabbits increase their ability to

Table 2.

Group	Cell No	Mac%†	Lymph%†	Poly%†	Eosin%†	Viab%‡
Naive (4)	9.8	91.7	1.6	1.1	5.6	92
2 week (4)	86.2*	49.6*	6.3*	43.4*	0.6*	93
4 week (4)	87.4*	44.4*	4.5*	46.9*	3.9	92

Number of animals indicated within parentheses.

Cell No. = Number of cells $\times 10^{-6}$

† Determined by Wright-Giemsa stain of cytocentrifuge preparation.

‡ Determined by exclusion of trypan blue dye.

* $P < 0.05$ compared with Naive group.

2 week guinea-pigs were sensitized with *M. faeni* (with Freund's adjuvant and three i.t. injections) and injected i.t. for 2 weeks with *M. faeni* weekly.

4 week guinea-pigs were sensitized with *M. faeni* (with Freund's adjuvant and three i.t. injections) and injected i.t. for 4 weeks with *M. faeni* weekly.

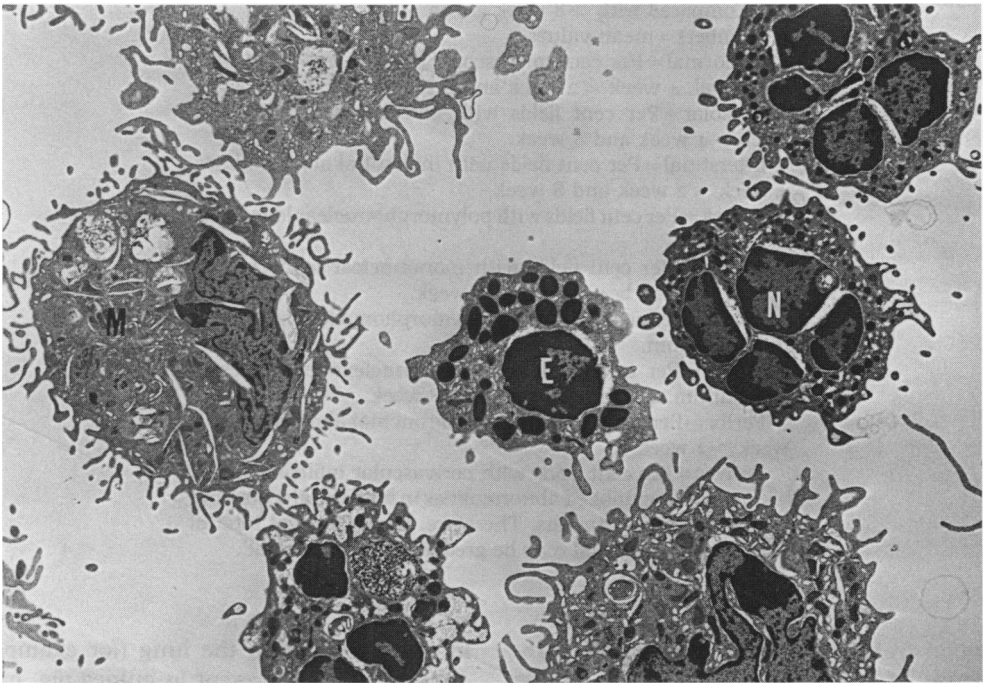


Fig. 8. Broncho-alveolar lavage of guinea pig 4 days after the last of two challenge injections of *M. faeni*. Stained with uranyl acetate and lead hydroxide. $\times 4000$. There is a mixture of alveolar macrophages, polymorphonuclear leucocytes and eosinophils.

phagocytize particles via their Fc receptors (Schuyler & Steinberg 1982c), but alveolar macrophages from *M. faeni* exposed guinea-pigs do not (unpublished observations). Another possibility is differences in the balance between helper and suppressor cells within the lung between the species.

Despite the overall increase of interstitial abnormalities over eight challenges, there was evidence of transient decrease (after four challenges) in guinea-pigs. Thus, at different time periods, these guinea-pigs resemble either most individuals exposed to *M. faeni* (decreased pulmonary inflammation) or a minority of exposed individuals (progression of abnormalities). This diminution of pulmonary inflammation could be a result of suppressor cell influences. Suppressor lymphocytes have been described in bronchoalveolar lavage of asymptomatic pigeon breeders, but not in those from patients with pigeon breeders' disease (Moore *et al.* 1980; Keller *et al.* 1982b). Similar findings have been reported in monkeys with HP caused by inhalation of pigeon serum (Keller *et al.* 1982a). Future experiments will assess the activity of suppressor cell influences within the lung in this model after four challenges.

Acknowledgements

This work was supported by the Veterans Administration Research Service.

References

- BATRA K., ELROD L. & SCHREK R. (1966) Species differences in the *in vitro* sensitivity of lymphocytes to prednisolone and X-rays. *J. Pharmac. exp. Ther.* **152**, 525-528.
- CLAMAN H. (1972) Corticosteroids and lymphoid cells. *N. Engl. J. Med.* **287**, 388-397.
- EMANUEL D., WENZEL F., BOWERMAN C. & LAWTON B. (1964) Farmer's Lung. *Am. J. Med.* **37**, 392-401.
- FOURNIER E., TONNEL A., GOSSET P., WALLAERT B., AMEISEN J. & VOISON C. (1985) Early neutrophil alveolitis after antigen inhalation in hypersensitivity pneumonitis. *Chest* **88**, 563-566.
- GOLDSTEIN A. (1964) *Biostatistics: an Introductory Text*. MacMillan. New York pp. 144-166.
- KELLER R., CALVANICO N. & STEVENS J. (1982a) Hypersensitivity pneumonitis in non human primates. I. Studies on the relationship of immunoregulation and disease activity. *J. Immunol.* **128**, 116-122.
- KELLER R., FINK J., LYMAN S. & PEDERSON G. (1982b) Immunoregulation in hypersensitivity pneumonitis. I. Differences in T-cell and macrophage suppresser activity in symptomatic and asymptomatic pigeon breeders. *J. Clin. Immunol.* **2**, 46-54.
- KURUP V. & AGRE N. (1983) Transfer of *Micropolyspora rectivirgula* (Krassilnikov & Agre 1964) Lechevalier, Lechevalier and Becker 1966 to *Faeni gen. nov.* *Int. J. Systemic Bacteriol.* **33**, 663-665.
- MOORE V., PEDERSON G., HAUSER W. & FINK J. (1980) A study of lung lavage materials in patients with hypersensitivity pneumonitis: *In vitro* response to mitogen and antigen in pigeon's breeders' disease. *J. Allergy Clin. Immunol.* **65**, 365-370.
- MONKARE S., IKONEN M. & HAAHELA T. (1985) Radiologic findings in Farmer's lung. *Chest* **87**, 460-466.
- PEPYS J., JENKINS P., FESTENSTEIN G., GREGORY P., LACEY M. & SKINNER P. (1963) Farmer's lung: thermophilic actinomycetes as a source of 'Farmer's lung hay' antigen. *Lancet* **ii**, 607-611.
- RICHERSON H., SEIDENFELD J., RATAJCZAK H. & RICHARDS D. (1978) Chronic experimental hypersensitivity pneumonitis in the rabbit. *Am. Rev. Resp. Dis.* **117**, 5-13.
- SCHUYLER M., SCHMITT D. & STEINBERG D. (1982a) Hypersensitivity pneumonitis in strain II guinea pigs. I. Histologic Features. *Int. Arch. Allergy Appl. Immunol.* **68**, 108-111.
- SCHUYLER M., SCHMITT D. & STEINBERG D. (1982b) Hypersensitivity pneumonitis in strain II guinea pigs. II. Immunologic features. *Int. Arch. Allergy Appl. Immunol.* **68**, 112-116.
- SCHUYLER M. & STEINBERG D. (1982c) Activated alveolar macrophages: IgG and complement receptors. *J. Lab. Clin. Med.* **100**, 932-942.
- SCHUYLER M., KLEINERMAN J., PENSKY J., BRANDT C. & SCHMITT D. (1983) Pulmonary response to repeated exposure to *Micropolyspora faeni*. *Am. Rev. Resp. Dis.* **128**, 1071-1076.
- SCHUYLER M. & SALVAGGIO J. (1984) Hypersensitivity pneumonitis. *Seminars in Resp. Med.* **5**, 246-254.
- SCHUYLER M. & SCHMITT D. (1984) Experimental hypersensitivity pneumonitis: Lack of tolerance. *Am. Rev. Resp. Dis.* **130**, 772-778.
- SEAL M., HAPKE E. & THOMAS G. (1968) The

- pathology of acute and chronic stages of farmer's lung. *Thorax* 23, 469-489.
- SMYTH J., ADKINS E., LLOYD M., MOORE B. & McWHITE E. (1975) Farmer's lung in Devon. *Thorax* 30, 197-203.
- WILLOUGHBY J. & WILLOUGHBY W. (1977) *In vivo* responses to inhaled proteins. I. Quantitative analysis of antigen uptake, fate and immunogenicity in a rabbit model system. *J. Immunol.* 119, 2137-2146.