

# Cytochemical and Ultrastructural Studies of the Intestinal Mucosa of Children with Celiac Disease

Luis Biempica, M.D., Horacio Toccalino, M.D., and  
Juan Carlos O'Donnell, M.D.

CURRENT KNOWLEDGE of the ultrastructure and cytochemistry of the human intestinal epithelial cell is based upon the development and widespread application of the peroral biopsy technique.<sup>1-3</sup> Tissue obtained in this fashion has helped in the understanding of the physiologic and morphologic changes associated with intestinal dysfunction, including celiac disease in adults.<sup>4-24</sup> Because of technical difficulties there are few studies in "celiac children," especially those in the younger age groups.<sup>25-27</sup> Particularly limited is information on the extent of recovery of organelles in epithelial cells of children treated with gluten-free diets. This work describes the columnar cells in normal children, in children with celiac disease, and in children treated with a gluten-free diet.

## Material and Methods

Biopsy specimens from the small intestine were obtained from:

Group A: 7 normal children, ranging in age from 1 to 12 years. These children had no history of diarrhea or bulky stools. Roentgenologic studies of the small intestine revealed loops of normal caliber with intact mucosal patterns. Intestinal parasitic infection was excluded. Results of quantitative 72-hr. fecal fat determinations<sup>28</sup> were within normal limits.

Group B: 20 children, from 1.5 to 12 years of age, with clinical courses typical of celiac disease. Most of the patients had never been on gluten-free diets. The remainder, who had been on such diets at some time, were on unrestricted diets for at least several months prior to the time of biopsy. All patients displayed most of the features of malabsorption syndrome. Roentgenologic studies revealed an abnormal mucosal pattern in the small intestine. Fecal fat values were abnormal. Parasitic infection was excluded. Finally, a small intestinal biopsy was interpreted as compatible with celiac disease in all patients.

Group C: 10 children from Group B were biopsied after being on a gluten-free

---

From the Departments of Pathology and of Medicine, Albert Einstein College of Medicine, Bronx, N. Y.; the Hospital de Niños, Buenos Aires, Argentina; the Instituto de Gastroenterología, Institutos Nacionales de la Salud, Haedo, Argentina; and the Instituto de Biología y Medicina Experimental, Buenos Aires, Argentina.

Supported by grants from the U. S. Public Health Service (CA-06576, AM-10852-01A1, TIAM-5384), and the Argentine Research Council.

Preliminary reports of this study were presented at the Extraordinary Meeting of the Interamerican Association of Gastroenterology, Madrid, Spain, October 1966, and at the Annual Meeting of the Federation of American Societies for Experimental Biology, Chicago, Ill., April 1967.

Accepted for publication Jan. 10, 1968.

Address for reprint requests: Dr. Biempica, Department of Pathology, Albert Einstein College of Medicine, Yeshiva University, Eastchester Rd. and Morris Park Ave., Bronx, N. Y. 10461.

diet for 6 months or more. All showed dramatic clinical, roentgenologic and biochemical improvement at the time of the second biopsy.

Conventional light microscopy and cytochemical studies were performed on all biopsy specimens. The specimens from 6 normal, 12 untreated celiac, and 6 treated celiac patients were also studied by electron microscopy.

Biopsies were obtained following 14 hr. or more of fasting. The Crosby-Kugler capsule<sup>3</sup> was employed. Progression of the capsule through the intestine to the site of biopsy was determined by fluoroscopy. All specimens were obtained from the region of the ligament of Treitz. Just prior to biopsy, a small volume of warm (37°C.) saline was gently instilled through the tube to wash out mucus and detritus. The tissue was rapidly removed from the capsule, placed on a wax plate, and divided into 3 portions:

1. *For conventional light microscopy:* The tissue was positioned by placing its nonvillous surface on a piece of filter paper to facilitate orientation and sectioning, fixed in 4% formaldehyde or Bouin's fluid, and embedded in paraffin. Sections (5 $\mu$ ) were stained by hematoxylin-eosin and Lillie's Azure A-eosin<sup>29</sup> for morphologic study. Sections were also stained by the periodic acid-Schiff (PAS) reaction, with and without diastase digestion, for determination of the presence of glycogen. Masson's trichrome stain was used for study of connective tissue, and the Perls' reaction was employed for study of iron.<sup>29</sup> Neutral lipids were visualized in frozen sections, using oil red O or Sudan black B.<sup>29,30</sup>

2. *For enzyme cytochemistry:* The tissue was flattened on filter paper; fixed overnight at 4°C. in 4% neutralized formaldehyde containing 1% CaCl<sub>2</sub>,<sup>31</sup> or in 2.5% glutaraldehyde in 0.1 M cacodylate buffer, pH 7.4,<sup>32</sup> for 2 hr. at 4°C.; and rinsed overnight in the same buffer containing sucrose at 0.2 M final concentration. Frozen sections (10 $\mu$ ) were cut with a freezing microtome. These were incubated as free-floating sections at 37°C. to visualize enzymatic activities that serve as "markers"<sup>33,34</sup> for different cytoplasmic organelles as follows:

Plasma membrane: Nucleoside phosphatase with adenosinetriphosphate as substrate<sup>35</sup> for 15 and 30 min., and alkaline phosphatase<sup>30</sup> for 5, 15, and 30 min.

Endoplasmic reticulum: Nucleoside diphosphatase with inosine diphosphate as substrate<sup>36</sup> for 15 and 30 min.

Mitochondria: Reduced nicotinamide adenine dinucleotide-nitro blue tetrazolium, NADH-NBT (2,2'-di-p-nitrophenyl-5,5'-diphenyl-3,3'[p-biphenylene]-ditetrazolium chloride) or tetranitro blue tetrazolium, TNBT (2,2',5,5'-tetra-p-nitrophenyl-3,3'-[3,3'-dimethoxy-4,4'-diphenylene]-ditetrazolium chloride)-reductase<sup>37</sup> for 10 and 20 min.

Lysosomes: Acid phosphatase with  $\beta$ -glycerophosphate as substrate<sup>30</sup> for 15 and 30 min. To examine the enzymatic reaction product in the electron microscope, 25- $\mu$  frozen sections were incubated in the same medium, washed 3 times in 7.5% sucrose solution, post-fixed in osmium tetroxide in phosphate buffer,<sup>38</sup> and processed according to the method described below for electron microscopy.

Golgi apparatus: Thiamine pyrophosphatase, with thiamine pyrophosphate as substrate<sup>36</sup> for 15 and 45 min., and alkaline phosphatase with glycerophosphate as substrate<sup>30</sup> for 5, 15, and 30 min.

3. *For electron microscopy:* Small portions of the biopsies were immersed in cold 1% osmium tetroxide in phosphate buffer, pH 7.4,<sup>38</sup> for 1-2 hr. at 0-4°C. In some cases, tissue was also fixed in 3% glutaraldehyde-0.1 M cacodylate buffer, pH 7.4,<sup>32</sup> for 2-3 hr. at 0-4°C., and post-fixed in 1% osmium tetroxide-phosphate for 1-2 hr. After fixation, the tissues were rinsed in buffer, dehydrated in a series of ethanols, and embedded in Epon.<sup>39</sup> Thick sections (1.0-1.5  $\mu$ ) were cut to select appropriate areas (tips of villi) or to reorient the tissue in the block.

Thin sections were cut with diamond knives on a LKB Ultratome and mounted on naked copper grids. They were stained at room temperature with dilute alcoholic

solution of uranyl acetate<sup>40</sup> for 20–30 min., followed by lead citrate<sup>41</sup> for 15–30 min., and examined in a Siemens Elmiskop I at 80 kv.

## Results

The biopsy specimens usually included the entire thickness of the mucosa through the muscularis mucosa. The columnar epithelium of cells described are always those at the apex of the villi in the normal biopsies and those at the luminal surface (Zone 3 of Padykula *et al.*<sup>7</sup>) in biopsies of celiac patients.

### Normal Children

In specimens from normal children, the general architecture of the villi and glands (Fig. 1, 3, 4, 7, 10, and 13–15) is similar to that described in adults. The lamina propria is richly vascularized with prominent capillaries, and lymphatics forming most of the villus core. Some of the vessels are adjacent to the epithelial layer. Histiocytes, plasma cells, lymphocytes, eosinophils, and polymorphonuclear leukocytes are present throughout the lamina propria.

The columnar cells at the apices of the villi are 30–45  $\mu$  high and 6–10  $\mu$  wide, and their size and morphology do not vary significantly from the tip to the sides of the villus.

### Plasma Membrane and its Differentiations

**Luminal Surface.** The luminal surface stains strongly and evenly in the nucleoside phosphatase (Fig. 1), alkaline phosphatase (Fig. 3 and 4), and thiaminepyrophosphatase preparations. The staining stops abruptly at the entrance to the crypts of Lieberkühn. In formaldehyde-fixed tissues, the intensity of staining is similar for nucleoside phosphatase (with adenosine triphosphate as substrate) and alkaline phosphatase, and both are more active than nucleosidediphosphatase (with inosine diphosphate as substrate) and thiaminepyrophosphatase. With brief fixation, activity is seen following incubation in the acid phosphatase medium, but this may reflect residual activity of alkaline phosphatase at the low pH.

With the electron microscope, the microvilli are slender and regular, 1.4–1.8  $\mu$  high by 0.1–0.15  $\mu$  wide (Fig. 13). They are evenly arranged and roughly perpendicular to the cell surface. The delimiting unit membrane shows a dark inner layer. The cores of the villi contain a fibrillar system extending to the dense terminal webs. In fasted normal individuals the microvilli are covered by an even layer of fibrillar and granular material (“fuzz”<sup>42</sup>) as seen in Fig. 13.

**Apical Vesicles, Probably Pinocytotic Vesicles.** Vesicles of variable size are numerous at the apical surfaces of the cells. Probably some cor-

respond to the stained vacuoles seen beneath the striated border in nucleoside phosphatase, alkaline phosphatase, and PAS preparations. They are bounded by a unit membrane, and their content shows little or no electron density.

**Lateral Surfaces.** The lateral surfaces stain in both alkaline phosphatase and nucleosidephosphatase preparations (Fig. 4). Usually the staining is stronger at the sides of villi than at the apex. The lateral portions of plasma membrane in the principal cells of the glands are also stained.

The electron microscope shows lateral cell surfaces to be extensively folded, with the infoldings penetrating deeply into the cell (Fig. 13 and 15). In the supranuclear portion of the cell, the lateral membranes of adjacent cells are closely apposed to each other, whereas in the lower portion they are separated by wide spaces. Where the cells are closely apposed, both junctional complexes (Fig. 13) and individual desmosomes (Fig. 13 and 15) are present. The former are located at the apical end of the cell and the latter are situated more deeply, at variable intervals. The desmosomes show the complex structure described by Odland.<sup>43</sup> The intercellular space in these regions measures  $\sim 250 \text{ \AA}$ . It is bisected by an electron-dense line (Fig. 14, *BL*) and is delimited by the external leaflets of the adjoining plasma membranes (Fig. 14, *EL*). The internal leaflets (Fig. 14, *IL*) have a greater electron density than the external ones, as seen in the membranes of the microvilli. Apposed to the internal leaflet is a plaque of dense granular material. Fine fibrils generally converge to each side of the desmosome.

#### Endoplasmic Reticulum

In nucleosidediphosphatase preparations, the endoplasmic reticulum is strongly stained in the supranuclear portion of the columnar cells, especially in cells of the sides of the villus. Principal cells of the glands are usually more lightly stained than the absorptive cells.

Electron microscopy shows a moderately well-developed endoplasmic reticulum. The smooth endoplasmic reticulum predominates beneath the luminal surface (Fig. 15) and in the vicinity of the Golgi apparatus. It appears as short, dilated cisternae with a moderately dense content. Near the Golgi apparatus the endoplasmic reticulum takes the form of small, rounded cisternae with frequent fenestrations, similar to that of GERL \*<sup>44</sup> in other cell types.<sup>45,46</sup> In the basal half of the cell there are also small smooth cisternae dispersed among mitochondria. The granular endoplasmic reticulum is more abundant in the supranuclear than in the infranuclear cytoplasm. It appears usually as irregular cisternae, rounded or

\* Golgi-associated region of endoplasmic reticulum from which lysosomes apparently form.

elongated, with ribosomes attached at irregular intervals. Some rough cisternae are long, extending for several microns in the plane of the section. Ribosomal aggregates, including spirals, and free ribosomes are common (Fig. 15).

#### Golgi Apparatus

The Golgi apparatus is strongly stained in thiaminepyrophosphatase, nucleosidediphosphatase, and alkaline phosphatase preparations (Fig. 4). The organelle is less evident in the columnar cells at the very tip of the villus than in the cells of the sides of the villi; it is also prominent in the cells of the glands.

As observed by electron microscopy, the Golgi apparatus is extensive, sometimes seen across the width of the cell, extending from the nucleus to the lateral cell border. There are usually 3 or 4 parallel saccules, long ( $2-3 \mu$  in a section) and thin ( $250-300 \text{ \AA}$ ). One or 2 of the saccules, usually at the "forming face,"<sup>47</sup> have a denser content than the others. Vacuoles up to  $2-3 \mu$  in diameter are frequent, sometimes appearing as expansions of the saccules (Fig. 13). Small vesicles are numerous and may form clusters. In children fasted overnight, the Golgi saccules and vacuoles show no content except for the 1 or 2 saccules at the forming face which have a dense content.

#### Lysosomes

In acid phosphatase preparations, lysosomes are more abundant in the apex of the columnar cells. Darkly stained bodies are numerous below the striated border. Large lysosomes, with a diameter up to  $6 \mu$ , are common in the cells at the tips of the villi (Fig. 10); these are also stained in alkaline phosphatase preparations (Fig. 3). A few small lysosomes are found in the area of the Golgi apparatus, particularly in the cells at the sides of the villi.

Ultrastructurally, different types of lysosomes are identifiable. The large bodies of the columnar cells of the tip of the villi are autophagic vacuoles and contain cytoplasmic constituents (mitochondria, endoplasmic reticulum, ribosomes, lipid-like material, etc.). The most common type of lysosome is the dense body. This type prevails in the cells of the tip of the villi, as well as in those of the sides. These lysosomes may have bizarre shapes and contain a dense heterogeneous content. They are usually large, up to  $2-3 \mu$  delimited by a unit membrane, and contain dense granular material, fibrils, and myelin figures (Fig. 13, 15, and 16). A common feature is the presence of tail-like extensions (Fig. 15), bridge-like connections between 2 expansions, or signet rings. When sections are incubated for acid phosphatase activity and examined in the electron

microscope, these extensions show acid phosphatase activity (Fig. 16); they are probably portions of the smooth endoplasmic reticulum.

Multivesicular bodies are a third type of lysosome. They measure 0.5–1.0  $\mu$ . Most are located near the terminal web (Fig. 13 and 15). Some are also seen near the Golgi apparatus. They are bounded by a single membrane and display a dense matrix in which small vesicles are evident.

#### Mitochondria

NADH-NBT (or TNBT) preparations show intense staining of mitochondria in the columnar cells (Fig. 7). Occasionally, some cells at the extreme apex of the villus display weaker activity. With briefer incubations, the mitochondria are delineated.

Ultrastructurally, the intracellular distribution of mitochondria corresponds to the picture seen in NADH-NBT (or TNBT) preparations, with concentrations in the apical and basal parts of the cell. Most mitochondria are elongated and have diagonally oriented cristae. Dense granules are frequent in the matrix (Fig. 13 and 15).

#### Other Cytoplasmic Constituents

Fibrils are common in various areas of the columnar cell; they are most concentrated at the desmosomes. Microtubules are most easily seen in biopsies fixed in glutaraldehyde and postfixed in osmium tetroxide; they show no special localization. Glycogen, in the monoparticulate form, was found in columnar cells in only 2 cases. It is common in cells of the lamina propria. On one occasion it was found in a goblet cell of the villus. Lipid was not found in the epithelium by either light or electron microscopy. Lipid-like material was found in the histiocytes of the lamina propria.

#### Untreated Celiac Children

In the untreated celiac children the mucosa is characteristically flat with villi much blunted or absent (Fig. 2, 5, 8, 11, and 17). In the severely altered mucosa, areas are found in which epithelium is missing. The possibility cannot be excluded that this represents an artifact of the biopsy procedure or subsequent manipulation.

Where blunted villa are preserved, the ratio of villus to gland size is markedly diminished. The gland lumen is dilated and frequently contains debris. The lamina propria is invariably infiltrated by plasma cells and lymphocytes. This cellular infiltrate is more extensive than that reported in the adult celiac disease.<sup>13,15</sup> As a consequence, the vessels are less prominent than in the normal. Migrating cells infiltrate the epithelial layer in large numbers (Fig. 5).

The absorptive cells are markedly abnormal, no longer columnar, and contain numerous vacuoles. The striated border is inconspicuous or absent.

#### Plasma Membrane and its Differentiations

*Luminal Surface.* Similar results are obtained from nucleoside phosphatase (Fig. 2), alkaline phosphatase (Fig. 5), thiamine pyrophosphatase, and nucleoside diphosphatase activities. Staining is slight and uneven and, in some areas, totally absent. The loss of activity is greatest in the most-damaged tissues (Fig. 2). The apical portions of the glands are stained in the alkaline phosphatase preparations (Fig. 5), and to a lesser degree in the nucleosidephosphatase preparations.

The electron microscope shows microvilli to be present in the less-altered areas. They are short, unevenly spaced, and not perpendicular to the cell surface. The fuzz is diminished and uneven. Some microvilli show the inner fibrillar structure. In the very damaged areas, microvilli are absent and the fuzz is missing (Fig. 17).

*Apical Vesicles, Probably Pinocytotic Vesicles.* Apical vesicles, which are common in columnar cells of normal controls, are rarely encountered in specimens from patients with celiac disease. They are virtually absent from the severely damaged cells.

*Lateral Infoldings.* Staining of phosphatases is greatly diminished or absent in the villi, and present in the gland cells but to a lesser extent than in normal controls.

By electron microscopy, the membranes are straight or slightly curved in most cases. The junctional complexes are less apparent, but the desmosomes persist even in highly altered cells. The converging fibrils are preserved (Fig. 17).

#### Endoplasmic Reticulum

Nucleosidediphosphatase preparations show little or no staining of the cytoplasm. The principal cells of the glands show staining in most cases. As seen by electron microscopy, the smooth endoplasmic reticulum is absent except in less-damaged cells. The rough endoplasmic reticulum lacks its flattened cisternae and is composed of dilated vacuoles containing material of medium density (Fig. 17). Free ribosomes, often organized in clusters or spirals, are common and are dispersed throughout the cytoplasm (Fig. 17).

#### Golgi Apparatus

In thiaminepyrophosphatase, nucleosidediphosphatase, and alkaline phosphatase preparations, the Golgi apparatus is rarely seen in the cells

of the surface epithelium. The dark staining of the plasma membrane of migrating cells makes the identification of the Golgi structures difficult. In the gland cells, the Golgi apparatus stains irregularly and is fragmented.

With the electron microscope, the Golgi apparatus is not seen in the much-altered columnar cells (Fig. 17). The less-altered epithelial cells have remnants of Golgi saccules in the supranuclear region of the cell.

#### Lysosomes

In the severely damaged columnar cells, acid phosphatase-rich bodies are decreased in number or even absent (Fig. 11). Where atrophic villi are present, lysosomes are more numerous in the cells of the sides than in the cells of the tip of the villi. The lysosomes associated with Golgi apparatus in normal cells are not seen in the mucosa from celiac patients.

By electron microscopy, autophagic vacuoles with recognizable organelles are seen. Dense bodies and multivesicular bodies are uncommon in damaged cells. A few of the dense bodies show the tail-like and bridge-like extensions and, rarely, signet ring extensions.

#### Mitochondria

NADH-NBT (or TNBT) results vary with the extent of the damage to the epithelial cells. Much-altered cells show either no staining or scattered dots with low activity.

In the less-damaged cells, the stain is concentrated above the nucleus with little staining in the infranuclear zone (Fig. 8). The cells of the crypts of Lieberkhün stain strongly, especially those at the bottom of the gland.

By electron microscopy, the number of mitochondria is markedly diminished, especially in the much-altered cells (Fig. 17). They have a less-dense matrix and few cristae that are usually displaced to the periphery. Most mitochondria tend to be round.

#### Other Cytoplasmic Constituents

The fibrils are remarkably well preserved, even in the severely damaged cells (Fig. 17), and they remain concentrated in the vicinity of the desmosomes. Microtubules are rarely seen. Glycogen is not found in columnar cells but is present in cells of the lamina propria. Lipid-like material is not detectable in the columnar cells of celiac patients. It is present in some cells of the lamina propria.

*Celiac Children on Gluten-free Diets.* In treated children with celiac disease, the mucosa tends to revert toward a normal appearance. How-



ever, an entirely normal pattern is not seen. Most villi are shorter and broader than normal. Also, the mucosa differs from normal in the persistence of a variable degree of cellular infiltrate in the lamina propria (Fig. 12), in which plasma cells and lymphocytes predominate (Fig. 21). The vessels in the lamina propria remain less prominent than in the controls.

Villi are present and are lined by a uniform epithelial layer. The basement membrane is distinct and even. Columnar cells are entirely within normal limits in their size and shape. Cytochemical (Fig. 6, 9, and 12) and ultrastructural features (Fig. 18-20) do not differ from those in normal controls.

### Discussion

By electron microscopic examination and cytochemical staining procedures for enzyme activities, the columnar cells of the normal intestinal mucosa of the children we have studied are the same as those of adults, as previously described<sup>4-9,12-21,23,24</sup> and as studied in our laboratory.

The changes encountered in celiac children are similar to those described in celiac adults,<sup>4-15,17-24</sup> but are more severe. Reduction in the height and number of the microvilli is more marked and is associated with the diminution or absence of the luminal "coat" or fuzz. The endoplasmic reticulum, Golgi apparatus, and lysosomes show more extensive alterations than in adults. Shiner,<sup>48</sup> on the basis of light microscopic studies, considered the mucosal damage in celiac children to be greater than in adults, but Anderson and Townley<sup>49</sup> did not share this view. Clinically, the children that we studied were more severely ill than adult patients, and their massive diarrhea was commonly associated with hypocalcemia, frequent episodes of tetany, hypoproteinemia, and marked abdominal distention. The reduction or absence of microvilli and alkaline phosphatase and other phosphatase activities associated with microvilli may well account for the impaired absorption of a variety of substances. Our findings concerning alkaline phosphatase are in agreement with recent cytochemical observations<sup>5,23</sup> and biochemical studies.<sup>50,51</sup> Conflicting results have been reported in adults<sup>17,18</sup> including one combined cytochemical and ultrastructural study by Padykula *et al.*<sup>7</sup> These investigators reported that alkaline phosphatase activity seemed undiminished in the surface epithelium of the celiac patient. The reduction of activity and, in some areas, the absence of alkaline phosphatase that we have observed appears to be related to the more marked microvillar changes in our patients. Jos *et al.*<sup>27</sup> reported normal alkaline phosphatase activity in children with celiac disease; however, ultrastructural studies were not done and therefore the microvilli cannot be evaluated.

Our studies emphasize the remarkable return of the mucosal epithelium to normal when celiac children are treated with gluten-free diets. Previous studies have reported the recovery of microvilli in adults.<sup>6,8,10-12,16,21</sup> The recovery appears more striking in our material, perhaps because the children were on strict gluten-free diets for at least 6 months. The ultrastructure of the columnar cells of the celiac children on a gluten-free diet were indistinguishable from that of the normal controls, and this corresponded to a return to normal of the cytochemically demonstrable enzymatic activities associated with different organelles. Reports in the literature<sup>18,20,26</sup> of the failure of some enzyme activities to return completely to normal may reflect the insufficient duration<sup>23,27</sup> or strictness of the gluten-free diets.

The striking recovery of the columnar cells on gluten-free diets contrasts with the failure of the general architecture of the villi to return completely to normal. Similar findings have been reported in children<sup>27,52-54</sup> and adults.<sup>53,55</sup> The lamina propria remains infiltrated with numerous plasma cells, lymphocytes, and histiocytes, resulting in distortion of the villus architecture and separation of the glands. The capillaries in the villus cores are less prominent. The persistence of plasma cells suggests a chronic reaction of stromal elements, even in the absence of dietary gluten or a toxic subfraction.

In recent years it has been suggested that the prime etiologic factor in celiac disease is a genetic absence of intestinal peptidase<sup>56,57</sup> required for the hydrolysis of gluten. Since the nature and cytologic site of this enzyme in normal mucosa has not been established, our failure to find differences in the columnar cells of celiac children on a gluten-free diet and of normal controls is not necessary incompatible with this suggestion.

The mechanism by which a toxic factor in the gluten gains access to the columnar cells, and subsequently the lamina propria, is still unknown. Whole proteins are probably not absorbed by columnar cells past the neonatal period,<sup>58</sup> but the toxic fraction of gluten may be a small polypeptide and the absence of a specific peptidase may account for the events leading to the intestinal lesions described above. Our results suggest that an understanding of the pathogenetic process in celiac disease must include an appreciation of the cellular response in the lamina propria. It is possible that the increased cellularity in the lamina propria persisting in our treated celiac patients is a response to small quantities of toxic material still present in the presumed gluten-free diet. Plasma cells and lymphocytes constitute the bulk of this cell population. The significance of these cells in celiac disease remains unknown.

### Summary

Cytochemical and electron microscopic studies of columnar cells of small-intestine biopsies from untreated celiac children revealed variable abnormalities. Changes affected all cytoplasmic organelles. Staining of the striated border for nucleoside phosphatase and alkaline phosphatase activities was diminished. Microvilli were absent from many cells; where present, they were less numerous and shorter than in cells of normal specimens. The endoplasmic reticulum stained weakly for nucleoside diphosphatase activity. Smooth membranes were infrequent. Granular cisternae were rarely found; when present, they were dilated. Free ribosomes were numerous. The Golgi apparatus showed irregular and weak staining for thiamine pyrophosphatase. Lysosomes were less numerous than in controls. The mitochondria were fewer than in normal specimens and their staining for NADH-tetrazolium reductase was reduced.

Repeat biopsies of children with celiac disease who were treated with a gluten-free diet showed columnar cells which were indistinguishable from those of normal controls. In contrast to the recovery of the columnar cells, the mucosa tended to remain flattened and the infiltration of the lamina propria persisted.

### References

1. ROYER, M., CROXATTO, O., BIEMPICA, L., and BALCÁZAR MORRISON, A. J. Biopsia duodenal por aspiración bajo control radioscópico. *Prensa Med Argent* 42:2515-2519, 1955.
2. SHINER, M. Jejunal-biopsy tube. *Lancet* 1:85, 1956.
3. CROSBY, W. H., and KUGLER, H. W. Intraluminal biopsy of the small intestine: The intestinal biopsy capsule. *Amer J Dig Dis* 2:236-241, 1957.
4. HARTMAN, R. S., BUTTERWORTH, C. E., HARTMAN, R. E., CROSBY, W. H., and SHIRAI, A. An electron microscopic investigation of the jejunal epithelium in sprue. *Gastroenterology* 38:506-516, 1960.
5. BOLT, R. J., POLLARD, H. M., and MCCOOL, S. Staining of enzymes in mucosa of the small bowel, using a peroral biopsy tube. *Amer J Clin Path* 34:43-49, 1960.
6. ZETTERQVIST, H., and HENDRIX, T. R. A preliminary note on an ultrastructural abnormality of the intestinal epithelium in adult celiac disease (nontropical sprue) which is reversed by a gluten-free diet. *Bull Hopkins Hosp* 106:240-249, 1960.
7. PADYKULA, H. A., STRAUSS, E. W., LADMAN, A. J., and GARDNER, F. H. A morphological and histochemical analysis of the human jejunal epithelium in nontropical sprue. *Gastroenterology* 40:735-765, 1961.
8. SHINER, M., and BIRBECK, M. S. C. The microvilli of the small intestinal surface epithelium in coeliac disease and idiopathic steatorrhoea. *Gut* 2:277-284, 1961.
9. ASHWORTH, C. T., CHEARS, W. C., JR., SANDERS, E., and PEARCE, M. B. Nontropical sprue: Fine structure of the intestinal epithelial lesion. *Arch Path (Chicago)* 71:13-19, 1961.

10. ASHWORTH, C. T., and CHEARS, W. C., JR. Follow-up of intestinal biopsy in nontropical sprue after gluten-free diet and remission. *Fed Proc* 21:880-890, 1962.
11. RUBIN, C. E., BRANDBOG, L. L., FLICK, A. L., MACDONALD, W. C., PARKINS, R. A., PARMENTIER, C. M., PHELPS, P., SRIBHIBHADH, S., and TRIER, J. S. "Biopsy Studies on the Pathogenesis of Celiac Sprue." In *Intestinal Biopsy, Ciba Foundation Study Group 14*. Little, Boston, 1962, pp. 67-83.
12. SHINER, M., LACY, D., and HUDSON, R. H. "Electron Microscope Study of Fat Absorption in Normal Subjects and in Patients with Idiopathic Steatorrhea." In *Intestinal Biopsy, Ciba Foundation Study Group 14*. Little, Boston, 1962, pp. 24-36.
13. SHEARMAN, D. J. C., GIRDWOOD, R. H., WILLIAMS, A. W., and DELAMORE, I. W. A study with the electron microscope of the jejunal epithelium in primary malabsorptive disease. *Gut* 3:16-25, 1962.
14. RYBAK, B. J., and ADLESBERG, D. Estudio electromicroscópico de las células columnares del intestino delgado humano normal y mala absorción. *Prensa Med Argent* 50:746-753, 1963.
15. CURRAN, R. C., and CREAMER, B. Ultrastructural changes in some disorders of the small intestine associated with malabsorption. *J Path Bact* 86:1-8, 1963.
16. TRIER, J. S., PHELPS, P. C., and RUBIN, C. E. Electron microscopy of mucosa of small intestine. *JAMA* 183:768-774, 1963.
17. PLOSSOWE, R. P., BERG, G. G., and SEGAL, H. L. Enzyme histochemical studies of human gastric and jejunal biopsy specimens in normal and disease states. *Amer J Dig Dis* 8:311-318, 1963.
18. SPIRO, H. M., FILIPE, M. I., STEWART, J. S., BOOTH, C. C., and PEARSE, A. G. E. Functional histochemistry of the small bowel mucosa in malabsorptive syndromes. *Gut* 5:145-154, 1964.
19. SCHENK, E. A., SAMLOFF, I. M., and KLIPSTEIN, F. A. Morphologic characteristics of jejunal biopsy in celiac disease and tropical sprue. *Amer J Path* 47:765-781, 1965.
20. SAMLOFF, I. M., DAVIS, J. S., and SCHENK, E. A. A clinical and histochemical study of celiac disease before and during a gluten-free diet. *Gastroenterology* 48:155-172, 1965.
21. TRIER, J. S., and RUBIN, C. E. Electron microscopy of the small intestine: A review. *Gastroenterology* 49:574-603, 1965.
22. RUBIN, W., ROSS, L. L., SLEISENGER, M. H., and WESER, E. An electron microscopic study of adult celiac disease. *Lab Invest* 15:1720-1747, 1966.
23. RIECKEN, E. O., STEWART, J. S., BOOTH, C. C., and PEARSE, A. G. E. A histochemical study on the role of lysosomal enzymes in idiopathic steatorrhea before and during a gluten-free diet. *Gut* 7:317-332, 1966.
24. TRIER, J. S. Structure of the mucosa of the small intestine as it relates to intestinal function. *Fed Proc* 26:1391-1404, 1967.
25. NUNEZ-MONTIEL, O., BAUZA, C. A., BRUNSER, O., and SEPÚLVEDA, H. Ultrastructural variations of the jejunum in the malabsorption syndrome. *Lab Invest* 12:16-24, 1963.
26. SHELDON, W., and TEMPANY, E. Small intestine peroral biopsy in celiac children. *Gut* 7:481-489, 1966.
27. JOS, J., FRÉZAL, J., REY, J., and LAMY, M. Étude histochimique de la muqueuse duodéno-jéjunale dans la maladie coeliaque. *Pediat Res* 1:27-38, 1967.
28. VAN DE KAMER, J. H., HUININK, H. TEN B., and WEYERS, H. A. Rapid method for the determination of fat in feces. *J Biol Chem* 177:347-355, 1949.
29. LILLIE, R. D. *Histopathologic Technic and Practical Histochemistry*. McGraw-Hill, New York, 1954.

30. GOMORI, G. *Microscopic Histochemistry: Principles and Practice*. Univ Chicago Press, Chicago, 1952.
31. BAKER, J. R. The histochemical recognition of lipine. *Quart J Micr Sci* 87: 441-470, 1946.
32. SABATINI, D. D., BENSCH, K., and BARNETT, R. J. Cytochemistry and electron microscopy: The preservation of cellular ultrastructure and enzymatic activity by aldehyde fixation. *J Cell Biol* 17:19-58, 1963.
33. GOLDFISCHER, S., ESSNER, E., and NOVIKOFF, A. B. The localization of phosphatase activities at the level of ultrastructure. *J Histochem Cytochem* 12:72-95, 1964.
34. NOVIKOFF, A. B., and ESSNER, E. Pathological changes in cytoplasmic organelles. *Fed Proc* 21:1130-1142, 1962.
35. WACHSTEIN, M., and MEISEL, E. Histochemistry of hepatic phosphatases at a physiological pH with special reference to the demonstration of bile canaliculi. *Amer J Clin Path* 27:13-23, 1957.
36. NOVIKOFF, A. B. and GOLDFISCHER, S. Nucleoside diphosphatase activity in the Golgi apparatus and its usefulness for cytological studies. *Proc Nat Acad Sci USA* 47:802-810, 1961.
37. NOVIKOFF, A. B., SHIN, W. Y., and DRUCKER, J. Mitochondrial localization of oxidative enzymes: Staining results with two tetrazolium salts. *J Biophys Biochem Cytol* 9:47-61, 1961.
38. MILLONIG, G. "Further Observations on a Phosphate Buffer for Osmium Solutions in Fixation." BREESE, S. S., JR. Ed. In *Fifth International Congress for Electron Microscopy* (Vol. 2, P8). Acad. Press, New York, 1962.
39. LUFT, J. H. Improvements in epoxy resin embedding methods. *J Biophys Biochem Cytol* 9:409-414, 1961.
40. WATSON, M. L. Staining of tissue sections for electron microscopy with heavy metals. *J Biophys Biochem Cytol* 4:475-478, 1958.
41. REYNOLDS, E. S. The use of lead citrate at high pH as an electron-opaque stain in electron microscopy. *J Cell Biol* 17:208-212, 1963.
42. ITO, S. The enteric surface coat on cat intestinal microvilli. *J Cell Biol* 27:475-491, 1965.
43. ODLAND, G. F. The fine structure of the interrelationship of cells in the human epidermis. *J Biophys Biochem Cytol* 4:529-538, 1958.
44. NOVIKOFF, A. B. GERL, its form and function in neurons of rat spinal ganglia. (abst.). *Biol Bull* 127:358, 1964.
45. NOVIKOFF, A. B., ROHEIM, P. S., and QUINTANA, N. Changes in rat liver cells induced by orotic acid feeding. *Lab Invest* 15:27-49, 1966.
46. HOLTZMAN, E., NOVIKOFF, A. B., and VILLAVARDE, H. Lysosomes and GERL in normal and chromatolytic neurons of the rat ganglion nodosum. *J Cell Biol* 33:419-436, 1967.
47. MOLLENHAUER, H. H., and WHALEY, W. G. An observation of the functioning of the Golgi apparatus. *J Cell Biol* 17:222-225, 1963.
48. SEINER, M. (In discussion of ANDERSON, C. M., and TOWNLEY, R. R. W.) "The Effects of a Gluten-free Diet on Intestinal Histology in Celiac Disease." In *Intestinal Biopsy, Ciba Foundation Study Group 14*. Little, Boston, 1962, pp. 39-53.
49. ANDERSON, C. M., and TOWNLEY, R. R. W. "The Effects of a Gluten-free Diet on Intestinal Histology in Celiac Disease." In *Intestinal Biopsy, Ciba Foundation Study Group 14*. Little, Boston, 1962, pp. 39-53.
50. PLOTKIN, G. R., and ISSELBACHER, K. J. Secondary disaccharidase deficiency in adult celiac disease (nontropical sprue) and other malabsorption states. *New Eng J Med* 271:1033-1037, 1964.

51. WELSH, J. D., ROHRER, G. V., DREWRY, R., MAY, J. C., and WALKER, A. Human intestinal disaccharidase activity: II. Diseases of the small intestine and deficiency states. *Arch Intern Med (Chicago)* 117:495-503, 1966.
52. ANDERSON, C. M. Histological changes in the duodenal mucosa in celiac disease. *Arch Dis Child* 35:419-427, 1960.
53. RUBIN, C. E., BRANDBORG, L. L., PHELPS, P. C., TAYLOR, H. C., MURRAY, C. V., STEMLER, R., HOWRY, C., and VOLWYLER, W. Studies of celiac disease: II. The apparent irreversibility of the proximal intestinal pathology in celiac disease. *Gastroenterology* 38:517-532, 1960.
54. CAMERON, A. H., ASTLEY, R., HALLOWELL, M., RAWSON, A. B., MILLER, C. G., FRENCH, J. M., and HUBBLE, D. V. Duodenal-jejunal biopsy in the investigation of children with celiac disease. *Quart J Med* 31:125-140, 1962.
55. MACDONALD, W. C., BRANDBORG, L. L., FLICK, A. L., TRIER, J. S., and RUBIN, C. E. Studies of celiac sprue: IV. The response of the whole length of the small intestine to a gluten-free diet. *Gastroenterology* 47:573-589, 1964.
56. KRAINICK, H. G., and MOHN, G. Weitere Untersuchungen über den schädlichen Weizenmehleffekt bei der Cöliakie. 2. Die Wirkung der enzymatischen Abbauprodukte des Gliadin. *Helv Paediat Acta* 14:124-140, 1959.
57. KOWLESSAR, O. D., and SLEISENGER, M. H. The role of gliadin in the pathogenesis of adult celiac disease. *Gastroenterology* 44:357-362, 1963.
58. CLARK, S. L., JR. The ingestion of proteins and colloidal materials by columnar absorptive cells of the small intestine in suckling rats and mice. *J Biophys Biochem Cytol* 5:41-50, 1959.
59. HUGON, J., and BORGERS, M. Ultrastructural localization of alkaline phosphatase activity in the absorbing cells of the duodenum of mouse. *J Histochem Cytochem* 14:629-640, 1966.
60. FARQUHAR, M. G., and PALADE, G. E. Junctional complexes in various epithelia. *J Cell Biol* 17:375-412, 1963.
61. BIEMPICA, L., KOSOWER, N. S., and NOVIKOFF, A. B. Cytochemical and ultrastructural changes in rat liver in experimental porphyria: I. Effects of a single injection of allylisopropylacetamide. *Lab Invest* 17:171-189, 1967.

The authors wish to thank Miss Amalia Casco and Miss Myrna Lozzio for the light microscopic preparations, Mrs. Stella Biempica for assistance with the electron microscopy, and Mr. Jack Godrich for the preparation of the photographs. We also wish to thank Dr. Alfred A. Angrist, Dr. Michael I. Cohen, Dr. Sidney Goldfischer, and Dr. Alex B. Novikoff for their critical review of the manuscript.

[ *Illustrations follow* ]

### Legends for Figures

**Fig. 1.** Biopsy from normal control. Frozen section incubated for nucleoside phosphatase activity with ATP as substrate, 30 min. at 37°C. Strong uniform staining of striated border (arrows). Note slender shape of villi.  $\times 140$ .

**Fig. 2.** Biopsy from untreated celiac patient. Frozen section incubated for nucleoside phosphatase with ATP as substrate, 30 min. at 37°C. Striated border is almost completely unstained. Only short areas of brush border (arrows) and apical portion of some glands show irregular stain. Note strong staining of vessels of muscularis mucosa (V).  $\times 140$ .

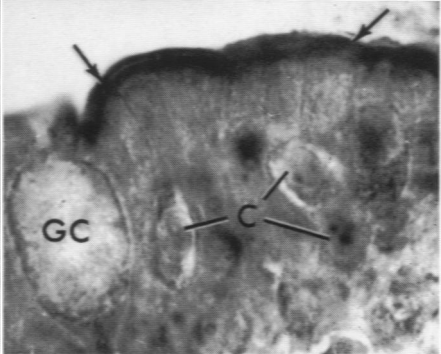
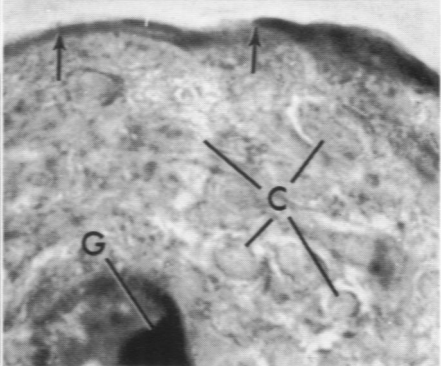
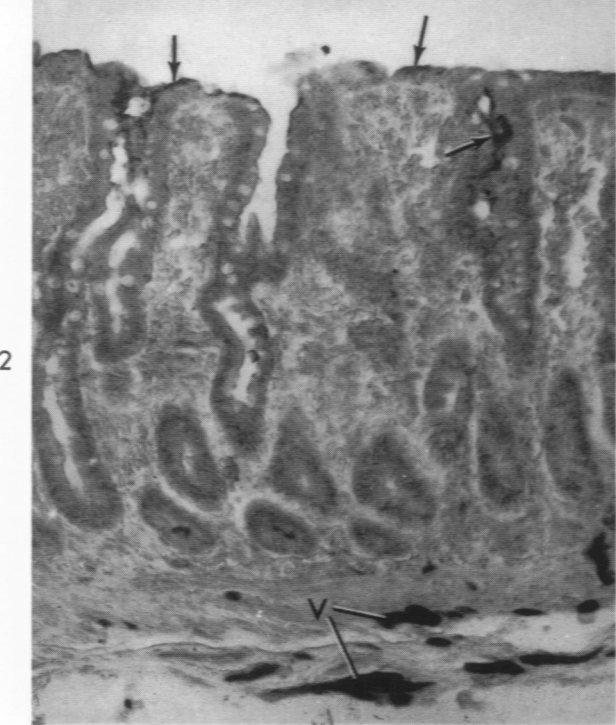
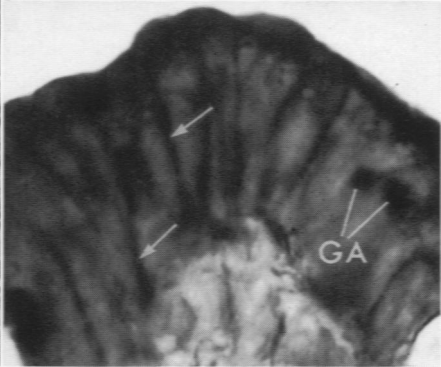
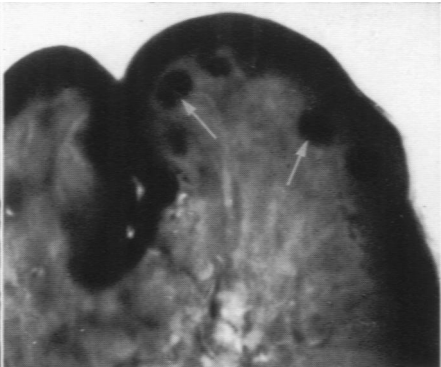
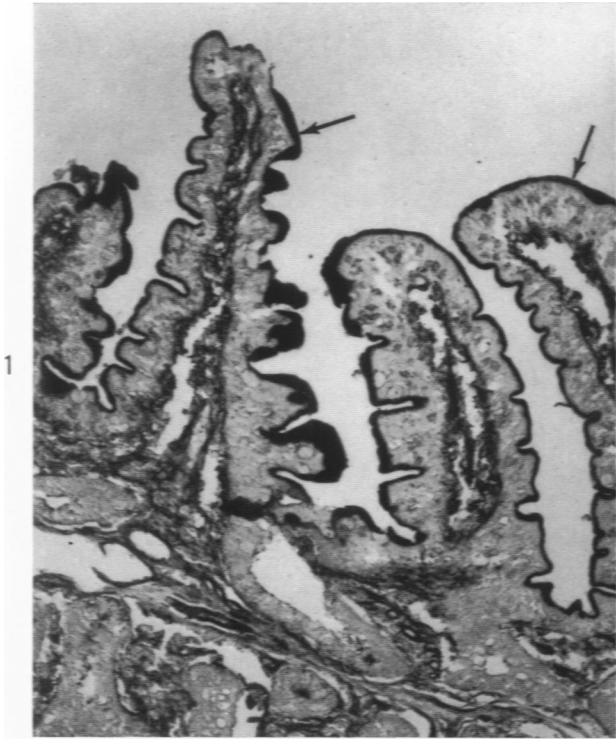**Fig. 3.** Biopsy from normal control. Frozen section incubated for alkaline phosphatase activity, 30 min. at 37°C. Striated border is strongly stained, as are some granules beneath the free surface (arrows) which probably represent large lysosomes.<sup>10</sup>  $\times 1200$ .

**Fig. 4.** Biopsy from normal control. Frozen section incubated as in Fig. 3. In addition to staining of striated border, there is marked activity in lateral portions of plasma membrane (arrows) and in Golgi apparatus of columnar cells (GA).  $\times 1200$ .

**Fig. 5.** Biopsy from untreated celiac patient. Frozen section incubated for alkaline phosphatase, 30 min. at 37°C. This is an area of very flat mucosa. Staining of free border is weaker and more uneven (arrows) than those of normal controls (Fig. 3 and 4). Note staining in gland lumen (G), and infiltration of epithelial layer by migrating cells (C).  $\times 1200$ .

**Fig. 6.** Biopsy from celiac patient under treatment. Frozen section processed as Fig. 3–5. Striated border is strongly and evenly stained (arrows). Stain is only interrupted by presence of a goblet cell (GC). Columnar cells show normal sizes and shapes. Infiltration (C) of epithelium persists.  $\times 1200$ .





**Fig. 7.** Biopsy from normal control. Frozen section incubated in medium for NADH-tetrazolium reductase, 10 min. at 37°C. This micrograph of villus apex shows strong and even staining of columnar cells, with heavy accumulation of formazan product at apical portion and at bottom of cells (arrows). Note unstained striated border (SB) and nucleus (N), and theca of a goblet cell (GC). LP, lamina propria.  $\times 1100$ .

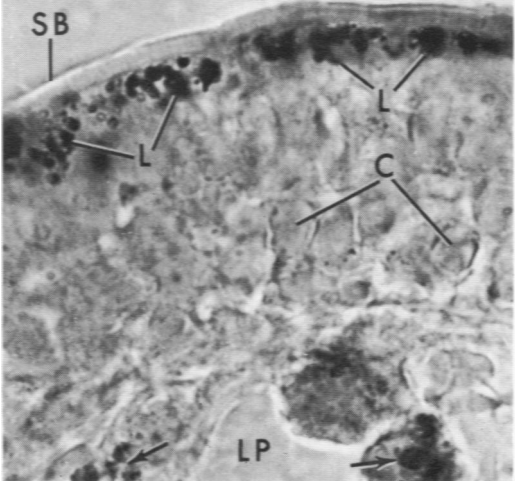
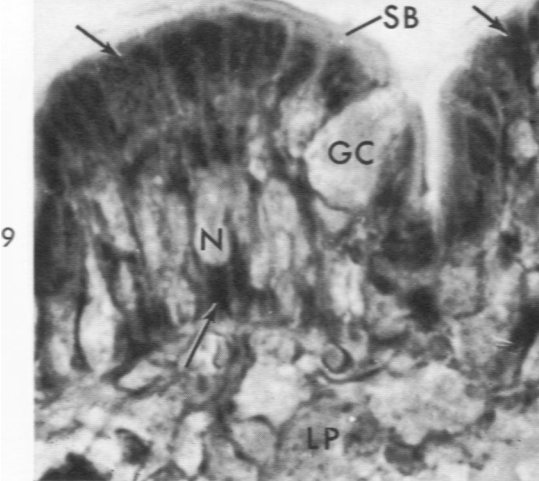
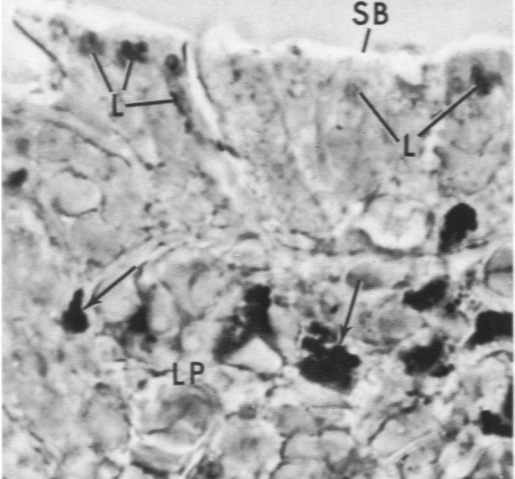
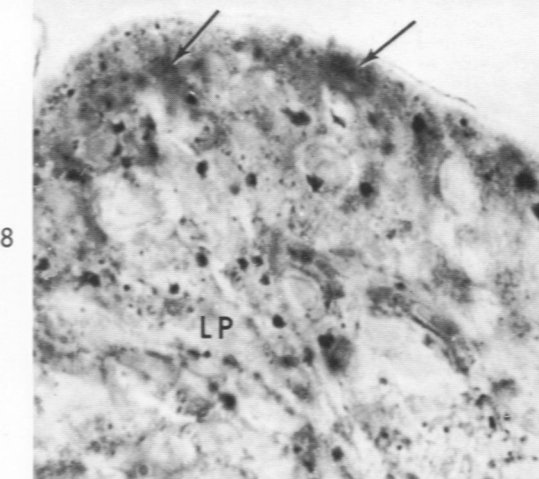
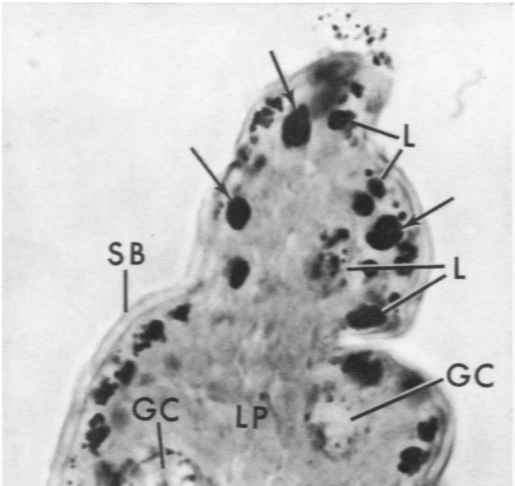
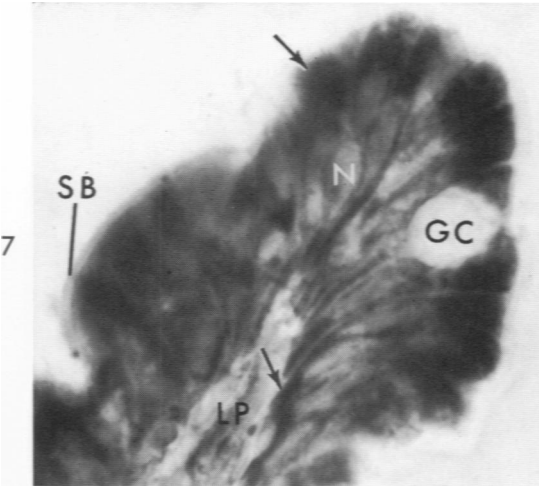
**Fig. 8.** Biopsy from untreated celiac patient. Frozen section processed as in Fig. 7. Staining is irregular and weak. Arrows indicate light staining of apical portions of columnar cells, LP, lamina propria.  $\times 1100$ .

**Fig. 9.** Biopsy from celiac patient on gluten-free diet. Frozen section processed as in Fig. 7. Strong and uniform staining of columnar cells is evident; arrows point to apical and basal regions of cell. Theca of goblet cell is unstained (GC). Despite flat appearance of the mucosa, columnar cells look normal (compare Fig. 7). Nuclei (N) and striated border (SB) are unstained. LP, lamina propria.  $\times 1100$ .

**Fig. 10.** Biopsy from normal control. Frozen section incubated for acid phosphatase, 15 min. at 37°C. Strong staining of acid phosphatase-rich bodies (variable in size) is evident in apical portion of columnar cells (L). In cells near tip of villus there are some (usually 1 per section of a cell) very large lysosomes (arrows). They also appear when incubated for alkaline phosphatase activity (compare Fig. 3). Note small lysosomes surrounding theca of goblet cells (GC) and unstained striated border (SB). LP, lamina propria.  $\times 1100$ .

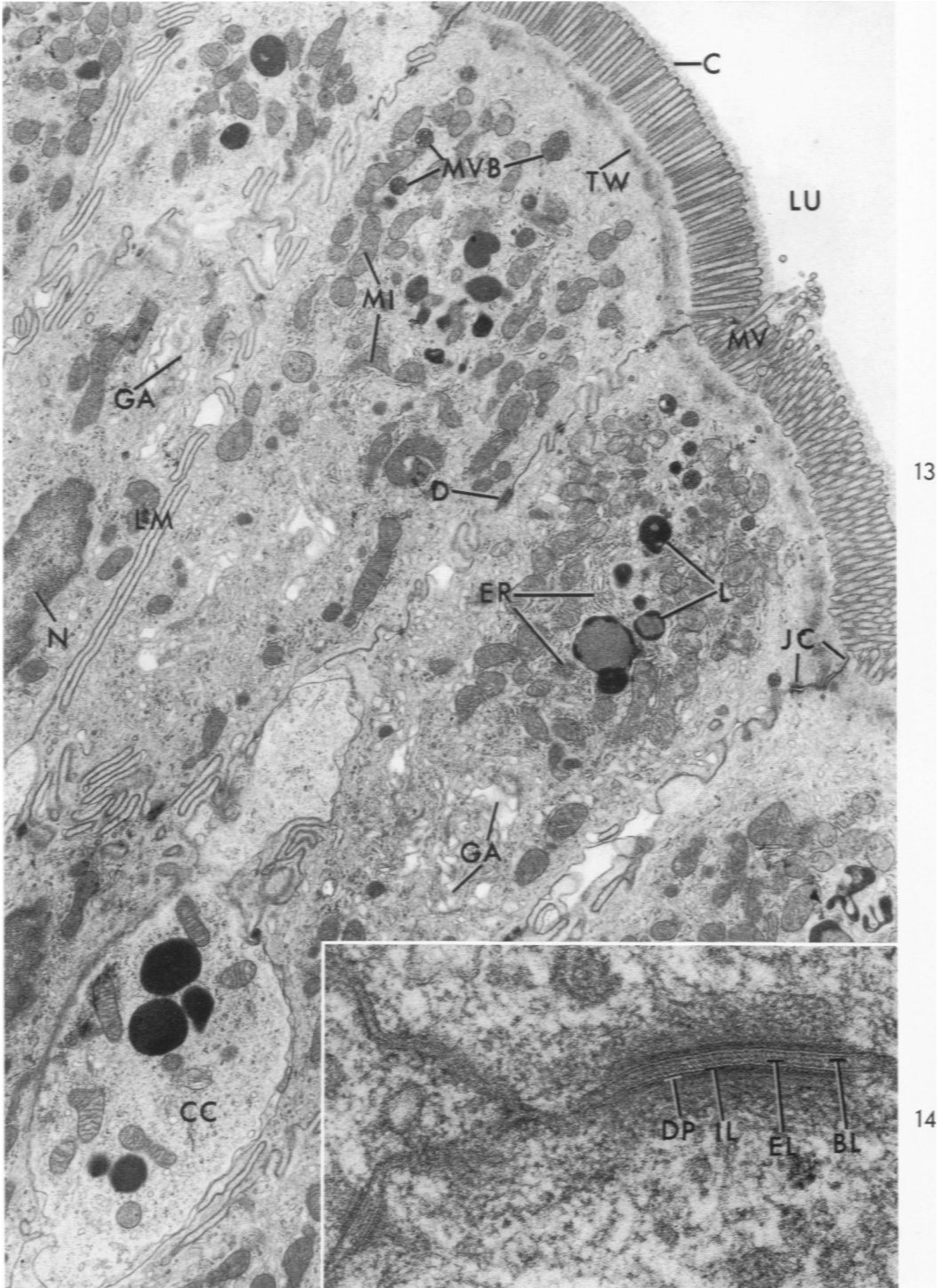
**Fig. 11.** Biopsy from untreated celiac patient. Frozen section processed as in Fig. 10. Only a few cells show scattered lysosomes (L). This contrasts with strong staining of connective tissue cells, probably histiocytes (arrows) of lamina propria (LP). SB, striated border.  $\times 1100$ .

**Fig. 12.** Biopsy from celiac patient on gluten-free diet. Frozen section processed as in Fig. 10. Columnar cells show numerous and strongly stained lysosomes (L). Most are concentrated below unstained striated border (SB). Lamina propria (LP) show some heavily stained cells (arrows). Note infiltration of epithelium (C).  $\times 1100$ .



**Fig. 13.** Biopsy from normal control. Epithelial cells of villus tip. Several columnar cells are facing intestinal lumen (LU). A uniform and even coat (C) covers slender, regular, and evenly spaced microvilli (MV). Plasma membranes at lateral portions of cell (LM) present different specializations: apical junctional complex<sup>sm</sup> (JC), desmosomes (D), complex system of interlocking membranes alternating with straight segments, and separations to form large spaces in which connective tissue cells (CC) are frequently seen. In apical cytoplasm, the terminal web is seen as a uniformly dense band (TW). Below it, apical cytoplasm is practically free of organelles. Supranuclear cytoplasm presents many mitochondria (MI), lysosomes of the dense-body (L) and multivesicular-body types (MVB). Among these organelles, the abundant endoplasmic reticulum (ER) is barely visible at this magnification. The Golgi apparatus (GA) is well developed. Portion of a nucleus (N) is seen. Fixed in osmium-phosphate; stained with uranium and lead.  $\times 7000$ .

**Fig. 14.** Biopsy from a normal control. One type of plasma membrane specialization, the desmosome, is seen. Unit membranes are evident with their internal leaflet (IL) and external leaflet (EL). The condensed line bisecting the space<sup>as,sm</sup> is shown at BL, and dense plaques of granular material at DP. Fixed in osmium-phosphate; stained with uranium and lead.  $\times 68,000$ .

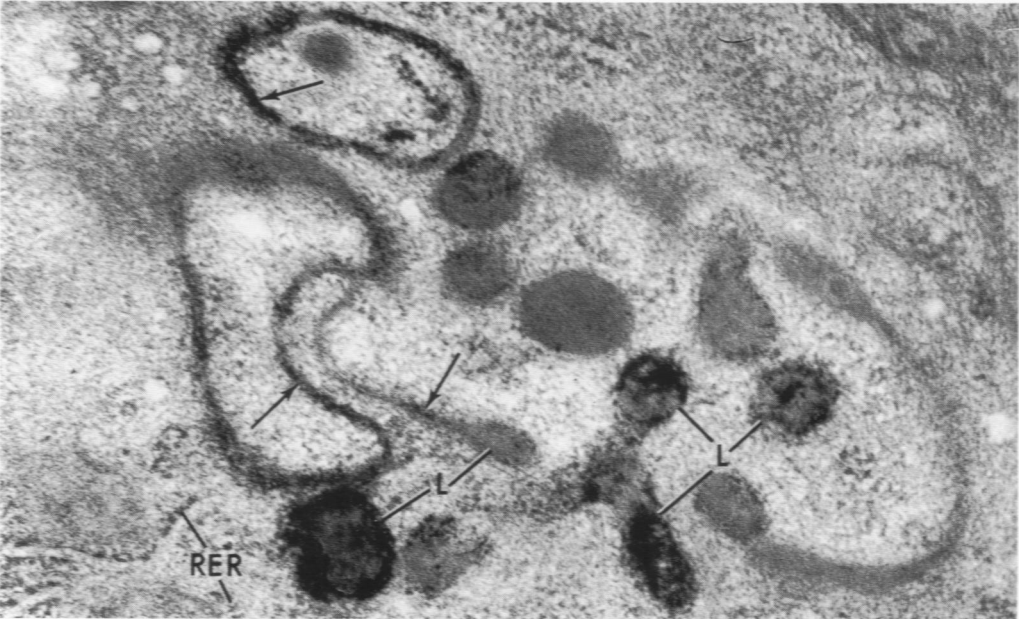
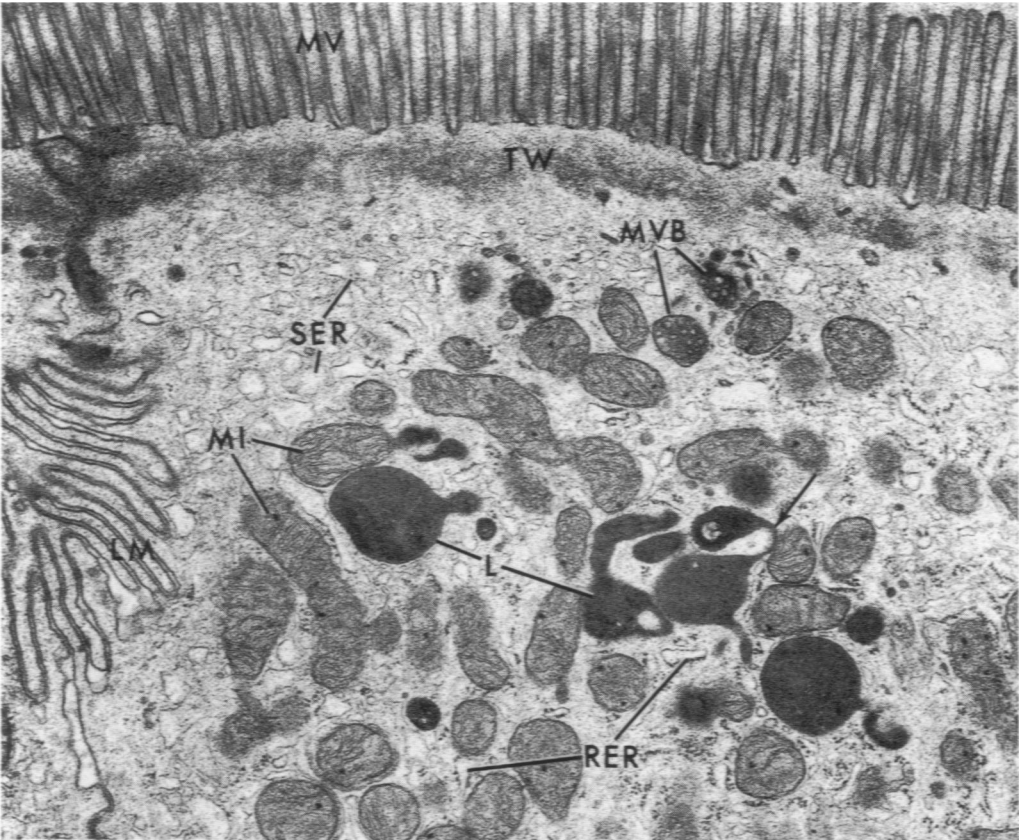


13

14

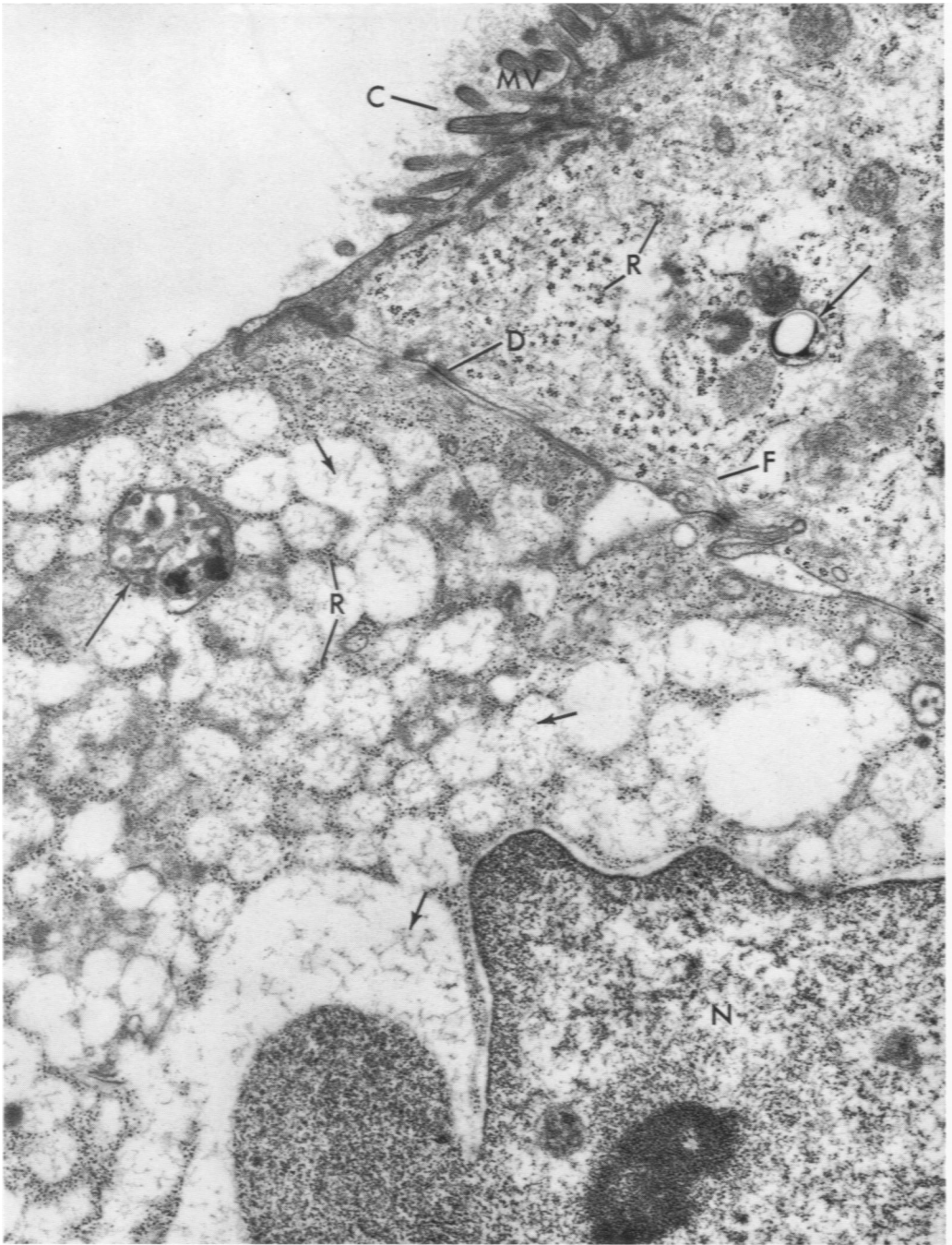
**Fig. 15.** Biopsy from normal control. Portions of 2 columnar cells near tip of villus. In addition to the ultrastructural features seen in Fig. 13, smooth endoplasmic reticulum (SER) and rough endoplasmic reticulum (RER) are evident. Several lysosomes of the dense-body type (L) are present among the numerous mitochondria (MI). The bridge-like areas (arrows) are similar to those seen in dense bodies of hepatocytes.<sup>45,61</sup> MV, microvilli; LM, lateral infoldings of the plasma membrane; TW, terminal web; MVB, multivesicular body. Fixed in osmium-phosphate; stained with uranium and lead.  $\times 17,000$ .

**Fig. 16.** Biopsy from normal control. Area of cell with lysosomes. Reaction product is present in dense bodies (L) and in bridge-like connections (arrows); compare Fig. 15. RER, rough endoplasmic reticulum. Fixed in glutaraldehyde, sectioned at  $25 \mu$ , incubated for acid phosphatase for 10 min. at  $37^{\circ}\text{C}$ ., and then processed for electron microscopy and stained with uranium and lead.  $\times 55,000$ .



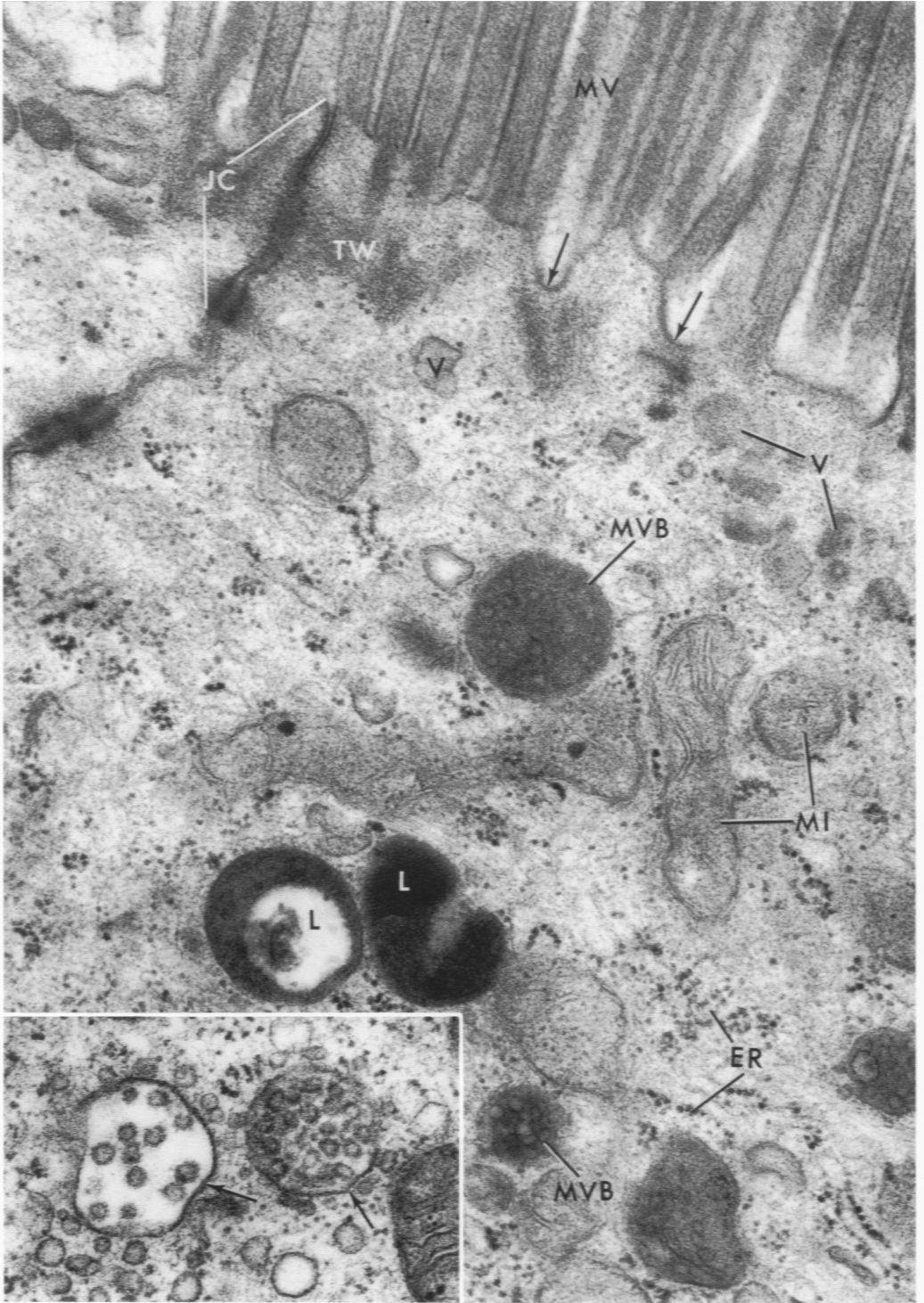
**Fig. 17.** Biopsy from untreated celiac patient. Portions of 2 altered cells of surface epithelium. Cell at right still has some short, irregular, and unevenly spaced microvilli (MV); very little coating (C) remains. No microvilli are found in cell at left. Lateral portions of cell membrane are straight, and desmosomes (D) show a less-developed structure. Apical cytoplasm reveals vacuoles with moderately dense contents (short arrows). Ribosomes (R), most free and some as conglomerates and spirals, are abundant. Fibrils (F) are still present and are concentrated near plasma membrane. Altered organelles, no longer recognizable, are seen (long arrows). N, nucleus. Fixed in osmium-phosphate; stained with uranium and lead.  $\times 15,000$ .





**Fig. 18.** Biopsy from celiac patient on gluten-free diet. Apical portion of 2 columnar cells from dome of mucosa. Microvilli (MV) are slender and evenly arranged. Probable micro-pinocytotic vacuoles (V) are seen at surface (arrows) and in cell. Junctional complexes (JC) and terminal webs (TW) are well developed. Mitochondria (MI) and endoplasmic reticulum (ER) are indistinguishable from those in normal controls. Lysosomes of dense-body (L) and multivesicular-body types (MVB) are frequently observed. Fixed in osmium-phosphate; stained with uranium and lead.  $\times 38,500$ .

**Fig. 19.** Biopsy from celiac patient on gluten-free diet. Lysosomes of multivesicular type are frequent in apex of columnar cells and near Golgi apparatus. This micrograph shows an area in the Golgi region. Two multivesicular bodies are seen; both show delimiting unit membranes (arrows). Note vesicles of varied size near vacuoles. (See Holtzman, Novikoff, and Villaverde<sup>26</sup> for discussion.) Fixed in osmium-phosphate; stained with uranium and lead.  $\times 48,000$ .

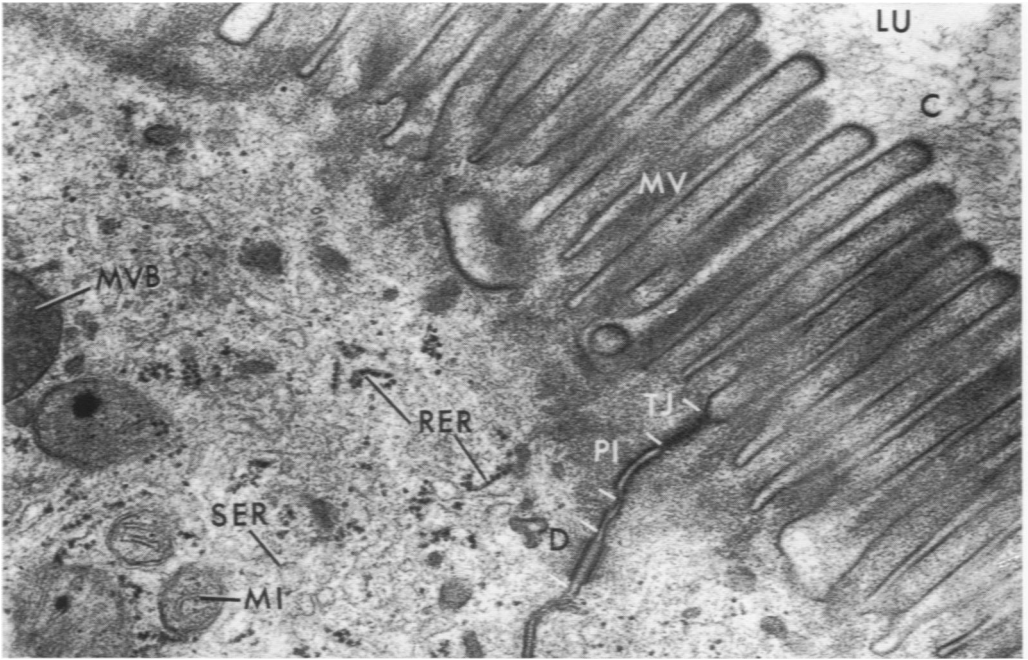


18

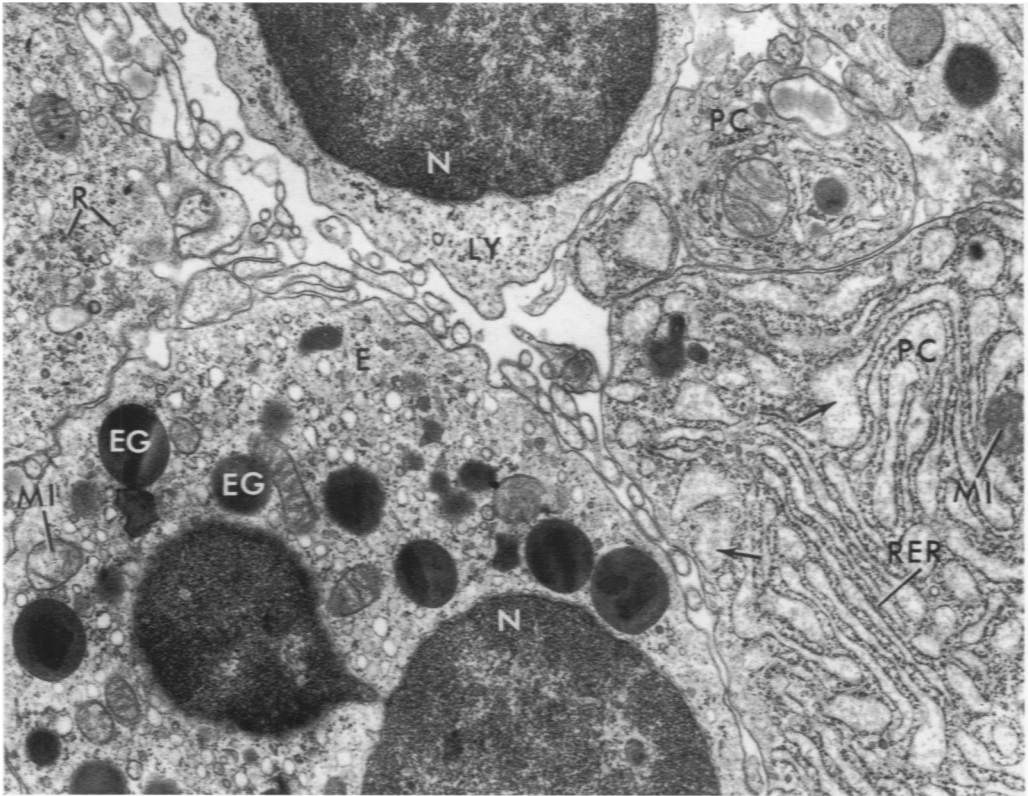
19

**Fig. 20.** Biopsy from celiac patient on gluten-free diet. Apical portions of 2 columnar cells are seen. Apparently normal microvilli (MV) face the lumen (LU); a uniform coating (C) covers them. Junctional complex shows 3 zones: T, TJ, tight junction (zonula occludens); PI, intermediate junction (zonula adhaerens); and D, desmosome. This junctional complex is indistinguishable from those of normal controls. Also seen are smooth endoplasmic reticulum (SER), rough endoplasmic reticulum (RER), mitochondria (MI), and a multivesicular body (MVB). Fixed in osmium-phosphate; stained with uranium and lead.  $\times 34,500$ .

**Fig. 21.** Biopsy from celiac patient on gluten-free diet. Lamina propria. Plasma cells (PC), eosinophils (E), and lymphocytes (LY) are abundant. Most plasma cells are mature, as judged by the abundant intracisternal content. Also seen are rough endoplasmic reticulum (RER); mitochondria (MI); eosinophil granules (EG); ribosomes (R); and nucleus (N). Fixed in osmium-phosphate; stained with uranium and lead.  $\times 11,500$ .



20



21