

# Rejection of Canine Cardiac Allografts

David T. Rowlands, Jr., M.D., Randall B. Vanderbeek, M.D.,  
Hilliard F. Seigler, M.D., and Paul A. Ebert, M.D.

IMMUNOLOGIC REJECTION of whole organs has been studied extensively,<sup>1,2</sup> with particular attention having been given to renal transplants.<sup>3,4</sup> Most of the studies of first-set tissue and organ allografts have supported the view that immunologic rejection depends on cellular immunity,<sup>5</sup> with humoral factors being of less importance.<sup>6</sup> It has now been amply demonstrated that the host response to the graft can be overcome with various immunosuppressive regimens.<sup>7</sup> Such successful therapy is associated with significant alterations of the morphologic features of graft rejection.<sup>8,9</sup>

The immunologic rejection of cardiac transplants has been studied, using both heterotopic and orthotopic preparations. Although cellular infiltrates of the type seen in other organ grafts have been consistently observed in cardiac transplants,<sup>10-15</sup> several investigators have suggested that humoral factors have an important role in the immunologic rejection of heart transplants.<sup>10,11,16</sup>

This study is concerned with the pathologic events of rejection of first-set heterotopic canine cardiac allografts placed in the necks of untreated recipient dogs. The technique of transplantation used is that of Mann *et al.*,<sup>17</sup> modified so that an interatrial defect was created and a leaflet of the mitral valve excised to eliminate the formation of a left ventricular thrombus. It has been possible with this model to obtain serial biopsies in order to compare the sequence of events in immunologic rejection of cardiac grafts. The efficacy of immunosuppression in cardiac transplantation is also demonstrated by serial biopsies of hearts in which the host was treated with antilymphocyte serum, steroids, and azathioprine.

## Materials and Methods

Donor hearts were obtained from dogs averaging 7 lb. in weight. The donors were anesthetized with sodium pentobarbital, and the hearts were removed for

---

From the Departments of Pathology and Surgery, Duke University Medical Center, Durham, N.C.

Supported by Grants AM 11797, HE 11309, and HE 09315 from the U. S. Public Health Service.

Accepted for publication July 17, 1968.

Address for reprint requests: Dr. Rowlands, Department of Pathology, Duke University Medical Center, Durham, N.C. 27706.

transplantation. Portions of the left atrium, right atrium, and atrial septum were left in the donor, but the sino-atrial (S-A) node of the graft was carefully preserved. The donor hearts were cooled by perfusion of the aortic root with saline at 4° C. immediately after being removed from the donor. In preparation of the hearts for transplantation, a leaflet of the mitral valve was excised and the posterior wall of the atrium closed in such a manner that a free communication existed between the left and right atria. The total anoxia time of the grafts averaged 35 min.

Recipient dogs were adult mongrels averaging 60 lb. in weight. Following anesthesia with intravenous sodium pentobarbital (30 mg./kg.), an external jugular vein and a common carotid artery of these animals were isolated and divided. Anastomosis of the donor aorta to the distal common carotid artery and of the pulmonary artery to the proximal jugular vein was accomplished with 6-0 silk. The overlying skin incision was loosely approximated.

Open biopsies were performed at 1- to 2-day intervals in anesthetized dogs. The specimens were obtained from the left ventricular wall with a scalpel and the wound was sutured closed. The sites of sequential biopsy specimens were as widely spaced as possible in order to reduce the possibility of confusion with the histologic changes of wound healing in previous biopsy sites. Endocardium was obtained only rarely by this method. The biopsy specimens were divided and fixed for routine study, fluorescence microscopy, and electron microscopy.

The present study deals with the light microscopic changes in cardiac graft rejection. These specimens were placed in Zenker-acetic acid fixative and embedded in paraffin. After the usual processing, sections were routinely cut at 4  $\mu$  and stained with hematoxylin and eosin. In critical cases, the following special stains were employed: Nile blue B, oil red O, tuberculin stain for fat, PTAH, routine and digested PAS stains, and the trichrome-Masson, the colloidal iron, and the acid fuchsin stains.

Immunosuppressive therapy included azathioprine (Imuran, Burroughs-Wellcome & Co., Tuckahoe, N.Y.), methylprednisolone, and antilymphocyte serum. The antilymphocyte serum was prepared using samples of dog lymph nodes and thymus. The lymphoid tissues were cleaned, dissected, and gently teased out in saline under sterile conditions. Red cell contamination was kept at a minimum (less than 3%). The viability of the lymphocytes was found to be 90-95%, using a 1% trypan blue exclusion test. The cells were next suspended in sterile saline, and a mule was immunized and given booster injections, using the subcutaneous and intradermal routes. Adjuvant was not used. Serum samples were obtained from the mule at weekly intervals, and antibody activity was assayed by a modification of the semi-micro method of cytotoxicity as described by Walford, Gallagher, and Troup.<sup>18</sup> Leukocyte-rich plasma was first incubated in nylon columns for 30 min. at 37° C. to remove neutrophils. The final lymphocyte suspension consisted of 95% mononuclear cells. Increasing dilutions of serum (0.02 ml.), suspensions of lymphocytes (0.02 ml. of 4000 cells per cubic millimeter), and rabbit complement (0.02 ml.) previously absorbed with dog leukocytes were incubated for 30 min. at 37° C. in disposable microtiter-V-plates. The supernatant was then drawn off and 0.04 ml. of 1% trypan blue was mixed with cell suspension. The cell suspensions with trypan blue were added to counting chambers and the percentage of stained cells was determined. Serum which, in a 1:19,000 dilution, yielded 100% dead lymphocytes was frozen and used in this study.

## Results

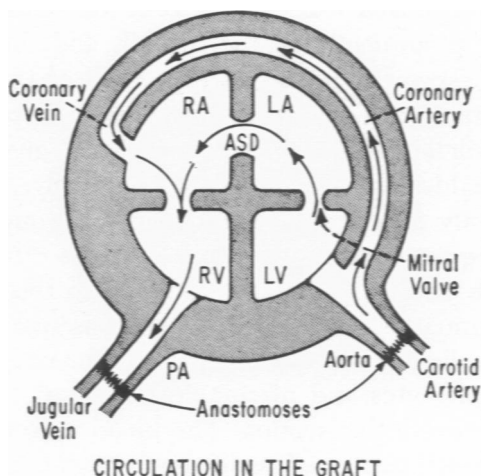
### Untreated Recipients

The technique used in these heterotopic cardiac allografts was designed to provide mitral insufficiency and an atrial septal defect so as

to prevent stasis of blood and thrombosis in the left ventricle and the left atrium. Text-figure 1 is a diagrammatic sketch of the donor heart in place. The success of this preparation is apparent since no thrombi were encountered in the ventricular or atrial chambers of the hearts included in this series.

A total of 10 transplants supplied the histologic material for these observations. Two of the hearts were removed electively after being in place for only 1 day and a third heart was removed after an anesthetic death of the host on the first postoperative day. None of the 7 remaining hearts were removed before the fifth postoperative day, and 1 of the transplanted hearts remained viable for 14 days. The average survival time of the transplants, excluding those removed after one day, was 7.3 days.

*Gross.* The external characteristics of the transplanted hearts were evaluated at the time of biopsy, and every heart was thoroughly examined at its removal. The hearts became enlarged and dilated within 2 days after transplantation (Fig. 1). The epicardial surfaces showed a fibrinous exudate as early as 1 day after transplantation. This exudate became organized and fibrotic as rejection progressed. The myocardium was congested in the early stages of rejection, but by the completion of rejection it assumed a mottled yellow appearance and was more flabby than normal. Thrombi were found in none of these transplants despite careful gross and microscopic study of the endocardium, including the vascular anastomoses. In no case were the valve leaflets grossly thickened.



TEXT-FIG. 1. Diagram of heart transplant showing the pattern of circulation in the graft.

*Microscopic.* The biopsy specimens from individual hearts showed steady progression of rejection. Although a moderate degree of variation between biopsies taken from different hearts was detected in the early periods, later biopsies showed slight variation.

**DAYS 1 AND 2.** There was little recognizable change in transplanted hearts during this 2-day period, but mild interstitial edema and perivascular cellular exudates could be identified in all but 2 hearts. The perivascular exudates were made up almost exclusively of small lymphocytes (Fig. 2). Although inflammatory changes were most conspicuous near the epicardium and the endocardium, they could be identified in all levels of the myocardium. The associated myocardium displayed only small foci of frank necrosis.

**DAYS 3-5.** The most obvious pathologic change noted in these sections continued to be a mononuclear cell infiltrate. Many of the infiltrates continued to have a perivascular distribution, but they were also found more generally distributed throughout the myocardium (Fig. 3). In contrast to early cellular infiltrates, which were made up mostly of small lymphocytes, the cellular exudate seen at this time also contained abundant medium lymphocytes and plasma cells. The inflammatory cells were frequently found in close association with myocardial fibers. Many of the myocardial fibers were stained bright red with acid fuchsin. The endocardium continued to be the seat of severe chronic inflammation (Fig. 4). The most extensive areas of myocardial necrosis were found deep in the myocardium rather than near either the endocardium or the epicardium.

**DAYS 6-8.** This phase of the rejection process is characterized by more widespread myocardial necrosis and cellular inflammation. Vascular changes with prominent endothelial cells and thickened walls became prominent, especially in the deep portions of the myocardium. In some vessels, intramural deposits could be easily recognized (Fig. 5). These deposits failed to stain for lipid, mucins, or glycogen in the fixed and paraffin-embedded specimens used in this study.

**DAYS 9-14.** Only 2 hearts remained viable beyond 8 days and one of these had to be removed on the ninth day, the other being removed on the fourteenth day. The changes observed in this final stage of rejection were continuations of the cellular and vascular processes already mentioned. The cellular infiltrate continued to be widespread and to be made up of lymphocytes and plasma cells (Fig. 6). Few viable myocardial fibers remain in this section. The blood vessels were even more severely altered, with thickened walls, hypertrophy of the endothelium (Fig. 7), and subendothelial deposits (Fig. 8). Much of the damaged myocardium was replaced by fibroblasts and small capillaries.

### Effect of Immunosuppression

Five adult dogs were treated with antilymphocyte serum (5 ml. S.C.) and Imuran (150 mg. p.o.) for 3 days prior to transplantation. Both drugs were given twice daily. Following transplantation, the animals continued to be treated with antilymphocyte serum and Imuran (150–200 mg./day) as well as with methylprednisolone (130 mg./day) until the tenth postoperative day when all immunosuppression was discontinued. Sequential biopsies were taken throughout the course of immunosuppression and during the subsequent graft rejection. In one instance the recipient died an anesthetic death 1 day after stopping immunosuppressive therapy.

Biopsies taken during the course of immunosuppression showed little abnormality of the myocardium (Fig. 9). Similarly, the blood vessels showed no abnormalities. The epicardium, however, displayed significant change with inflammation and eventual organization.

Rejection of the transplants began immediately after immunosuppressive therapy was discontinued, significant microscopic changes being evident within 2 days. The early cellular events were largely localized to the subepicardial and subendocardial layers but shortly became more widespread (Fig. 10). The single host heart which was examined showed no abnormality.

### Discussion

The model of cardiac transplantation used in this study has permitted us to follow the events of rejection in the transplanted heart with sequential biopsies and to test the effect of immunosuppression on cardiac transplants. The early appearance and persistence of perivascular aggregates of lymphocytes is the most striking pathologic change in these hearts. The cellular infiltrates originated in both subepicardial and endocardial portions of the heart, but the exudate spread rapidly to involve most of the myocardium. Small lymphocytes were the dominant cells in the earliest exudates but medium lymphocytes and plasma cells became more numerous later. The perivascular pattern of inflammation closely resembles that seen in renal allografts<sup>8,19-21</sup> both with respect to its initial location and to the diversity of cells making up the exudate. Similar perivascular mononuclear cells have been described by others in studies of cardiac graft rejection.<sup>10-15</sup>

The mechanism by which mononuclear cells injure grafts is incompletely resolved, but in-vitro studies have suggested that intimate contact with appropriate lymphocytes results in death of the target cells.<sup>5,22</sup> Waksman<sup>23</sup> postulated that the effect of immunologic cells in vivo was less direct and that the transplantation reaction resulted from the com-

bined effects of local accumulations of mononuclear cells as well as invasive destructive activities directed at parenchymal cells of the graft. More recent observations<sup>8,9</sup> have suggested that the primary lesion in renal graft rejection is at the peritubular capillary. A similar mechanism is suggested by the intimate relationship between lymphoid cells and myocardial fibers observed in the present study.

Vascular changes in cardiac transplants are characterized by thickening of the endothelium and vascular walls. Thick-walled vessels have been observed by other investigators;<sup>24</sup> the alterations in smaller vessels are similar to those described in the kidney.<sup>8</sup> The pathogenesis of the vascular lesions in graft rejection remains unclear, but the failure to recognize changes until after rejection is well under way suggests that they are not primary changes in cardiac graft rejection.

Immunosuppression was attempted by treatment of the host with antilymphocyte serum, azathioprine, and steroids. The success of the regimen used in the present series is obvious since these grafts retained their normal structure and functioned for nearly twice as long as was the case in untreated grafts. It is of interest that the course of rejection following withdrawal of immunosuppression was identical to that seen in unprotected animals.

### Summary and Conclusions

The morphologic changes in cardiac transplantation in dogs have been studied using a new modification of a technique for heterotopic grafting. The grafted hearts included an interatrial septal defect and mitral insufficiency to reduce the incidence of intracardiac thrombi. The transplanted hearts survived rejection for an average of 7.3 days and permitted obtaining serial biopsies.

Histologic changes were initiated by the appearance of perivascular exudates within 2 days. These early lesions were located primarily in subepicardial and subendocardial locations, but they rapidly became more widespread, involving the entire thickness of the myocardium. In later stages, direct associations between the inflammatory cells and myocardial fibers could be seen. Vascular alterations became apparent early in rejection and were characterized by hypertrophied endothelium and thickened arterial walls.

Morphologic and functional evidence of graft rejection was essentially eliminated by immunosuppression. When this therapy was stopped, rejection began immediately and followed a course identical to that seen in untreated animals.

**References**

1. WOODRUFF, M. F. A. *Transplantation of Tissues and Organs*. Thomas, Springfield, Ill., 1960.
2. RUSSELL, P. S., and MONACO, A. P. *The Biology of Tissue Transplantation*. Little, Boston, 1965.
3. CALNE, R. Y. *Renal Transplantation*. Williams & Wilkins, Baltimore, 1963.
4. STARZL, T. E., Ed. *Experience in Renal Transplantation*. Saunders, Philadelphia, 1964.
5. WILSON, D. E., and BILLINGHAM, R. E. Lymphocytes and transplantation immunity. *Advances Immun* 7:189-273, 1967.
6. STETSON, C. A. Role of humoral antibody in homograft rejection. *Advances Immun* 3:97-130, 1963.
7. MERRILL, J. P. Human tissue transplantation. *Advances Immun* 7:275-327, 1967.
8. PORTER, K. A. Morphological aspects of renal homograft rejection. *Brit Med Bull* 21:171-175, 1965.
9. ROWLANDS, D. T., JR., KIRKPATRICK, C. H., VATTER, A. E., and WILSON, W. E. C. Immunologic studies in human organ transplantation. IV. Serologic and pathologic studies following heterotransplantation of the kidney. *Amer J Path* 50:605-622, 1967.
10. DOWNIE, H. G. Homotransplantation of the dog heart. *AMA Arch Surg (Chicago)* 66:624-636, 1953.
11. WESOLOWSKI, S. A., and FENNESSEY, J. F. Pattern of failure of the homografted canine heart. *Circulation* 8:750-755, 1953.
12. ABBOTT, C. P., DEWITT, C. W., and CREECH, O., JR. The transplanted rat heart: histologic and electrocardiographic changes. *Transplantation* 3:432-445, 1965.
13. LOWER, R. R., STOFER, R. C., and SHUMWAY, N. E. Homovital transplantation of the heart. *J Thorac Cardiovasc Surg* 41:196-204, 1961.
14. REEMTSMA, K., WILLIAMSON, W. E., JR., IGLESIAS, F., PENA, E., SAYEGH, S. F., and CREECH, O., JR. Studies in homologous canine heart transplantation: prolongation of survival with a folic acid antagonist. *Surgery* 52:127-133, 1962.
15. BLUMENSTOCK, D. A., HECHTMAN, H. B., COLLINS, J. A., JARETSKI, A., III, HOSBEIN, J. D., ZINGG, W., and POWERS, J. H. Prolonged survival of orthotopic homotransplants of the heart in animals treated with methotrexate. *J Thorac Cardiovasc Surg* 46:616-625, 1963.
16. RAMOS, H. R., CHIBA, C., SCHOLLMAYER, P., WOLFF, P. L., PEARSON, B., and BING, R. J. The presence of humoral factors in homograft rejection of the transplanted heart. *Transplantation* 1:284-292, 1963.
17. MANN, F. C., PRIESTLY, J. T., MARKOWITZ, J., and YATER, W. M. Transplantation of the intact mammalian heart. *Arch Surg (Chicago)* 26:219-224, 1933.
18. WALFORD, R. L., GALLAGHER, R., and TROUP, G. M. Human lymphocyte typing with isologous antisera; technical considerations and a preliminary study of the cytotoxic reaction system. *Transplantation* 3:387-401, 1965.
19. DEMPSTER, W. J. Kidney homotransplantation. *Brit J Surg* 40:447-465, 1953.

20. SIMONSEN, M., BUEMANN, J., GAMMELTOFT, A., JENSEN, F., and JORGENSEN, K. Biological incompatibility in kidney transplantation in dogs. I. Experimental and morphological investigations. *Acta Path Microbiol Scand* 32:1-35, 1953.
21. HUME, D. M., and EGDAHL, R. H. Progressive destruction of renal homografts isolated from the regional lymphatics of the host. *Surgery* 38:194-214, 1955.
22. ROSENAU, W., and MOON, H. D. Lysis of homologous cells by sensitized lymphocytes in tissue culture. *J Nat Cancer Inst* 27:471-483, 1961.
23. WAKSMAN, B. H. The pattern of rejection in rat skin homografts, and its relation to the vascular network. *Lab Invest* 12:46-57, 1963.
24. CHIBA, C., WOLF, P. L., GUDBJARNASON, S., CHRYSOHOU, A., RAMOS, H., PEARSON, B., and BING, R. J. Studies on the transplanted heart. Its metabolism and histology. *J Exp Med* 115:853-866, 1962.

The authors wish to express their appreciation for the expert technical assistance of Betty Caywood.

---

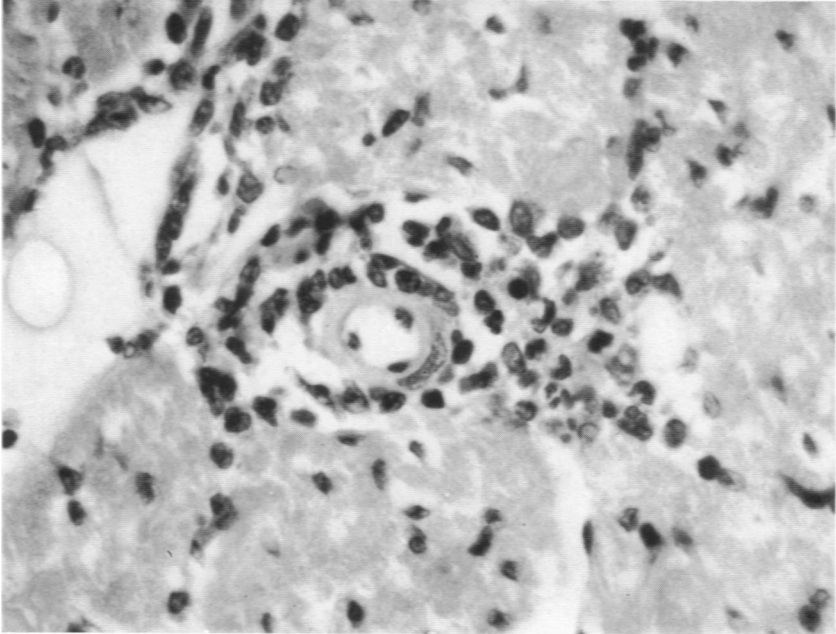
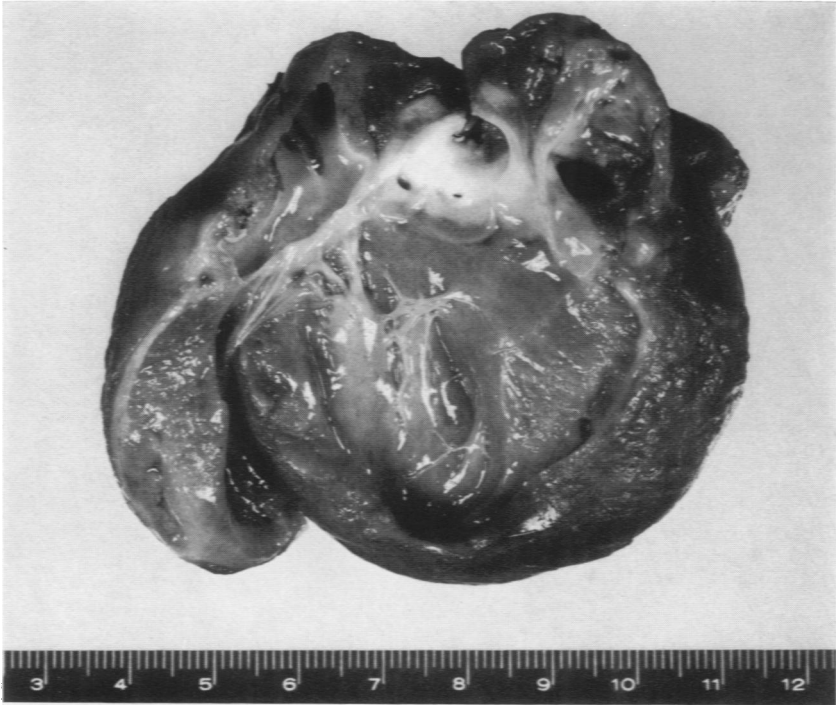
### Legends for Figures

All sections shown in photomicrographs were stained with hematoxylin and eosin.

**Fig. 1.** Transplanted heart removed after being in place for 6 days. Epicardial surface is roughened and fibrinous. Left ventricle is dilated, and myocardium has a mottled appearance.

**Fig. 2.** At 2 days, there is a moderately intense lymphocytic exudate surrounding this small blood vessel. Inflammatory cells are exclusively small lymphocytes.  $\times 640$ .



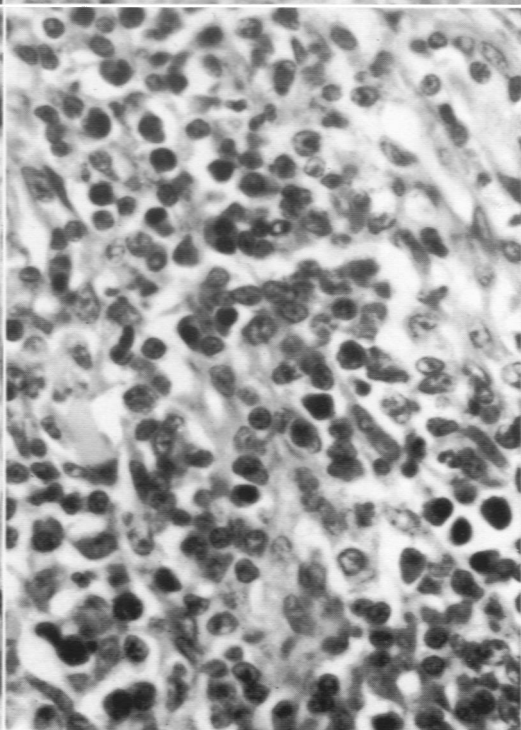
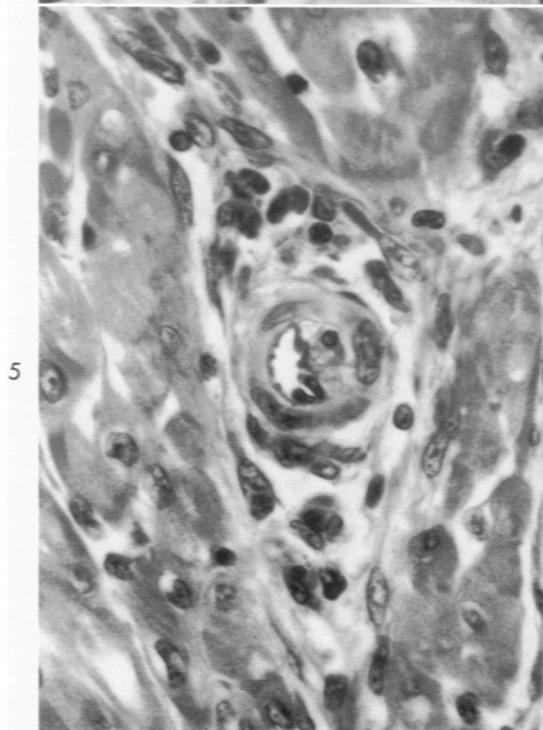
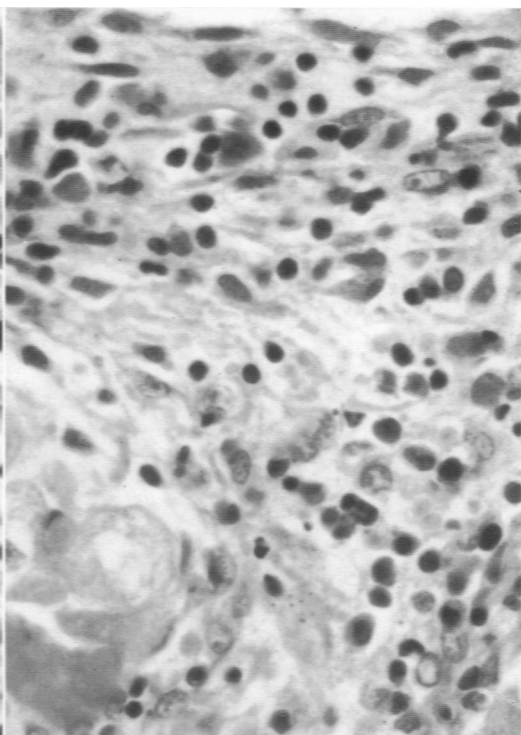
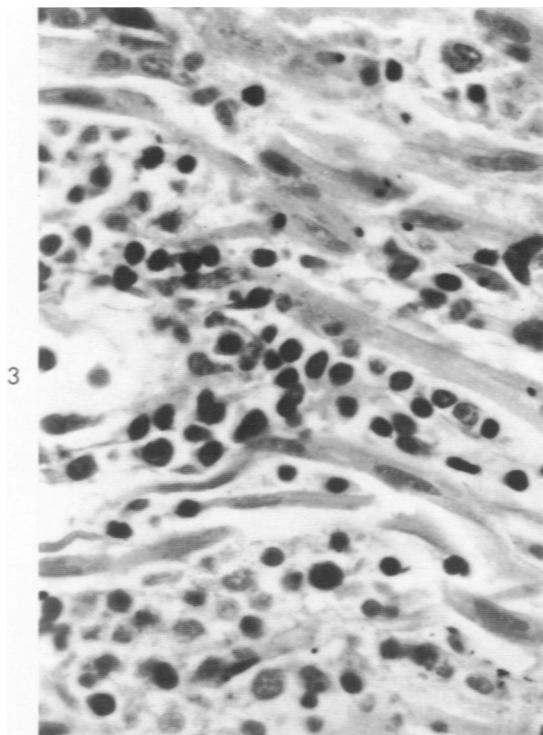


**Fig. 3.** At 5 days, exudate is more widespread than was previously noted. Inflammatory cells included in this field are small and medium lymphocytes. Many of the inflammatory cells are adjacent to myocardial fibers.  $\times 640$ .

**Fig. 4.** At 3 days, endocardium is thickened and edematous and contains abundant lymphocytes. Exudate extends into myocardium between muscle fibers.  $\times 640$ .

**Fig. 5.** At 7 days, vessels lie deep in myocardium and are associated with only small numbers of lymphocytes. The vessel wall is thickened, and there is an amorphous material in the subintimal portion of the vessel.  $\times 640$ .

**Fig. 6.** At 14 days, exudate, which is composed of various types of lymphocytes as well as plasma cells, is diffusely distributed and is associated with degenerating myocardial fibers.  $\times 640$ .



**Fig. 7.** At 9 days, the vessel wall is thickened by amorphous, granular material. Associated endothelium is hyperplastic. Fibroblasts are present in large numbers in surrounding tissues.  $\times 640$ .

**Fig. 8.** At 14 days, the endothelium of the vessel is hyperplastic, and it is severely distorted by subendothelial deposits. Very little myocardium remains intact.  $\times 640$ .

**Fig. 9.** After 8 days with immunosuppressive therapy, the myocardial fibers and vessels appear normal. There is no mononuclear cellular exudate.  $\times 640$ .

**Fig. 10.** At 5 days after discontinuation of immunosuppressive therapy. (This biopsy was from the same heart shown in Fig. 1.) The myocardium is disrupted, and infiltrates of mononuclear cells are prominent. The vessel near the center shows a thickened endothelial cell layer.  $\times 640$ .

