

Collagenase in Experimental Carbon Tetrachloride Cirrhosis of the Liver

Irmgard Montfort, MD, and Ruy Pérez-Tamayo, MD

The presence and distribution of collagenase in experimental CCl₄ cirrhosis of the liver in rats has been studied by immunohistochemical techniques. A monospecific anti-rat uterus collagenase antibody was raised in rabbits and used for indirect immunofluorescence staining of liver sections obtained from rats in both the reversible and irreversible stages of CCl₄-induced cirrhosis. Collagenase is present associated with connective tissue septums as long as cirrhosis is reversible, and it is not detectable in the irreversible stage. In animals sacrificed during the transition between the reversible and irreversible stages of cirrhosis, collagenase appeared bound to the outer surfaces of connective tissue septums and was absent from the deeper portions. These observations suggest that the irreversibility of experimental CCl₄ cirrhosis of the liver is associated with a disturbance in the mechanisms of collagen degradation, which may be a deficiency in collagenase activity, a change in the susceptibility of the substrate, or a combination of both factors. (Am J Pathol 92:411-420, 1978)

THE TERM "CIRRHOSIS OF THE LIVER" refers to a heterogeneous group of chronic, progressive, and irreversible diseases for which no satisfactory treatment is available.¹ Despite several significant differences among most etiologically defined categories,² all cases of cirrhosis are characterized morphologically by the loss of normal liver architecture, which is replaced by a new tridimensional structure based on the combination of variable degrees of liver cell regeneration and excessive connective tissue deposition.³ The pathogenesis of the revised liver architecture has been the subject of many speculations.⁴⁻⁶ It is universally accepted that once fibrosis is established, the process becomes irreversible.^{7,8} Many investigators, therefore, have directed their efforts to study means by which excessive connective tissue deposition may be prevented.^{9,10} The irreversibility of scar tissue has been accepted *a priori*,¹¹ and there are only few studies designed to explore the possibility that fibrous connective tissue in human cirrhosis may be subject to degradation and resorption.¹² On the other hand, there are some experimental models of liver cirrhosis in which the process has been shown to be reversible, such as chronic CCl₄ intoxication,^{13,14} *p*-dimethylaminoazobenzene¹⁵⁻¹⁷ or ethionine administration,^{18,19} and dietary cirrhosis.²⁰⁻²³ In each of these models, discontinuation of the cirrhotogenic agent is followed by a period of repair of the liver

From the Departamento de Patología, Instituto Nacional de la Nutrición, México, D.F., México.
Supported by Grant 003 from CONACyT, México.
Accepted for publication April 5, 1978.

Address reprint requests to Dr. Ruy Pérez-Tamayo, Departamento de Patología, Instituto Nacional de la Nutrición, Ave. San Fernando y Viaducto Tlalpan, México 22, D.F., México.

0002-9440/78/0810-0411\$01.00

411

changes, including complete or nearly complete disappearance of excessive fibrous tissue. In CCl_4 -induced cirrhosis, however, the process is reversible only for a certain period (40 or 50 days^{13,14}) and becomes irreversible when administration of this toxin is continued for more than 90 days. In this paper we report observations dealing with a possible mechanism of the irreversibility of experimental CCl_4 cirrhosis of the liver in rats.

Materials and Methods

Experimental CCl_4 Cirrhosis of the Liver

White female rats of Wistar strain weighing 100 g were caged in groups of 4, fed regular Purina pellets and water *ad libitum*, and weighed weekly throughout the experiment. All animals were injected intraperitoneally twice a week with 0.2 ml of a 33% solution of CCl_4 in mineral oil for 7 weeks. After 7 weeks, the CCl_4 injections were discontinued in one half the animals and the remaining half went on to complete 15 weeks of treatment. Throughout this period, and for up to 100 weeks after the CCl_4 treatment was discontinued, animals chosen at random from both groups were killed at different times by cardiac exsanguination under light ether anesthesia; the liver was removed, weighed, and treated as described below. Thus, liver specimens were available from rats treated with CCl_4 for up to 7 weeks (14 injections) and from this same group of animals after treatment was discontinued for as long as 52 weeks. Similarly, liver specimens were also available from rats treated with CCl_4 for as long as 15 weeks (30 injections) and from this same group of animals after treatment was discontinued for as long as 104 weeks.

Liver Sections

Thin slices of the right lobe of the liver were fixed in formalin. Other slices were frozen on cryostat chucks with Tissue-Tek, cut 6 to 10 μ thick, made to adhere to untreated glass slides, and kept at 0 C for no longer than 1 week before staining. Paraffin sections were stained with hematoxylin and eosin and by Masson's and Laidlaw's techniques.

Anticollagenase Antibodies

The preparation of pure collagenase from postpartum rat uterus and of monospecific anti-rat collagenase antibody in rabbits has been described in detail elsewhere.²⁴ Briefly, the enzyme was obtained from the culture medium of postpartum rat uterus fragments, purified by affinity chromatography on columns packed with collagen bound to Sepharose 4-B, and used as antigen to immunize rabbits. The antiserum was absorbed with both rat serum and collagen free of bound collagenase²⁵ and was shown to react specifically with rat postpartum uterus collagenase by immunodiffusion and inhibition tests.²⁴

Other Immunologic Reactants

Because all the immunohistochemical studies described below were performed by the indirect or "sandwich" technique, it was necessary to prepare a specific anti-rabbit IgG antibody, as well as other immunologic reactants, in a different species. The goat was chosen, and the details of this phase of the experiment have been described elsewhere.²⁴

Immunofluorescence Staining

After thorough washing with phosphate-buffered saline, liver sections were flooded with purified anticollagenase IgG for 30 minutes in a moist chamber at room temperature, followed by further washing (three times) with phosphate-buffered saline, and then covered with fluorescein-labeled goat IgG anti-rabbit IgG for another 30 minutes under the same conditions. Slides were observed immediately after staining under a Zeiss epifluorescence microscope equipped with activation filter BG 12, barrier filters 560 and 590, and a high pressure mercury vapor 200-watt lamp. Controls included liver tissue slides treated with the same concentration of nonstimulated rabbit IgG (instead of rabbit anti-rat uterus collagenase IgG) and also with fluorescein-labeled nonstimulated goat IgG (instead of goat anti-rabbit IgG antibody IgG). In some instances tissues were flooded directly with the fluorescein-labeled goat IgG anti-rabbit IgG and also with nonstimulated, fluorescein-labeled goat IgG.²⁴

Results

Early Response of Normal Collagenase Distribution to CCl₄ Administration

The distribution of collagenase in the normal rat liver has been briefly described.²⁴ The enzyme is present in the portal spaces, localized on the fine collagen fibers that separate vessels and bile ducts, and on the interlamellar reticulum fibers outlining the walls of the sinusoidal capillaries. Positive fluorescence staining was also seen on the wall of large efferent veins and on the fibrous capsule (Figure 1). In animals killed after 2 weeks of CCl₄ treatment (four injections), the normal pattern of immunofluorescence was changed only around the central veins, where staining was absent from the reticulum fibers (Figure 2). A similar picture was observed in animals killed after 4 weeks of CCl₄ treatment (eight injections), but the area where no collagenase was present was larger, corresponding to the centrilobular necrosis and fatty metamorphosis.¹³

Reversible CCl₄ Cirrhosis of the Liver

After 6 to 8 weeks of CCl₄ treatment (12 to 16 injections), most animals revealed early cirrhosis of the liver, characterized by fine connective tissue septums separating irregular nodules of liver parenchyma. Histologic signs of liver cell regeneration were minimal or entirely absent at this stage. Immunofluorescence staining was positive on the fibrous septums, with only very few reticulum fibers faintly stained within the liver cell nodules, usually with a random distribution (Figure 3). The normal immunofluorescence of portal spaces and efferent veins remained unchanged. Animals from this group that were killed 4 and 12 weeks after the CCl₄ treatment was discontinued revealed progressive disappearance of connective tissue bands and return to normal liver architecture; however, as long as fibrous septums were present, they were detected by positive immunofluorescence staining.

Irreversible CCl₄ Cirrhosis of the Liver

Animals surviving CCl₄ treatment for longer than 8 weeks and up to 15 weeks (16 to 30 injections) developed advanced cirrhosis of the liver, characterized by gross distortion of liver architecture, broad connective tissue septums, and irregular nodules of parenchyma with many cytologic signs of regeneration. Immunofluorescence staining showed progressive displacement of the positive material to the periphery of the fibrous septums (Figures 4 through 6) which were considerably thicker than those in the group with reversible cirrhosis. Finally, no fluorescence was visible in the connective tissue septums (Figure 7). Rats in which the CCl₄ treatment was discontinued on completion of 30 injections and which were kept in the laboratory for as long as 104 additional weeks still showed the same advanced cirrhosis and were persistently negative with the immunofluorescence stain, although some reticulum fibers within the regenerated liver cell nodules were positive.

Discussion

Since the early studies of Cameron and Karunaratne¹³ it has been recognized that experimental CCl₄ cirrhosis of the liver goes through two successive and dose-dependent stages. The first stage is characterized morphologically by thin connective tissue septums surrounding discrete nodules of liver cells with little or no signs of regeneration. This stage is reversible provided the administration of CCl₄ is discontinued at the right time (not later than 6 to 8 weeks or 15 injections). The second stage reveals broader fibrous tissue septums separating well-defined parenchymal nodules with abundant cytologic signs of regeneration; the normal relation of portal spaces to controlobular veins is lost. This stage of cirrhosis is irreversible, and the liver will remain as such despite discontinuation of the toxic and for as long as the animal lives. Rubin et al^{14,26} showed that the half life of collagen deposited in this experimental model of liver cirrhosis varied according to the stage of the disease. In the reversible stage, the half life of collagen was 30 days, whereas in the irreversible stage it was of the order of 300 days. Their data suggest a disturbance in the turnover of collagen and, since it appears well established that in the irreversible stage of experimental CCl₄ cirrhosis there is little or no increased collagen biosynthesis,²⁷ their data are also compatible with faulty collagen degradation, which the same authors later attributed to an excess of chondroitin sulfate B.²⁸ We²⁹ have shown that an experimentally induced focal liver scar is almost completely resorbed in the normal rat in approximately 3 weeks but that a similar scar produced in a

liver with irreversible CCl_4 cirrhosis will remain unchanged for the entire life of the animal.

The experiments reported in this paper demonstrate that collagenase is associated with collagen in the connective tissue septums throughout the reversible phase of CCl_4 cirrhosis of the liver and that the enzyme protein is no longer detectable in the irreversible phase of the disease. Differences in the intensity of immunofluorescence staining of tissue sections are difficult to translate into quantitative statements, especially when several important variables remain unknown, such as the molarity of specific antibodies in the IgG preparations used, the reactivity of the antigen bound to tissue structures (as opposed to the purified antigen in a test tube), and the possible presence in the tissues of substances capable of modifying the stoichiometry of the antigen-antibody reaction. For this reason, variations in the intensity of immunofluorescence have not been taken into account and the only differences noted are simply positive or negative. It is acknowledged that the lack of positive staining does not discriminate between the absence of the antigen in the tissue and its presence at concentrations below the sensitivity of the technique used to detect it. Nevertheless, our observations may be correlated with the report of Okazaki and Maruyama,³⁰ who showed that during the early stages of CCl_4 cirrhosis collagenase activity was increased in the liver and that in the advanced stages of the experimental disease the enzyme activity was comparatively poor. These authors used the *in vitro* technique of Gross and Lapière,³¹ which consists of the incubation of diced specimens of rat liver on top of reconstituted collagen gels; the area of lysis of the gel around the explant permits a semiquantitative estimate of collagenolysis. It is likely that Okazaki and Maruyama were detecting newly synthesized enzyme, since frozen and thawed liver fragments from early cirrhosis failed to show collagenase activity, whereas living tissue from the same rat revealed appreciable enzymatic activity. It should be emphasized, however, that very little is known about the turnover of collagenase *in vivo* and that once the enzyme becomes bound to its substrate it becomes very difficult to remove it.²⁵

During the transition between reversible and irreversible stages in CCl_4 cirrhosis of the liver, collagenase was progressively excluded from the deeper portions of the connective tissue septums before it disappeared completely. This observation suggests that as connective tissue septums grow thicker (and perhaps older) the collagen fibers become heterogeneous not only in regard to their location within the septums, and possibly in the degree of cross-linking, but also with respect to the

presence or absence of collagen-bound collagenase. A similar distribution of collagenase has been observed on thick collagen bundles in the dermis, tail tendon, and other organs in the normal rat, where the enzyme was present only on the outer surface of the collagen bundles.²⁴

In theory, the inability of the cirrhotic liver to remove the increased fibrous tissue once the administration of CCl_4 is discontinued could be due to several factors¹²: a) deficiency of the normal collagen-degrading mechanism; b) presence of collagen not susceptible to the degrading mechanism; c) interference with the enzyme:substrate reaction (collagenase:collagen) by other substances, such as enzyme inhibitors or associated molecules; and d) combinations of some or all the preceding factors. Our observations fail to discriminate between the various possibilities, since they may be explained by any one of them. Nevertheless, three observations would seem to support the hypothesis that irreversibility of CCl_4 cirrhosis involves some alteration in collagenase: 1) the inability of the liver with irreversible cirrhosis to eliminate a focal scar induced when the process was already advanced,²⁹ suggesting that even recently deposited collagen is not degraded; 2) the demonstration that little or no collagen biosynthesis occurs during the irreversible phase of CCl_4 cirrhosis,²⁷ which militates against the possibility of replacement of connective tissue septums by a collagenase-resistant type of collagen; and 3) the presence of the enzyme in the reversible phase of CCl_4 cirrhosis and its absence in the irreversible phase, established by the *in vitro* observations of Okazaki and Maruyama³⁰ and by the experiments reported in this paper. To clarify the precise mechanism(s) responsible for the irreversibility of CCl_4 cirrhosis, direct quantitative determinations of collagenase activity and collagen susceptibility should be made under conditions resembling the *in vivo* situation as closely as possible. Such studies are under way in our laboratory.

References

1. Conn HO: Cirrhosis. Diseases of the Liver. Fourth edition. Edited by L Schiff. Philadelphia, J. B. Lippincott Co., 1975, pp 833-939
2. Leevy CM, Popper H, Sherlock S (criteria committee): Diseases of the Liver and Biliary Tract: Standardization of Nomenclature, Diagnostic Criteria, and Diagnostic Methodology. Fogarty International Center Proceedings, No. 22. US Department of Health, Education and Welfare Publication No. (NIH) 76-725, 1976
3. Popper H: Pathologic aspects of cirrhosis. *Am J Pathol* 87:228-264, 1977
4. Popper H, Elias H: Histogenesis of hepatic cirrhosis studied by the three-dimensional approach. *Am J Pathol* 31:405-441, 1955
5. Baggenstoss AH: Postnecrotic cirrhosis: Morphology, etiology, and pathogenesis. *Prog Liver Dis* 1:14-38, 1961
6. Gall EA: Posthepatic, postnecrotic and nutritional cirrhosis: A pathologic analysis. *Am J Pathol* 36:241-261, 1960
7. Popper H, Udenfriend S: Hepatic fibrosis: Correlation of biochemical and morphologic investigations. *Am J Med* 49:707-721, 1970

8. Popper H, Kent G: Fibrosis in chronic liver disease. *Clin Gastroenterol* 4:315-332, 1975
9. Rojkind M, Kershenobich D: Regulation of collagen synthesis in liver cirrhosis: Inhibition of fibrogenesis in rats and humans. *Collagen Metabolism in the Liver*. Edited by H Popper, K Becker. New York, Stratton Intercontinental Medical Book Corp., 1975, pp 129-138
10. Rojkind M, Kershenobich D: Hepatic fibrosis. *Prog Liver Dis* 5:294-310, 1976
11. Pérez-Tamayo R: Some aspects of connective tissue of the liver. *Prog Liver Dis* 2:192-210, 1965
12. Pérez-Tamayo R: Pathology of collagen degradation. *Am J Pathol* 92:507-566, 1978
13. Cameron GR, Karunaratne WAE: Carbon tetrachloride cirrhosis in relation to liver regeneration. *J Pathol Bacteriol* 42:1-21, 1936
14. Rubin E, Hutterer F, Popper H: Reversibility of cirrhosis related to collagen and interstitial cell turnover. *Gastroenterology* 48:504-505, 1965 (Abstr)
15. Orr JW: The histology of the rat's liver during the course of carcinogenesis by butter-yellow (*p*-dimethylaminoazobenzene). *J Pathol Bacteriol* 50:393-408, 1940
16. Steinberg B, Martin RA: Absorption of scar tissue in experimental nodular cirrhosis of the liver: With a method of visualizing cirrhotic changes. *Arch Pathol Lab Med* 41:1-10, 1946
17. Morrione TG: Quantitative study of collagen content in experimental cirrhosis. *J Exp Med* 85:217-226, 1947
18. Hutterer F, Rubin E, Singer EJ, Popper H: Quantitative relation of cell proliferation and fibrogenesis in the liver. *Cancer Res* 21:205-215, 1961
19. Hutterer F, Rubin E, Popper H: Mechanism of collagen resorption in reversible hepatic fibrosis. *Exp Mol Pathol* 3:215-223, 1964
20. Plough IC, Patek AJ Jr, Bevans M: The relative effects of protein, choline, and methionine in the treatment of experimental dietary cirrhosis in the rat. *J Exp Med* 96:221-231, 1952
21. Patek AJ Jr, Oken DE, Sakamoto A, de Fritsch N, Bevans M: Recovery from dietary cirrhosis of the liver in the rat. *Arch Pathol Lab Med* 69:168-174, 1960
22. Takada A, Porta EA, Hartroft WS: The recovery of experimental dietary cirrhosis. I. Functional and structural features. *Am J Pathol* 51:929-957, 1967
23. Takada A, Porta EA, Hartroft WS: The recovery of experimental dietary cirrhosis. II. Turnover changes of hepatic cells and collagen. *Am J Pathol* 51:959-976, 1967
24. Montfort I, Pérez-Tamayo R: The distribution of collagenase in normal rat tissues. *J Histochem Cytochem* 23:910-920, 1975
25. Pardo A, Montfort I, Pérez-Tamayo R: Collagen-bound collagenase. (In preparation)
26. Hutterer F, Eisenstadt M, Rubin E: Turnover of hepatic collagen in reversible and irreversible fibrosis. *Experientia* 26:244-245, 1970
27. Rojkind M, Díaz de León L: Collagen biosynthesis in cirrhotic rat liver slices: A regulatory mechanism. *Biochim Biophys Acta* 217:512-522, 1970
28. Hutterer F, Rubin E: Mucopolysaccharides in reversible and irreversible experimental hepatic fibrosis.⁹ pp 53-56
29. Pérez-Tamayo R, Montfort I: Homeostasis of connective tissue. *Injury, Inflammation and Immunity*. Edited by L Thomas, JW Uhr, L Grant. Baltimore, Williams & Wilkins Co., 1964, pp 3-21
30. Okazaki I, Maruyama K: Collagenase activity in experimental hepatic fibrosis. *Nature* 252:49-50, 1974
31. Gross J, Lapière CM: Collagenolytic activity in amphibian tissues: A tissue culture assay. *Proc Natl Acad Sci USA* 48:1014-1022, 1962

Acknowledgments

We gratefully acknowledge the excellent technical help of Mr. Eusebio Tello.

[Illustrations follow]

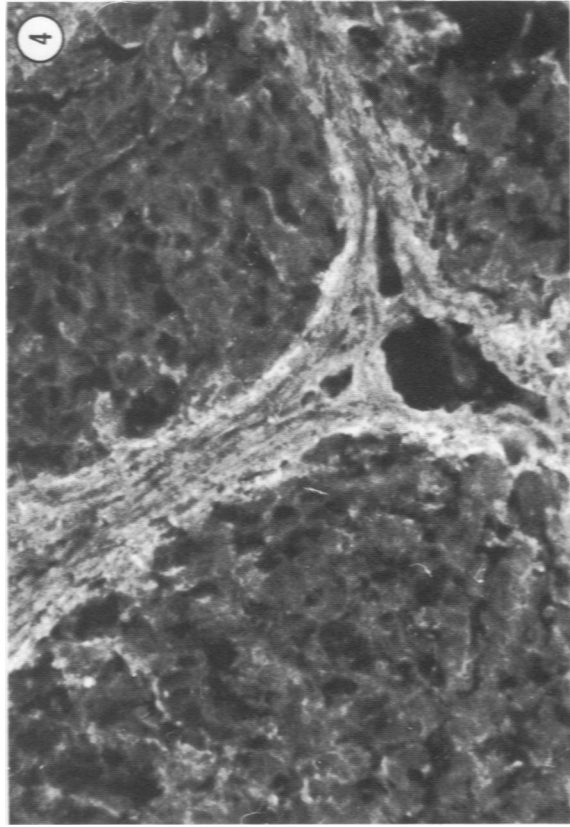
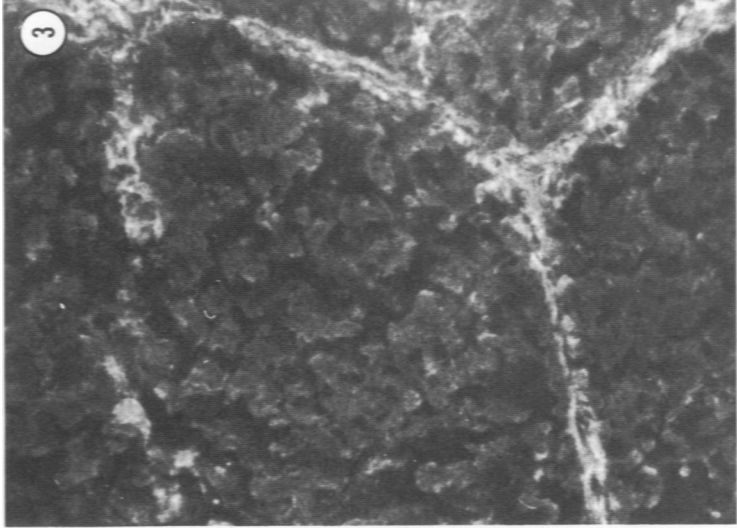
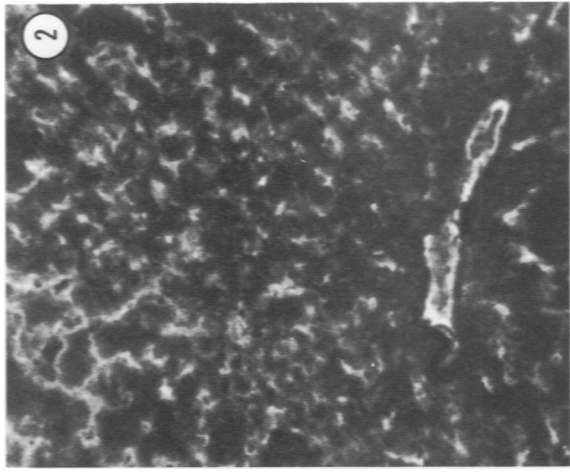
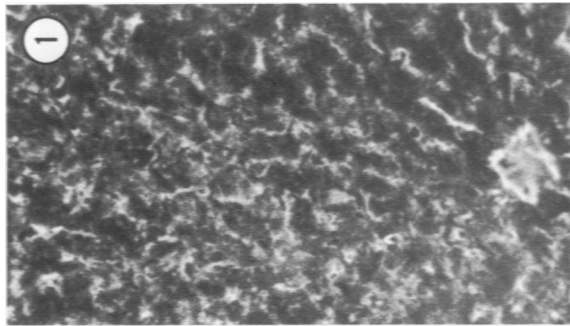


Figure 1—Distribution of collagenase in the normal rat liver. Collagen fibers in the wall of an efferent vein are positively stained in the lower part of the photomicrograph. Reticulum fibers are also stained with variable intensity. (Indirect immunofluorescence reaction for collagenase, $\times 125$) **Figure 2**—After 2 weeks (4 injections) of CCI, treatment. Disappearance of reticulum staining limited to the area surrounding an efferent vein. (Indirect immunofluorescence reaction for collagenase, $\times 125$) **Figure 3**—After 6 to 8 weeks (12 to 16 injections) of CCI, treatment, thin connective tissue bands are positively stained for collagenase. There is very little staining of reticulum fibers within the liver nodules. (Indirect immunofluorescence reaction for collagenase, $\times 150$) **Figure 4**—Liver of rat treated with CCI, for 12 weeks (24 injections) showing broad bands of fibrous tissue positively stained for collagenase. Note that fluorescence is more intense in the periphery of the connective tissue septum. (Indirect immunofluorescence reaction for collagenase, $\times 150$)

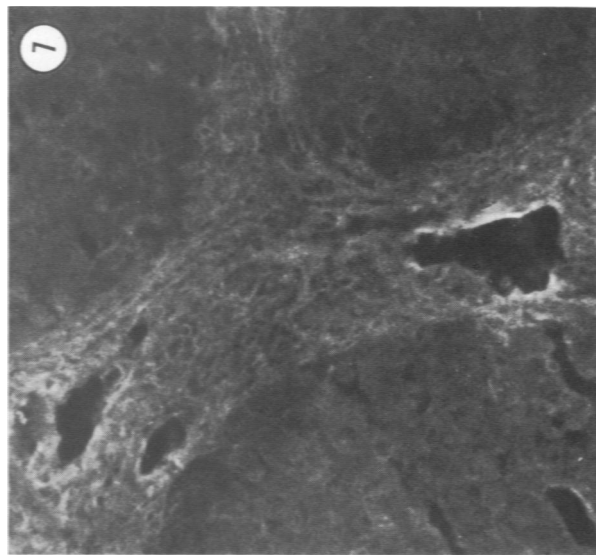
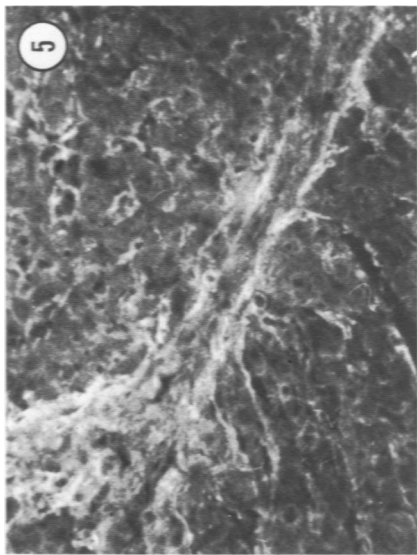


Figure 5—After 15 weeks of CCl₄ treatment (30 injections) the connective tissue septums are still positively stained, but the central portion is devoid of immunofluorescence. Note that reticulum fibers are again positively stained. (Indirect immunofluorescence reaction for collagenase, \times 150)

Figure 6—Another example of irreversible cirrhosis induced by 15 weeks of CCl₄ treatment (30 injections), in which the broad connective tissue septum is enclosing a small nodule of regenerated liver cells. The central part of the septum shows no immunofluorescence, which is limited to the outer layers. (Indirect immunofluorescence reaction for collagenase, \times 150)

Figure 7—Irreversible CCl₄ cirrhosis of the liver examined 6 months after discontinuation of treatment. A broad band of fibrous tissue with no immunofluorescence. (Indirect immunofluorescence reaction for collagenase, \times 125)

