

GENERALIZED LIPODYSTROPHY

BY

M. SEIP and O. TRYGSTAD

From the Paediatric Department and Paediatric Research Laboratory, University Hospital, Oslo

(RECEIVED FOR PUBLICATION MARCH 15, 1963)

In 1959, three patients with generalized lipodystrophy, increased growth rate and a number of other clinical features were described by one of us (Seip, 1959). The signs of the disease were present from birth, and two of the patients were siblings. The main clinical features of the syndrome were: generalized lipodystrophy, increased growth rate with acromegaloid pattern, large hands and feet, advanced bone age and dental development, muscular hypertrophy, increased muscular glycogen, hepatosplenomegaly (fatty infiltration and slight cirrhotic changes in the liver), cardiomegaly, corneal opacities, skin pigmentation and dry, coarse skin, hypertrichosis, phlebomegaly, and abnormal pneumoencephalogram. In two cases the parents were consanguineous.

Two further cases have now been seen at the Paediatric Department, University Hospital, Oslo, making our total number of cases five. Four of the five patients are from the same small area in south-western Norway.

Including our cases, a total of eight patients with congenital (or almost certainly congenital) generalized lipodystrophy have been reported in the literature. Two additional cases are known, but have not been published in detail. Generalized lipodystrophy may also occur as an acquired condition, often combined with diabetes ('lipotrophic diabetes').

The purpose of this report is to present two new cases of this very rare syndrome, and also some new information on our previously described cases. The corticosteroid metabolism in this condition will be discussed in some detail.

Case Reports

Case 1. A.E. is a girl born February 7, 1952. Since the last report in 1959 her rate of growth (Fig. 1) and skeletal maturation have decreased. Otherwise her clinical condition has remained essentially unchanged. She is attending the ordinary primary school where her progress has been average. In August 1962 her height was 157 cm. and her skeletal age 18 years. Epiphysal

fusion had not yet occurred, and we can predict that her adult height is likely to be normal. The skeleton was sclerotic. Her glucose tolerance was increased, as before. No signs of puberty were present. Her basal metabolic rate varied between 138 and 123%; her protein-bound iodine level was 8.0 γ %.

Case 2. M.E., the brother of A.E., was born on January 6, 1957. Since our 1959 report he has been seen twice in our department, in August 1961 and August 1962. He seems to follow the same pattern of growth and development as his sister. When last seen in August 1962 his height was 129.5 cm. and his skeletal age 9 years. His skeleton was sclerotic; protein-bound iodine level was 7.2 in 1961, and 5.5 in 1962; there was some cardiomegaly; glucose tolerance was normal in 1961.

Case 3. This boy, K.S., born May 5, 1957, was also reported in 1959. He is from a different part of the country and is not related to the other four patients. (A normal girl was born into this family in 1960.) He is now 130 cm., i.e. 5 cm. above the 97.5 percentile; his skeletal age is between 7 and 8 years, and there is an increased calcium content in his skeleton. His I.Q. is 80. The hyperlipaemia is less marked than previously. His protein-bound iodine level is 5.2. Glucose tolerance curve has remained flat.

Case 4. L.S.N., a boy born on July 2, 1959, after a normal pregnancy and delivery as the first child of young, healthy parents, weighed 4,100 g. and measured 53.5 cm. His paternal grandparents were first cousins.

Lipodystrophy was noticed at birth, and he was admitted to our department at 4 months of age. He presented the same clinical picture as the three foregoing patients (Fig. 2), being tall and athletic with muscular hypertrophy and moderately hypertrophic external genitalia. The liver was enlarged, reaching down to the umbilicus; the spleen was felt one to two fingers below the costal margin. His scalp was covered by abundant blond hair which soon became curly. Hypertrichosis and hyperpigmentation were present. His rate of growth has been much above normal: when seen in the ward at 3 years of age he measured 111.5 cm., i.e. 6.5 cm. above the 97.5 percentile. His psychomotor develop-

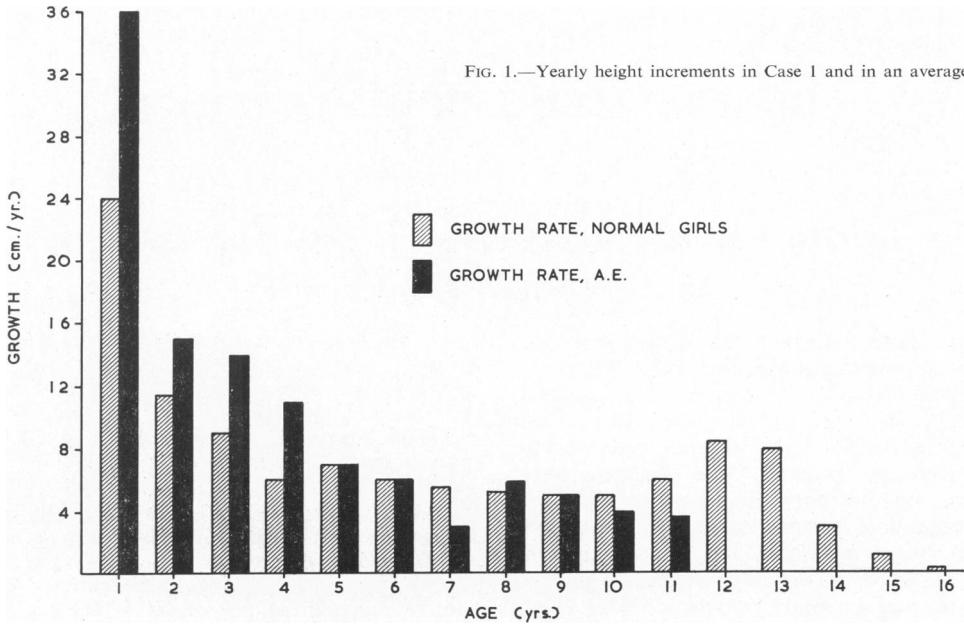


FIG. 1.—Yearly height increments in Case 1 and in an average girl.

ment has been normal. His blood pressure was 130/80 mm. Hg at 3 years of age. No corneal opacities have been demonstrated in this patient.

Special Studies. A diffuse enlargement of the heart was shown on radiological examination (Fig. 3). The electrocardiogram and the chromosomal pattern were both normal. His skeletal development had advanced in proportion to his rate of growth: at 3 years of age his skeletal age was between 6 and 7 years. The skeleton was sclerotic. A pneumoencephalogram showed general-ized dilatation of the ventricles of the brain, including the

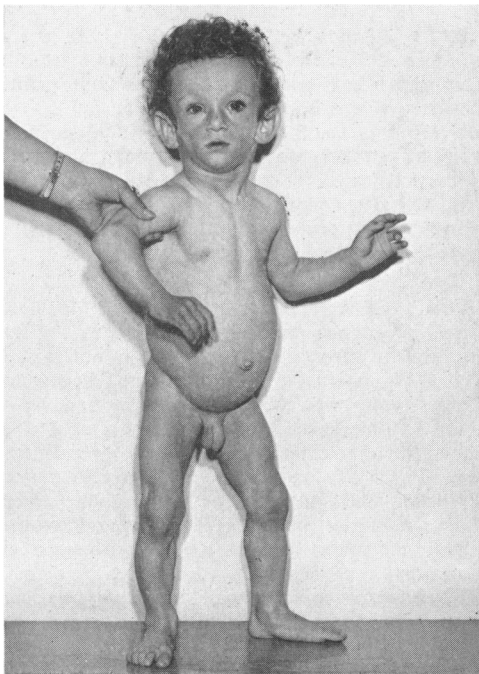


FIG. 2.—Case 4, 1 year old.

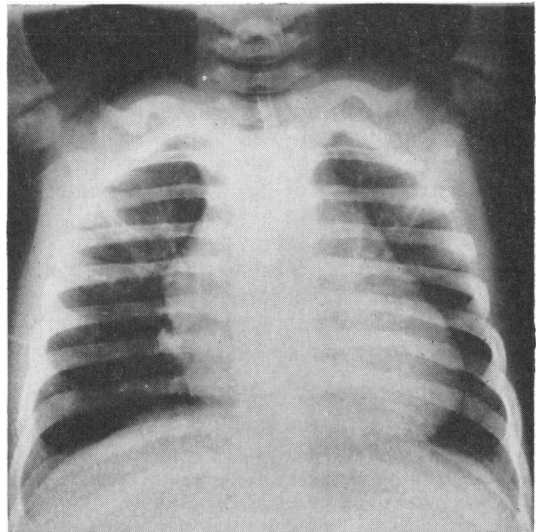


FIG. 3.—A diffuse enlargement of the heart has been demonstrable in all five cases. This film was taken at 2 years of age in Case 4.

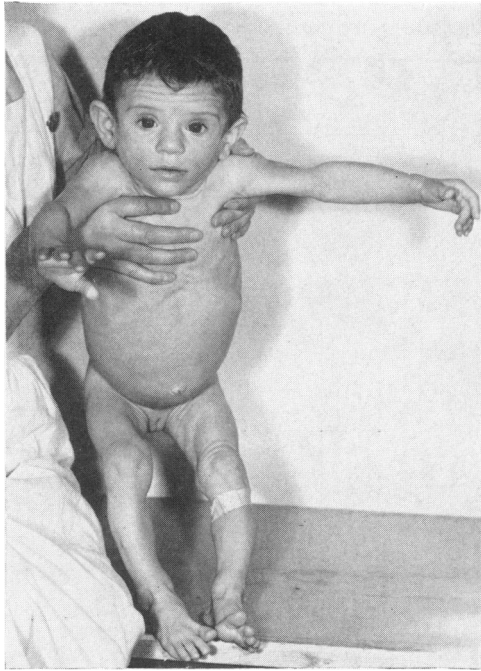

FIG. 4.—Case 5, 6 months old.

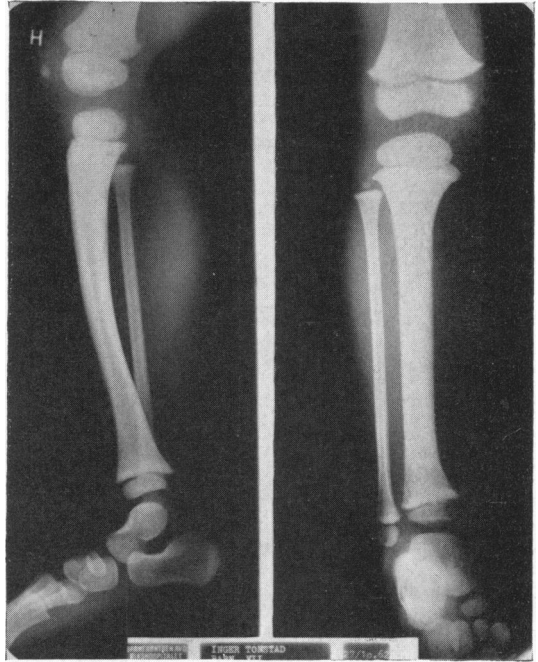


FIG. 5.—The sclerotic skeleton of Case 5 at 20 months.

third ventricle, and large basal cisterns. His serum total lipids were high, 1,650-1,000 mg./100 ml., with the most marked increase in neutral fats (607-338 mg./100 ml.). Both parents also have relatively high serum lipid levels particularly as regards the triglyceride fraction which was found to be 544 mg./100 ml. in the mother and 355 mg./100 ml. in the father. The patient's glucose tolerance curve was flat in 1959 and 1960, but normal in 1961. Serum proteins, calcium and phosphatase were normal; serum phosphorus 5.1, 4.6 and 5.1 mg./100 ml. Protein-bound iodine level was 4.7 γ %.

Case 5. I.T., a girl born on February 27, 1961, after a normal pregnancy and delivery, weighed 3,830 g. and her length was 54 cm. The parents and an older sister are living and healthy. Lipodystrophy was present at birth, and soon afterwards an increased rate of growth was also observed. She was admitted to our department in August 1961, and readmitted in March 1962 and in October 1962.

The clinical features have been like those of the other patients (Fig. 4). At 20 months of age the height was 94 cm. (5.5 cm. above the 97.5 percentile), and the skeletal age was 4 years. The calcium content of the skeleton was increased (Fig. 5). She was shown to have a generalized enlargement of the heart; blood pressure was 105/60 mm. Hg. The liver was palpable 3 cm. below the costal margin; the spleen was not felt. Hypertrichosis and hyperpigmentation were present. Psychomotor development has been essentially normal.

A pneumoencephalogram showed a mild but unquestionable dilatation of the right lateral ventricle, the third ventricle and the basal cisterns. There were no abnormal findings on ophthalmological examination. The chromosomal pattern was normal.

The serum total lipid level was raised, up to 1,490 mg./100 ml., mainly due to an increase in neutral fats of up to 570 mg./100 ml. It was especially high during the first two admissions. Both parents also have relatively high levels of triglycerides, the mother 500 mg./100 ml., and the father 370 mg./100 ml. The glucose tolerance curve has been flat. Protein-bound iodine level was 3.8 in March 1962; serum proteins, calcium and phosphatase were normal, and serum phosphorus was slightly increased, 6.5 and 6.3 mg./100 ml. at 6 months, and 6.0 mg./100 ml. at 20 months.

Discussion

Ziegler (1928) described the first reported patient with generalized lipodystrophy. In this case the lipodystrophy developed in the lower half of the body at 11 years of age, and not until 13 years later in the upper half. The patient developed diabetes when she was 23, and died from an unknown cause at 38. In the cases of generalized lipodystrophy described later, the lipodystrophy has almost invariably been generalized from the very beginning.

Up till the present, 14 acquired cases have been

TABLE 1
GENERALIZED LIPODYSTROPHY, ACQUIRED FORM

Author	Age at Last Report (yrs.)	Age at Onset of Lipoatrophy (yrs.)	Age at Onset of Diabetes (yrs.)	Sex	Age at Death	Cause of Death
Ziegler (1928)	38	11 (lower part) 24 (upper part)	23	F	38	Unknown
Hansen and McQuarrie (1940), Hansen, McQuarrie and Ziegler (1961)	9	3	6	M	9	Gastro-intestinal haemorrhage
Lawrence (1946)	33	28	25	F	33	Died following operation for ovarian cysts
Corner (1952)	22	1½, following pertussis	14	F	32	Gastro-intestinal haemorrhage
Berardinelli (1954)	7	2½	5-6	M	7	Gastro-intestinal haemorrhage
Davis and Tizard (1954), J. A. Davis (1962), personal communication ..	11	1½, following measles	—	F	—	—
Fontan, Verger, Couteau and Péry (1956)	11	1½	—	F	?	Gastro-intestinal haemorrhage
Witzgall (1957)	41	23(?), following difficult delivery	—	F	41	Heart failure
J. W. Conn, cited by Craig and Miller (1960)	12	7	8	M	—	—
J. W. Conn, cited by Craig and Miller (1960)	28	6	21	F	—	—
Craig and Miller (1960)	21	13	13	F	—	—
Craig and Miller (1960)	17	12	12	F	—	—
B. Hood, cited by Craig and Miller (1960)	55	42 or less	40	F	—	—
S. Aarseth (1962), personal com- munication	62	33	50	F	—	—

reported (Table 1), three male and 11 female: in 11 of these the lipoatrophy was first observed in infancy or in childhood. All except three had diabetes at the time of publication. Usually lipoatrophy precedes the diabetes, often by many years, but in two cases (Lawrence, 1946; B. Hood, cited by Craig and Miller, 1960) diabetes seems to have developed first. The term lipoatrophic diabetes, introduced by Lawrence for this condition, is therefore somewhat misleading, particularly when applied to the congenital form, as will be shown later. Most cases of acquired lipoatrophy have shown marked hyperlipaemia, hepatomegaly, a high basal metabolic rate not due to hyperthyroidism, and a number of other features. We know that at least seven of these patients have died, five from gastro-intestinal haemorrhage, probably due to oesophageal varices, one after operation, and one from an unknown cause.

The known cases of congenital lipodystrophy are tabulated in Table 2. They comprise four male and six female, a much closer sex ratio than in the acquired form. Only one of these patients had

diabetes at the time of the last report, compared to 11 out of 14 among the acquired cases. None in this group had died, but the periods of observation were shorter than in the acquired group.

We have good reasons to believe that some cases of congenital lipodystrophy are hereditary with an autosomal recessive mode of transmission (Seip, 1959). Thus, in four of our five patients, the disease is thought to be genetically determined. These four derive from a restricted area in south-western Norway, and three of them live in a small and isolated community. Their parents have some degree of hyperlipaemia of a similar pattern to the patients. The parents of Cases 1 and 2 are consanguineous, and so are the parents of Berardinelli's case (1954).

Chromosome analyses were performed on all five cases by A. Brøgger and C. B. van der Hagen at the Institute of Medical Genetics, University of Oslo. In Case 1 an abnormal chromosome with a long, heterochromatic segment was found. The chromosome is tentatively interpreted as a C' chromosome (Patau notation) with a duplication of the heterochromatic segment, making the patient trisomic

TABLE 2
GENERALIZED LIPODYSTROPHY, CONGENITAL FORM

Author	Age at Last Report (yrs.)	Age at Onset of Lipodystrophy (yrs.)	Age at Onset of Diabetes (yrs.)	Sex
Berardinelli (1954)	2 $\frac{2}{12}$	Birth(?)	—	M
Seip (1959)	10 $\frac{1}{12}$	Birth	—	F
Seip (1959)	5 $\frac{1}{12}$	Birth	—	M
Seip (1959)	5 $\frac{1}{12}$	Birth	—	M
Schwartz, Schafer and Renold (1960)	16	Birth(?)	12	F
Senior (1961)	2 $\frac{1}{12}$	Birth	—	F
Seip and Trygstad (present paper)	3	Birth	—	M
Seip and Trygstad (present paper)	1 $\frac{2}{12}$	Birth	—	F
Moltan, unpublished data	—	Birth	—	F
Evans, unpublished data	—	Birth	—	F

for the heterochromatic region of chromosome C'. The quality of the chromosome preparations from the other patients is not in all cases satisfactory enough to exclude the existence of the abnormal chromosome in their karyotypes. A more decisive evaluation of the chromosome findings must await supplementary chromosome analyses.

In some of the patients with acquired lipodystrophy the signs appeared after a severe acute illness which may have damaged the brain, severe pertussis (Corner, 1952), severe measles (Davis and Tizard, 1954) and exceptionally difficult delivery (Witzgall, 1957). In the case reported by Davis and Tizard mild left-sided hemiplegia was also present. In most cases, however, the onset has been gradual without an initial acute episode.

In spite of the many striking similarities between the congenital and the acquired form of generalized lipodystrophy it will be apparent from the discussion above that there are differences in apparent aetiology, in sex distribution and in incidence of diabetes, etc. The prognosis *quoad vitam* is probably more serious in acquired cases.

The clinical picture of congenital lipodystrophy was described in detail in an earlier publication (Seip, 1959). A few new features can now be added: we have been able for instance to make further observations on our patients' growth pattern. The oldest is now more than 10 years of age, and her growth velocity curve is presented in Fig. 1. We see that the growth rate is very high during the first, second, third and fourth years of life, but thereafter falls off. Her increase in height age corresponds closely with her increase in skeletal age. The skeletal age is now 18 years, and we can predict that the adult height will be quite normal. *Sexual development corresponds to chronological age, and not to skeletal age.* The urinary output of oestrogens is low (oestriol 1.3 $\mu\text{g./day}$, oestrone 0.1 $\mu\text{g./day}$, oestradiol 0.5 $\mu\text{g./day}$). The other four patients are younger but seem to follow

the same pattern of growth and skeletal maturation.

In our five patients the skeleton was sclerotic with increased calcium content (Fig. 5). J. A. Davis (personal communication, 1962) found that the calcium excretion in the urine was consistently raised in his case. We have studied the calcium output in two patients only: in Case 3 it was found to be 112 mg./day at 5 $\frac{1}{2}$ years of age, and in Case 5, 32 mg./day at 20 months (i.e. not very high).

An abnormal pneumoencephalogram has been a constant finding in our patients; the changes vary from a slight dilatation of the third ventricle and basal cisterns in two of them to a more pronounced and generalized dilatation of the brain ventricles in the remaining three. The brain lesions have been essentially symmetrical, except in Case 5. Case 3 showed a moderate mental retardation (I.Q. = 80), while in the others the intelligence seemed to be within normal limits.

The cardiomegaly became somewhat more pronounced with increasing age (Fig. 3). The enlargement of the heart was diffuse, and the picture suggested a storage disease of the heart muscle (glycogen?). Cardiac catheterization in two of the cases showed a moderate increase in pulmonary artery pressure and pulmonary artery resistance. These findings are compatible with the concept of a myocardial affection. Case 3 also had an atrial septal defect.

The hyperlipaemia was most marked during the first few years of life, but still persists in the 11-year-old girl. The hepatosplenomegaly also seems to regress to some extent with increasing age. All five patients showed an increased glucose tolerance during their first stay in our department, but in two of them the glucose tolerance curves have subsequently become normal. No signs of diabetes have developed so far. Further studies on the disturbances in lipid and carbohydrate metabolism are in progress, and the results will be published later.

TABLE 3
URINARY OUTPUT OF 17-KETOSTEROIDS AND OF 17-KETOGENIC STEROIDS (mg./24 hrs.)

Age (yrs.)	Case 1		Case 2		Case 3		Case 4		Case 5	
	17-KS	17-KGS	17-KS	17-KGS	17-KS	17-KGS	17-KS	17-KGS	17-KS	17-KGS
$\frac{1}{3}$							0.1	0.3	0.2	0.5
1			0.5	3.1	0.3	4.7	0.8		0.2	1.9
2			0.5				2.3	3.3	0.8	6.3
3							0.8	3.8		
4			1.1	4.0	2.8	7.2				
5					0.9	7.0				
6	1.7	10.4			0.2	1.3				
10	1.8	8.1								
11	5.5	6.3								

Bold figures are those at or above the upper limit of normal for the patient's age.

Corticosteroid Metabolism. The patients show certain abnormalities in corticosteroid metabolism. The urinary output of 17-ketogenic steroids is usually moderately increased or at the upper limit of normal (Table 3). (The Diczfalussy, Plantin, Birke and Westman (1955) modification of Norymberski's method was used for these determinations, and the bold figures are those at or above the upper limit of normal for the patient's age.)

The excretion of 17-ketosteroids is also shown in Table 3. The bold figures are considered to be at or slightly above the upper limit of normal with the method used (Vestergaard, 1951). Although none of these values is grossly abnormal, amounts of 17-ketosteroids in the urine are slightly increased or near the upper limit of normal.

The results of metyrapone tests are set out in Table 4: 10-15 mg./kg. body weight of metyrapone were given orally (in one instance intravenously) every six hours for 24 hours, and the amount of 17-ketosteroids, 17-ketogenic steroids, and, in most instances, tetrahydro S in the urine before and after administration was determined. The results of

these tests showed great variability, but the increase in 17-ketosteroids, 17-ketogenic steroids and tetrahydro S excretion was slight or negligible. Two of the patients had reduced responses at one determination, but normal responses at another. This variability in response to metyrapone may indicate a disturbance in the regulation of A.C.T.H. production and provides new evidence in favour of our theory that the syndrome of generalized lipodystrophy is characterized by a hypothalamic disturbance with increased formation of several pituitary hormones. (This theory is also supported by the following findings on post-mortem examination in H. Witzgall's case: lesions in the floor of the third ventricle, hyperplasia of the basophil cells of the anterior lobe of the pituitary gland, and adrenocortical hyperplasia (1962, personal communication).) In the two patients with a varying response to metyrapone the normal response was found at a time when the basal corticosteroid excretion was relatively low and a reduced response when it was high. A.C.T.H. stimulation tests, with determination of 17-ketosteroids and 17-ketogenic steroids in

TABLE 4
SU-4885 TEST (ORAL)

Case No.	Age (yrs.)	17-KS (mg.)			17-KGS (mg.)			THS (μ g.)		
		Day			Day			Day		
		1	2	3	1	2	3	1	2	3
1	{ 10 11	5.5	5.4	7.7	10.5 6.3	11.6 8.7	15.5 8.0	0	2,150	6,660
2	5				5.7	4.8	6.9			
3	{ 5 6	0.9 0.2	0.8 1.0	0.6 1.8	7.0 1.3	5.6 5.2	3.6 10.0	26 92	81 795	12 1,420
4*	3	0.8	0.7		3.8	2.2		55	800	
5	1	0.2	0.2	0.5	1.9	2.3	2.5	0	6	92

* Intravenous test.

TABLE 5
PREGNANETRIOL IN URINE
(mg./day)

Case No.	Age (yrs.)	Pregnanetriol (mg./day)
1	10	3.5
2	5	3.0
3	5	0.9

the urine and hydroxysteroids in the plasma gave normal results, indicating a normal responsiveness of the adrenal cortex.

Pregnanediol excretion proved normal, but pregnanetriol excretion was high in two out of three patients studied (Table 5). The daily urinary output of aldosterone was determined in three patients and found to be increased in Case 1 (24 µg./day at 10 years of age) and in Case 5 (5 µg./day at 1 year) and normal in Case 3 (1 µg./day at 5 years).

Growth Hormone Determinations. Many features of our syndrome may indicate a moderately increased formation of pituitary growth hormone. Dr. J. Girard at the Children's Hospital, University of Basel, Switzerland, has kindly determined the growth hormone (STH) level in the plasma in our five patients by means of Read's haemagglutination inhibition method (Table 6). The level was found to be much increased in Case 5, moderately increased in Cases 1 and 4, high normal in Case 3, and average in Case 2. The case with the highest growth hormone level also had the highest serum phosphorus level, 6.0-6.5 mg./100 ml., as we might expect.

Summary

Findings in five children suffering from congenital generalized lipodystrophy with associated endocrine manifestations are described. A further five patients with this very rare syndrome have been reported by other authors. In addition, at least 14 cases of the acquired form of generalized lipodystrophy (lipotrophic diabetes) have so far been reported. A survey of these conditions has been given.

There are many similarities between the congenital and acquired cases of lipodystrophy, but also some dissimilarities. The congenital form may be genetically determined with an autosomal recessive mode of inheritance, affects the two sexes almost equally (female predominates in the acquired group) and is not so liable to lead to diabetes. The prognosis *quoad vitam* is probably more serious in the acquired group, gastro-intestinal haemorrhage being the most frequent cause of death: the periods of

TABLE 6
GROWTH HORMONE LEVELS IN THE PLASMA

Case No.	Age (yrs.)	STH γ%
1	10	54
2	5	36
3	5	45
4	3	54
5	1½	82

observation are, however, shorter for the congenital group. Noteworthy disturbances in lipid and carbohydrate metabolism are found both in congenital and acquired cases. In one of our cases an abnormal chromosome with a long heterochromatic segment was demonstrated.

The corticosteroid metabolism in our five patients has been studied in some detail. They have a tendency towards increased excretion of 17-ketogenic and 17-ketosteroids, and show a variable and often poor or absent response to metyrapone administration. The urinary output of pregnanetriol and aldosterone was relatively high in two out of three patients studied. The pituitary growth hormone level in the plasma was found to be increased in three of the patients, high normal in one and average in one. A disturbance of the hypothalamic-hypophysial system is thought to be present.

REFERENCES

- Berardinelli, W. (1954). An undiagnosed endocrinometabolic syndrome: Report of 2 cases. *J. clin. Endocr.*, **14**, 193.
- Corner, B. D. (1952). Lipotrophic diabetes. *Arch. Dis. Childh.*, **27**, 300.
- Craig, J. W. and Miller, M. (1960). Lipotrophic diabetes. In *Diabetes*, ed. R. H. Williams, p. 700. Hoeber, New York.
- Davis, J. and Tizard, J. P. M. (1954). Generalized lipodystrophy. Infectious mononucleosis. Mild infantile hemiplegia. *Proc. roy. Soc. Med.*, **47**, 128.
- Diczfalusy, E., Plantin, L.-O., Birke, G. and Westman, A. (1955). Some factors influencing the estimation of urinary 17-ketogenic steroids. *Acta endocr. (Kbh.)*, **18**, 356.
- Fontan, A., Verger, P., Couteau, J. M. and Péry, M. (1956). Hypertrophie musculaire généralisée à début précoce, avec lipodystrophie faciale, hépatomégalie et hypertrophie clitoridienne chez une fille de 11 ans. *Arch. franç. Pédiat.*, **13**, 276.
- Hansen, A. E. and McQuarrie, I. (1940). Serum and tissue lipids in a peculiar type of generalized lipodystrophy (lipohistiodiæsis). *Amer. J. Dis. Child.*, **60**, 754.
- and Ziegler, M. R. (1961). Lipohistiodiæsis. A syndrome of lipodystrophy universalis, accelerated growth, lipemia, hepatic cirrhosis, and insulin-resistant diabetes without ketosis. *J.-Lancet*, **81**, 533.
- Lawrence, R. D. (1946). Lipodystrophy and hepatomegaly with diabetes, lipaemia, and other metabolic disturbances: A case throwing new light on the action of insulin. *Lancet*, **1**, 724 and 773.
- Schwartz, R., Schafer, I. A. and Renold, A. E. (1960). Generalized lipotrophy, hepatic cirrhosis, disturbed carbohydrate metabolism and accelerated growth (lipotrophic diabetes). *Amer. J. Med.*, **28**, 973.
- Seip, M. (1959). Lipodystrophy and gigantism with associated endocrine manifestations. A new diencephalic syndrome? *Acta paediat. (Uppsala)*, **48**, 555.
- Senior, B. (1961). Lipodystrophic muscular hypertrophy. *Arch. Dis. Childh.*, **36**, 426.
- Vestergaard, P. (1951). Rapid micro-modification of the Zimmermann/Callow procedure for the determination of 17-ketosteroids in urine. *Acta endocr. (Kbh.)*, **8**, 193.
- Witzgall, H. (1957). Hyperlipämische Lipotrophie. *Ärztl. Wschr.*, **12**, 1093.
- Ziegler, L. H. (1928). Lipodystrophies: report of seven cases. *Brain*, **51**, 147.