

# Diagnostic Value of the Café-au-lait Spot in Children

DENNIS WHITEHOUSE

*From the Department of Pediatrics, Johns Hopkins Hospital, Baltimore, Maryland, U.S.A.*

The significance of the café-au-lait spot in the diagnosis of certain disorders of childhood is still not as widely appreciated as it should be, partly due to lack of information as to the normal incidence of such pigmentation, and partly to confusion over its relation to other forms of congenital pigmentation.

The varieties of congenital melanin pigmentation of the skin consist of a number of separate entities superimposed upon the basic normal colour of the skin, depending on the racial and genetic endowment of the individual. Although these entities are clear cut and separate in form and histology, and irrespective of the basic colour of the skin, a small number may give rise to difficulty in differentiation from each other. These accessory pigmented areas include the various types of moles or melanotic naevi, mongolian spots, and café-au-lait spots. The various types of vitiligo also merit inclusion in this group, because there is often a distinct suggestion of hyperpigmentation at the border of the depigmented areas.

Although these pigmentary changes are so universally present as to be regarded as normal, under certain circumstances they may indicate the coexistence of an underlying disease. This is particularly so with respect to the café-au-lait spot and, to a lesser degree, to the reverse phenomenon, vitiligo. Even in a very recent and comprehensive review of the pigment cell (Riley and Fortner, 1963), the café-au-lait spot has been largely ignored.

Early recognition of the importance of the café-au-lait mark was probably obscured by the nineteenth century grouping of all congenital pigmented birth marks as 'pigmented naevi', but Marie and Bernard (1896) and Chauffard (1896) independently drew attention to the association of certain types of pigmentation of the skin with generalized neurofibromatosis of the type previously described in 1882 by von Recklinghausen. Since that time the significance of these observations has been amply confirmed and extended, but the condi-

tions under which the association may be made are still not as widely recognized as they should be. In 1950, Burman delineated the characteristics of the café-au-lait spot and, in a study on a small group of patients with various disorders including congenital deformities, he came to the conclusion that these skin markings were associated especially with mesodermal and skeletal disorders. Crowe and Schull (1953) studied the incidence of these marks in 'normal' individuals in an institution, together with a group of patients with neurofibromatosis and their apparently non-affected relatives. Using a minimal size criterion of 1.5 cm., they concluded that any person with 6 or more café-au-lait spots should be presumed to have neurofibromatosis until proven otherwise.

Owing to the fact that careful scrutiny will often show these spots to be present in the first few weeks or months of life, and certainly fully developed by the age of 5 years, whereas the more classical features of neurofibromatosis are often not present before the age of puberty, it becomes very important to define the clinical criteria for normality in childhood. The pigmentation may then be crucial in making a correct diagnosis when there are associated manifestations of this disease, such as glaucoma or certain skeletal anomalies which may be present at birth or soon after, before the neurofibromatous tumours are obvious.

This study was, therefore, undertaken to define the incidence of this type of pigmentation in normal children of 5 years and under.

## Methods and Materials

Information on the incidence of café-au-lait pigmentation in normal children was obtained by the examination of children in well-baby clinics conducted by the Baltimore City Health Department. The group consisted of white and Negro children aged 1 month to 5 years, seen at random in the course of their routine physical examinations. These examinations were normally carried out either at 1 month of age, at 6 months of age, or at yearly intervals thereafter. Each child was examined personally by the author in a good light, fully

undressed, early efforts having shown the ease with which small or faint marks could be missed. The minimum size used for inclusion in this study was 0.5 cm., in contrast with the study of Crowe and Schull, since it was felt that no confusion with freckles was likely to arise in this age-group. Any café-au-lait pigmented spot meeting this criterion was included, as long as it represented a circumscribed area, however irregular. Little difficulty was experienced in excluding mongolian spots or pigmented naevi; the former on the basis of their location and the bluish pigmentation, the latter on the basis of the darker colour of the pigmentation and the deeper nature of the lesion.

In every case where a café-au-lait spot was found, routine inquiry was made into the personal and family history, in order to uncover the possibility of the existence of any neuroectodermal or related disorder, including pigmentary anomalies.

Results

A total of 365 children was examined and Table I shows the over-all distribution of café-au-lait spots in the entire group of children. The graph in the Figure shows the distribution of café-au-lait spots in the white and Negro children respectively. As may be seen from the Table, nearly 99% of the children had two or less marks. The graph shows a significantly greater number of Negro children to have one or two marks compared with the white children (22% as compared with 11%, and 5% compared with 2%). Only one white child was seen with more than 2 café-au-lait spots. He showed 3, with no other evidence of abnormality. The other 3 children with more than 2 spots, all Negro, showed 4, 5, and 8 spots, respectively. The first child came from a family where both the mother and the maternal grandmother had similar multiple spots distributed over their bodies. At least 5 were seen on the mother in a limited examination. No one in the family was known to have developed tumours or any other diagnosable evidence of neurofibromatosis or related disease, but the family is regarded as an example of the *forme fruste* described by Weber (1909), and the child is therefore not strictly to be classified as 'normal'. The second child showed 5 café-au-lait spots identical with those seen in the

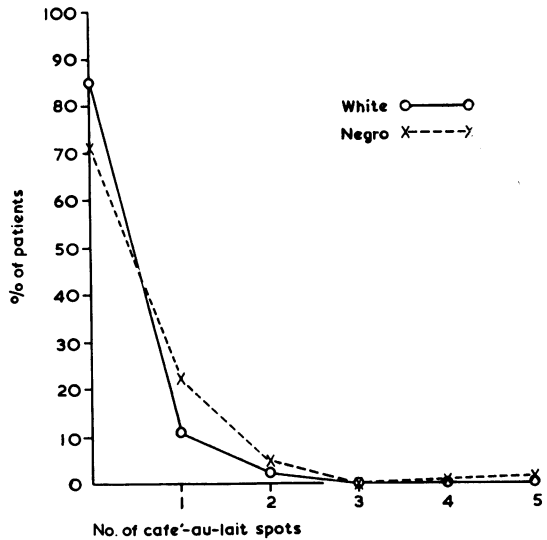


FIG.—Incidence of café-au-lait spots in white and Negro children under 5 years of age.

other children, but with no suggestion of associated disease and no family history of pigmentation or neuroectodermal dysplasia. The last child showed 8 typical café-au-lait spots and numerous small brown marks less than 0.5 cm. in size. He was mentally retarded, small in size (below the third percentile for his age), and his mother had classical neurofibromatosis with numerous café-au-lait spots over her body and marked molluscum fibrosum, including two large pendulous tumours. This child is, therefore, regarded as having neurofibromatosis, and again is not to be classified as a normal child.

Two other children merit individual description. One, a male Negro aged 1 year, showed a large area of pigmentation over the left side of his chest extending up into the axilla and for a short distance down the inner aspect of his left arm. The pigmentation was similarly distributed back and front, and had a relatively smooth outline and uniform depth of colour. It ran up to but did not cross the

TABLE  
Over-all Distribution of Café-au-lait Spots in Baltimore Children Under 5 Years of Age

	No. of Spots						Total
	0	1	2	3	4	5 or more	
No. of children .. ..	277	69	15	1	1*	2†	365
Percentage .. .. .	75.8	18.9	4.2	0.3	0.3	0.5	100

\* Child with *forme fruste*. † One child with neurofibromatosis.

midline. There was in addition one small café-au-lait spot about 2 cm. in diameter on the right shoulder. He also had a poorly defined area above the left shoulder which resembled a linear naevus. Despite the extent of this pigmentary abnormality, no other disease was found and the family history was negative. Technically, this child had only 2 café-au-lait spots, though one was massive in proportions. He appeared to be a normal child with a normal family history.

The other, also a Negro infant, showed 12 or more pigmented areas over the entire body, resembling the distribution of café-au-lait spots, but each appeared to be deeper and more blue than the usual café-au-lait spot. All the marks had disappeared by the age of 2 years and were clearly mongolian spots with an unusual distribution. No vitiliginous areas were seen in any child in the series, and no evidence of neuroectodermal dysplasia was found in any other child or in the family of any child with café-au-lait spots other than the two described above.

### Discussion

The café-au-lait spot is a distinct histological entity in that naevus cells are not seen in the deeper tissues. The pigmentation is found among the basal cells of the epidermis, either free or in melanocytes which are not easily seen in routine staining. Controversy still rages over the histology and ontogeny of these different birth marks. Curiously enough, the true pigmented naevi often show neurofibromatous changes in their deeper structures, according to Willis (1953). This is in contradistinction to the café-au-lait spot which is normally quite separate from neurofibromatous tissue, even when occurring in a patient with generalized neurofibromatosis.

It is a very definite clinical lesion and these results show that it is quite a common lesion in normal children even under the age of 5 years. Vitiligo appears to be much less common, though just as definite a lesion when seen. Multiple vitiliginous areas can be found on the body occasionally with smooth contours and uniform pallor, resembling a café-au-lait mark 'in reverse'. There is a considerable body of opinion to suggest that café-au-lait marks may both increase in intensity and in number with increasing age. The former process, though difficult to measure, is certainly seen in patients with neurofibromatosis and cutaneous pigmentation. No evidence was found to indicate an actual increase in the number of marks in any child in this series, and though this phenomenon cannot be ruled out, a possible explanation for the reported increase may be the fact that faint marks had not been previously

observed by the parents or physician. It is common for many parents to have failed to notice the marks at all before their attention is drawn to them by the examining physician.

The higher incidence of café-au-lait spots in the Negro is perhaps in keeping with the increased general pigmentation of the skin and also with the increased incidence of mongolian spots. Pack, Davis, and Oppenheim (1963) quote the incidence of the latter as being less than 5% in the white race compared with 95% in the Negro race. On the other hand, with regards to the true pigmented naevus, Pack, Lenson, and Gerber (1952) reported the average incidence of these as being 14.6 naevi per person in a study of white individuals, as compared to just under 2 per person in a group of Negroes. There is no clear evidence that neurofibromatosis is any more common in either race.

These results suggest that 1 or 2 café-au-lait spots in a child is a common and normal phenomenon. The incidence of more than 2 is distinctively uncommon and the evidence here, together with evidence from the many studies on children and adults with neurofibromatosis, not only indicates that multiple spots are highly suggestive of associated disease but that there may be a gap between the normal and abnormal distribution bridged by the very rare child who shows 3, 4, or possibly 5 marks with no abnormality. Most patients with neurofibromatosis and café-au-lait spots present far more than the commonly accepted 6 or more spots.

### Summary

Examinations were carried out on 365 children under 5 years of age for the presence of café-au-lait spots: 19% of the children showed one café-au-lait spot, but only 0.75% of the normal children showed more than 2 spots. The Negro children had a significantly higher total count of café-au-lait spots in each group as compared with the white children. Of the 3 children who had 4 or more spots, 2 showed evidence of either a *forme fruste* or true neurofibromatosis in both family and child.

It is concluded that the presence of multiple café-au-lait spots in a child under the age of 5 years is rare in normal children, and can be of considerable importance in suggesting the presence of an associated neuroectodermal disorder, such as neurofibromatosis. The presence of 5 or more such spots makes diagnosis of neuroectodermal dysplasia mandatory until proven otherwise. This fact is emphasized in view of the occasional manifestation of skeletal and visceral components of neurofibromatosis early in the first five years of life before classical tumours are present. In this situation

pigmentation may afford the only clue to accurate diagnosis and appropriate treatment.

I would like to express my thanks to Dr. Robert Farber and the nurses of the Baltimore City Health Department well-baby clinics for their co-operation in carrying out this study.

REFERENCES

- Burman, M. (1950). Significance of the café au lait spot. *Bull. Hosp. Jt. Dis. (N.Y.)*, **11**, 140.
- Chauffard, A. (1896). Dermo-fibromatose pigmentaire (ou neuro-fibromatose generalisée); mort par adénome des capsules surrénales et du pancréas. *Bull. Mém. Soc. méd. Hôp. Paris*, **13**, 777.
- Crowe, F. W., and Schull, W. J. (1953). Diagnostic importance of café-au-lait spot in neurofibromatosis. *Arch. intern. Med.*, **91**, 758.
- Marie, P., and Bernard, A. (1896). Présentation d'un malade atteint de neurofibromatose généralisée. *Bull. Mém. Soc. méd. Hôp. Paris*, **13**, 200.
- Pack, G. T., Davis, J., and Oppenheim, A. (1963). The relation of race and complexion to the incidence of moles and melanomas. *Ann. N. Y. Acad. Sci.*, **100**, 719.
- , Lenson, N., and Gerber, D. M. (1952). Regional distribution of moles and melanomas. *A.M.A. Arch. Surg.*, **65**, 862.
- von Recklinghausen, F. (1882). *Ueber die multiplen Fibrome der Haut und ihre Beziehung zu den multiplen Neuomen*. A. Hirschwald, Berlin.
- Riley, V., and Fortner, J. G. (Editors) (1963). The pigment cell, molecular, biological, and clinical aspects. *Ann. N.Y. Acad. Sci.*, **100**.
- Weber, F. P. (1909). Cutaneous pigmentation as an incomplete form of Recklinghausen's disease, with remarks on the classification of incomplete and anomalous forms of Recklinghausen's disease. *Brit. J. Derm.*, **21**, 49.
- Willis, R. A. (1953). *Pathology of Tumours*, 2nd ed., pp. 902, 904. Butterworth, London.