

Amnioscopy and Foetal Blood Sampling: Observations on Foetal Acidosis*

E. SALING†

From Department of Obstetrics and Gynaecology Berlin-Neukölln, West Berlin

The assessment of the state of the foetus has in the past depended almost entirely on auscultation of the foetal heart. Two methods have recently been developed which enable the state of the foetus during late pregnancy and during labour to be observed. In late pregnancy amnioscopy is employed, and during labour analysis of foetal blood.

Amnioscopy

Amnioscopy is available as an out-patient procedure, whenever hazards threaten the life of the foetus during late pregnancy. An endoscope—the amnioscope—is passed into the cervical canal so that the amniotic fluid can be inspected through the intact forewaters. Amniotic fluid which is clear, or milky from emulsification of vernix, indicates that conditions within the uterus are normal. Green or yellow liquor or an absence of liquor should indicate that there are signs of threatened danger to the foetus.

Because nearly all the abnormalities of late pregnancy endangering the life of the foetus are only slowly progressive, it is only necessary to perform amnioscopy as a screening test every other day.

Indications. Amnioscopy should be carried out if there is any suspicion of placental insufficiency during the last six weeks of pregnancy. This includes nearly every intrauterine danger to the foetus in late pregnancy. The main hazards are maternal toxæmia and suspected postmaturity.

Technique. The patient is placed in the lithotomy position and a pelvic examination made. According to the state of the cervix, the largest suitable amnioscope is selected, the external diameters of the amnioscope tubes available being 12, 16, and 20 mm. The selected tube is guided by one or two fingers into the cervical canal. The

obturator is removed, and a light source is inserted (Fig. 1). In most cases it is possible without difficulty to obtain a reliable estimate of the colour and quantity of the amniotic fluid.

Significance of positive amnioscopic findings. A foetus that is surrounded by meconium-stained, bilirubin-stained, or deficient liquor must be regarded as in danger. The presence of these signs is an indication, therefore, for immediate rupture of the membranes so that blood can be obtained for analysis, and the state of the foetus assessed. Analysis of blood from babies with positive amnioscopic findings enables a decision to be taken as to whether spontaneous delivery can be safely awaited, or whether surgical intervention to hasten delivery is preferable.

Dangers of amnioscopy. The risk of introducing infection by amnioscopy is slight. The incidence of post-partum morbidity in patients subjected to amnioscopy is practically the same as in those who have not been examined vaginally (Giaquinto and Abelli, 1964; Imholz, 1965; Tittler, 1964).

The incidence of inadvertent rupture of the membranes is 2.1%. The danger of inducing the onset of labour in women who have not yet reached term is similarly low, the incidence of unintentionally provoked premature labour being about 1%.

Foetal Blood Sampling

The presenting part of the foetus is visualized, either with the help of a conical endoscope (Fig. 2), or, if the cervix is sufficiently dilated, with a speculum. After making the skin hyperæmic by freezing with ethylchloride spray, it is smeared with a layer of paraffin oil so that the blood will collect in a drop. A stab incision is made. The blood that collects is sucked into a heparinized capillary tube, and its pH measured. The Astrup equipment is

* Based on a lecture given at St. Mary's Hospital, London, on March 23, 1966.

† Address: 1 Berlin 44, Mariendorfer Weg 28, Germany.

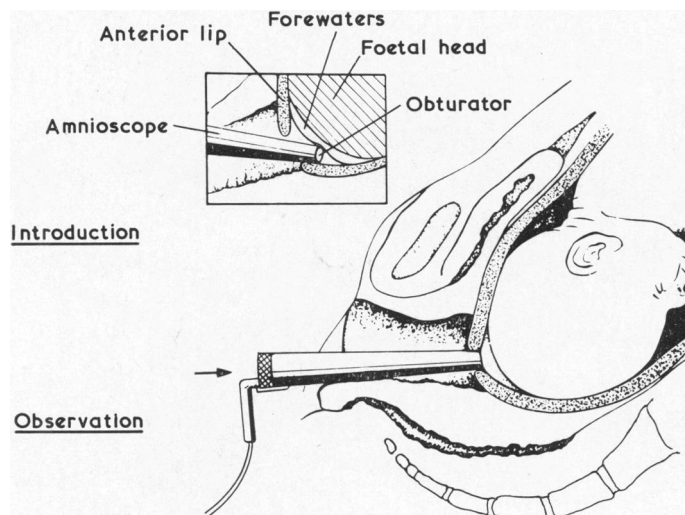


FIG. 1.—Amnioscopy. Inset shows introduction of the instrument. Below, the instrument in place with the obturator withdrawn.

suitable for pH measurement, and allows also the PCO_2 , bicarbonate, and base excess to be measured. An acidosis can thus be characterized as either *metabolic* (lowered bicarbonate and base-excess), or *respiratory* (raised PCO_2).

The presence of a caput succedaneum exerts a negligible effect on the results, as has been shown by comparing blood values from the foetal scalp with those from the umbilical vessels (Saling, 1966a).

Two Forms of Foetal Acidosis Resulting from Hypoxia

Two types of intrauterine disturbance are seen, the slowly developing and the rapidly progressive. A typical example of the slowly developing disturbance is placental insufficiency, while umbilical cord obstruction illustrates the rapidly progressive type.

The slowly developing type of disturbance is the more common. Analysis of foetal blood has defined

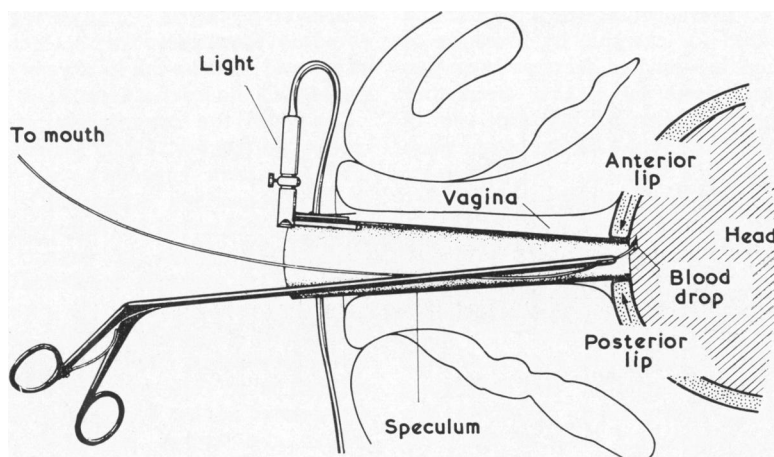


FIG. 2.—Foetal blood sampling. The presenting part has been pricked, and a drop of blood is about to be sucked into a heparinized tube, held in special forceps.

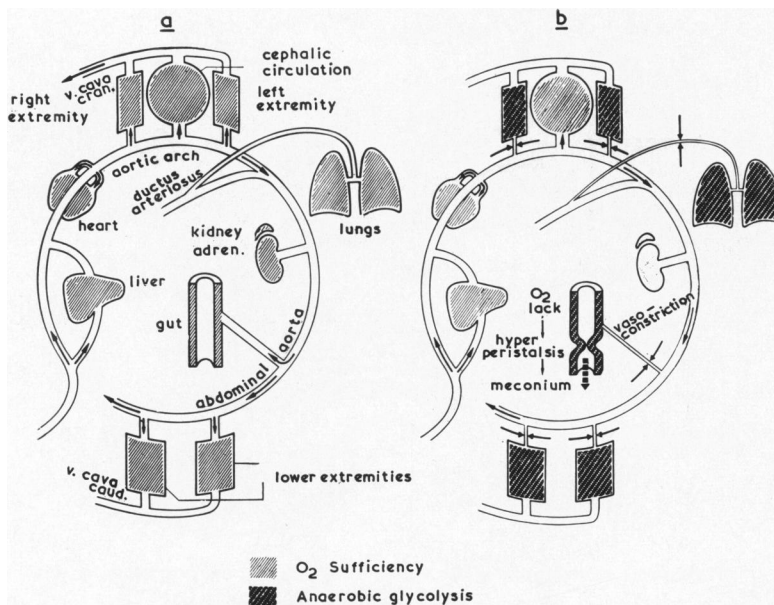


FIG. 3.—Diagrammatic representation of 'oxygen-conserving adaptation' of circulation in the foetus. (a) All organs are well perfused when oxygenation is normal (light hatching). (b) When oxygen supplies are limited, vaso-constriction ($\rightarrow \leftarrow$) cuts off arterial supplies to less essential organs, with resulting anaerobic glycolysis in these (dark hatching).

the picture of *primary metabolic acidosis*. This is a metabolic acidosis caused by an accumulation of lactic acid, associated with normal or nearly normal blood oxygen levels. This condition may develop insidiously and is especially dangerous because there are seldom any marked changes in the foetal heart rate.

Primary metabolic acidosis is thought to arise in the following way. If as a consequence of placental insufficiency—caused for example by toxæmia or postmaturity—there is a gradual decrease in oxygen supply, the foetus reacts by making circulatory adjustments aimed at economizing the use of oxygen. The blood supply to less important parts of the body, such as the muscles, skin, intestines, and lungs, is reduced by vasoconstriction (Fig. 3b). In this way a number of organs, which would otherwise consume oxygen, are more or less cut off from their source of supply of oxygen. Thus other organs essential for life are enabled to maintain near normal oxygenation. Because the total oxygen requirements of the foetus have now been reduced, the oxygen content of the circulating arterial blood remains near normal. However, this 'oxygen-conserving adaptation' leads to anaerobic glycolysis in the ischaemic tissues, lactic acid is formed in increased amounts, and escapes into the central circulation. In this way, blood obtained

from the central circulation shows an excess of lactic acid with a near normal oxygen level.

Scholander (1959) observed diving seals and obtained evidence that somewhat similar circulatory adjustments occurred to reduce oxygen consumption. During a dive there was a great reduction in the blood flow through muscles, which coincided with a local accumulation of lactic acid from anaerobic glycolysis. The diving seal differs however from the stressed foetus, since the arterial blood of the seal shows a fall in oxygen content with little increase in the level of lactic acid.

Some of the experiments of Dawes and his colleagues (Dawes, 1962; Dawes and Mott, 1962) also lend some support to the hypothesis of an 'oxygen-conserving adaptation'. In foetal lambs subjected to a reduction in oxygen supply the total foetal consumption of oxygen fell, and when subjected to asphyxia the blood flow through the lungs was reduced. In the presence of a slowly developing 'oxygen-conserving adaptation' of the foetal circulation, the intestinal tract seems to be affected at an early stage by vasoconstriction. In asphyxiated adults (Van Liere, 1942), a local oxygen deficit also causes increased peristalsis, which Desmond, Lindley, Moore, and Brown (1956) suggest accounts for the passage of meconium by the asphyxiated foetus *in utero*. In this way the foetus

possesses a very sensitive distress signal that can be readily appreciated by amnioscopy.

The rapidly progressive type of intrauterine disturbance is less common. In typical cases of asphyxia of this type there is initially hypoxaemia and hypercapnia, i.e. a respiratory acidosis. Later, as a consequence of anaerobic glycolysis and the accumulation of lactic acid, a metabolic acidosis is added to this. After the onset of anaerobic glycolysis, there is a fall in the production of CO₂, and the CO₂ content of the blood may fall, even though the disturbance continues. Estimation of oxygen content in these cases is also unreliable, because 'oxygen-conserving adaptation' may begin, and there is then the possibility that the blood oxygen level may return to normal.

Bearing in mind all these considerations, estimation of pH is the most reliable method of providing information on the state of the foetus.

Foetal Heart Rate as an Indication of the State of the Foetus

As a result of the large experience accumulated in the past few years from blood analysis, there is no longer any doubt that the state of the foetus *cannot* be reliably monitored simply by listening to the foetal heart sounds through a stethoscope. For instance, on many occasions, a marked acidosis has been observed when the foetal heart sounds are normal.

If we recall the events that occur with a slowly developing type of intrauterine asphyxia, it can be seen that the onset of the 'oxygen-conserving adaptation' in the foetal circulation will ensure that the oxygen supply to the cardio-regulatory centre and to the heart muscle itself remains practically normal. The cardio-regulatory centre is situated amongst the nuclei in the floor of the fourth ventricle, and is supplied by the cerebral circulation. The chemoreceptors in the carotid sinus and aortic arch, which influence the heart rate, are also in that part of the circulation where the O₂ and CO₂ composition of the blood is practically normal, as a consequence of the 'oxygen-conserving adaptation' (Fig. 3b). Therefore, auscultation of foetal heart sounds is an inadequate means of studying the state of the foetus. Experience gained with foetal blood analysis has shown that alterations in foetal heart rate occur mainly in association with the rapidly progressive type of intrauterine asphyxia, i.e. with those conditions that also cause a change in the blood gases. The heart rate is usually normal or only slightly altered with the slowly developing primary type of metabolic acidosis, though in these cases there is nearly always passage of meconium.

Indications for Foetal Blood Analysis

Foetal blood should be sampled in any patient in whom there is the slightest reason to suspect that the foetus may be in danger. This includes patients in whom there is an alteration of the foetal heart rate of any type—slowing, acceleration, or irregularity—and whenever the amniotic fluid is meconium-stained. With the passage of meconium the underlying cause is frequently a primary metabolic acidosis, particularly so if the amniotic fluid is thick, green, and like pea soup. In practice the number of babies whose blood need be sampled amounts to about 15% of all labours.

The usefulness of foetal blood analysis in the clinical management of labour is due to the fact that there is no serious threat of hypoxia to the foetus that is not accompanied by acidosis. The close correlation between acid-base changes and danger to the foetus can be seen from the elegant experimental observations of Dawes, Hibbard, and Windle (1964) on asphyxiated newborn rhesus monkeys. These workers found that by correcting the blood pH with the help of buffer infusions, they could largely prevent histologically demonstrable cerebral damage.

Treatment of the Acidotic Newborn Infant

For the past two years we have been giving buffer infusions to babies born in a state of metabolic acidosis. If, during labour, a baby is discovered to be acidotic, treatment is begun immediately it has been delivered. 12 ml. of a solution of 7% tris buffer—THAM—and 8% glucose is injected into the umbilical vein, milking the contents of the umbilical cord towards the baby. If this is not sufficient to correct the blood pH, the same solution is run in through a catheter inserted into the umbilical vein. The pH levels are followed by taking blood samples from a catheter in the umbilical artery.

In addition to the obviously important use of endotracheal oxygen, vasodilators are given with the idea of relieving the postpartum persistence of 'oxygen-conserving adaptations' in the circulation. This includes the relief of peripheral and pulmonary vasoconstriction, which is reflected by skin pallor or by oxygen-resistant cyanosis. We have used a mixture containing papaverine, atropine, and theophylline with good results.

Results

We have used both amnioscopy and foetal blood analysis routinely throughout the 24 hours, for five years. The results obtained in patients with suspected post-maturity can be seen in Table I, and in patients with toxæmia in Table II.

TABLE I
Results of Use of Amnioscopy in Management
of Suspected Post-maturity

	Without Amnioscopy 1955-1960	With Amnioscopy 1961-1964
(1) Number of deliveries	10,429	9576
(2) Cases with suspected post- maturity	763 (7%)	894 (9%)
(3) Frequency of induced labour in (2), above	276 (36%)	65 (7%)
(4) Frequency of operative interven- tions in (2), above	91 (12%)	77 (9%)
(5) Perinatal mortality in (2), above . .	19 (2.5%)	8 (1%)

In about 2500 patients examined by amnioscopy the ante-partum foetal mortality was only 0.4 per thousand. The perinatal mortality in a series of 1686 patients examined with the amnioscope was 1.2%. The perinatal loss in 1539 cases monitored by foetal blood analysis was 32 foetuses and newborns, an incidence of 2.3%. If must be remembered that this series includes babies exposed to an increased intrauterine risk, for in all of them there was a clinical indication for obtaining foetal blood. In 17 of the 32 perinatal deaths the infants were premature, and 13 of these weighed less than 2000 g. In a previous series of 1214 foetuses with the same

TABLE II
Results of Use of Amnioscopy in Management
of Maternal Toxaemia

	Without Amnioscopy 1955-1960 (423 cases)	With Amnioscopy 1961-1964 (712 cases)
Foetal deaths before onset of labour	15 (3.5%)	0 (0%)
Perinatal deaths	35 (8%)	12 (2%)

clinical signs of distress, the perinatal mortality in our Department was 8.5% (Pakzad, personal communication). The decrease in perinatal mortality from 8.5% to 2.3% is, therefore, highly significant ($p > 0.001$).

BIBLIOGRAPHY

- Beard, R. W., and Morris, E. D. (1965). Foetal and maternal acid-base balance during normal labour. *J. Obstet. Gynaec. Brit. Cwlth*, **72**, 496.
- Dawes, G. S. (1962). The umbilical circulation. *Amer. J. Obstet. Gynec.*, **84**, 1634.
- , Hibbard, E., and Windle, W. F. (1964). The effect of alkali and glucose infusion on permanent brain damage in Rhesus monkeys asphyxiated at birth. *J. Pediatr.*, **65**, 801.
- , and Mott, J. C. (1962). The vascular tone of the foetal lung. *J. Physiol. (Lond.)*, **164**, 465.
- Desmond, M. M., Lindley, J. E., Moore, J., and Brown, C. A. (1956). Meconium staining of newborn infants. *J. Pediatr.*, **49**, 540.
- Giaquinto, M., and Abelli, G. (1964). Valore diagnostico dell'amnioscopia. *Atual. Obstet. Gynec.*, **10**, 726.
- Huntingford, P. J. (1964). A direct approach to the study of the foetus. Report of a new technique from West Berlin for the early detection of intrauterine asphyxia. *Lancet*, **1**, 95.
- Imholz, G. (1965). Erste Erfahrungen mit der Amnioskopie. *Gynaecologia (Basel)*, **160**, 190.
- Saling, E. (1961a). Untersuchungen des Kindes unter der Geburt durch Blutentnahme am vorangehenden Teil. *Zbl. Gynäk.*, **83**, 1663.
- (1961b). Neue Untersuchungsmöglichkeiten des Kindes unter der Geburt (Einführung und Grundlagen). *ibid.*, **83**, 1906.
- (1962). Die Amnioskopie, ein neues Verfahren zum Erkennen von Gefahrenzuständen des Feten bei noch stehender Fruchtblase. *Geburtsh. u. Frauenheilk.*, **22**, 830.
- (1963). Die Amnioskopie, ein neues Verfahren zum Erkennen von Gefahrenzuständen des Feten bei noch stehender Fruchtblase. *Zbl. Gynäk.*, **85**, 108.
- (1966a). *Das Kind im Bereich der Geburtshilfe*. Georg Thieme, Stuttgart.
- (1966b). Neue Gesichtspunkte über den Ablauf fetaler Hypoxien. *Zbl. Gynäk.*, **88**, 76.
- Scholander, P. F. (1959). Experimental studies of asphyxia in animals. In *Oxygen Supply to the Human Foetus*, ed. J. Walker and A. C. Turnbull, p. 267. Blackwell, Oxford.
- Titler, W. (1964). Untersuchungen über die Morbidität nach Amnioskopie. Dissertation, Berlin.
- Van Liere, E. J. (1942). *Anoxia, its Effect on the Body*. University of Chicago Press, Chicago.