

Intestinal Malabsorption in Childhood

CHARLOTTE M. ANDERSON

From the Gastroenterological Research Unit, Royal Children's Hospital Research Foundation, Melbourne, Australia

In reviewing the subject of intestinal malabsorption in childhood one is faced with two major difficulties: first, the continually expanding knowledge of normal and abnormal intestinal function—malabsorption 1966 is not malabsorption 1965 or 1967; and second, defining what is meant by these two words, or at least what is the clinician's concept of 'malabsorption' on the one hand and the clinical scientist's on the other. The term is one of a number that are used by the clinician to describe a young infant whose weight gain is slow or inadequate, whose abdomen is considered protruberant, and whose stools are described by the mother as pale, frequent, and bulky. The clinical scientist wishes to be more precise in his terminology: he needs to define the substances involved; whether maldigestion or malabsorption is the error; how to demonstrate the defects; and what are the exact physiological mechanisms that are disordered.

Until about 30 years ago, clinicians could do little more than manipulate the diet empirically when a malabsorptive state was suspected; now, many individual diseases leading to intestinal malabsorption of a generalized or specific nature can be precisely defined, new ones being uncovered with dismaying frequency. The major contributions to this progress have been three. First, astute and careful clinical observations with subsequent laboratory co-operation to test the clinical hypothesis, well illustrated by the work of Dicke and his colleagues (Dicke, 1950; Dicke, Weijers, and van de Kamer, 1953) in demonstrating the relation of wheat flour to the genesis of the symptoms and signs of coeliac disease. Secondly, the introduction of more precise techniques of investigation of the gastro-intestinal tract, such as peroral intestinal biopsy, allowing both histological and metabolic examination of 'living' intestinal mucosa. Thirdly, increase in knowledge of normal enzymatic and transport mechanisms involved in the digestion and absorption of food-stuffs, made possible by the rapid advances in laboratory technology and experimentation. This is well illustrated by such work as that of Dahlqvist and Borgström (1961),

Wilson (1962), Crane (1960, 1962), and others, in regard to the enzymatic and transport mechanisms involved in carbohydrate digestion and absorption.

Recent reviews have summarized modern knowledge of the mechanisms of intestinal absorption: carbohydrate and fat (Isselbacher and Senior, 1964), amino acids (Saunders and Isselbacher, 1966), and the clinical states of malabsorption of adult life and their investigation (Jeffries, Weser, and Slesinger, 1964). Since the review by Frazer (1960), much has been written regarding malabsorptive diseases in childhood, particularly of their investigation. This review will attempt to discuss critically these advances, and to indicate how they aid the precise definition of the disease process present in the child with suspected malabsorption. Physiological and clinical classifications of malabsorptive conditions will be put forward, and the presently available techniques of investigation, their value, and indications will be discussed. Some individual diseases will be discussed with particular reference to recent work. In so doing, I shall draw heavily on the experience gained in my department from the study of a large number of children referred during the past 14 years for the further investigation of suspected intestinal malabsorption. It is not intended to give a comprehensive review of all recent publications, but rather to choose those of significance to the various facets being discussed.

Physiological Basis of Malabsorption

In general, diseases causing malabsorption are diseases of the small intestine, or diseases which affect the normal functioning of this organ (Wollaeger and Scudamore, 1964), and an understanding of the requirements for normal digestion and absorption is desirable to approach the clinical problems logically. Although the small intestine has immense reserves, certain criteria must be fulfilled for optimal function. Briefly, it should be of sufficient length and capable of undisturbed forward propulsive movement of its contents; the flow of pancreatic enzymes and bile into the duodenum must be

TABLE I

Diseases Exhibiting Steatorrhoea Classified According to Area of Small Intestinal Dysfunction

Area of Physiological Dysfunction of Small Intestine	Condition
1: <i>Abnormalities of Intestinal Mucosa</i> (A) Non-specific mucosal abnormality (B) Specific mucosal abnormality (C) Specific metabolic abnormality	Coeliac disease (wheat gluten intolerance) Chronic infections and infestations Salmonella <i>Giardia lamblia</i> Tuberculosis Hookworm (Sheehy, Meroney, Cox, and Soler, 1962) Secondary disaccharidase deficiency Protein-calorie malnutrition (Stanfield, Hutt, and Tunnicliffe, 1965) Iron-deficiency anaemia Liver cirrhosis with portal hypertension Regional ileitis Ulcerative colitis Folic acid deficiency. ? in childhood Associated with antibiotic therapy (neomycin) (Jacobson, Prior, and Falcon 1960), ? in childhood Intestinal lymphangiectasis with protein-losing enteropathy A- β -lipoproteinaemia Whipple's disease Acrodermatitis enteropathica ? Specific disaccharidase deficiencies (sucrase-isomaltase) Glucose-galactose malabsorption
2: <i>Deficient Secretions from Liver and Pancreas</i> (A) Pancreatic exocrine dysfunction (B) Liver disease	Cystic fibrosis (fibrocystic disease of the pancreas) Syndrome of pancreatic achylia, chronic neutropenia, and other bone-marrow abnormalities General malnutrition Protein-calorie malnutrition Specific lipase deficiency Other rare types of pancreatic insufficiency Biliary obstruction Neonatal hepatitis and childhood cirrhosis of liver
3: <i>Abnormal Anatomy</i>	Malrotation; universal mesentery Duplication Subacute stenosis of jejunum or ileum Intestinal scarring from intrauterine peritonitis (motor dysfunction) Blind loop following surgery Small intestinal resection
4: <i>Miscellaneous</i>	Emotional Associated with chronic non-specific chest infection Ganglioneuroma Endocrine disturbances Hyper- } parathyroidism Hypo- } A- γ -globulinaemia Renal disease—structural and metabolic Chronic constipation with or without overflow symptoms Familial dysautonomia

adequate; and the mucosal lining must be capable of the complex mechanisms of absorption of digested food products, as well as resynthesis and transportation of these substances into the blood stream and lymph vessels.

Any of these functions can be disturbed by disease processes with resulting malabsorption. In Table I diseases accompanied by generalized intestinal malabsorption are classified by relating each disease to an area of disturbed function.

Many terms, including malabsorption syndrome, coeliac syndrome, and steatorrhoea, have been used to describe the patient with failure to thrive, abdominal distension, and loose, bulky, pale stools. The term 'coeliac syndrome' has largely disappeared

since coeliac disease now designates only those patients who are intolerant of wheat gluten.

Strictly, steatorrhoea means fatty stools. The demonstration of steatorrhoea or of excessive fat excretion in the stools has long been used as an index of generalized malabsorption and is the criterion for inclusion of all conditions listed in Table I. However, some of these have as their aetiological basis a specific malabsorptive defect (e.g. deficiency of sucrase-isomaltase), one effect of which is to lead to more generalized malabsorption. Other diseases in which there is malabsorption of specific substances, e.g. of certain amino acids, vitamins, and minerals, will not be discussed unless they also do this.

General Approach to a Patient with Suspected Intestinal Malabsorption

Although we now have at our disposal greater basic knowledge, and an armamentarium of investigations from which to choose, diagnosis of the presence of intestinal malabsorption and the determination of its precise aetiology remains *par excellence* a situation where a detailed and accurate clinical history is still of primary importance. Much of the valuable experience (gained no doubt because they had little else to aid them) and the teachings of our clinical forbears is in danger of becoming clouded by the concept that newer technical investigations can produce prompt and easy answers. But investigatory procedures are costly, often only available in specialized centres, sometimes still in the stage of development with their final value not known, and occasionally not without some risk to the patient, e.g. intestinal biopsy. The clinician still remains the most readily available and least expensive investigatory tool, and with an understanding of the physiological background to malabsorption, his interrogations and observations

can go a long way towards determining whether the patient should be investigated further and if so, along which carefully selected lines.

A classification of disorders exhibiting intestinal malabsorption according to frequency of occurrence is helpful, and Table II, compiled largely from our own experience, has been designed for this purpose. It indicates the relative frequency of the conditions as they have been referred to a specialized unit, and also includes a number of rarely reported entities which we have not encountered. Illustrative references have been placed opposite the rare entities, as it is not proposed to discuss them all in detail. One cannot define the actual incidence of many of the conditions, as accurate data are not available. However, the estimates in Table II may give perspective to clinical thinking regarding an individual patient.

In a previous review of some unusual causes of steatorrhoea, Anderson, Townley, Freeman, and Johansen (1961) stated that in a community of predominantly European origin, the majority of children with persistent steatorrhoea suffered from

TABLE II
Relative Frequency of Diseases with Steatorrhoea

Disease	Estimation of Frequency
Cystic fibrosis	20-25 per year
Coeliac disease	10-15 per year
Secondary disaccharidase deficiencies	Only recognized during past 2 years—about 6 per year have presented as malabsorption syndrome; (more present as watery diarrhoea.)
<i>Giardia lamblia</i> infestation	3 per year
Associated with chronic non-specific upper and lower chest infection	Temporary malabsorption syndrome common, 3-4 per year in earlier years of study
Renal disease—structural and metabolic	About 2 per year referred as malabsorption syndrome—renal origin unsuspected
Chronic constipation with or without overflow symptoms	1-2 per year referred as malabsorption syndrome—constipation unrecognized
Pancreatic insufficiency with chronic neutropenia	11 cases now seen
Malrotation of the gut	6 cases seen
Small bowel resection and blind loop syndromes some years after surgery	5 cases seen
Emotional (maternal rejection)	4 cases seen
Malnutrition	3 cases seen
Iron-deficiency anaemia	Only 3 cases investigated (see also Naiman, Oski, Diamond, Vawter, and Schwachman, 1964)
Liver cirrhosis with portal hypertension	3 cases investigated (Astaldi and Strosselli, 1960)
Pancreatic achylia with diabetes mellitus	2 cases seen
Intestinal lymphangiectasis with protein-losing enteropathy	2 cases seen (Jarnum and Peterson, 1961)
Familial dysautonomia	2 cases seen (Burke, 1966)
Hypoparathyroidism	2 cases seen (Jackson, 1957; Williams and Wood, 1959)
Ganglioneuroma	1 cases seen (Sindhu and Anderson, 1965; Rosenstein and Engelman, 1963)
Regional ileitis	1 case seen (Shiner and Drury, 1962)
α - β -lipoproteinaemia	1 case seen (Salt <i>et al.</i> , 1960; Anderson <i>et al.</i> , 1961; Isselbacher, Scheig, Plotkin, and Caulfield, 1964)
Acrodermatitis enteropathica	1 case seen (Kelly and Anderson, 1960; Moynahan, Johnson, and McMinn, 1963)
Specific lipase deficiency	Not seen (2 cases described by Rey <i>et al.</i> , 1966; Sheldon, 1964)
Specific bile salt deficiency	Not seen (1 case described by Ross, Frazer, French, Gerrard, Sammons, and Smellie, 1955)
Whipple's disease	Not seen (1 case described by Bruni and Massimo, 1959; no biopsy; Dickinson, Hartog, and Shiner, 1960; adults)
Hyperparathyroidism	Not seen (Davies, Dent, and Willcox, 1956)
Agammaglobulinaemia	Not seen (Pelkonen <i>et al.</i> , 1963)
Neonatal hepatitis and childhood liver cirrhosis (recently recognized to have steatorrhoea)	(Burke and Danks, 1966)

Shows disorders with proven steatorrhoea referred to Gastroenterological Research Unit, Royal Children's Hospital, Melbourne, between 1952 and 1966 (14 years), in order of frequency. In many instances an estimate only of the frequency is given. Patients derived from a population of 2 to 2.5 million with about 60,000 births per year. Over 80% of the 2 major entities probably referred for investigation. References to rare disorders given.

either coeliac disease, or fibrocystic disease of the pancreas, or persistent small intestinal infection, bacterial or parasitic, and that other causes of steatorrhoea, though numerous, were individually rare. Since that time, the disorders of sugar digestion and absorption have been recognized, and these, particularly the secondary type, now form a major group. Although the predominant symptom of sugar intolerance is fluid diarrhoea, many patients show abdominal distension and steatorrhoea. This group will be the subject of a review by Dr. A. Holzel to be published in this journal.

Recently some less common entities have also been recognized, such as the syndrome of pancreatic achylia, chronic neutropenia, and other bone-marrow abnormalities.

Clinical History and Observations

The clinical patterns of the commoner diseases associated with malabsorption are now familiar. However, let us consider a few well-known, but sometimes neglected, features which should be elicited in the clinical history. One is the chronological sequence of events; for instance, what was the relation of the onset of symptoms or signs to birth (cystic fibrosis); what was the relation of these to the introduction of cereals into the diet (coeliac disease); when was cane sugar introduced (sucrase-isomaltase deficiency); was there an acute onset of diarrhoea followed by persistent subacute symptoms (secondary disaccharidase deficiency)?

The clinician's dilemma seems more often to be in deciding whether the child, who is said to have persistent or recurrent subacute diarrhoea but does not appear ill, has any organic basis for his symptoms and should be investigated further. Although some will have chronic bowel infection (*salmonella*) or parasitic infestation (*Giardia lamblia*) or belong to the sugar-intolerant group (sucrase-isomaltase deficiency or secondary lactose intolerance following unrecognized enteric infection), many have no clear aetiology revealed by simple tests. Some, on admission to hospital for investigation, as paediatricians know only too well, have no further diarrhoea, and have no steatorrhoea. When considering this problem the following points are important: is the patient really failing to thrive; is there real abdominal distension; what are the characteristics of the stools; is the child of a labile, sensitive temperament, and is there a history of similar family temperament?

Failure of normal growth is well revealed by centile charts on which weights from infant health centres or baby clinic records are graphed. For instance, Fig. 1 illustrates the typical, and, in our experience, very constant early normal progress,

then gradual decline in weight of the infant with coeliac disease (wheat gluten intolerance), and the slow weight gain from birth of the infant with cystic fibrosis. Weight gain which is continuing steadily along the normal centile lines, even in the presence of some abnormal bowel symptoms, might suggest watchful expectancy rather than active investigation.

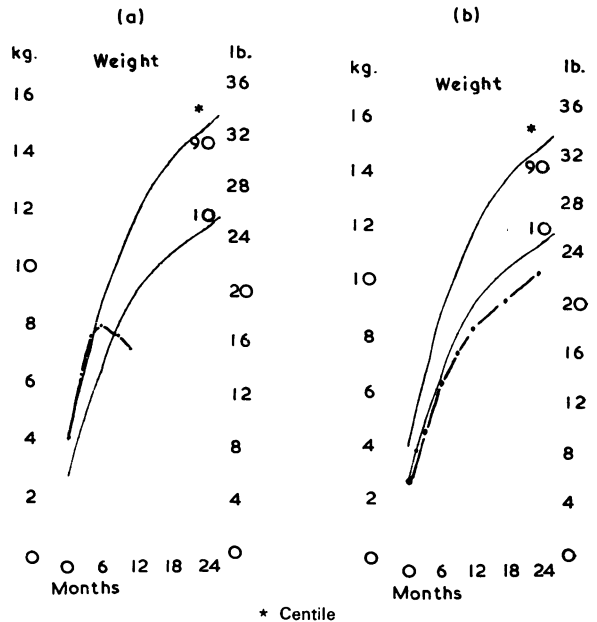


FIG. 1.—Charts illustrating typical weight graphs of (a) coeliac disease, showing early thriving with gradual growth failure, and (b) cystic fibrosis, with slow growth from birth.

Personal observation of the stools may be revealing: first, the mother's statement that they are loose and pale may not be confirmed; dark-coloured stools rarely show steatorrhoea; friable stools containing obvious vegetable matter may indicate the toddler who is generously fed with roughage; mucus should direct attention to chronic infection, large bowel pathology, or nervous factors; if the stool has a fluid content, testing with pH papers for acidity and for sugar with Clinitest tablets (Kerry and Anderson, 1964) may suggest sugar intolerance and direct further attention to the association of diarrhoea with certain dietary substances or feeding changes.

Investigations of Intestinal Malabsorption

Investigations may be grouped in two categories, (1) those indicating that malabsorption (steatorrhoea)

is present; (2) those aimed at elucidating its cause. The former includes tests devised to determine the absorption of different substances—fats, sugars, amino acids, using the results either as an index of general malabsorption or of the particular substance only. The latter are aimed chiefly at testing the integrity of individual facets of small intestinal structure or function, for example, pancreatic function, mucosal structure.

Demonstration of steatorrhoea. The absorption of fat is readily disturbed because of the complex mechanisms which the usual dietary long-chain fats must undergo in the process of emulsification, digestion, absorption, and chylomicron formation for transport into the lymph and blood stream, and unabsorbed fat contributes largely to the abnormal appearance of the stools in malabsorptive states.

The macroscopic appearance of the stool containing excess fat varies greatly, particularly the stool consistency, which may range from liquid to solid, and even constipation may be present. Paleness is probably the most constant feature. Two appearances are characteristic, the aluminium sheen of the pasty stool in coeliac disease, and the 'melted butter' oozing from the stool in pancreatic insufficiency.

Microscopical examination of the stool for fat is of limited but definite diagnostic value, this being confined to the recognition of fat globules in pancreatic deficiency states, particularly cystic fibrosis. It can be a useful consulting room procedure to indicate whether the baby with recurrent bronchitis or persistent cough should be investigated further. To be significant, fat globules should be present in large numbers and may be seen quite readily in the unstained preparation. They may be present in stools resulting from intestinal hurry in acute infections, or occasionally in cases of coeliac disease with very loose stools or associated with biliary obstruction. It is wise to make sure that the baby's feed is not free of fat at the time of the test, and that petroleum jelly is not used on a rectal thermometer or for rectal examination.

Chemical examination of stool for fat—'fat balance'. A quantitative determination of faecal fat excreted during a 3- to 8-day period still remains the most reliable measure of steatorrhoea, and individual adaptations of the rapid method for the determination of fat in faeces first introduced by van de Kamer, Huinink, and Weyers (1949) have considerably eased the laboratory work involved, provided the latter is

equipped with an adequate fume cupboard and rapid means of disposal of faecal waste. However, problems of collection of faeces for prolonged periods still appear to concern many workers, and other tests to determine fat absorption, based on short-term loading doses, have been advocated. The author has little personal experience of these but none have gained universal acceptance. They will be briefly discussed in the next section.

During a stool collection for determining faecal fat excretion the following should receive attention. The patient should be ingesting an adequate amount of his usual type of dietary fat each day, but chemical estimation of the intake is unnecessary provided calculation to within approximately 10% of accuracy is possible. The entire stool must be collected each day, and if the fat is estimated daily (readily achieved by the rapid method of van de Kamer *et al.* (1949)) considerable variation is likely, and the necessary length of each collection to give a valid result may be determined. Three days will suffice if steatorrhoea is gross and a stool passed each day; 5 days or even 8 days becomes necessary if the patient is constipated or steatorrhoea minimal.

We place the upper limit of normal faecal fat excretion at 4.5 g. per day and give a guarded interpretation of 5 g. per day. The coefficient of absorption, i.e. percentage of intake absorbed, is then 90% or over.

A normal child on a fat-free diet excretes up to 1.5 g. per day of faecal fat (personal observations), predominantly derived from endogenous sources—either desquamated mucosal cells, intestinal lymph, or from the bacterial flora of the gut. A low intake of fat during the collection period may therefore give a misleading result, particularly if the coefficient of absorption is taken as the index. In patients with malabsorption the fatty acid composition of the faeces varies with that of the diet (Webb, James, and Kellock, 1963) and the feeding of fats containing fatty acids of differing saturation or chain length may lead to differing absorption. For instance, there are now many reports indicating better absorption of medium chain length (C_8 - C_{12}) fats in various states of malabsorption (Isselbacher, 1966).

Although the patient is usually in hospital, the procedure can be carried out quite well at home, provided good printed instructions are given to a mother thought to be a reliable and careful person. In this case it is our custom to estimate a 3-day collection. Borderline results are looked at critically and the test repeated in hospital if necessary.

If the stools are soft or fluid, the patient must be nursed on a metabolic frame or have plastic squares placed under the napkins. Frames need only be of

simple design with a single hole under which a collecting receptacle is placed. The mixture of urine and faeces is not a bar to the estimation of faecal fat by the method described. Accurate collection of urine and faeces from children should be one of the skills of the modern paediatric nurse.

Estimation of fat in isolated specimens of faeces, and the interpretation of fat absorption from one 24-hour collection are mentioned only to be condemned. It is surprising how often results of these estimations are still given in reports referring patients for further investigation.

'Short-term' absorption tests. Some of these tests have been thought to measure the general absorbing capacity of the small intestine. Such a test is usually performed during a period of several hours, and involves the determination of either blood levels or urinary levels of single substances, following a loading dose. It thus introduces the capacities of other systems as well as that of the small intestine.

Short-term absorption tests of fat include the ^{131}I -labelled triolein and oleic acid test, and the lipiodol absorption test. The former test was greeted enthusiastically at first by workers in the field of adult gastro-enterology, but more recently was shown to have limitations. Gross steatorrhoea may be diagnosed, but with lower grades ambiguous results have been obtained, and even the differential indication of pancreatic insufficiency using the two substances has been placed in doubt. Jeffries *et al.* (1964) have critically summarized the published reports. The over-all results do not appear to justify the use of an isotopic tracer in children.

Lipiodol excretion test. The use of lipiodol as a test substance with measurement of the iodine appearing in the urine was suggested by Silverman and Shirkey (1955) as a simplified way of assessing intestinal fat absorption, and this test has been modified by O'Brien, Walker, and Ibbott (1959) and by Jones and di Sant'Agnes (1963). The latter authors describe it in detail and have compared their results with 4-day fat balances in controls and in patients with steatorrhoea, finding complete agreement amongst 45 children.

We have no experience with this test, but where facilities for faecal fat estimations are poor it may offer advantages. As Jones and di Sant'Agnes point out, there are a number of precautions to be taken. Kidney function must be adequate. Urine must be collected, and this is not always easy in female infants and toddlers, the latter age-group comprising as a rule the bulk of patients to be tested.

However, this test is certainly of more value than the glucose tolerance test, gelatine and amino acid curves, chylomicron counting, and vitamin A absorption test, all of which we have found to be unreliable indices of malabsorption. The glucose tolerance test is known to be influenced by factors other than intestinal absorption (Test, Nichols, Landau, Ricketts, and Loughhead, 1956). In children, oral loading tests may be unreliable, because of variation of stomach emptying time caused by the emotional reaction of the child to the taste of the dose or the trauma of the usual blood-taking involved in the tests, or by the substance itself—e.g. large single doses of fat. At best these single substances test only the absorptive capacity for that substance, often only absorption in the upper gut, and add little to the understanding of the underlying defect causing malabsorption.

Xylose excretion test. In recent years the xylose excretion test has obtained popularity with paediatricians to circumvent the necessity for stool collections (Clark, 1962; Hubble and Littlejohn, 1963). An oral dose of 5 g. xylose is given and the urine collected for 5 hours and the output of xylose measured. Values of 25% or more of the dose indicate normal absorption in the upper gut, while values below 15% indicate malabsorption. The latter workers recognize an equivocal range between these levels.

This test involves accurate collection of urine, and tests only the absorption of xylose by the upper gut; if malabsorbed, the xylose can, like all unabsorbed sugars, cause osmotic diarrhoea and intestinal hurry, thus further minimizing the value of the result.

While it is reasonable to perform one test of this variety to indicate malabsorption, the performance of multiple tests should be avoided, as they will not contribute to the solution of the primary cause of the malabsorption.

In brief, therefore, excessive faecal fat excretion demonstrates malabsorption most reliably, and the next step must be to determine its cause. Tests to elucidate the cause of malabsorption or steatorrhoea comprise the following: radiological examination of the small intestine; bacteriological studies of the content of the small intestine; peroral intestinal mucosal biopsy; determination of pancreatic exocrine function; estimation of sweat sodium and chloride; and miscellaneous tests.

Radiological Examination of Small Intestine

Some years ago Astley and French (1951) and Anderson, Astley, French, and Gerrard (1952)

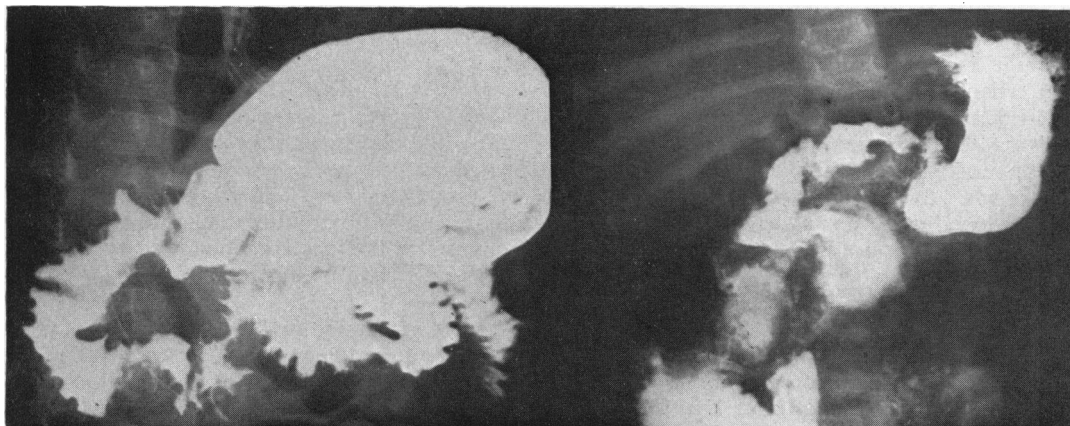


FIG. 2.—Barium radiographic studies illustrating normal C-shaped duodenum on left and S-shaped duodenum of intestinal malrotation on right.

showed that in children with coeliac disease, barium sulphate and water gave a flocculated appearance when used as an opaque medium for radiological studies of the small intestine. When an emulsified barium preparation was used, the small bowel mucosal pattern did not have a normal feathery outline but a smooth pattern with the bowel appearing dilated and barred. This seemed at first a useful confirmatory test for coeliac disease, but further experience has shown the same appearance in any state of malabsorption. Intestinal biopsy has largely rendered the use of opaque radiological examination unnecessary in true coeliac disease.

However, barium studies of the small intestine are useful in delineating anatomical abnormalities such as malrotation and should always be carried out when malabsorption cannot be readily attributed to one of the commoner disorders, particularly when the symptoms are intermittent and associated with abdominal pain and or vomiting. The duodenum in this case takes on an S-shaped appearance in distinction to the C shape of the normal fixation (Fig. 2).

Occasionally subacute ileal stenosis or regional ileitis may be demonstrated. However, barium studies of the distal small gut can be difficult to interpret, so that if clinical features are suggestive, these diagnoses should not be discarded.

Barium studies in disorders of absorption following intestinal surgery may reveal stasis, dilated loops, or blind loops, and occasionally a jejuno-colic fistula. Occasionally duodenal diverticulitis is demonstrated, and lymphangiectasis in the intestinal mucosa may show a typical appearance.

Bacteriological Studies of Contents of Small Intestine

This investigation has a place when assessing malabsorption associated with anatomical abnormalities of the gut, but only results of limited quantitative value can be obtained in children with current methods.

While examination of the faeces will reveal so-called pathogenic organisms which may be present in the small gut, it can give no idea of the 'normal' flora. Alterations in this flora have been shown to be associated with malabsorption, particularly in surgically induced abnormalities of the gut in adults (Goldstein, Wirts, and Kramer, 1961).

Anderson and Langford (1958) confirmed in children the demonstration of Cregan and Hayward (1953) that the adult human small intestine is virtually sterile, any organisms found there being so few in number that they should be regarded as transient contaminants passing through with the ingesta. They also showed that the upper small gut flora did not deviate from normal in quantity in children with coeliac disease or fibrocystic disease of the pancreas. However, in children, Bishop and Anderson (1960), and in adults, Bishop and Allcock (1960), demonstrated the existence of an abnormally profuse flora above the point of complete or incomplete small intestinal obstruction, and considered that colonization had taken place from above. After considering a number of possibilities, they suggested that the maintenance of the relatively sterile condition of the normal small intestinal contents was probably related to normal motility patterns and that any stasis might contribute towards overgrowth of

organisms. Further unpublished observations in our own unit have confirmed those of others (reviewed by Donaldson, 1964), that stasis and overgrowth of 'normal' bowel flora go together. We have encountered difficulties of this type following intestinal resection in newborn infants when the gut above an anastomosis is of greater calibre than that below, or when the anastomosis has been placed in a position which leaves the duodenum or the caecum and ascending colon as a 'blind loop'.

Shiner (1963) has devised a capsule for the purpose of obtaining uncontaminated intestinal juice for accurate bacteriological assay in adults, but this tube is not easy to use in infants. We find Levin's radio-opaque duodenal tubes convenient and take specimens rapidly after the tube is in position. If the flora is present in quantity sufficient to induce malabsorption the duodenal contents are often cloudy and may smell. Using the plating technique of Cregan and Hayward (1953), a profuse growth of coliform organisms, or occasionally monilia or *Clostridium welchii*, may be shown. Specimens are rarely obtained distal to the proximal jejunum, as experience has shown us that if there is a delay of some hours while the tube travels further, the mere presence of the tube in the gut will alter motility patterns enough to allow overgrowth of normal flora.

Taking due cognisance of these difficulties, this type of examination may be useful in relevant cases, and does allow organisms to be tested against antibiotics, and more rational bowel antisepsis instituted.

Peroral Biopsy of Small Intestinal Mucosa

A glance at Table I will indicate that in a number of pathological conditions malabsorption is related to abnormalities of the intestinal mucosa. Recognition of this has only been possible since the introduction, 10 years ago, of a technique for examining the intestinal mucosa during life, without laparotomy.

Autolysis of the intestinal mucosa takes place very rapidly after death, and the intimate structure of the intestinal villi is destroyed. Therefore, it had been considered that any abnormality seen at necropsy in patients dying of malabsorption syndromes could not be interpreted as of pathological significance. In 1954, Paulley demonstrated abnormalities in the mucosa from one patient with adult coeliac disease when a piece of small intestine was removed at laparotomy. Wood, Doig, Motteram, and Hughes (1949) and Tomenius (1950) perfected gastric suction biopsy tubes and from these the instrument of Shiner (1956a, b), and the multi-purpose biopsy tube of Brandborg, Rubin, and

Quinton (1959) were designed, independently of each other, to pass into the duodenum and upper jejunum. At about the same time, Crosby and Kugler (1957) designed a capsule using a rather different principle for suction and release of the knife blade, and since then suction biopsy tubes have been devised by many others.

These tubes were initially designed for use in adults. Sakula and Shiner (1957) were the first to demonstrate the mucosal abnormality of coeliac disease in a child by this method.

Types of 'biopsy' tube. The subject of peroral biopsy and its diagnostic usefulness has recently been reviewed by Rubin and Dobbins (1965), while other workers including Crosby (1963), Lander (1963), and Bolt (1964) have reviewed the types of biopsy tube now available and their particular applications. In this review I shall confine myself to a consideration of the use of this technique in children, with comments on suitable instruments, technical points, dangers, and diagnostic usefulness. These comments will be based largely on the experience gained in my department since 1958, when I was fortunate to obtain one of the early multi-purpose biopsy tubes. Since that time some hundreds of biopsies have been performed by us, at first with this tube, subsequently with the paediatric modification of the Crosby and Kugler capsule, described by Kauder and Bayless (1964), and during the past 2 years with a modification of this type of capsule developed in England (Read, Gough, Bones, and McCarthy, 1962).*

The multi-purpose biopsy tube consists of a plastic-sheathed long flexible coiled spring, down the centre of which passes a pull-wire with a cylindrical knife blade and capsule attached to the distal end, and a mechanism for manipulating the wire backwards and forwards and also applying suction, attached at the proximal end. When the tube is passed into the duodenum under fluoroscopic control, the hole in the capsule is opened by manipulating the pull-wire. Suction is then applied to a side arm of the upper end for a few seconds, and with the suction held, the pull-wire retracted to close the aperture or port in the capsule, thus severing the small piece of mucosa previously sucked into the port.

This tube and capsule† is of a satisfactory size for passage into the duodenum of quite small infants, and was used by us for about 5 years without complications of bleeding or perforation of the gut. The tissue obtained was ideal for histological examination but the pieces were small, and though capsules with 2 holes became available there was seldom enough tissue for newly

* Obtainable from W. Watson and Son, Barnet, Hertfordshire, England.

† Obtainable from W. E. Quinton Instrument Co., 3051 44th Avenue West, Seattle 99, Washington, U.S.A.

developed enzymatic studies as well. The manipulations of this tube in a young child are emotionally traumatic and technically difficult unless the child is under basal anaesthesia, for which we used rectal bromethol (Anderson, 1960). The procedure had then to be carried out promptly before the child woke, and required at least 3 personnel. If the tube was not successfully positioned in the duodenum within the limits of the time of fluoroscopy allowed for safety, the procedure had to be abandoned for that occasion. It was not easy to pass the end of this tube beyond the ligament of Treitz and usually tissue was obtained from the third part of the duodenum.

The 'Crosby capsule'* eliminates the pull-wire and sheathed metal spring. It was first introduced as a capsule of 9.5 mm. diameter with a port of 3 mm., suitable only for adults and older children, and was used successfully by us for the latter. The capsule contains a knife block which is activated by a spring mechanism released by suction applied to the upper end of the fine plastic tubing attached to the capsule. The suction alters the pressure on a piece of thin rubber sheet (finger cot or dental dam) placed between the 2 portions of the capsule (Fig. 3). Crosby and Kugler gradually reduced the size of the capsule and port, and the current paediatric model measures 8 mm. diameter with a port of 2 mm., and is satisfactory for passage into the small intestine of children from the very early weeks of life. The advantages of this type of tube are several; it is readily tolerated by most children, it may be passed with sedation only; it does not need more than one person to assist the operator; fluoroscopy may be used sparingly as one can be reasonably sure that the capsule has entered the duodenum when clear yellow fluid siphons up the tubing. The piece of tissue usually weighs 15-20 mg. and can be cut into portions for histological examination and enzyme studies, etc.

The capsule developed in England is similar to the paediatric version of the Crosby capsule except that the knife block and spring are in one piece (Fig. 3). This capsule is less expensive than the Crosby but in our hands has proved to have more technical troubles both in duration of effectiveness of the knife block and reliability of firing. The capsule is also apt to come apart in the intestine unless the two pieces are secured together (Fig. 3).

Both must have the plastic tube protected from puncture by teeth, and a method has been developed (Kauder and Bayless, 1964) whereby the tube is passed through a feeding bottle teat. My colleague, Dr. Burke, has used a baby's dummy for this purpose (Fig. 3). Recently Frič and Lepšik (1965) recommended the use of Ödman-Ledin red (no. 1) arterial catheter instead of other tubing. This has the advantage of being radio-opaque, more rigid, and in less need of protection from teeth bites. We now use this with success but without the guide wire they suggest. No doubt there are different biopsy tubes used by others for children but our

experience has been limited to those discussed and to occasional use of the tube of Baker and Hughes* (1960), which has recently been produced in a size suitable for children. This tube is hydraulically activated, and it is possible to obtain pieces of tissue from a number of levels in the small intestine during one biopsy procedure. The tube is less well tolerated by young children owing to its diameter, and probably has limited use, as at present it is rarely necessary that multiple areas be examined for diagnostic purposes. However, as a research tool a multiple retrieving biopsy tube has a place (Rubin and Dobbins, 1965).

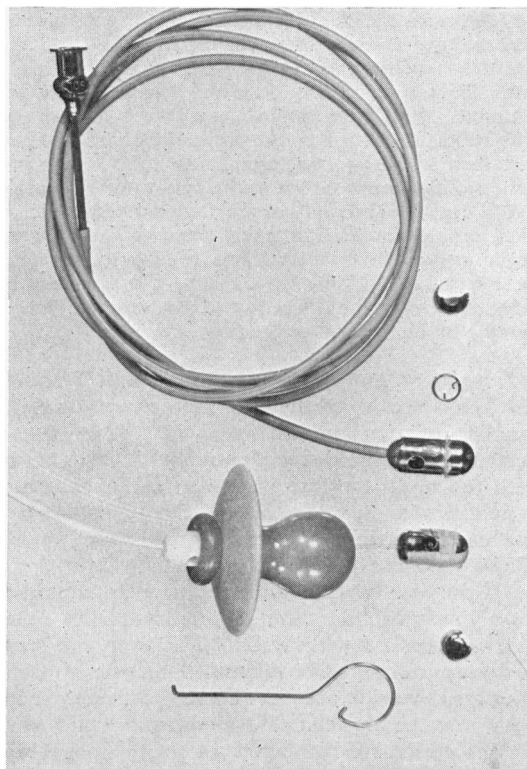


FIG. 3.—Peroral intestinal biopsy tubes. Above is paediatric Crosby capsule, with spring and knife-block illustrated separately. Ödman-Ledin red No. 1 arterial catheter attached to capsule. Below is English capsule (Read et al., 1962). Note infant's dummy to protect radio-opaque portex tubing, waterproof adhesive to secure lower dome of capsule, knife-block and spring in one piece, and hook for loading capsules.

Technique for peroral intestinal mucosal biopsy. Burman (1963) has described the technique of the biopsy procedure in detail. Hypoprothrombinaemia

* Made by College Park Instruments, P.O. Box 73, College Park, Maryland, U.S.A.

* Made by H. Taylor and Sons, 44 Macfarlane St., Sth. Yarra, Melbourne, Australia.

should be excluded before the procedure. The test is done with the patient in the fasting state, and some form of sedative is given about half an hour before. We use chloral, others use chlorpromazine derivatives which may induce amnesia for the procedure. As a small image-intensifier is readily available, it is our practice, after the capsule is swallowed, to manipulate the capsule towards the pylorus under fluoroscopy by external pressure on the abdomen and posturing. This reduces the length of the procedure, as the tube can remain in the fundus of the stomach for some time. After a short wait, with the patient on the right side, yellow fluid may begin to siphon up the tube. In this case it is likely that the capsule has passed the pylorus and this can be checked by fluoroscopy. If not, further manipulation on the abdominal wall may hasten the tube's progress. Specimens from near to the duodenal-jejunal flexure are desirable. Suction is applied by a 20 ml. syringe and with a short sharp pull on the piston the capsule is fired. It is then withdrawn by traction on the tubing, and some resistance may be felt at the pylorus or the cardia.

The capsule is opened and the piece of tissue, which is often curled in on itself, is gently extracted and arranged as flat as possible on a small square of paper or nylon mesh and fixed in 10% formal saline. It may then be examined under the dissecting microscope and subsequently by histological techniques.

Dangers in the procedure. Rubin and Dobbins (1965) have reviewed the published reports, and the number of perforations recorded. They cite a personal communication recording 3 perforations with the multi-purpose biopsy tube but have had none themselves. Vidinli and Finlay (1964) had one massive haemorrhage in a child following its use. We have obtained several hundred biopsies with the multi-purpose tube, including quite a large number from young babies, without complications of either haemorrhage or perforation. However, we have had one perforation from about 200 biopsies with the paediatric version of the Crosby capsule. This baby was an emaciated 3-month-old child with malabsorption of unsolved origin. Biopsy was attempted when all other tests had failed to explain the steatorrhoea, and a piece of very thin, 'flat' mucosa was obtained which showed a small amount of circular muscle in the section.

Perforations have been recorded much more commonly with the Crosby capsule than with the multi-purpose tube, and Rubin and Dobbins have collected published reports of 15, more than one-third being in children. Perforation and peritonitis have occurred in an 18-month-old infant, and recently Partin and Schubert (1966) report no less than 6 perforations amongst 83 biopsies. They recommend that in children the size of the port in the capsule should not be more than 2 mm. and they aim to use one of 1.5 mm.

It is obvious that our experience has been fortunate with one perforation out of some hundreds. However, we are constantly aware of this possibility and would like to make the following points. During the 8 years that intestinal biopsy has been performed in the Royal Children's Hospital, Melbourne, all the biopsies have been obtained by only 4 people. This has meant that each person has gained considerable experience in the technique. In the early years of our experience, very young and very undernourished babies were not subjected to biopsy. Now age is not a great worry to us, but the very undernourished baby is still approached with great caution. Biopsy is only carried out on such a baby if it is felt that the information obtained is likely to be diagnostic or life-saving, and those experienced in the diagnosis and management of a large variety of conditions with malabsorption will realize that it is rare that one cannot afford to wait until nutrition is better. One may have to make a presumptive diagnosis and institute treatment empirically and temporarily, but the risk of this is considerably less than that of a biopsy in such a baby. Laparotomy may even be preferred in the puzzling case.

It is our impression that the English capsule is safer than the American Crosby and we prefer to use this in young babies. The aperture in this capsule is a little smaller than in the Crosby and we believe that newer models of this tube have overcome the mechanical difficulties.

This is certainly not a technique to be embarked on lightly, rather should it be carried out by persons who are in a situation to gain experience and to continue that experience. Whatever the choice of tube, no more than adequate suction must be employed, and the aperture in the capsule must be small. Peroral suction biopsies on children should be carried out by those with experience in the handling of children, and at the risk of being thought pedantic we feel that it is preferable to have this technique available only in the larger centres or in centres where experience is more than occasional. It is perhaps better to transport the patient for a day or so rather than take risks with inexperience.

Value of intestinal biopsy and interpretation of mucosal appearances. Since its introduction 10 years ago, we have for the first time been able to obtain living human intestinal mucosa, and to study both normal structure and function as well as the pathological. Tissue may be examined under the dissecting microscope for gross surface structure, by light microscopy with conventional staining, with cytochemical staining, by electron microscopy, and

for the presence of various enzymes using whole or homogenized tissue. Specimens may be used for organ culture, uptake, and transport studies using isotopically-labelled tracers, etc. The basic information gained by some of these means, and the possibilities for the future, particularly in the study of metabolic processes, is too extensive to be discussed in this review, and I will confine my remarks to the value of biopsy as a diagnostic and research tool in elucidating the malabsorptive conditions of childhood.

Normal mucosal patterns. Those who were pioneers in the field, especially Brandborg *et al.* (1959), stressed the importance of the correct technique of histological examination so that the true normal appearance of the villi could be shown and abnormalities recognized without artefact. The tissue should be dealt with gently at all times. After removal from the capsule it is orientated with mucous surface uppermost on a small square of paper or nylon mesh and gently manipulated so that the tissue is not curled on itself. Sections should be cut serially through the biopsy in a plane parallel to the villi and perpendicular to the laminal surface, until at least some sections are obtained from the central core so as to be free of tangential artefact, a potent cause for misinterpretation of villous shape.

Most workers have developed individual methods of describing, measuring, or counting intestinal villi, and one worker's interpretation is often hard to compare with that of another. However, we are in agreement with Rubin and Dobbins (1965) when they state that perhaps the best way is to describe the morphology seen, commenting on each feature of the mucosa, such as integrity of epithelial cells, shape, size, number, and branching of villi, cellularity of lamina, etc. It is then possible to compare results with others. One person's 'partial villous atrophy' is not another's. Terms such as this were introduced early by Shiner and Doniach (1960) and have perhaps proved more useful in interpreting biopsies from adults than from children where normal villous architecture seems more variable.

The shape and size of the villi of the child's upper small intestine vary considerably depending particularly on distance away from the pylorus. Duodenal villi are wider, more blunt, and more variable in shape than upper jejunal villi (Fig. 4). The latter are finger-like and have regular lateral branching. Irregular lateral branching occurs in the duodenum, where its presence seems to be an important feature of normality. The villi nearest to the pylorus may be very short and blunt and Brunner's glands may occupy most of the glandular mucosa. Villi are

blunt over lymphoid collections, and areas such as this should be avoided when interpreting villous shape. The integrity of the epithelial cells is an important diagnostic criterion; these should be tall and slender with basal nuclei.

This normal variation between duodenum and jejunum has been referred to by Townley, Cass, and Anderson (1964) when showing the readiness with which the mucosal pattern is altered by its external environment, i.e. the intestinal contents. They suggest that duodenal mucosa is more exposed to minor degrees of 'damage' by hydrochloric acid and food fragments than is the more distal small gut.

Variations in villous shape can be recognized when the specimen is examined under low magnification as by the dissecting microscope, and this will now be considered.

Examination by dissecting microscope. Rubin, Brandborg, Phelps, and Taylor (1960) were the first to suggest examination of the unstained specimen under a low magnification, and Booth, Stewart, Holmes, and Brackenbury (1962), when summarizing their findings by dissecting microscope examination, described a number of types of villous appearance: fingers, leaves, ridges, and convolutions, and a flat pitted appearance. They considered that only fingers were normal, but the material they had examined was predominantly from the upper jejunum of adults. Our experience agrees with the recent conclusions of Rubin and Dobbins (1965) that grossly abnormal biopsies can be distinguished from normal ones, but little else. It is rare that biopsy specimens from any point distal to the ligament of Treitz are available from children, and in these leaf-shaped villi are normally more common than fingers. Under light microscopy this type of villus will appear normal. Sometimes short ridges or an occasional convolution can be seen in a normal specimen.

Again there are geographical differences in villous shape. Normal Indians very rarely show finger-like villi in the duodenum or upper jejunum (Baker, Ignatius, Mathan, Vaish, and Chacko, 1962) and light microscopy shows the lamina to be more cellular. Similar findings have been recorded in African natives (Banwell, Hutt, and Tunnicliffe, 1964). Such facts are important in interpreting biopsies from children of countries with very different economic, hygienic, and dietary patterns.

Mucosal pathology. Sakula and Shiner (1957) were the first to demonstrate mucosal pathology by peroral biopsy in a child. Having demonstrated similar appearances in the biopsies

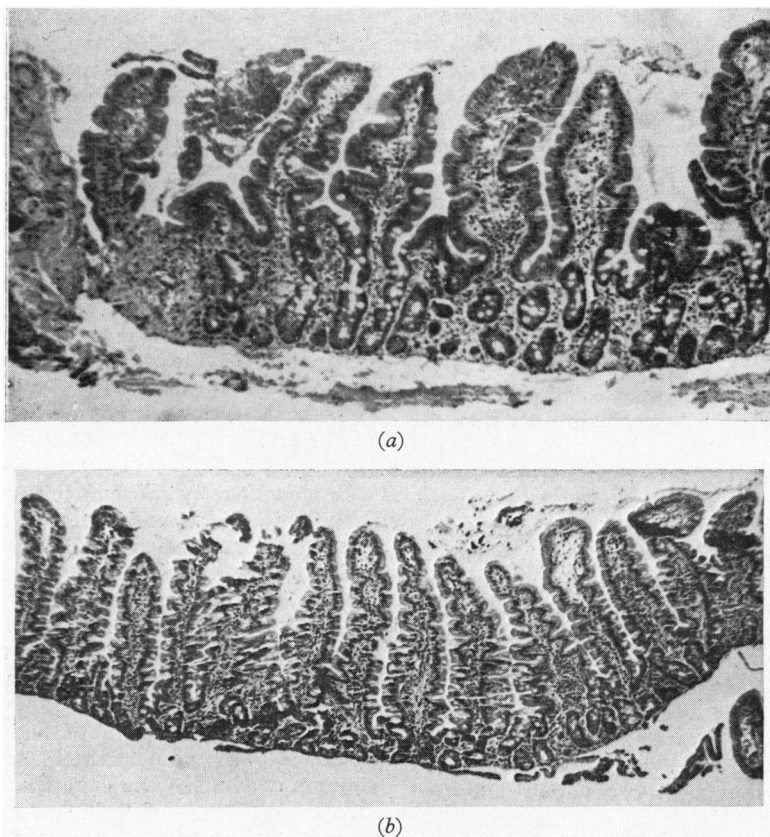


FIG. 4.—Histological appearances of peroral intestinal biopsy specimens from (a) duodenum, (b) proximal jejunum. (H. and E. $\times 50$.) Note wider villi in duodenum with irregular branching.

from adults with coeliac disease, they showed the duodenal mucosa of a boy with untreated coeliac disease to be grossly altered; the surface epithelial cells were flattened and irregular and sometimes appeared to be in layers; villi were absent giving the tissue a flat appearance, with only the crypts penetrating to the base of a rather cellular lamina propria. This appearance, of which Fig. 5a is an example, was soon amply confirmed by others, and Rubin *et al.* (1960) concluded that these specific changes were confined to adult and childhood coeliac disease with the possible exception of tropical sprue. However, time has shown that this conclusion was premature, wider use of the technique in many parts of the world indicating that the upper small intestinal mucosal pattern deviates from normal in a similar fashion in many pathological states, both in adults and in children.

Abnormal villous pattern in childhood coeliac disease was shown to revert to normal when wheat

and rye gluten were rigidly excluded from the diet, and varying grades of initial pathology (Fig. 5b) and of improvement could be seen in these children (Anderson, 1960; Cameron, Astley, Hallowell, Rawson, Miller, French, and Hubble, 1962), demonstrating that this type of mucosal change was a very labile one. The latter workers also demonstrated lesser grades of mucosal abnormality in giardia lamblia infestation (Fig. 5d) and iron deficiency anaemia (Fig. 5e). Townley *et al.* (1964) showed experimentally that repeated application of various irritating substances to the intestinal mucosa resulted in a flat appearance similar to even the most severe lesions seen in coeliac disease, and that these lesions reverted to normal when the insult ceased. They suggested that the altered morphology reflected a property of response inherent in the mucosa and was not specific to the damaging agent, and further that all grades of change between a very 'flat' mucosa and minor villous blunting could be possible,

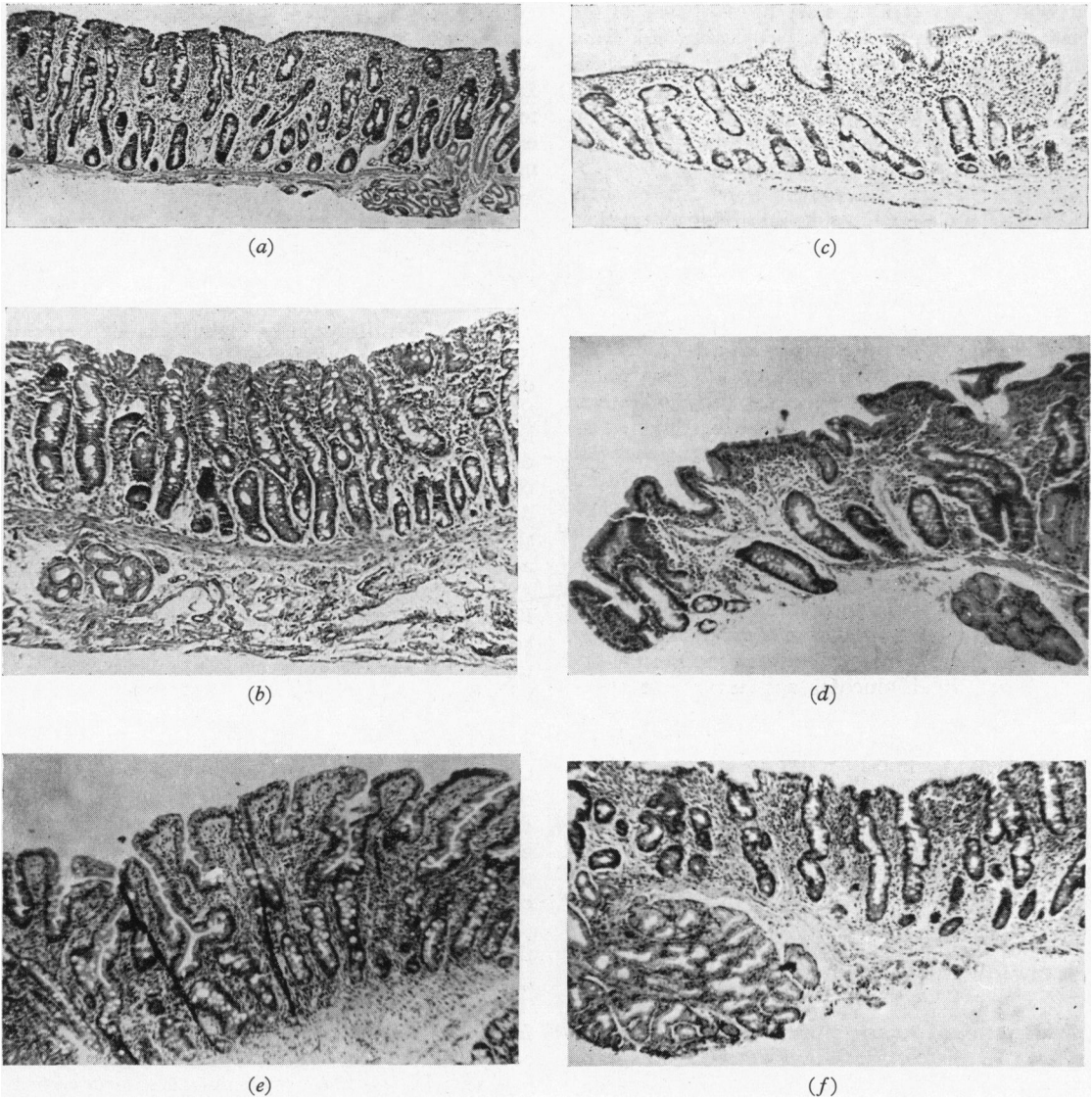


FIG. 5.—Histological appearances of duodenal mucosa in six of the Group A (Table I) conditions. (H. and E. $\times 33$.) Note over-all similarity, differences being of degree. (a) Coeliac disease, severe changes. (b) Coeliac disease, mild changes. (c) Secondary disaccharidase deficiency. (d) Heavy *Giardia lamblia* infestation. (e) Iron-deficiency anaemia. (f) Portal hypertension. ((a) and (b) from Anderson (1960); (c) from Burke et al. (1965), with acknowledgment to the publishers.)

reflecting perhaps the severity of the damaging influence, or stages in the healing process. Creamer, Shorter, and Bamforth (1961) and Creamer (1962, 1964a, b) have studied villous dynamics extensively and confirm these suggestions.

However, Townley *et al.* (1964) still considered that in clinical paediatrics, the really flat intestinal mucosal appearance was probably confined to coeliac disease, though theoretically not pathognomonic of it. Even this statement has not stood the

test of time, as can be seen by a glance at the illustrations of mucosal patterns obtained from babies with secondary disaccharidase deficiencies following non-specific bowel infections (Burke, Kerry, and Anderson, 1965) (Fig. 5c). Again further application of the biopsy technique, this time to younger babies, has been revealing.

Changes in mucosal morphology can be held responsible for alterations in intestinal absorption, by limiting surface-absorbing area, and by damaging the integrity of epithelial cells as regards both enzyme content and transport mechanisms. However, since it is only a single small piece of tissue that is examined, its morphology may not reflect the state of the mucosa of the small intestine as a whole. Clinical features are of importance, and should these fail to relate to the biopsy findings it is likely that the latter do not reflect changes over an extensive region of the gut (e.g. reduced disaccharide splitting enzymes in 'flat' coeliac biopsies but no symptoms of sugar intolerance (Anderson, Burke, Messer, and Kerry, 1966)).

To summarize, not only is experience in the technique of biopsy important but also experience in examination and interpretation of mucosal histology. There is a narrow margin between the normal and slightly abnormal mucosal appearances; there is similarity between abnormal mucosal appearances in conditions of differing aetiology, and the relation of the findings to clinical symptoms may be lacking. In our group, it has been the custom for the clinician responsible for obtaining the biopsy specimen to view the histology and to study the patient also. Only then is an interpretation of the findings given. Elsewhere it is the pathologist who gives an opinion on the tissue only. Both methods have desirable features, the latter perhaps with less bias towards reporting minor abnormalities.

Biochemical examination of biopsy specimens. In clinical paediatrics detection of specific enzyme deficiencies in relevant tissues of patients with inborn errors of metabolism is of recent development, and tissue from the small gut has already been of value. Shortly after the introduction of biopsy techniques, one of the members of my department developed a technique for the examination of peptidase activity of duodenal mucosa in coeliac and normal children (Messer, Anderson, and Townley, 1961). Subsequently a method was devised to study chromatographically the hydrolysis of disaccharides by duodenal mucosa obtained in this way, and we recognized our first patients with sucrase-isomaltase deficiency (Anderson, Messer, Townley, and Freeman, 1963). Soon after, quanti-

tative methods for estimating disaccharidases in such tissue were developed (Auricchio, Rubino, Tosi, Semenza, Landolt, Kistler, and Prader, 1963; Dahlqvist, 1964), and these methods are in wide use today. No doubt one can look forward to other enzyme deficiencies being demonstrated in intestinal mucosa, either specific to the intestinal tract or not.

Tests for Pancreatic Exocrine Function

Pancreatic exocrine function in childhood has not received the great attention devoted to it in adults, where many more pathological processes affect the pancreas. Until recently estimation of exocrine function has largely been restricted to defining the diagnosis of cystic fibrosis, and even in this disease the demonstration of raised sweat electrolyte levels has almost entirely replaced the necessity for duodenal intubation. About 95% of patients show complete absence of trypsin, lipase, and amylase in duodenal fluid obtained by intubation, the rest showing reduced levels but usually adequate for normal fat absorption.

In severe nutritional deficiencies, Véghelyi, Kemény, Pozsonyi, and Sós (1950), and in kwashiorkor (Thompson and Trowell, 1952), pancreatic function is impaired and usually returns to normal with repair of the malnutrition. Recently, with the demonstration of another pancreatic deficiency syndrome, that of pancreatic achylia with associated chronic neutropenia and other bone-marrow abnormalities, and of more specific pancreatic enzyme deficiencies, e.g. trypsinogen or lipase, there has been growing interest in more precise methods of determining altered pancreatic exocrine function in childhood.

Shwachman and Dooley (1955) have summarized the tests for exocrine function of the pancreas in childhood and have given details of methodology. They point to the difficulties of drawing conclusions from the duodenal fluid obtained by intubation and suction after an overnight fast, and emphasize that the wide range of activity reported as occurring in normal children is a reflection of varying activity of the gland, admixture of other secretions, technique of collection, time interval before analyses, and varying methods of assay.

Our technique of intubation is similar and we also use No. 10 or 12 single-lumen Levin's radio-opaque duodenal tubes. These are obtained without holes which are then cut only to within 2-4 cm. of the end of the tube, ensuring that they will not still be in the stomach when the tip has passed into the duodenum. Gentle intermittent suction on the tube is continued until about 5 ml. clear yellow fluid of pH 7 or over has been obtained. This usually takes only a few

minutes in a normal subject but may take longer in a patient with cystic fibrosis, the fluid being viscous, often cloudy yellow, and rarely of a pH above 6.8. Enzyme estimations should be carried out within half-an-hour or the fluid should be frozen. We measure pH by indicator papers and activity of amylase by the method of Free and Myers (1943), lipase by that of Nothman, Pratt, and Benotti (1948) (using olive oil as substrate), and trypsin by that of Tomarelli, Charney, and Harding (1949) (with azo albumin as substrate). Levels of amylase 2-10 units, of lipase 2-6 units, and of trypsin 10-60 units are considered normal. Like Shwachman and Dooley (1955), we introduce a few ml. olive oil down the duodenal tube as a pancreatic stimulation test, and assess enzyme levels before and after instillation. This overcomes the possibility that the resting pancreas may give a false idea of its capacity to produce enzymes.

In future, more accurate assessment of pancreatic exocrine function will be needed, with estimation of volume, pH variation, bicarbonate content, and a greater range of enzymes including chymotrypsin, trypsinogen, and carboxypeptidase, before and after secretion and pancreozymin stimulation. Examination of bile acids would be of interest. Such methods are being developed.

Indirect Tests for Pancreatic Function

Microscopical examination of the stool for fat globules has been discussed under estimation of faecal fat. Undigested meat fibres and starch may also be seen, but the latter may be of no significance in toddlers having a high vegetable diet or in young babies in whom pancreatic amylase is normally very low until almost 9-12 months of age.

Tests such as the lipiodol excretion test and gelatin and amino acid curves, have been dealt with under 'short-term' tests for absorption in a previous section. They are of little value in defining pancreatic exocrine function.

Estimation of sodium and chloride in sweat.

Since the demonstration of raised sodium and chloride concentrations in the sweat of patients with cystic fibrosis by Darling, di Sant'Agnesse, Perera, and Andersen (1953) the estimation of these electrolytes has proved the most reliable single test for the detection of this disease and has replaced the assessment of pancreatic function except in a few atypical cases.

Many techniques of sweat collection have been described, but discussion will be limited to the methods most frequently used. Early methods used heat as the stimulus to induce sweating, but this can

be dangerous and such methods have no real place. Then followed methods of sweat stimulation by chemical means, mecholyl or pilocarpine. We collect sweat on a weighed piece of gauze (washed salt free), from a patch on the forearm following the intradermal injection of mecholyl (Anderson and Freeman, 1958). However, a satisfactory method based on the iontophoresis of pilocarpine to induce sweating was introduced by Gibson and Cooke in 1959, and is now the most widely used 'sweat test'. Technical details are available in the *Guide to Diagnosis and Management of Cystic Fibrosis* (1963) of the National Cystic Fibrosis Research Foundation.

Methods designed to make the test quicker are currently being devised by many workers. Rapidity is a desirable feature now that the test is widely applied to young infants with refractory respiratory infection. However, accuracy is also necessary as this is the final confirmatory test for a disease which carries a very serious prognosis. Goldbloom and Sekelj (1963) have developed a method utilizing the application of a sodium electrode to the skin. Warwick and Hansen (1965) briefly record a similar technique and claim that reliable results can be obtained from infants 3 days old—difficult with other methods. de Haller, de Haller, and Siegenthaler (1965) have devised a capillary method for collection of sweat following iontophoresis. As yet we have no experience of these new tests.

Levels of sweat sodium and/or chloride above 60 mEq/litre have been accepted as abnormal in children in our laboratory. Untreated adrenal insufficiency is the only other condition which may give levels above this. Other laboratories accept 50 mEq/litre as the upper normal, and this choice may depend upon the method in use. Our 'mecholyl' method records levels slightly higher than the iontophoresis method and certainly higher than heat sweat. We regard levels between 50 and 60 mEq/litre for either sodium or chloride critically, and repeat the test if there are suggestive clinical features or fat globules in the stools. For infants under 6 months of age we accept 50 mEq/litre as the upper normal level.

The 'sweat test' is not difficult but requires experience in micro-laboratory techniques. It is wise to check the result, especially if positive, with the clinical features shown by the patients and with the examination of the stools for fat globules. Should a positive test be obtained and the stools be normal, then the test should be repeated, unless the other features are very characteristic. In such cases duodenal intubation may be indicated, as a small number of patients with cystic fibrosis have in-

complete pancreatic achylia with normal stools. A positive diagnosis of cystic fibrosis carries a very serious prognosis, likewise a missed diagnosis might defer early treatment. It is therefore wise for laboratory and clinician to confer, and further investigation to be carried out if there is doubt one way or the other.

There is now reasonable agreement that normal sweat sodium and chloride levels may be higher after puberty, and the 'sweat test' becomes less satisfactory for use in adults (Anderson and Freeman, 1960; McKendrick, 1962; Lobeck and Huebner, 1962). The test cannot identify individual heterozygotes, though there may be a slight tendency toward higher levels in these persons if the statistical means of large groups of normals and heterozygotes are compared.

Miscellaneous investigations. A glance at the list of disorders exhibiting malabsorptions in Table I will indicate that there are a number of common investigations which should be routinely carried out and some less common investigations that may be necessary if the aetiology of the malabsorption is not clear. For instance, microscopical examination of the stools for ova and cysts should be a necessary investigation. The clinical picture of *Giardia lamblia* infestation may mimic mild coeliac disease (Cortner, 1959; Court and Anderson, 1959), and patients with coeliac disease may have associated *Giardia lamblia* infestation. Culture of the stool is important also to exclude chronic bacterial, particularly salmonella, infection as a cause of persistent subacute diarrhoea with mild steatorrhoea.

Mantoux test is of lesser value now that abdominal tuberculosis is rare in countries with high living standards but still of value in less affluent regions. A haematological examination may reveal the iron deficiency anaemia so commonly a feature of coeliac disease, or the occasional macrocytic anaemia of this disease in childhood, the latter being much more common in adults. Abnormally-shaped red cells known as acanthocytes may be seen in the condition known as α - β -lipoproteinaemia (Salt, Wolff, Lloyd, Fosbrooke, Cameron, and Hubble, 1960). Serum cholesterol, total lipid, and chylomicron counts are low and lipoprotein electrophoresis reveals absent or very low β -lipoprotein levels in this disease. Serum folic acid and B12 assay and the Schilling test may be useful at times, particularly in studying the results of intestinal resection and in assessing necessary treatment. Liver function tests may confirm suspected liver disease. The estimation of urinary catecholamine metabolites should be performed if the diarrhoeal symptoms are difficult to explain

(Sindhu and Anderson, 1965). Serum levels of Ca, P, and Mg may be useful in assessing the treatment necessary for secondary effects of the malabsorption, and may be revealing if disorders of parathyroid function are present. Serum proteins may reveal hypoproteinaemia in any long-standing malabsorption, but if oedema is also present it may indicate that more sophisticated studies for protein-losing enteropathy should be carried out. Specific hypo- or α - γ -globulinaemia may be found (Pelkonen, Siurala, and Vuopio, 1963).

Chronic renal disorders in young children, particularly those involving congenital abnormalities of the collecting systems, with infection, may present with the triad of symptoms, failure to thrive, abdominal distension, and pale stools. Sometimes the stools are pale but the child constipated. Urine examination and blood urea are tests that should be performed in any case of malabsorption that does not have a very ready explanation, and intravenous pyelogram may be necessary.

Occasionally a barium enema is helpful as both chronic constipation, Hirschsprung's disease, or megacolon may present as a 'malabsorption syndrome'.

Finally, an emotional cause, such as maternal deprivation or rejection may need to be considered, and if the explanation of the malabsorption is not readily apparent, a detailed clinical history should be taken with this in mind. However, it should be remembered that the coeliac child may show depressive difficult behaviour of an extreme degree which disappears completely after removal of wheat gluten from the diet.

Malabsorptive Diseases

Recent information and experience concerning some disorders in each area of disturbed physiology indicated in Table I will now be discussed. Coeliac disease (wheat gluten intolerance) and cystic fibrosis (fibrocystic disease of the pancreas) will not be completely reviewed. Table II includes references to the rare conditions which will receive little further comment.

This review is based primarily on disorders of intestinal absorption seen in countries of higher economic development and with populations of predominantly European origin, but the frequency of certain conditions will differ greatly in other countries. For instance, problems of malabsorption associated with protein-calorie malnutrition, and chronic intestinal infection with associated secondary sugar intolerance will probably be the commonest entities in underdeveloped countries, while true coeliac disease seems rare and possibly

genetically absent amongst African and South Asian races. Cystic fibrosis, though recognized in Japan (Ikai, Sugie, Sugino, Nitta, Iida, Ogawa, and Suchi, 1965), may not occur in other Asian countries and is rarely recorded in the negro race.

Abnormalities of Intestinal Mucosa

In this group, two disorders comprise the bulk of the clinical problems encountered in countries of higher economic development—coeliac disease and secondary sugar intolerances. The symptoms and signs of both are secondary to impairment of absorption by disease of the intestinal epithelium but are caused by different agents. In coeliac disease the agent is wheat or rye gluten or some digestive intermediary of that protein; in sugar intolerance the agents are varied, and it seems likely that damage to intestinal epithelial cells from any cause (infective, mechanical, metabolic) if involving sufficient length of small gut, may lead to impairment of either their disaccharide hydrolysing properties or the transport mechanisms for monosaccharides. Thus amongst the disorders listed in Table I there is considerable overlap in symptomatology, secondary disaccharide intolerance being possible in coeliac disease, chronic infections, protein-calorie malnutrition, ulcerative colitis, regional ileitis, α - β -lipoproteinaemia, and certain anatomical abnormalities, particularly those created surgically.

There is now good evidence from intestinal biopsy of alterations to mucosal structure in a number of conditions, in addition to coeliac disease. The abnormalities already recognized may be classified, as in Table I, into 3 groups: (A) non-specific mucosal abnormality; (B) specific mucosal abnormality; and (C) proven and probable metabolic abnormalities.

Fig. 5 (a-f) shows examples of group A from our own experience, indicating the similarity of the over-all changes in the various conditions (coeliac disease, severe and mild; secondary disaccharidase deficiency; *Giardia lamblia* infestation; iron-deficiency anaemia; liver cirrhosis with portal hypertension), differences being of degree rather than of specificity. There is general alteration of the villous architecture in all, with degrees of flattening of the mucosal surface; alteration of epithelial cells so that they have lost their tall columnar appearance, to become cuboidal, flat, or layered; and a variable infiltrate of the lamina with plasma, eosinophilic or polymorphonuclear cells.

Fig. 6 shows examples of the specific abnormalities (group B) that have been seen in α - β -lipoproteinaemia, and intestinal lymphangiectasis. In group C

the conditions listed show normal villous architecture.

Coeliac Disease

The clinical description by Gee (1888) of the child with coeliac disease has not been improved but only clarified by the increasing knowledge of the aetiology of the symptoms of this disorder. Gee was aware that this disorder affected only a few people; that the symptoms had an insidious onset and progression after babyhood, and were related to alteration of the absorptive capacity of the small intestine, ameliorated in later childhood, and often became subclinical.

Modern knowledge now explains the time of onset—i.e. after wheat cereals are introduced into the diet (Dicke, 1950; Dicke *et al.*, 1953); and the damage to the absorbing capacity of the small intestine in terms of mucosal abnormality (Sakula and Shiner (1957) and others). Gee did not refer to the familial incidence now clearly documented by biopsy (MacDonald, Dobbins, and Rubin, 1965).

In summary, this is an uncommon familial condition with specific intolerance of ingested wheat and rye cereal protein, the latter causing alteration to the small intestinal mucosa and thus impairing absorption. Both symptoms and mucosal abnormalities disappear when wheat and rye cereals are avoided, and reappear if they are ingested again (Anderson, 1960; Cameron *et al.*, 1962). The disease, therefore, appears to fulfil many of the criteria for an inborn error of metabolism, but the nature of this has not been defined.

'Gluten toxicity.' The mechanism of the harmful action of wheat and rye gluten or gliadin (a protein fraction of gluten) remains uncertain but two hypotheses receive most attention. The evidence for each was discussed fully by Frazer (1960) and he called them the 'toxic' and 'allergic' hypotheses. The 'toxic' considers the disorder an inborn error with deficiency of a specific peptidase in the gut, leading to incomplete digestion of gluten, with accumulation of an intermediate digestive product that is toxic to small intestinal epithelium. The 'allergic' hypothesis considers that the disease has its basis in an immunological response of the gut to the wheat and rye protein. The present weight of evidence lies with the 'toxic' hypothesis but proof is lacking. The complexity of the chemical structure of the gluten polypeptide and the difficulty of long-term feeding experiments or repeated biopsies in children renders progress slow, and it may yet be some time before this matter is solved. Messer, Anderson, and Hubbard (1964) favour the missing peptide and suggest from their work that

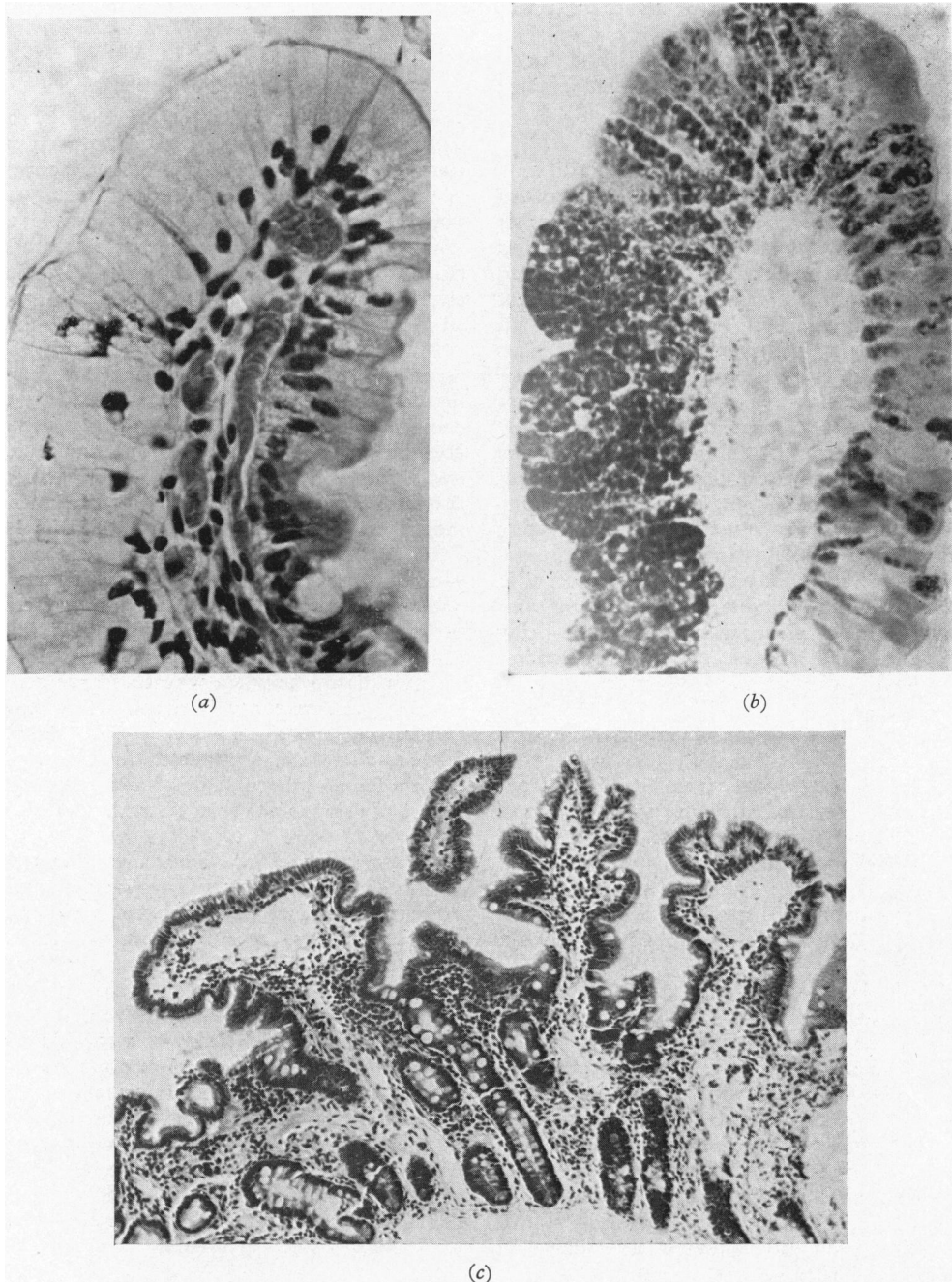


FIG. 6.—Specific mucosal abnormalities (Group B, Table I). Histological appearances of peroral duodenal mucosal biopsy specimens. (a) Villus from patient with α - β -lipoproteinaemia (H. and E. \times 900), showing empty dilated epithelial cells; and (b) stained for fat with osmic acid showing epithelial cells filled with triglyceride (condition thought to be block in chylomicron formation). (c) Mucosa of intestinal lymphangiectasis (H. and E. \times 250), showing dilated lacteals. (Boy 2½ years with oedema and hypoproteinaemia since birth.)

this has an amino acid sequence with glutamine in an N terminal position. Bronstein, Haeffner, and Kowlessar (1965) suggest, in an abstract only, that an acidic peptide plays a major role, and Biserte and Han (1965) that these patients have an inability to form pyrrolidone compounds (but their chemical methodology can be criticized).

On the other hand, supporters of the 'allergic' hypothesis point to the high frequency of antibodies to gliadin in coeliac patients, though agreeing that this can be a non-specific finding (Heiner, Lahey, Wilson, Gerrard, Shwachman, and Khaw, 1962). Recently Rubin, Fauci, Sleichner, and Jeffries (1965), using immunofluorescent techniques, suggest that the epithelial cells of coeliac patients bind gliadin, this being an inherent property, but they are unable to explain its significance.

Genetic factors. The recent survey (MacDonald *et al.*, 1965) by intestinal biopsy of 96 relatives of 17 probands with coeliac disease showed the characteristic mucosal lesion in 11 relatives including sibs and parents of 6 of the probands. Five of these 11 were initially asymptomatic. Our own material confirms this, not by such a survey, but by proving the existence of the disease in sibs with symptoms of 7 probands (Fig. 7) and in parents of 3 other probands (Fig. 8a and b). The symptoms of some of the sibs have been very mild, such as in the boy of 11, who was well grown, had no bowel symptoms, but had a mild macrocytic anaemia discovered during blood testing for an intercurrent infection. Steatorrhoea and mucosal pathology were both present on investigation. Of the 3 parents, 2 mothers and 1 father, 1 was very anaemic after pregnancy and placed herself on the diet following diagnosis of her older daughter, 2 had had symptoms and treatment in early childhood and none since, but agreed to investigation.

Carter, Sheldon, and Walker (1959) studied relatives of clinic patients, only taking as positive any clinical story that had been proven elsewhere by faecal fat studies. They estimated the incidence of the disease in England at about 1 in 3000 from these data. No biopsies were performed at that time and therefore subclinical cases could be missed, indicating perhaps a higher incidence. The pattern of inheritance and incidence of this disease will probably not be clear until an easier and more definitive test than biopsy is available.

Diagnosis. In most cases the diagnosis is strongly suspected from the clinical history, and investigations confirm malabsorption and mucosal abnormality, and exclude other conditions. The

insidious onset of symptoms after introduction of cereals; the fair-haired miserable negative depressed child with abdominal distension, muscle wasting, and hypotonia; the pale stools often soft but occasionally constipated; the occasional large effortless vomits; the retrogression in standing and walking; the presence of iron-deficiency anaemia; the absence of pathogenic bacteria, ova, or cysts from the stool; the demonstration of steatorrhoea by faecal fat estimations; the characteristic histological abnormalities of the duodenal mucosa obtained by peroral biopsy; the gradual response, well under way in a few weeks, to a wheat and rye gluten-free diet; the maintenance of perfect health and growth while on a strict diet; but the relapse, sometimes slow and insidious, when the diet is relaxed—this summarizes the story of the child with coeliac disease.

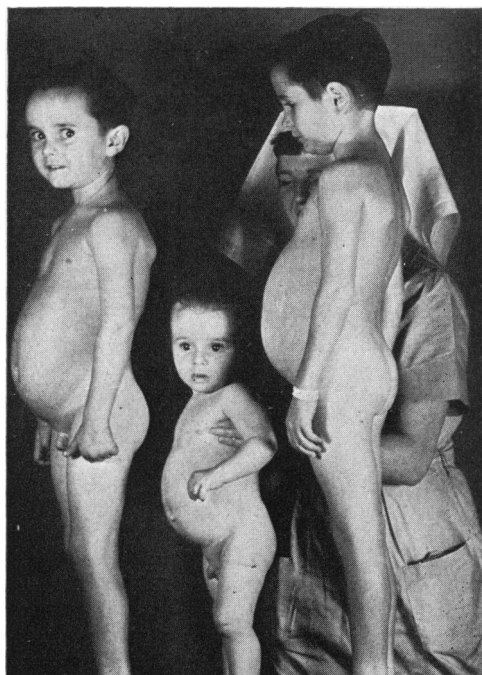

FIG. 7.—Three brothers with coeliac disease, all presenting at the same time. Ages, from left to right, 4½ years, 10 months, 6 years.

Differential diagnosis is rarely from cystic fibrosis which now presents most commonly in early babyhood with the characteristic chest illness. However, in those who escape early chest infection and present with the malabsorptive picture, such features as large appetite, lack of misery, oily stools with fat globules on microscopical examination,

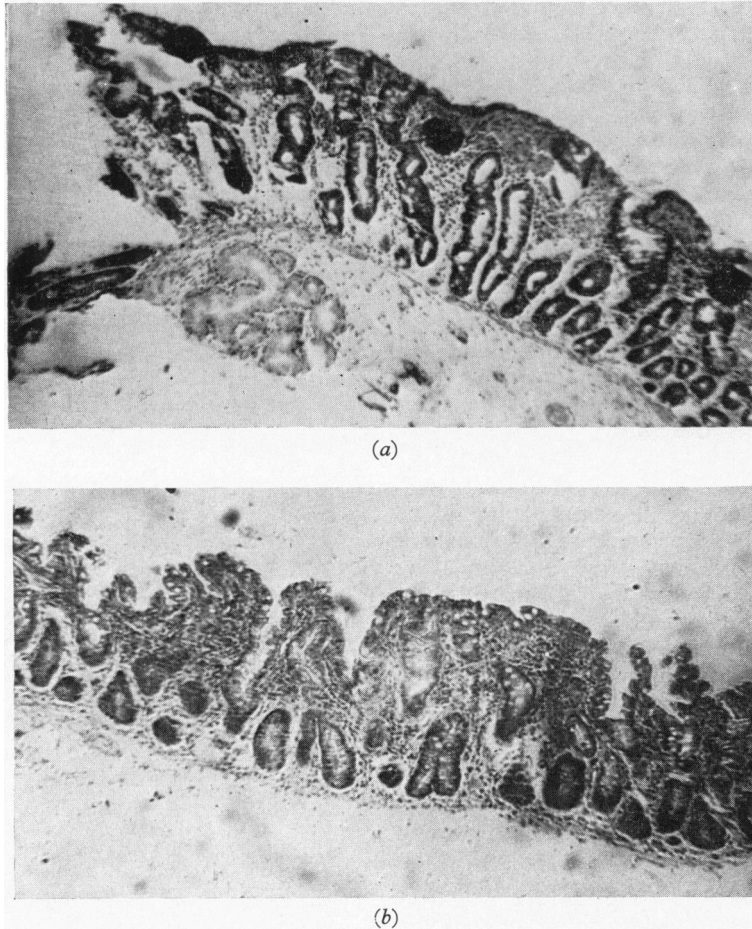


FIG. 8.—Histological appearance (*H. and E.* $\times 50.$) of peroral duodenal biopsies from (a) child with coeliac disease, (b) mother of child (on gluten-free diet about 1 month before biopsy taken).

emphysematous shape of chest, mild finger clubbing, lead one to a sweat test rather than a fat balance and intestinal biopsy. The latter shows normal villous architecture but is not a desirable investigation in patients with cystic fibrosis.

Probably the most difficult differential diagnosis is from secondary disaccharidase intolerance following non-specific or specific enteric infections, and in retrospect we know we have made errors before this latter condition was defined. Fig. 5 (a and c) illustrates the similarity in mucosal biopsy appearances. In our experience it is the young baby (3-6 months of age) who most commonly shows this type of disaccharidase deficiency (Burke *et al.*, 1965), and if the symptoms continue for some weeks or months the clinical picture presented may closely resemble

coeliac disease, with abdominal distension, wasting, and steatorrhoea. As the practice of introducing cereal food in earlier months of life is spreading, one can expect coeliac disease to present earlier, and cause confusion with this condition. The problem may not be solved even by disaccharidase estimations in a biopsy specimen, since in coeliac disease this may also show generalized and marked reduction of all disaccharidases but especially of lactase. Stools from both may be fluid, acid, and show sugar to Clinitest, but in our experience symptoms from the disaccharidase deficiency are uncommon in coeliac disease (Anderson *et al.*, 1966), probably because the distal gut in this disease may not be affected (Rubin, Brandborg, Flick, Phelps, Parmentier, and Van Niel, 1962). If the situation cannot be resolved, a

trial of a lactose-free milk will give immediate improvement in the stools, with negative Clinitest, if secondary disaccharide intolerance is the only disease present, and weight will be gained, despite continuance of gluten.

Treatment. Wheat and rye gluten-free diets are now very familiar and even baby food manufacturers recognize their existence in a satisfactory manner. We exclude barley but have not found it necessary rigidly to exclude oats—others do. The evidence for the toxicity of these two cereals is hard to document but Dicke *et al.* (1953) early suggested they should be excluded.

It is often several weeks before response to the diet becomes clinically evident, but cessation of misery and return of appetite are the earliest features, possibly indicating a more generalized effect of gluten. Only in very sick children and in those with large fluid losses from the bowel have we found it necessary to restrict fat intake greatly or have recourse to a lactose-free diet (Anderson *et al.*, 1966). Occasionally steroids have been helpful in cutting short the rare 'coeliac crisis'.

Duration of the diet is the commonest query. That this disease is the same as adult idiopathic steatorrhoea is now clear; that relapse after stopping the diet can be very slow and insidious is well recognized (Hubble, 1963); that untreated cases without symptoms exist is also clear (MacDonald *et al.*, 1965). What, as Hubble (1963) debates, should one advise the healthy, treated teenage patient? We advise strict diet till growth is complete; then the patient should be taught to understand his own disease, to take care with his diet, and to keep under some sort of periodic supervision, particularly for haematological abnormalities. However, it is likely that the teenage patient will do just what he or she wants in this regard.

Pancreatic Exocrine Dysfunction

Cystic fibrosis. In economically developed countries the most frequent manifestation of pancreatic insufficiency in childhood occurs in the disease known as cystic fibrosis, and as Table II indicates, this condition is the commonest single malabsorptive state amongst our material. It is now recognized as the commonest inherited congenital disease of childhood in those of European origin, the mode of inheritance being Mendelian recessive. Recent estimates of incidence include that derived from our own population in the state of Victoria, Australia, where the minimum incidence was found to be 1 in 2448 live births and the frequency of

heterozygotes therefore at least 1 in 25 live births (Danks, Allan, and Anderson, 1965), and that of Honeyman and Siker (1965) in the U.S.A. with a minimum incidence of 1 in 1863.

The complex pattern of pathology is considered to arise from the viscid property of mucous secretions throughout the body, and the salty sweat. The basic defect underlying these abnormalities is not yet clear, but may have its origin in the poorly understood mechanisms of transport of electrolytes across or into cells responsible for regulating the electrolyte and water content of exocrine and mucous secreting tissue. Excellent recent reviews of the disease and its treatment (*Guide to Diagnosis and Management of Cystic Fibrosis*, 1963; *Symposium on Cystic Fibrosis*, 1964) are available and can be purchased inexpensively for teaching purposes.

Diagnosis. As has been stated, diagnosis is now more commonly made in early infancy because of the characteristic pattern of chest infection. This is evident from Table III, illustrating the clinical presentations of our own cases during the past 8 years. In summary, the diagnosis now rests on

TABLE III
Mode of Presentation in 142 Patients with Cystic Fibrosis

Mode of Presentation	No. of Patients
Predominantly chest	100 (43 diagnosed under 12 months)
Abnormal stools	15 (10 diagnosed over 3 years)
Failure to thrive	
Sib of known case	15 { 9 newborns* 6 older
Meconium ileus	7
Rectal prolapse	3
Heat exhaustion	2
Total	142

* Newborn sibs tested by sweat test because they were from known families.

demonstrating raised levels of sweat sodium and chloride in a child with chronic or recurrent obstructive staphylococcal lung infection, poor growth, fat globules in the stools (90-95% of patients), and often a sib suffering from the same disease. It seems probable that all patients with this disease have raised levels of Na and Cl in the sweat. However, not all patients show complete pancreatic insufficiency, a few have enough pancreatic exocrine secretion to ensure normal fat absorption and normal stools. Amongst our patients, 8 of 142 patients seen in the past 8 years are of this type. This may cause difficulty in diagnosis, but the characteristic chest illness with *Staphylococcus aureus* present in

the sputum or cough plate, or a family history, will indicate the necessity for a 'sweat test'. Duodenal intubation reveals reduced levels of trypsin and lipase in a viscid juice in this group.

Treatment has improved the prognosis of this disease considerably (McIntosh, 1965), though patients surviving to older ages run the risks of added complications such as cirrhosis of the liver, diabetes mellitus, pulmonary osteoarthropathy, and subacute intestinal obstruction from muco-faecal masses. Shwachman, Kulczycki, and Khaw (1965) have recently reviewed 65 patients over 17 years of age and ascribe the more favourable outcome to 4 causes: a clearer understanding of the pathogenesis of the disease; more accurate means of diagnosis; greater efficacy of treatment of the superimposed bacterial lung infection; and last but not least the appreciation of the existence of mild or asymptomatic cases. It is clear that many patients will now reach adult life and pass into the care of physicians caring for adults who should now become aware of the ramifications of this disease.

Syndrome of pancreatic insufficiency, chronic neutropenia, and other bone-marrow abnormalities. Paediatricians now recognize that some children with pancreatic insufficiency do not have chronic chest infection and raised electrolyte levels in the sweat. Recently, Bodian, Sheldon, and Lightwood (1964) described congenital hypoplasia of the exocrine pancreas in 2 such children, and reviewed the papers concerning other cases, with a similar clinical pattern. Variable neutropenia occurred in both their cases, but did not receive special comment. In 1964, Shwachman, Diamond, Oski, and Khaw reported 5 similar patients, drawing particular attention to the association of haematological and pancreatic abnormalities. Together with our haematological colleagues we were stimulated by this report to review patients known to us with either pancreatic insufficiency without the other characteristics of cystic fibrosis, or with chronic or cyclical neutropenia (Colebatch, Anderson, Simons, and Burke, 1965). Of 16 patients investigated adequately and known to have one of these features, 11 have been shown to have both. We believe this to be the commonest cause of pancreatic insufficiency in childhood after excluding cystic fibrosis, and, like Shwachman *et al.* (1964), find a familial incidence. Likewise we found a tendency for steatorrhoea to diminish with time in these patients, though pancreatic insufficiency can still be demonstrated. The association of these two features may readily be overlooked, particularly in older patients, because symptoms of malabsorption may be minimal and

neutropenia variable. White cell counts may have to be performed regularly for several weeks to detect the latter. Metaphysial dysostosis and Hirschsprung's disease were present in some of our patients, and this suggests that the syndrome is more complex.

Other conditions with specific pancreatic disturbances have recently been described. Townes (1965) has found a condition of specific trypsinogen deficiency; Sheldon (1964), and Rey, Frezal, Royer, and Lamy (1966) have described patients with specific lipase deficiency.

Disorders of Biliary Secretion

Bile salts and pancreatic secretion are both necessary for normal absorption of long chain fats in humans. That steatorrhoea follows biliary obstruction is well recognized, the commonest cause in infancy being biliary atresia. That the fat content of the pale stools of patients with neonatal hepatitis without biliary obstruction, and of patients with cirrhosis of the liver, is consistently raised is of recent recognition. Burke and Danks (1966) describe a group of patients with neonatal hepatitis or cirrhosis, all with faecal fat levels in excess of normal—many in the region of 10-12 g. per day. The cause of steatorrhoea is not clear. Intestinal biopsies have shown normal villous architecture. Further work is planned to investigate the excretion of bile acids by the liver in these conditions and their relation to lipid metabolism (Dawson and Isselbacher, 1960).

Babies with neonatal hepatitis fail to gain weight well, a fact customarily equated with the infection. However, Burke and Danks (1966) find that on feeding a milk containing medium chain triglycerides*, steatorrhoea disappeared and weight gain occurred. This diet was particularly effective in a 12-year-old girl with chronic hepatitis who was jaundiced and whose growth had been stationary for 2 years. Growth rate has increased to normal, energy has returned, and jaundice has disappeared. This work is progressing, but the feeding of medium chain fats seems worthy of consideration in patients with liver disease.

Abnormal Anatomy

Malrotation of the gut. Children with malrotation of the gut may present with the clinical picture of malabsorption. In addition to the steatorrhoea there may be episodic exacerbations of the diarrhoea with abdominal pain, vomiting,

* Supplied for clinical trial by Mead Johnson Company, Evansville, Indiana, U.S.A.

increased distension of the abdomen, and severe dehydration. The attack may abate in a few days but the stools remain pale and loose. An x-ray film of the abdomen during an attack may show fluid levels, and barium studies may show a hold-up in the duodenal region, an S-shaped duodenum (Fig. 2), or a high wandering caecum. Anderson *et al.* (1961) described such a case in which repeated barium studies were necessary to reveal the wandering caecum.

Operative treatment is necessary for correct delineation of the anatomy and to relieve the chronic volvulus that may be present. It is customary to cut the adhesive bands which usually pass between the duodenum and the posterior surface of the liver and posterior abdominal wall, and to complete Ladd's procedure, placing the caecum in the left iliac fossa. This usually relieves the acute attacks but the patient referred to above has continued to have persistent malabsorption with minor attacks, though her growth has not been disturbed. It seems likely that some permanent small intestinal insufficiency remains, possibly due to vascular damage during intermittent volvulus. She has not been investigated by intestinal biopsy.

We have recently recorded the clinical details of a 14-month-old girl, presenting with hypoproteinaemia, generalized oedema, steatorrhoea, hypocalcaemia, and hypoprothrombinaemia (Burke and Anderson, 1966). Malrotation of the gut was diagnosed by barium studies, and intubation revealed a profuse growth of 'normal' bowel flora in the duodenum. At laparotomy, chronic volvulus causing obstruction of the mesenteric lymphatics and veins was demonstrated. Protein-losing enteropathy associated with lymphatic obstruction was considered the most likely cause of the clinical features, but the stasis and bacterial overgrowth may also have contributed to malabsorption. Although other measures were employed as well, there was evidence that a milk containing medium chain triglycerides (MCT) instead of long chain fats was of considerable help before operation, both ameliorating protein loss from the gut and improving fat absorption.

Small intestinal resection. Considerable lengths, even up to 50% of the small intestine, may be surgically removed without permanent malabsorption. However, the result will depend on the underlying condition leading to the resection, the presence of any disordered motility or stasis proximal to the anastomotic site, or to a blind loop left *in situ*.

Long-term survival is possible following very

extensive resection: a girl with 6 inches (15 cm.) remaining has already survived for 9 years (Anderson, 1965), despite early post-operative difficulties. These difficulties may now be mitigated by attention to stool losses of potassium and magnesium, recognition of the symptoms associated with sugar intolerance, and by making use of the differential absorption of medium chain fatty acids (Fernandes, van de Kamer, and Weijers, 1962), and thereby replacing much of the long chain fat in the diet with a feeding containing medium chain triglycerides.

Zurier, Campbell, Hashim, and Van Itallie (1966) report beneficial effects of feeding MCT to adult patients following gut resection. My colleague, Dr. Burke, has recently treated a newborn infant who had all but 6 inches (15 cm.) of jejunum removed, this being anastomosed to the transverse colon. Severe fluid diarrhoea occurred when feedings were first instituted, and it was apparent, by testing these stools for sugar, that the baby could not even tolerate monosaccharides. A feeding containing protein, fat, and electrolytes was made, and sugar was gradually reintroduced as it was tolerated, beginning with glucose. When disaccharides were tolerated without excess fluid losses in the stool, the MCT milk which contained lactose was fed. The baby has thrived and now at the age of 7 months is almost its normal weight and has one or two formed stools per day. When MCT milk becomes commercially available it should be of value in patients of this type, particularly in the earlier stages of post-operative management.

It is well recognized by paediatric surgeons that many newborn babies suffer from fluid diarrhoea and malabsorption for varying periods after operative procedures to obtain continuity of gut, after an area of atretic gut has been removed. Preliminary work in our department indicates that sugar intolerance may be responsible for some of the fluid losses. A blind loop-type syndrome with stasis and an overgrowth of flora in the bowel above the anastomosis, despite absence of any real obstruction, has occurred in some of these infants. Usually symptoms can be controlled by manipulating the sugar content of the feed, giving oral antibiotics such as neomycin and nystatin after testing the antibiotic sensitivities of the organisms obtained by intubation, and later altering the fat in the diet to MCT. The general condition can then be maintained fairly well until normal motor function of the gut around the anastomosed area returns.

So ends malabsorption in childhood 1966. Many problems of diagnosis and treatment have been solved, and many remain. Delineation of the

underlying defect of cystic fibrosis would be an important advance. Understanding of the role of sugar in malabsorptive states, and the differential absorption of various chain length fats have been the most recent advances to have important implications for treatment.

First, I must thank the physicians and surgeons of the Royal Children's Hospital, Melbourne, for referring the many patients with malabsorption; secondly, the medical and scientific staff of my unit who have contributed so much to the clinical care and basic investigation of these patients—Drs. R. R. W. Townley, J. M. Court, V. Burke, I. McIntyre, Miss M. Freeman, Drs. M. Messer, and P. Johansen, and Mr. K. Kerry and the technical assistants, Mrs. R. Kay, Miss L. Hubbard, Miss D. Boden, and Miss A. Carroll. The nursing staff have devoted themselves to many years of metabolic collections. Miss M. Barry has given help in preparing this review.

REFERENCES

- Anderson, C. M. (1960). Histological changes in the duodenal mucosa in coeliac disease: reversibility during treatment with a wheat gluten free diet. *Arch. Dis. Childh.*, **35**, 419.
- (1965). Long-term survival with six inches of small intestine. *Brit. med. J.*, **1**, 419.
- , Astley, R., French, J. M., and Gerrard, J. W. (1952). The small intestine pattern in coeliac disease. *Brit. J. Radiol.*, **25**, 526.
- , Burke, V., Messer, M., and Kerry, K. R. (1966). Sugar intolerance and coeliac disease. *Lancet*, **1**, 1322.
- , and Freeman, M. (1958). A simple method of sweat collection with analysis of electrolytes in patients with fibrocystic disease of the pancreas and their families. *Med. J. Aust.*, **1**, 419.
- , and — (1960). 'Sweat test' results in normal persons of different ages compared with families with fibrocystic disease of the pancreas. *Arch. Dis. Childh.*, **35**, 581.
- , and Langford, R. F. (1958). Bacterial content of small intestine in health, in coeliac disease, and in fibrocystic disease of pancreas. *Brit. med. J.*, **1**, 803.
- , Messer, M., Townley, R. R. W., and Freeman, M. (1963). Intestinal sucrose and isomaltase deficiency in two siblings. *Pediatrics*, **31**, 1003.
- , Townley, R. R. W., Freeman, M., and Johansen, P. (1961). Unusual causes of steatorrhoea in infancy and childhood. *Med. J. Aust.*, **2**, 617.
- Astaldi, G., and Strosselli, E. (1960). Peroral biopsy of the intestinal mucosa in hepatic cirrhosis. *Amer. J. dig. Dis.*, **5**, 603.
- Astley, R., and French, J. M. (1951). The small intestine pattern in normal children and in coeliac disease. Its relationship to the nature of the opaque medium. *Brit. J. Radiol.*, **24**, 321.
- Auricchio, S., Rubino, A., Tosi, R., Semenza, G., Landolt, M., Kistler, H., and Prader, A. (1963). Disaccharidase activities in human intestinal mucosa. *Enzymol. Biol. Clin. (Basel)*, **3**, 193.
- Baker, S. J., and Hughes, A. (1960). Multiple-retrieving small-intestinal biopsy tube. *Lancet*, **2**, 686.
- , Ignatius, M., Mathan, V. I., Vaish, S. K., and Chacko, C. C. (1962). Intestinal biopsy in tropical sprue. In *Intestinal Biopsy (Ciba Foundation Study Group, No. 14)*, ed. G. E. W. Wolstenholme and M. P. Cameron, p. 84. Churchill, London.
- Banwell, J. G., Hutt, M. S. R., and Tunnicliffe, R. (1964). Observations on jejunal biopsy in Ugandan Africans. *E. Afr. med. J.*, **41**, 46.
- Biserte, G., and Han, K. (1965). Peptides résiduels de l'hydrolyse enzymatique de la gliadine du blé. *Bull. Soc. Chim. biol. (Paris)*, **47**, 597.
- Bishop, R. F., and Allcock, E. A. (1960). Bacterial flora of the small intestine in acute intestinal obstruction. *Brit. med. J.*, **1**, 766.
- , and Anderson, C. M. (1960). The bacterial flora of the stomach and small intestine in children with intestinal obstruction. *Arch. Dis. Childh.*, **35**, 487.
- Bodian, M., Sheldon, W., and Lightwood, R. (1964). Congenital hypoplasia of the exocrine pancreas. *Acta paediat. (Uppsala)*, **53**, 282.
- Bolt, R. J. (1964). Methods of small-bowel biopsy. *J. Amer. med. Ass.*, **188**, 40.
- Booth, C. C., Stewart, J. S., Holmes, R., and Brackenbury, W. (1962). Dissecting microscope appearances of intestinal mucosa. In *Intestinal Biopsy (Ciba Foundation Study Group No. 14)*, ed. G. E. W. Wolstenholme and M. P. Cameron, p. 2. Churchill, London.
- Brandborg, L. L., Rubin, C. E., and Quinton, W. E. (1959). A multipurpose instrument for suction biopsy of the esophagus, stomach, small bowel, and colon. *Gastroenterology*, **37**, 1.
- Bronstein, H. D., Haeffner, L. J., and Kowlessar, O. D. (1965). The nature of the toxic peptides of gliadin and their effects in coeliac disease. *Clin. Res.*, **13**, 251.
- Bruni, R., and Massimo, L. (1959). Descrizione di un rarissimo caso di malattia di Whipple nell'età pediatrica. *Minerva pediat.*, **11**, 935.
- Burke, V. (1966). Familial dysautonomia. *Aust. paediat. J.*, **2**, 58.
- , and Anderson, C. M. (1966). Chronic volvulus as a cause of hypoproteinaemia, oedema and tetany. *ibid.*, **2**, 114.
- , and Danks, D. M. (1966). Medium-chain triglyceride diet: its use in treatment of liver disease. *Brit. med. J.*, **2**, 1050.
- , Kerry, K. R., and Anderson, C. M. (1965). The relationship of dietary lactose to refractory diarrhoea in infancy. *Aust. paediat. J.*, **1**, 147.
- Burman, D. (1963). Coeliac disease. I. Diagnosis by jejunal biopsy. *Clin. Pediat. (Philad.)*, **2**, 581.
- Cameron, A. H., Astley, R., Hallowell, M., Rawson, A. B., Miller, C. G., French, J. M., and Hubble, D. V. (1962). Duodeno-jejunal biopsy in the investigation of children with coeliac disease. *Quart. J. Med.*, **31**, 125.
- Carter, C., Sheldon, W., and Walker, C. (1959). The inheritance of coeliac disease. *Ann. hum. Genet.*, **23**, 266.
- Clark, P. A. (1962). The use of the d-xylose excretion test in children. *Gut*, **3**, 333.
- Colebatch, J. H., Anderson, C. M., Simons, M. J., and Burke, V. (1965). Neutropenia and pancreatic disorder. *Lancet*, **2**, 496.
- Cortner, J. A. (1959). Giardiasis, a cause of coeliac syndrome. *Amer. J. Dis. Child.*, **98**, 311.
- Court, J. M., and Anderson, C. M. (1959). The pathogenesis of Giardia lamblia in children. *Med. J. Aust.*, **2**, 436.
- Crane, R. K. (1960). Intestinal absorption of sugars. *Physiol. Rev.*, **40**, 789.
- (1962). Hypothesis for mechanism of intestinal active transport of sugars. *Fed. Proc.*, **21**, 891.
- Creamer, B. (1962). Dynamics of the mucosa of the small intestine in idiopathic steatorrhoea. *Gut*, **3**, 295.
- (1964a). Variations in small-intestinal villous shape and mucosal dynamics. *Brit. med. J.*, **2**, 1371.
- (1964b). Small intestinal mucosal dynamics and the environment. *ibid.*, **2**, 1373.
- , Shorter, R. G., and Bamforth, J. (1961). The turnover and shedding of epithelial cells. Part I. The turnover in the gastro-intestinal tract. *Gut*, **2**, 110.
- Cregan, J., and Hayward, N. J. (1953). The bacterial content of the healthy human small intestine. *Brit. med. J.*, **1**, 1356.
- Crosby, W. H. (1963). Small intestinal studies: methods for obtaining intraluminal contents and intestinal mucosa. A review. *Amer. J. dig. Dis.*, **8**, 2.
- , and Kugler, H. W. (1957). Intraluminal biopsy of the small intestine; the intestinal biopsy capsule. *ibid.*, **2**, 236.
- Dahlqvist, A. (1964). Method for assay of intestinal disaccharidases. *Analyt. Biochem.*, **7**, 18.
- , and Borgström, B. (1961). Digestion and absorption of disaccharides in man. *Biochem. J.*, **81**, 411.
- Danks, D. M., Allan, J., and Anderson, C. M. (1965). A genetic study of fibrocystic disease of the pancreas. *Ann. hum. Genet.*, **28**, 323.
- Darling, R. C., di Sant'Agnes, P. A., Perera, G. A., and Andersen, D. H. (1953). Electrolyte abnormalities of the sweat in fibrocystic disease of the pancreas. *Amer. J. med. Sci.*, **255**, 67.
- Davies, D. R., Dent, C. E., and Willcox, A. (1956). Hyperparathyroidism and steatorrhoea. *Brit. med. J.*, **2**, 1133.

- Dawson, A. M., and Isselbacher, K. J. (1960). Studies on lipid metabolism in the small intestine with observations on the role of bile salts. *J. clin. Invest.*, **39**, 730.
- Dicke, W. K. (1950). *Coeliakie. Een Onderzoek naar de Nadelige Invloed van Sommige Graansoorten op de Lijder aan Coeliakie*. Thesis, Utrecht.
- , Weijers, H. A., and Kamer, J. H. van de (1953). Coeliac disease: presence in wheat of factor having deleterious effect in cases of coeliac disease. *Acta paediat. (Uppsala)*, **42**, 34.
- Dickinson, C. J., Hartog, M., and Shiner, M. (1960). A report of two cases of Whipple's disease diagnosed by peroral small intestinal biopsy. *Gut*, **1**, 163.
- Donaldson, R. M., Jr. (1964). Normal bacterial populations of the intestine and their relation to intestinal function. *New Engl. J. Med.*, **270**, 938, 994, 1050.
- Fernandes, J., Kamer, J. H. van de, and Weijers, H. A. (1962). Differences in absorption of the various fatty acids studied in children with steatorrhea. *J. clin. Invest.*, **41**, 488.
- Frazer, A. C. (1960). The present state of knowledge on the coeliac syndrome. *J. Pediat.*, **57**, 262.
- Free, A. H., and Myers, V. C. (1943). The estimations of the enzymes, amylase, proteinase, and lipase in duodenal contents. *J. Lab. clin. Med.*, **28**, 1387.
- Frčić, P., and Lepšik, J. (1965). Use of Ödman-Ledin catheter and Seldinger wire with Crosby capsule. *Gut*, **6**, 101.
- Gee, S. (1888). On the coeliac affection. *St Bart. Hosp. Rep.*, **24**, 17.
- Gibson, L. E., and Cooke, R. E. (1959). A test for concentration of electrolytes in sweat in cystic fibrosis of the pancreas utilizing pilocarpine by iontophoresis. *Pediatrics*, **23**, 545.
- Goldbloom, R. B., and Sekel, P. (1963). Cystic fibrosis of the pancreas. Diagnosis by application of a sodium electrode to the skin. *New Engl. J. Med.*, **269**, 1349.
- Goldstein, F., Wirts, C. W., and Kramer, S. (1961). The relationship of afferent limb stasis and bacterial flora to the production of postgastroctomy steatorrhea. *Gastroenterology*, **40**, 47.
- Guide to Diagnosis and Management of Cystic Fibrosis: a Syllabus for Physicians* (1963). National Cystic Fibrosis Research Foundation, New York.
- de Haller, R., de Haller, J., and Siegenthaler, P. (1965). Accuracy of the sweat test: advantage of a micromethod. *Arch. Dis. Childh.*, **40**, 684.
- Heiner, D. C., Lahey, M. E., Wilson, J. F., Gerrard, J. W., Shwachman, H., and Khaw, K. T. (1962). Precipitins to antigens of wheat and cow's milk in coeliac disease. *J. Pediat.*, **61**, 813.
- Honeyman, M. S., and Siker, E. (1965). Cystic fibrosis of the pancreas: an estimate of the incidence. *Amer. J. hum. Genet.*, **17**, 461.
- Hubble, D. (1963). Diagnosis and management of coeliac disease in childhood. *Brit. med. J.*, **2**, 701.
- , and Littlejohn, S. (1963). The d-xylose excretion test in coeliac disease in childhood. *Arch. Dis. Childh.*, **38**, 476.
- Ikai, K., Sugie, I., Sugino, I., Nitta, H., Iida, T., Ogawa, J., and Suchi, T. (1965). Cystic fibrosis cases found by re-examination of histology of pancreas and postmortem protocol in Japanese children and sweat test on the siblings. *Acta paediat. jap.*, **7**(13), 23.
- Isselbacher, K. J. (1966). Biochemical aspects of fat absorption. *Gastroenterology*, **50**, 78.
- , Scheig, R., Plotkin, G. R., and Caulfield, J. B. (1964). Congenital β -lipoprotein deficiency: an hereditary disorder involving a defect in the absorption and transport of lipids. *Medicine (Baltimore)*, **43**, 347.
- , and Senior, J. R. (1964). The intestinal absorption of carbohydrate and fat. *Gastroenterology*, **46**, 287.
- Jackson, W. P. U. (1957). Steatorrhea and hypoparathyroidism. *Lancet*, **1**, 1086.
- Jacobson, E. D., Prior, J. T., and Falcon, W. W. (1960). Malabsorptive syndrome induced by neomycin: morphologic alterations in the jejunal mucosa. *J. Lab. clin. Med.*, **56**, 245.
- Jarnum, S., and Peterson, V. P. (1961). Protein-losing enteropathy. *Lancet*, **1**, 417.
- Jeffries, G. H., Weser, E., and Slesinger, M. H. (1964). Malabsorption. *Gastroenterology*, **46**, 434.
- Jones, W. O., and di Sant'Agnes, P. A. (1963). Laboratory aids in the diagnosis of malabsorption in pediatrics. *J. Pediat.*, **62**, 44.
- Kamer, J. H. van de, Huinink, H. ten Bokkel, and Weyers, H. A. (1949). Rapid method for the determination of fat in feces. *J. biol. Chem.*, **177**, 347.
- Kauder, E., and Bayless, T. M. (1964). Peroral intestinal biopsy in children: a technique. *Amer. J. Dis. Child.*, **107**, 582.
- Kelly, R., and Anderson, C. M. (1960). A case of acrodermatitis enteropathica. *Aust. J. Derm.*, **5**, 219.
- Kerry, K. R., and Anderson, C. M. (1964). A ward test for sugar in faeces. *Lancet*, **1**, 981.
- Lander, H. (1963). Instruments used for gastro-intestinal biopsy. *Aust. Ann. Med.*, **12**, 238.
- Lobeck, C. C., and Huebner, D. (1962). Effect of age, sex, and cystic fibrosis on the sodium and potassium content of human sweat. *Pediatrics*, **30**, 172.
- MacDonald, W. C., Dobbins, W. O., III, and Rubin, C. E. (1965). Studies of the familial nature of coeliac sprue using biopsy of the small intestine. *New Engl. J. Med.*, **272**, 448.
- McIntosh, R. (1965). Progress in cystic fibrosis. Commentary. *Pediatrics*, **36**, 673.
- McKendrick, T. (1962). Sweat sodium levels in normal subjects, in fibrocystic patients and their relatives, and in chronic bronchitic patients. *Lancet*, **1**, 183.
- Messer, M., Anderson, C. M., and Hubbard, L. (1964). Studies on the mechanism of destruction of the toxic action of wheat gluten in coeliac disease by crude papain. *Gut*, **5**, 295.
- , —, and Townley, R. R. W. (1961). Peptidase activity of biopsies of the duodenal mucosa of children with and without coeliac disease. *Clin. chim. Acta*, **6**, 768.
- Moynahan, E. J., Johnson, F. R., and McMinn, R. M. H. (1963). Acrodermatitis enteropathica: demonstration of possible intestinal enzyme defect. *Proc. roy. Soc. Med.*, **56**, 300.
- Naiman, J. L., Oski, F. A., Diamond, L. K., Vawter, G. F., and Shwachman, H. (1964). The gastrointestinal effects of iron-deficiency anemia. *Pediatrics*, **33**, 83.
- Nothman, M. M., Pratt, T. D., and Benotti, J. (1948). The effect of ligation of the pancreatic ducts and of pancreatotomy after duct ligation on serum lipase. *J. Lab. clin. Med.*, **33**, 833.
- O'Brien, D., Walker, D. M., and Ibbott, F. A. (1959). Specificity of the iodized oil test for fat absorption. *Pediatrics*, **23**, 422.
- Partin, J. C., and Schubert, W. K. (1966). Precautionary note on the use of the intestinal biopsy capsule in infants and emaciated children. *New Engl. J. Med.*, **274**, 94.
- Paulley, J. W. (1954). Observations on the aetiology of idiopathic steatorrhea: jejunal and lymph-node biopsies. *Brit. med. J.*, **2**, 1318.
- Pelkonen, R., Siurala, M., and Vuopio, P. (1963). Inherited agammaglobulinemia with malabsorption and marked alterations in the gastrointestinal mucosa. *Acta med. scand.*, **173**, 549.
- Read, A. E., Gough, K. R., Bones, J. A., and McCarthy, C. F. (1962). An improvement to the Crosby peroral intestinal biopsy capsule. *Lancet*, **1**, 894.
- Rey, J., Frezal, J., Royer, P., and Lamy, M. (1966). L'absence congénitale de lipase pancréatique. *Arch. franc. Pédiat.*, **23**, 5.
- Rosenstein, B. J., and Engelman, K. (1963). Diarrhea in a child with a catecholamine-secreting ganglioneuroma. *J. Pediat.*, **63**, 217.
- Ross, C. A. C., Frazer, A. C., French, J. M., Gerrard, J. W., Sammons, H. G., and Smellie, J. M. (1955). Coeliac disease: The relative importance of wheat gluten. *Lancet*, **1**, 1087.
- Rubin, C. E., Brandborg, L. L., Flick, A. L., Phelps, P., Parmentier, C., and Van Niel, S. (1962). Studies of coeliac sprue. III. The effect of repeated wheat instillation into the proximal ileum of patients on a gluten free diet. *Gastroenterology*, **43**, 621.
- , —, Phelps, P. C., and Taylor, H. C., Jr. (1960). Studies of coeliac disease. I. The apparent identical and specific nature of the duodenal and proximal jejunal lesion in coeliac disease and idiopathic sprue. *ibid.*, **38**, 28.
- , and Dobbins, W. O., III. (1965). Peroral biopsy of the small intestine. A review of its diagnostic usefulness. *ibid.*, **49**, 676.
- Rubin, W., Fauci, A. S., Slesinger, M. H., and Jeffries, G. H. (1965). Immunofluorescent studies in adult coeliac disease. *J. clin. Invest.*, **44**, 475.
- Sakula, J., and Shiner, M. (1957). Coeliac disease with atrophy of the small-intestine mucosa. *Lancet*, **2**, 876.
- Salt, H. B., Wolff, O. H., Lloyd, J. K., Fosbrooke, A. S., Cameron, A. H., and Hubble, D. V. (1960). On having no beta-lipoprotein: A syndrome comprising a-beta-lipoproteinaemia, acanthocytosis, and steatorrhea. *ibid.*, **2**, 325.

- Saunders, S. J., and Isselbacher, K. J. (1966). Intestinal absorption of amino acids. *Gastroenterology*, **50**, 586.
- Sheehy, T. W., Meroney, W. H., Cox, R. S., Jr., and Soler, J. E. (1962). Hookworm disease and malabsorption. *ibid.*, **42**, 148.
- Sheldon, W. (1964). Congenital pancreatic lipase deficiency. *Arch. Dis. Childh.*, **39**, 268.
- Shiner, M. (1956a). Duodenal biopsy. *Lancet*, **1**, 17.
- (1956b). Jejunal-biopsy tube. *ibid.*, **1**, 85.
- (1963). A capsule for obtaining sterile samples of gastrointestinal fluids. *ibid.*, **1**, 532.
- , and Doniach, I. (1960). Histopathologic studies in steatorrhea. *Gastroenterology*, **38**, 419.
- , and Drury, R. A. B. (1962). Abnormalities of the small intestinal mucosa in Crohn's disease (regional enteritis). *Amer. J. dig. Dis.*, **7**, 744.
- Shwachman, H., Diamond, L. K., Oski, F. A., and Khaw, K. T. (1964). The syndrome of pancreatic insufficiency and bone marrow dysfunction. *J. Pediat.*, **65**, 645.
- , and Dooley, R. R. (1955). Tests of exocrine functions of the pancreas in childhood. *Pediat. Clin. N. Amer.*, **2**, 201.
- , Kulczycki, L. L., and Khaw, K. T. (1965). Studies in cystic fibrosis. A report on sixty-five patients over 17 years of age. *Pediatrics*, **36**, 689.
- Silverman, F. N., and Shirkey, H. C. (1955). A fat absorption test using iodized oil, with particular application as a screening test in the diagnosis of fibrocystic disease of the pancreas. *ibid.*, **15**, 143.
- Sindhu, S., and Anderson, C. M. (1965). Ganglioneuroma as a cause of diarrhoea and failure to thrive. *Aust. paediat. J.*, **1**, 56.
- Stanfield, J. P., Hutt, M. S. R., and Tunnicliffe, R. (1965). Intestinal biopsy in kwashiorkor. *Lancet*, **2**, 519.
- Symposium on Cystic Fibrosis* (1964). The Chest and Heart Association, London.
- Test, C. E., Nichols, R. L., Landau, R. L., Ricketts, H. T., and Loughhead, R. (1956). A study of the 'flat' oral glucose tolerance curve and its relation to rate of emptying of the stomach. *Amer. J. med. Sci.*, **231**, 69.
- Thompson, M. D., and Trowell, H. C. (1952). Pancreatic enzyme activity in duodenal contents of children with a type o kwashiorkor. *Lancet*, **1**, 1031.
- Tomarelli, R. M., Charney, J., and Harding, M. L. (1949). The use of azoalbumin as a substrate in the colorimetric determination of peptic and tryptic activity. *J. Lab. clin. Med.*, **34**, 428.
- Tomenius, J. (1950). An instrument for gastrobiopsies. *Gastroenterology*, **15**, 498.
- Townes, P. L. (1965). Trypsinogen deficiency disease. *J. Pediat.*, **66**, 275.
- Townley, R. R. W., Cass, M. H., and Anderson, C. M. (1964). Small intestinal mucosal patterns of coeliac disease and idiopathic steatorrhea seen in other situations. *Gut*, **5**, 51.
- Véghelyi, P. V., Kemény, T. T., Pozsonyi, J., and Sós, J. (1950). Dietary lesions of the pancreas. *Amer. J. Dis. Child.*, **79**, 658.
- Vidinli, M., and Finlay, J. M. (1964). Massive hemorrhage following small bowel biopsy. *Canad. med. Ass. J.*, **91**, 1223.
- Warwick, W. J., and Hansen, L. (1965). The silver electrode method for rapid analysis of sweat chloride. *Pediatrics*, **36**, 261.
- Webb, J. P. W., James, A. T., and Kellock, T. D. (1963). The influence of diet on the quality of faecal fat in patients with and without steatorrhea. *Gut*, **4**, 37.
- Williams, E., and Wood, C. (1959). The syndrome of hypoparathyroidism and steatorrhea. *Arch. Dis. Childh.*, **34**, 302.
- Wilson, T. H. (1962). *Intestinal Absorption*. W. B. Saunders, Philadelphia.
- Wollaeger, E. E., and Scudamore, H. H. (1964). Spectrum of diseases causing steatorrhea. *Arch. intern. Med.*, **113**, 819.
- Wood, I. J., Doig, R. K., Motteram, R., and Hughes, A. (1949). Gastric biopsy; report on fifty-five biopsies using a new flexible gastric biopsy tube. *Lancet*, **1**, 18.
- Zurier, R. B., Campbell, R. G., Hashim, S. A., and Van Itallie, T. B. (1966). Use of medium-chain triglyceride in management of patients with massive resection of the small intestine. *New Engl. J. Med.*, **274**, 490.