

Congenital Heart Block and Widespread Fibrosis Due to Maternal Lupus Erythematosus

D. HULL, B. A. O. BINNS, and D. JOYCE

From the Departments of Paediatrics and Obstetrics, Radcliffe Infirmary, Oxford

We here report the clinical and pathological findings of a newborn infant with complete heart block who died 25 minutes after birth. Extensive fibrosis was found in many organs, including the heart, liver, and kidneys. The mother suffered from systemic lupus erythematosus and it seems probable that the maternal disease was responsible for the infant's condition.

Case Report

Maternal history. In 1949 the mother (age 22) developed the characteristic cutaneous rash of lupus erythematosus. The clinical diagnosis was supported by the histological appearance of a skin biopsy. The erythrocyte sedimentation rate ranged between 68-100 mm./hr., and the white cell count between 3000-4000/c.mm. Since that time her general health has been good, the skin lesions have varied in severity, and the leucopenia and high sedimentation rate have persisted. LE cells were not found in the peripheral blood, and the Wassermann reaction was negative. Her blood group was O Rh positive.

Previous pregnancies. In 1947 her first child was born at 34 weeks' gestation after surgical induction (male, birthweight 2.3 kg.). In 1953 her second child was born at term (female, 2.8 kg.). The delivery and subsequent development of both infants were normal. In 1957 her third child was born by spontaneous vertex delivery at term (female, 2.8 kg.). At birth the baby had a rash on the face and scalp, which was characteristic of chronic discoid lupus erythematosus. The rash cleared spontaneously over the next few months.

Present pregnancy. In December 1962 the mother (age 37) became pregnant for the fourth time. During the first three months of the pregnancy she took chloroquine 250 mg. once or twice each day because of an exacerbation of the skin lesions. At 36 weeks' gestation it was noted that the foetal heart rate was slow but regular. The bradycardia persisted and a clinical diagnosis was made of intrauterine heart block. This was confirmed by foetal ECG which showed the rate to be 45 beats/minute.

Delivery. Labour commenced at 38 weeks' gestation after spontaneous rupture of the membranes. There was moderate hydramnios and the liquor was stained with meconium. The labour lasted 3½ hours. When the cervix was fully dilated, the head was rotated by hand from the occipito-posterior position and delivered after an easy pull with Wrigley's forceps.

Infant. The infant (male, 2.5 kg.) had gross oedema of the head and trunk. In contrast the abdomen and limbs were not swollen. There were numerous purple patches on the face, scalp, and upper chest, which were similar to blotch haemorrhages commonly seen in newborn infants with severe anaemia, and the liver and spleen were both enlarged (3-4 cm. below the costal margin). The scrotum was darkly pigmented.

At birth, the infant had normal muscle tone and reflex irritability and, though he did not gasp or cry, he immediately began regular respiratory movements. The ECG showed complete heart block, atrial rate 168 beats/min., and ventricular rate 45 beats/min. (Fig.). His chest, which initially appeared to be full, did not expand with the respiratory efforts. On auscultation no breath sounds were heard. The heart sounds were accompanied by a loud systolic ejection murmur which could be heard over all the anterior chest wall. One minute after birth the infant's colour deteriorated. The pharynx was aspirated under direct laryngoscopy and an endotracheal tube was passed. With intermittent positive pressure ventilation superimposed on the infant's own respiratory efforts his colour improved but, despite pressures above 30 cm. H₂O, only poor expansion of the lungs was achieved. When the infant was 15 minutes old, the regular respirations were replaced by intermittent gasps, the infant became hypotonic, and the cardiac impulse was weaker. Artificial respiration was stopped 5 minutes later and the infant died when he was 25 minutes old.

Post-mortem findings. At necropsy, the lungs showed atelectasis with some patchy emphysema. There was a large pericardial effusion (20 ml.) and extensive endocardial fibroelastosis. The heart muscle showed fibrosis with patchy calcification. The atrioventricular node and bundle of His could not be identified. The liver (110 g.) and the spleen (30 g.) were enlarged. Histological sections of these organs showed fine diffuse fibrosis with extensive haemopoiesis. The fibrosis also involved

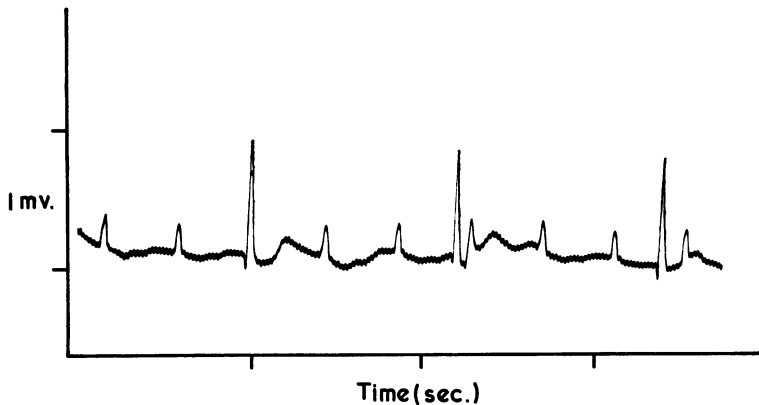


FIG.—Electrocardiogram taken soon after birth showing complete heart block.

the kidney and suprarenal gland. There was a large intracranial haemorrhage due to a tentorial tear.

The placenta was bilobed, oedematous, fibrous, and friable.

Unfortunately the specimen of cord blood was haemolysed and the infant's haemoglobin concentration is unknown. Tests on the specimen for the antinuclear factor were negative.

Comment. At birth the infant was grossly oedematous. This was presumably due to the combined effects of the myocardial fibrosis and pericardial effusion. The failure to expand the lungs was due to this large effusion. The intracranial haemorrhage was the immediate cause of death. It is difficult to understand how a tentorial tear could be caused by an easy manual rotation and 'lift-out' with Wrigleys forceps unless the supporting structures of the brain were oedematous and friable. The pigmented scrotum was possibly due to fibrosis of the suprarenal gland.

Discussion

Antibodies are known to cross the placenta from the mother to the foetus. The blood of patients suffering from disseminated lupus erythematosus contains antibodies against many cellular constituents (Anderson, 1963). The diagnostic investigation for LE cells demonstrates indirectly the presence of an antinuclear antibody. LE cells have been found in the serum of many newborn infants of mothers suffering from systemic lupus erythematosus (Bridge and Foley, 1954; Berlyne, Short, and Vickers, 1957; Burman and Oliver, 1958; Mijer and Olsen, 1958; Beck and Rowell, 1963): they gradually disappear from the blood over the first 15 weeks of life (Beck and Rowell, 1963). On clinical examination these infants appeared to be normal, and so in these cases the transplacental passage of the antinuclear antibody was apparently harmless.

In 1954, McCuiston and Schoch described an infant (gestation 40 weeks, birthweight 2.2 kg.) who had atrophic telangiectatic skin lesions on the face and scalp; the mother, a primigravida, developed acute lupus erythematosus 10 months later. Epstein and Litt (1961) reported similar skin lesions on the face of a newborn negro infant (gestation 38 weeks, birthweight 2.5 kg.); the mother suffered from rheumatoid arthritis. LE cells were not found in the blood of either infant. Jackson (1964) described a third infant (gestation 38 weeks, birthweight 2.1 kg.) who also had face and scalp lesions characteristic of discoid lupus erythematosus, and LE cells were found in the blood; the mother had subacute lupus erythematosus. In all 3 infants, the skin lesions cleared over the first few months of life. In the present case report the mother's third child had skin lesions similar to these 3 infants, and it seems probable that the skin lesions were caused by the placental transmission of antibodies.

There is evidence that lupus antibodies can have more serious effects. Nathan and Snapper (1958) described an infant (gestation 37 weeks, birthweight 1.5 kg.) with transient thrombocytopenia and LE cells in the peripheral blood; the mother had subacute lupus erythematosus. Seip (1960) observed transient anaemia, thrombocytopenia, and leucopenia in a newborn infant (gestation and birthweight not stated) whose mother developed an acute exacerbation of disseminated lupus erythematosus soon after delivery. LE cells were found in the mother's blood, but not in the infant's. Finally, Hogg (1957) in a limited necropsy found subendocardial fibroelastosis and haemotoxylin bodies in the myocardium of a newborn infant. The infant (gestation 38 weeks, birthweight 2.0 kg.) was asphyxiated at birth and died on the second day:

he was noted to have complete atrioventricular block. His mother suffered from subacute disseminated lupus erythematosus. Hogg considered that the infant's pathology was due to the maternal disease and she called the condition congenital acute lupus erythematosus.

In the case here described the infant had congenital heart block, extensive endocardial fibroelastosis with fibrosis and calcification of the myocardium, and extensive fibrosis in other organs. The striking similarity between this infant and that described by Hogg strongly reinforces her view that the condition is due to the maternal lupus erythematosus, and presumably it is caused by the transplacental passage of antibodies. In the present case the mother took chloroquine 250 mg. once or twice each day for the first 3 months of the pregnancy. It is possible that the lesions were due to the placental transmission of this drug, but this seems unlikely. Many pregnant women have received the drug for malarial prophylaxis, and no ill-effects have been reported. Chloroquine in larger doses has been given to pregnant women suffering from malaria (Berberian and Dennis, 1948), and in one instance it was taken accidentally in excessive dosage by a mother who was 5 months' pregnant (Kjaer, 1955). In all instances normal healthy infants were delivered.

There are many reviews and individual case reports describing the effect of lupus erythematosus on pregnancy. In general, it appears that in systemic lupus erythematosus there is an increase in the abortion, stillbirth, and prematurity rates (Crawford and Leeper, 1950; Ellis and Bereston, 1952; Friedman and Rutherford, 1956; Murray, 1958; Madsen and Anderson, 1961; Garsenstein, Pollak, and Kark, 1962; Mund, Simpson, and Rothfield, 1963). The prognosis is worse if the mother has an exacerbation of the disease in early pregnancy. If the placental transmission of maternal antibodies leads to widespread fibrosis of foetal tissues, it may be the cause of early foetal death. Equally it may also be responsible in part for the apparent increase in prematurity rate, for most of the affected infants discussed above were under weight for their gestational age. On the criterion of birth-weight they would be considered to be premature.

Summary

The clinical history and necropsy findings of the fourth infant of a mother suffering from subacute systemic lupus erythematosus is described. Congenital heart block was diagnosed before birth.

The infant had gross oedema and died 25 minutes after birth. There was extensive endocardial fibroelastosis, fibrosis, and calcification of the heart muscle, and widespread fibrosis of the liver, spleen, kidneys, and suprarenal glands. Blotch haemorrhages on the skin and excessive erythropoiesis in the liver and spleen suggested severe anaemia. It is thought that the condition was due to transplacental transmission of antibodies from the mother to the foetus.

The provisional clinical diagnosis of foetal heart block was made by Mr. Stallworthy who supervised the antenatal care of this patient. We are indebted to him for allowing us to publish this case report and to Dr. Derek de Sa' for performing the necropsy.

REFERENCES

- Anderson, J. R. (1963). Auto-antibodies in diseases of man. *Brit. med. Bull.*, **19**, 251.
- Beck, J. S., and Rowell, N. R. (1963). Transplacental passage of antinuclear antibody. *Lancet*, **1**, 134.
- Berberian, D. A., and Dennis, E. W. (1948). Field experiments with chloroquine diphosphate. *Amer. J. trop. Med.*, **28**, 755.
- Berlyne, G. M., Short, I. A., and Vickers, C. F. H. (1957). Placental transmission of the L.E. factor; report of two cases. *Lancet*, **2**, 15.
- Bridge, R. G., and Foley, F. E. (1954). Placental transmission of the lupus erythematosus factor. *Amer. J. med. Sci.*, **227**, 1.
- Burman, D., and Oliver, R. A. M. (1958). Placental transfer of the lupus erythematosus factor. *J. clin. Path.*, **11**, 43.
- Crawford, G. M., and Leeper, R. W. (1950). Diseases of the skin in pregnancy. *Arch. Derm. Syph. (Chic.)*, **61**, 753.
- Ellis, F. A., and Bereston, E. S. (1952). Lupus erythematosus associated with pregnancy and menopause. *ibid.*, **65**, 170.
- Epstein, H. C., and Litt, J. Z. (1961). Discoid lupus erythematosus in a newborn infant. *New Engl. J. Med.*, **265**, 1106.
- Friedman, E. A., and Rutherford, J. W. (1956). Pregnancy and lupus erythematosus. *Obstet. and Gynec.*, **8**, 601.
- Garsenstein, M., Pollak, V. E., and Kark, R. M. (1962). Systemic lupus erythematosus and pregnancy. *New Engl. J. Med.*, **267**, 165.
- Hogg, G. R. (1957). Congenital, acute lupus erythematosus associated with subendocardial fibroelastosis. *Amer. J. clin. Path.*, **28**, 648.
- Jackson, R. (1964). Discoid lupus in a newborn infant of a mother with lupus erythematosus. *Pediatrics*, **33**, 425.
- Kjaer, K. (1955). Effects of an overdose of chloroquine in a pregnant woman. *Amer. J. trop. Med.*, **4**, 259.
- McCouston, C. H., and Schoch, E. P. (1954). Possible discoid lupus erythematosus in a newborn infant. *Arch. Derm. Syph. (Chic.)*, **70**, 782.
- Madsen, J. R., and Anderson, G. V. (1961). Lupus erythematosus and pregnancy. *Obstet. and Gynec.*, **18**, 492.
- Mijer, F., and Olsen, R. N. (1958). Transplacental passage of the L.E. factor. *J. Pediat.*, **52**, 690.
- Mund, A., Simpson, J., and Rothfield, N. (1963). Effect of pregnancy on course of systemic lupus erythematosus. *J. Amer. med. Ass.*, **183**, 917.
- Murray, F. A. (1958). The problem of pregnancy complicated by systemic lupus erythematosus and renal involvement. *Guy's Hosp. Rep.*, **107**, 449.
- Nathan, D. J., and Snapper, I. (1958). Simultaneous placental transfer of factors responsible for L.E. formation and thrombocytopenia. *Amer. J. Med.*, **25**, 647.
- Seip, M. (1960). Systemic lupus erythematosus in pregnancy with haemolytic anaemia, leucopenia and thrombocytopenia in the mother and her newborn infant. *Arch. Dis. Child.*, **35**, 364.