

Oral-facial-digital Syndrome

J. A. DODGE and D. C. KERNOHAN

From the Departments of Child Health, and Child and Preventive Dentistry, Queen's University of Belfast, and Royal Belfast Hospital for Sick Children

Papillon-Léage and Psaume in 1954 reported a 'hereditary malformation of the buccal mucous membrane, and abnormal frenula' (Papillon-Léage and Psaume, 1954a). Other French and German authors have since published full accounts of this condition, and Gorlin and Pindborg (1964) have summarized current knowledge of the syndrome in a recent textbook. They described it under the heading of orodigitofacial dystosis, but as there is involvement of other tissues than bone the term oral-facial-digital (OFD) syndrome is to be preferred (Doerge, Thuline, Priest, Norby, and Bryant, 1964).

Apart from an isolated case report by Nesbitt (1965), British authors appear to have been curiously unaware of the syndrome, though Smithells (1964) drew attention to it in a British journal without adding any further examples. This paucity of references is surprising, as the first account of the syndrome was probably given by Murray in 1860. He described a Scottish female infant with characteristic features in a footnote to an account of a somewhat similar familial disorder. The family described by Doerge *et al.* (1964) in the United States was also of Scottish descent.

It may be that the condition is more common in Britain than was believed hitherto; Gorlin and Psaume (1962) suggested an incidence in France of 12 cases in 1000 individuals with cleft palate. Wahrman, Berant, Jacobs, Aviad, and Ben-Hur (1966) calculated that among Caucasian peoples the expected incidence might be about 0.0225 per 1000 live births. On this basis about 22 affected infants would be born each year in the United Kingdom.

We report five patients with the OFD syndrome, and comment on the clinical and genetic features of this condition.

Case Reports

Case 1. This girl was born at term after a normal pregnancy and weighed 3.4 kg. Her mother was 34 and

her father 38 years of age. Developmental milestones were passed at the appropriate ages though speech development was somewhat slow. There were no abnormalities of the mouth or extremities in the parents or either of her older sisters, who have all been examined. Her mother had had no miscarriages or stillbirths.

When first seen by us, the patient was in hospital at the age of 3½ years with mumps meningitis. Relevant findings were as follows.

The facial appearance was unusual with flat malar bones, slight hypertelorism, and small epicanthic folds. The upper lip had a slight, midline 'pseudocleft' of the vermilion border, and the nose was short and upturned. There was frontal bossing. The hair, which was fine and dry, was sparse in both parietal regions but there was no frank alopecia. The hard palate was intact but had a high arch, and lateral ridges, and the soft palate was normal. There were three frenula on the upper lip, while three similar frenula on the lower lip appeared to divide the alveolar ridge. The tongue was cleft into four lobules, with small, yellowish, fibrous lumps between the clefts (Fig. 1). Histology of one of these nodules showed a covering of stratified squamous epithelium

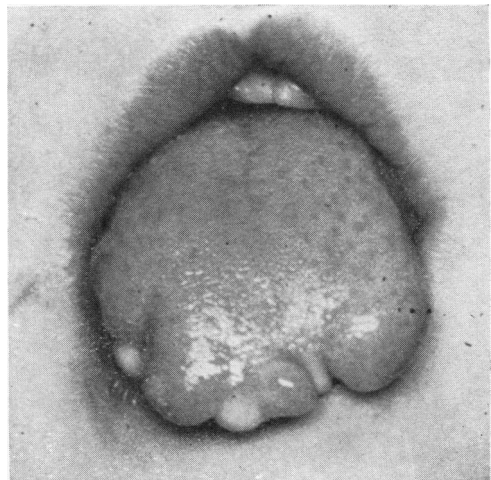


FIG. 1.—Case 1, showing lobulated tongue with hamartomata. Note pseudocleft of lip.

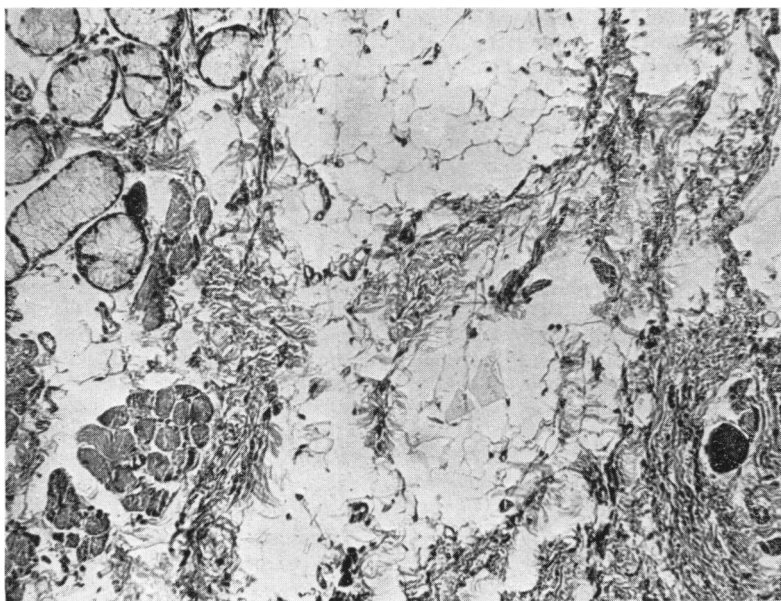


FIG. 2.—Case 1, histological appearances of hamartoma. (H. and E. $\times 110$.)

around a core of intermingled skeletal muscle, fatty tissue, and salivary gland tissue (Fig. 2).

Examination of the teeth showed a supernumerary right upper canine. Both lower lateral incisors were missing, and the left lower canine was hypoplastic.

There was a partial web between the fourth and fifth digits of the left hand. The great toe of the right foot was abnormally broad and had two separate nails (Fig. 3). Radiography showed accessory phalanges (Fig. 4). The nasion-sella-basion angle was very flattened (155°).

Chromosome analysis showed a normal karyotype.

Case 2. This patient was the mother of Cases 3, 4, and 5; she had no other children. She was aged 34 at the time of examination. She had small extra frenula between the lower lip and the gum, and had two supernumerary teeth, both lower lateral incisors. There was no abnormality of the facies and no alopecia. No digital abnormalities were present but all her fingerprints were arches. Her nasion-sella-basion angle was 151° (normal 131°).

Chromosome analysis demonstrated a normal female 46/XX constitution. This patient is an only child. It

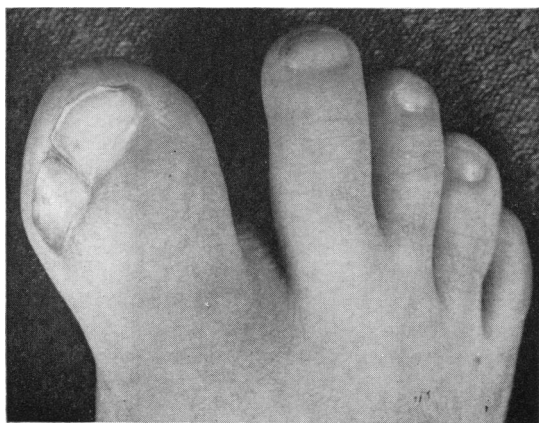


FIG. 3.—Case 1, toes of right foot.

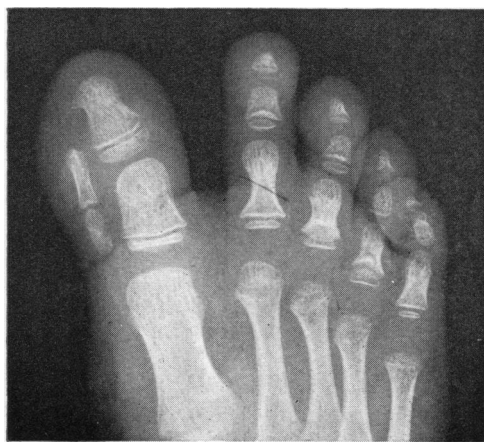

FIG. 4.—Case 1, x-ray film of right foot.

has not been possible to examine her parents and we have no information concerning their OFD status. No information with regard to consanguinity is obtainable.

Case 3. This little girl, age 10½ years, who was the eldest child of Case 2, was diagnosed as having 'tongue-tie' in infancy. The frenulum of the tongue was divided. Her speech was not affected. On examination she had a bifid tongue with a short thick frenulum and a fibrous nodule between the lobes. There were multiple frenula between the lips and the gums. The lower right gum was cleft by a thick abnormal frenulum at the position of the second incisor (which was missing) (Fig. 5). The teeth showed enamel hypoplasia. The palate was intact and the facial appearance unremarkable. There was slight clinodactyly of both little fingers, but no other digital anomaly. Her nasion-sella-basion angle was 148°.

Chromosome analysis showed a 46/XX constitution with no morphological abnormality of the chromosomes.

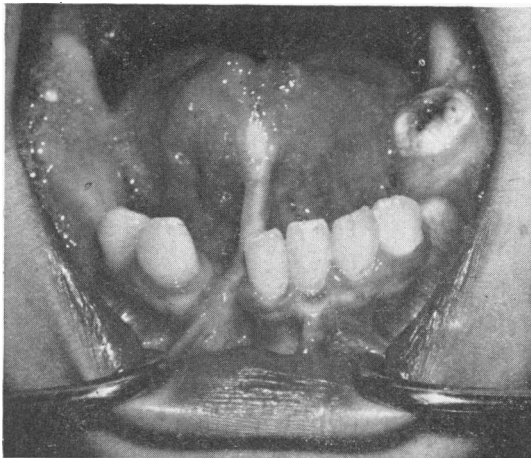


FIG. 5.—Case 3, hypertrophied frenulum, bifid tongue, hamartoma, absent incisor.

Case 4. This girl, age 8 years, was also born with 'tongue-tie' and had her lingual frenulum severed in the newborn period. She showed multiple lower anterior frenula and some in the upper canine regions. The tongue was bifid, and there was a yellow fibrous nodule on the right edge of the tongue about half way back. There was considerable dental caries. The face showed slight epicanthus and frontal bossing. There was some alopecia, mainly frontal. Her nasion-sella-basion angle was 147°.

The karyotype was normal.

Case 5. The youngest girl, age 2½ years, had no 'tongue-tie', but a 1 cm. nodule on her tongue was removed at the age of 6 months. The histology of this

tumour showed a core of fibro-fatty tissue in which small salivary glands were embedded. It was covered by stratified squamous epithelium and was thought to be a lipomatous hamartoma.

On examination we found that her facial appearance was similar to that of Case 1. There was frontal bossing, epicanthic folds, and hypertelorism. The nose was broad and flattened. The hair was very sparse. Both hands showed short digits and clinodactyly. The tongue was lobulated, and there were hamartomata on both the left and right inferior aspects between the lobules. The upper teeth were normal. Radiographs confirmed the absence of three lower incisors. There was a marked lingual frenulum and multiple frenula between lower lip and gum. The palate was high and arched, showing a submucous cleft with shelving laterally. The soft palate was intact.

Chromosome complement and morphology were normal.

Discussion

Clinical features. A full description of the OFD syndrome has been published by Gorlin and Pindborg (1964) and the clinical features described by them and by others have been summarized in the Table. We wish to draw attention to the considerable variability of expression. It seems likely that the three children of our second patient have inherited the disorder from her, though her only abnormality is the presence of two supernumerary incisors. Supernumerary teeth are, however, a well-documented feature of the OFD syndrome, and though they may occur as an isolated phenomenon, it is very unusual to have six lower incisors. We feel that this finding probably indicates a *forme fruste* of the OFD syndrome. All three of the progeny show much more clearly defined features as described above, but digital abnormalities are minor. Ruess, Pruzansky, Lis, and Patau (1962) estimated that 42% of affected subjects had no digital involvement. A similar proportion are said to be mentally retarded (Ruess, Pruzansky, and Lis, 1965). No psychological tests have been performed upon our patients, but they seem to be of average intelligence.

The management of patients with the OFD syndrome depends upon the particular features present in the individual case. Curtin (1964) has described the use of corrective surgery. The indication for early surgical intervention is to relieve or forestall respiratory, feeding, or speech problems. In the patients reported here there was no history of either respiratory or feeding abnormality, but in one child (Case 1) there was evidence of an incorrect speech habit. This may have been caused by the irregular contour of the tongue preventing an adequate seal. There was also excessive interest and preoccupation with the tongue shape which

alone could be regarded as an indication for operation.

The surgical reconstructive and corrective procedures associated with the multiple buccal frenula, the midline cleft of the upper lip, and the digital deformities are considered to be less urgent and may be carried out electively. None of our patients had a cleft palate but this, when present, should be repaired before the onset of speech.

The dental anomalies which include malposition, malformation, and absence of teeth, with an associated altered mandibular development, predispose to severe malocclusion. Reduced lingual mobility and multiple vestibular frenal attachments prevent a satisfactory level of oral hygiene, and flat surface caries is not uncommon.

similarities to make it highly probable that it is the same, or a very closely related syndrome. The fact that one male has survived in no way invalidates the concept that the syndrome is usually lethal in males. Other virtually sex-limited conditions, which are cited by Doege *et al.*, i.e. incontinentia pigmenti and Wildervanck's syndrome, have been known to occur in males, though, as in the OFD syndrome, the great majority of affected persons are female. Hooft and Jongbloet (1964) described two brothers with what they regarded as a variant of the OFD syndrome, and suggested that their early deaths were compatible with the idea of lethality in the male. We feel that, though their reasoning is correct, the particular clinical features present in their parents are insufficient to make a firm diagnosis of OFD syndrome, even in a variant form.

The inheritance of the OFD syndrome is not clear. In the largest recorded pedigree, it has been shown that inheritance is compatible with either a sex-linked or an autosomal dominant, lethal in males (Doege, 1965). In other instances of the syndrome other possibilities arise. Thus, the first of our patients had no family history of similar disorders, and other such sporadic occurrences of the syndrome are on record. These could well have been inherited as recessive characteristics, but one would expect a history of consanguinity to have been obtained occasionally if such an uncommon condition were inherited in this fashion. The most plausible theory appears to be that of an X-linked dominant gene, lethal when hemizygous. Support was given to this theory by the discovery that the male patient of Wahrman and his colleagues (1966) had a 47/XXY chromosome complement.

The multisystem involvement suggests, however, that a chromosomal aberration, involving more than one gene, is also a possibility; but the evidence is that the amount of chromosome material involved is small. Inconsistent reports of a chromosomal abnormality have been published. Gorlin (1961) described an abnormality of a No. 1 chromosome in one of his patients. Kushnick and his colleagues (1963) reported complete trisomy of a group A chromosome, probably No. 1, in their one male patient. No family history of OFD syndrome could be obtained in the latter. The suggestion has been made by Wahrman *et al.* (1966) that this patient's karyotype could be rearranged in such a way as to be compatible with a diagnosis of Klinefelter's syndrome. This would mean that both of the well-authenticated male instances of the syndrome had an extra X chromosome, and no autosomal abnormality. Patau, Therman, Inhorn, Smith, and Ruess (1961) described an insertion of

TABLE
Clinical Features Described in OFD Syndrome

A. Oral	Tongue	Lobulated, with hamartomata between lobules; short frenulum; incomplete differentiation of floor of mouth
	Gums	Cleft by abnormal supernumerary frenula
	Palate	Cleft, often in soft palate, may be bilateral or asymmetrical; high vault with lateral ridges
	Teeth	Malposition, supernumerary teeth, absent teeth, often enamel hypoplasia
	Lips	Midline notch ('pseudocleft') in upper lip
B. Facial	Eyes	Hypertelorism, epicanthic folds
	Nose	Hypoplastic alar cartilages
	Cheeks	Flattened, hypoplastic maxillae
C. Digital	Fingers and toes	Polydactyly, syndactyly, camptodactyly, clinodactyly, brachydactyly; x ray may show osteoporosis
D. Other	Cranial	Frontal bossing; wide nasion-sella-basion angle
	Skin	Dryness or seborrhoea; alopecia
	Mental	Mental retardation (?30-50%)
	Neurological	Familial trembling; hydrocephalus with porencephalic cyst; hydranencephaly; ? agenesis of corpus callosum
	Internal	Polycystic kidneys

This Table is derived from the descriptions of Ruess *et al.* (1962), Gorlin and Pindborg (1964), Ruess *et al.* (1965), and Wahrman *et al.* (1966).

Genetic features. Of all six instances of the syndrome described in males, only one is completely acceptable (Wahrman *et al.*, 1966), and this occurred in an individual with XXY Klinefelter's syndrome. Another male, who probably has OFD syndrome, was described by Kushnick, Massa, and Baukema (1963). Doege *et al.* (1964) seemed reluctant to accept this as an authentic case. However, the description given is difficult to apply to any other condition; though slightly atypical, there are enough

chromatin material into one arm of a No. 1 chromosome in two of their patients, a mother and daughter. They deduced that it had been derived from a C-group chromosome. The interpretation of their observations by Patau *et al.* was challenged by Cooper and Hernits (1963) who felt that it was not proved that the abnormal No. 1 chromosome was due to an insertion, nor that the extra fragment had been donated by the C¹ (6-12) chromosome. Cooper and Hernits described a male pseudohermaphrodite with a 44/XY constitution and an abnormal No. 1 chromosome similar to that described by Patau *et al.* He had none of the features of the OFD syndrome.

Nevertheless, the observations of Patau *et al.* cannot be disregarded, and it is noteworthy that the chromatin insertion was present in two subjects of the same family. Four other patients without a family history of OFD syndrome had normal karyotypes. Were a small fragment detached and not inserted into another chromosome, it would probably be overlooked or regarded as an artefact in cell analysis. A similar finding, of a chromosomal fragment, has been noted in certain karyotypes of male Amsterdam dwarfs, and regarded as significant only because of its presence in a high proportion of cells examined (Jervis and Stimson, 1963; Dodge, 1965; Hoof, Lormans, and Jongbloet, 1965). Recently, Falek, Schmidt, and Jervis (1966) have described a family group with the De Lange Amsterdam dwarf syndrome and an apparent translocation of part of one of the G group chromosomes to part of chromosome A3 in unaffected carriers. They concluded that excess of chromosome A3 material may have produced the disorder.

It is suggested that in isolated instances of the OFD syndrome a partial trisomy could have occurred but have been undetectable because the separated fragment was very small. In familial cases, however, the possibility of translocation arises as in Down's syndrome, and in Falek *et al.*'s family of Amsterdam dwarfs, and this would agree with Patau *et al.*'s observations. Papillon-Léage and Psaume (1954a, b) state that 'clearly the age of the parents is above average' but give no details to support this statement. Similar statements were made in respect of Down's syndrome before it became apparent that in familial cases, with translocation of a 21 chromosome, the parents' ages were often much lower. The mean age of the mothers of patients reported in the literature, where known, shows no difference between familial and sporadic groups, but the numbers are too few (10 and 7 cases, respectively) to allow valid comparison. The family described by Doege *et al.* all appeared to have

normal white blood cell karyotypes, though liver cell culture in one individual with polycystic disease of the liver, kidneys, and pancreas revealed trisomy of a group G chromosome. They stated that further analysis of the leucocyte chromosomes was being undertaken, and it is obvious that photographs of a high technical quality are required for the definition of a small insertion.

We have been unable to find any evidence of a chromosomal abnormality in our own patients. Although the suggestion of a partial trisomy is attractive, we believe that there is insufficient supporting evidence, and that a mutation of a single gene or small gene-complex is more in keeping with the currently known facts. This issue can only be resolved by analysis of many more karyotypes.

Summary

The oral-facial-digital (OFD) syndrome is probably more common in the United Kingdom than the published reports would suggest. Five instances of the OFD syndrome are presented. Four of these are members of the same family—a mother and three daughters.

The genetics of this syndrome are discussed. We found no chromosomal abnormality in our patients, and believe that further studies are required before accepting a partial trisomy as the cause of the OFD syndrome. On present evidence, an X-linked dominant gene, lethal when hemizygous, appears to be the most likely cause of the condition.

We would like to thank Professor I. J. Carré, Mr. D. Stewart, and Mr. R. I. H. Whitlock for permission to report these cases; Dr. W. R. Morton and Mr. N. P. Bishun for chromosome studies; Dr. H. Jones for the pathology report; Mr. R. G. Wood for photography; Miss M. Weller for typing.

REFERENCES

- Cooper, H. L., and Hernits, R. (1963). A familial chromosome variant in a subject with anomalous sex differentiation. *Amer. J. hum. Genet.*, **15**, 465.
- Curtin, J. W. (1964). Plastic surgical correction of the oral-facial-digital syndrome. *Plast. reconstr. Surg.*, **34**, 579.
- Dodge, J. A. (1965). De Lange's Amsterdam dwarfs syndrome. *Develop. Med. Child Neurol.*, **7**, 31.
- Doege, T. C. (1965). Calculation of sex limitation (in O.F.D. syndrome). *New Engl. J. Med.*, **272**, 54.
- , Thuline, H. C., Priest, J. H., Norby, D. E., and Bryant, J. S. (1964). Studies of a family with the oral-facial-digital syndrome. *ibid.*, **271**, 1073.
- Falek, A., Schmidt, R., and Jervis, G. A. (1966). Familial De Lange syndrome with chromosome abnormalities. *Pediatrics*, **37**, 92.
- Gorlin, R. J. (1961). Orodigitofacial dysostosis: a new chromosomal abnormality. *New Engl. J. Med.*, **265**, 150.
- , and Pindborg, J. J. (1964). *Syndromes of the Head and Neck*. McGraw Hill, New York.
- , and Psaume, J. (1962). Orodigitofacial dysostosis: a new syndrome. A study of 22 cases. *J. Pediat.*, **61**, 520.

- Hoof, C., and Jongbloet, P. (1964). Syndrome oro-digito-facial chez deux frères. *Arch. franç. Pédiat.*, **21**, 729.
- , Lormans, J., and Jongbloet, P. (1965). Typus degenerativus amstelodamensis ou syndrome de Cornelia de Lange. *Acta paediat. belg.*, **19**, 5.
- Jervis, G. A., and Stimson, C. W. (1963). De Lange syndrome. *J. Pediat.*, **63**, 634.
- Kushnick, T., Massa, T. P., and Baukema, R. (1963). Orofacio-digital syndrome in a male. *ibid.*, **63**, 1130.
- Murray, J. J. (1860). Contributions to teratology: undescribed malformation of the lower lip occurring in four members of one family. *Brit. foreign med. chir. Rev.*, **26**, 502.
- Nesbitt, A. (1965). Orodigitofacial dysostosis. Report of a case. *Brit. dent. J.*, **119**, 363.
- Papillon-Léage, Mme., and Psaume, J. (1954a). Une malformation héréditaire de la muqueuse buccale. Brides et freins anormaux. *Rev. Stomat. (Paris)*, **55**, 209.
- , and — (1954b). Une nouvelle malformation héréditaire: dysmorphie des freins buccaux: huit observations. *Actualités odonto-stomat.*, **25**, 7.
- Patau, K., Therman, E., Inhorn, S. L., Smith, D. W., and Ruess, A. L. (1961). Partial-trisomy syndromes. II. An insertion as cause of the O.F.D. syndrome in mother and daughter. *Chromosoma (Berl.)*, **12**, 573.
- Ruess, A. L., Pruzansky, S., and Lis, E. F. (1965). Intellectual development and the O.F.D. syndrome: a review. *Cleft Palate J.*, **2**, 350.
- , —, —, and Patau, K. (1962). The oral-facial-digital syndrome: a multiple congenital condition of females with associated chromosomal abnormalities. *Pediatrics*, **29**, 985.
- Smithells, R. W. (1964). The orofaciocigital syndrome. *Develop. Med. Child. Neurol.*, **6**, 421.
- Wahrman, J., Berant, M., Jacobs, J., Aviad, I., and Ben-Hur, N. (1966). The oral-facial-digital syndrome: a male-lethal condition in a boy with 47/XXY chromosomes. *Pediatrics*, **37**, 812.