

Leigh's Subacute Necrotizing Encephalopathy: Clinical and Biochemical Study, with Special Reference to Therapy with Lipoate

BARBARA E. CLAYTON, R. H. DOBBS, and A. D. PATRICK

From Queen Elizabeth Hospital, Hackney Road, London, E.2, and the Department of Chemical Pathology, Institute of Child Health, Great Ormond Street, London W.C.1

Since the report by Leigh (1951) of an unusual infantile encephalopathy characterized by bilateral symmetrical lesions in the brain-stem, which were strikingly similar to those of Wernicke's encephalopathy of adults suffering from thiamine deficiency, a total of 30 case reports has appeared, in which similar pathological changes have been found (28 cases were summarized by Ebels, Blokzijl, and Troelstra (1965), including Case 1 of the present report, and 2 sibs were reported by Worsley, Brookfield, Elwood, Noble, and Taylor (1965)). In none of these cases was there reason to suspect a nutritional deficiency of thiamine, and no response was observed in those that were given thiamine. However, the occurrence of the disease among sibs suggested that an inherited metabolic defect, involving reactions for which thiamine is only one of several essential components, might be the primary cause of the illness.

This report concerns a further family of three sibs suffering from this condition. In two of these, as a result of the necropsy on the first sib, the diagnosis was made during life; this has not been reported previously, and it enabled biochemical investigations to be made which revealed hyperpyruvaemia as the outstanding abnormality. Further investigations of the aetiology of this defect have been made, and the results of therapy with α -lipoic acid are described.

Case Reports

The family consisted of 4 children, of whom 3 have been clinically affected. J.R. (male) is now 11 years old and clinically normal. P.R. (male) developed symptoms at 7 months and died at 3 years 7 months. F.R. (female) developed symptoms at 11 months and died at 3 years 10 months. H.R. (female) developed symptoms at 10 months and died at 6 years 6 months.

A further pregnancy was terminated therapeutically.

The parents are healthy and unrelated, the mother being German and the father English. No previous neurological disturbance was known in either family.

Case 1 (Male, born May 27, 1957). A boy of birth-weight 3.51 kg. was the second child in the family. Pregnancy and labour were reported to have been normal, and he was said to have developed normally until 13 months of age, sitting alone at 7 months, standing at 11 months, and saying a few words at 1 year. Nevertheless, when he started sitting up it was already noticed that he slumped forward with marked kyphosis, and supported himself on his hands. At 13 months he developed a pyrexial illness associated with vomiting and convulsions, and CSF contained 22 cells/mm.³ A diagnosis of unspecified encephalitis was made. From this time on he became progressively more hypotonic, and within 2 months was unable to support himself, sit up, or even lift his head from the bed. He ceased speaking, though he continued to recognize his parents and to smile and play with his hands. From this time, also, he suffered periodic attacks of vomiting, during one of which he was admitted to hospital with suspected intracranial tumour. Lumbar puncture revealed clear fluid containing 60 polymorphs/mm.³ and 70 mg. protein/100 ml. Blood counts, and plasma Ca, P, and electrolytes were normal. Skull x-ray films and EEG showed no abnormality.

Thereafter he was admitted periodically to several hospitals with sudden attacks of pyrexia, vomiting, and acute dehydration, but repeated investigations revealed no significant abnormality.

At the age of 2 years 7 months he was transferred to Queen Elizabeth Hospital. On examination he was extremely wasted and somewhat dehydrated. His weight was 7.94 kg., and length 74.5 cm., both well below the 3rd centile for age; heart and lungs were normal; the liver was palpable 3 cm. below the costal margin in the mid-clavicular line; the head appeared large compared to the body and measured 51 cm. in circumference; there was marked hypotonia in all limbs, and he was unable to sit up or to support his head, though he moved his hands and could grasp objects. He smiled with evident enjoyment on being talked to or

played with, but showed little ability to do much more. He recognized his parents or those who were frequently around him, but soon forgot anyone who was absent for a few days. Knee- and ankle-jerks could be elicited, and at times were even thought to be brisker than normal; plantar responses were equivocal and infantile in type; the possibility of sensory disturbances could not be excluded, but appreciation of light touch and pinprick was probably normal in all areas. The fundi were very pale, but otherwise the cranial nerves appeared normal except for rolling movements of the eyes, described below, which were first noticed about 2 months after admission; pupils reacted to light and accommodation.

A wide range of special investigations was carried out, details of which are given in the Appendix Table. A high creatinine excretion indicated the degree of muscle wasting, and electromyography was reported as suggesting 'a denervating process probably of peripheral origin rather than anterior horn cell'. A muscle biopsy showed no histological abnormality. Plasma Ca and P levels were within normal limits, but plasma alkaline phosphatase levels were constantly below normal for age. There was no adequate explanation for this finding.

Ventriculography revealed some enlargement of the ventricles, with wide and deep sulci, suggesting a degree of cortical atrophy. A brain biopsy was performed by Mr. Northfield at the London Hospital; the report, from the Bernhard Baron Institute of Pathology (Record No. 74130, 1960) was as follows. 'Frozen sections show fat-laden macrophages containing sudanophil and PAS positive material around intracerebral vessels, but no abnormality of the white matter included in the section. No specific diagnosis can be given, but the features are strongly suggestive of changes in the deeper white matter.'

During 5 months in hospital there was little change in the child's general condition, but he suffered periodic bouts of pyrexia, profuse sweating, considerable dehydration, and loss of weight, often accompanied by vomiting. The attacks were spontaneous and were sometimes associated with transient neck rigidity. These were treated with copious oral fluids, and subsided in two or three days.

Two further curious features, which later developed also in the two younger sibs reported below, made their appearance soon after admission and became increasingly frequent during his stay in hospital. The first was the occurrence of deep sighing respirations, which were particularly marked when he was played with or became excited. These gave the impression of temporary air-hunger and usually lasted about 5 minutes. The second feature was the appearance of eye-rolling movements, which were often initiated when the child was disturbed or stimulated, and tended to occur in association with the sighing respiration. Both eyes moved simultaneously in a big involuntary upward and circular sweeping movement, repeated several times within a few moments. In other ways there was a slight steady deterioration in muscle tone and movements, and he made very poor weight gains.

At 3 years and 1 month old the child was transferred

to a convalescent home, where he gradually weakened, contracting bronchopneumonia, and dying suddenly at the age of 3 years and 7 months.

Necropsy. Apart from extensive bronchopneumonia, the only significant changes were present in the central nervous system. Dr. Crome summarized the histological findings as follows: 'The changes are characteristic of necrotizing encephalomyelopathy, but the spinal cord appears to have been more extensively affected in this than in most of the previously reported cases.'

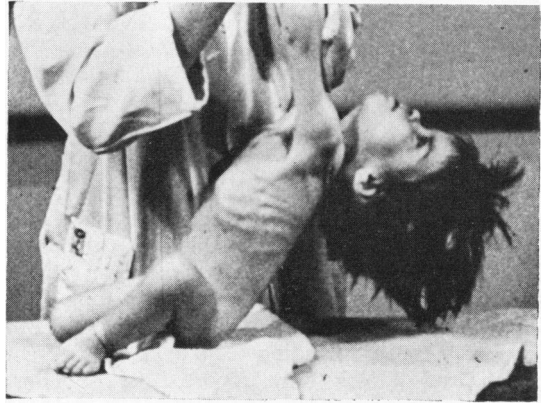


FIG. 1.—Case 2, aged 2 years.

Case 2 (Female, born October 13, 1958). The birth-weight was 3.06 kg., and pregnancy and labour were normal. Early development appears to have been normal and at 10 months she was beginning to walk and to say a few words. At 11 months her illness began suddenly, with muscular weakness and hypotonia, and bouts of erratic vomiting with fever and severe loss of weight. Within 3 weeks she was unable to walk or stand and, within 2 months, even to support herself sitting. She became apathetic and miserable, and further attempts to talk ceased completely.

At 13 months of age she was seen by Dr. Douglas Gairdner who immediately recognized not only the similar symptomatology to that of her brother, but also the remarkable facial similarity, with a large head, retrousse nose, and forward-facing nostrils.

She was admitted to Queen Elizabeth Hospital when 14 months old. On examination she was wasted, extremely hypotonic, and somewhat dehydrated. She weighed 6.90 kg., well below the 3rd centile. The head circumference was 48 cm. The liver was palpable, with a hard edge, 4 cm. below the costal margin. The lungs showed no abnormality. She was completely atonic and unable to sit up or even to support her head (Fig. 1), but lying on her back she followed objects alertly, would smile wanly, and readily accepted food in the form of slops.

Cranial nerves and optic fundi appeared normal. Limb movements were possible but she grasped only very weakly, and all deep reflexes were absent. Plantar

responses were probably flexor. Sensation was normal within the limits of examination. No abnormality was found in the CSF.

Biopsies of liver, spleen, and muscle were all found to be histologically normal at this time.

Numerous blood and urine tests gave normal results (see Appendix Table). X-ray film showed a bone-age of 6 months, with slight generalized decalcification, and plasma alkaline phosphatase levels were below normal, as found in Case 1.

She remained in hospital until the age of 1 year 7 months and was then transferred to a convalescent home with her brother. During this period she became progressively more hypotonic and feeble and continued to lose weight. Like her brother she suffered several bouts of vomiting of sudden onset with no apparent cause, during which she became even more listless and hypotonic but quickly recovered after treatment with copious oral fluids and sodium lactate.

Following the death of her brother and the finding at necropsy of cerebral changes of subacute infantile necrotizing encephalopathy, the child was readmitted to Queen Elizabeth Hospital in October 1960, where she remained until August 1961. Here the blood pyruvate level was found to be raised, and, because of this finding and of the similarities between subacute infantile necrotizing encephalopathy and Wernicke's encephalopathy of adults suffering from thiamine deficiency, further investigations relating to carbohydrate metabolism were undertaken by the Department of Chemical Pathology, Institute of Child Health, Great Ormond Street. These investigations are described in detail in a later section. Briefly, the outstanding biochemical abnormalities were the greatly increased concentrations of pyruvate and lactate in the blood. Mean values found at this time were 2.17 mg./100 ml. for pyruvate (chemical estimation, upper normal = 1.40 mg./100 ml.) and 28.5 mg./100 ml. for lactate (upper normal = 16.0 mg./100 ml.). The mean urinary pyruvate concentration was 1.37 mg./kg./24 hr. compared to a control value of 0.32 mg./kg./24 hr.

Attempts to correct these abnormal biochemical findings by the administration first of thiamine (50 mg. and later 100 mg./day orally), next of thiamine pyrophosphate ('berolase', 10 mg. intramuscularly daily), and later of D-penicillamine (100 mg. t.d.s. orally for 3 days each week), were without effect. Little clinical improvement could be expected in a child whose condition had deteriorated so greatly, and no significant alteration was detected following these therapeutic trials.

The curious features of sighing respiration and eye-rolling, first noticed in her brother at the age of 2 years and 9 months, also appeared at almost the same age in this patient, and continued until she died 13 months later. The periodic bouts of spontaneous vomiting, dehydration, and acidosis, lasting up to 3 days, remained a persistent feature.

At the age of 3 years and 8 months she was transferred to The Hospital for Sick Children, where the effect of administration of the pyruvate oxidation factor, α -lipoic acid, and of vitamin B₁₂, on the blood pyruvate level was

investigated. Lipoic acid was given in a dosage of 5 mg. twice daily in an enteric-coated capsule for three consecutive days each week, and vitamin B₁₂ in a dosage of 1000 μ g. i.m. twice weekly. During this trial period of 4 weeks the mean concentration of blood pyruvate was 1.90 mg./100 ml., and no significant response to therapy was observed.

At the age of 3 years and 10 months she developed bronchopneumonia and died suddenly in a manner very similar to that of her brother. The necropsy, performed by the late Dr. Martin Bodian, revealed little of significance outside the central nervous system, other than bronchopneumonia and extreme bodily emaciation. The findings in the brain and central nervous system of subacute necrotizing encephalopathy are being reported fully elsewhere (Claireaux, Crome, Dayan, and Ockenden, 1967).

Case 3 (Female, born April 6, 1960). Birthweight 2.43 kg.: 43 weeks' gestation. At 9 months of age, after an uneventful early infancy, she developed a febrile bronchitis and was subsequently left slightly wheezy.

At 10 months she became rather fretful, probably began to develop hypotonia, and was admitted to Queen Elizabeth Hospital for investigation because the parents thought she might be developing symptoms similar to those of her sibs. At this time she could sit up, grasp objects, and stand and walk with support. Her weight was 7.75 kg., and routine clinical examination revealed no abnormality apart from a mild degree of generalized hypotonia. On extensive biochemical analysis of blood and urine (see Appendix Table), the only abnormality found was an increased blood pyruvate concentration of 2.25 mg./100 ml. Blood lactate was rarely in excess of 16 mg./100 ml. From this it appears that the biochemical impairment was already severe at a time when the clinical abnormalities were comparatively slight. Urinary excretion of pyruvate at this time was 0.45 mg./kg. 24 hr.

At the age of 1 year her weight, 7.30 kg., and height, 66 cm., were both below the 3rd centile. The bone-age was about 1 year, and skull circumference was 47.3 cm. Muscles were thin, wasted, and hypotonic; biceps, ankle- and knee-jerks were present, triceps and supinator jerks absent, plantar responses were flexor, and abdominal reflexes were absent; optic discs were normal. X-ray pictures of bones and skull showed no abnormality. Examination of the chest revealed slight generalized bronchitis. The liver was palpable two finger-breadths below the costal margin, and the spleen could just be felt.

During the next year trials of thiamine, thiamine pyrophosphate, and D-penicillamine for possible therapeutic effect were carried out in a similar manner to those applied to her sister, but no significant response was observed. Blood pyruvate concentration remained high, with a mean value of 2.04 mg./100 ml., and blood lactate was usually a little greater than 20 mg./100 ml.

Her condition slowly deteriorated (Fig. 2 and 3), with increasing hypotonia and acute episodes of anorexia and vomiting, similar in every way to those which her sibs suffered. Between the age of 1 and 2 years she was

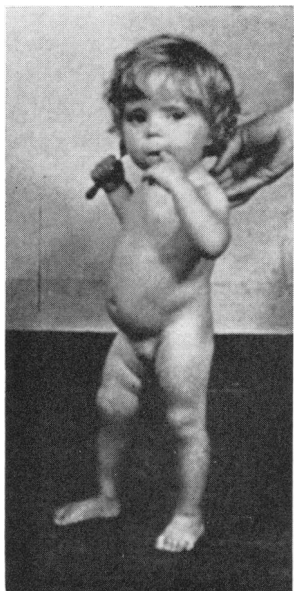


FIG. 2.—Case 3, aged 1 year and 5 months.

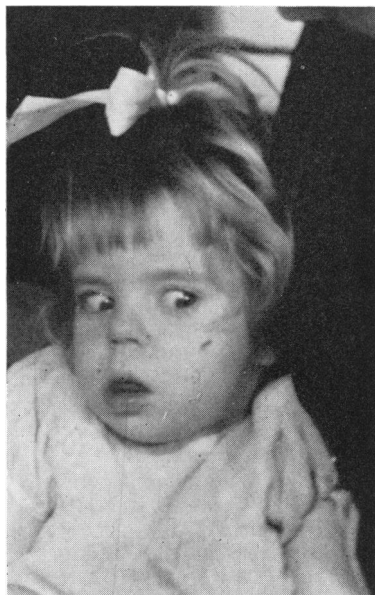

FIG. 4.—Case 3, aged 3 years and 8 months, showing first phase of eye-rolling movement.

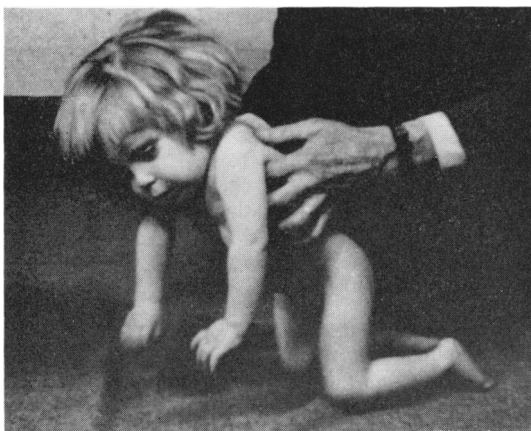


FIG. 3.—Case 3, aged 1 year and 11 months.

admitted to hospital on five occasions with these attacks, and had several bouts at home. Also, at 2 years of age eye-rolling (illustrated in Fig. 4 at 3 years 8 months) and sighing respiration similar in every way to those features seen in her two older sibs, were first noted.

At 2 years 4 months (weight 7.25 kg.), she was transferred with her sister to The Hospital for Sick Children for therapeutic trials of lipoic acid and vitamin B₁₂ (as described in Case 2). The effects of these trials are summarized for Case 3 in Fig. 5. Though no striking immediate fall of blood pyruvate concentration was observed, for the first time somewhat lower values (mean

1.93 mg./100 ml.), related to the administration of lipoic acid, were recorded.

After 2 months she was discharged home on oral enteric-coated lipoic acid (5 mg. twice a day) and B₁₂ (500 μg. intramuscularly), each given alternately on 3 days a week. A month later her mother reported that not only was there no improvement but she actually seemed worse after the B₁₂ injections. These injections were therefore stopped, and lipoic acid alone was continued. After one month on lipoic acid alone she began to improve. She would pull herself up, was trying to climb the stairs, and according to the general

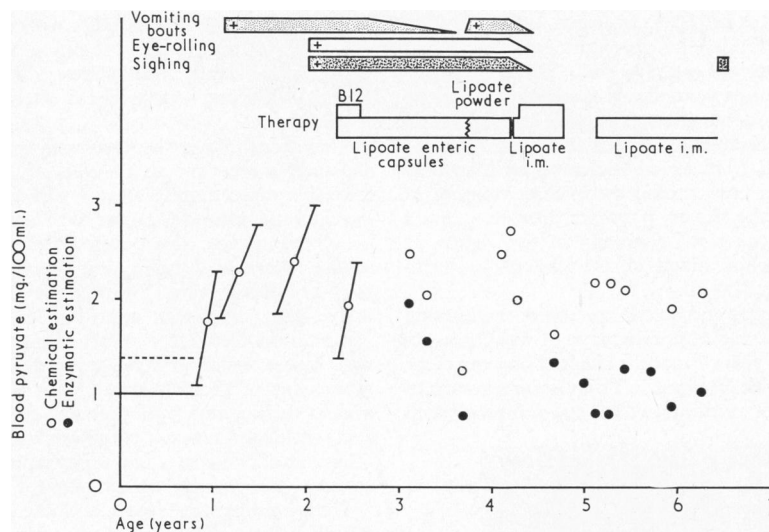


FIG. 5.—Case 3. *Effects of lipoate therapy. Upper normal pyruvate concentrations, ----- by chemical estimation; ————— by enzymatic estimation.*

The staggered lines represent the range of pyruvate concentrations found on frequent estimation over the periods indicated.

practitioner she was 'very changed in her personality, more approachable and friendly'.

By 3 years of age, she weighed 9.07 kg. Progress continued until at the age of 3 years 7 months she was standing without support, saying a number of words clearly, playing with dolls, eating well, and having no attacks of vomiting, or of choking with solid food. Also, during this period blood pyruvate concentration, as estimated both chemically and enzymatically, gradually fell to normal values (Fig. 5). Blood lactate concentration was usually about 18 mg./100 ml.

However, during the next 8 weeks she became irritable again, had occasional vomits, was not so well, became anorexic, and was finally readmitted to Queen Elizabeth Hospital at 3 years and 9 months as an emergency with considerable dehydration. After rehydration it was immediately obvious that her muscle weakness was worse. She was unable to stand but could sit up with help. She had slightly laboured breathing, took frequent big gasping respirations, and constantly rolled her eyes. Her speech had deteriorated into words which were scarcely comprehensible except to her mother, though it was evident that she still understood what was said to her and could point to, and pick out, named objects. Her weight on rehydration was little different from what it was at the age of 10 months. It seems probable that this period of deterioration coincided with the time when her mother began to remove the lipoic acid from the enteric-coated capsules and to give it as a powder.

After returning home, she continued to receive lipoic acid powder instead of enteric-coated capsules. She made very little progress, and blood pyruvate concentration increased to 2.7 mg./100 ml.

At 4 years 2 months, while in Cheyne Hospital for family reasons, it was decided to try the effect of intra-

muscular, instead of oral, lipoic acid, and 5 mg. twice weekly was given for one month, and then 10 mg. twice weekly for six months. After only two weeks improvement was apparent and gradually she became much happier. There were no attacks of vomiting, and sighing respirations and eye-rolling movements gradually ceased, she again grasped small objects and played, and could raise her head and sit up with support. Her weight reached 7.84 kg. only. The injections were stopped at 4 years 9 months because routine liver function tests showed a large increase in serum transaminase activity. When retested after 4 months, the transaminases had returned to normal.

During this period of lipoate injections, blood pyruvate concentration, estimated chemically, fell to 1.63 mg./100 ml., the corresponding value by enzymatic assay being 1.33 mg./100 ml., which continued to fall to 1.12 mg./100 ml. when lipoate was discontinued (Fig. 5).

At 5 years 1 month she was cheerful and continued to be free of vomiting attacks, sighing respirations, and eye-rolling movements. She could sit up alone but tended to slump forward. She could stand only with support but was able to manoeuvre herself across the floor with a 'walker'. She tried hard to talk and vocalized a lot but was not really comprehensible. Nevertheless, she had a great understanding of speech. She was thin and wasted and her limbs were hypotonic, though knee-jerks were obtainable. Her plantar responses were equivocal. There seemed to be an ataxic element in her arm movements. She was neither dry nor clean.

Lipoate injections were resumed at a lower dosage of 5 mg. twice weekly, care being taken that the ampoules were stored at 4° C. until used, and during the ensuing 6 months there was no further indication of liver damage. During this time enzymatic assay of blood pyruvate gave

values within the range 0.80-1.36 (mean 1.08) mg./100 ml., but values obtained by chemical estimation had risen to approximately 2 mg./100 ml. This increasing difference between the two methods of assay could not be accounted for as pyruvate arising from the breakdown of oxaloacetate, but chromatography of the dinitrophenylhydrazones derived from blood indicated an increased concentration of an unidentified component running in front of that of the faster pyruvate isomer. Blood lactate concentrations were generally in the region of 20 mg./100 ml., while blood citrate showed a steady increase to 2.7 mg./100 ml.

She remained happy and, in the opinion of the nursing staff, showed increasing comprehension of what went on around her. By 5 years 7 months she had become clean by day and would ask for a pot. There was no return of attacks of acidosis or vomiting, nor of eye-rolling or deep

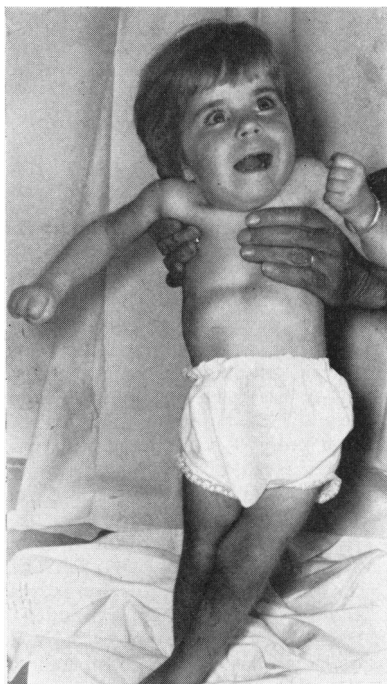

FIG. 6.—Case 3, aged 6 years and 3 months.

sighing. She weighed 9.20 kg., was 77.5 cm. tall, and showed no changes on physical examination compared with 6 months previously.

When seen at the age of 6 years and 3 months there was little further change. She could sit up alone and support her head, but stood only with support (Fig. 6). She was in good general health, though very thin and hypotonic, and weighed only 10 kg. Nevertheless, she was cheerful and friendly, made meaningful sounds, indicated her needs by gestures, obeyed simple commands, and recognized objects. An element of ataxia in her movements and gestures, and nystagmus on lateral deviation of the eyes were new features.

Blood pyruvate concentration by enzymatic assay was 1.09 mg./100 ml., and by chemical assay 2.30 mg./100 ml. Blood lactate concentration had fallen to 12.4 mg./100 ml. Serum transaminase activities had not increased.

Two months later she developed tonsillitis from which she took some time to recover, and which seemed to initiate a rapid deterioration. She became listless, lost her appetite, ceased to sit, or to make much effort to talk or communicate. Respiration began to be laboured, with a return of deep sighing which had not been seen for more than 2 years. Within a few weeks she lost 1 kg. in weight. She was admitted to Queen Elizabeth Hospital on October 7, 1966, obviously dying. There was coarse bilateral nystagmus and marked athetoid movement of the left arm. This was associated with attacks during which the left arm extended and became stiff, with simultaneous extension backward of the head. These attacks lasted a few minutes, and left her looking anxious, and sighing and gasping for breath.

Deterioration was rapid, and she died in respiratory failure 4 days after admission, aged 6 years 6 months. Necropsy showed bilateral patchy collapse and oedema of lungs with petechiae over the pleural surfaces, and terminal haemorrhages in the stomach. The brain was preserved for neuro-pathological examination.

Further Biochemical Investigations (Cases 2 and 3)

Blood and urine. While the increased concentration of pyruvate was the main feature of chromatography of the dinitrophenylhydrazones of keto acids of blood and urine, an increased concentration of α -ketoglutarate was also apparent. Mean concentrations found in blood were 0.15 and 0.18 mg./100 ml. for Cases 2 and 3, respectively, compared with a mean control value of 0.08 mg./100 ml. Urinary excretion of α -ketoglutarate by Case 3 was 1.6 mg./kg. 24 hr., compared with a mean control value of 0.49 mg./kg. 24 hr.

Initially, glyoxylate was detected in blood and urine of both cases, but quickly disappeared when 'berolase' was administered, and was not detected subsequently when the children were receiving thiamine orally. An increase in the neutral carbonyl fraction of the blood of Case 3 was due mainly to acetaldehyde, the concentration of which was 5.5 μ g./ml. blood, as estimated with alcohol dehydrogenase. Methyl glyoxal was not detected in either blood or urine.

Succinate and fumarate were barely detectable on chromatography of the citrate cycle acids of blood and urine, while urinary citrate appeared to be excessive. Before lipoate therapy, blood citrate concentration was usually in the low normal range, mean values of 1.4 mg./100 ml. and 1.3 mg./100 ml. being found for Cases 2 and 3, respectively, compared with a mean control value of 2.1 mg./100 ml. During treatment of Case 3 with lipoate, blood citrate concentrations increased to 2.0-2.7 (mean 2.4) mg./100 ml.

In both Cases 2 and 3 the most prominent glycolytic intermediate found in erythrocytes was fructose 6-phosphate (approx. conc. 0.13 mg./ml. cells), which could not be detected in controls. However, estimates

TABLE
Activity of Enzymes in Post-mortem Tissues

Case	Lipoate Transacetylase	Lipoate Dehydrogenase	Diaphorase	Citrate Synthase		Oxaloacetate Carboxylase	Fructose 1, 6-diphosphatase	Phosphofructokinase
	Liver	Liver	Liver	Liver	Brain	Liver	Liver	Muscle
Case 2	1.3	0.23	127	1.2	2.4	13	2.2	0.14
Control	1.0	0.17	155	1.2	3.6	12	2.4	1.25
Units of activity*	μ moles acetyl lipoate formed/hr.	μ moles NADH oxidized/min.	O.D. change of 0.01/min.	μ moles acetyl phosphate used/min.		μ l. CO ₂ produced/min.	μ moles inorganic P released/min.	μ moles fructose diphosphate formed/min.

* Activities refer to g. wet wt. of tissue.

of total ester phosphorus showed no difference between erythrocytes of patients and controls. Measurement of the glycolytic rate in control erythrocytes gave mean values for glucose uptake and lactate production of 4.2 and 6.5 μ moles/ml. cells per hr., respectively, i.e. approximately 80% of the glucose could be accounted for as lactate. In contrast, the production of 3.4 μ moles of lactate by erythrocytes of Case 3 accounted for only 50% of a glucose uptake of 3.3 μ moles/ml. cells per hr.

Thiamine status. When no vitamin supplements were being given, the thiamine concentrations in erythrocytes of Cases 2 and 3 were 7.4 and 11.2 μ g./100 ml. cells, respectively, in agreement with recorded normal values. Thiamine was entirely in the phosphorylated form. At this time urinary excretion of thiamine per 24 hours was 0.55 mg. for Case 2 and 0.04 mg. for Case 3. After receiving 10 mg. thiamine orally, Case 2 excreted 2.66 mg./24 hr. and Case 3 excreted 1.59 mg./24 hr., both values being in the normal range.

In thiamine deficiency the activity of transketolase is depressed, and pronounced activation occurs on addition of thiamine pyrophosphate to tissue extracts. In Case 3 the transketolase activity of erythrocytes was normal, and a normal increase (12%) of activity occurred on adding thiamine pyrophosphate. Transketolase activity was also normal in post-mortem specimens of brain of Case 2.

Tissue studies. Tissues of Case 2 obtained at necropsy 12 hours after death (with intervening refrigeration) were frozen in solid CO₂ and stored at -20° C. Enzymes were assayed after 3 to 6 months of storage. Tissues from cases in which there was no evidence of primary metabolic disease were used as controls.

The activities of several enzymes concerned in the oxidation or general metabolism of pyruvate are given in the Table. Except for phosphofructokinase, for which the activity of muscle was only 11% of the control value, similar values were observed for tissues of Case 2 and controls. Attempts to use homogenates of fresh leucocytes for the assay of the complete pyruvate oxidase system, using pyruvate—C¹⁴ as substrate, were unsuccessful for both Case 3 and controls. Fresh biopsy tissue specimens were not available for investigation.

The coenzyme A activity in the liver of Case 2 was 103 units/g. wet weight, compared with a value of 93 units/g. wet weight for a fresh biopsy specimen obtained in a case of type 1 glycogen storage disease.

Discussion

These sibs are three further examples of the condition first described by Leigh (1951) and called by him 'Sub-acute Necrotising Encephalomyelopathy'. The symptomatology as reviewed by Ebels *et al.* (1965) has been somewhat varied, but certain features have been constantly present. The age of onset of symptoms in 26 of the 32 reported cases has been within the first 2 years of life. In all cases in which clinical features are described, physical weakness, eventually becoming extreme, and reversion to an infantile mentality have been outstanding characteristics. In most there has been marked hypotonia, with either normal reflexes or occasionally extensor or infantile type plantar responses; in a few stiffness or spasticity has been present; tremors, ataxia, and optic atrophy are mentioned in some reports, and bizarre eye movement or nystagmus in others. In many cases gasping or sighing respirations are reported in the late stages of the disease.

The symptomatology and its variations are presumably, and in some reports can be, related to the sites of the pathological process. These have their main location in and around the brain-stem and the pons, the cranial nuclei, the walls of the 3rd and 4th ventricles, the optic tracts, the basal ganglia, the medulla and spinal cord, the posterior nerve roots and, when they have been examined, the peripheral nerves. With three exceptions (Christensen, Melchior, and Plum, 1963; Namiki, 1965; and Case 3 of the present report), the characteristic course of the disease has been a progressive deterioration, with death from respiratory paralysis and

pneumonia within a few months to four years following the onset of symptoms.

Of the total 32 cases now reported, 19 were male, 12 female, and in 1 sex was not stated. 9 children from 4 families were affected and very similar pathological changes were found at necropsy (Feigin and Wolf (1954), Cases 2 and 3; Ebels *et al.* (1965), Cases 1 and 2; Worsley *et al.* (1965), Cases 1 and 2; and the 3 cases in the present report). In 6 additional case reports a total of 8 other sibs, on evidence of varying validity, were reported to have died of a 'similar' or 'very similar' disease (Reye (1960), Case 1; Richter (1957), Case 3; Ule (1959); Ebels *et al.* (1965), Cases 3 and 4 as well as a third sib of Cases 1 and 2; and Tuthill (1960)). Tuthill's report is of twins (zygosity not stated), both seen at 7 months of age, in whom all investigations undertaken were normal. The first twin died of bronchopneumonia 3 days after admission, and showed the typical bilateral symmetrical changes in the brain. The second twin was removed from hospital on the day the first twin died, but he also succumbed. Permission for necropsy was not granted.

The only report of a consanguineous marriage was that of Feigin and Wolf (1954) where the parents were first cousins, as were also the grandparents. This familial incidence is compatible with the affected children being homozygous for a recessive gene.

The symptoms in the three cases in the present report were very similar. Development was apparently normal until, as each child approached the end of the first year, symptoms developed with great rapidity. Cases 1 and 2, both of which had started to take steps and to say a few words, were reduced by hypotonia and by reversion to infantile mentality to complete helplessness within a period of 2 months. There followed a long period of much more gradual deterioration, characterized in both children first, by repeated episodes of vomiting, dehydration, and acidosis, which came on for no obvious reason and went within a few days; secondly, by brief but increasingly frequent episodes of sighing respiration, likened to air-hunger; and thirdly by bouts, sometimes associated with sighing respiration, of bizarre eye-rolling movements. Both these children succumbed, shortly before their 4th birthdays, to bronchopneumonia. In Case 3 the deterioration was, perhaps from onset, somewhat less rapid, but the extreme hypotonia, unexplained bouts of vomiting and dehydration, and the same sighing respiration and eye-rolling movements were all fully in evidence by the age of 2 years. About this time Case 1 died, and necropsy revealed the nature of the

condition enabling rational biochemical investigation and, later, treatment to be undertaken in both Case 2 and Case 3.

Despite certain differences in pathological findings, all previous authors describing infantile subacute necrotizing encephalopathy have stressed its histological similarities to Wernicke's encephalopathy of adults suffering from thiamine deficiency. The present investigations also demonstrate that there is a biochemical similarity between the two conditions, characterized by increased concentrations of pyruvate and lactate in blood. In Cases 2 and 3 there was no significant excess of lactate over pyruvate, as occurs in lactic acidosis resulting from cellular hypoxia (Huckabee, 1961), and all available evidence was contrary to the hyperpyruvaemia occurring as a result of alkalosis following primary hyperventilation.

Detection of the biochemical abnormalities at an early age in Case 3, when clinical signs of deterioration were slight, suggested that the illness was derived from a primary defect directly related to the metabolism of pyruvate. As in thiamine deficiency, a generalized defect in the oxidation of α -keto acids was suggested by the increased concentrations of α -ketoglutarate in the blood of our patients. A further keto acid abnormality, occurring in Cases 2 and 3 before supplementary thiamine was given, was the appearance of glyoxylate in the blood. This has been reported in thiamine-deficient humans (Buckle, 1963) and rats (Liang, 1962a). Glyoxylate is known to inhibit citrate oxidation (Ruffo, Adinolfi, Budillon, and Capobianco, 1962), and it has been suggested that excess citrate in tissues might contribute to the symptoms of thiamine deficiency by complexing with calcium (Gruber and Halbeisen, 1948) or by depressing the metabolism of heart muscle (Yendt, 1957). Before lipoate therapy, blood citrate concentrations in our patients were usually in the lower normal range, in keeping with a diminished rate of entry of pyruvate into the citric acid cycle, but urinary citrate concentrations were usually increased. The significance of the latter finding is not understood; both high and low citrate excretions have been reported in thiamine deficiency. Glyoxylate disappeared promptly from the blood of our patients when supplementary thiamine was given, and was probably derived from excess glycine resulting from the muscle-wasting process (Liang, 1962b). Under these conditions, the availability of thiamine pyrophosphate might become a limiting factor in the oxidation of glyoxylate. To this extent thiamine dependency of certain metabolic reactions might be a secondary feature of the disease, but in none of the reported

cases has there been reason to suspect a nutritional deficiency of thiamine, and no response was observed in those patients who were treated with thiamine. This was confirmed by the absence of any clinical or biochemical effect of thiamine in our patients, for whom thiamine status was normal, as judged not only by the concentration of phosphorylated thiamine in blood, and the recovery of urinary thiamine after a test dose, but also by the normal effect of thiamine pyrophosphate on the transketolase activity of erythrocytes (Brin, 1964).

The successive steps in the oxidation of pyruvate to acetyl-CoA in tissues involve a multi-enzyme complex consisting of at least three enzymes and a number of coenzymes (Fig. 7). In addition to

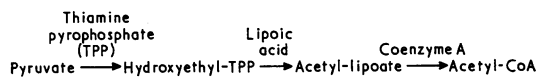


FIG. 7.—Intermediate steps in the oxidation of pyruvate by pyruvate dehydrogenase.

thiamine pyrophosphate, these coenzymes include coenzyme A and α -lipoic acid, for which the maintenance of thiol-disulphide equilibria is a further important factor. Deficiency or abnormal functioning of any constituent part of this system might be expected to give rise to biochemical and clinical features similar to those found in thiamine deficiency.

Therapeutic trials with D-penicillamine and vitamin B₁₂, designed to test the possibility of inactivation of essential thiol groups of pyruvate dehydrogenase, were without effect. Fresh biopsy tissue specimens with which to assay the complete pyruvate dehydrogenase system were not available during these investigations, and attempts to detect respiration in separated leucocytes from controls, using pyruvate—C14, were unsuccessful. However, some information on those enzymes of the dehydrogenase complex for which lipoate is the intermediary, and on other enzymes related to pyruvate metabolism, was obtained using post-mortem tissues. The activities of citrate synthase and oxaloacetate carboxylase ('malic enzyme'), deficiencies of which would depress the further metabolism of pyruvate, were found to be normal, as was the activity of fructose diphosphatase, a specific enzyme effecting reversal of glycolysis. Liver also possessed normal activity of coenzyme A.

The markedly decreased activity of phosphofructokinase in muscle was of interest in view of the decreased amount of lactate produced from a normal glucose uptake by erythrocytes of Case 3, and of the increased concentration of fructose 6—phosphate in erythrocytes of Cases 2 and 3. Phosphofructokinase

is inhibited by a number of intracellular constituents, e.g. phosphoenolpyruvate (Uyeda and Racker, 1965), and appears to be a key regulatory enzyme under conditions of decreased carbohydrate oxidation. Worsley *et al.* (1965) also obtained evidence of accumulation of glycolytic intermediates in erythrocytes of a patient found to have lactic acidosis with necrotizing encephalopathy. While, in their patient, glucose uptake by erythrocytes was lower than that of controls, the over-all production of lactate was increased and was considered to be derived from endogenous substrates. Hartmann, Wohltmann, Purkerson, and Wesley (1962) also observed increased glycolysis in whole blood of a mongol girl, presenting in early infancy with heavy breathing, muscular weakness, and failure to thrive, and found to have lactic acidosis. However, in their case lactate production was accounted for by a corresponding increase in the glucose consumption of blood. These authors postulated that the abnormally rapid glycolysis accounted for the lactic acidosis of their patient, and made further investigations which excluded glycogen storage disease, hypoxia, and thiamine and coenzyme A deficiencies as possible causes.

In the present investigations further interest lay in the role of lipoic acid in pyruvate oxidation. Lipoate participates in a number of reactions mediated by lipoate transacetylase and lipoate dehydrogenase, the activities of which were normal in the liver of Case 2 (Table). However, the further possibilities of a deficiency of lipoate synthesis, of lipoate depletion resulting from its combination with pyruvate, or of abnormal lipoate dependency, suggested the use of lipoate in therapeutic trials in Case 3. Oral administration of lipoate in enteric capsules was followed by considerable clinical improvement which continued until the capsules were being opened before use, whereupon the patient's condition deteriorated rapidly, with the return of bouts of vomiting. When lipoate was next given by intramuscular injection, a marked improvement was apparent after only two weeks.

Clinical improvements seen included the cessation of attacks of vomiting and acidosis, the patient once again was able to swallow solid food, and she no longer rolled her eyes or had bouts of sighing respiration. In addition, she became happy and cheerful, in striking contrast to her rather irritable nature previously.

It was assumed that lipoate in a dosage of 10 mg. twice weekly was the cause of the increased serum transaminase activity found after six months of treatment in Case 3. Gal and Rzevska (1960) demonstrated toxic effects of lipoate in thiamine-

deficient rats, and Wirtschafter and Smith (1962) observed dosage-dependent liver damage in normal rats. Transaminase levels returned to normal when the high dosage of lipoate was discontinued, and remained at normal values during treatment with 5 mg. twice weekly for 16 months. During this time the patient showed no deterioration until one month before she died, though physical improvement was minimal. She showed more comprehension and became clean by day.

Accompanying the general clinical improvement, evidence of a biochemical response to lipoate was suggested by the slow but continuous decrease of pyruvate concentration and the increase of citrate concentration in the blood. The decrease in pyruvate concentration could be detected only by enzymatic assay, the apparent concentration estimated as the dinitrophenylhydrazone returning to a high value after showing an initial fall. The reason for this difference is not clear. It could not be accounted for as pyruvate derived from the decomposition of oxaloacetate, nor as hydroxypyruvate, but may have been due to an unidentified keto-compound which was detected on chromatograms during lipoate therapy.

A primary state of lipoate deficiency or of abnormal lipoate dependency has not been described, but the specific role of α -lipoic acid in the oxidation of α -keto acids has prompted its use, with variable results, in a number of hyperpyruvaemic neuropathies. The biochemical lesion responsible for the hyperpyruvaemia in the cases presented here has not been defined, but the clinical and biochemical effects observed after lipoate administration were considered to be encouraging in view of the age of the patient and the advanced state of the disease when treatment was begun. It would be of considerable interest to determine the effect of lipoate in cases where an early diagnosis was made.

The disease is apparently very rare, and the clinical picture by no means pathognomonic. However, we suggest that there are now sufficient case histories, as summarized in the clinical section, upon which to build a fairly likely onset and early course of the disease in most cases. We consider that the findings described in this paper of high blood pyruvate levels will, if confirmed, not only make a presumptive diagnosis possible in a difficult case of a degenerative condition affecting the CNS, in which all other laboratory and special investigations have proved negative, but may also enable the biochemical abnormality to be detected before the development of symptoms in affected younger sibs of cases in which the disease is discovered at necropsy.

Summary

The clinical course of three sibs with subacute necrotizing encephalomyelopathy is described.

Biochemical studies undertaken in two of the patients demonstrated a hyperpyruvaemia, though the defect responsible was not defined.

It is suggested that the finding of a raised blood pyruvate level in a child with a suggestive history, or in a sib of a previously known case, would be presumptive evidence of the presence of the disease.

A clinical trial of lipoate administration in the youngest sib gave encouraging results. The hyperpyruvaemia was reduced and, for a considerable time, clinical improvement was shown, particularly by the cessation of vomiting attacks, eye-rolling movements, and sighing respiration. It is suggested that it would be of considerable interest to administer lipoate to a patient in whom diagnosis was made at an early stage of the disease.

The pattern of the familial incidence in cases so far reported is compatible with a mode of inheritance through a single autosomal recessive gene.

We wish to thank Mr. A. E. Whitfield for skilled technical assistance. We are indebted to the nursing staff at Queen Elizabeth Hospital, The Hospital for Sick Children, and Cheyne Hospital for all their help with the investigations, to the staff of the Departments of Medical Illustration at Queen Elizabeth Hospital and The Hospital for Sick Children for the photographs, and to the Nuffield Foundation for financial support.

Appendix

Biochemical methods. Blood pyruvate was estimated either by the colorimetric method of Friedemann and Haugen (1943) or with lactate dehydrogenase and NADH. Before treatment with lipoate, the pyruvate abnormality was always prominent when tested in the fasting state, and little further information was gained from tests following a glucose load, which often resulted in vomiting. Blood pyruvate values, therefore, refer to random specimens usually taken about 1 hour after a meal. Upper normal values obtained by the colorimetric and enzymatic methods were 1.40 and 1.00 mg./100 ml., respectively. Urinary pyruvate was estimated by the colorimetric method after treatment of acidified urine with Fuller's Earth. Blood lactate was estimated either by the method of Ryan (1958), or with lactate dehydrogenase and NAD. Upper normal concentration was approximately 16 mg./100 ml. Citrate was estimated by the method of McArdle (1955).

Chromatography of dinitrophenylhydrazones of α -keto acids of blood and urine, and the estimation of α -ketoglutarate, were carried out according to McArdle (1957). Dinitrophenylhydrazones of neutral carbonyl compounds were chromatographed in the solvent system of Meigh (1952). The methods of Lugg and Overell (1948) were used for chromatography of non-volatile

APPENDIX TABLE
 Biochemical and Other Special Investigations

Investigations	Case 1	Case 2	Case 3
<i>Urine</i>			
Concentration s.g.	1020-1039	Up to 1030	—
pH	5·2	5·6	5·3
Albumin	Nil	Occasional trace	Occasional trace
Sugar	Nil	Occasional fructose	Occasional fructose
Cells	Nil	Transient urinary infection	5 per high-power field
Deposit	Nil abnormal	Transient urinary infection	Nil abnormal
Amino acids	Normal in amount and pattern	Normal in amount and pattern	Normal pattern
Phenyl ketones	Absent	Absent	Absent
Creatine coefficient	11·9	—	—
Phosphoethanolamine	None detected several occasions	None detected 2 occasions	—
<i>Blood</i>			
Hb %; WBC; differential	76-80%; 3500-10,000; normal	80%; up to 12,000; normal	76-81%; 11,100; normal
Urea (mg./100 ml.)	23-36	39	35
Sugar (mg./100 ml.)	111	94	87
Proteins; total (g./100 ml. plasma)	7·9	7·8	6·9
Albumin (g./100 ml. plasma)	5·6	5·2	—
Calcium (mg./100 ml. plasma)	9·9-11·9 (5 occasions)	8·9-10·2 (4 occasions)	10·1
Phosphorus (mg./100 ml. plasma)	4·7-6·5	3·4-4·5 (3 occasions)	5·1
Alkaline phosphatase (KA units/100 ml. plasma)	6·6-11 (6 occasions)	5·7·1 (3 occasions)	11
Electrolytes	Normal except at vomiting bouts	Normal except at vomiting bouts	Frequent bouts of acidosis
Cholesterol (mg./100 ml. serum)	210	171	—
Pyruvate (mg./100 ml.) (see text)	—	—	2·5 (at age 10 months)
Creatine phosphokinase	—	—	Normal
<i>CSF</i>			
Protein (mg./100 ml.)	70	Normal	—
Cells (c.mm.)	60 at onset; normal later	Normal	—
Sugar (mg./100 ml.)	Within normal limits	Normal	—
<i>Miscellaneous</i>			
Bone-age	15/12-18/12 at 27/12 years old	6/12 at 13/12 years old	1 year at 1 year old
EEG	Within normal limits for age	—	—
Brain biopsy	Evidence of underlying abnormality of white matter	—	—
Electromyogram	'Denervating process probably of peripheral nerves'	'Consistent with peripheral neuropathy'	—
Muscle biopsy	—	Histologically normal	—
Liver biopsy	—	Histologically normal	—
Spleen biopsy	—	Histologically normal	—

organic acids in ether extracts of acidified urine and plasma.

The phosphorylated thiamine content of blood was assayed by the method of Burch, Bessey, Love, and Lowry (1952), and urinary thiamine by the method of Johnson, Sargent, Robinson, and Consolazio (1945). Transketolase activity of blood was assayed according to Dreyfus (1962) and that of brain according to Dreyfus and Moniz (1962). Phosphorylated intermediates in erythrocytes were analysed by the methods of Le Page (1951). Glucose uptake and lactate production by erythrocytes were estimated using the incubation conditions of Grimes (1963).

Methods of assay of enzymes in necropsy tissues were as follows: citrate synthase (Ochoa, Stern, and Schneider, 1951); lipoate transacetylase (Brady and Stadtman, 1954); lipoate dehydrogenase (Massey, Gibson, and Veeger, 1960); diaphorase (Savage, 1957); oxaloacetate

carboxylase (Mehler, Kornberg, Grisolia, and Ochoa, 1948); fructose 1, 6-diphosphatase (Pogell and McGilvery, 1952); phosphofructokinase (Ling, Byrne, and Lardy, 1955). Coenzyme A was estimated by the method of Kaplan and Lipmann (1948).

REFERENCES

- Brady, R. O., and Stadtman, E. R. (1954). Enzymatic thiol-transacetylation. *J. biol. Chem.*, **211**, 621.
- Brin, M. (1964). Erythrocyte as a biopsy tissue for functional evaluation of thiamine adequacy. *J. Amer. med. Ass.*, **187**, 762.
- Buckle, R. M. (1963). The glyoxylic acid content of human blood and its relationship to thiamine deficiency. *Clin. Sci.*, **25**, 207.
- Burch, H. B., Bessey, O. A., Love, R. H., and Lowry, O. H. (1952). The determination of thiamine and thiamine phosphates in small quantities of blood and blood cells. *J. biol. Chem.*, **198**, 477.
- Christensen, E., Melchior, J. C., and Plum, P. (1963). Infantile chronic necrotizing encephalopathy. *Acta paediat. (Uppsala)*, **52**, 304.

- Claireaux, A. E., Crome, L., Dayan, A. D., and Ockenden, B. (1967). In preparation.
- Dreyfus, P. M. (1962). Clinical application of blood transketolase determinations. *New Engl. J. Med.*, **267**, 596.
- , and Moniz, R. (1962). The quantitative histochemical estimation of transketolase in the nervous system of the rat. *Biochim. biophys. Acta (Amst.)*, **65**, 181.
- Ebels, E. J., Blokzijl, E. J., and Troelstra, J. A. (1965). A Wernicke-like encephalomyelopathy in children (Leigh), an inborn error of metabolism? *Helv. paediat. Acta*, **20**, 310.
- Feigin, I., and Wolf, A. (1954). A disease in infants resembling chronic Wernicke's encephalopathy. *J. Pediat.*, **45**, 243.
- Friedemann, T. E., and Haugen, G. E. (1943). Pyruvic acid: the determination of keto acids in blood and urine. *J. biol. Chem.*, **147**, 415.
- Gal, E. M., and Razevska, D. E. (1960). Studies on the *in vivo* metabolism of lipoic acid. I. The fate of DL-lipoic acid—S35 in normal and thiamine-deficient rats. *Arch. Biochem.*, **89**, 253.
- Grimes, A. J. (1963). Glycolysis in young and mature normal human erythrocytes. *Nature (Lond.)*, **198**, 1312.
- Gruber, C. M., Jr., and Halbeisen, W. A. (1948). Study on the comparative toxic effects of citric acid and its sodium salts. *J. Pharmacol. exp. Ther.*, **94**, 65.
- Hartmann, A. F., Jr., Wohltmann, H. J., Purkerson, M. L., and Wesley, M. E. (1962). Lactate metabolism. Studies of a child with serious congenital deviation. *J. Pediat.*, **61**, 165.
- Huckabee, W. E. (1961). Abnormal resting blood lactate. *Amer. J. Med.*, **30**, 833 and 840.
- Johnson, R. E., Sargent, F., Robinson, P. F., and Consolazio, F. C. (1945). Estimation of riboflavin, thiamine, and N-methyl nicotinamide. *Ind. Engng Chem. analyt. Edn*, **17**, 384.
- Kaplan, N. O., and Lipmann, F. (1948). The assay and distribution of coenzyme A. *J. biol. Chem.*, **174**, 37.
- Le Page, G. A. (1951). In *Manometric Techniques and Tissue Metabolism*, ed. W. W. Umbreit, p. 185. Burgess Publishing Co., Minneapolis.
- Leigh, D. (1951). Subacute necrotizing encephalomyelopathy in an infant. *J. Neurol. Neurosurg. Psychiat.*, **14**, 216.
- Liang, C.-C. (1962a). Studies on experimental thiamine deficiency. Trends of keto acid formation and detection of glyoxylic acid. *Biochem. J.*, **82**, 429.
- (1962b). Studies on experimental thiamine deficiency. II. Tissue breakdown and glyoxylic acid formation. *ibid.*, **83**, 101.
- Ling, K.-H., Byrne, W. L., and Lardy, H. (1955). Phosphohexokinase. *Meth. Enzymol.*, **1**, 306.
- Lugg, J. W. H., and Overell, B. T. (1948). One- and two-dimensional partition chromatographic separations of organic acids on an inert sheet support. *Aust. J. sci. Res., A*, **1**, 98.
- McArdle, B. (1955). A modified method for the microdetermination of citric acid. *Biochem. J.*, **60**, 647.
- (1957). The quantitative estimation of pyruvic and α -oxoglutaric acids by paper chromatography in blood, urine and cerebrospinal fluid. *ibid.*, **66**, 144.
- Massey, V., Gibson, Q. H., and Veeger, C. (1960). Intermediates in the catalytic action of lipoyl dehydrogenase (diaphorase). *ibid.*, **77**, 341.
- Mehler, A. H., Kornberg, A., Grisolia, S., and Ochoa, S. (1948). The enzymatic mechanism of oxidation-reductions between malate or isocitrate and pyruvate. *J. biol. Chem.*, **174**, 961.
- Meigh, D. F. (1952). Separation of the 2, 4-dinitrophenylhydrazones of volatile aldehydes and ketones by paper chromatography. *Nature (Lond.)*, **170**, 579.
- Namiki, H. (1965). Subacute necrotizing encephalomyelopathy. *Arch. Neurol. (Chic.)*, **12**, 98.
- Ochoa, S., Stern, J. R., and Schneider, M. C. (1951). Enzymatic synthesis of citric acid. II. Crystalline condensing enzyme. *J. biol. Chem.*, **193**, 691.
- Pogell, B. M., and McGilvery, R. W. (1952). The proteolytic activation of fructose-1, 6-diphosphatase. *ibid.*, **197**, 293.
- Reye, R. D. K. (1960). Subacute necrotizing encephalomyelopathy. *J. Path. Bact.*, **79**, 165.
- Richter, R. B. (1957). Infantile subacute necrotizing encephalopathy with predilection for the brain stem. *J. Neuropath. exp. Neurol.*, **16**, 281.
- Ruffo, A., Adinolfi, A., Budillon, G., and Capobianco, G. (1962). Control of the citric acid cycle by glyoxylate. II. Mechanism of the inhibition of respiration in liver and kidney particles. *Biochem. J.*, **85**, 593.
- Ryan, H. (1958). An improved microdiffusion procedure for the determination of lactic acid. *Analyst*, **83**, 528.
- Savage, N. (1957). Preparation and properties of highly purified diaphorase. *Biochem. J.*, **67**, 146.
- Tuthill, C. R. (1960). Der morphologische Wernicke-Komplex in frühem Kindesalter. *Arch. Psychiat. Nervenkr.*, **200**, 520.
- Ule, G. (1959). Über eine der Wernickeschen Pseudoencephalitis entsprechende Encephalopathie bei Kindern. *Virchows Arch. path. Anat.*, **332**, 204.
- Uyeda, K., and Racker, E. (1965). Regulatory mechanisms in carbohydrate metabolism. VII. Hexokinase and phosphofruktokinase. *J. biol. Chem.*, **240**, 4682.
- Wirtschafter, Z. T., and Smith, F. W. (1962). Effect of lipoic acid on the normal rat liver. *J. Lab. clin. Med.*, **60**, 649.
- Worsley, H. E., Brookfield, R. W., Elwood, J. S., Noble, R. L., and Taylor, W. H. (1965). Lactic acidosis with necrotizing encephalopathy in two sibs. *Arch. Dis. Childh.*, **40**, 492.
- Yendt, E. R. (1957). Citrate intoxication. *Canad. med. Ass. J.*, **76**, 141.