

Retinal Photography in the Newborn

C. J. BULPITT and J. D. BAUM

From M.R.C. Clinical Pharmacology Research Group, Department of Medicine, Royal Postgraduate Medical School, and Neonatal Research Unit, Institute of Child Health, Hammersmith Hospital, London

Several pathological changes affect the eyes of newborn infants, one of the most important of which is retrolental fibroplasia. The object of developing retinal photography in the newborn was to record the appearance of blood vessels in premature infants who are at risk of developing retrolental fibroplasia. In addition it has proved possible to record the normal appearance of the newborn fundus at varying gestational ages and the patterns of retinal haemorrhage, and to detect changes in the calibre of vessels in response to changing levels of arterial oxygen tension. In this paper we describe the method used, and some of the findings in the normal newborn fundus.

Material and Method

The baby is fed half an hour before photography and one drop of 0.5% cyclopentolate hydrochloride is instilled into each eye. Sedative drugs have not been required. The infant is placed on a trolley in a warm neonatal ward. Normal clothing is adequate for babies being nursed in a cot. For the small or sick newborn who require incubator therapy, a 'silver swaddler' (Baum and Scopes, 1968) is used to prevent heat loss. The greatest fall in rectal temperature over a period of an hour's photography has been 0.5 °C. As a rule, however, photography has been completed in 5 or 10 minutes. Once in position on the trolley, a vertically-mounted Carl Zeiss fundus camera is wheeled into position. One team member holds the infant's head with the eyelids gently opened. He rotates the head to enable different views of the retina to be obtained. The other team member is free for photography (Fig. 1).

We have used the hand-held Kowa fundus camera but abandoned this technique in favour of the mounted Zeiss camera which is easier to manipulate and produces photographs of better definition. However, securing retinal photographs of reasonable quality in the newborn is hampered by certain difficulties.

(1) The tunica vasculosa lentis or pupillary membrane is present up to about 32 weeks of gestation (Gans, 1959) and prevents photography of the retina (Fig. 2). (2) After 32 weeks clarity may be obscured by pupillary membrane remnants or immaturity and haziness of the

vitreous. (3) The viewing light beam is 8 mm. wide and small deep-set eyes are difficult to illuminate, as this beam may be partially obstructed by the eyelids. (4) There may be inadequate midriasis in infants with a pigmented iris at birth, usually those of African or Asiatic origin, and these may require further doses of cyclopentolate hydrochloride. (5) Closure of the eyelids every few seconds helps maintain the cornea moist and clear. In addition installation of sterile normal saline drops is advisable to prevent any temporary clouding of the cornea. (6) The amount of eye movement varies from baby to baby and with the level of consciousness. Larger infants are more troublesome in this respect especially when crying and may require refeeding and much patience. (7) In infants who forcibly close their eyes, or who have puffy eyelids, attempts to overcome contraction of the orbicularis oculis may merely evert the tarsal plates. In this situation eyelid retractors have proved helpful (Fig. 3). (8) If the infant fixes on the viewing light, rotating the head or closing the eyelids will usually allow photography of areas other than the macula.

Results

The retina in the newborn differs in appearance from that of the adult in a number of respects.

- (1) In the more immature eye one may see the pupillary membrane (Fig. 4) or remnants of the hyaloid system of vessels persisting as Bergemeister's papilla at the disc (Fig. 5).
- (2) Up to 36 weeks' gestation the vasculature of the retina is still proliferating and is incomplete at the periphery. On ophthalmoscopy this avascular peripheral zone may be seen as a grey band into which the vessels are growing. We have not as yet been able to photograph beyond the equator of the orbit with any clarity.
- (3) There is a relative absence of choroidal pigmentation in Caucasian infants, leaving the choroidal circulation clearly visible (Fig. 6). In coloured infants, however, the choroid is deeply pigmented by 32 weeks' gestation (Fig. 5).

Received March 3, 1969.




FIG. 1.—Photographing the retina in a premature infant.

- (4) In the premature infant the optic disc commonly appears grey. This may be related to the incomplete myelination of the optic nerve proximal to the lamina cribrosa.
- (5) The physiological cup and lamina cribrosa are frequently not visible in the premature fundus. They appear from about 36 weeks onwards with the atrophy of Bergemeister's papilla.

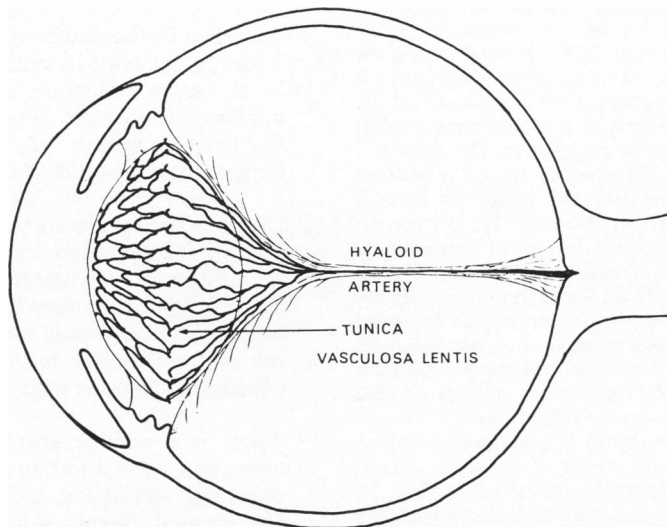


FIG. 2.—Diagrammatic representation of the hyaloid artery and tunica vasculosa lentis (pupillary membrane), at about 28 weeks of gestation.

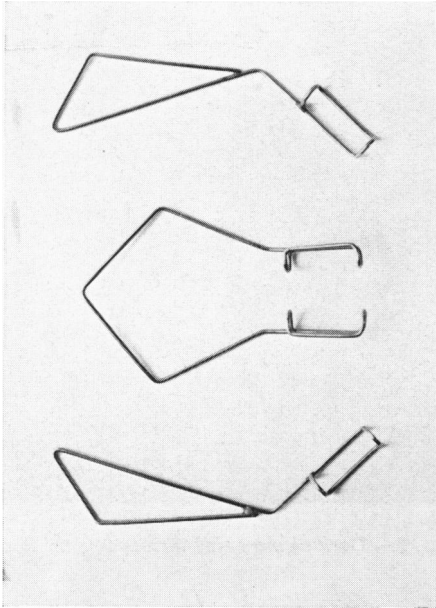


FIG. 3.—*Eyelid retractors.*

- (6) The foveal pit is not a feature of the immature eye. It appears from about 40 weeks' gestation.
- (7) The disc commonly appears oval or elliptical in outline, which is due to astigmatism of the immature cornea (Fig. 5).

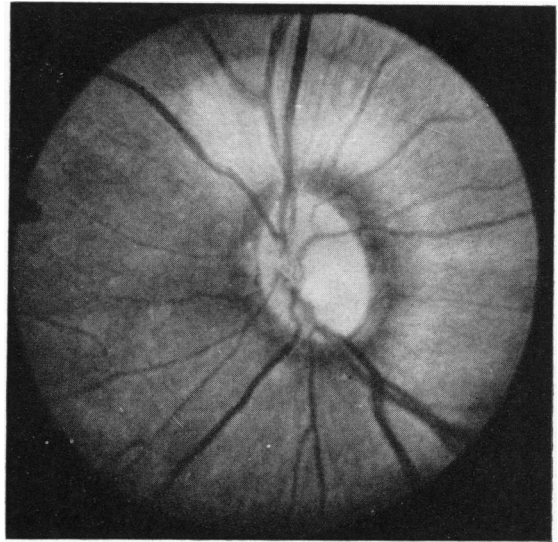


FIG. 5.—*Pigmented choroid in a coloured infant of 32 weeks' gestation.*

- (8) An extremely common finding in the newborn is a dark ring surrounding the optic disc (Fig. 7). This pigment ring has not attracted much attention in the past and may be due to migrating choroidal pigment. Fluorescein studies have shown the retinal vascular bed to be normal near the disc, indicating that the pigment, which is in any case deficient elsewhere in the

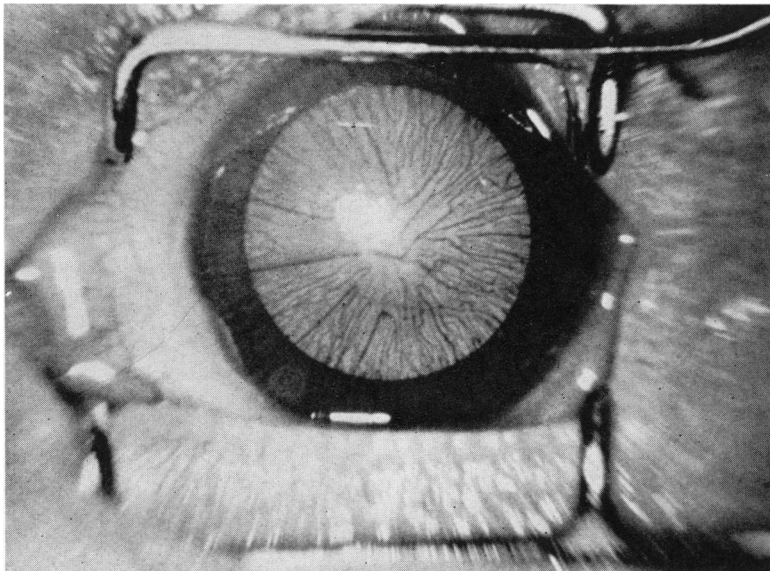


FIG. 4.—*Pupillary membrane in a premature infant of 29 weeks' gestation.*

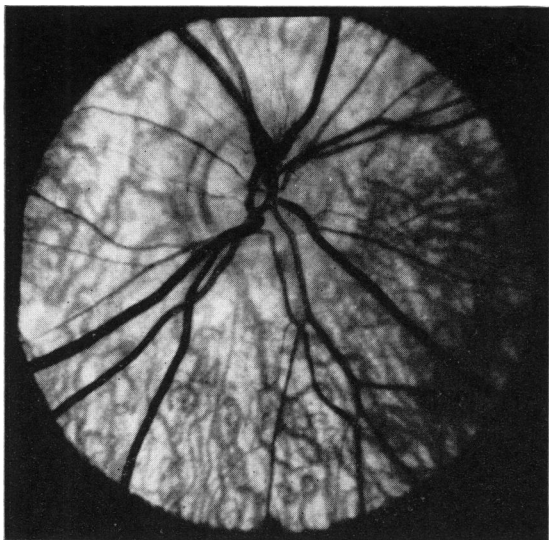


FIG. 6.—Absence of pigment leaving the choroidal circulation clearly visible in an infant of 34 weeks' gestation.

choroid neonatally, is not abnormally visible simply due to a locally thin retinal bed.

- (9) Multiple retinal haemorrhage is a common finding in the newborn (Critchley, 1968). These haemorrhages show a great diversity of form (Fig. 7, 8, and 9).

Conclusion

The normal appearance of the retina in the new-

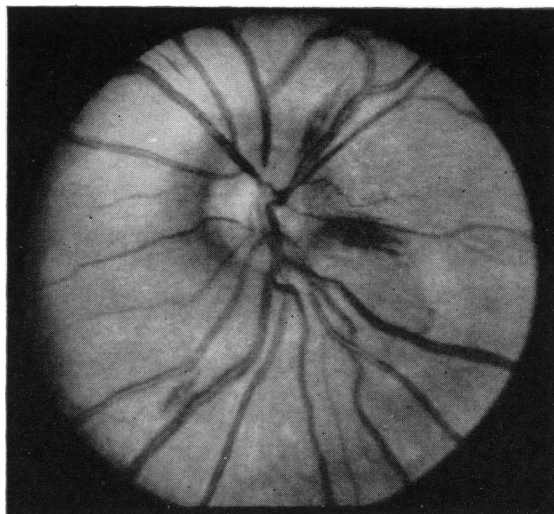


FIG. 7.—Dark pigment ring surrounding the disc.

born differs in a number of respects from the adult. In addition haemorrhage is a common finding in otherwise normal newborn infants, presumably the result of inevitable birth trauma.

The ability to photograph the neonatal retina with reasonable definition makes it possible to study serially changing retinal appearances, to measure retinal vascular responses to alterations in arterial oxygen tension, and to perform fluorescein studies

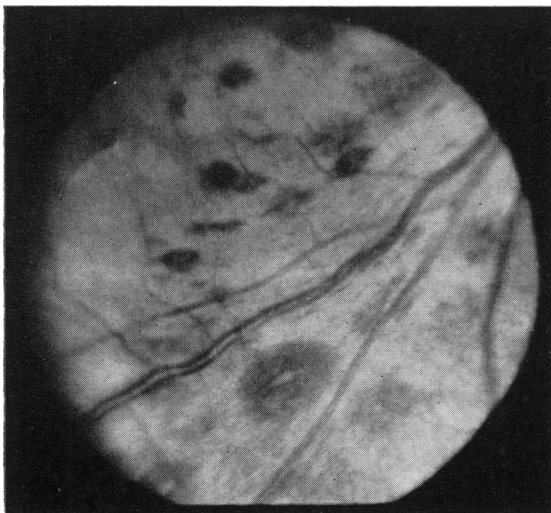


FIG. 8.—Flame-shaped haemorrhages.

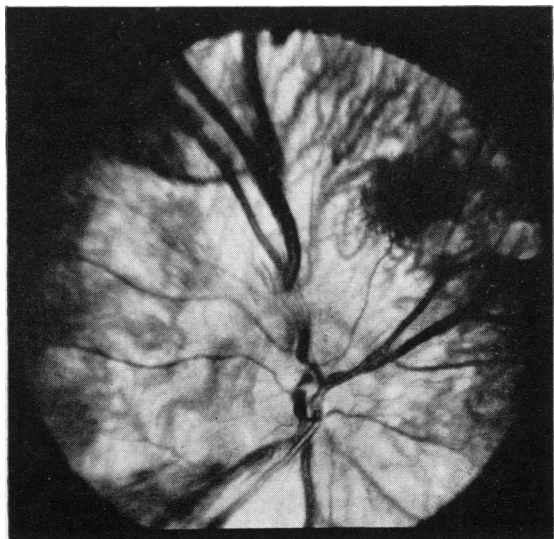


FIG. 9.—Venous engorgement with extensive lake haemorrhages.

to define the anatomy and physiology of this maturing microcirculation.

Summary

A method is described for taking retinal photographs in newborn infants. The difficulties include keeping the infant warm, holding the eyes open, and securing clear photographs of selected areas of the retina. The common findings in the normal and premature eye are discussed, in particular the remnants of the hyaloid system of vessels, the grey disc, the non-pigmented choroid, and retinal birth haemorrhages.

We would like to thank Professor C. T. Dollery and Professor J. P. M. Tizard for their advice and

guidance with this work. These studies were supported by grants from the Medical Research Council (to C. J. B.) and the Percy J. Neate Research Fellowship of the Clothworkers Company (to J. D. B.), and we are grateful for facilities provided by the Sir William Coxon Trust Fund.

REFERENCES

- Baum, J. D., and Scopes, J. W. (1968). The silver swaddler. Device for preventing hypothermia in the newborn. *Lancet*, **1**, 672.
- Critchley, E. M. R. (1968). Observations on retinal haemorrhages in the newborn. *J. Neurol. Neurosurg. Psychiat.*, **31**, 259.
- Gans, B. (1959). The pupillary membrane in premature infants. *Arch. Dis. Childh.*, **34**, 292.

Correspondence to Dr. J. D. Baum, Dept. of Paediatrics, Hammersmith Hospital, Du Cane Road, Shepherds Bush, London W.12.