

Central Pontine Myelinolysis in Childhood and Adolescence*

THOMAS E. CADMAN and LUCY BALIAN RORKE

From the Departments of Neurology and Pathologic Anatomy, The Children's Hospital of Philadelphia; and the Departments of Pediatric Pathology and Neuropathology, Philadelphia General Hospital, Philadelphia, U.S.A.

Central pontine myelinolysis, a pathological entity first described by Adams, Victor, and Mancall in 1959, is characterized by destruction of myelin sheaths in the central portion of the basis pontis, with relative sparing of both axis cylinders and neurones. Oligodendroglia are decreased in number or absent, and foamy macrophages accumulate in the involved area. Though the disorder may be suspected clinically, a diagnosis can be made only at necropsy.

About 70 cases of central pontine myelinolysis have been reported (Adams, 1962; Adams *et al.*, 1959; Aleu and Terry, 1963; Chason, Landers, and Gonzalez, 1964; Ito, Hasegawa, and Uchida, 1965; Kepes, Reece, and Oxley, 1965; Lopez and Collins, 1968; Mathieson and Olszewski, 1960; Matsuoka *et al.*, 1965; McCormick and Danneel, 1967; Nakamura *et al.*, 1966; Nishiyama, 1965; Rosman, Kakulas, and Richardson, 1966; Schneck, 1966; Shiraki, Ilzuka, and Seitelberger, 1963), of which 11 have occurred in childhood or adolescence (Table). The disease, however, may be more common in children than these reports suggest, since, in the past 3 years, we have observed the following 4 additional cases in patients aged 3, 3½, 4½, and 15 years.

Case Reports

Case 1. A 20-month-old girl was admitted to hospital with a three-week history of fever, fatigue, and irritability. Examination showed a pale infant weighing 11 kg. Her liver and spleen were moderately enlarged. A diagnosis of acute myelogenous leukaemia was made by bone-marrow examination, and treatment included prednisone, vincristine, mercaptopurine, and transfusions of platelets and packed cells.

Received October 14, 1968.

* This study was supported by the National Institute of Neurological Diseases and Blindness Training Grant No. 2 TI NB 5260-09, NINDB Special Fellowship 2F11 NB 1481-03 (Dr. Cadman) and NINDB Research Grant 5 R01 NB 03889-06 NEUA (Dr. Rorke).

The patient did fairly well until one year later when she was readmitted because of persistent fever. The liver was enlarged, but the spleen was not palpable. Neurological examination was normal. The course of the disease was complicated by increasing jaundice, anaemia, cardiac failure, and chronic diarrhoea. Oral intake proved inadequate, and intravenous fluids were given, but no vitamin supplements were administered.

Potassium and calcium values were below normal (K 2.8 to 3.6 mEq/l. and Ca 7.7 to 8.6 mg./100 ml.) on several occasions, despite oral and intravenous supplementation. Finally, she developed left-sided motor seizures, but without localizing neurological residua, and then coma. She died aged 3 years. A spinal tap on the day of death gave a normal pressure, 7 WBC and 5 RBC/cu.mm., and a protein of 53 mg./100 ml.

Drugs included multiple antibiotics in addition to methotrexate, leucovorin, cytosine arabinoside, mercaptopurine, hydrocortisone, prednisone, digitalis, and phenobarbitone.

Necropsy. The body was that of a dehydrated girl weighing 13 kg.; there was no evidence of leukaemia. Signs of congestive heart failure were present, and the lungs showed an acute bronchopneumonia. Haemosiderin deposits were present in the liver, spleen, lymph nodes, bone-marrow, and lungs. There was mesenteric adenitis due to cryptococcal infection.

The *brain* was slightly atrophic. There was dilatation of the lateral ventricles and congestion of deep vessels. Transverse section through the mid-pons at the exit of the fifth nerve root showed a 1.2 × 1 cm. grey, translucent area located in midline of the dorsal basis pontis (Fig. 1). Microscopically there was demyelination of nerve fibres with preservation of neurones. A few oligodendroglia were found, but foamy macrophages were not conspicuous.

Case 2. A 3½-year-old girl with marked obesity from the age of 17 months was initially evaluated as a hospital outpatient. No organic disease was found, and a dietary regimen was recommended. She lost 6 kg. in three weeks, during which she received a diet consisting of non-caloric beverages and two multiple vitamin tablets daily. At the end of this period she

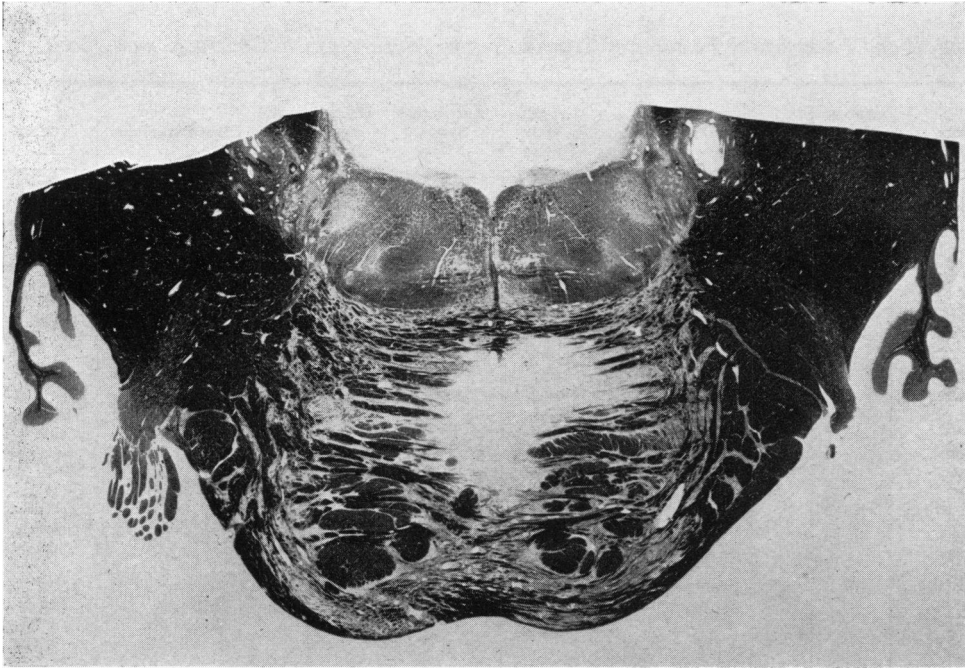


FIG. 1.—Case 1. Transverse section pons, showing asymmetrical midline focus of myelinolysis in dorsal basis pontis. Note sparing of corticospinal tracts and absence of involvement of tegmentum. (Luxol Fast Blue-Cresyl Violet Stain. $\times 3.5$.)

was referred to this hospital because of poor intake and drowsiness.

She was semi-comatose, dehydrated, and in moderate respiratory distress. Weight was 28 kg. (over the 97th centile), and height was 102 cm. (75th centile). The liver was moderately enlarged. Significant neurological findings included generalized hyperreflexia, a left Babinski sign, and bilateral ankle clonus.

The following laboratory studies were normal: Hb, serum electrolytes, thymol turbidity, alkaline phosphatase, and proteins. Blood pH was 7.31, serum glutamic oxalacetic transaminase 170 units, and cephalin flocculation 3+ in 24 hours. Skull and chest x-rays were normal. EEG showed excessive low voltage fast activity. She received intravenous fluids during the first 36 hours, at the end of which time she was alert and oriented. She was then given a regular diet for 10 days, followed by a 500-calorie diet without vitamin supplement. Her intake was good after the initial 2 days of oral feedings.

After 22 days in the hospital, she seemed generally improved and was discharged, but was readmitted 2 days later because of respiratory distress. During the next 7 days her level of consciousness varied considerably. The neurological examination was otherwise normal. A positive pressure respirator was used to provide adequate ventilation. Antibiotics, including methicillin and ampicillin, were given, and hydration was

maintained with parenteral fluids without vitamin supplementation. She died aged 3½ years.

Necropsy. The body was that of an extremely obese child with abdominal striae and peripheral oedema. There was immense dilatation of the vena cava, and a premortem thrombus, firmly fixed to the endocardial surface of the right atrium, extended through the tricuspid valve into the right ventricle. The lungs showed multiple infarctions and scattered areas of pneumonia. Marked hepatomegaly with fatty dystrophy was present. There were recent splenic infarctions without splenomegaly and scattered foci of cortical necrosis in the kidneys.

The brain weighed 1252 g. Except for generalized convolitional atrophy associated with passive ventricular dilatation, there were no obvious gross abnormalities. Significant microscopic findings were limited to the pons at the level of the exit of the fifth nerve roots. A rectangular area of myelinolysis of about 2×1 cm. was localized to the midline area of the basis pontis just ventral to the tegmentum. There was loss of myelin sheaths, but the axis cylinders and neurones were well preserved. Large numbers of foamy macrophages were found, but oligodendroglia were inconspicuous, and astrocytic proliferation was not present.

Case 3. A 4½-year-old girl, who had had a bleeding disorder since the age of 14 months, was admitted to

TABLE

Clinical and Pathological Features of Central Pontine Myelinolysis in Childhood and Adolescence

Authors	Age at Death (yr.)	Sex	Clinical Diagnoses	Length of Illness	Nutritional Status	Dehydration Electrolyte Imbalance	Liver Pathology	Neuropathology
Mathieson and Olszewski (1960)	9	M	Mumps with CNS sequelae	9 wk.	Poor	Dehydration	No abnormalities reported	(1) CPM*—dorsal part of basis pontis (1.2 × 0.4 cm.) (2) Area of demyelination in the cerebellum and symmetrical necrosis of the striatum
Adams (1962)	7	M	Volvulus; malrotation of colon	5 yr.	Poor	Both	No abnormalities reported	(1) CPM—extensive lesion with almost total destruction of basis pontis (1.2 × 0.9 cm.) (2) Anoxic changes in cerebrum and cerebellum
Kepes <i>et al.</i> (1965)	7	M	Cranio-pharyngioma	7 mth.	Not listed	Both	No abnormalities reported; clinically jaundiced	(1) CPM—lesion involving basis pontis and part of tegmentum (greatest diameter 1.5 cm.)
Ito <i>et al.</i> (1965)	15	F	Generalized muscular atrophy—cause?	17 mth.	Poor	Electrolyte imbalance	No abnormalities noted	(1) CPM—medial area of basis pontis (2) Oedema of brain
Matsuoka <i>et al.</i> (1965)	12	M	Cranio-pharyngioma	11 mth.	Not listed	Neither	Necropsy confined to brain	(1) CPM—almost entire basis pontis (2) Craniopharyngioma (partially removed)
Matsuoka <i>et al.</i> (1965)	15	F	Wilson's disease	1 yr.	Good	Neither	Cirrhosis	(1) Small foci CPM—rostral and middle basis pontis (2) Brain-stem haemorrhages (3) Atrophy of putamen
Nishiyama (1965)	13	M	Wilson's disease	8 mth.	Not listed	Not listed	Cirrhosis	(1) CPM (2) CNS changes of Wilson's disease
Rosman <i>et al.</i> (1966)	7	M	Acute lymphoblastic leukaemia	7 mth.	Good	Neither	Increased portal fibrous tissue; necrosis of periportal liver cells; infiltration with lymphs and plasma cells; bile pigment in canaliculi; iron in Kupffer cells	(1) CPM—median raphe between corticospinal tracts (5 × 3 mm.) (2) Old haemorrhages in remainder of brain

TABLE—continued

Authors	Age at Death (yr.)	Sex	Clinical Diagnoses	Length of Illness	Nutritional Status	Dehydration Electrolyte Imbalance	Liver Pathology	Neuropathology
Schneck (1966)	16	M	Chronic renal disease (kidney transplant 95 days before death)	7 mth.	Poor	Electrolyte imbalance	No abnormalities noted	(1) CPM—central basis pontis (3 × 3 mm.) (2) Glial nodules in cerebral white matter, putamen, thalamus, cerebellum, and pons
Lopez and Collins (1968)	12	F	Chronic glomerulonephritis (renal transplant 50 days before death)	5½ mth.	Poor	Electrolyte imbalance	Focal areas of centrilobular parenchymal necrosis; eosinophilic bodies in liver sinusoids	(1) CPM—upper and mid basis pontis (2) Wernicke's encephalopathy
Nakamura <i>et al.</i> (1966)	15	F	Pyramidal tract disease	2 yr.	Poor	Dehydration	Fatty infiltration	(1) CPM—basis pontis (2) Occlusion right anterior cerebral artery (3) Corticospinal tract degeneration
Present cases								
1	3	F	Acute myelogenous leukaemia	17 mth.	Fair	Both	Haemosiderin deposits	(1) CPM—mid-pons at level of exit of fifth nerve (1.2 × 1 cm.) (2) Dilatation of lateral ventricles
2	3½	F	Idiopathic obesity	2 yr.	Very poor	Dehydration	Fatty infiltration	(1) CPM—localized to midline tissue of basis pontis (2 × 1 cm.) (2) Convolutional atrophy; ventricular dilatation
3	4½	F	Acute myelogenous leukaemia	3½ yr.	Poor	Electrolyte imbalance	Haemosiderosis	(1) CPM—central and peripheral, bilateral, symmetrical foci of myelinolysis in basis pontis (2) Convolutional atrophy; dilatation of lateral and third ventricles
4	15½	M	Sickle cell disease, rheumatic heart disease, congestive heart failure	5 yr.	Poor	Both	Cirrhosis, bile stasis; multiple micro-infarcts	(1) CPM—T-shaped lesion in basis pontis (2) Cortical atrophy and severe congestion of brain

* Central pontine myelinolysis.

hospital because of epistaxis, fever, excessive thirst, and multiple ecchymoses. There was generalized lymphadenopathy, and the liver was much enlarged and tender. There were no neurological abnormalities. Her bone-marrow was diagnostic of acute myelogenous leukaemia. Treatment included vincristine, mercaptopurine, prednisone, hydrocortisone, methotrexate, cytosine arabinoside, and allopurinol. The child also received transfusions of platelets, buffy-coated white cells, and whole blood. Despite this treatment, no remission of the leukaemia occurred. Throughout her 3-month hospital course there was an erratic fever. Persistent buccal ulcerations and almost daily vomiting interfered with adequate intake, and repeated intravenous feedings were necessary. No vitamin supplements were given until one month before death, when vitamin D was added to her diet. Electrolytes were normal until 5 weeks before death, when potassium and calcium values fell as low as 1.5 mEq/l. and 5.5 mg./100 ml., respectively, despite supplementary oral and intravenous replacement.

While in hospital she was irritable and uncooperative, and during the final 3 weeks her mood was one of depression, but otherwise there were no objective signs of central nervous system disease. Terminally, she

deteriorated rapidly over two days and died three months after admission, aged 4½ years.

Necropsy. The body was that of a well-developed girl weighing 18 kg. There was generalized hyperpigmentation of the skin, and numerous purpuric lesions were present over the distended abdomen and lower extremities. The lungs contained multiple mycotic abscesses which on culture grew aspergillus. In addition, multiple thromboemboli were found in the small branches of the pulmonary artery. The liver was much enlarged and showed microscopical haemosiderosis. There was no histological evidence of leukaemia.

The *brain* showed generalized convolutional atrophy with moderate dilatation of the lateral and third ventricles. Significant microscopical changes were limited to the pons, where there were both central and peripheral symmetrical foci of myelinolysis in the basis pontis (Fig. 2). Fine linear pathways of involvement connected the areas in a T-shaped distribution. The corticobulbar and corticospinal tracts were relatively spared, and tegmental structures were not affected. Microscopically there was loss of myelin sheaths, diminution of oligodendroglia, and accumulation of macrophages (Fig. 3). The latter were bulging with

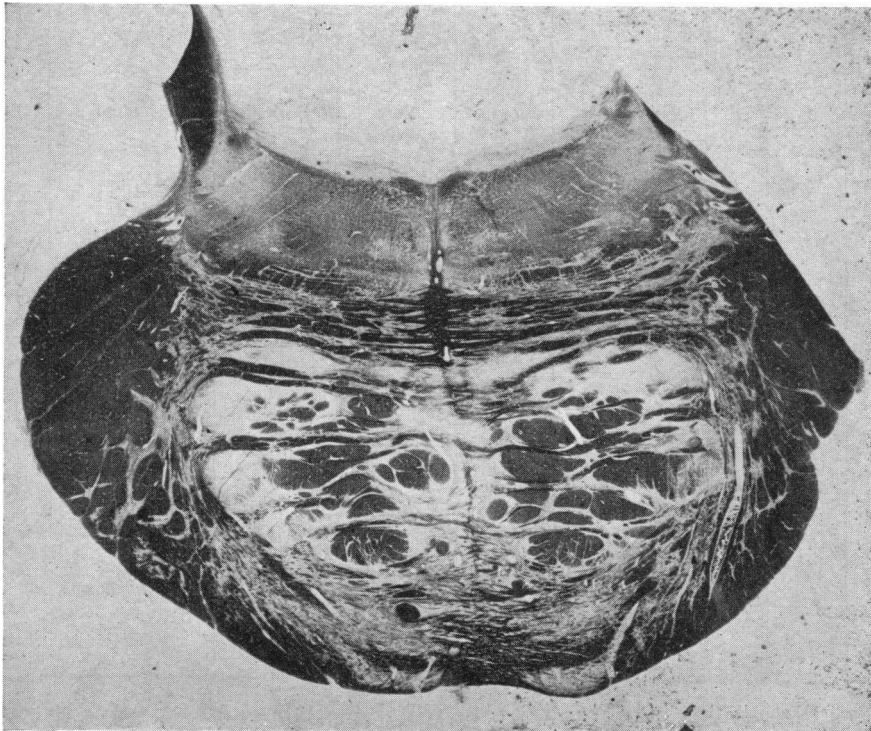


FIG. 2.—Case 3. Patchy central and peripheral foci of myelinolysis in mid-pons. Note relative sparing of descending cortical tracts. (Luxol Fast Blue-Cresyl Violet. $\times 3.25$.)

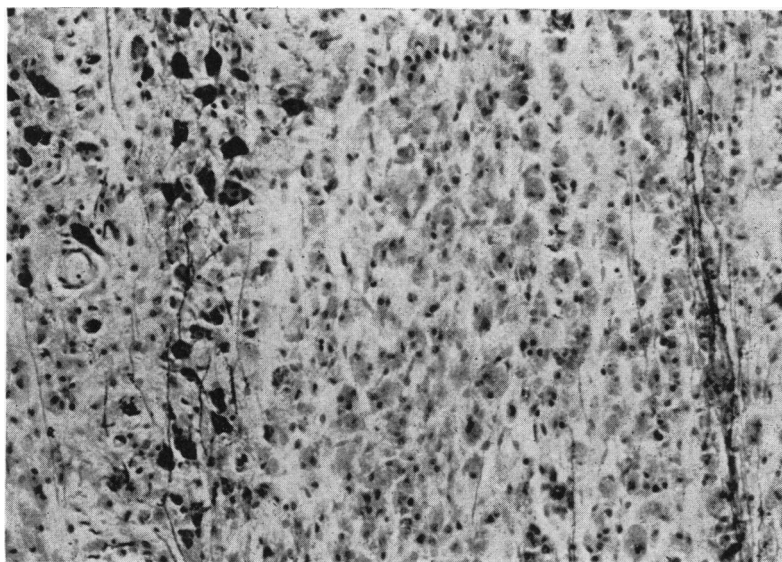


FIG. 3.—Case 3. Accumulation of foamy macrophages, with preservation of neurones and partial preservation of axis cylinders in area of myelinolysis. (Holmes-Luxol Fast Blue Stain. $\times 60$.)

fragments of degenerated myelin. There was partial destruction of axis cylinders and neurones, but astrocytic proliferation was absent.

Case 4. A 10-year-old Negro boy was admitted to hospital because of weakness, joint pain, and decreased appetite. He was found to have sickle cell disease, rheumatic heart disease, and congestive heart failure. Treatment included digitalis, penicillin, hydrochlorothiazide, spironolactone and packed red blood cell transfusions. He improved and did fairly well over the course of the next $4\frac{1}{2}$ years.

He was readmitted for the last time aged 15, because of congestive heart failure. He had appeared chronically ill, and was jaundiced and dehydrated. His lungs were clear, but the heart was grossly enlarged, with a pansystolic apical murmur. The liver was moderately enlarged. He was lethargic but responded to simple questions; deep tendon reflexes were decreased, but there were no focal neurological abnormalities.

Intractable congestive heart failure persisted. Serum sodium was 96 mEq/l. on admission and remained below normal despite attempted intravenous correction. He had a generalized motor seizure, but focal neurological signs did not appear. A duodenal ulcer was treated with a bland diet. Oral intake was poor throughout the course, and supplements of folic acid and vitamin K were given daily. The illness was further complicated by recurrent sickle cell crises with increasing jaundice, and he died aged $15\frac{1}{2}$.

Necropsy. The body was that of a jaundiced, cachectic boy. The heart was enlarged; there was mitral stenosis and old rheumatic endocarditis of the

left atrium. The spleen weighed only 3.5 g. and consisted merely of calcified fibrous tissue. The liver showed cirrhosis, multiple micro-infarcts, and bile stasis. Both kidneys were the site of multiple acute and old infarctions.

Gross examination of the *brain* disclosed generalized cortical atrophy and severe congestion, but significant microscopical findings were confined to a T-shaped area of myelinolysis at the level of the mid pons (Fig. 4). The lesion involved the midline and most dorsal region of the basis pontis, with sparing of the corticospinal tracts. Within the demyelinated areas there were innumerable foamy macrophages, but oligodendroglia were diminished, and there was no astrocytic proliferation. The axis cylinders were poorly preserved. Blood vessels were normal though they were filled with sickle cells.

Discussion

The clinical and pathological characteristics of the present cases and of the 11 previously reported cases in children are listed in the Table. The patients died at ages ranging between 3 and 16 years; the first three presented in this paper are the youngest. The group, which included 8 boys and 7 girls, had a variety of chronic debilitating illnesses for periods ranging from 9 weeks to 5 years. 3 children had leukaemia, a disease not reported in older patients with central pontine myelinolysis. Case 4 in our series is the only one with sickle cell disease.

The aetiology of central pontine myelinolysis

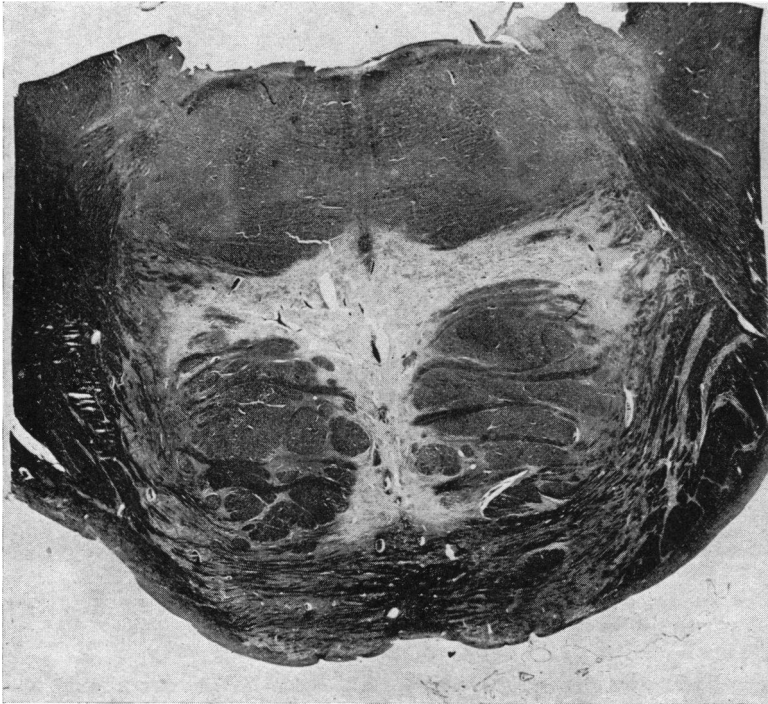


FIG. 4.—Case 4. T-shaped area of myelinolysis in mid-pons, localized to midline and dorsal basis, with sparing of descending cortical tracts. (Luxol Fast Blue-Cresyl Violet Stain. $\times 3.25$.)

remains unknown, though a variety of factors has been implicated: malnutrition, alcoholism, fluid and electrolyte imbalance, vascular disease, drugs, and hepatic dysfunction. Most frequently, there has been some malnutrition, due either to inadequate intake or in association with a chronic debilitating disease. It is possible that a specific vitamin deficiency, e.g. thiamine, may be responsible in these cases. The concomitant occurrence of central pontine myelinolysis and Wernicke's polioencephalopathy, for example, cannot be ignored (Lopez and Collins, 1968). Beyond this possibility there is little or no information regarding the specific nutritional factors that may be important.

McCormick and Danneel (1967) suggested that poor nutrition in general might have an adverse effect on the function of oligodendroglial cells, but this would not account for selective localization of the lesion in the basis pontis. Though the specific mechanism remains obscure, it is nevertheless well established that it occurs in poorly-nourished people. This is particularly evident among the cases in children, since 10 of the 12 cases on whom information is available were poorly nourished. Our Case 2, a 3½-year-old girl who received only

non-caloric beverages and vitamins for 3 weeks, followed by inadequate oral and caloric intake during the remainder of her illness, emphasizes the relation between malnutrition and central pontine myelinolysis.

Though it has been suggested that it may be due to toxic effects of alcohol, affected children have shown the classic lesion; an indirect effect of alcohol on nutritional metabolic pathways, however, cannot be discounted (Adams *et al.*, 1959; Chason *et al.*, 1964).

The mechanism by which electrolyte disturbances and dehydration might cause the disease is unknown. Rosman *et al.* (1966) found 12 of 34 patients with central pontine myelinolysis to be dehydrated, and 7 of the 34 had electrolyte imbalance. 8 of the 14 children and adolescents on whom information is available had electrolyte abnormalities, and 7 were dehydrated.

Most authors agree that the pathological lesion in this anomaly is not due to vascular disease, since no one vessel supplies the mid pons. In addition, it is unlikely that arterial or venous occlusion would result in myelin destruction without axon or nerve cell involvement. The brain of our patient with

sickle cell disease contained no ischaemic lesions, though many vessels were filled with the abnormal red cells. Absence of vascular disease has been a consistent characteristic in most cases of central pontine myelinolysis.

Aleu and Terry (1963) suggested that since central pontine myelinolysis, 'a characteristic and easily recognizable lesion', had been seen only in recent years, new environmental factors might play a role. Among these would be antibiotics and antileukaemic agents. Almost without exception, the clinical course of patients with this disease has been complicated by infections requiring the use of a variety of antibiotics. In addition, its occurrence in 3 children with leukaemia, all treated with multiple antileukaemic drugs, is worthy of note.

Shiraki *et al.* (1963) called attention to the frequent association of liver dysfunction and central pontine myelinolysis. Two-thirds of the children on whom information is available had either clinical, laboratory, or pathological evidence of hepatic disease. It is well known that patients with acquired liver disease occasionally develop an encephalopathy characterized by neuronal degeneration and astroglial proliferation, especially involving the cortex and corpus striatum (Victor, Adams, and Cole, 1965). In addition, Dayan and Williams (1967) found a demyelinating peripheral neuropathy in 10 patients with different varieties of cirrhosis, portocaval shunt, or hepatic necrosis. It is possible that liver dysfunction, perhaps through different disordered metabolic pathways, may cause at least two types of CNS lesions, one in which neurones and glia are primarily affected, and one in which myelin sheaths are primarily involved.

Central pontine myelinolysis is probably more common than is generally appreciated. Patients who develop the disease generally have complicated systemic illnesses, and subtle neurological signs may be obscured. Furthermore, if the area of demyelination is small and does not involve either tegmental nuclei (cranial nerves or reticular formation) or corticospinal tracts, signs suggesting a pontine lesion may be minimal. McCormick and Danneel (1967) listed several neurological signs and symptoms commonly seen with this disorder: reflex changes, pathological corticospinal reflexes, quadriparesis or quadriplegia, extraocular muscle palsies and pupillary abnormalities, convulsions, tremor, dysarthria, dysphagia, incontinence, and mutism. Similar findings are seen with other diseases involving the brain-stem, including Wernicke's polio-encephalopathy, vascular lesions, tumours, or even inflammatory processes. A

possibly useful clinical feature in the children and adolescents with central pontine myelinolysis is the alteration in state of consciousness which occurred in 10 of these patients. When this feature is present in malnourished patients with chronic illnesses, myelinolysis may be suspected, especially if there are signs of brain-stem disease. A definite diagnosis, however, can only be made at necropsy.

Summary

Central pontine myelinolysis, a pathological entity characterized by demyelination in the central part of the basis pontis, may be a less uncommon disorder in childhood and adolescence than has been thought. 4 new cases, ranging in age from 3 to 15 years, are added to the 11 already reported. All of the cases in children had chronic debilitating illnesses. Diagnosis of the pontine lesion is rarely made during life because the disease is localized in a functionally silent area. One suggestive clinical feature is some alteration in the state of consciousness.

A variety of causative factors have been implicated, malnutrition, alcoholism, fluid and electrolyte imbalance, vascular disease, drugs, and hepatic dysfunction, but the pathogenesis remains unknown.

REFERENCES

- Adams, J. H. (1962). Central pontine myelinolysis. In *Proceedings of the Fourth International Congress of Neuropathology*, Vol. 3, p. 303. Ed. by H. Jacob. G. Thieme, Stuttgart.
- Adams, R. D., Victor, M., and Mancall, E. L. (1959). Central pontine myelinolysis: a hitherto undescribed disease occurring in alcoholic and malnourished patients. *Arch. Neurol. Psychiat. (Chic.)*, **81**, 154.
- Aleu, F. P., and Terry, R. D. (1963). Central pontine myelinolysis. *Arch. Path.*, **76**, 140.
- Chason, J. L., Landers, J. W., and Gonzalez, J. E. (1964). Central pontine myelinolysis. *J. Neurol. Neurosurg. Psychiat.*, n.s. **27**, 317.
- Dayan, A. D., and Williams, R. (1967). Demyelinating peripheral neuropathy and liver disease. *Lancet*, **2**, 133.
- Ito, J., Hasegawa, J., and Uchida, T. (1965). A clinical case of amyotrophic lateral sclerosis and a postmortem examination of central pontine myelinolysis accompanied by predominant muscular atrophy of limbs. *Yonago Acta med.*, **9**, 20.
- Kepes, J. J., Reece, C. A., and Oxley, D. K. (1965). Central pontine myelinolysis in a 7-year-old boy. *J. Neurol. Neurosurg. Psychiat.*, n.s. **28**, 39.
- Lopez, R. I., and Collins, G. H. (1968). Wernicke's encephalopathy: a complication of chronic hemodialysis. *Arch. Neurol. (Chic.)*, **18**, 248.
- McCormick, W. F., and Danneel, C. M. (1967). Central pontine myelinolysis. *Arch. intern. Med.*, **119**, 444.
- Mathieson, G., and Olszewski, J. (1960). Central pontine myelinolysis with other cerebral changes. *Neurology (Minneapolis)*, **10**, 345.
- Matsuoka, T., Miyoshi, K., Saka, K., Hayashi, S., and Kageyama, N. (1965). Central pontine myelinolysis. *Acta neuropath. (Berl.)*, **5**, 117.
- Nakamura, H., Shimoda, Y., Fukuda, M., and Ito, J. (1966). Positive spikes in EEG and brain stem lesions. (Japanese.) *Brain Nerve (Tokyo)*, **18**, 723.

- Nishiyama, A. (1965). Central pontine myelinolysis with Wilson's disease. Read before the Sixth Japanese Neuropathologist Meeting, Kurume, Japan.
- Rosman, N. P., Kakulas, B. A., and Richardson, E. P., Jr. (1966). Central pontine myelinolysis in a child with leukemia. *Arch. Neurol. (Chic.)*, **14**, 273.
- Schneck, S. A. (1966). Neuropathological features of human organ transplantation. II. Central pontine myelinolysis and neuroaxonal dystrophy. *J. Neuropath. exp. Neurol.*, **25**, 18.
- Shiraki, H., Izuka, R., and Seitelberger, F. (1963). Six autopsy cases with central pontine myelinolysis. Read before the Fourth Japanese Neuropathologist Meeting, Kyoto, Japan.
- Victor, M., Adams, R. D., and Cole, M. (1965). The acquired (non-Wilsonian) type of chronic hepatocerebral degeneration. *Medicine (Baltimore)*, **44**, 345.

Addendum

The authors have recently seen an additional case of central pontine myelinolysis in a 1-year-old boy dying with stem cell leukaemia.

Correspondence to Dr. T. E. Cadman, Geisinger Medical Center, Danville, Pennsylvania, 17821, U.S.A.