

(8) Patients with congestive glaucoma are usually nervous and worrying individuals. This tendency is less marked in simple glaucoma.

(9) A plea is made that practitioners should suspect the disease in all patients over 40 years with eye symptoms, especially if haloes have been seen or if there is a unilateral disturbance of vision.

This analysis touches very briefly upon the work of Mr. G. D. Elphick on visual fields, Mr. H. E. Hobbs on gonioscopy, and Mr. D. A. Langley on the phasic variations in simple glaucoma, carried out at the Glaucoma Clinic under the direction of Sir Stewart Duke-Elder. The social histories were taken by Misses Abbey, Armstrong, and Collis; patients were mainly referred from the surgeons of Moorfields, Westminster, and Central Eye Hospital; the secretarial work was undertaken by Miss J. Brown: to all of whom my thanks are due.

## REFERENCES

- Blaxter, P. L. (1950). *Brit. J. Ophthalmol.*, 34, 442.  
 Duke-Elder, W. S. (1940). *Textbook of Ophthalmology*, 3, 3366. London.  
 Friedenwald, J. S. (1949). *Trans. Amer. Acad. Ophthalm. Otolaryng.*, 53, 169.  
 Hobbs, H. E. (1950). *Proc. roy. Soc. Med.*, 43, 1018.  
 Langley, D., and Swanlung, H. (1951). *Brit. J. Ophthalmol.*, 35, 445.  
 MacKenzie, W. (1830). *Treatise on Diseases of the Eye*. London.  
 Sorsby, A. (1951). *Genetics in Ophthalmology*, Preface, p. vii. London.  
 Traquair, H. M. (1935). *British Medical Journal*, 2, 933.

## CEPHALIC TETANUS WITH REPORT OF A CASE

BY

L. BAGRATUNI, B.M., B.Ch.

Registrar, Department of Clinical Biochemistry, Radcliffe Infirmary, Oxford

Cephalic tetanus is a rare disease developing after injuries to the scalp, face, or neck, and associated with palsies of cranial nerves III, IV, VI, VII, IX-X, XII, singly or in any combination. Although general tetanus does not always follow, the condition is invariably associated with some degree of trismus.

Cumstone (1918) and Raven (1940) both recognize a type of cephalic tetanus after head or face injury which is without palsy and in which trismus is the principal sign. This type should not strictly be included in the term "cephalic tetanus," since it does not differ from local tetanus as found in other parts of the body. For this reason it is suggested that the term "cephalic tetanus" should be limited to those cases in which there is a cranial-nerve palsy. For this reason, again, cases such as those of Hyman (1935), in which there was tetanus with trismus and slight neck stiffness after tonsillectomy, and Bagchi (1929), who reported generalized tetanus associated with discharging ears, are not true cases of cephalic tetanus, in spite of the injury being limited to the head.

Rose (1869) is generally credited with the first comprehensive description of the disease, although Sir Charles Bell reported a case in London in 1836 and Pollock another from Dublin in 1847. Brown (1912) reviewed 94 cases, and in 1935 Abel and Hampil comprehensively reviewed the earliest literature on tetanus in general. Jayme-Goyaz (1941) and Wetzel (1942) almost simultaneously published reviews on cephalic tetanus in relation to eye injuries. For the past 25 years the *Quarterly Cumulative Index Medicus* has reported on an average two to three cases annually, bringing the present reported total to over 200.

## Case Report

A 19-year-old engineer's apprentice was admitted to the Radcliffe Infirmary on July 17, 1949, as an emergency. His complaint was stiffness of the jaws for the previous 12 hours. There was nothing relevant in his past or family history, and he had always enjoyed good health. On July 7 he had had an accident while riding a bicycle along a flint road which was strewn with hay. He fell off and received a cut over his left eyebrow from a pedal. At no time was he unconscious. With a friend he telephoned for a car, which brought them to his doctor in five minutes. After cleansing, two stitches were put into the wound and he received a prophylactic injection of antitetanic serum into his left deltoid. He was home, in bed, within half an hour of the accident. On the next day he felt quite well except for a slight headache behind the left eye which lasted for two days. His doctor, however, advised him to remain in bed.

On July 16 he was allowed up by his doctor for the first time. He felt a little tired but had no other symptoms. Later in the day he had slight difficulty in closing the left eye, but took little notice of this. During the night he was awakened twice by an involuntary closure of the jaws which caused him to bite his tongue. On waking the following morning he noticed that he could not move the left side of his face as well as his right if he spoke or smiled. The left side felt "stiff." Next he noticed that the jaw was "stiff" on the left side. These symptoms progressed. At 8 p.m. he was seen by his doctor, who found a complete left facial palsy, trismus, and no other signs. He sent him into hospital. There had been no difficulty in swallowing and no stiffness anywhere apart from the trismus.

On admission he looked healthy and felt perfectly well apart from the palsy and slight trismus. In fact, he treated the whole matter as a joke. His temperature was 97.8° F. (36.6° C.), pulse 60, and respirations 20.

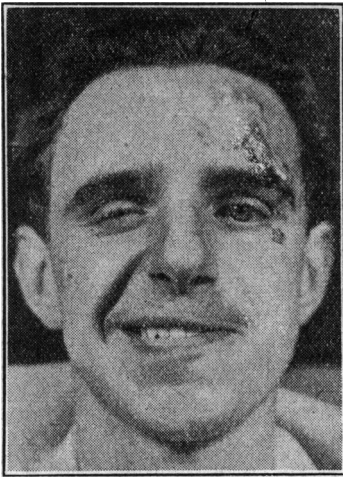
Examination showed a moderately deep wound over the left eyebrow, 1½ in. (3.8 cm.) long, sprinkled with penicillin powder. It was clean and there were no signs of inflammation. Multiple superficial abrasions were present on both elbows, extensor aspects of both forearms, both palms, and the left knee. These were healing well. There was no stiffness of the neck, back, or abdomen. He had a well-marked upper and lower facial palsy on the left, but could with an effort give a short whistle now and then. He could not close the left eye, although the right closed normally. The left naso-labial fold was almost completely obliterated. There was also mild trismus. No further abnormalities of the cranial nerves were found; the fundi appeared normal, and tone, power, movement, and reflexes in the limbs and abdomen showed no abnormality. The plantar responses were flexor. There was no abdominal rigidity. The cardiovascular and respiratory systems were normal. The blood pressure was 110/80. Urine analysis revealed no abnormal constituents.

## Progress and Investigations

He was at once put to bed and given 100,000 units of antitetanic serum intravenously and 100,000 units intramuscularly. He received phenobarbitone and sodium amylal and was given a high-calorie high-protein diet. A skull x-ray film showed no fracture or other lesion.

July 18.—The stitches were removed and a swab was taken from the wound, which appeared quite clean. *Clostridium tetani* was not cultured from the swab. The haemoglobin was 17.4 g.%. The white blood cells numbered 5,000, with a normal differential count. The blood sedimentation rate was 1 mm. in one hour (Westergren). The Wassermann and Kahn reactions were negative. He was well and was fairly active in spite of the sedation. The accompanying photograph was taken on this day.

July 19.—The trismus was increasing and he was having difficulty in taking solid foods.



Photograph showing wound and left facial palsy on July 18.

*July 20.*—The trismus was worse. He complained spontaneously of diplopia for distant objects. The mouth opened  $\frac{1}{4}$  in. (1.9 cm.). There was minimal weakness of the left external rectus muscle on looking to the left. He was developing a right-sided ptosis. He complained of some stiffness of the left side of his neck. There was no abdominal rigidity.

*July 21.*—The ptosis was more pronounced. The diplopia persisted, but it was difficult to

analyse in spite of the images being side by side. There was very slight dilatation of the right pupil. He complained of some blurring of vision. He was unable to take solid food. The wound was quite clean.

*July 22.*—The ptosis was increasing and there was slight impairment of upward movement of the right eye and slight limitation of lateral movement of the left eye. There was no difficulty in swallowing.

*July 23.*—The diplopia persisted for distant objects and there was occasional difficulty in swallowing.

*July 24.*—His sleep was disturbed by involuntary tongue-biting. The trismus was very marked on the left side and the mouth hardly opened, so that fluids had to be taken from a feeder. Occasionally fluids passed into the trachea but not into the nose. The diplopia persisted, but there were no signs of general tetanus.

*July 27.*—He began to improve. The mouth opened wider and the tongue-biting at night had become much less frequent. The facial palsy and ptosis remained as before. Movements of the left eye were improved, but the right eye movements were still impaired.

*July 28.*—The diplopia was improving.

*July 31.*—The ptosis was less marked and the mouth opened wider. He was taking solid food.

*August 4.*—The facial palsy remained unchanged. The mouth opened wider but fluids still entered the trachea at times although there was no difficulty in swallowing. Vision: right eye, 6/5 and Jaeger 1; left eye, 6/9 and Jaeger 1 with hesitation. The ptosis was improving, but the diplopia persisted. There were no pupillary abnormalities. Changes were observed in the left fundus for the first time.

*August 9.*—Seen by Mr. J. P. F. Lloyd at the Oxford Eye Hospital, with the following findings. Vision: right eye, 6/5; left eye, 6/18. Orthoptic report: cover test, near and distance slight convergence, rapid recovery; ocular movements show slight left external and left inferior rectus weakness; left superior rectus appears to overact. Synoptophore: angle + 3° straight ahead, + 5° laevoversion, and + 3° on dextroversion; fuses at + 3°; adducts 24°; abducts 4/5°. He still complained of horizontal diplopia on laevoversion and depression which was improving. The Hess chart was attempted, but the angle of deviation was too small. The fundi showed a lesion of the left macular, the fovea appearing to be situated in a small greyish area. This was thought to be due to macular exudate, detachment, or haemorrhage after the trauma of the accident. The 6/18 vision of the left eye was not improved by glasses. In Mr. Lloyd's opinion the incoordination of eye movement could not be attributed to any one muscle, but seemed to involve a midbrain nuclear disturbance.

*August 10.*—The patient was up and about in the ward. The ptosis was less marked and the mouth opened fairly well, but the facial weakness persisted. The wound was now well healed.

*August 12.*—Electromyography of the facial muscles showed normal nerve conduction on both sides on faradic stimulation. All facial muscles responded to both faradic and galvanic stimulation, although the response was slightly more sluggish on the left side. The electrical reactions were virtually normal. He was discharged home on August 13. During his 27 days in hospital his temperature rose to 100° F. (37.8° C.) on only four separate occasions.

When seen as an out-patient on September 6 there was some facial asymmetry at rest and upper and lower facial weakness was still present, but much less marked. The left palpebral fissure was slightly smaller than the right. The mouth still did not open fully, but he was eating and chewing his food normally.

On December 15, 1950, eighteen months after the initial injury, he was symptomless and quite well. At rest there was still minimal facial asymmetry, with the left nasolabial fold less marked than the right, but there was no facial weakness. The mouth opened fully, although he did not think it opened as well as before the injury. There were no eye symptoms or signs. Indeed, the only traces remaining of his illness were the well-healed scars over the eyebrow and slight facial asymmetry.

### Discussion

In the days before serum was used Brown found the mortality in cephalic tetanus to be 53% in 94 cases, but in the 14 cases in which facial palsy preceded trismus this was raised to 64%. Wetzel's 30 cases after eye injury had a mortality of 80%. The six cases which recovered all had antitetanic serum. For general tetanus Cole (1940) found the mortality to be 38% in 43 consecutive cases in civilian practice. Pratt (1945) found a mortality of 43% among 56 children with all forms. Cole considered the prognosis bad for general tetanus if spasm appeared within 48 hours after injury and good if after this period. Reports certainly suggest that cephalic tetanus is more deadly than other forms and the prognosis is worse the earlier the signs appear.

The palsy may last a few days or persist for several months in the absence of other symptoms. The facial palsy is the most persistent, but recovery always seems to occur in the end. The present patient had a slight facial weakness two months after the initial injury. He was perfectly well apart from this. Sigwald's (1946) case, however, had a persistent facial palsy for seven months with no signs of recovery. This is very exceptional.

Ptosis also tends to persist, but usually for a shorter period. Palsies of the other cranial nerves are generally confined to the height of the illness only.

### Pathogenesis and Pathology

The tetano-spasmin fraction of the tetanus toxin is fatal to man in a dose of 0.5 mg. Barnes and Trueta (1941) suggest that it is absorbed by the lymphatics and carried to the anterior horn cells by the blood. The work of Harvey (1939), Schaefer (1944), and Vincent and de Prat (1945), however, suggests that the spastic phenomena may be explained by a purely peripheral action of the toxin on the motor end-plate and proprioceptive endings, associated with increased liberation of acetylcholine.

The paralytic phenomena are very much harder to understand. Rose originally thought that the facial nerve swelled under the influence of the toxin and became strangulated in the stylo-mastoid canal, resulting in the commonest type of palsy. Watkins (1939) found an impaired sensation to taste associated with facial palsy and suggested a similar mechanism with involvement of the chorda tympani. Jayme-Goyaz quoted Mendel, who suggested that the third-nerve lesions were due to intense absorption of toxin from the orbicu-

laris and ciliary regions, which are supplied by this nerve. In Sigwald's case the limitation of ocular movement as determined by electrical tests was due to paralysis and not to spasm of the eye muscles. In the present case myograms of the facial muscles after the patient had improved showed little change from normal, although the response was more sluggish on the side of the palsy. Gunther and Walker (1943) found that in local tetanus myograms showed action currents present even at rest, with exaggerated summation during contraction and after a noise stimulus.

Baker (1943) reviewed the early literature on the pathological changes; it was extremely conflicting. It may be said in general that no definite nerve lesion had been found except for haemorrhages which might have been due to violent spasms. He recorded the case of a farmer who died of general tetanus after the removal of a wart from the hand. He died with irregular heart and respiratory action not associated with spasms and apparently due to failure of the respiratory and cardiovascular centres in the medulla. Sections of the brain showed destructive changes in the motor nuclei of the fifth nerve and in the dorsal nucleus of the tenth nerve. Minimal changes were found elsewhere, and there was no significant lesion of the anterior horn cells. Baker suggested that selective nuclear damage may often be a cause of death in tetanus, and is usually ascribed to respiratory spasms rather than paralysis. Such localized nuclear changes would certainly account for the bizarre ocular signs found in the present and other reported cases. Baker's patient had no ocular signs, and no damage was observed in any of the ocular nuclei. Reversible damage to the nucleus would account for the temporary nature of the paresis, and the extent of the damage would determine its duration.

#### Treatment

No matter how mild the initial symptoms may be, every case of cephalic tetanus should be treated as a potential case of general tetanus. Antitoxin should be given, 100,000 units intravenously and 100,000 intramuscularly, as soon as possible after the signs appear. Adequate sedation to prevent spasms, a special nurse, and a darkened room are essential. A high-protein high-calorie diet should also be given, by nasal tube if the trismus is intense.

Tongue-biting may be troublesome and the teeth may have to be wedged with gauze. The general nursing of the patient is often of greater importance than any specific therapy. Mephenesin ("myanesin") has been used to overcome the spasms and it is useful for feeding, but there is a danger of haemolysis (Torrens *et al.*, 1948).

#### Summary

Cephalic tetanus is defined as tetanus after head or face injury which is accompanied by some cranial-nerve palsy. A case with recovery is described.

The clinical picture involves bizarre palsies of cranial nerves III, IV, VI, VII, IX-X, XII, single or in any combination. Exceptionally, the chorda tympani may be involved. It is suggested that the condition results in transient or permanent damage to the cranial-nerve nuclei.

Prognosis is better than earlier reports suggest if prompt treatment with antitetanic serum and sedation is carried out.

I should like to thank Dr. A. M. Cooke for permission to publish this case and for helpful criticism in connexion with this paper. I should also like to thank Mr. J. P. F. Lloyd, of the Oxford Eye Hospital, for the eye examinations.

#### REFERENCES

- Abel, J. J., and Hampill, B. (1935). *Bull. Johns Hopk. Hosp.*, 57, 343.  
 Bagchi, H. N. (1929). *Indian med. Gaz.*, 64, 89.  
 Baker, A. B. (1943). *Amer. J. Path.*, 19, 709.  
 Barnes, J. M., and Trueta, J. (1941). *Lancet*, 1, 623.

- Bell, C. (1836). *The Nervous System of the Human Body*, 3rd ed., p. 330. London.  
 Brown, A. J. (1912). *Ann. Surg.*, 55, 473.  
 Cole, L. (1940). *Lancet*, 1, 164.  
 Cumstone, C. G. (1918). *N.Y. med. J.*, 107, 505.  
 Gunther, L., and Walker, J. E. (1943). *Wa. Med.*, 4, 57.  
 Harvey, A. M. (1939). *J. Physiol.*, 96, 348.  
 Hyman, S. (1935). *Amer. J. Dis. Child.*, 49, 1540.  
 Jayme-Goyaz, G. G. (1941). *Amer. J. Ophthalm.*, 24, 1281.  
 Pollock, G. (1847). *Dublin med. Pr.*, 17, 372.  
 Pratt, E. L. (1945). *J. Amer. med. Ass.*, 129, 1243.  
 Raven, R. W. (1940). *Post-Grad. med. J.*, 16, 260.  
 Rose, E. (1869). In *Handbuch der Chirurgie*, edited by F. J. von Pitha and C. A. T. Billroth, vol. 1, part 2. Stuttgart.  
 Schaefer, H. (1944). *Arch. exp. Path. Pharmacol.*, 203, 59.  
 Sigwald, M. J. (1946). *Rev. Neurol.*, 78, 584.  
 Torrens, J. A., Edwards, P. M., and Wood, M. W. W. (1948). *Lancet*, 2, 807.  
 Vincent, D., and de Prat, J. (1945). *C.R. Soc. Biol., Paris*, 139, 1146.  
 Watkins, A. L. (1939). *Arch. Neurol. Psychiat.*, Chicago, 41, 788.  
 Wetzel, J. O. (1942). *Amer. J. Ophthalm.*, 25, 933.

## ESTIMATION OF TRYPSIN IN DUODENAL JUICE

BY

I. GORDON, M.B., M.R.C.P., M.R.C.P.Ed., D.C.H.

B. LEVIN, M.D., Ph.D., B.Sc.

AND

T. P. WHITEHEAD, A.R.I.C.

(From the Queen Elizabeth Hospital for Children, London)

It has been shown (Andersen, 1942) that trypsin is always low or absent from the duodenal juice in fibrocystic disease of the pancreas, and this forms a reliable basis of diagnosis. Andersen has pointed out that the estimation of proteolytic enzyme need not be exact, as there is a fairly wide difference between the amounts found in fibrocystic disease and those found in other conditions, and she therefore adopted a simple modification of Fermi's method (1906) for routine estimation of trypsin. For some time we have been using a modification of the method of d'Este Emery (quoted by Harrison, 1930), which utilizes the gelatin of an x-ray film as substrate for estimating trypsin in duodenal juice and faeces. It has the advantage of ease and simplicity and is accurate enough for diagnosis. A similar method has been described for faeces by Shwachman, Patterson, and Laguna (1949), who appear to have overlooked the prior description.

In this investigation, using the method of James (1951) for aspirating duodenal juice, the normal levels of trypsin have been determined by the x-ray film method; a comparison has been made between this method, the gelatin method of Andersen, and a more accurate method based upon the proteolytic action of trypsin on casein (Northrop, 1924).

#### Method of Intubation

An ordinary duodenal tube containing a magnet in the tip was used as in the method of James (1951). In an infant the 10 o'clock feed was not given; in the older child breakfast was omitted so that intubation was performed with the stomach empty. There was no restriction of fluids. Sedatives were unnecessary; in several instances where one was given a longer time was needed to obtain a satisfactory specimen of duodenal juice, possibly because of the diminished gastric peristalsis or because the patients were more restless when the tube was passed. Whenever possible the tube was passed through the nose, as better control was thus obtained. In most cases a small plotting compass— $\frac{1}{2}$  in. (1.25 cm.)—with a non-dipping needle was used to locate the tip. The point at which maximum oscillation of the needle occurred was found by experience to be always