

# Cell-to-Cell Herniae in the Arterial Wall

## *I. The Pathogenesis of Vacuoles in the Normal Media*

Isabelle Joris, PhD, and Guido Majno, MD

Vacuoles were observed by light microscopy in the smooth muscle cells of the media in normal rat arteries. By electron microscopy these vacuoles were limited by two membranes; they usually contained myelin figures, a few organelles (especially mitochondria and microfilaments), and an amorphous background material that varied greatly in density. Morphologic evidence indicates that these structures arise by herniation of one smooth muscle cell into another; it is presumed that herniation occurs during contraction at weak points corresponding to areas where adjacent cells come in close contact. Such cell-to-cell herniae were mostly seen in small arteries (arterioles) with a diameter of 0.4 to 0.2 mm; however, none was found in coronary arteries of this size. This discrepancy suggests that the pathogenesis of cell-to-cell herniae is correlated not only with the caliber of the artery but also with functional demands. (*Am J Pathol* 87:375-398, 1977)

THIS PAPER REPORTS a peculiar but common type of intracellular structure which manifests itself by light microscopy as a vacuole and arises by herniation of one cell into its neighbor.

The finding was made by accident. An earlier study of the normal arterial wall had focused our attention on cellular breakdown within the smooth muscle of the media as a physiologic event.<sup>1</sup> We therefore decided to study a naturally occurring situation in which this phenomenon might be increased, i.e., the uterine artery postpartum (in the rat). This we did—but found no evidence at all of increased cell death. Instead, it became apparent that many smooth muscle cells of the normal uterine artery (postpartum or otherwise) contained obvious vacuoles. Further work showed that similar vacuoles occurred normally in many other small arteries and brought us to study the pathogenesis, and the significance, of these structures.

### **Materials and Methods**

#### **Animals**

We used 14 male and 22 female rats of the Wistar strain (Charles River Breeding Laboratories, Wilmington, Mass). The females were either virgin, 20 days pregnant, or 12 hours postpartum, and weighed 145 to 440 g. The adult male rats weighed from 275 to 580 g.

---

From the Department of Pathology, University of Massachusetts Medical Center, Worcester, Massachusetts.

Supported by Grant HL-16952 from the National Institutes of Health.

Accepted for publication December 30, 1976.

Address reprint requests to Dr. Isabelle Joris, Department of Pathology, University of Massachusetts Medical Center, 55 Lake Avenue North, Worcester, MA 01605.

### Experimental Procedure

To sample different branches of the arterial tree under standard conditions and as close as possible to the physiologic state, tissues were taken from animals perfused with fixative, as follows. The rat was overanesthetized with chloroform; as soon as respiration ceased, the chest was opened, the left lung was eased toward the right side, an 18-gauge needle was inserted downward into the descending aorta and secured with a ligature, and the perfusion was started. An exit for the perfusing fluid was provided by cutting the femoral vessels at the groin; when it was necessary to preserve the femoral vessels for electron microscopy, male rats were used, and the outflow was provided by cutting off one testis. The perfusion was continued for 20 minutes and required about 300 cu cm of fixative. To fix the coronary arteries, perfusion was done in retrograde fashion, by inserting the needle upward into the abdominal aorta as described elsewhere.<sup>1</sup>

The fixative routinely used for perfusion was 3% glutaraldehyde in cacodylate buffer at pressures of 110 to 130 mm Hg. In early experiments, before perfusing with fixative, the blood vessels were washed out for 3 minutes with a physiologic solution (Ringer's with 5% glucose, pH 7.4, bubbled with 95% oxygen and 5% carbon dioxide); later we found that this precaution was unnecessary, and we perfused directly with the fixative. Two rats were perfused with Karnovsky's fixative;<sup>2</sup> results were the same. In a few experiments, segments of arteries were excised and fixed by immersion.

### Sampling and Processing of Arterial Segments

As soon as the perfusion was stopped, the spermatic or uterine arteries were excised under a surgical microscope (Applied Fiber Optics Company); samples were also taken from the abdominal aorta, the renal, superior and inferior mesenteric, iliac, femoral, saphenous, and tibial arteries.<sup>3</sup> In the rat the saphenous artery is the most superficial and most extensive branch of the femoral.<sup>3</sup> The specimens were further fixed with 3% glutaraldehyde in cacodylate buffer for a total of 5 hours at room temperature, then left in cacodylate buffer for 12 hours at 4 C, postfixed in 2% osmium tetroxide in collidine buffer for 2 hours at 4 C, dehydrated in graded ethanols, and embedded in Epon 812.<sup>4</sup> For light microscopy, sections 1- $\mu$ -thick were stained with toluidine blue. Ultrathin sections were cut with a diamond knife on an LKB Ultratome III, mounted on uncoated grids, stained with uranyl acetate and lead citrate,<sup>5,6</sup> and examined with a Philips EM 301 electron microscope.

### Estrus Cycle

A series of virgin female rats was sacrificed on each of the 4 days of the estrus cycle, determined by vaginal smears stained by the Papanicolaou technique.<sup>7</sup> Fixation-perfusion was performed as usual, and the uterine arteries were sampled for electron microscopy.

### Hormone Treatments

Two groups of virgin female rats were treated either with estrogen ( $\beta$ -estradiol, Sigma, 25  $\mu$ g/day for 4 and 5 days), or progesterone (Sigma, 2 mg/day for 4 and 5 days). Fixation-perfusion was performed as usual, and the uterine arteries were sampled for electron microscopy.

## Results

### Light Microscopic Observations

Vacuoles were clearly visible in 1- $\mu$  sections of Epon-embedded uterine and spermatic arteries (Figure 1A and B). Typically, they appeared as

intracellular inclusions that were about the size of a nucleus, rounded or oval, and sometimes very long and occupying a large part of the cell. A few of the larger vacuoles appeared to be producing one or more smaller ones by a "budding" process; apposed vacuoles were often separated by a very thin septum, barely visible. Most of the vacuoles were clear; inside them it was sometimes possible to see faint convoluted structures suggesting thin membranes, and indeed by electron microscopy they could be identified as myelin figures. Other vacuoles were filled with a homogeneous material, which stained more lightly than the cell itself, and sometimes contained one or two opaque granules.

#### Electron Microscopic Observations

The first impression by electron microscopy was that the number of vacuoles was greater than anticipated: many had escaped detection by the light microscope because they were too small or their content was similar in density to the cytoplasm. Some, especially the larger ones, deformed the nucleus (Figure 2A); where they bulged close to the cell surface, they usually remained separated from it by a thin layer of cytoplasm (Figure 2B). The most unexpected finding was that practically all vacuoles were limited by *two* membranes, each similar in thickness to the cell membrane (Figure 3A and B). At times, a vacuole bulging close to the cell surface seemed to push through it: at that point, where it was exposed to the extracellular space, it had only one membrane (Figure 3A and B). The significance of this observation remained unclear until the pathogenesis of the vacuoles was explained: in a number of cases we found a connection between a vacuole and an *adjacent* cell, clearly implying that the vacuole was a hernia from that cell into its neighbor (Figure 4). Therefore, the inner membrane of each vacuole belonged to the herniating cell, the outer one to the recipient. We saw enough of these "necks," connecting a vacuole to a nearby cell to remain convinced that this was a general phenomenon underlying the formation of all the vacuoles under consideration. Since the necks were all very thin, and of the same order of thickness as the ultrathin sections (500 to 1000 Å, see Figure 4) the chance of cutting one lengthwise in any given section was slim.

The content of the vacuoles included vesicles (Figure 4); microfilaments (Figure 5, lower vacuole); myelin figures of varying complexity, which could be interpreted as degeneration products of normal membrane-bounded cell structures (Figures 2A, B, 3A, 6); and more rarely mitochondria (Figure 7A). Microtubules were also found, as were granules of glycogen and free ribosomes. The double membrane was not always continuous. It was best preserved in the smaller vacuoles (Figure

7A); in the larger ones, which also had the loosest, least dense content, only traces of a membranous lining were visible. At times it seemed possible to trace the breakdown of the paired lining membranes into myelin figures (Figure 5, upper vacuole); but the myelin figures could obviously arise from any of the intracellular bodies, such as mitochondria or vesicles. We believed at first that the presence of paired lining membranes was evidence of poor fixation; but this could not explain the large, dense multilayered myelin figures which suggested a long process of formation and condensation (Figure 2B).

Lysosome-like bodies were never seen loose inside a vacuole; however, Figure 7B shows two dense bodies—presumably lysosomes—in close relation to a clear vacuole: one is just outside and apparently making contact at a point where the double membrane is missing; the other is inside the vacuole, adherent to its inner surface and lacking a membrane.

Electron microscopy confirmed other features that had been observed in 1- $\mu$  sections: the “budding” process (Figure 3B) and the presence of thin septa (Figure 7A).

#### Number and Distribution of the Vacuoles in the Arterial Tree

By comparing light and electron microscopic findings on the vacuoles, we noticed that their relative *distribution* could reliably be followed by light microscopy, although their absolute *number*—for the reasons mentioned above—was underestimated. Within a given artery, if vacuoles were present, they could be anywhere within the media. Arterial calibers were measured under the microscope, with a micrometer, using the outer surface of the media as a limit. The distribution of the vacuoles in the arterial tree, as estimated from 1- $\mu$  sections, is summarized in Table 1. In

Table 1—Distribution of Medial Vacuoles in the Arterial System of the Rat

Artery*	Diameter (mm)†	No. of sections examined‡	No. of sections with vacuoles	Total No. of vacuoles§
Aorta	1.13	10	2	3
Iliac	0.88	17	5	10
Femoral	0.76	13	0	0
Mesenteric	0.37	13	13	157
Saphenous	0.32	10	0	0
Coronary	0.29	30	0	0
Uterine	0.25	23	21	248
Spermatic	0.22	14	13	113
Tibial	0.19	13	5	15

\* Listed in order of decreasing diameter.

† Mean value using the outer limits of the media.

‡ Epon-embedded arteries, 1- $\mu$  sections, each section from a different block.

§ Counted by light microscopy (by electron microscopy the total would be greater).



the aorta, vacuoles are very uncommon: on the average, we found a vacuole or two in one of five sections. Then, proceeding distally, the number of vacuoles increases—but not as a simple function of the caliber. In the large, elastic branches they are very sparse; we found some in the iliac, none in the femoral, and none in the carotid. Greater numbers begin to appear when the caliber drops to about 0.4 mm: the most affected are the uterine, spermatic and mesenteric arteries, whose calibers are in the 0.40 to 0.20 mm range (we have not yet studied smaller vessels).

#### **Effect of Estrus Cycle, Gestation, and Hormone Treatments**

No changes in the number or distribution of vacuoles were found that could be correlated with any of the conditions listed.

## **Discussion**

#### **Reliability of the Perfusion Technique**

Since vacuoles can develop in cells that are poorly fixed, it was essential to make sure that our perfusions led to immediate and satisfactory fixation. We noticed that adequate fixation of the aorta required 20 minutes; after that time it remained rigid when cut, having lost most of its elasticity (underfixed aortas behaved rather like rubber bands). Occasionally, a streak of blood was found against one side of the aortic wall; this did not appear to interfere with fixation. No significant problem was encountered in fixing the aorta, the renal, the superior and inferior mesenteric, the spermatic, iliac, femoral, saphenous and tibial arteries. Instead, fixation of the uterine arteries (and thus also of the uterus) was rather erratic. When all the abdominal organs including the uterus were found to be free of blood and stiff from fixation, the electron microscopic fixation of the uterine artery was consistently good. At other times the fixation of the abdominal viscera was incomplete; in such cases, it was often observed that one uterine horn was not fixed, whereas the other appeared yellowish, stiff, and apparently well fixed; yet electron microscopy of the “well-fixed” side showed poor preservation of the artery. It was then realized that *the naked-eye appearance of “well-perfused, well-fixed” tissue did not necessarily imply good fixation at the level of electron microscopy.* The only explanation that we can offer for this seemingly contradictory state of affairs is that during the 20 minutes of perfusion the penetration of fixative into a uterine artery is sometimes unaccountably delayed, so that after 20 minutes the gross appearance suggests good fixation, but the initial delay has been long enough to cause poor results. Of all the abdominal arteries examined, the uterine appeared to be the most diffi-

cult to perfuse; a satisfactory reason could not be found. We could not obtain more reliable results by varying the type of outflow, i.e., by cutting the femoral vein alone or the femoral vein as well as the artery. Washing out the blood before fixation with Ringer's solution did not help.

Another problem to consider is the *caliber of the arteries after perfusion-fixation*. All the larger arteries sampled were clearly distended, as proven by the straight or only slightly wavy elastica interna; but the uterine, spermatic, mesenteric (superior and inferior), saphenous, and tibial arteries were not uniformly distended. Whether this condition was caused by the perfusion itself, or preexisted in the intact animal, we do not know. The quality of fixation, however, was just as good in the narrow as in the wider parts.

#### Significance of the Vacuoles

Our electron micrographs indicate that smooth muscle cells, in the media of certain arteries, can herniate into each other; and that the herniated cytoplasm can become an isolated vacuole.

Early in this study we suspected that the double membrane lining of these vacuoles indicated a derivation from mitochondria: but this suspicion was dissipated by the appearance of mitochondria *inside* some vacuoles (Figure 7A). We have also ruled out the possibility that the vacuoles represent an artifact: the myelin figures observed inside them (Figure 2B) are considerably more complex and more dense than those known to arise during the process of inadequate fixation. If they are not an artifact, then how do they develop?

The likeliest mechanism to explain the herniation of one smooth muscle cell into another is that one cell contracts and squirts its cytoplasm into a neighbor cell which has not—or not yet—contracted.

This hypothesis is supported by the work of Fay and Delise<sup>8</sup> showing that upon electrical stimulation, as well as in response to K<sup>+</sup> or acetylcholine, isolated smooth muscle cells contract and shorten, forming evaginations of the cell membrane. These bulbous projections contain few myofilaments, and their plasma membrane is relatively free of dense bodies. In a muscular artery, this mechanism would require the existence of cell-to-cell contacts susceptible to allow herniation. Such areas exist as a normal feature in vascular smooth muscle; their accepted function is to serve intercellular communication.<sup>9-11</sup> At this level, the basement membrane which surrounds each cell disappears; the two cell membranes become closely apposed, usually without any local specialization, and with an intervening space of 100 Å or more<sup>9</sup> (rare junctions of the nexus or gap junction type have been found only in the dog aorta and carotid

artery<sup>11</sup>). These areas of close contact are often flat, but sometimes one cell protrudes into the other with a pseudopod, suggesting a "peg-and-socket" joint.<sup>9,10</sup> Sometimes the "peg" bulges into a mushroom shape (Figure 8A, B, C) reminiscent of the much larger herniae illustrated in Figure 4. Rhodin has aptly noticed a structural feature of these junctions between smooth muscle cells which should make them more prone to herniate: the lack of local reinforcements, such as the "anchoring" fibrils radiating from desmosomes.<sup>9</sup>

Another mechanical condition necessary for the herniation event is that one cell should contract before its neighbor. This can be assumed to occur because the very purpose of the junctions described above is to transmit the wave of contraction from cell to cell; and in fact, it is common to see—in the media of small arteries—adjacent cells in very different stages of contraction. Contracted smooth muscle cells stand out, by electron microscopy, because of their greater density,<sup>12</sup> the scalloping of their margins, and the indentations of their nucleus. These features are also recognizable in 1- $\mu$  sections of epoxy-embedded arteries stained with toluidine blue.

We have never noticed that the herniating cell is darker than its neighbor; but since most vacuoles represent past accidents, there is little hope of catching one at the exact moment at which the herniation occurs. This point can only be proven under conditions of experimentally induced contraction; we have performed this experiment, and the results fully support our proposed sequence of events.<sup>13</sup>

#### **What Happens to the Herniated Structure?**

Small herniae are presumably reversible, much like their clinical counterparts. However, electron microscopic evidence indicates that sometimes the neck of the hernia pinches off the parent cell, so that the hernia becomes an independent vacuole, and therefore a true cell-to-cell graft. Proof of this event could only come from serial sections; however, one fact is suggestive: some of the vacuoles—and especially those that we interpret as older—have lost much of their membranous lining (inner *and* outer layer). At this stage the vacuole is no longer properly speaking a hernia, but a fluid-filled cleft inside the host cell; its former point of entry, along the cell membrane, must have sealed itself off.

Whether the vacuole is severed from the parent cell or not, its content undergoes a series of changes. The various aspects observed suggest the following sequence of events: soon after its development, the content of the vacuole resembles, in electron density, normal cytoplasm; it contains recognizable organelles (Figure 7A). Later the vacuole swells, and the

entrapped organelles disappear, giving rise to myelin figures. (It is tempting to speculate about the mechanism of this swelling. If the vacuole has become separated from the body of its cell, the sodium pump within its membrane should run out of energy and allow excessive uptake of water.) Lysosomes may empty into the vacuole and digest its contents, leading to a further decrease in electron density (Figure 7B). Later, the membranes forming its wall begin to disintegrate; presumably the myelin figures become more compact, and the vacuole slowly collapses. We cannot offer any acceptable guess as to the duration of this process. A study of rats at various ages could provide a clue.

#### Distribution of the Vacuoles Within the Arterial Tree

The most affected vessels are the uterine, spermatic, and mesenteric arteries. Their caliber range lies between the *terminal arteries* and *arterioles* in the nomenclature of Rhodin,<sup>14</sup> who places the beginning of the arterioles or "resistance vessels" roughly at 300  $\mu$ . However, the presence of vacuoles is not just a matter of caliber: the coronary arteries would be of precisely the "right" size (about 0.3 mm), yet we never found a single vacuole in dozens of blocks examined for this and for a previous study.<sup>1</sup> The diameter of the saphenous artery falls between those of the mesenteric and uterine, yet the presence of vacuoles in this vessel is exceptional.

The absence or small number of vacuoles in the larger, elastic arteries is accountable for reasons of both structure and function, and well in keeping with the herniation mechanism discussed above: a) The smooth muscle cells are physically separated into concentric layers by elastic membranes; within each layer, the cells are separated by collagen and other interstitial materials.<sup>15</sup> On the surface of each cell, the area of contact with neighboring cells is small, which means that the opportunity to herniate is also small. A further deterrent from herniation is perhaps due to the presence of "reinforced" contacts of the nexus type.<sup>11</sup> b) The smooth muscle coat of the large elastic vessels is not called upon to contract as intensely as in the arteries of smaller caliber; indeed, very little is known about the true *muscular* function of the medial coat of these large arteries, despite the many physiologic studies of aortic rings *in vitro*. Active changes in caliber of the living aorta are not described. As far as we know, the only established function of the smooth muscle cells in the large vessels is to synthesize their collagen and elastic components<sup>16-18</sup> and presumably to maintain them.

The greater number of vacuoles in small arteries can also be explained by the structure and function of these vessels: a) the smooth muscle cells are closely packed and connected by relatively extensive, weak junctions

prone to herniate; and b) they are constantly stimulated to contract, since these arteries are primarily responsible for the maintenance of the peripheral resistance.

The total absence of vacuoles in the coronary arteries is intriguing. Although we cannot explain it, we can offer the following speculation. Our current working hypothesis is that the vacuoles are an indication of the contractile demands placed upon an artery; perhaps, then, the coronary arteries in the rat are not subject to much stimulation. We might go ever further and suggest that from the number of vacuoles present in an arterial media, it may be possible to infer the intensity of vasoconstrictor stimuli affecting that particular vessel.

How easy would it be, then, to recognize the presence of vacuoles in routine sections of arteries? *A posteriori*, we have studied paraffin-embedded uterine and spermatic arteries stained with hematoxylin and eosin; having seen the vacuoles in epoxy-embedded material, it is possible to guess their presence as pale lacunae in the thickness of the media (Figure 9). They would easily escape notice (as indeed they have so far) or perhaps be dismissed as "faintly staining nuclei." On the other hand, they are rather well visible in tissues embedded in methacrylate, cut, and stained for light microscopy at 2 to 3  $\mu$ .

#### Previous Observations of Cell-to-Cell Herniae

There are very few electron microscopic studies of small arteries under normal conditions. One of the earliest<sup>19</sup> concerns the normal mesenteric arteries of the rat, where vacuoles are common, but none were mentioned: presumably they were dismissed as artifact, since vacuoles (although with a single limiting membrane) commonly arise through poor fixation.

The earliest observation of "vacuoles" in the arteriolar wall appears to be that of Suzuki *et al.*,<sup>20</sup> who studied the blood vessels in several organs of the guinea pig. The extensive vacuolation of arterial endothelia described in this paper is probably the result of fixation; however, it is noted that in the "arteries" (arterioles) of several organs the smooth muscle cells contain, "besides the nucleus, 1 or 2 vacuoles;" "remarkable vacuolation" is described in the wall of the mesenteric arteries. The two limiting membranes of all such vacuoles were also observed, although no mechanism for their origin was suggested.

Shortly thereafter, Rhodin<sup>10</sup> published a detailed study of fascial arterioles in the rabbit. His electron micrographs showing rounded cellular inclusions limited by two membranes (Figures 33-36) are virtually identical to some of our own. They were obtained from arterioles with one or at most two layers of smooth muscle cells, and therefore, they were inter-

preted, at the time, as representing one of two possible phenomena: a) *Protrusion of the endothelium into the underlying smooth muscle cell.* Protrusions of this kind certainly exist; they were first described by Rhodin<sup>9</sup> and recently also illustrated in his textbook of histology (Figures 16–34).<sup>14</sup> Rhodin interprets these “myo-endothelial junctions” as possible receptor sites where the endothelial cell may initiate the contraction of the smooth muscle. (A reverse situation has been described in retinal capillaries of the human eye, where pericytes protrude with finger-like processes into endothelial cells<sup>21</sup>). b) The other interpretation, implying that *nerve axons* are embedded into the smooth muscle cells, should now be dismissed.<sup>22</sup> It is, in fact, very difficult to observe nerve endings terminating onto the surface of smooth muscle cells<sup>9</sup>—and penetration of axons into smooth muscle cells has never been seen.

Under pathologic conditions, cellular herniae have been observed in a number of organs and tissues—especially in contractile tissues. In a study of venous congestion in the cremaster muscle, we observed balloon-like herniations of endothelial cells into pericytes, apparently occurring at the site of endothelium-to-pericyte junctions (comparable to Rhodin’s myo-endothelial junctions).<sup>23</sup> Hoff and Gottlob<sup>24</sup> injured the rabbit aorta by various means, including hemorrhagic shock, and noticed protrusions arising from smooth muscle cells, poking outward through fenestrae of the internal elastic membrane, and bulging into the body of endothelial cells. Hoff *et al.*<sup>25</sup> also examined the rabbit aorta 10 to 15 minutes after ligation: endothelial vacuoles bordered by two membranes were interpreted as probable sections of pseudopodia arising from neighboring smooth muscle or endothelial cells. Similar structures were observed by Cooke and Smith<sup>26</sup> in the untouched aorta of the white Carneau pigeon, which develops spontaneous atherosclerosis. The media of these birds is different from that of mammals in that it contains two types of cells, muscular and nonmuscular. In this media, “clusters of bleb-like surface differentiations from smooth muscle cells pass through fenestrations in the elastic laminae and impinge upon adjacent . . . cells.” Some of these “surface differentiations,” once embedded into neighboring cells, give rise to structures similar to our vacuoles. It is not clear whether they are interpreted as normal events or as an expression of early atherosclerosis.

Cellular herniations have also been described, but not always recognized as such, in the myocardium. Definite, small herniations were described in 1967 by Page<sup>27</sup> in normal cat hearts; they formed across the intercalated disc. In small arteries of dog heart homografts, Kosek *et al.*<sup>28</sup> saw many “vacuoles;” one structure labeled “cytosegresome” (Figure 9) has two membranes and is almost certainly a hernia. Large, clear vacuoles

were found by De la Iglesia *et al.*<sup>29</sup> as early as 5 hours after coronary narrowing in the pig; mitochondria were present in some of the vacuoles, and the electron micrographs clearly show that their "membrane" is double; there is little doubt that they are herniae. Definite herniations in myocardial fibers, that were recognized as such, were strikingly illustrated by Csapó *et al.*<sup>30</sup> in the myocardium of rats injected with isoproterenol. Beginning already 4 to 15 minutes after the injection, herniations formed across the intercalated disc; interestingly, "the cells that herniated were generally fixed in the state of hypercontraction, while the recipient cells were in relaxation". Similar observations were made by Ratliff *et al.*<sup>31</sup> in the heart of cats submitted to hemorrhagic shock; again, the herniae formed across the intercalated disc, with a narrow neck at that level.

In all the situations described above, it is not known whether herniation may eventually proceed to the stage of a separate, discrete vacuole, as happens in smooth muscle. However, one general lesson that may be learned from all these findings is that an intracellular structure limited by two membranes probably arose by protrusion of one cell into another. It is true, of course, that mitochondria are also limited by two membranes—an exception among all intercellular organelles; but in fact, this intriguing peculiarity of mitochondria once led J. D. Robertson<sup>32</sup> to speculate that these organelles, too, may arise through herniation of the cell into itself.

#### **Are the Medial Vacuoles a Sign of Cellular Disease?**

In the beginning of this study, when we were focusing almost exclusively on the uterine and spermatic arteries, we believed that we were dealing with an abnormal condition peculiar to these vessels. Later we found that vacuolation of medial cells depended primarily on the small caliber of the artery (although small arteries of some beds were more affected than others). The question therefore arose, whether this condition, which appears to develop through normal function, represents a cellular disease.

Small cellular *herniae*, as we have documented in this discussion, certainly can be normal structures, and as such they presumably have a physiologic function. When they increase in size and pinch off as vacuoles, they presumably lose that function; this event can be labeled abnormal, even if it does not visibly endanger the life of either cell—and especially when many vacuoles are present within one cell (Figure 10).

At present, we feel that vacuole formation in the wall of small arteries is a cellular accident, resulting from an intrinsic defect—or weak point—in the fine structure of the media and brought about by functional demands. If this is true, then an exaggeration of such demands should increase the

incidence of vacuolation. We tested this hypothesis by examining small arteries submitted to pharmacologic spasm, as well as arteries of hypertensive animals. Our expectations were borne out; the results of these experiments will be published shortly.<sup>13</sup>

## References

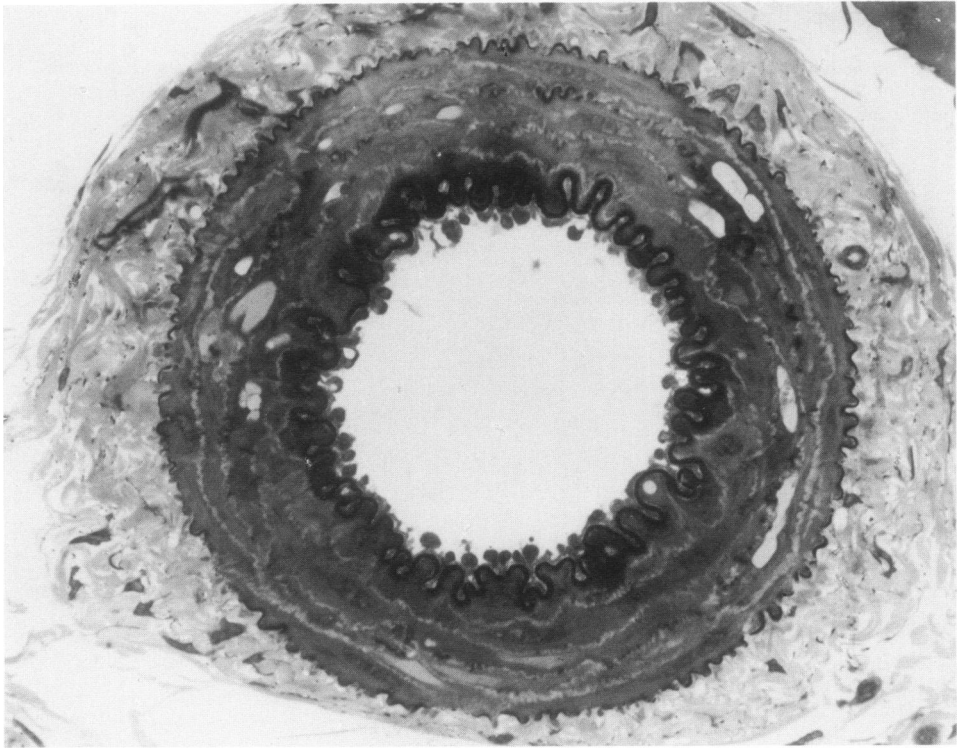
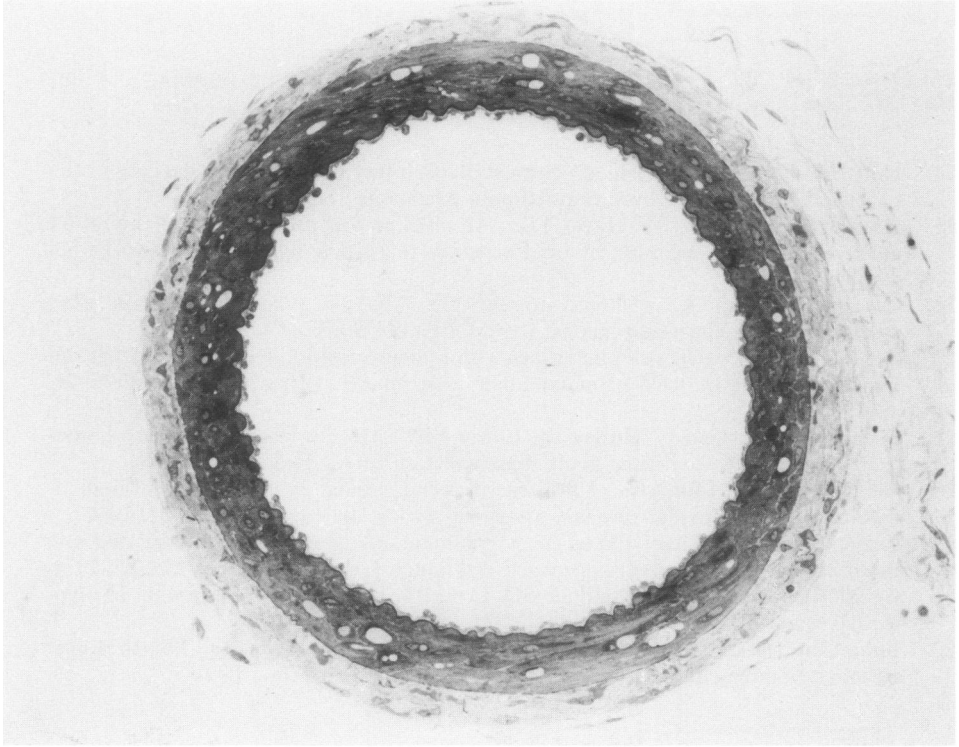
1. Joris I, Majno G: Cellular breakdown within the arterial wall: An ultrastructural study of the coronary artery in young and aging rats. *Virchows Arch Pathol Anat Histol* 364:111-127, 1974
2. Karnovsky MJ: A formaldehyde-glutaraldehyde fixative of high osmolality for use in electron microscopy. *J Cell Biol* 27:137A-138A, 1965
3. Greene EC: *Anatomy of the Rat*. Hafner Publishing Co., New York, 1955
4. Luft JH: Improvements in epoxy resin embedding methods. *J Biophys Biochem Cytol* 9:409-414, 1961
5. Reynolds ES: The use of lead citrate at high pH as an electron-opaque stain in electron microscopy. *J Cell Biol* 17:208-212, 1963
6. Fahmy A: An extemporaneous lead citrate stain for electron microscopy. *Proceedings of the Electron Microscopy Society of America*, 1967, pp 148-149
7. Papanicolaou GN: Memorandum on staining (prepared for distribution with supplement No. 2 to the Atlas of Exfoliative Cytology. Cambridge, Mass., Harvard University Press, 1960)
8. Fay FS, Delise CM: Contraction of isolated smooth muscle cells: Structural changes. *Proc Natl Acad Sci USA* 70:641-645, 1973
9. Rhodin JAG: Fine structure of vascular walls in mammals: With special reference to smooth muscle component. *Physiol Rev* 42(Suppl 5):48-87, 1962
10. Rhodin JAG: The ultrastructure of mammalian arterioles and precapillary sphincters. *J Ultrastruct Res* 18:181-223, 1967
11. Henderson RM: Types of cell contacts in arterial smooth muscle. *Experientia* 31:103-105, 1975
12. Lane BP: Alterations in the cytologic detail of intestinal smooth muscle cells in various stages of contraction. *J Cell Biol* 27:199-213, 1965
13. Joris I, Majno G: Cell-to-cell herniae in the arterial wall. II. The effect of drug-induced spasm. Unpublished data
14. Rhodin JAG: *Histology: A Text and Atlas*. New York, Oxford University Press, 1974
15. Gerrity RG, Cliff WJ: The aortic tunica media of the developing rat. I. Quantitative stereologic and biochemical analysis. *Lab Invest* 32:585-600, 1975
16. Ross R, Klebanoff SJ: The smooth muscle cell. I. In vivo synthesis of connective tissue proteins. *J Cell Biol* 50:159-171, 1971
17. Ross R: The smooth muscle cell. II. Growth of smooth muscle in culture and formation of elastic fibers. *J Cell Biol* 50:172-186, 1971
18. Narayanan AS, Sandberg LB, Ross R, Layman DL: The smooth muscle cell. III. Elastin synthesis in arterial smooth muscle cell culture. *J Cell Biol* 68:411-419, 1976
19. Matthews MA, Gardner DL: The fine structure of the mesenteric arteries of the rat. *Angiology* 17:902-928, 1966
20. Suzuki Y, Osada M, Watanabe A: Cytological and electron microscopical observations on the vascular system of the various organs and mesentery of guinea pigs, with special reference to the endothelial cells. *Arch Histol Jap* 22:477-514, 1962
21. Matsusaka T: Tridimensional views of the relationship of pericytes to endothelial cells of capillaries in the human choroid and retina. *J Electron Microsc* 24:13-18, 1975
22. Rhodin JAG: Personal communication
23. Majno G, Leventhal M: Unpublished observations



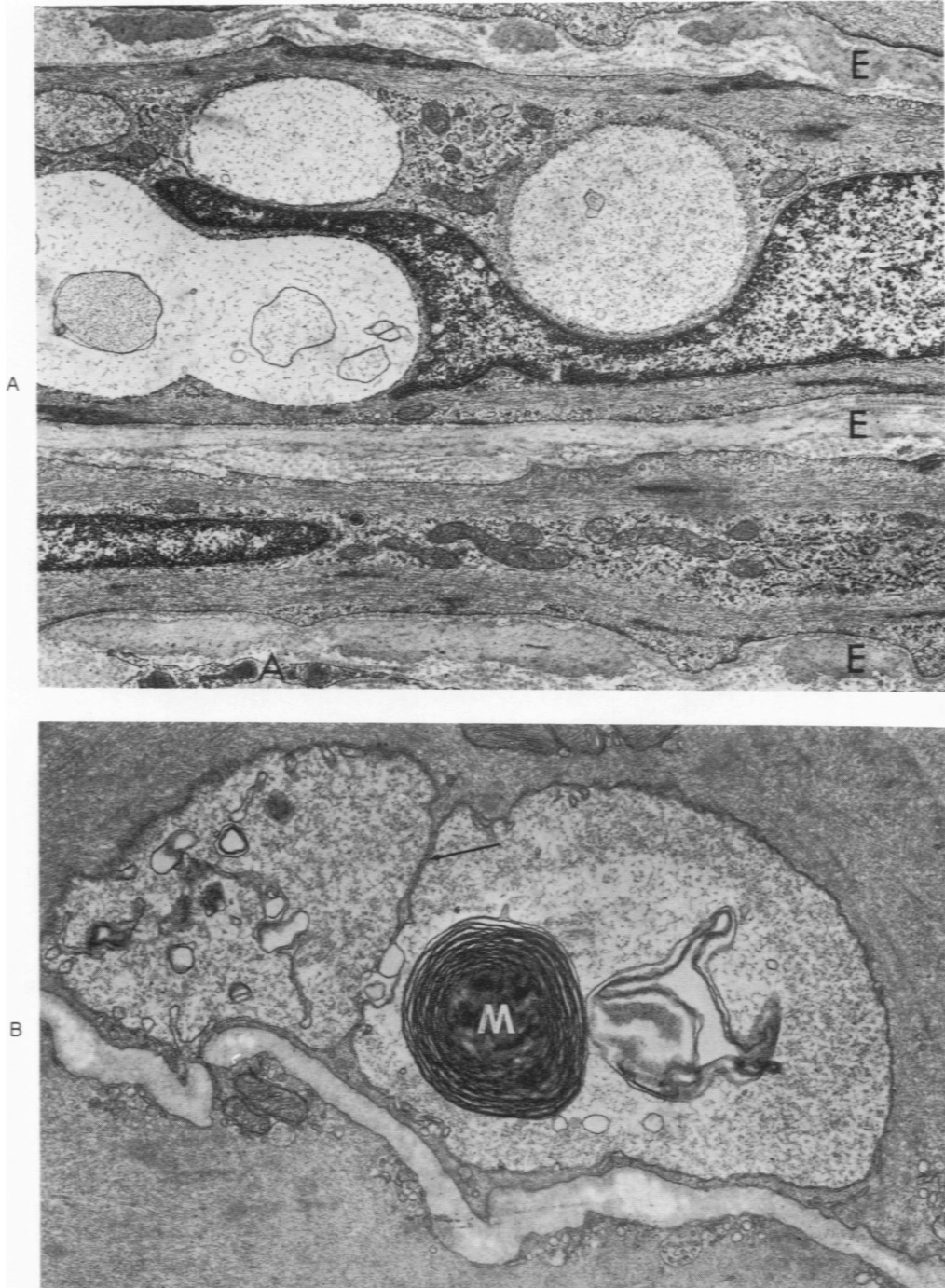
24. Hoff HF, Gottlob R: A fine structure study of injury to the endothelial cells of the rabbit abdominal aorta by various stimuli. *Angiology* 18:440-451, 1967
25. Hoff HF, McDonald LW, Hayes TL: An electron microscope study of the rabbit aortic intima after occlusion by brief exposure to a single ligature. *Br J Exp Pathol* 49:68-73, 1968
26. Cooke PH, Smith SC: Smooth muscle cells: The source of foam cells in atherosclerotic white Carneau pigeons. *Exp Mol Pathol* 8:171-189, 1968
27. Page E: The occurrence of inclusions within membrane-limited structures that run longitudinally in the cells of mammalian heart muscle. *J Ultrastruct Res* 17:63-71, 1967
28. Kosek JC, Chartrand C, Hurley EJ, Lower RR: Arteries in canine cardiac homografts: Ultrastructure during acute rejection. *Lab Invest* 21:328-335, 1969
29. De la Iglesia FA, Lumb G: Ultrastructural and circulatory alterations of the myocardium in experimental coronary artery narrowing. *Lab Invest* 27:17-31, 1972
30. Csapó Z, Dušek J, Rona G: Peculiar myofilament changes near the intercalated disc in isoproterenol-induced cardiac muscle cell injury. *J Mol Cell Cardiol* 6:79-83, 1974
31. Ratliff NB, Kopelman RI, Goldner RD, Cruz PT, Hackel DB: Formation of myocardial zonal lesions. *Am J Pathol* 79:321-334, 1975
32. Robertson JD: Cell membrane and the origin of mitochondria. Fourth International Neurochemical Symposium. Oxford, Pergamon Press, 1960

## Acknowledgments

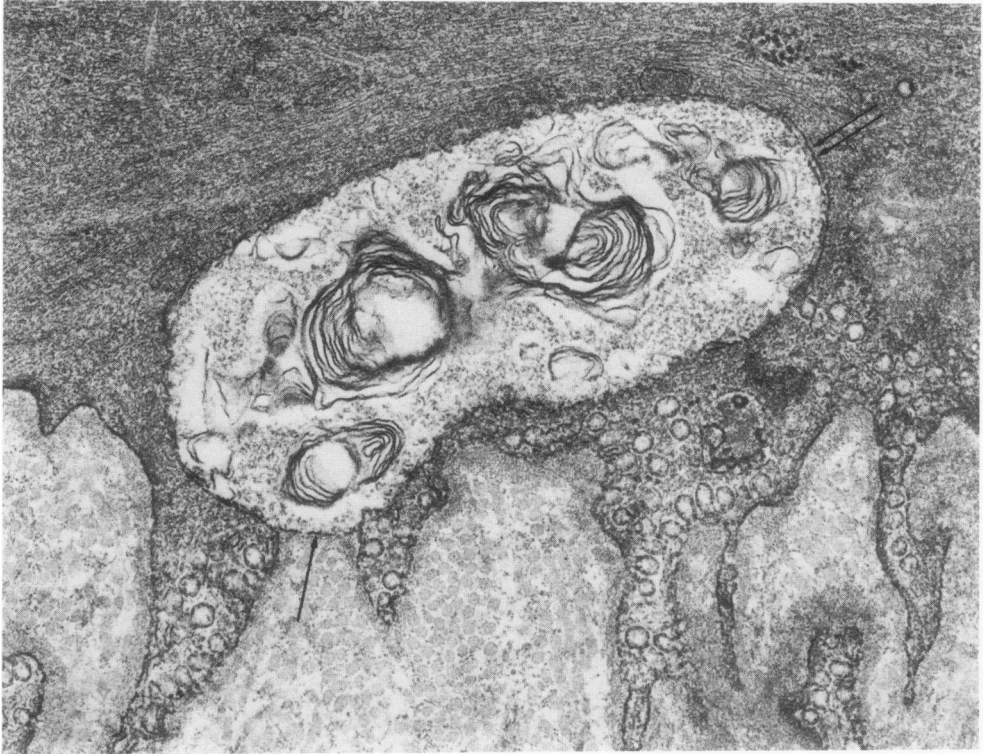
We are indebted to Jean M. Underwood, Angela Valu, Nancy H. Bull, and Dolores Charron for excellent technical assistance, to Peter W. Healey and Joseph Harvey Royer for the photographic prints, and to Karen E. Melia for secretarial help.



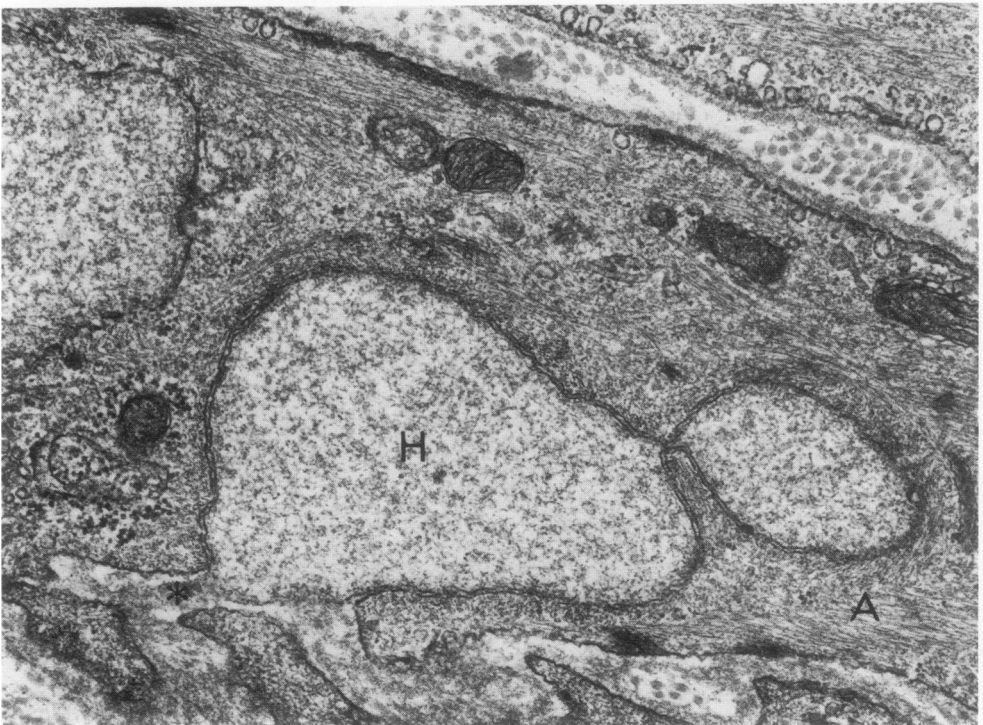
**Figure 1**—Normal uterine arteries from 2 rats, fixed by perfusion and embedded in Epon; 1- $\mu$  sections were stained with toluidine blue. **A**—Example of artery in a state of near-complete distention. About 40 vacuoles are visible in the media; actual diameter, 0.38 mm. ( $\times 300$ ) **B**—Example of artery that was found in a contracted state, although it had been fixed in the same manner as the artery above (note folded internal and external elastic membranes). Actual diameter, 0.14 mm. ( $\times 660$ )



**Figure 2—A—Uterine artery; vacuoles of different densities impinge upon the nucleus of a smooth muscle cell in the media. A = adventitia, E = elastin ( $\times 10,800$ ) B—Spermatic artery, media. Adjacent vacuoles in smooth muscle cells; each one is lined by two membranes (best visible at arrow). The large and complex myelin figure (M) indicates that the corresponding vacuole could not have formed during fixation. ( $\times 25,500$ )**

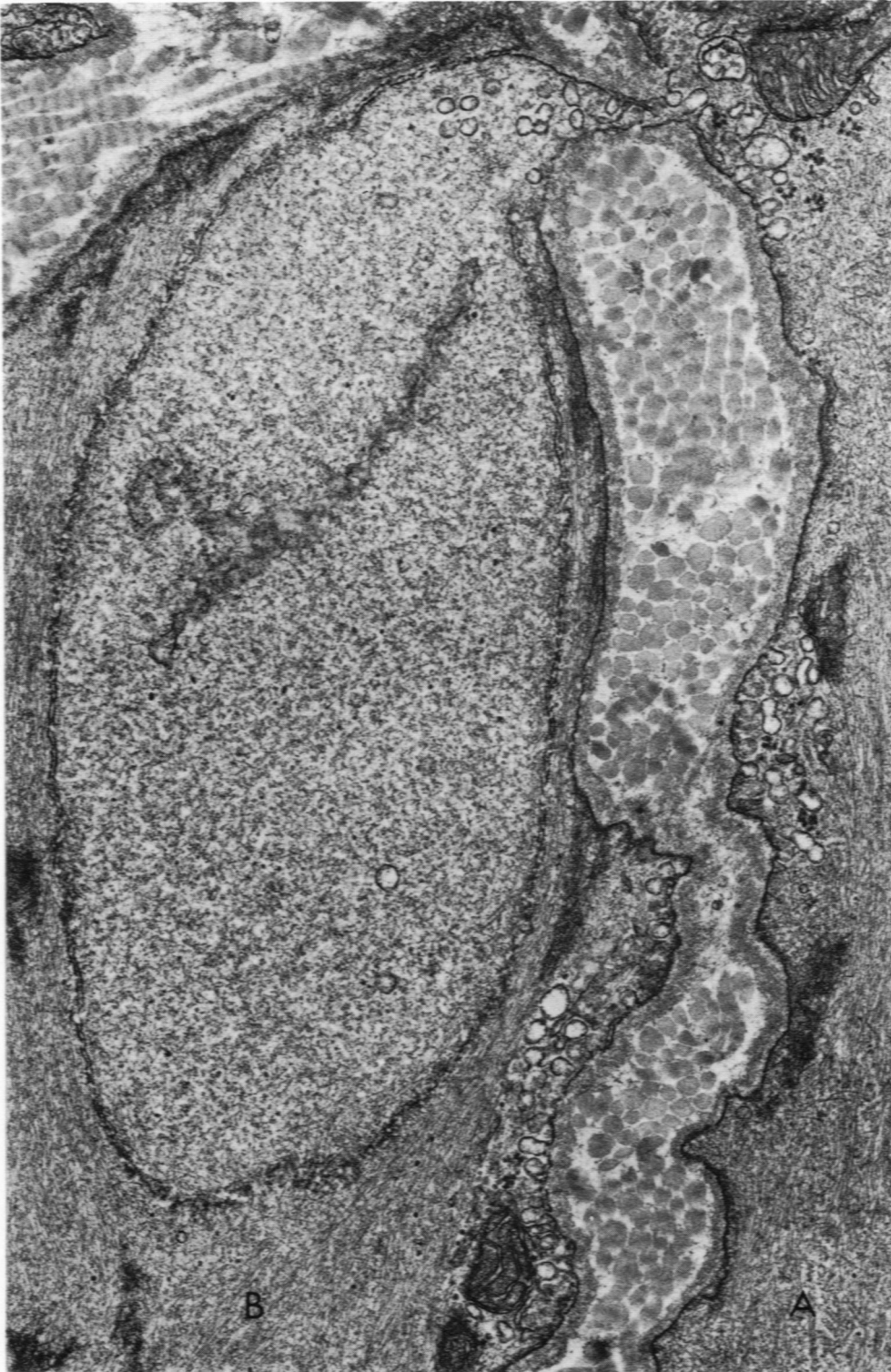


A



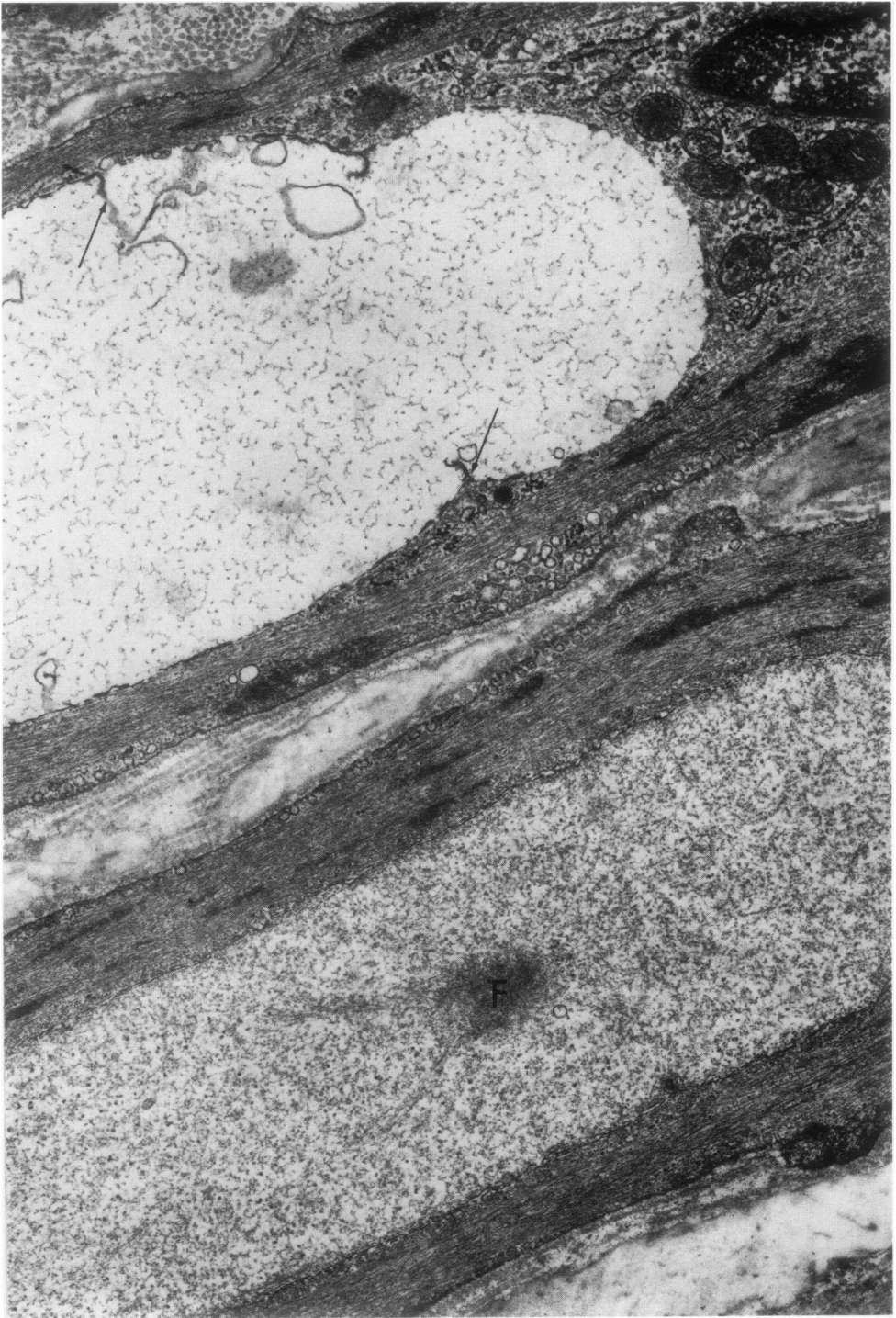
B

**Figure 3**—From the media of uterine arteries. **A**—Vacuole limited by two membranes (*double arrows*), except where it surfaces to the extracellular space, where it has only one membrane (*single arrow*): this “open” zone could well correspond to the point of entry of the hernia which produced the vacuole. Note the many myelin figures in the vacuole. ( $\times 37,500$ ) **B**—The structure labeled *H* could be a hernia penetrating into the cell (*A*); if so, the area indicated (\*) would be a grazing view of the stalk. Note the “budding” process, and the obvious double lining membranes (except at the point of entry, as in the figure above). ( $\times 32,300$ )

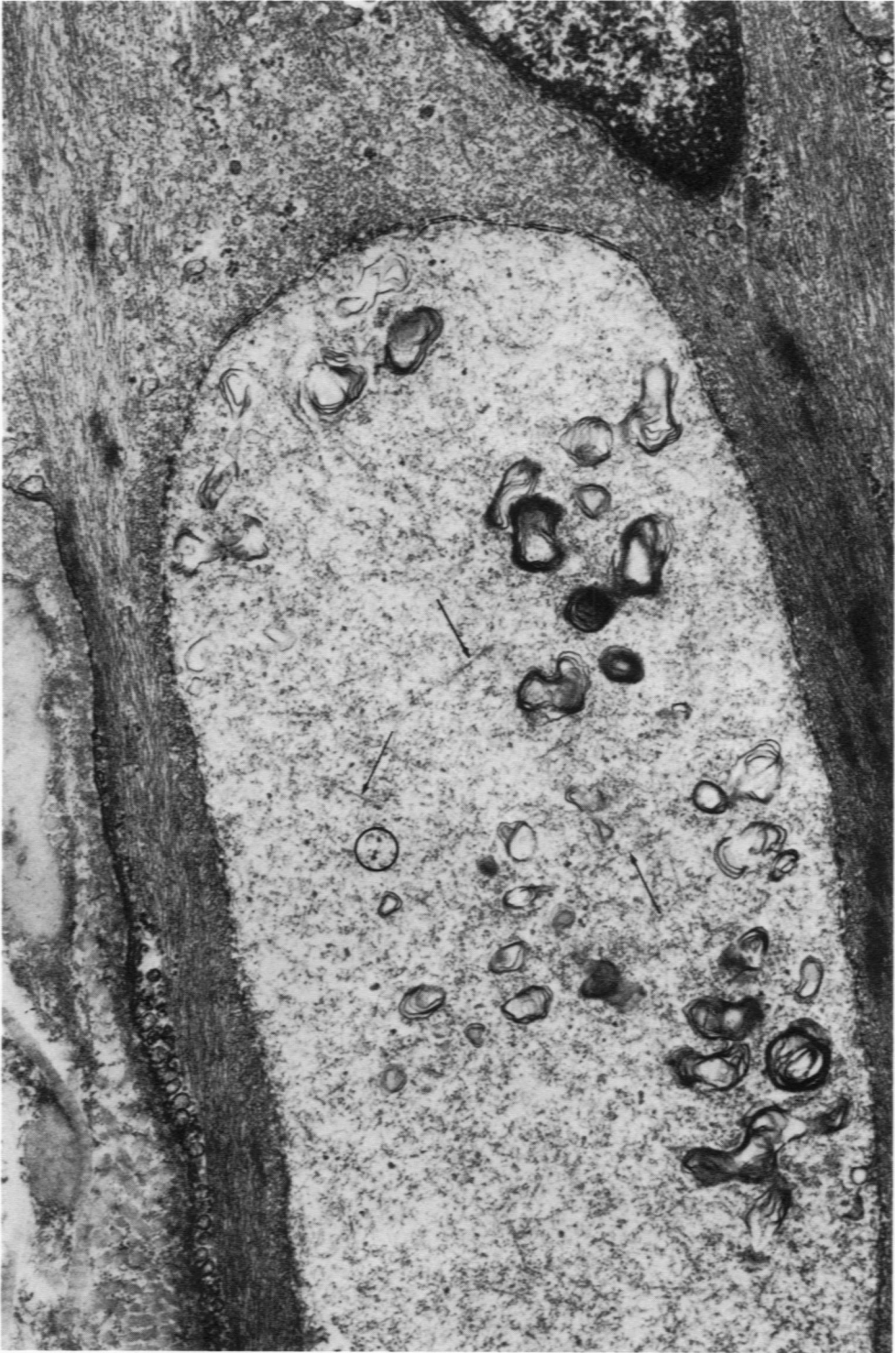

**Figure 4**—From the media of a spermatic artery. Typical herniation of one smooth muscle cell (A) into its neighbor (B). The stalk of the hernia is well visible in this plane of section; its thickness is about the same as that of a routine ultrathin section. The density of the herniated mass is so similar to that of the cells that it would not be visible by light microscopy ( $\times 37,500$ )

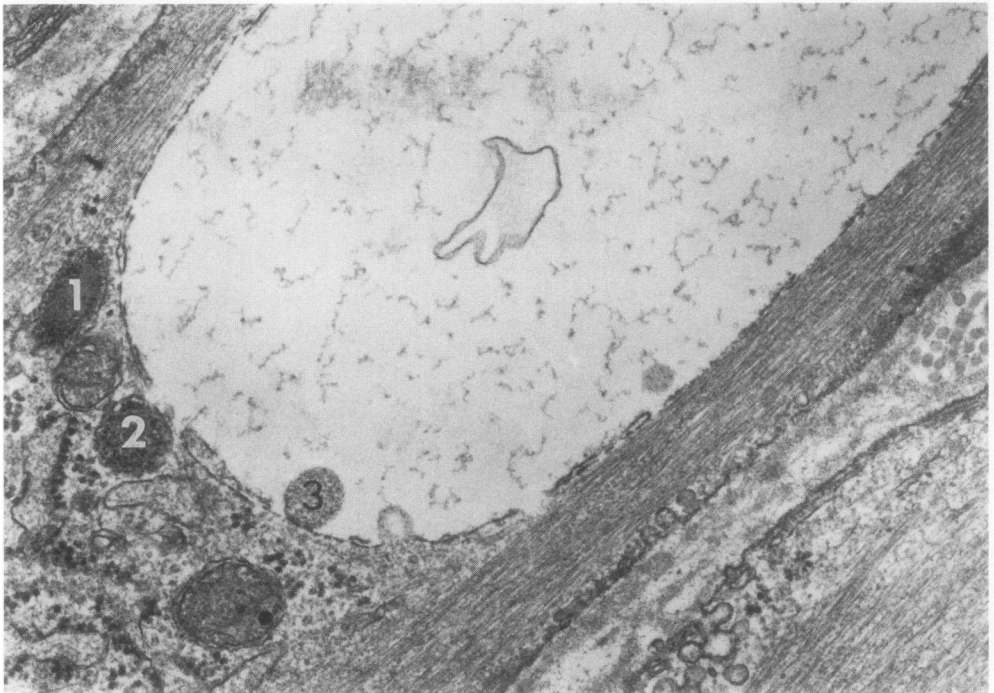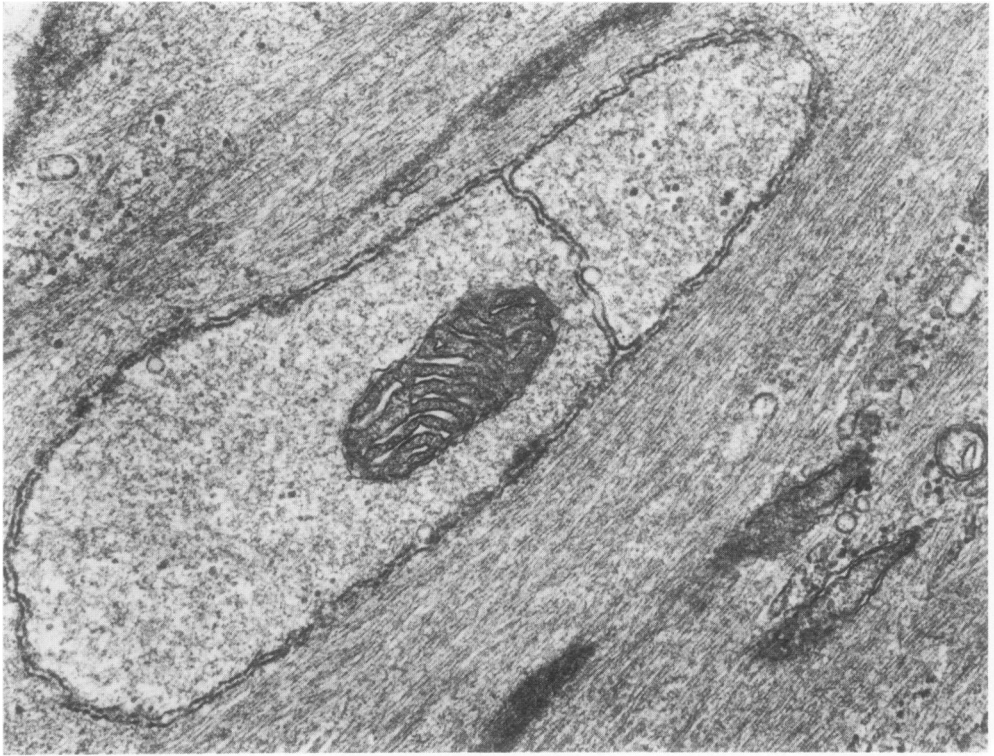




**Figure 5**—From the media of a uterine artery. Two adjacent smooth muscle cells with large vacuoles of different content. The denser vacuole is probably the most recent: it contains recognizable fibrils (*F*), and a scattering of granules (probably glycogen); its two lining membranes are fairly well preserved. In the upper, more “watery” vacuole, the lining membranes are breaking down and giving rise to small myelin figures (*arrows*). ( $\times 23,100$ )

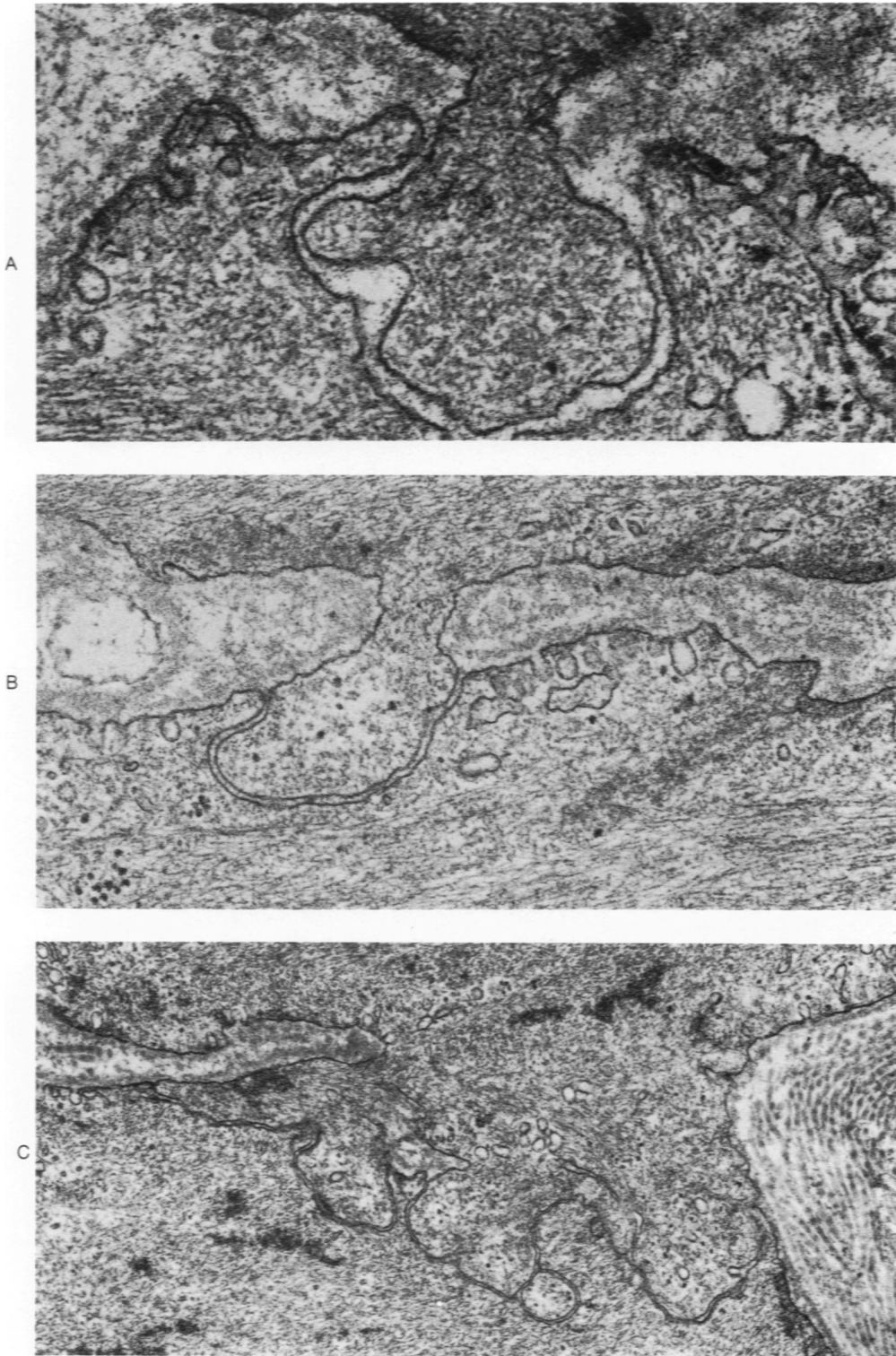


**Figure 6**—Uterine artery; part of a large vacuole inside a medial smooth muscle cell. Its two membranes are well visible at the top. In the lumen, many myelin figures, fibrils (arrows), and a few granules, presumably glycogen (*circle*). ( $\times 31,500$ )

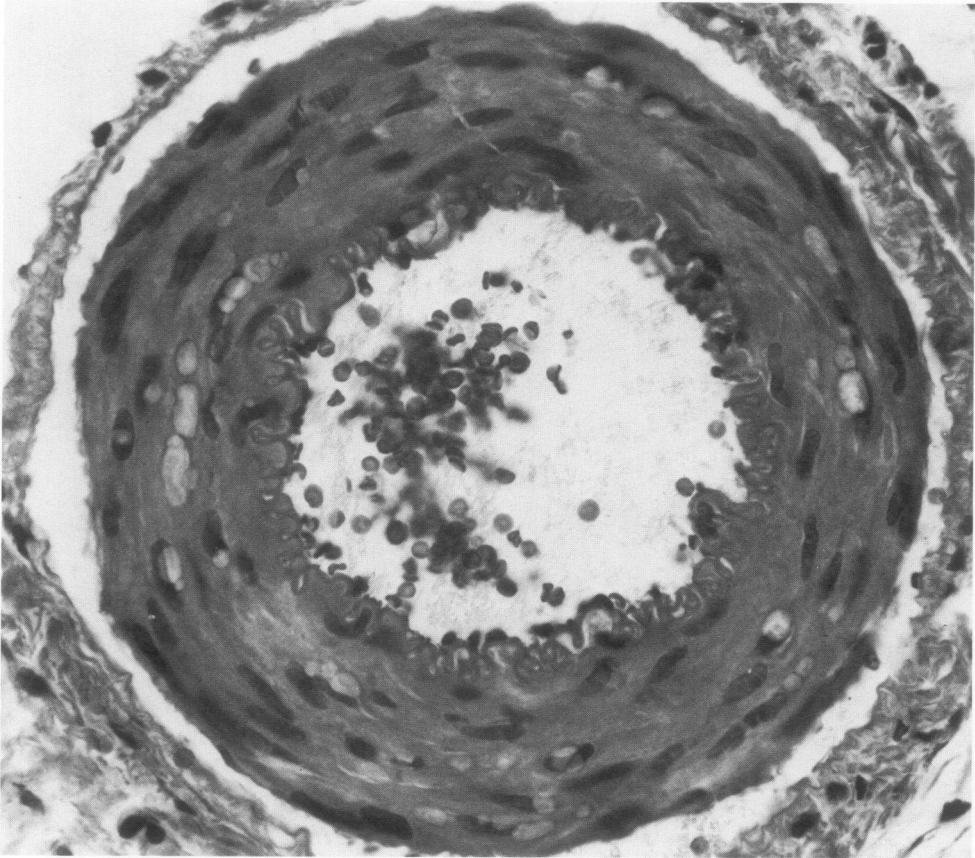


**Figure 7A**—A relatively small vacuole with two compartments, the largest containing a mitochondrion. The density of the vacuole content approaches that of the smooth muscle cell; when this occurs, it is doubtful that a vacuole could be seen by light microscopy. Media of a spermatic artery. ( $\times 45,000$ ) **B**—Part of a large clear vacuole in a smooth muscle cell. One lysosome (1) is close to the vacuole; another (2) appears to have made contact with its membranous lining; a third one (3) is entirely contained within the vacuole, and has no visible membrane. These may represent stages in lysosomal digestion of the vacuole content and may explain its very dilute aspect. Media of a uterine artery. ( $\times 47,500$ )

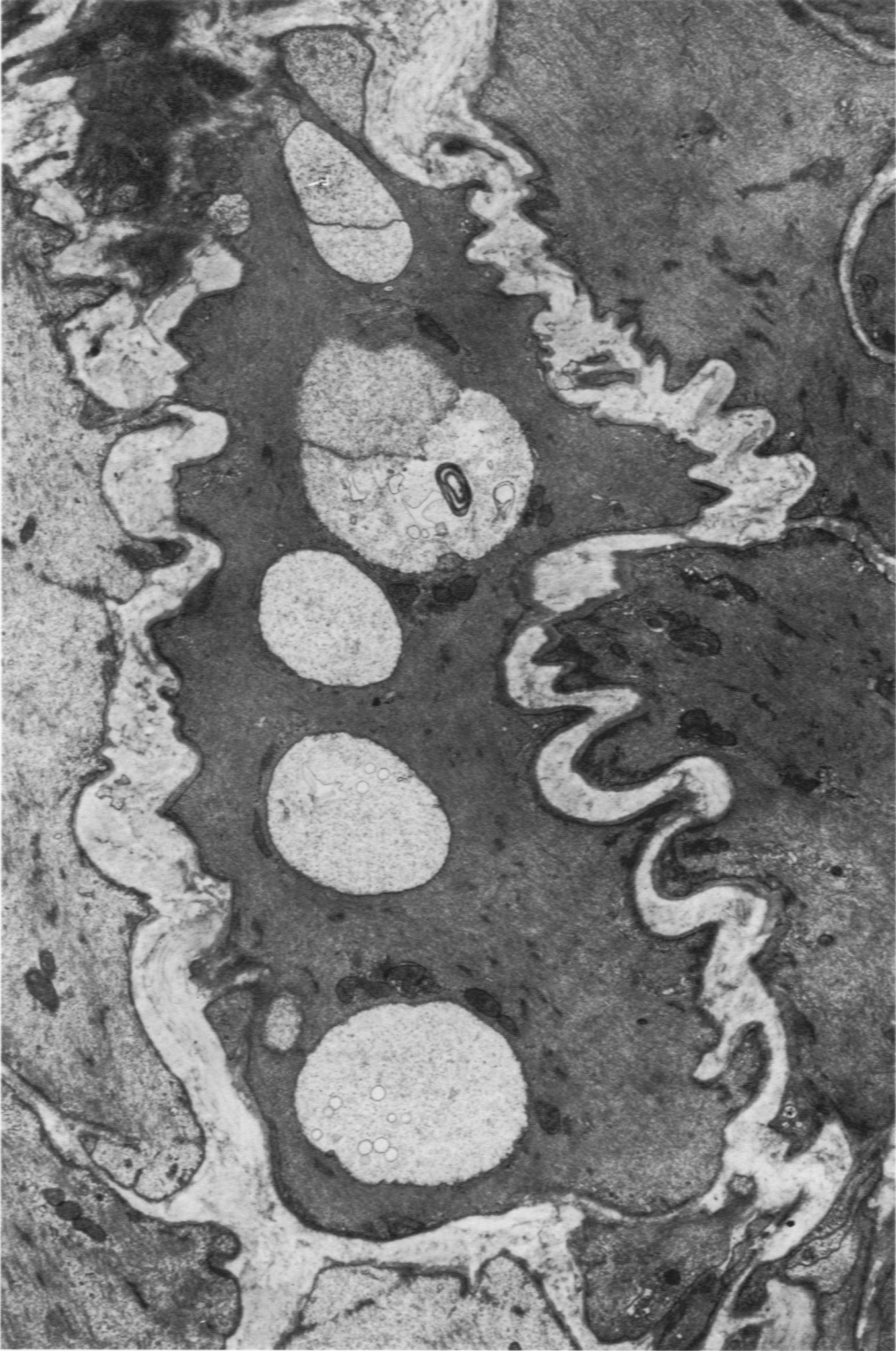



**Figure 8**—Three types of “peg and socket” connections between smooth muscle cells, a normal feature of the arterial media, probably related to intercellular communication. Note the rather surprising absence of membrane specializations along these close contacts. These structures could well be the weak points where cell-to-cell herniation occurs. Uterine arteries. (A,  $\times 82,500$ ; B,  $\times 47,500$ ; C,  $\times 27,500$ )



**Figure 9**—Uterine artery, paraffin embedded. Vacuoles in the media are readily recognizable. (Formalin fixation without perfusion, H&E,  $\times 500$ )



**Figure 10**—Rat spermatic artery. A medial smooth muscle cell with many vacuoles in its cytoplasm. ( $\times 78,200$ )

*[End of Article]*