

# Changes in Bone and Bone Marrow of Rabbits Bearing the VX-2 Carcinoma

## *A Comparison of Local and Distant Effects*

Aubrey Hough, Jr., MD, Hannsjoerg Seyberth, MD, John Oates, MD,  
and William Hartmann, MD

The VX-2 carcinoma in 32 New Zealand white rabbits was studied morphologically with respect to the osseous effects induced by the inoculation and subsequent growth of tumor in the soft tissues over periods ranging from 1 to 5 weeks. Although more severe changes were noted in bones of tumor-bearing than in non-tumor-bearing limbs, effects could be seen in both experimental situations. Severe bone marrow hyperplasia was noted consistently in tumor-bearing animals. A marked increase in numbers of osteoclasts over control rabbit bones was observed along the surface of bones near and distant from the tumor. Resorptive changes were also noted in the cortex of tumor-bearing rabbits. The increase in osteoclast numbers was related chronologically to the development of hypercalcemia and was proportional to the degree of hypercalcemia at the time the animals died. The number of osteoclasts was inversely proportional to the serum creatinine. A diminution of osteoclast numbers was noted in the latter stages of the disease. These changes may be the morphologic expression of humoral hypercalcemia accompanying the VX-2 carcinoma. (*Am J Pathol* 87:537-552, 1977)

THE PHENOMENON of malignancy-associated hypercalcemia is a common clinical<sup>1-3</sup> and experimental<sup>4-7</sup> entity. Most of these examples<sup>8</sup> result from overt destruction of bone by metastatic tumor.<sup>9</sup> There exists, however, another class of malignancy-associated hypercalcemias where bony metastases are absent or inconspicuous and various humoral mediators have been identified.<sup>4-7,10</sup> One example of this group is the VX-2 carcinoma of New Zealand white rabbits.<sup>11</sup> This tumor, originally described after a spontaneous malignant change in a virus-induced cutaneous papilloma,<sup>12</sup> induces severe hypercalcemia,<sup>13</sup> presumably by production of prostaglandin E<sub>2</sub><sup>11</sup> or a related substance.<sup>13</sup> This paper describes the natural history of the VX-2 carcinoma in the soft tissues of the rabbit thigh, the local and remote osseous changes which result from this growth, and the relationship of the chemical to the osteopathology.

---

From the Departments of Pathology and Pharmacology, Vanderbilt School of Medicine, and the Veterans Administration Hospital, Nashville, Tennessee.

Supported in part by Grant GM-15431 from the US Public Health Service and by the Veterans Administration Medical Research Service; Dr. Oates is the Joe and Morris Werthan Professor of Investigative Medicine; Dr. Hough is a fellow of the American Cancer Society; Dr. Seyberth is supported by the Deutsche Forschungsgemeinschaft.

Address reprint requests to Dr. Aubrey Hough, Jr., Department of Pathology, School of Medicine, Vanderbilt University, Nashville, TN 37232.

## Materials and Methods

Female New Zealand white rabbits weighing 1.5 to 3.0 kg were fed Wayne rabbit ration and water *ad libitum*. A rabbit bearing the tumor was generously supplied by Dr. E. F. Voelkel of Harvard Medical School. Propagation of the tumor was by the method of Voelkel *et. al.*<sup>11</sup> Tumor tissue was removed aseptically after 2 to 3 weeks of growth and gently homogenized in sterile saline using a hand-driven Teflon pestle; 1 g of tumor was injected into the muscles of each thigh. Care was taken to discard nonviable tumor fragments. Replantation for purposes of propagation was carried out at 2- to 3-week intervals.

Calcium and creatinine values were obtained using a Dupont Automatic Clinical Analyzer. Ten tumor-bearing rabbits were housed in metabolic cages, and their urine was collected under refrigerated conditions. Aliquots were stored at  $-70^{\circ}\text{C}$ . The major urinary metabolite of prostaglandin  $\text{E}_2$  ( $7\alpha$ -hydroxy-5,11-diketotetranorprostane-1,16-dioic acid, PGE-M) was determined using the method of Hamberg<sup>14</sup> and expressed as micrograms per gram urinary creatinine.

The long bones of forelimbs and hindlimbs were excised from 32 female New Zealand white rabbits bearing the VX-2 carcinoma for periods of 1 to 6 weeks. In addition, bones of 5 normal female rabbits of the same age, size, and source were utilized as controls. The bones were dissected free of soft tissues, attention being given to retaining the periosteum intact, and immediately sawed in the sagittal plane. Care was taken to obtain a midline plane of section parallel to the long axis of the bone to minimize possible variation in osteoclast numbers due to a tangential section. Bones were fixed in either 4% formaldehyde buffered with 2% sodium citrate or in Zenker's (Technicon) solution. After fixation for 24 to 48 hours, the bones were decalcified in 5% unbuffered formic acid. After decalcification, the specimens were further trimmed to provide a complete midline, longitudinal section of each bone. The bone specimens were then bisected perpendicular to the long axis, washed in cold running water for 24 hours, dehydrated, embedded in paraffin, sectioned at  $4\ \mu$  on a Leitz 1212 rotary or Lipshaw 80A sliding microtome and stained with Harris hematoxylin and eosin-phloxine. For each animal, two sections were prepared from each of eight sites: proximal and distal halves of femur, tibia, and humerus, as well as distal halves of radius and ulna.

After evaluation of each microscopic section to verify a complete cross-section, the diaphyseal portion was demarcated by a line drawn 1 mm below the intersection of the most remote epiphyseal cancellous bone and the diaphyseal cortex. The overall distance between this line and the midpoint of the bisected bone was measured with a micrometer. Using a  $40\times$  objective, the number of periosteal osteoclasts counted in this defined distance was expressed as osteoclasts per millimeter of cortex for each of eight sites studied. In addition, the mean osteoclast count of the four hindlimb and four forelimb sites was calculated for each animal. No information relative to serum calcium and creatinine concentration or stage of tumor growth was available to the observer during this counting process.

Sections were also prepared from thyroid glands, parathyroid glands, and kidneys of both control and tumor-bearing animals. Histologic sections of tumor also were prepared at 1 through 5 weeks of growth, and the percentage of viable tumor estimated using a Zeiss integrating ocular. The presence or absence of osteomalacia was determined on portions of undecalcified bone using a modification of the technique of Xipell<sup>15</sup> with subsequent staining by von Kossa's silver nitrate.<sup>16</sup>

Small portions of tumor from animals sacrificed after various periods of growth were fixed in 2.0% phosphate-buffered glutaraldehyde, postfixed in 1.0% phosphate-buffered osmic acid, dehydrated in graded alcohols, embedded in Epon 812, sectioned at 100 nm on an LKB ultramicrotome, stained with uranyl acetate and lead citrate, and examined in a Philips EM 200 operating at 80 kV.

## Results

### Natural History of the VX-2 Carcinoma

Small foci of tumor could be identified microscopically within the thigh musculature as soon as 1 week after injection of tumor cells. Thereafter, the tumor grew rapidly so that by 2 weeks of growth a total of 6 to 20 g (mean  $\pm$  SD,  $10 \pm 4.5$  g) of grossly viable tumor tissue could be removed from the rabbit thigh muscles. At 5 weeks, however, large cystic areas of necrosis were noted (Figure 1). The amount of viable tumor did not increase after the third week of growth, falling from 84% of total tumor at 2 weeks to 12% at 5 weeks.

The histology of early tumors was that of a poorly differentiated carcinoma growing in membrane-bounded nests within the soft tissues (Figure 2). Necrosis of individual cells was uncommon. Confluent areas of necrosis were not seen at this stage. Degeneration occurred rapidly, and by 4 to 5 weeks of growth, viable tumor was confined to the walls of cystic spaces. Although granulocytic inflammatory responses frequently occurred within the tumors, lymphoid infiltration of the tumor capsules was inconspicuous.

Although keratinization could not be detected by light microscopy, the epidermoid character of the tumor was confirmed by transmission electron microscopy. Ultrastructural examination uniformly disclosed numerous tonofilaments and desmosomes typical of an epidermoid or squamous carcinoma (Figure 3). In many cells, dense aggregates of tonofilaments were identified. Active growth and protein synthesis were suggested by numerous aggregated ribosomes, dispersed chromatin, and prominent nucleoli. Features suggestive of cellular secretory activity such as rough and smooth endoplasmic reticulum and Golgi apparatus, although present, were not prominent. In 2 animals treated with indomethacin (20 mg/kg), the tumor did not differ in ultrastructural appearance from that in the nine untreated tumors examined by electron microscopy.

Necropsy of 32 tumor-bearing animals revealed spread of the tumor beyond the soft tissues of the hindlimb in only 4 cases. In 1 instance, tumor entered the femoral diaphysis by direct extension through a microfracture. In two others, pulmonary metastases were identified, and a single animal harbored a microscopic renal metastasis. All 4 instances of metastasis occurred in animals bearing tumors for at least 4 weeks. Examination of thyroid, parathyroid, and adrenal glands disclosed no detectable histologic abnormalities. Although the tumor-bearing animals were fed *ad libitum*, their weights remained stable or fell slightly relative to the control group.

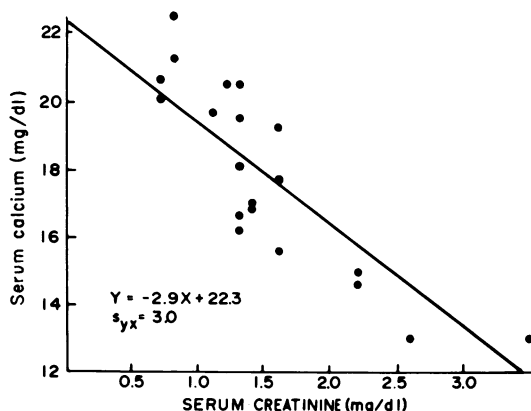
Renal degenerative changes were present in 8 of 10 animals bearing tumors for at least 4 weeks. These included glomerular and tubular obsolescence, interstitial inflammation and scarring, and nephrocalcinosis. Animals found dead were uniformly severely affected.

The natural history of the disease was also studied chemically by measuring serum calcium, serum creatinine, and urinary PGE-M. In 23 of the 32 tumor-bearing rabbits, serum calcium and creatinine values were obtained at or near the death of the animal. Serum calcium rose from  $15.6 \pm 0.2$  mg/dl (95% confidence limits) in control animals to  $18.6 \pm 1.4$  and  $19.2 \pm 1.9$  mg/dl at 2 and 3 weeks of tumor growth, respectively. However, at 4 and 5 weeks of growth, values for serum calcium were lower than at 3 weeks. Serum creatinine values showed a progressive rise from  $0.65 \pm 0.25$  mg/dl at 1 week to  $1.84 \pm 0.45$  mg/dl at 4 weeks of tumor growth, reflecting the deterioration in renal histology noted previously. After the animals had become hypercalcemic (about 2 weeks of tumor growth) the serum calcium and creatinine demonstrated an inverse relationship ( $r = -0.75$ ) as seen in Text-figure 1. The mean creatinine of animals with advanced tumors was significantly greater ( $P < 0.05$ ) than those in the 2 to 3 week stages of tumor growth.

Urinary PGE-M values increased from  $6.5 \pm 2.1$   $\mu$ g/g creatinine in control animals to  $20.5 \pm 12.5$  and  $32.5 \pm 15.0$   $\mu$ g/g creatinine at 3 and 4 weeks of tumor growth.

#### Comparison of Osseous Changes

When compared with bones of control animals, those in tumor-bearing rabbits demonstrated changes in sites both distant from and in proximity to the tumor. Most alterations were a matter of degree. An example of this



TEXT-FIGURE 1—Regression line of serum calcium and serum creatinine in 20 VX-2 carcinoma-bearing rabbits. All animals were or had been hypercalcemic and had borne the tumor for 2 weeks or more. An inverse relationship is apparent.

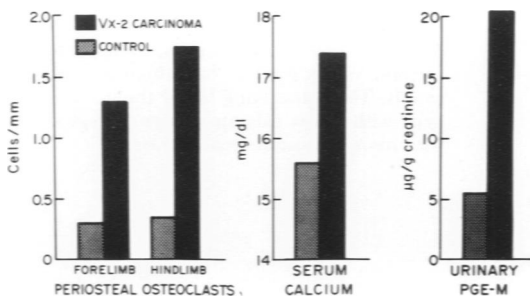
type of change was the hyperplasia of osteoclasts along the diaphyseal periosteum in bones of tumor-bearing rabbits (Figure 4A) as compared with matched sites in control animals (Figure 4B), where osteoclasts were inconspicuous.

The increase in absolute numbers of periosteal osteoclasts was significantly greater ( $P < 0.05$ ) in hindlimbs (tumor-bearing extremity) than in the forelimbs. Both hindlimbs and forelimbs, however, showed significant increases ( $P < 0.01$ ) over comparable control bones. These changes along with the increases in serum calcium ( $P < 0.01$ ) and urinary PGE-M ( $P < 0.01$ ) for the control and VX-2 carcinoma-bearing groups are summarized in Text-figure 2.

Cortical resorptive changes deep to the periosteum were noted in 11 of the 32 rabbits examined. These consisted of irregularly shaped spaces lined by osteoclasts (Figure 4C) and were noted in both forelimb and hindlimb bones. Of the 11 animals revealing this form of resorption, 8 had borne the tumor for more than 3 weeks. Based on the frequency distribution of the rabbits according to time, only 4 examples of this type of resorption would be expected in this group by chance alone.

Other pathology noted included a conspicuous hyperplasia of bone marrow seen in 29 of 32 tumor-bearing rabbits (Figure 4D) as compared with matched sites in control animals (Figure 4E). This alteration was noted in both hindlimb and forelimb sites. Although periodic acid-Schiff staining revealed the majority of the cells as granulocytic precursors, there appeared to be an increase in the number of erythroid precursors as well. However, red cell counts of the rabbits did not rise, and often fell, during the course of the disease.

Epiphyseal growth arrest was noted in 25 of 32 tumor-bearing rabbits (Figure 4F), as compared to no control animals (Figure 4G). This change occurred with approximately equal frequency in forelimb and hindlimb bones. It was noted in tumor-bearing animals both with and without



TEXT-FIGURE 2—Effects of VX-2 carcinoma on periosteal osteoclast count and levels of serum calcium and urinary PGE-M in female New Zealand white rabbits. Significant increases in all three parameters are noted in rabbits bearing tumors for 2 weeks or more. Hindlimb osteoclast counts are significantly greater ( $P < 0.05$ ) than forelimb values.

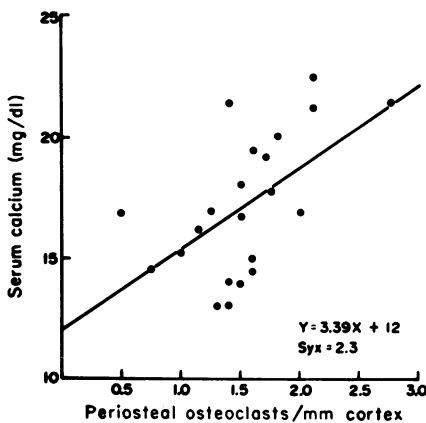
weight loss, although the change was more common in animals with inanition than those without demonstrable weight loss.

Periosteal new bone formation was noted in 15 and microfracture in 3 of the 32 tumor-bearing rabbits. Unlike the other osseous alterations produced by the VX-2 carcinoma, these changes were identified only in the hindlimbs. However, they also were more frequent in animals with chronologically advanced disease.

The relationship of the number of periosteal osteoclasts per millimeter to the serum calcium at time of death is shown in Text-figure 3. Animals with high serum calcium levels tended to have a high osteoclast count as well. Of those 8 animals lying below the regression line (low serum calcium in relation to osteoclast count), 6 were rabbits 4 weeks or more from the time of transplantation. Furthermore, the mean serum creatinine at death for this group was  $2.2 \pm 0.6$  as compared to  $1.1 \pm 0.3$  for the 15 remaining rabbits. This difference was statistically significant ( $P < 0.05$ ) and reflected the declining renal function associated with the later stages of tumor growth. In general, an inverse relationship existed between the osteoclast count of tumor-bearing animals and the serum creatinine (Text-figure 4). Although the correlation was not strong ( $r = -0.45$ ), the point distribution suggested that renal failure was not the cause of the observed osteoclastic hyperplasia. Furthermore, osteomalacia could not be identified in any rabbit using undecalcified sections, and the osteoclast counts were maximal at a time prior to that when creatinine values were significantly elevated.

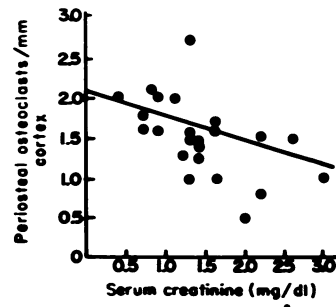
## Discussion

The natural history of the VX-2 carcinoma injected into the rabbit thigh may be divided into three phases. There is an initial latent phase of



TEXT-FIGURE 3—Regression line of serum calcium values and periosteal osteoclast counts. A positive correlation is present. Higher serum calcium values tend to have higher osteoclast counts. The points lying below the line are animals with lower calcium values in association with more advanced renal disease.

TEXT-FIGURE 4—Regression line of periosteal osteoclast counts and serum creatinine levels in 23 VX-2 carcinoma-bearing rabbits. An inverse relationship exists between the two quantities.



approximately 1 to 2 weeks in which the tumor is small and hypercalcemia absent. This is followed by a 2- to 3-week period of hypercalcemia. During this period of time, the actual amount of viable tumor increases very little, urinary PGE-M levels reach a plateau, and renal failure develops in most animals. A terminal phase of variable length follows the period of hypercalcemia. This period is marked by variable calcium values depending on the degree of renal failure. At the time of death of the animal, usually occurring by 6 weeks of tumor growth, the tumor is largely necrotic.

Even in animals dying of the tumor, metastases are extremely rare. Distant metastases to bone were not identified in the present study or in those of other authors.<sup>11,13,17-19</sup> Thus, the hypercalcemia accompanying the growth of the tumor is due to humoral effects and not to bone destruction by metastases. That this hypercalcemia is in some way related to increased production of prostaglandins has been established by several authors<sup>11,13</sup> and, in fact, urinary PGE-M excretion continues to rise up to 4 weeks of tumor growth.

The extent of the morphologic osseous lesions accompanying the hypercalcemia has been the subject of discussion. Voelkel *et al.*<sup>11</sup> have stated that resorptive changes are present at sites remote from the tumor and that they are not substantially greater near the site of tumor growth. More recently, Young *et al.*<sup>17,18</sup> have maintained that morphologic changes, although severe near the injection site, are absent in bones distant from the tumor. The presence or absence of resorptive changes distant from the tumor is an important point since the exact nature of the prostaglandin mediators in this tumor is unclear.<sup>11,13</sup> The finding and quantitation, as described in the present paper, of resorptive changes in bones separated by the pulmonary vascular bed supports the concept that the hypercalcemia results largely from a humoral mediator and not merely from local effects of the tumor.

The hypercalcemia associated with this tumor is mediated by one or more of the prostaglandin-related products formed from the metabolism

of arachidonic acid by fatty acid cyclooxygenase; inhibition of fatty acid cyclooxygenase by indomethacin will reverse the hypercalcemia.<sup>11</sup> Most of the evidence accumulated to date has been related to the possibility that circulating prostaglandin E<sub>2</sub> (PGE<sub>2</sub>), released from the tumor, causes bone resorption. PGE<sub>2</sub> is a potent stimulus for bone resorption in organ culture,<sup>20-22</sup> and in one study, an infusion of PGE<sub>2</sub> was shown to produce transient hypercalcemia in the rat.<sup>23</sup> In addition, radioimmunoassayable PGE<sub>2</sub> is elevated in the venous effluent from the tumor<sup>11</sup> and the major urinary metabolite of PGE<sub>2</sub> is quite increased in rabbits bearing this tumor.<sup>13</sup> However, PGE<sub>2</sub> is largely inactivated in a single passage through the lungs,<sup>24,25</sup> and significant elevations of peripheral plasma concentrations of PGE<sub>2</sub> have not been detected in VX-2 carcinoma-bearing rabbits until long after hypercalcemia is evident.<sup>11</sup> Thus, lacking definitive evidence that PGE<sub>2</sub> from the tumor reaches the peripheral circulation in adequate concentrations to yield hypercalcemia, the possibility remains that the hypercalcemia could be mediated by metabolites of arachidonic acid in the cyclooxygenase pathway other than PGE<sub>2</sub> itself.

The observation that resorptive changes are quantitatively greater in the hindlimb bones than in those of the forelimb suggests the possibility of local vascular or lymphatic connections between the tumor and bone. Young *et al.*<sup>17-18</sup> have noted absence of hypercalcemia when the VX-2 carcinoma is injected intraperitoneally and therefore postulated the necessity of close osseous contact by the tumor for the development of hypercalcemia. However, the importance of the liver in metabolizing any prostaglandin-related substances formed in the peritoneal cavity was not determined; as the liver is rich in several of the enzymes that participate in the metabolic inactivation of prostaglandins,<sup>26,27</sup> intraperitoneal formation of the hypercalcemic mediator cannot be equated with its systemic availability.

Changes other than the increase in numbers of osteoclasts appear to accompany the growth of the tumor. Two of these were sufficiently constant to suggest some relationship, direct or indirect, to the VX-2 carcinoma. One of these phenomena, epiphyseal growth arrest, has also been noted in calcitonin-treated animals,<sup>28</sup> although there is no evidence that a compensatory elevation of calcitonin is present in VX-2 carcinoma-bearing rabbits, and growth arrest could result from the inanition and cachexia associated with tumor growth. The hyperplasia noted in the marrow of the tumor-bearing rabbits was likewise severe and relatively constant. Whether this is a prostaglandin-mediated effect is not known. However, squamous cell carcinoma of the bronchus, the most common antecedent of humoral hypercalcemia of malignancy in humans,<sup>2,29,30</sup> is



also the most common tumor associated with secondary granulocytosis in man.<sup>31</sup> Similar reactions have been described in squamous cell carcinomas in mice.<sup>32</sup> The observation that erythroid precursors are also increased may be related to the known ability of prostaglandins to potentiate the effects of erythropoietin<sup>33</sup> and to stimulate its synthesis in some cases.<sup>34</sup>

The VX-2 carcinoma is significant for human cancer patients for several reasons. Unlike many animal tumors which induce hypercalcemia,<sup>4-7,35</sup> the VX-2 carcinoma is clearly descended from a squamous carcinoma,<sup>12</sup> the histologic pattern of tumor most commonly associated with the syndrome of humoral hypercalcemia of malignancy in humans.<sup>2</sup> Both human<sup>8</sup> and rabbit syndromes<sup>18</sup> usually occur after soft tissue spread of the tumor. Furthermore, the tumors involved are similar ultrastructurally in that both human<sup>36-38</sup> and rabbit neoplasms contain numerous tonofilaments and desmosomes while being relatively poor in rough and smooth endoplasmic reticulum, features not suggestive of polypeptide hormone production. In addition, the hypercalcemic effects of some bronchogenic carcinomas<sup>1</sup> appear to be related, like the VX-2 carcinoma, to prostaglandin excess.

Finally, there is the problem of the biologic perspective of the osteoclastic hyperplasia in VX-2 carcinoma-bearing rabbits. Since the increase in osteoclast numbers precedes the development of renal failure, and serum creatinine values appear inversely related to osteoclast counts, it appears unlikely that this lesion is an epiphenomenon related to secondary hyperparathyroidism in renal failure. Similar, but not identical, osseous lesions have been described for other tumors producing humoral hypercalcemia in both man<sup>30</sup> and animals.<sup>35,39</sup> Although the osseous lesions described in the VX-2 carcinoma are somewhat subtle in comparison to those associated with hypercalcemia due to osseous metastases,<sup>9</sup> their widespread occurrence and chronologic relationship to the hypercalcemia suggests that they are a morphologic expression of the syndrome.

The relative importance of the local versus the distant lesions in the genesis of the hypercalcemia is difficult to ascertain. Although the osteoclastic hyperplasia is quantitatively greater in sites near the tumor than at a distance from it, there is no evidence concerning the relative contribution of each in the development of the hypercalcemia. The relative metabolic activity of the osteoclasts may differ considerably and could be assessed by quantitative techniques.

## References

1. Seyberth HW, Segre GV, Morgan JL, Sweetman BJ, Potts JT, Jr, Oates JA: Prostaglandins as mediators of hypercalcemia associated with certain types of cancer. *N Engl J Med* 293:1278-1283, 1975

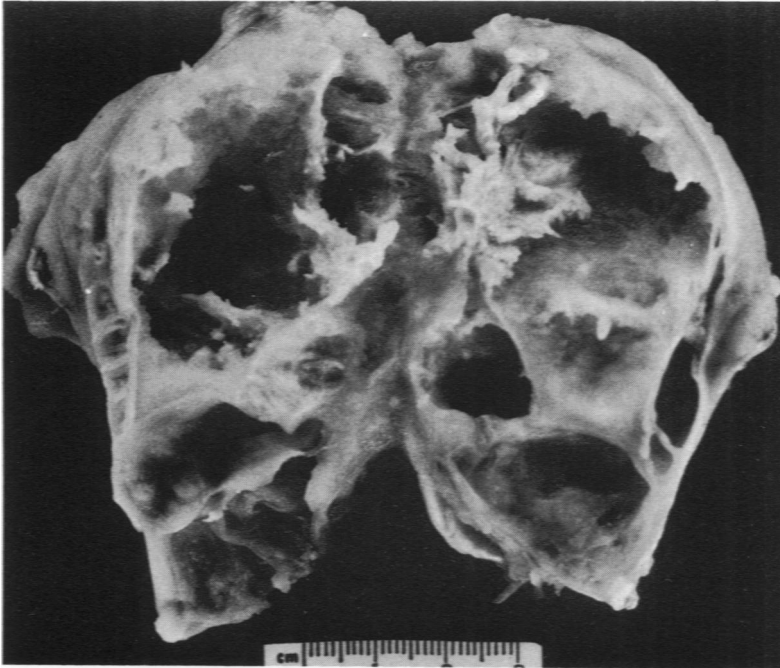
2. Chopra D, Clerkin EP: Hypercalcemia and malignant disease. *Med Clin N Am* 59:441-447, 1975
3. Powell D, Singer FR, Murray TM, Munkin C, Potts JT Jr: Nonparathyroid humoral hypercalcemia in patients with neoplastic diseases. *N Engl J Med* 289:176-181, 1973
4. Ziegler WS, Schafer A, Minne H: Paraneoplastic secretion of an osteolytic factor by a Walker tumor in the rat. Proceedings of the Fourth International Symposium on Endocrinology 1973. London, Heinemann, 1974, pp 316-372
5. Rice BF, Roth LM, Cole FE, MacPhee AA, David K, Ponthier RL, Sternberg WH: Hypercalcemia and neoplasia: Biologic, biochemical, and ultrastructural studies of a hypercalcemia-producing Leydig cell tumor of the rat. *Lab Invest* 33:428-439, 1975
6. Humes JL, Strausser, HR: Prostaglandins and cyclic nucleotides in Moloney sarcoma tumors. *Prostaglandins* 5:183-196, 1974
7. Tashjian AH Jr., Voelkel EF, Levine L, Goldhaber P: Evidence that the bone resorption-stimulating factor produced by mouse fibrosarcoma cells is prostaglandin E<sub>2</sub>: A new model for the hypercalcemia of cancer. *J Exp Med* 136:1329-1343, 1972
8. Amatruda TT Jr.: Nonendocrine secreting tumors. Duncan's Diseases of Metabolism. Edited by PR Bondy, LE Rosenberg. Philadelphia, WE Saunders, 1974, pp 1633-1636
9. Milch RA, Changus GW: Response of bone to tumor invasion. *Cancer* 9:340-351, 1956
10. Tashjian AH Jr, Voelkel EF, Goldhaber P, Levine L: Prostaglandins: Calcium metabolism and cancer. *Fed Proc* 33:81-86, 1974
11. Voelkel EF, Tashjian AH Jr, Franklin R, Wasserman E, Levine L: Hypercalcemia and tumor prostaglandins: The VX-2 carcinoma model in the rabbit. *Metabolism* 24:973-986, 1975
12. Kidd JG, Rous P: A transplantable rabbit carcinoma originating in a virus-induced papilloma and containing the virus in masked or altered form. *J Exp Med* 71:813-838, 1940
13. Seyberth HW, Hubbard WC, Morgan JL, Sweetman BJ, Oates JA: Prostaglandin mediated hypercalcemia in the VX-2 carcinoma-bearing rabbit. *Clin Res* 24:370A, 1976 (Abstr)
14. Hamberg M: Inhibition of prostaglandin synthesis in man. *Biochem Biophys Res Commun* 49:720-726, 1972
15. Xipell J, Makin H, McKinnon P: A method for the preparation of undecalcified bone sections for light microscopy and microradiography. *Stain Technol* 49:69-76, 1974
16. Lillie RD: *Histopathologic Technique and Practical Histochemistry*, Third edition. Philadelphia, Blakiston, 1965
17. Young DM, Fioravanti JL, Prieur DJ, Ward JM: Hypercalcemia and malignancy: The VX-2 carcinoma. *Fed Proc* 35:866, 1976 (Abstr)
18. Young DM, Fioravanti JL, Prieur DJ, Ward JM: Hypercalcemic VX-2 carcinoma in rabbit: A clinicopathologic study. *Lab Invest* 35:30-46, 1976
19. Wilson JR, Merrick H, Vogel SD, Woodward ER: Hyperparathyroid-like state in rabbits with the VX-2 carcinoma: Further studies. *Am Surg* 31:145-152, 1965
20. Klein DC, Raisz LG: Prostaglandins: Stimulation of bone resorption in tissue culture. *Endocrinology* 86:1436-1440, 1970
21. Dietrich JW, Goodson JM, Raisz LG: Stimulation of bone resorption by various prostaglandins in organ culture. *Prostaglandins* 10:231-240, 1975
22. Gomes BC, Hausmann E, Weinfeld N, DeLuca C: Prostaglandins: Bone resorption stimulating factors released from monkey gingiva. *Calcif Tiss Res* 19:285-293, 1976

23. Franklin RB, Tashjian AH Jr: Intravenous infusion of prostaglandin (PG)<sub>E<sub>2</sub></sub> raises plasma calcium concentration in the rat. *Endocrinology* 97:240-243, 1975
24. Ferreira SH, Vane JR: Prostaglandins: Their disappearance from and release into the circulation. *Nature (Lond)* 216:868-873, 1967
25. Piper PJ, Vane JR, Wyllie JH: Inactivation of prostaglandins by the lungs. *Nature (Lond)* 225:600-604, 1970
26. Hamberg M, Israelsson U: Metabolism of prostaglandin E<sub>2</sub> in guinea pig liver. I. Identification of seven metabolites. *J Biol Chem* 245:5107-5114, 1970
27. Hamberg M: Metabolism of prostaglandins in rat liver mitochondria. *Eur J Biochem* 6:135-146, 1968
28. Zichner L: Die Wirkung des Calcitonins auf das Knochengewebe: Eine licht-, elektronen-, fluoreszenzmikroskopische und autoradiographische Untersuchung. *Res Exp Med* 164:293-313, 1974
29. Bender RA, Hansen H: Hypercalcemia in bronchogenic carcinoma: A prospective study of 200 patients. *Ann Intern Med* 80:205-208, 1974
30. Azzopardi JG, Whittaker RS: Bronchial carcinoma and hypercalcaemia. *J Clin Pathol* 22:718-724, 1969
31. Robinson WA: Granulocytosis in neoplasia. *Ann NY Acad Sci* 230:212-218, 1974
32. Lappat EJ, Cawein M: A study of the leukemoid response to transplantable A-280 tumor in mice. *Cancer Res* 24:302-311, 1964
33. Schooley JC, Mahlmann LJ: Stimulation of erythropoiesis in plethoric mice by prostaglandins and its inhibition by anti erythropoietin. *Proc Soc Exp Biol Med* 138:523-524, 1971
34. Mujovic VM, Fisher JW: The effects of indomethacin on erythropoietin production in dogs following renal artery constriction. I. The possible role of prostaglandins in the generation of erythropoietin by the kidney. *J Pharmacol Exp Ther* 191:575-80, 1974
35. Strausser HR, Humes JL: Prostaglandin synthesis inhibition: Effect on bone changes and sarcoma tumor induction in BALB/c mice. *Int J Cancer* 15:724-730, 1975
36. Lupulescu A, Boyd CB: Lung cancer: A transmission and scanning electron microscopic study. *Cancer* 29:1530-1538, 1972
37. Obiditisch-Mayer I, Breitfellner G: Electron microscopy in cancer of the lung. *Cancer* 21:945-951, 1968
38. Moore GE, Merrick SB, Woods LK, Arabasz NM: A human squamous cell carcinoma cell line. *Cancer Res* 35:2684-2688, 1975
39. Mundy GR, Raisz LG, Cooper RA, Schechter GP, Salmon SE: Evidence for the secretion of an osteoclast stimulating factor in myeloma. *N Engl J Med* 291:1041-1046, 1974

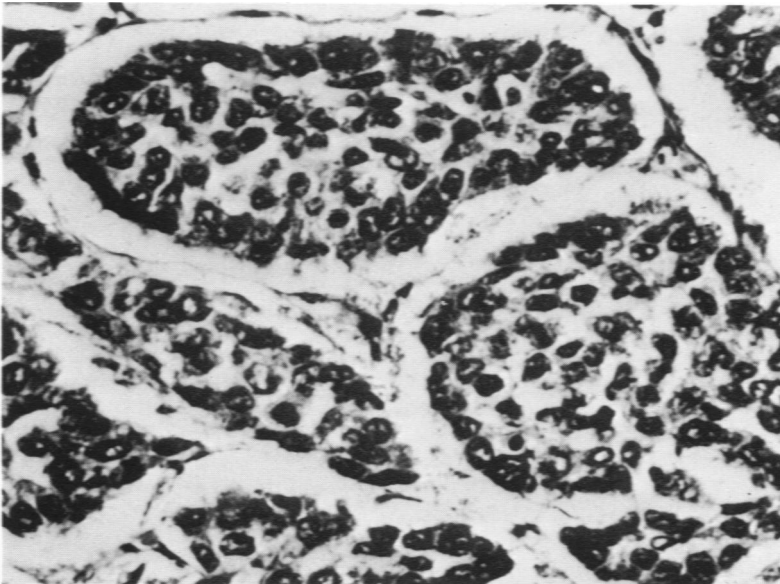
### Acknowledgments

The excellent technical assistance of Lee Morgan and Sara Settle is greatly appreciated.

*[Illustrations follow]*



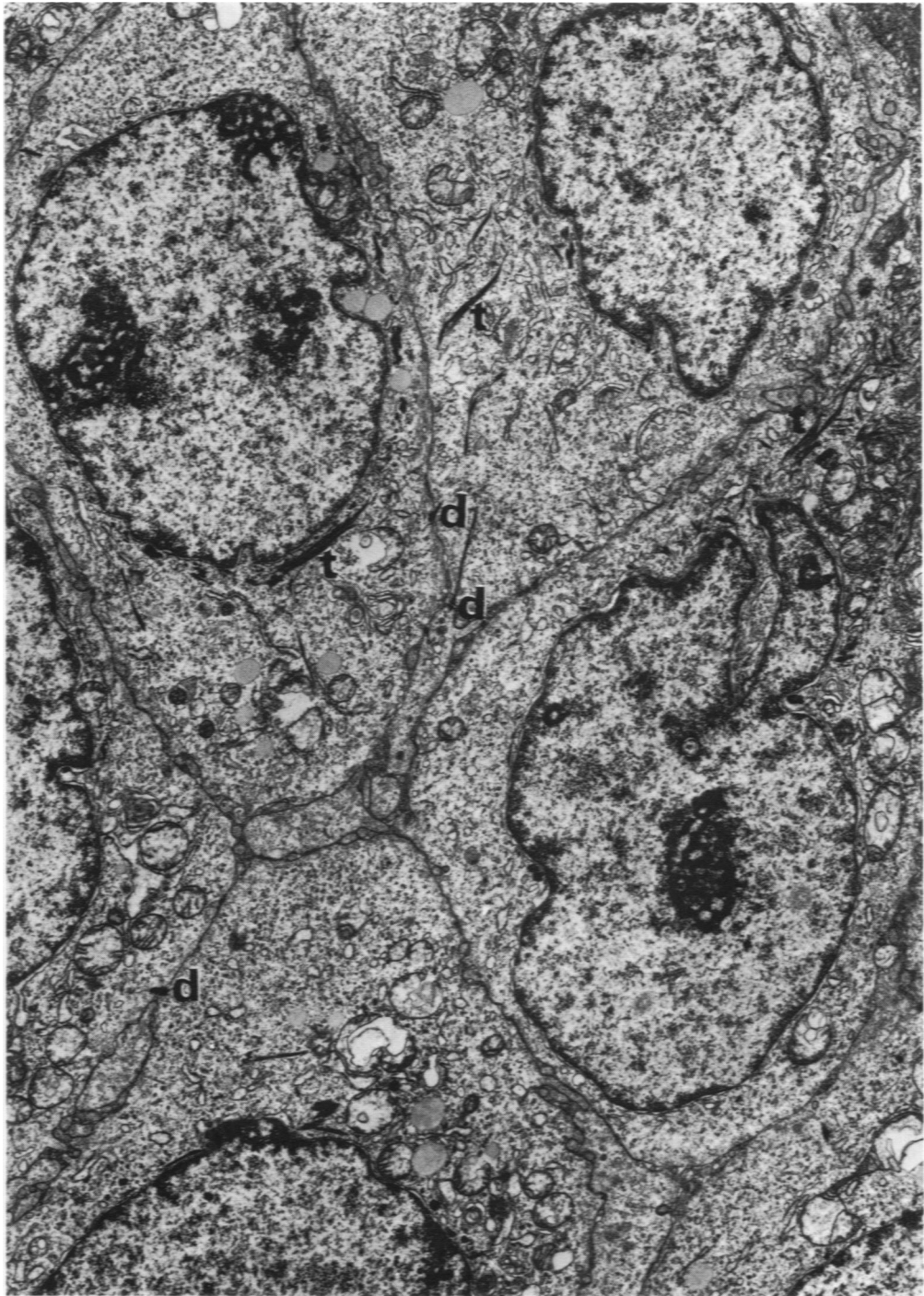
1

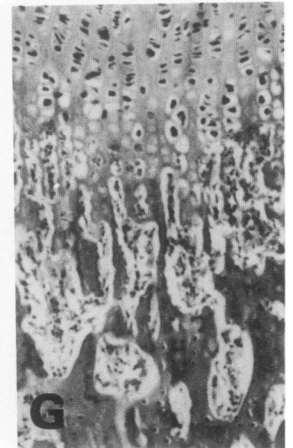
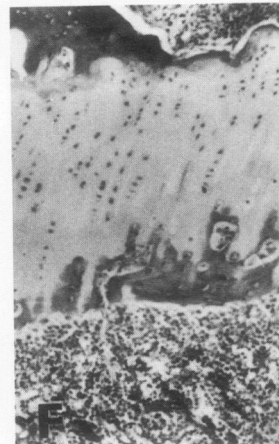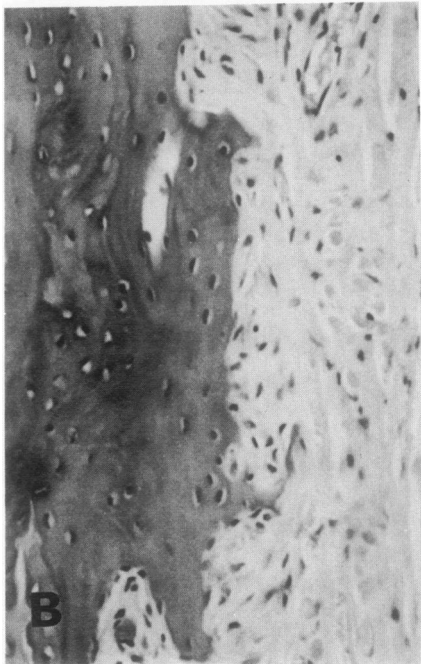
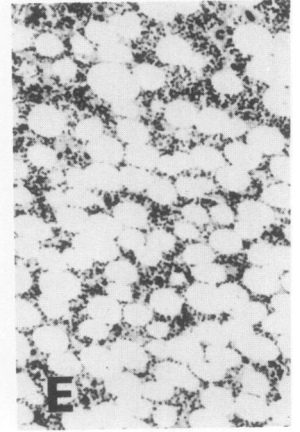
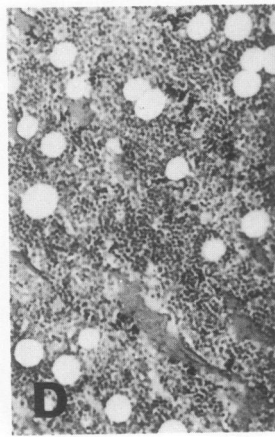
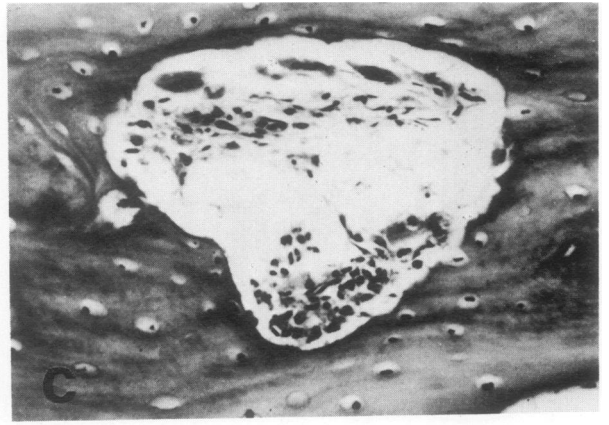

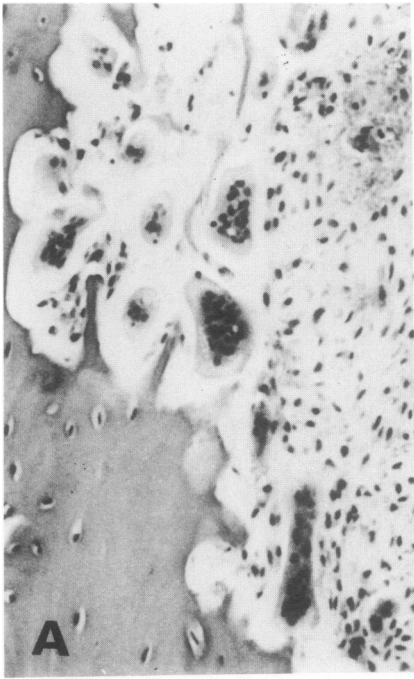
2

**Figure 1**—VX-2 carcinoma in rabbit thigh after 5 weeks of growth. Sagittal section reveals extensive cystic necrosis. **Figure 2**—VX-2 carcinoma in rabbit thigh after 2 weeks of growth. Nests of poorly differentiated carcinoma with little apparent cytoplasmic differentiation are seen. (H & E,  $\times 220$ )

**Figure 3**—Ultrastructure of VX-2 carcinoma. Numerous tonofilaments (*t*), desmosomes (*d*), and aggregated free ribosomes are present. (Uranyl acetate and lead citrate × 12,800)





**Figure 4**—Osseous effects associated with the VX-2 carcinoma as compared with control animals (H & E). **A**—Osteoclastic resorption in humeral periosteum of rabbit bearing the VX-2 carcinoma for 3 weeks. Numerous osteoclasts and resorptive spaces are present. ( $\times 100$ ) **B**—Absence of resorption in humerus of control rabbit ( $\times 100$ ). **C**—Cortical osteolysis in rabbit bearing VX-2 carcinoma for 4 weeks. Irregular resorption space lined by osteoclasts. ( $\times 120$ ) **D**—Extensive hyperplasia of marrow elements in femur of tumor-bearing rabbit as compared with **E**. **E**—Marrow of femur in control rabbit of similar body weight ( $\times 40$ ). **F**—Epiphyseal growth arrest in proximal humerus of rabbit bearing tumor for 3 weeks. Note absence of chondrocytic proliferation and bone production and thinning of epiphysis as compared with **G**. **G**—Humeral epiphysis of control rabbit of similar weight ( $\times 40$ ).