

Profile of Intracytoplasmic Lysozyme in Normal Tissues, Myeloproliferative Disorders, Hairy Cell Leukemia, and Other Pathologic Processes

An Immunoperoxidase Study of Paraffin Sections and Smears

Geraldine S. Pinkus, MD, and Jonathan W. Said, MB, ChB

Intracytoplasmic lysozyme (muramidase) may be readily identified in paraffin sections of tissues fixed in formalin or Zenker's acetic acid and in smears of peripheral blood or bone marrow using an immunoperoxidase technique. Sites of intracellular lysozyme in normal human tissues and in various specimens from patients with myeloproliferative and lymphoproliferative disorders, hairy cell leukemia, granulomatous diseases, toxoplasmic lymphadenitis, and other pathologic processes were defined by this method. Intracellular lysozyme was demonstrated in mature and immature neutrophilic and eosinophilic myeloid cells, in monocytic cells, and in some types of histiocytes and had a limited distribution in normal tissues. The neoplastic cells of hairy cell leukemia were devoid of intracytoplasmic lysozyme. Identification of intracellular lysozyme, as determined by the immunoperoxidase technique, was compared with various cytochemical methods, particularly chloroacetate esterase and α -naphthyl butyrate esterase studies, for detection and characterization of myeloid cells, monocytes, and histiocytes. (*Am J Pathol* 89:351-366, 1977)

LYSOZYME (muramidase) is an intracellular enzyme found in myeloid cells, monocytes, and histiocytes and in some body fluids and secretions including tears, saliva, human milk, and serum.¹⁻⁴ This bacteriolytic enzyme acts on walls of susceptible microorganisms by cleavage of the bond between *N*-acetylmuramic acid and *N*-acetylglucosamine. Serum lysozyme levels apparently reflect liberation of this enzyme by cells of myeloid, monocytic, and histiocytic types. Elevated levels of serum lysozyme have been reported in myeloproliferative disorders,⁴⁻⁷ particularly those with monocytic differentiation, and in diseases associated with granulomatous inflammation, including tuberculosis,⁸ sarcoidosis,⁹ and Crohn disease.¹⁰

In most studies, lysozyme has been detected on the basis of its enzymatic activity using *Micrococcus lysodeikticus* as a substrate.^{1-3,5-7,11,12} Immunofluorescent techniques have also been used to define intracytoplasmic lysozyme.^{13,14} Disadvantages of these methods include a) the

From the Department of Pathology, Peter Bent Brigham Hospital, Boston, Massachusetts.

Supported by Grants CA-17615, HL-06370, and RR-05489 from the National Institutes of Health, US Public Health Service.

Accepted for publication July 1, 1977.

Address reprint requests to Dr. Geraldine S. Pinkus, Department of Pathology, Peter Bent Brigham Hospital, 721 Huntington Avenue, Boston, MA 02115.

inability to apply these techniques to paraffin sections, b) their failure to demonstrate localization of lysozyme in a permanent preparation with good morphologic detail, and c) the requirement of intact enzymatic activity for some assays. Recently, immunoperoxidase techniques have been successfully applied to paraffin-embedded tissues for identification of various intracytoplasmic antigens. Intracellular immunoglobulin, for example, may be identified and specifically characterized using this procedure.^{15,16} Mason and Taylor¹⁷ have demonstrated that the immunoperoxidase technique may also be applied to paraffin sections for detection of tissue lysozyme.

The purpose of this study is to evaluate the immunoperoxidase method for identification of intracytoplasmic lysozyme in paraffin sections and smears of normal human tissues and specimens from a variety of disorders, particularly those associated with proliferations of myeloid cells, monocytes, and/or histiocytes. The immunoperoxidase technique has also been compared with cytochemical reactions for identification of these various cell types.

Materials and Methods

Paraffin-embedded tissues were retrieved from the surgical pathology files of the Peter Bent Brigham Hospital. All bone marrow biopsies were fixed in Zenker's acetic acid solution (20:1, v/v) for 4 to 6 hours, washed in running water for 1 hour, then placed in 10% buffered formalin, and processed routinely. All other tissues were fixed in 10% buffered formalin and processed routinely. Time of storage for paraffin blocks used for these studies varied from several weeks to 14 years (1 year or less for most specimens). Smears of peripheral blood and bone marrow aspirates were stored for several days to 3 months prior to studies.

Rabbit anti-human lysozyme antiserum, swine anti-rabbit serum IgG antiserum, peroxidase-rabbit antiperoxidase complexes (PAP), normal swine serum, and normal rabbit serum were obtained from Dakopatts A/S of Copenhagen, Denmark (U.S. agent, Accurate Chemical and Scientific Corporation, Hicksville, N.Y.). Paraffin sections were cut at 3 to 4 μ , deparaffinized in xylene, and placed in absolute alcohol. All smears were initially fixed in 95% ethanol for 5 minutes. Endogenous peroxidase activity in sections and smears was blocked, i.e., consumed, by a 30-minute incubation in a 0.5% solution of hydrogen peroxide in methanol (one volume of 3% aqueous hydrogen peroxide to five volumes of methanol). Control sections demonstrated that endogenous peroxidase activity was completely eliminated by the methanolic-peroxide treatment.

The immunoperoxidase technique was performed as previously described.^{16,17} Briefly, following the methanolic-peroxide incubation, the sections were sequentially incubated with rabbit anti-human lysozyme antiserum (1:20 and 1:40 dilutions tested), swine anti-rabbit serum IgG antiserum (1:20 dilution), and PAP (1:100 dilution). Tris buffer (0.5 M, pH 7.6) was used for all dilutions. The site of antibody binding was determined using a diaminobenzidine reaction,¹⁸ which detects the peroxidase label. Neutrophils were present in varying numbers in most sections and provided internal positive controls for intracellular lysozyme. Control sections, substituting normal rabbit serum for the rabbit anti-human lysozyme antiserum in the initial incubation, gave negative results.

To verify the specificity of the rabbit anti-human lysozyme antiserum, sections of normal and pathologic tissues (containing abundant cells with intracellular lysozyme) were

initially incubated with antiserum which had been neutralized with purified human lysozyme (kindly provided by Dr. William Moloney, Hematology Department). No staining was observed in these sections. Serial sections incubated with nonneutralized antiserum of identical titer demonstrated cells with strong cytoplasmic staining for lysozyme.

In some tissues, particularly those fixed in Zenker's acetic acid solution or specimens with prominent fibrosis or collagenous stroma (e.g., skin), nonspecific background staining was observed. As previously described,¹⁷ background staining may be effectively eliminated or reduced by incubation of sections with normal swine serum (1:20 dilution) prior to incubation with rabbit anti-human lysozyme antiserum. This treatment does not interfere with subsequent reactions.

All bone marrow biopsies, spleens, lymph nodes, tissues from myeloproliferative disorders, and peripheral blood and bone marrow smears as available, were also studied by histochemical techniques. Chloroacetate esterase (CAE) studies, peroxidase determinations, and Sudan black B studies for detection of myeloid cells and α -naphthyl butyrate esterase (NBE) studies with and without fluoride inhibition for identification of monocytes (NBE activity inhibited with fluoride) and histiocytes (fluoride-resistant NBE activity) were performed by methods previously described.¹⁹⁻²² Peroxidase studies were performed only on smears which had been stored for less than 2 weeks.

Results

All tissues examined by the immunoperoxidase technique showed excellent morphologic detail. Intracytoplasmic lysozyme was readily detected by dark brown staining at the site of antibody binding, which contrasted sharply with hematoxylin or methyl green counterstain. Neutrophils were present in varying numbers in all tissues and consistently showed strong cytoplasmic staining.

Distribution of Lysozyme in Normal Human Tissues

The distribution of intracytoplasmic lysozyme in a variety of normal human tissues is presented in Table 1. A total of 68 specimens were studied and represent two or more samples of most tissues. Eight bone marrow biopsies, ten spleens, and four lymph nodes were evaluated. Sites of intracellular lysozyme were relatively limited and mainly included myeloid cells in bone marrow and spleen, some serous glands of parotid and submaxillary glands, serous glands of pulmonary bronchial wall, Paneth cells, renal proximal tubular cells, chondrocytes (hyaline cartilage), acinar cells of lacrimal glands, and acinar cells and luminal secretions of lactating breast tissue. Figure 1 illustrates the presence of intracytoplasmic lysozyme in serous glands in the wall of a bronchus.

Chloroacetate esterase studies of paraffin sections showed negative to weakly positive cytoplasmic staining in the myeloid cells of the Zenker's-acetic-acid-fixed bone marrow biopsies and moderate to strong staining of these cells in the formalin-fixed spleen and lymph node sections. With the immunoperoxidase technique, myeloid cells could be effectively characterized in paraffin sections of the bone marrow biopsies, lymph nodes,

Table 1—Distribution of Intracytoplasmic Lysozyme in Normal Human Tissues as Determined by Immunoperoxidase Studies

Tissue	Result*
Bone marrow	Mature myeloid cells and precursors—strongly positive Other hematopoietic cells—negative Bone marrow histiocytes—variable positivity to negative
Small intestine	Paneth cells—strongly positive
Stomach	Occasional epithelial cells—positive
Liver	Kupffer cells—variable positivity
Lung (bronchus)	Serous glands of bronchial wall—strongly positive Mucous glands and lung parenchyma—negative
Parotid gland	Some serous glands—positive (focal)
Submandibular gland	Serous glands—positive
Lacrimal gland	Acinar cells—positive
Breast	Lactating: Acinar cells and secretions—positive Nonlactating—negative
Kidney	Proximal tubular cells—positive
Hyaline cartilage	Chondrocytes in lacunae—strongly positive Matrix—negative
Lymph node	Macrophages in follicles—weakly positive to negative Sinus lining cells—variable positivity or negative
Spleen	Macrophages in follicular centers of white pulp—weakly positive to negative Cord macrophages and sinus lining cells—negative

* Myeloid cells were strongly positive in all tissues evaluated.

The following tissues did not demonstrate intracytoplasmic lysozyme: colon, prostate, endometrium, cervix, testis, ovary, adrenal, thyroid, cardiac and skeletal muscle, and skin.

and spleens on the basis of intracytoplasmic lysozyme. Lymphoid cells were negative for lysozyme.

α -Naphthyl butyrate esterase activity was completely inactivated in the paraffin sections of both formalin-fixed and Zenker's-acetic-acid-fixed tissues. In cryostat sections, NBE activity was found in various types of histiocytes in lymph nodes and spleens. The distribution of intracytoplasmic lysozyme, as detected in paraffin sections of these tissues by the immunoperoxidase technique, did not parallel NBE activity. Sinus lining cells in lymph nodes and macrophages in follicular centers of lymph nodes and spleens showed strong NBE activity but were weakly positive to negative for intracytoplasmic lysozyme. Similarly, splenic cord macro-

phages and sinus lining cells demonstrated strong NBE activity but appeared devoid of intracellular lysozyme. These results suggest that overall detection of histiocytes is better achieved on the basis of NBE activity, provided that cryostat sections or smears are available. For paraffin-embedded tissues, the immunoperoxidase technique for intracellular lysozyme represents a more effective means of detecting histiocytes, though the staining pattern for these cells may be variable.

Evaluation of monocytes in peripheral blood smears from normal individuals and from a patient with monocytosis demonstrated that these cells were NBE positive (inhibited with fluoride) and contained intracytoplasmic lysozyme.

Intracytoplasmic Lysozyme in Various Pathologic Processes

Granulomatous Diseases

In lymph nodes from 7 patients with sarcoidosis and 1 patient with tuberculous lymphadenitis, most of the epithelioid histiocytes and multinucleate giant cells in the granulomas, and occasional histiocytes near or between granulomas, were moderately to strongly positive for intracytoplasmic lysozyme (Figure 2).

In 1 patient with xanthogranulomatous pyelonephritis, the histiocytic cells in the infiltrate were also positive.

Toxoplasmic Lymphadenitis

Six lymph nodes with characteristic histologic features of toxoplasmic lymphadenitis showed moderate to strong cytoplasmic staining for lysozyme in epithelioid type histiocytes, present singly or in small clusters within follicles and in the interfollicular areas. The perisinusoidal monocytoïd cells were negative. Macrophages in the follicular centers and the sinus lining cells were negative to faintly positive.

Lymphoproliferative Disorders

Recent immunologic and morphologic studies suggest that malignant lymphomas of large cell types which have been designated as histiocytic lymphomas in the Rappaport classification may actually represent neoplasms of large lymphoid cells.^{23,24} Fifteen lymph nodes classified as histiocytic lymphoma were evaluated for intracytoplasmic lysozyme. In all cases, lysozyme was absent from the neoplastic cells but was identified in benign reactive-type histiocytes within the infiltrate of some nodes. Ten lymph nodes of other types of non-Hodgkin lymphoma (8 poorly differentiated lymphocytic, 1 mixed lymphocytic-histiocytic, and 1 well-differ-

entiated lymphocytic) revealed intracellular lysozyme in occasional phagocytic histiocytes. Lymphoid cells were negative.

Lymphoid cells were uniformly negative for intracytoplasmic lysozyme in bone marrow biopsies of patients with acute lymphocytic leukemia (2 cases) and in peripheral blood smears of patients with chronic lymphocytic leukemia (7 cases) and lymphosarcoma cell leukemia (1 case).

Hairy Cell Leukemia (Leukemic Reticuloendotheliosis)

Considerable controversy still exists as to whether the cell type involved in hairy cell leukemia (leukemic reticuloendotheliosis) is of lymphoid or monocytic origin.²⁵⁻²⁷ Since monocytes may contain intracytoplasmic lysozyme and lymphoid cells appear devoid of this enzyme, the immunoperoxidase technique was applied to tissues from 16 patients with characteristic clinical and histologic features of this disorder. Intracytoplasmic lysozyme was not found in hairy cells of sixteen spleens, eleven lymph nodes, eight bone marrow biopsies, one liver biopsy, and two peripheral blood smears. In all tissues studied, myeloid cells were strongly positive (Figure 3). These results do not support the possibility of a monocytic derivation for the neoplastic cells of hairy cell leukemia.

Eosinophils

Intracytoplasmic lysozyme was identified in eosinophilic myeloid cells present in tissues showing a prominent eosinophilic infiltrate, including two lymph nodes, colonic tissue from a patient with a parasitic disorder, and colonic tissue with a nonspecific infiltrate. Chloroacetate esterase studies demonstrated no activity in eosinophils.

Myeloproliferative Disorders

Bone marrow biopsies (thirty-two), spleens (eight), and lymph nodes (five) from a variety of myeloproliferative disorders were studied using the immunoperoxidase technique. Bone marrow biopsies included specimens from patients with acute myelogenous leukemia (sixteen), acute monocytic leukemia (one), chronic myelogenous leukemia (four), chronic myelogenous leukemia in blast crisis (three), polycythemia vera (three), polycythemia vera in transition to acute myelogenous leukemia (one), myelofibrosis (three), and erythroleukemia (one). In all bone marrow biopsies, myeloid cells at various stages of maturation, from promyelocytes to segmented forms, were strongly positive for intracytoplasmic lysozyme. Blasts showed variable positivity or appeared negative. Figure 4 illustrates lysozyme-positive blasts from a patient with acute myelogenous leukemia. Erythroid cells, lymphocytes, and plasma cells

were negative. Megakaryocytes were usually negative but occasionally showed nonspecific cytoplasmic staining. Some marrows showed apparent specific background staining associated with a dispersion of cytoplasmic granules from myeloid cells. In tissues from a subject with acute monocytic leukemia, immature forms of both monocytic and myeloid types were positive for intracellular lysozyme. Figure 5 demonstrates cytoplasmic staining for lysozyme, predominantly in monocytic cells of this case. Chloroacetate esterase studies of bone marrow biopsies were negative or showed focal weak positivity in myeloid cells; NBE studies were uniformly negative.

Spleens (seven) and lymph nodes (four) with extramedullary hematopoiesis, from subjects with myelofibrosis, and a spleen and lymph node with leukemic infiltration from cases of chronic myelogenous leukemia were studied. In these specimens, myeloid cells at all stages of maturation, including eosinophilic types (abundant in cases of chronic myelogenous leukemia), showed strong staining for cytoplasmic lysozyme (Figure 6). Chloroacetate esterase studies of paraffin sections of these formalin-fixed tissues also showed positive staining for mature neutrophilic myeloid cells and their precursors, but eosinophilic myeloid cells were negative. α -Naphthyl butyrate esterase studies were uniformly negative.

Extensive studies were performed on a subcutaneous tumor composed of immature monomyelocytic cells (apparently an unusual variant of myeloblastoma). The cells comprising this lesion contained round, oval, or reniform nuclei and showed no distinct cytoplasmic granules by routine staining. At the time of initial biopsy of this lesion, the patient did not have findings of a leukemic process in bone marrow or peripheral blood, though changes evolved after more than a year. Frozen sections and imprints demonstrated immature cells which were strongly NBE positive (inhibited with fluoride), CAE positive, Sudan black positive, and peroxidase negative. Electron microscopic studies showed immature cells with features compatible with monocytic and myeloid derivation, with primary and secondary granules identified in some cells. Paraffin sections revealed focal CAE activity and were NBE negative. The immunoperoxidase method was the most effective means of identifying the immature cells in paraffin sections, with strong staining for intracytoplasmic lysozyme evident in nearly all the immature cells (Figure 7).

In a patient with acute myelogenous leukemia presenting with an oral myeloblastoma, intracytoplasmic lysozyme was detected in leukemic cells in the paraffin sections. The results of CAE studies were negative (Zenger's fixed tissue).

The immunoperoxidase technique for identification of intracellular ly-

sozyme was applied to smears of bone marrow aspirates from 8 patients with acute myelogenous leukemia and peripheral blood smears from 15 patients with various myeloproliferative disorders, including acute myelogenous leukemia (8), acute monomyelocytic leukemia (1), chronic myelogenous leukemia (1), chronic myelogenous leukemia in blast crisis (2), acute monocytic leukemia (1), and myelofibrosis (2). In 11 of 19 cases with a predominance of blasts, nearly all blasts demonstrated cytoplasmic staining for lysozyme. In the other 8 cases, blasts were either negative or only a few were positive. Myeloid cells at later stages of maturation were positive, with strong cytoplasmic staining evident in mature myeloid cells in all specimens. Figure 8 illustrates intracytoplasmic lysozyme in blasts in a bone marrow aspirate from a patient with acute myelogenous leukemia.

Cytochemical studies were also performed on smears (as available). Blasts characterized by intracytoplasmic lysozyme generally also demonstrated peroxidase activity (5 subjects studied) and/or Sudan black positivity (10 subjects studied). The immunoperoxidase technique was more sensitive than CAE determinations (15 subjects studied) in characterizing blasts, in that the latter showed variable staining, both quantitatively and qualitatively. Except in the patient with acute monocytic leukemia, in which nearly all blasts showed NBE activity, few NBE-positive blasts were observed (14 patients were studied). Mature myeloid cells present in all patients tested showed positive cytoplasmic staining with Sudan black, CAE activity, peroxidase activity, and the presence of intracellular lysozyme.

Malignant Tumors

In evaluation of undifferentiated malignant tumors, neoplasms of true histiocytic type or those of myeloid or myelomonocytic origin potentially may be identified on the basis of intracytoplasmic lysozyme using the immunoperoxidase technique. To determine if tumors of other cell types would also yield positive staining, a total of twenty-three malignant tumors were tested, including colonic (twelve), breast (three), prostatic (one), renal (two), pulmonary (one), and gastric (one) carcinomas, undifferentiated carcinomas (two), and mesothelioma (one). Two pleomorphic adenomas of the parotid gland were also studied. Intracellular lysozyme was not detected in the neoplastic cells of these tumors.

Comparison of Methods

Table 2 compares the immunoperoxidase method for detection of intracellular lysozyme with CAE and NBE studies for characterization of myeloid cells, monocytes, and histiocytes in paraffin sections and smears.

Table 2—Comparison of Immunoperoxidase Studies for Intracellular Lysozyme With Cytochemical Techniques for Characterization of Myeloid Cells, Monocytes, and Histiocytes in Paraffin Sections and Smears

Method	Myeloid cells		Monocytes/histiocytes	
	Paraffin sections	Smears	Paraffin sections	Smears
Intracellular lysozyme	+	+	+*	+
Chloroacetate esterase	+†‡	+‡	0	0
α-Naphthyl butyrate esterase	0	0	0§	+

* Histiocytes show variable positivity, as defined in text.

† CAE activity effectively demonstrated in formalin-fixed tissues but not in Zenker's-fixed specimens.

‡ Eosinophilic myeloid cells do not show CAE activity.

§ NBE activity demonstrable only in cryostat sections.

The immunoperoxidase technique has wider applicability than cytochemical determinations, though the latter will specifically differentiate between myeloid and monocytic cells in smears. Neutrophilic myeloid cells may be characterized in smears and in paraffin sections on the basis of CAE activity, provided that tissues are fixed in formalin rather than Zenker's solution. Eosinophilic myeloid cells, however, lack CAE activity and cannot be defined by this technique. α-Naphthyl butyrate esterase studies may be applied to smears or cryostat sections for characterization of monocytes and/or histiocytes, but NBE activity is not retained in paraffin sections. For formalin-fixed or Zenker's-fixed, paraffin-embedded tissues, the immunoperoxidase technique for identification of intracellular lysozyme represents the most effective method for detection of neutrophilic and eosinophilic myeloid cells, monocytes, and histiocytes.

Discussion

The immunoperoxidase indirect sandwich technique represents a sensitive and specific method for identification of intracytoplasmic lysozyme in paraffin sections or smears. Compared with immunofluorescent determinations or bioassay techniques, immunohistochemical detection of intracellular lysozyme has considerable advantages. Immunoperoxidase studies provide permanent preparations with excellent morphologic detail and are readily capable of detecting lysozyme, even in an enzymatically inactive state.

In normal tissues, sites of intracytoplasmic lysozyme, as defined by this study (Table 1), were similar to those described previously^{17,28} with several exceptions. Intracytoplasmic lysozyme was identified in some serous glands of the parotid and in occasional gastric epithelial cells in our

study but was not described in these sites by Mason and Taylor.¹⁷ In previous reports^{1,8} based on assays of enzymatic activity, eosinophils were found to have little or no lysozyme. In our study and that of Mason and Taylor,¹⁷ both of which used the same immunohistochemical method, strong cytoplasmic staining for lysozyme was observed in eosinophilic myeloid cells in paraffin sections. The discrepancy between the latter studies and earlier reports may be related to differences in technique.

Different types of histiocytes demonstrated varying staining patterns for intracytoplasmic lysozyme as defined by the immunoperoxidase method. Little or no lysozyme was detected in splenic cord macrophages, in sinus lining cells of spleens and lymph nodes, and in macrophages in follicular centers of lymph nodes and spleens. However, epithelioid histiocytes associated with toxoplasmic lymphadenitis and granulomatous diseases contained easily detectable intracellular lysozyme. Elevated levels of serum lysozyme in tuberculosis,⁸ sarcoidosis,⁹ and Crohn disease¹⁰ presumably reflect increased production and liberation of lysozyme by the histiocytes characterizing these granulomatous processes.

The presence of intracellular lysozyme in myeloid and monocytic cells of various myeloproliferative disorders, as determined by immunoperoxidase studies, corroborates earlier reports which were based on bioassay, immunofluorescent, and immunoelectrophoretic techniques.^{6,12-14,29} Increased production and destruction of myeloid and/or monocytic cells provide a basis for the increased levels of serum lysozyme observed in these conditions. For characterization of myeloid and/or monocytic cells in various specimens from myeloproliferative disorders, the immunoperoxidase method for identification of intracytoplasmic lysozyme has wider applicability than CAE or NBE studies (Table 2).

In our subjects with hairy cell leukemia, lysozyme was not detected in the neoplastic mononuclear cells in bone marrow biopsies, spleens, lymph nodes, liver, or peripheral blood. The absence of cytoplasmic lysozyme in these patients fails to support a possible monocytic origin for this disorder, but correlates well with low serum lysozyme levels reported for patients with hairy cell leukemia.^{30,31} The neoplastic cells in lymph nodes of patients with "histiocytic" lymphoma also were devoid of intracellular lysozyme, suggesting that these tumors may not be of histiocytic origin.

Potential applications of the immunoperoxidase method for detection of intracellular lysozyme include evaluation of myeloproliferative disorders, detection of poorly differentiated neoplasms of myeloid and/or monocytic derivation, and identification of malignant lymphomas of true histiocytic type.

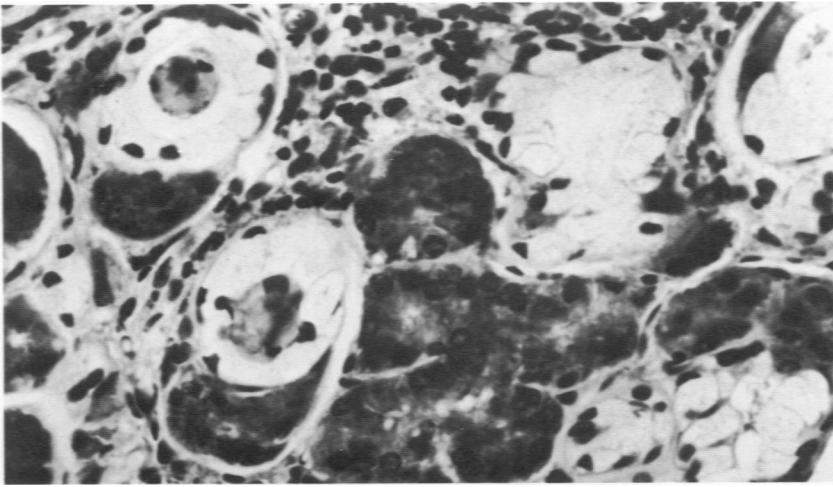
References

1. Briggs RS, Perillie PE, Finch SC: Lysozyme in bone marrow and peripheral blood cells. *J Histochem Cytochem* 14:167-170, 1966
2. Flanagan P, Lionetti F: Lysozyme distribution in blood. *Blood* 10:497-501, 1955
3. Syrén E Raeste A-M: Identification of blood monocytes by demonstration of lysozyme and peroxidase activity. *Acta Haematol (Basel)* 45:29-35, 1971
4. Hansen NE: Lysozyme in haematology: Pathophysiology and clinical use. *Scand J Haematol* 14:160-165, 1975
5. Osserman EF, Lawlor DP: Serum and urinary lysozyme (muramidase) in monocytic and monomyelocytic leukemia. *J Exp Med* 124:921-952, 1966
6. Catovsky D, Galton DAG, Griffin C: The significance of lysozyme estimations in acute myeloid and chronic monocytic leukaemia. *Br J Haematol* 21:565-580, 1971
7. Levi JA, Speden JB, Vincent PC, Gunz FW: Studies on muramidase in hematologic disorders. *Cancer* 31:939-947, 1973
8. Perillie PE, Khan K, Finch SC: Serum lysozyme in pulmonary tuberculosis. *Am J Med Sci* 265:297-302, 1973
9. Pascual RS, Perillie PE, Gee JBL, Finch SC: Serum and urine lysozyme in sarcoidosis. *Lysozyme*. Edited by EF Osserman, S Beychok, RE Canfield. New York, Academic Press, Inc., 1974, pp 391-398
10. Falchuk KR, Peretto JL, Isselbacher KJ: Serum lysozyme in Crohn's disease and ulcerative colitis. *N Engl J Med* 292:395-397, 1975
11. Litwack G: Photometric determination of lysozyme activity. *Proc Soc Exp Biol Med* 89:401-403, 1955
12. Karle H, Hansen NE, Killmann SA: Intracellular lysozyme in mature neutrophils and blast cells in acute leukemia. *Blood* 44:247-255, 1974
13. Asamer H, Schmalzl F, Braunsteiner H: Der immunzytologische lysozymnachweis in menschlichen blutzellen. *Acta Haematol* 41:49-54, 1969
14. Asamer H, Schmalzl F, Braumsteiner H: Immunocytological demonstration of lysozyme (muramidase) in human leukaemic cells. *Br J Haematol* 20:571-574, 1971
15. Taylor CR: The nature of Reed-Sternberg cells and other malignant "reticulum" cells. *Lancet* 2:802-806, 1974
16. Pinkus GS, Said JW: Specific identification of intracellular immunoglobulin in paraffin sections of multiple myeloma and macroglobulinemia using an immunoperoxidase technique. *Am J Pathol* 87:47-58, 1977
17. Mason DY, Taylor CR: The distribution of muramidase (lysozyme) in human tissues. *J Clin Pathol* 28:124-132, 1975
18. Graham RC Jr, Karnovsky MJ: The early stages of absorption of injected horseradish peroxidase in the proximal tubules of mouse kidney: Ultrastructural cytochemistry by a new technique. *J Histochem Cytochem* 14: 291-302, 1966
19. Moloney WC, McPherson K, Fliegelman L: Esterase activity in leukocytes demonstrated by the use of naphthol-AS-D-chloroacetate substrate. *J Histochem Cytochem* 8:200-207, 1960
20. Yam LT, Li CY, Crosby WH: Cytochemical identification of monocytes and granulocytes. *Am J Clin Pathol* 55:283-290, 1971
21. Li CY, Yam LT, Crosby WH: Histochemical characterization of cellular and structural elements of the human spleen. *J Histochem Cytochem* 20:1049-1058, 1972
22. Sheehan HL, Storey GW: An improved method of staining leukocyte granules with Sudan black B. *J Pathol Bacteriol* 59:336-337, 1947
23. Lukes RJ, Collins RD: Immunologic characterization of human malignant lymphomas. *Cancer* 34:1488-1503, 1974
24. Taylor CR: An immunohistological study of follicular lymphoma, reticulum cell

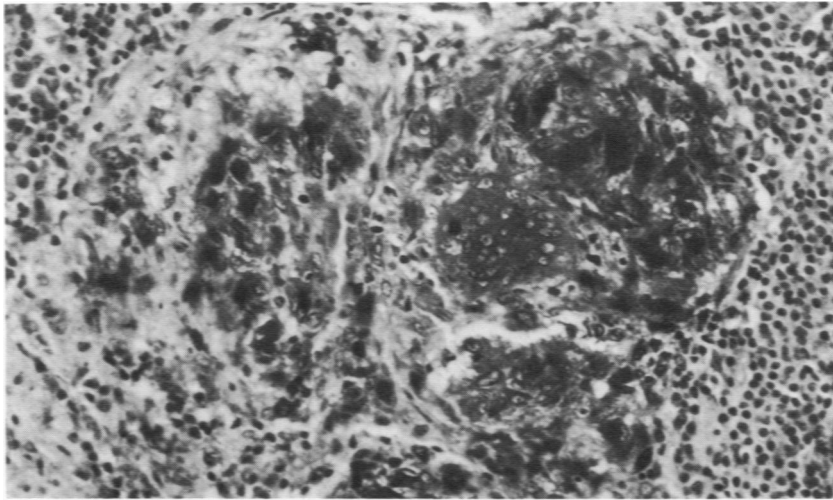
- sarcoma and Hodgkin's disease. *Eur J Cancer* 12:61-75, 1976
25. Catovsky D: Hairy cell leukaemia and polymorphocytic leukaemia. *Clin Haematol* 6:245-268, 1977
 26. Jaffe ES, Shevach EM, Frank MM, Green I: Leukemic reticuloendotheliosis: Presence of a receptor for cytophilic antibody. *Am J Med* 57:108-114, 1974
 27. Schnitzer B, Kass L: Hairy-cell leukemia: a clinicopathologic and ultrastructural study. *Am J Clin Pathol* 61:176-187, 1974
 28. Erlandsen SL, Parson JA: Immunochemical localization of lysozyme in the small intestine of man using the unlabeled antibody enzyme method. *J Histochem Cytochem* 21:405-406, 1973 (Abstr)
 29. Johansson BG, Malmquist J: Quantitative immunochemical determination of lysozyme (muramidase) in serum and urine. *Scand J Clin Lab Invest* 27:255-261, 1971
 30. Burns CP: Serum muramidase in leukaemic reticuloendotheliosis. *Lancet* 2:964, 1974
 31. Burns CP, Maca RD, Hoak JC: Biochemical, morphological, and immunological observations of leukemic reticuloendotheliosis. *Cancer Res* 33:1615-1624, 1973

Acknowledgments

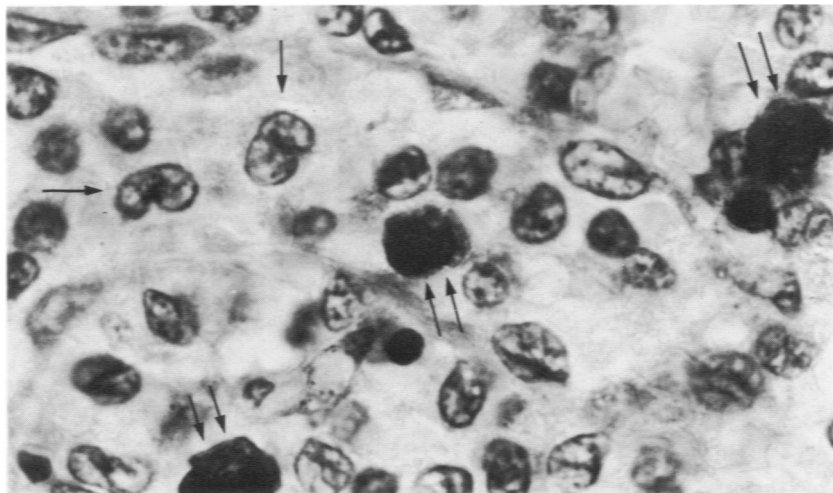
The authors are grateful for the capable technical assistance of S. St. Andre, D. Barbuto, and J. Pane; the skilled secretarial assistance of M. Cialdea and M. Cook; and the generous cooperation of Dr. W. C. Moloney, Hematology Department.



1

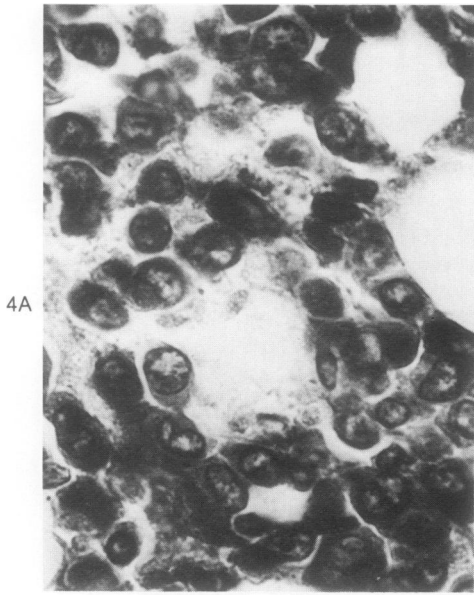


2

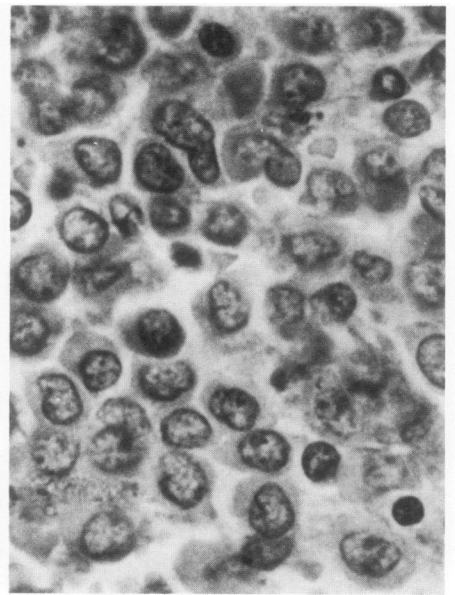


3

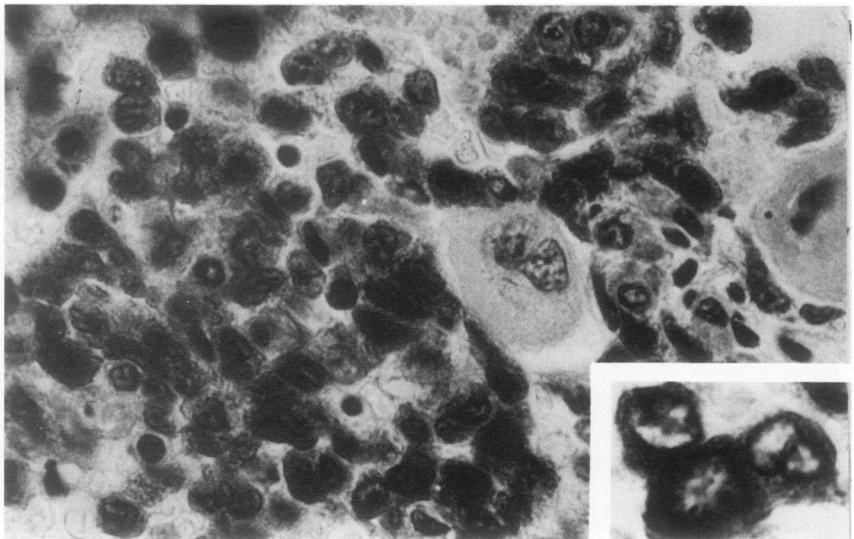
Figure 1—Bronchus; formalin-fixed paraffin section. Intracellular lysozyme (black) was identified in serous glands of bronchial wall by the immunoperoxidase technique. Mucous glands are clearly negative. (Hematoxylin counterstain, X 550) **Figure 2**—Sarcoidosis. Lymph node; formalin-fixed paraffin section. Intracellular lysozyme (black) is present in histiocytes and multinucleate giant cells of granulomas. (Hematoxylin counterstain, X 350) **Figure 3**—Hairy cell leukemia. Spleen; formalin-fixed paraffin section. Neoplastic mononuclear cells (*arrows*) within a splenic sinus are negative for intracellular lysozyme. The strong cytoplasmic staining for lysozyme (black) evident in neutrophils (*double arrows*) partially obscures details of segmented nuclei in the illustration. Myeloid cells were readily identified by microscopic examination of the stained sections. (Hematoxylin counterstain, X 2000)



4A

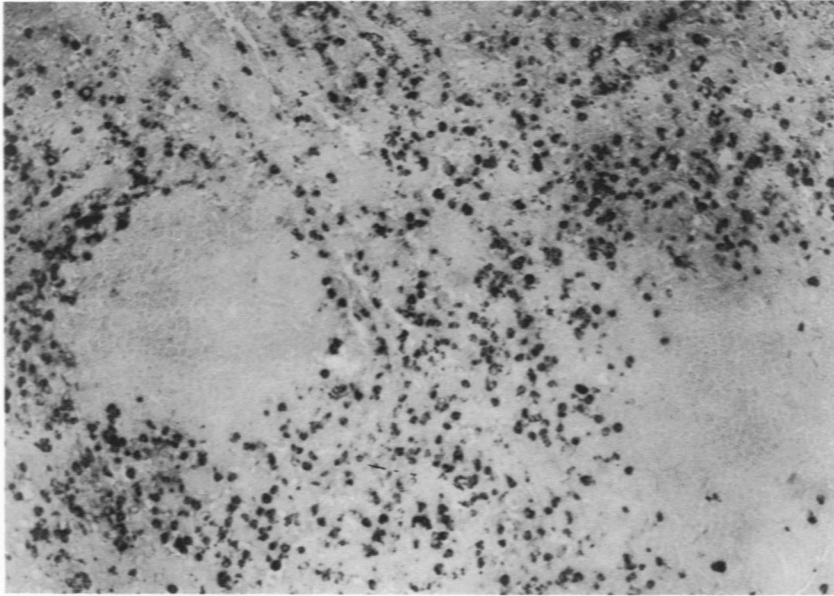


4B

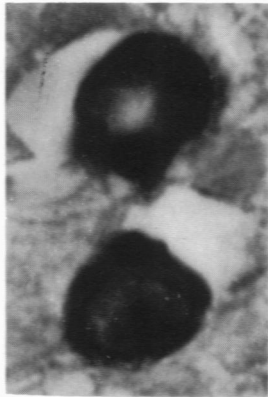


5

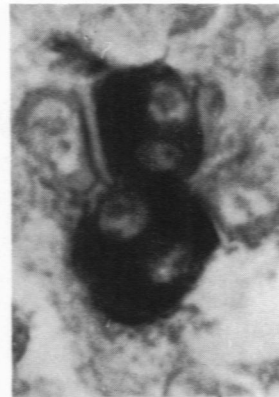Figure 4—Acute myelogenous leukemia. Bone marrow biopsy; Zenker's acetic acid fixation, paraffin section. (Hematoxylin counterstain, $\times 900$) **A**—The entire cell population consists of blasts which show strong cytoplasmic staining for intracellular lysozyme (black). **B**—No cytoplasmic staining observed in blasts of control section incubated with normal rabbit serum. Section incubated with rabbit anti-human lysozyme antiserum which had been neutralized with purified human lysozyme similarly gave negative results. Bone marrow aspirate in this case revealed a predominance of peroxidase-positive blasts, some of which contained Auer rods. **Figure 5—Acute monocytic leukemia.** Bone marrow biopsy; Zenker's acetic acid fixation, paraffin section. Monocyctic cells predominate in this section and show strong cytoplasmic staining for intracellular lysozyme (black). **Inset**—Higher magnification of immature monocyctic cells which contain oval, reniform, or irregular nuclei. Megakaryocytes and erythroid cells are negative for intracytoplasmic lysozyme. Bone marrow aspirate demonstrated a predominance of monocyctic cells which were NBE positive (inhibited with fluoride). Serum and urinary lysozyme levels were markedly elevated in this subject. (Hematoxylin counterstain, $\times 900$; **inset**, $\times 1300$)



6A



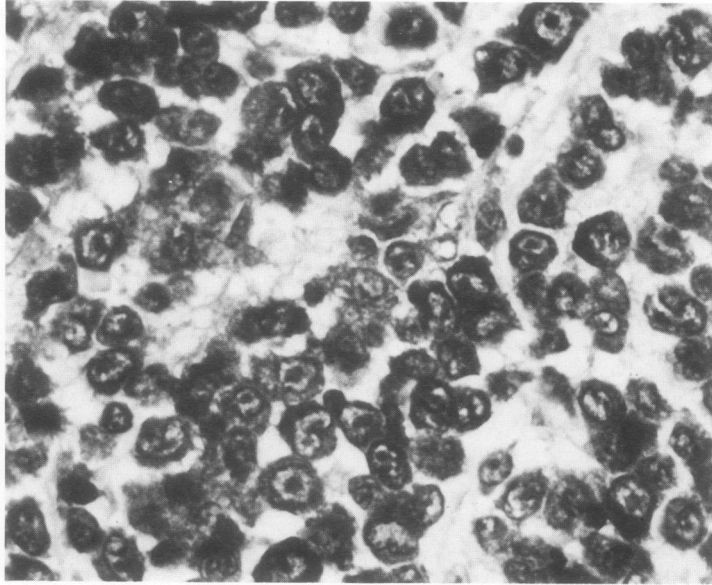
6B



6C

Figure 6—Spleen with extramedullary hematopoiesis in a patient with myelofibrosis; formalin-fixed paraffin section. **A**—At low power, abundant lysozyme-containing myeloid cells (black) are evident in the red pulp. White pulp (pale staining areas) is negative for lysozyme. ($\times 100$) **B** and **C**—Higher magnifications of myeloid cells at various stages of maturation illustrating strong staining for intracellular lysozyme (black) in myelocytes and metamyelocytes (**B**) and in mature myeloid cells (**C**). (Methyl green counterstain, $\times 2200$)

7



8

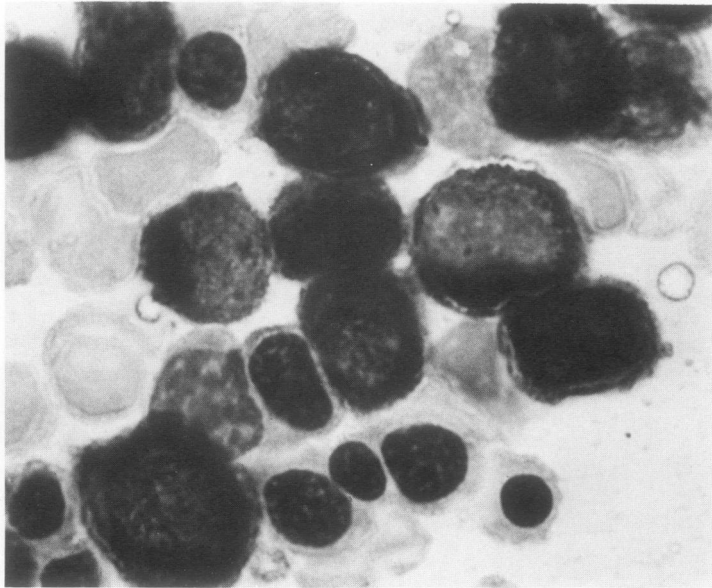


Figure 7—Monomyelocytic tumor. Subcutaneous tissue; formalin-fixed paraffin section. The entire section is comprised of immature monomyelocytic cells which demonstrate cytoplasmic staining (black) for lysozyme. Cytochemical studies (cryostat sections, imprints, and paraffin sections were evaluated) demonstrated NBE activity (inhibited with fluoride) and CAE activity in these cells. (Hematoxylin counterstain, $\times 900$) **Figure 8**—Acute myelogenous leukemia. Bone marrow aspirate; alcohol-fixed smear. Blasts show strong staining for intracytoplasmic lysozyme (black). No lysozyme identified in erythroid cells. (Hematoxylin counterstain, $\times 2000$)