

## Mouse Cytomegalovirus

### *Necrosis of Infected and Morphologically Normal Submaxillary Gland Acinar Cells During Termination of Chronic Infection*

Donald Henson, MD and Alfonso J. Strano, MD

The ultrastructural lesions in the submaxillary glands of C<sub>3</sub>H mice chronically infected with the murine cytomegalovirus are reported. Virus was synthesized in the nucleus of acinar glandular cells. After passage into the cytoplasm, virus was located in large vesicles which were derived from the Golgi apparatus. These vesicles, which were periodic acid-Schiff positive, migrated to the apex of the cell and released virus into the acinar lumen or canaliculi. Eventually, lymphocytes infiltrated the interstitium and surrounded the basal lamina of acini which contained infected cells. In acini encompassed by lymphocytes, both infected cells and morphologically normal acinar cells simultaneously degenerated, producing a small focus of necrosis. Physical contact between lymphocytes and necrotic cells did not occur for an intact basal lamina was always found interposed between them. Degeneration of infected cells coincided with a decrease in virus titer in the salivary glands. Degeneration of infected and normal acinar cells also occurred in DBA 2 mice which lack the fifth component of complement. In mice conditioned with cortisone to suppress inflammation, neither infected nor normal acinar cells degenerated. We concluded from the electron microscope observations that lymphocytes terminate chronic MCMV infection, that MCMV infection of acinar epithelium is not cytolytic and that normal cells also undergo necrosis during termination of chronic MCMV infection. It is postulated that lymphocytes in responding to infection release a cytotoxic substance which diffuses into the acini and causes indiscriminate necrosis of acinar cells (*Am J Pathol* 68:183-202, 1972).

MANY VIRUSES BELONGING TO SEVERAL DIFFERENT GROUPS produce chronic infection either in their natural or in experimental hosts. With some of these viruses specific pathologic lesions develop during the course of chronic infection which differ from lesions produced during acute infection. For instance, in man, subacute scleros-

---

From the Laboratory of Pathology, National Cancer Institute, and Viro-Pathology Branch, Armed Forces Institute of Pathology, Washington, DC.

The opinions or assertions contained herein are the private views of the authors and are not to be construed as official or as reflecting the views of the Department of the Army or the Department of Defense.

Supported in part by a research contract, Project Number 3A061102B71Q, from the Medical Research and Development Command, US Army, Washington, DC.

Accepted for publication Mar 7, 1972.

Address reprint requests to Dr. Donald Henson, Laboratory of Pathology, National Cancer Institute, National Institutes of Health, Room 2A-29, Bldg 10, Bethesda, Md 20014.

ing panencephalitis has been associated with chronic measles virus infection of the central nervous system;<sup>1-4</sup> and, in mice, glomerulonephritis frequently occurs during chronic lymphocytic choriomeningitis virus infections.<sup>5</sup> The mechanisms of virus-induced tissue injury during chronic infection have not been elucidated, although there is a consensus that numerous mechanisms are involved.<sup>6</sup>

The cytomegaloviruses (CMV) belong to the herpesvirus family and cause chronic infection in many species of animals in which they occur. In newborn infants, congenital CMV infection causes cytomegalic inclusion disease. In older children and adults, CMV infections have been associated with pneumonitis,<sup>7,8</sup> fever with rash,<sup>8</sup> heterophil-negative infectious mononucleosis,<sup>9,10</sup> parotitis<sup>11</sup> and hepatitis.<sup>12-14</sup> As with other viruses causing persistent infection, disease apparently can occur during the course of chronic CMV infection.<sup>8</sup> One approach to understanding the pathogenesis of human CMV infection involves experimental studies with laboratory animal strains of CMV. In mice, the murine cytomegalovirus (MCMV) produces a hepatitis<sup>15</sup> and chronic infection in salivary glands,<sup>16,17</sup> kidneys<sup>17</sup> and lymphoid tissue.<sup>18</sup> The hepatic lesions and sites of virus persistence are similar to that found in humans infected with CMV. In this report, the ultrastructural cellular lesions that occur in the submaxillary glands during chronic MCMV infection are described. The results suggest that one mechanism of virus-induced tissue injury operates during the termination of chronic infection.

## Materials and Methods

### Mice

Male C<sub>3</sub>H/He and DBA/2 mice 6 to 8 weeks of age were used. Mice were obtained from the NIH breeding colony and were free of MCMV infection.\*

### Experimental Procedure

Mice were inoculated intraperitoneally with 0.25 ml of virus suspension prepared by homogenizing the salivary glands of 3-week postinfected C<sub>3</sub>H mice. Virus suspension was initially prepared as a 10% homogenate in saline and diluted 10<sup>-2</sup> before injection. Following infection, submaxillary glands were removed twice a week for 9 weeks for electron and light microscopy. Generally, the left gland was fixed in Bouin's solution for light microscopy and the right gland was cut into 1-mm cubes and fixed in 0.1 M phosphate-buffered 4% glutaraldehyde at pH 7.2 for electron microscopy. In addition, mice were killed periodically after infection for assay of virus in the submaxillary glands. The methods of virus assay have been described.<sup>16,19</sup>

\* In conducting the research described in this report, the investigators adhered to the "Guide for Laboratory Animal Facilities and Care," as promulgated by the Committee on the Guide for Laboratory Animal Facilities and Care of the Institute of Laboratory Animal Resources, National Academy of Sciences-National Research Council.

### **Cortisone Administration**

Cortone® (Cortisone acetate, Merck, Sharpe and Dohme, West Point, Pa) was used. Mice were injected intraperitoneally 3 times a week with 0.5 mg cortisone beginning 10 days after MCMV infection.

### **Electron Microscopy**

Glutaraldehyde-fixed tissue was washed in phosphate-buffered 5% sucrose solution pH 7.2, postfixed in 1% osmium tetroxide in water, dehydrated in alcohol and propylene oxide and embedded in Epon 812. Sections were cut on a Porter-Blum MT-2 Ultramicrotome, double stained with uranyl acetate and lead hydroxide and examined with a Siemens Elmskop I. Over 1600 sections were examined in the electron microscope.

### **Histology**

Bouin's fixed tissues were embedded in paraffin and sections stained with hematoxylin and eosin or by the periodic acid-Schiff reaction. Reticulum stains were done by the Gridley method.

### **Results**

The submaxillary glands of C<sub>3</sub>H mice are trilobed, with each lobe containing only one type of secretory cell—serous, mucous or seromucous. During chronic infection, intranuclear inclusion bodies appear predominantly in seromucous secreting cells, occasionally in mucous secreting cells and rarely in serous secreting cells.

#### **Ultrastructure of the Seromucous Secreting Cells**

The ultrastructure of the seromucous secreting cells and acini is presented first as reference for describing changes in the infected cells. The acini consist of 8 to 10 pyramid-shaped cells with the apical regions forming the acinar lumen. The cytoplasm of these cells contains a well-developed Golgi apparatus, small amounts of rough and smooth endoplasmic reticulum, scattered small secretory granules, small vesicles near the Golgi region, occasional laminated myelin bodies and lysosomes. The nucleus is in the basilar half of the cell, oval in shape and has finely dispersed chromatin which is more dense along the nuclear membrane. The nucleolus is not prominent, but when present, it is located at the nuclear membrane. Laterally, the plasma membranes which interdigitate with adjacent cells are focally connected by desmosomes. Between adjacent cells are canaliculi formed by projecting microvilli. Surrounding the acini is a nonfenestrated basement lamina or membrane. Between the basal lamina and acinar cells lie the long, slender cytoplasmic processes of the myoepithelial cells. There are no desmosomes or interdigitating connections between acinar cells and

myoepithelial cells. Interspersed between acini in the interstitium are collagen bundles, nerve fibers, capillaries and some fibroblasts.

#### Multiplication of MCMV in Submaxillary Glands

Virus appeared in the submaxillary glands 7 to 10 days after infection, reached maximum titers by days 16 to 21, then decreased in titer during the subsequent 3 to 4 weeks. Intranuclear inclusion bodies, which appeared 1 to 3 days after infectious virus was detected, increased in number to about day 21, then decreased as the virus titer declined. Concomitant with a decrease in number of inclusions was a progressive focal interstitial inflammatory reaction (Table 1).

#### Ultrastructure of Submaxillary Glands from Infected C<sub>3</sub>H Mice

##### First Week

There were no changes evident. Although mature virus was seen in the hepatic sinusoids and vessels on days 4 to 7,<sup>20</sup> none was visible in arteries, capillaries or tissues of the salivary glands.

##### Second Week

The first indication of infection was not observed until the twelfth day. The nuclei of acinar cells became enlarged and rounded and the chromatin more uniformly dispersed. Within the region of the nucleolus, the first assembly of virus was seen. The nucleoli which remained along the nuclear membrane enlarged and exhibited feathering around the periphery (Figure 1). High-power magnification of the feathery edges revealed hollow fibrils identical to those of the virus

Table 1—Correlation of Virologic and Histologic Observations on Submaxillary Glands of C<sub>3</sub>H Mice Infected with the Murine Cytomegalovirus

Days after infection	Virus titer*	Relative No. intranuclear inclusions	Relative amount inflammation
4	<1.0 × 10 <sup>1</sup> †	—	—
16	2.9 × 10 <sup>6</sup>	+++	++
20	3.2 × 10 <sup>6</sup>	++++	+++
27	2.0 × 10 <sup>6</sup>	+++	++++
34	4.5 × 10 <sup>3</sup>	++	++++
43	7.5 × 10 <sup>1</sup>	—	++
55	1.8 × 10 <sup>2</sup>	—	—

\* Plaque-forming units per milliliter of a 10% salivary gland homogenate.

† Titer for one mouse.

membrane. Irregular dense cores soon became associated with and surrounded by these hollow fibrils which seemed to form the capsid of the virus. Subsequently, cores, fibrils and virus were seen throughout the nucleoplasm. As virus passed into the cytoplasm it acquired a second membrane from the inner nuclear membrane.

The first change evident in the cytoplasm of infected cells was an increase in number and size of organelles. The mitochondria enlarged, the cisternae of the smooth and rough endoplasmic reticulum dilated and the number of vesicles greatly increased, especially in the area of the Golgi apparatus. After emerging from the nucleus, the virions were usually seen free within the cytoplasm. Eventually, they made contact with a unit membrane of a dilated vesicle, and by a process of invagination, passed into the vesicle (Figure 2). As the virus entered the vesicle, it acquired a third membrane, or envelope, from the invaginated part of the vesicular membrane. Although this process occurred most often in the Golgi region, we have seen virus enter vesicles derived from the endoplasmic reticulum. Initially, the vesicles contained only several complete viral particles, but as time progressed the vesicles enlarged, particularly when they approached the apex of the cell, and eventually contained as many as 100 virions visible on thin sections (Figure 3). Often individual infected cells contained as many as 10 large vesicles and numerous smaller ones. Inside the vesicles, the virions were randomly arranged in a poorly staining granular matrix. With light microscopy, these large vesicles were periodic acid-Schiff positive and appeared as intracytoplasmic inclusion bodies. Eventually, these large vesicles reached the apical margin and ruptured releasing virus into the lumen or into the canaliculi (Figure 4).

As shown by multiple sections, the acini usually contained one, rarely two, infected cells. Occasionally, infected cells were binucleated with both nuclei producing virus.

At this stage, there were no changes in myoepithelial cells, basal lamina, or interstitial elements. The desmosome connections persisted between adjacent infected and uninfected cells.

#### Third Week

During this time, the number of infected cells increased, reaching maximum around day 21, which coincided with peak viral titers in the salivary gland. However, there were no significant changes in the infected cells. Although the number of viral particles within the acinar lumens, caniculi and ducts increased, virus was never seen in the interstitium, between or entering uninfected cells or in vascular chan-

nels. The morphology and development of MCMV in the submaxillary glands of inbred C<sub>3</sub>H mice resembles that reported for random bred Swiss-Webster mice.<sup>21</sup>

After the sixteenth day, inflammatory cells began to appear in the interstitium. They progressively increased in number and surrounded acini in which there were infected cells, often dispersing periacinar fibroblasts and collagen (Figure 5). The early infiltrate consisted of small lymphocytes, and later, a combination of small lymphocytes, larger lymphocytes corresponding to the intermediate type,<sup>22</sup> and macrophages. The intermediate type predominated and were usually found aligned along the periphery of the basal lamina. The lymphocytes had a moderately developed rough endoplasmic reticulum, prominent Golgi apparatus and large nucleolus. At this time, silver-impregnated histologic sections showed displacement and fragmentation of the periacinar reticulum and severe distortion of acini by the inflammatory cells. However, the basal lamina remained intact, despite marked distortion of the acini. Penetration of inflammatory cells through the basal lamina was not observed. Polymorphonuclear leucocytes were never seen in the interstitial tissues of the salivary glands.

#### Fourth and Fifth Weeks

During this time, the number of inflammatory cells increased and the first evidence of necrosis was noted in acini encompassed by lymphocytes. Necrotic changes occurred simultaneously in infected and in uninfected acinar cells (Figure 6). The lysosomes enlarged, often coalesced and accumulated a dense osmophilic amorphous material. Organelles surrounding the lysosomes seemed to disintegrate and the ergastoplasm became disorganized. This was accompanied by an increase in number and size of laminated bodies within vesicles. In the infected cells, vesicles which still contained virus collapsed and the virions were dispersed in the cytoplasm. Nuclear changes occurred after the cytoplasmic changes were moderately advanced; they consisted of chromatin condensation and subsequent pyknosis.

The number of uninfected cells undergoing necrosis varied in the different acini. In some of the acini, only cells adjacent to infected cells became necrotic while in other acini, all visible cells except myoepithelial cells degenerated (Figure 7).

Degeneration of cells was visible only in acini surrounded by lymphocytes. Infected cells found in acini about which there were no inflammatory cells showed no evidence of necrosis, even though numerous virus containing vesicles were present in the cytoplasm. Further-

more, physical contact between lymphocytes and degenerating cells was not observed for an intact basal lamina was always found interposed between them. Necrosis was not recognized in acini adjacent to those acini with infected cells. Necrosis of acinar cells was maximal from days 25 to 35, corresponding to a progressive decline in the titer of infectious virus. Necrotic cells were extruded into the lumen and apparently were removed by passage out the ducts.

The myoepithelial cells did not become infected nor did they degenerate with the acinar cells. Instead they enlarged and frequently extended their cytoplasmic processes toward the acinar lumen in between acinar cells (Figure 8).

#### **Sixth to Ninth Weeks**

This period was characterized by healing. Inflammatory cells migrated out of the submaxillary gland and the acini regenerated. The myoepithelial cells assumed their normal size and position. At the end of this period, the histology of the salivary gland was indistinguishable from that of uninfected mice.

#### **Mucous Secreting Glands**

In the lobe with mucous secreting cells there were fewer infected cells and correspondingly less inflammation. However, virus synthesis and the changes in the acini during termination of infection were virtually identical to that in the seromucous lobes.

#### **Cortisone Conditioned Mice**

In this group of mice the interstitial inflammatory reaction was completely suppressed through the entire period of observation. Compared to infected control mice, infected cells in this group exhibited greater cytomegaly, often compressing adjacent cells and severely distorting the acini. The cytoplasm of these cells also contained more vesicles filled with virus (Figure 9). However, we could not determine if this increase in number of vesicles resulted from greater virus production or delayed rupture at the apical plasma membrane. The assembly of virus, exodus of virus from the nucleus, and release from infected cells was the same as that in control mice. However, acini often contained 2 or 3 infected cells or, less frequently, multinucleated infected cells.

In the cortisone-conditioned mice there was no necrosis of infected or uninfected acinar cells. By day 39, when nearly all infected cells had degenerated in control mice, the infected cells were intact and

showed no evidence of necrosis or focal degenerative changes. We concluded from these observations that lymphocytes are essential for terminating chronic MCMV infection.

#### **DBA/2 Mice**

The DBA/2 strain was selected because it reportedly lacks the fifth component of complement (C5),<sup>23</sup> thus affording us the opportunity to test whether necrosis of acinar cells required complement.

The sequence of changes in the salivary glands of infected DBA/2 mice was similar to that seen in C<sub>3</sub>H mice. Inflammatory cells appeared in the interstitium and surrounded acini which contained infected cells; subsequently, both infected and uninfected acinar cells degenerated. This suggests, therefore, that C5 is not essential for necrosis of acinar cells and termination of MCMV infection.

#### **Discussion**

The results of this study support conclusions based on histologic observations that termination of chronic MCMV infection is associated with periacinar accumulation of lymphocytes.<sup>16</sup> In addition, the electron microscope revealed that, during termination of chronic infection, infected and morphologically normal acinar cells undergo simultaneous degeneration producing, in effect, a small focus of tissue necrosis. However, because of the dense inflammation and severe architectural distortion, these small focal lesions were not clearly evident in routine histologic sections. Interestingly, degeneration of acinar cells occurred while lymphocytes were aligned along the periphery of the basal lamina outside the acini. Lymphocytes were never seen within acini or in physical contact with necrotic cells. The basal lamina, which is considered to be a product of the overlying epithelium, remained intact and appeared to form an anatomical barrier between infected cells and lymphocytes.

Because acinar cells degenerated only in the presence of lymphocytes, we concluded that these inflammatory cells terminate chronic MCMV infection. This is consistent with other studies which suggest that cell-mediated immunologic mechanisms terminate certain viral infections. Mice infected with ectromelia virus and injected with anti-thymocyte serum to depress cellular immunity have a higher mortality than control mice.<sup>24</sup> Injections of spleen cells prepared from immune mice into marasmic mice infected with Coxsackie virus reduce mortality and extent of pathologic lesions.<sup>25</sup> Clinically, observations on human infants with primary immunologic deficiency diseases suggests



that cell-mediated immune mechanisms are essential for recovery from vaccinia virus infection.<sup>26</sup>

Although mechanisms by which lymphocytes terminate viral infections are unknown, recent studies have indicated that *in vitro* lymphocytes elaborate several cytotoxic substances following specific or non-specific mitogenic stimulation.<sup>27-29</sup> Released *in vivo*, these substances could diffuse and cause widespread tissue damage. Furthermore, lymphocytic choriomeningitis virus which also causes chronic infection in mice stimulates release *in vitro* of a cytotoxic factor from spleen cells of immune mice.<sup>30</sup> *In vitro*, this factor has a nonspecific effect, killing both infected and uninfected target cells.<sup>30</sup> Because of these data and the electron microscopic observations in this study, we suggest that lymphocytes, in responding to infection, released a cytotoxic substance which diffused into the acini and caused indiscriminate and simultaneous necrosis of acinar cells.

The possibility must be considered that uninfected cells either contained virus on their surface or were cryptically infected and were consequently treated as infected cells by the host. However, there was no morphologic evidence for these possibilities; uninfected cells appeared ultrastructurally normal, exhibited normal secretory activity prior to necrosis, did not contain intranuclear or intracytoplasmic virus and did not have virus visibly adsorbed on the surface. Furthermore, lymphocytes only surrounded acini in which there were infected cells. If acinar cells can become cryptically infected with MCMV, then one might expect that lymphocytes would also be found around acini in which no overt infected cells were seen. This, however, was not observed.

These morphologic studies suggest that MCMV infection of acinar epithelium is not cytolytic, in contrast to *in vitro* infection of mouse embryo cells<sup>19</sup> or macrophages.<sup>31</sup> Necrosis of acinar cells was seen only after inflammatory cells appeared in the periacinar interstitium and did not occur if cortisone was administered to suppress inflammation. These data are in accord with previously published histologic observations on MCMV chronically infected mice conditioned with cortisone.<sup>16</sup> Persistence of infected epithelial cells in the salivary glands and possibly in the renal tubules with periodic release of virus may be one mechanism of chronic intermittent excretion of virus in the saliva and in the urine.<sup>8</sup>

We do not know what attracts lymphocytes into the salivary glands of infected mice. It does not seem to be intact virions since they were never seen outside the acini. Necrotic cells were not visible until after

the lymphocytes appeared. Most probably, an antigenic alteration on the surface of infected cells attracted the lymphocytes, perhaps in a manner analogous to that by which lymphocytes are attracted into the area of an allograft. Although surface changes on MCMV-infected cells have not been demonstrated as yet, cells infected with a related virus, herpes simplex, acquire new membrane antigens demonstrable by several immunologic technics.<sup>32,33</sup> In addition, some interesting relationships exist between salivary gland tissue and lymphoid tissue. The submandibular glands of male mice contain a saline extractable substance which induces generalized lymphoid atrophy in mice and prolongs survival of H-2 incompatible skin allografts.<sup>34,35</sup> Also, a protein has been isolated from mouse salivary glands which induces *in vivo* and *in vitro* transformation of thymic small lymphocytes into cells of the plasma series.<sup>36</sup> What role these substances play, if any, in the pathogenesis of chronic MCMV infection is unknown at present.

Results of this study have implications for diseases of suspected viral etiology which are characterized by focal lesions such as multiple sclerosis or focal myocardial fibrosis. The morphologic data indicate that focal lesions can develop during the termination of a chronic viral infection. Consequently, in searching for viruses that cause focal lesions, one should also look in uninvolved areas of tissue since, in the necrotic foci, the infection may have already been terminated and the virus no longer present. Furthermore, these data raise the question whether the cerebral lesions of congenital CMV infection or other pathologic lesions associated with this virus result from a lymphocytotoxic substance.

Corticosteroids are considered to be contraindicated during CMV and many other viral infections. However, if pathologic lesions are caused by immunologic mechanisms, then corticosteroids or other immunosuppressive agents may be indicated. For instance, in adult mice infected with lymphocytic choriomeningitis virus, immunosuppression prevents manifestations of the disease.<sup>37,38</sup> In mice chronically infected with MCMV cortisone administration clearly suppresses the histologic lesions in the submaxillary glands<sup>16</sup> although it prolongs the infection. The beneficial effects of corticosteroid treatment on neonatal CMV infections have been reported.<sup>39-41</sup> Perhaps, in these cases, the corticosteroids were suppressing immunologically induced tissue injury.

From the morphologic data, we conclude that MCMV infection is not cytolytic in the salivary glands of mice, that lymphocytes are responsible for terminating chronic infection possibly by elaborating a

cytotoxic substance which diffuses into the acini and that morphologically normal acinar cells also degenerate during termination of chronic infection.

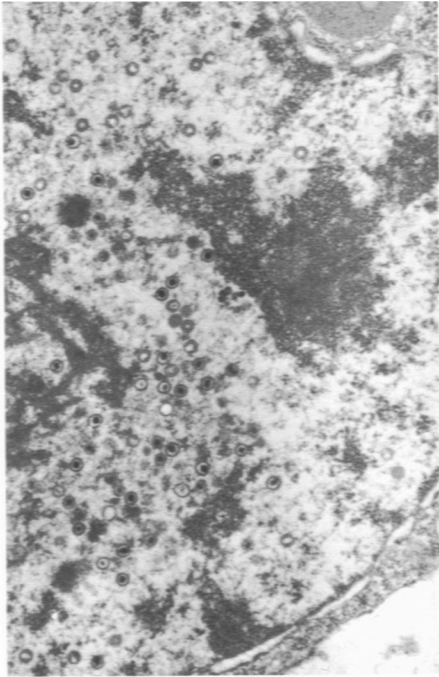
### References

1. Connolly JH, Allen IV, Hurwitz LJ, Millar JHD: Measles-virus antibody and antigen in subacute sclerosing panencephalitis. *Lancet* 1:542-544, 1967
2. Horta-Barbosa L, Fuccillo DA, Sever J, Zeman W: Subacute sclerosing panencephalitis: Isolation of measles virus from a brain biopsy. *Nature* 221: 974, 1969 (abstr)
3. Payne, FE, Baublis, JV, Itabashi, HH: Isolation of measles virus from cell cultures of brain from a patient with subacute sclerosing panencephalitis. *N Engl J Med* 281:585-589, 1969
4. Parker, JC Jr, Klintworth GK, Graham DG, Griffith JF: Uncommon morphologic features in subacute sclerosing panencephalitis (SSPE). *Am J Pathol* 61:275-289, 1970
5. Kajima M, Pollard M: Ultrastructural pathology of glomerular lesions in gnotobiotic mice with congenital lymphocytic choriomeningitis (LCM) virus infection. *Am J Pathol* 61:117-140, 1970
6. Brody JA, Henle W, Koprowski H, editors: *Chronic Infectious Neuro-pathic Agents (CHINA) and Other Slow Virus Infections*, Vol 40, *Current Topics in Microbiology and Immunology*. New York, Springer-Verlag, 1967
7. Craighead JE: Pulmonary cytomegalovirus infection in the adult. *Am J Pathol* 63:487-504, 1971
8. Henson D, Siegel SE, Fuccillo DA, Matthew E, Levine AS: Cytomegalovirus infections during acute childhood leukemia. Submitted for publication.
9. Klemola E, Kääriäinen L: Cytomegalovirus as a possible cause of a disease resembling infectious mononucleosis. *Br Med J* 2:1099-1102, 1965
10. Klemola E, von Easen R, Wager O, Haltia K, Koivuniemi A, Salmi I: Cytomegalovirus mononucleosis in previously healthy individuals: Five new cases and follow-up of 13 previously published cases. *Ann Int Med* 71:11-19, 1969
11. Diosi P, Rosin N: Cytomegalic infection in the submaxillary glands of an adult. *Pathol Microbiol* 28:420-424, 1965
12. Hanshaw J: Acquired cytomegalovirus infection: Association with hepatomegaly and abnormal liver function tests. *N Engl J Med* 272:602-609, 1965
13. Carter AR: Cytomegalovirus disease presenting as hepatitis. *Br Med J* 3:786, 1968
14. Henson D: Cytomegalovirus hepatitis in an adult. An autopsy report. *Arch Pathol* 88:199-203, 1969
15. Henson D, Smith RD, Gehrke J: Non-fatal mouse cytomegalovirus hepatitis: Combined morphologic, virologic and immunologic observations. *Am J Pathol* 49:871-888, 1966
16. Henson D, Neapolitan C: Pathogenesis of chronic mouse cytomegalovirus infection in submaxillary glands of C<sub>3</sub>H mice. *Am J Pathol* 58:255-267, 1970
17. Medearis DN Jr: Mouse cytomegalovirus infection. II. Observations during prolonged infections. *Am J Hyg* 80:103-112, 1964

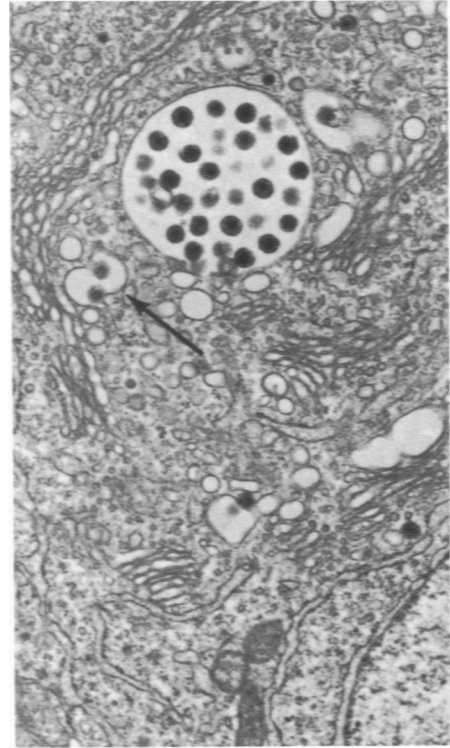
18. Henson D, Strano A, Slotnik M, Goodheart C: Mouse cytomegalovirus: Isolation from lymphoid organs of chronically infected mice. (In press)
19. Henson D, Pinkerton H: Characteristics of a plaque method for the murine salivary gland virus. *Proc Soc Exp Biol Med* 114:130-133, 1963
20. Henson D, Strano A: Unpublished data
21. Reubner BH, Hirano T, Slusser R, Osborn J, Medearis DN Jr: Cytomegalovirus infection. Viral ultrastructure with particular reference to the relationship of lysosomes to cytoplasmic inclusions. *Am J Pathol* 48:971-989, 1966
22. Daniels JC, Ritzman SE, Levin WC: Lymphocytes. Morphological, developmental and functional characteristics in health, disease and experimental study. An analytical review. *Tex Rep Biol Med* 26:5-93, 1968
23. Nilsson UR, Müller-Eberhard HJ: Deficiency of the fifth component of complement in mice with an inherited complement defect. *J Exp Med* 125:1-16, 1967
24. Blanden RV: Mechanisms of recovery from a generalized viral infection: Mousepox I. The effects of antithymocyte serum. *J Exp Med* 132:1035-1054, 1970
25. Woodruff JF, Woodruff JJ: Modification of severe coxsackievirus B<sub>1</sub> infection in marasmic mice by transfer of immune lymphoid cells. *Proc Nat Acad Sci USA* 68:2108-2111, 1971
26. Fulginiti VA, Kempe CH, Hathaway WE, Pearlman DS, Sieber OF, Eller JJ, Joyner JJ, Robinson A: Progressive vaccinia in immunologically deficient individuals. *Immunologic Deficiency Dis in Man* 4:129, 1968
27. Granger GA, Kolb WP: Lymphocyte *in vitro* cytotoxicity: Mechanisms of immune and non-immune small lymphocyte mediated target L Cell destruction. *J Immunol* 101:111-120, 1968
28. Williams TW, Granger GA: Lymphocyte *in vitro* cytotoxicity: Mechanism of lymphotoxin-induced target cell destruction. *J Immunol* 102:911-918, 1969
29. Granger GA, Moore GE, White JG, Matzinger P, Sundsmo JS, Shupe S, Kolb WP, Kramer J, Glade PR: Production of lymphotoxin and migration inhibitory factor by established human lymphocytic cell lines. *J Immunol* 104:1476-1485, 1970
30. Oldstone MBA, Dixon FJ: Tissue injury in lymphocytic choriomeningitis viral infection: Virus-induced immunologically specific release of a cytotoxic factor from immune lymphoid cells. *Virology* 42:805-813, 1970
31. Tegtmeyer, PJ, Craighead JE: Infection of adult mouse macrophages *in vitro* with cytomegalovirus. *Proc Soc Exp Biol Med* 129:690-694, 1968
32. Nii S, Morgan C, Rose HM, Hsu KC: Electron microscopy of herpes simplex virus. IV. Studies with ferritin-conjugated antibodies. *J Virol* 2:1172-1184, 1968
33. Roizman B, Spear PG: Herpesvirus antigens on cell membranes detected by centrifugation of membrane-antibody complexes. *Science* 171:298-300, 1971
34. Takeda T, Yamasaki Y, Yamabe H, Suzuki Y, Haebara H, Irino T, Grollman A: Atrophy of the lymphoid tissues of mice induced by extracts of the submaxillary gland. *Proc Soc Exp Biol Med* 126:212-216, 1967
35. Kongshavn PAL, Bliss JQ: Effect of mouse submandibular gland extracts on survival of H-2 incompatible skin allografts. *Immunol* 19:363-367, 1970

36. Naughton MA, Koch J, Hoffman H, Bender V, Hagopian H, Hamilton E: Isolation and activity of a thymocyte-transforming factor from the mouse submaxillary gland. *Exp Cell Res* 57:95-103, 1969
37. Rowe W: Studies on pathogenesis and immunity in lymphocytic choriomeningitis infection of the mouse. *Naval Med Res Inst Rep* 12:167-219, 1954
38. Hotchin J, Weigand H: The effects of pre-treatment with X-rays on the pathogenesis of lymphocytic choriomeningitis in mice. I. Host survival, virus multiplication and leucocytosis. *J Immunol* 87:675-681, 1961
39. Margileth AM: Diagnosis and treatment of generalized cytomegalic inclusion disease of newborn. *Pediatrics* 15:270-283, 1955
40. Birdsong M, Smith DE, Mitchell FN, Corey JH Jr: Generalized cytomegalic inclusion disease in newborn infants. *JAMA* 162:1305-1308, 1956
41. Gelderen HH van: Successfully treated case of cytomegalic disease in a newborn infant. *Acta Paediat* 48:169-174, 1959

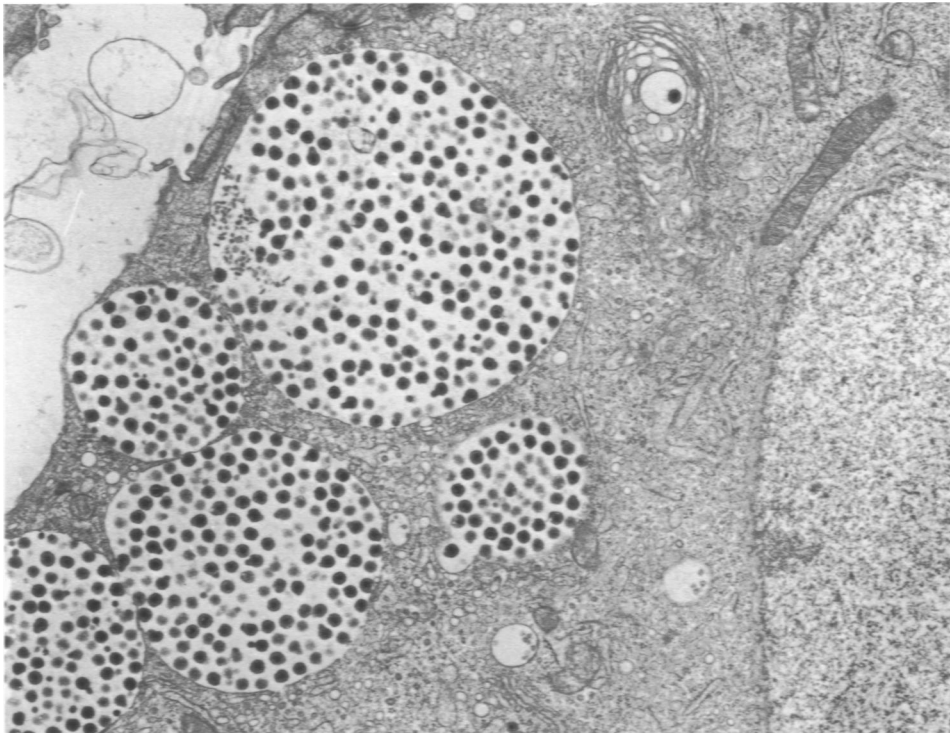
*[Illustrations follow]*



1



2



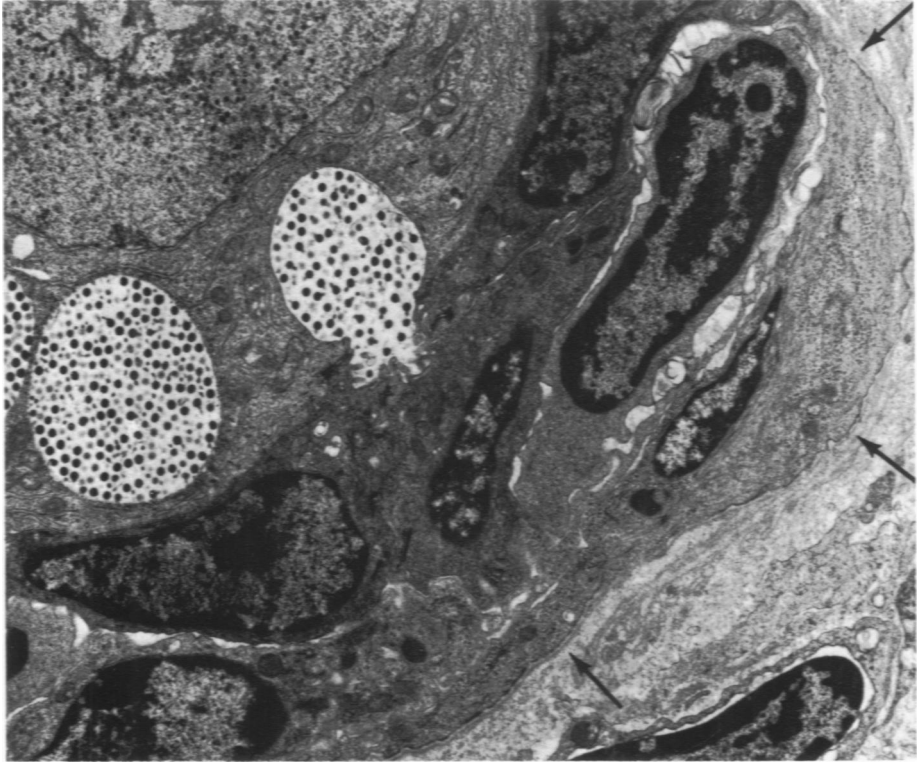
3

**Fig 1**—An enlarged nucleolus in an infected cell. The nucleolus is partly surrounded by filamentous structures which form the virus capsid ( $\times 15,900$ ). **Fig 2**—Virus (arrows) budding into small vesicle in region of Golgi. Adjacent is a large virus-filled vesicle. Other viral particles lie free within cytoplasm ( $\times 14,000$ ). **Fig 3**—Salivary gland from C<sub>3</sub>H mouse 21 days after mouse cytomegavirus infection. Large virus-filled vesicles are present in apical cytoplasm near acinar lumen ( $\times 9600$ ).

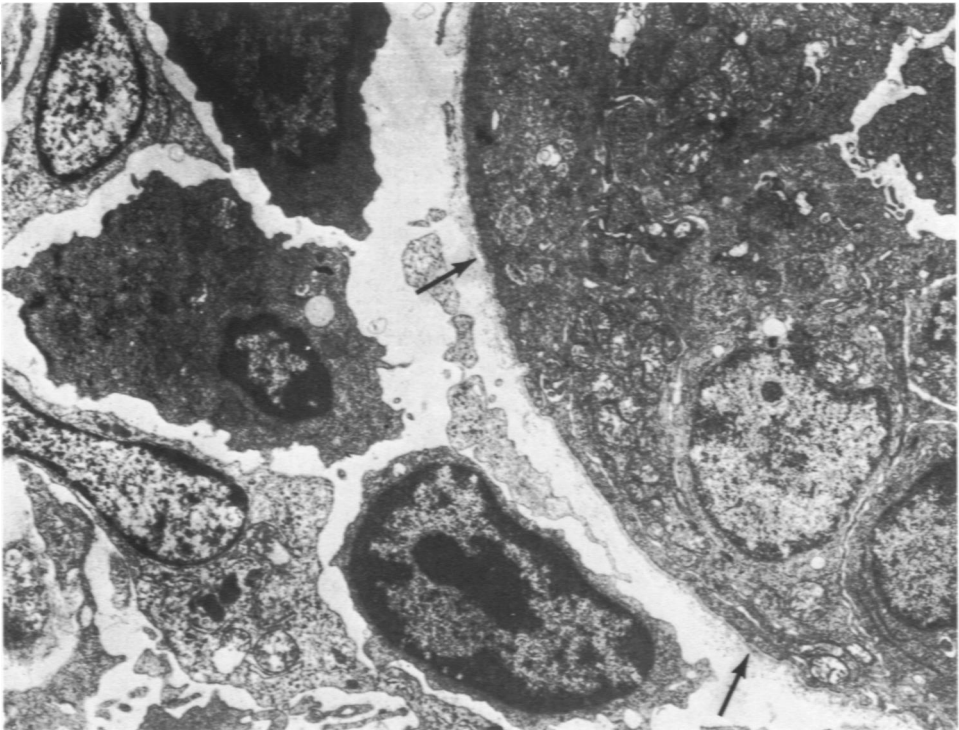
**Fig 4**—Mouse 23 days after infection. A virus-filled vesicle has ruptured releasing virus into a canaliculus. Nucleus of infected cell contains virus. Contiguous uninfected acinar cells are markedly compressed by the enlarged infected cell and the acinus distorted. *Arrows* indicate basal lamina (× 6750).

**Fig 5**—C<sub>3</sub>H submaxillary gland 34 days after MCMV infection. To the right in the electron micrograph is part of an acinus surrounded by an intact basal lamina (*arrows*). Infected acinar cell is not included in the micrograph. Three lymphocytes are present to the left in the interstitium. Penetration of lymphocytes through basal lamina was never observed (× 4000).

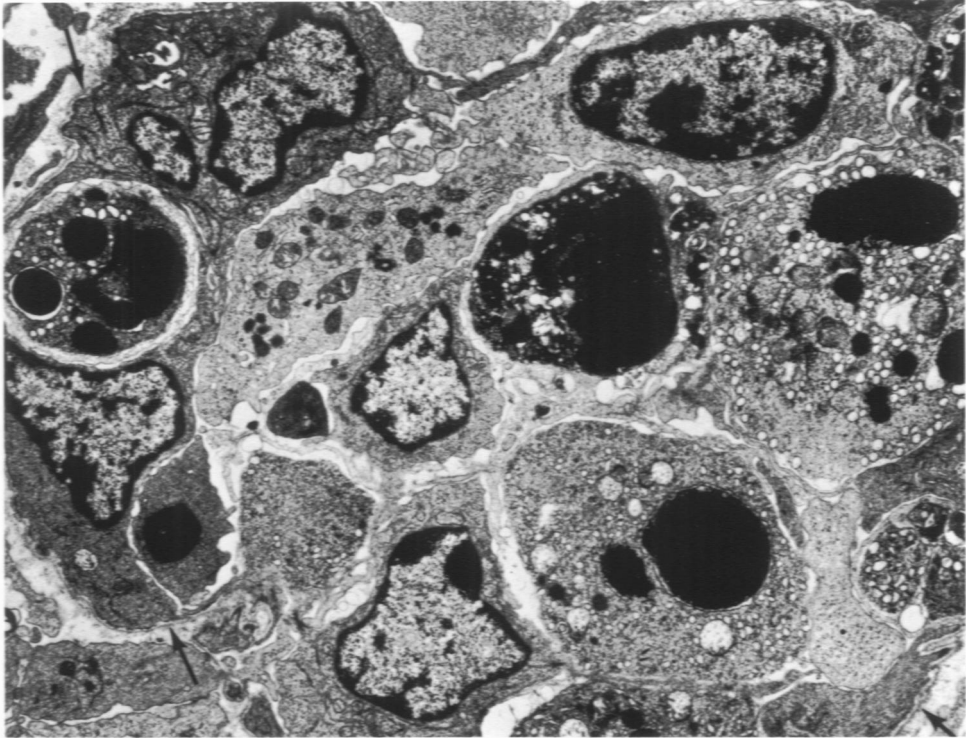




4



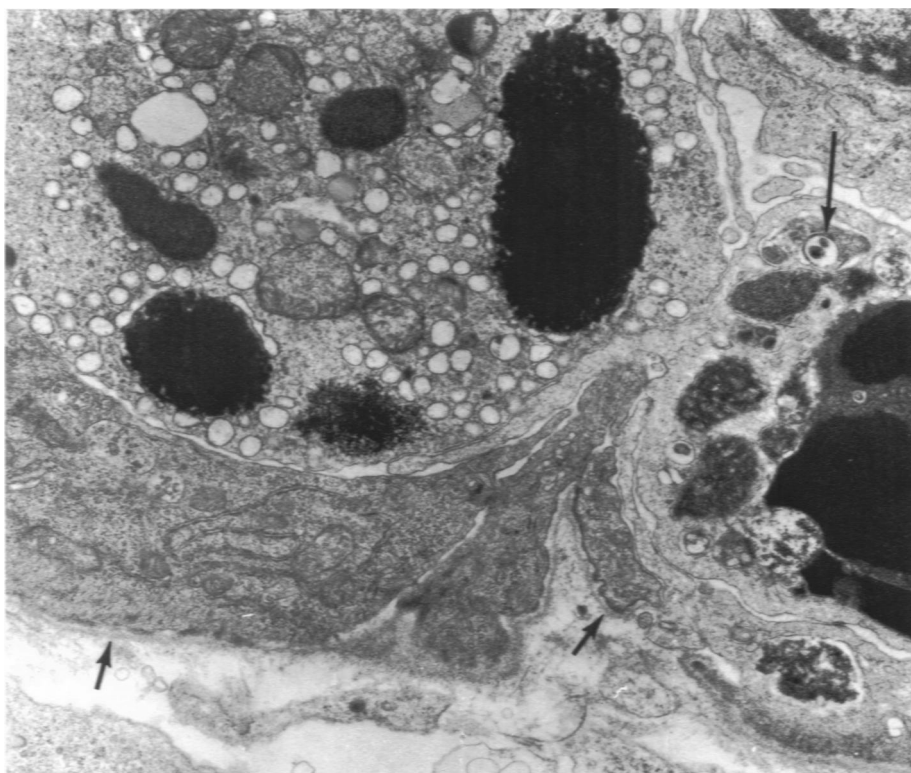5



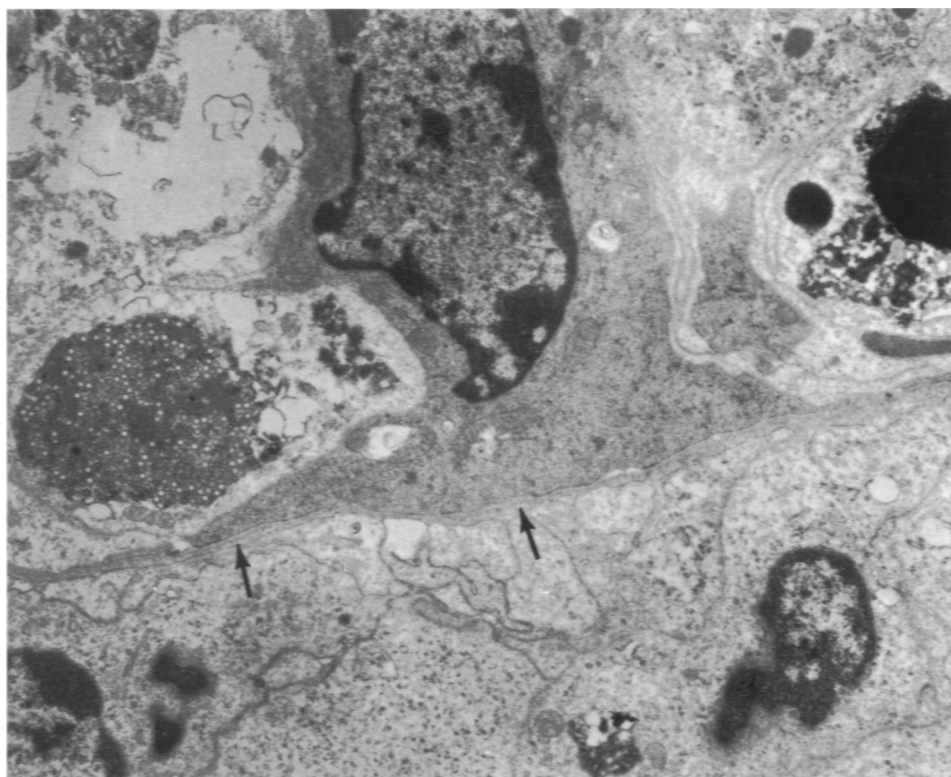
**Fig 6**—Section through acinus from submaxillary gland of C<sub>57</sub>H mouse 34 days after MCMV infection. Many of the acinar cells are undergoing necrosis, characterized by an accumulation of dense osmophilic material within large cytoplasmic vesicles. At this advanced stage of degeneration, it was often difficult to determine which cell had been infected. An intact basal lamina is present around the periphery (*arrows*) ( $\times 4800$ ).

**Fig 7**—Necrosis of adjacent infected and non-infected acinar cells 34 days post infection. Basal lamina (*arrows*) is intact. Infected cell is recognized by remnants of virus-filled vesicles (*long arrow*) in cytoplasm. Part of a myoepithelial cell is situated between basal lamina and noninfected cell ( $\times 10,600$ ).

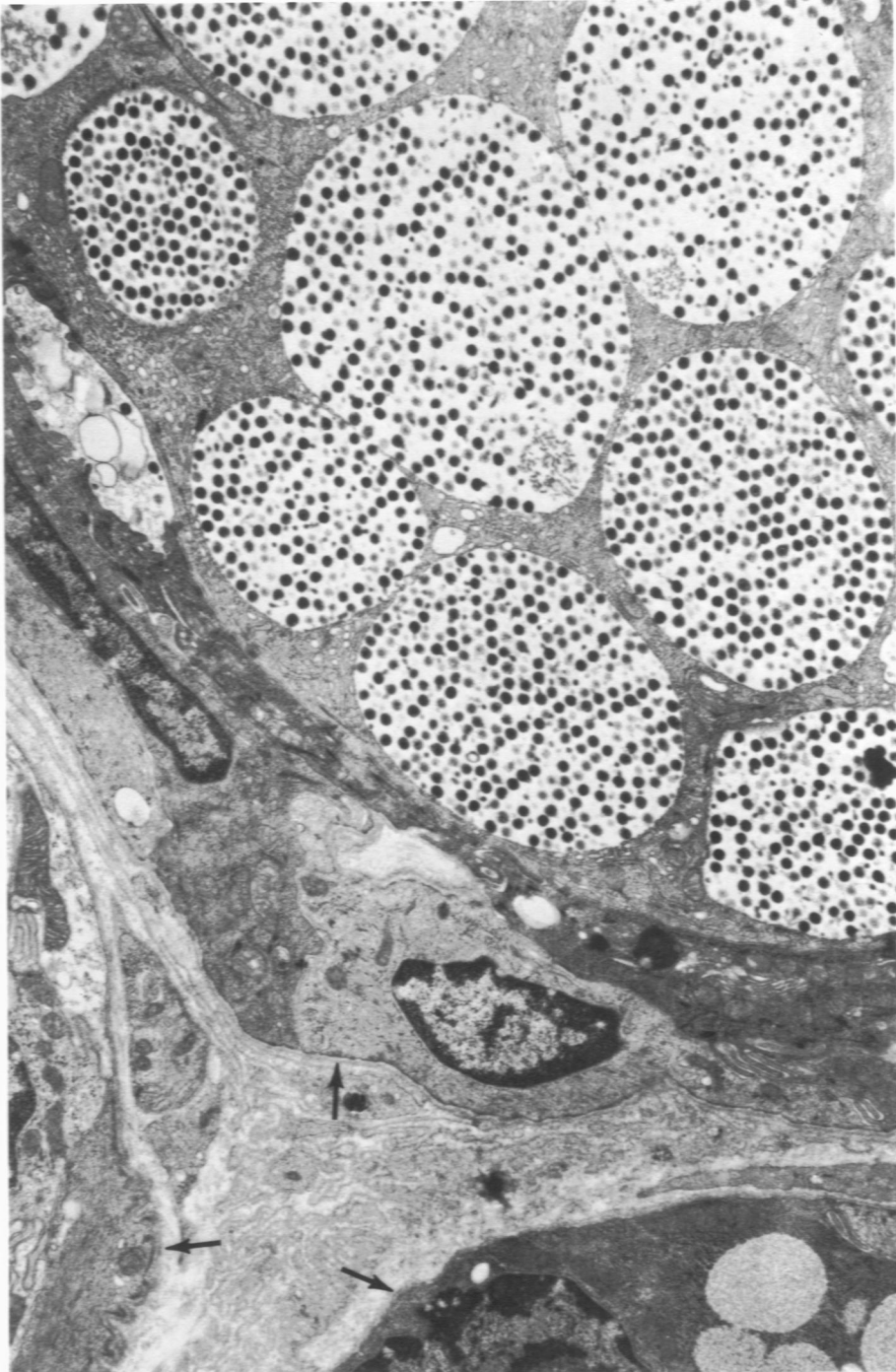
**Fig 8**—C<sub>57</sub>H mouse salivary gland 39 days after infection. *Arrows* indicate intact basal lamina. In the center is a myoepithelial cell with its cytoplasm extending toward the acinar lumen. To the left is a degenerating infected cell recognizable by the presence of incomplete virions. To the right is degeneration of a noninfected acinar cell characterized by accumulation of dense osmophilic material. Inflammatory cells are present along the basal lamina outside the acinus ( $\times 6000$ ).



7



8



**Fig 9**—Submaxillary gland from cortisone-conditioned C,H mouse 28 days after infection. Numerous large vesicles containing mature virions fill cytoplasm of an enlarged cell. There is no evidence of necrosis. Inflammatory cells are not present in the interstitium. Arrows indicate basal lamina of two adjacent acini and small duct ( $\times 10,200$ ).