

**REVIEW  
ARTICLE**

**THE PATHOLOGY OF RENAL  
HOMOGRAFT REJECTION**

# The Pathology of Renal Homograft Rejection

## *A Review*

David T. Rowlands, Jr., MD, Gary S. Hill, MD, and  
Chester M. Zmijewski, PhD

THE PATHOLOGY OF ALLOGRAFT REJECTION has, in recent years, become important to the general anatomic pathologist because of the increasing frequency of organ transplants and the increasing success in overcoming graft rejection. Because of these therapeutic triumphs, anatomic pathologists are often presented with tissue in which the basic process and textbook picture of graft rejection have been extensively modified. It is hoped that this review will provide a useful approach to interpreting anatomic changes in human organ grafts.

### **General Aspects of Graft Rejection**

The work of Medawar and his colleagues in the 1940s<sup>1-4</sup> set the stage for our understanding of the pathology of graft rejection. It was already generally appreciated that higher animals were able to readily recognize allografted tissue (with rare exceptions such as the cornea) as foreign and to react to these tissues. However, until Medawar's classic studies, with the exception of transplanted tumors,<sup>5</sup> there was general confusion whether or not graft rejection depended on immunologic mechanisms.

Medawar's studies defined several cardinal points of the biology of transplantation: the first evolved from his demonstration of "second set" rejection in which animals rejected the second of two sequentially placed grafts more rapidly than the first graft. That this form of recognition is highly specific could be shown by the failure of the animal sensitized by an initial graft to reject tissue from another animal more rapidly.

Other investigators extended these observations to show that under appropriate conditions, antibodies against the donor could be demonstrated in the blood of the recipient.<sup>6-8</sup> This indicated that there was some form of humoral sensitivity involved in graft rejection. A second major point to emerge from early studies was that sensitization of the host could be conferred by other tissues from the same individual and even by

---

From the Department of Pathology, University of Pennsylvania School of Medicine, Philadelphia, Pennsylvania.

Supported in part by Grant CA-15822 from the US Public Health Service.

Address reprint requests to Dr. David T. Rowlands, Jr., Department of Pathology, University of Pennsylvania, School of Medicine, Philadelphia, PA 19174.

injections of leukocytes.<sup>9</sup> Thus, the concept evolved that the major antigens responsible for rejection are characteristic of the individual and not of a specific tissue or organ. These alloantigens have been named *histocompatibility antigens*, and the major histocompatibility system in man has been assigned the designation HLA.

Histocompatibility antigens of the HLA system have been extensively studied and characterized biologically, largely by making use of the fact that these antigens may induce circulating antibodies in individuals who do not carry the antigen. It has been possible to partially define the HLA locus in man by serologic techniques such as lymphocytotoxicity and leucoagglutination. Antisera used for this purpose are derived for the most part from multiparous women who have been stimulated by repeated exposure to paternal antigens carried by fetal cells.<sup>10-12</sup>

A considerable amount of information regarding the mode of inheritance and biologic significance of the HLA system has been derived from additional data obtained in genetic studies of large family groups and from skin grafts exchanged among members of such groups. The HLA genetic region is a complex, highly polymorphic chromosomal locus, initially thought to consist of two subloci, first called LA and FOUR, and now known as A and B. According to the two sublocus hypothesis, each of the subloci carries one of a series of mutually exclusive alleles that controls the production of a single HLA antigen. Therefore, each parent contributing a single chromosome has the potential of transmitting only two HLA alleles to his offspring. As a consequence, and because of codominance, every individual can have no more than four HLA antigens. This idea has been modified somewhat, since (as will be mentioned later), it is now known that there are, in fact, four closely linked HLA loci and not two subloci. The general principle, however, that one-half of an individual's genotype or haplotype with respect to HLA is inherited from one parent still holds true. An important consequence of this mode of inheritance is that a person is by definition HLA semiidentical with each parent, and therefore has a one in two chance of being semiidentical with a sibling and a one in four chance of being identical with that sibling. The significance of this is underlined when it is realized that there are now at least 47 HLA antigens recognized at the first two loci alone.<sup>13,14</sup> Thus the chance of finding an HLA-identical individual in the general population is very small. Computerized techniques among cooperating centers comparing a given donor to a large selection of potential recipients have greatly increased the chances of locating a donor with a perfect match or a mismatch for only one HLA antigen<sup>15</sup> in either the A or B loci.

At this time, the histocompatibility antigens have been only partially

purified and characterized chemically.<sup>16</sup> The antigens appear to be polypeptides of moderately large molecular weight (48,000 daltons), with a small carbohydrate moiety. They can be split on exposure to acid or other dissociating agents into two fragments. The larger, about 33,000 daltons, appears to be different for each antigen and carries the antigenic specificity. The smaller, at 11,000 daltons, has been shown to be similar to and probably identical to  $\beta$ -2-microglobulin, first identified as a protein in urine and since shown to be widely distributed on cell surfaces of lymphocytes and many cells of mesenchymal and epithelial origin.  $\beta$ -2-Microglobulin is constant in structure among all HLA antigens and is strikingly similar to the constant regions of immunoglobulins.<sup>17</sup> HLA antigens are confined to cell surfaces, both endothelial and epithelial, and it is known that they are absent from glomerular basement membranes. There is some suggestion that, although HLA antigens are expressed on both lymphocytes and kidney cells, there may be quantitative differences in their expression on the two cell types, so that on occasion antigens not detected on the lymphocytes used in typing may be subsequently found on cultures of transplanted kidney cells.

The HLA system has turned out to be much more complex than the two sublocus hypothesis originally proposed.<sup>14</sup> It is now realized that there are a series of serologically defined (SD) HLA antigens which are under the control of a third locus. This locus, labeled C, is very close to but not identical with the second or B locus. The five antigens controlled by alleles in this region are more difficult to define than other serologically defined HLA antigens due to a lack of monospecific antisera, and their clinical relevance in terms of transplantation has not yet been fully ascertained.

In addition to three loci controlling the production of serologically demonstrable antigens, there is a fourth HLA locus, called D. Antigens determined by alleles found at this HLA locus cannot be recognized by routine serologic tests and depend on mixed lymphocyte culture (MLC) for their recognition. The MLC reaction is based on the principal fact that blast transformation and mitosis occur when genetically dissimilar lymphocytes are cultured together. The reactions are evaluated by measuring the uptake of tritiated thymidine by the cells in culture as an index of DNA synthesis. Thus far, six alleles have been recognized at this locus, which seems to be very near the B locus.

The HLA gene complex has been shown to be situated on chromosome 6, and the order of loci according to their genetic distance away from the centromere appears to be D-B-C-A. The genetic distance between the loci is not great, so that the alleles appear to be closely linked. However, cross-

over and genetic recombination does occur. As might be expected, this is most frequent between B and A and much less frequent between B and C and B and D.

Besides histocompatibility antigens, there are other genes near the HL-A complex controlling the synthesis of properdin factor (Bf) and perhaps other complement factors as well.

In the mouse, the H-2 locus, which thus far seems completely analogous to the HLA locus in man, has been identified and extensively characterized in genetic and immunologic terms. In addition to SD and LD histocompatibility antigens similar to those in man, there is a series of genes governing immune responses, the so-called Ir genes. These genes determine whether or not there will be an antibody response to a given series of antigens and the magnitude of that response. It seems likely that these genes are identical to those which determine the degree of susceptibility to various oncogenic viruses. Such genes have not yet been identified in man, but the analogy between the H-2 and HLA systems has been so perfect to date that it seems quite likely that they will be. And, indeed, in primates other than man, there is evidence that these genes exist at a locus analogous to the D locus.<sup>18</sup>

Ir genes, if demonstrated in man, may be found to be partly, or perhaps entirely, responsible for two very interesting and important clinical phenomena. The first of these is the association of various HLA phenotypes with given disease entities, as for example the association between HLA-B27 and ankylosing spondylitis, where 90% of patients carry the B27 allele compared to only 8% of controls, or the association of the two antigens DW2 and B7 with multiple sclerosis. It is suggested that these HLA antigens and certain immune response genes are in strong linkage disequilibrium. (*Linkage disequilibrium* is the tendency for alleles at closely linked loci to be transmitted together rather than segregating randomly.) According to this theory, these immune response alleles would then be the actual factor responsible for determining susceptibility to these diseases, the HLA antigen simply serving as a marker for the likely presence of the responsible immune response allele.

A second phenomenon which may be explained by immune response genes is the well-documented clinical observation that some patients who have had multiple pregnancies and/or transfusions have failed to make antibodies against the histocompatibility antigens to which they have been exposed, whereas others have responded with vigorous antibody production. These groups have been labeled *nonresponders* and *responders*, respectively, and it has been found that the nonresponders as a group

tolerate transplanted kidneys substantially better, with longer graft survival, than the responder group (see discussion of this phenomenon below).

The degree of correlation between the "tissue match" and the graft survival has been a matter of intense study.<sup>19</sup> Certainly, identity of transplantation antigens, as in identical twins, is associated with the best results in terms of graft survival (90 to 100% 1 year). This is especially striking when compared to results of grafts using cadaver donors (55% 1-year survival overall) where a match, even for the two major SD loci, is uncommon. Where a parent serves as donor, the values for graft survival are intermediate (75% with 1-year survival). Among the group of cadaver donors, where matching is probably most important, the correlation between tissue typing and graft survival is not as good as one might have hoped. Examination of the data from the European experience (Eurotransplant and Scandia transplant) in a very large series reveals a broad correlation between the match at the A and B loci and survival, the best results being obtained with grafts having a four-antigen match and the worst with those completely unmatched.<sup>20</sup> The American experience has not been so favorable, although even here the same broad trends have been noted.<sup>21</sup> An interesting sidelight of analysis of recent transplant experience by Terasaki<sup>19</sup> is the fact that graft survival among *all* groups of transplantees, both living-related and cadaver, has been declining at the rate of approximately 2% per year since the late 1960s, with an overall decline among all groups of 15 to 20% in the last decade. The reason for this is not clear at present. Terasaki feels that it may relate to the fact that patients are now no longer transfused as frequently in the pretransplant period as in former years and demonstrates that those patients with six or more transfusions have had substantially better graft survival than those with no transfusions. However, it is also probable that the observation is merely a statistical artifact resulting from uncontrolled data and errors in the massive input.

It is very tempting to relate this observation to the clinical observation that a second renal graft may have an enhanced survival in some patients with humoral immunity directed against the histocompatibility antigens, leading some workers to suggest that these antibodies enhance graft survival.<sup>18-23</sup>

However, there are multiple other factors which might explain the overall decline in graft survival, perhaps most importantly the fact that nowadays a broader range of patients, both younger and older and often in more serious condition, is undergoing transplantation than in the 1960s.

Another aspect of histocompatibility matching which has received no-

tice in recent years is the suggestion in some studies that certain antigens at the B locus are stronger and more important in determining rejection than those at the A locus. This contention has been contested by other authors. However, there is no absolute certainty that the association with poor graft survival is concerned directly with these supposedly "strong" antigens or with known alleles at the C or D locus in strong linkage disequilibrium with the recognized antigens of the B locus. The possibility remains that there are still other antigens, as yet unrecognized, controlled by the HLA region and in strong genetic disequilibrium with the recognized alleles. These unknown antigens could in fact be the true transplantation antigens. Therefore, HLA though acting as a genetic marker, is not the total answer.

The D locus is known to be responsible for significant histocompatibility differences. Preliminary studies have been presented showing a correlation between the results of MLC studies and graft survival,<sup>24</sup> but there are no large-scale studies currently available that systematically evaluate the relative contribution of incompatibilities at the D as well as the C locus to graft survival in the same manner that information is available for antigens at the A and B loci.

In addition to the four loci described above, there is another locus which may also be in the vicinity of the HLA complex, responsible for a whole new series of alloantigens that, unlike the widely distributed HLA antigens, appear to be confined largely to the B lymphocytes. Antisera to these B-cell alloantigens strongly inhibit the MLC reaction, possibly by blocking receptors on the stimulating cells. It is thought that these antibodies may represent the classic "enhancing" antibodies recognized in various tumor systems. Because of certain analogies between these antigens and similar ones found in the Ir complex of the mouse, it has been speculated that B cell antigens may have an even more significant role in graft compatibility than the recognized antigens of the HLA system. This point will certainly be the subject of a great deal of study in the next few years.

Although HLA antigens represent the system of greatest concern in man, it is important to recognize that other antigens may also determine the fate of an organ allograft.<sup>11,19,25</sup> For example, the donor and recipient must be matched with regard to their major blood group antigens. The antigens of the ABO blood group system are present not only on erythrocytes, but also in tissues. What is more, as will be pointed out later, the humoral antibody directed against A, B, and H antigens, which is universally present, can cause immediate hyperacute rejection. Thus the ABO barrier cannot be transgressed, and the antigens, because of their extreme

importance in graft rejection, have been labeled by some as the strongest human transplantation antigens.

Graft rejection depends, as outlined above, upon host recognition of the grafted tissue as foreign. The host becomes sensitized to these foreign antigens either locally at the site of the graft or by transport of appropriate antigens to the host's lymphoid tissues.<sup>26-29</sup> "Passenger leukocytes," donor leukocytes lodged in the interstitium and small vessels which leave the graft after transplantation and enter the host's circulation, may account for the latter form of sensitization.<sup>30-33</sup> Or small patches of antigen-bearing material such as cellular fragments may be phagocytized by host macrophages, and the antigenic information transported to lymph nodes in this fashion.

It is now generally appreciated that the efferent or effector aspect of graft rejection has both cellular and humoral components.<sup>25</sup> Early work had concentrated primarily on the cellular mechanisms of graft rejection, and initially there was skepticism that humoral immunity played *any* role in allograft rejection. The initial reports of Medawar<sup>1-4</sup> pointed to the intense inflammatory infiltration of lymphocytes as representing the fundamental immune response generated by the host towards the graft. Because of the nature of the cells involved in this immune response and their localization about small vascular channels, it was believed that graft rejection represented a form of cellular immunity similar to delayed hypersensitivity. It was noted that these inflammatory cells appear before there is readily demonstrable tissue damage, suggesting that these lymphocytes are the cause of tissue damage rather than a response to it. As might be anticipated, such cellular infiltrates are limited or absent in grafts whose survival has been prolonged by drug-induced suppression of the host's immune response. Further support for the thesis that cellular immunity accounts for graft rejection was given by the early failures to transfer sensitivity to grafted tissues to normal animals with serum in the face of the ease with which this sensitivity could be transferred to normal animals with lymphoid cells.<sup>34-37</sup>

It has since been shown that a portion of the lymphocytes in the graft are from clones of immunologically committed cells which have developed in regional nodes and the spleen in specific response to the antigen stimulus.<sup>38,39</sup> Other unsensitized lymphocytes appear in the graft by poorly understood mechanisms; some of these lymphocytes may subsequently have sensitization conferred upon them. The sensitized lymphocytes release a variety of substance upon contact with graft antigens and one of these, migration inhibition factor (MIF), may be partially responsible for the accumulation of macrophages within the graft.<sup>40</sup> In



addition, some lymphocytes may be stimulated to proliferate directly by passenger leukocytes, a situation analogous to the mixed lymphocyte culture performed *in vitro*.

Most of the cells which gather early in the graft are thymus-derived (T) lymphocytes. The lymphocytes obstruct capillary lumens of the graft and are capable, in a manner which is not yet clear, of damaging the endothelium, leading even to disruption of the capillary wall with leakage of cells and fluid into the interstitium.<sup>41</sup> As alluded to above, the interstitial and peritubular accumulations of lymphocytes which appear are the clinical reflections of cell-mediated immunity.

Although it remains likely that cellular immunity is the prime mechanism by which grafts are rejected, it is now generally agreed that humoral immunity also plays an important role in allograft injury.<sup>25</sup> Evidence in support of this view came very early from the observation that grafts between disparate species of animals (xenografts) were lost more rapidly than would be expected with allografts. Secondly, it was known that a second allograft, using the same donor-recipient pair, was lost more rapidly than was the first graft. These accelerated graft rejections often showed a pale or white appearance (hence "white graft"), a finding which resulted from damage to blood vessels. In both the xenografts and white grafts it could be shown that antibodies to donor tissues were plentiful and appeared to play an important role in graft rejection.

Since both of these conditions were unusual, it was persistently maintained that humoral immunity was insignificant in ordinary allograft rejection. However, in recent years, other evidence has accumulated supporting the active participation of humoral immunity in rejection of allografts.<sup>8,42-44</sup> Several observations are important in this regard; the first is the relative prominence of plasma cells in the inflammatory infiltrate in rejecting grafts, particularly with the passage of time, as compared with their paucity in the infiltrates seen in classic delayed hypersensitivity reactions. A second piece of evidence supporting the role of antibodies in allograft rejection comes from the observation that vascular changes are common in many renal allografts.<sup>45-50</sup> First to be appreciated were the thickened vascular walls in long-standing renal allografts, but it was soon found that acute vascular alterations were frequent in experimental graft rejection as well as in human renal allografts undergoing acute rejection. It was then only a short step to demonstrating that circulating antibodies participated in these acute vascular injuries. Although it is uncertain whether the vascular injury comes about as a result of direct antigen-antibody interaction or through immune complex formation and deposition, it is clear that complement is involved in the initial injury. It

has now been shown that there is antibody production in regional lymph nodes as early as 48 hours after transplantation.<sup>35</sup> It has also been shown that humoral antibodies *in vitro* are capable of killing renal allograft cells.<sup>51-53</sup> A final observation supporting a role for humoral immunity in graft rejection is that multiparous women, because of their extensive opportunities to respond with humoral immunity to histocompatibility antigens, are more apt to reject a renal allograft than are otherwise comparable graft recipients.<sup>54-58</sup>

### **Pathologic Changes in Renal Autografts and Isografts**

The transplant specimen the pathologist is most frequently asked to evaluate is a biopsy of renal allograft that has been removed from 1 hour to several years posttransplant in a recipient receiving variable amounts of steroid and immunosuppressive medication. The kidney may have come either from a living related donor, most often a parent or sibling, or from a cadaver donor. The basic question the pathologist is asked is: "How severe is graft rejection here?", or put another way: "What is the balance between rejection phenomena, infection, and the effects of therapy?"

In order to evaluate these questions, it is first necessary to dissect away those alterations attributable simply to surgical trauma from those due to immunologic graft rejection. Second, it is necessary to have some appreciation for the type, severity, and time-course of lesions in rejection of grafts unmodified by any immunosuppressive therapy in order to evaluate the extent to which therapy has altered graft rejection of the biopsied tissue.

Having looked at these issues, we will turn our attention to examination of the changes in renal allografts in recipients under immunosuppressive therapy.

In evaluating posttransplant biopsies, particularly those from recently transplanted kidneys, it is important to remember that, in addition to rejection, certain nonimmunologic factors related simply to procedures necessary for translocation of the kidney may themselves contribute to the structural alterations seen. Both mechanical factors (e.g., interruption of lymphatics and nerves) and anoxia from temporary interruption of blood flow can lead to significant changes in both renal structure and function.

The two models which appear to be most useful in analyzing these factors are instances where the kidney is removed temporarily and replaced in either the same site or an alternate site (autografts) and grafts between identical twins (isografts).<sup>59,60</sup> The immediate changes seen in these renal grafts are similar and reversible, so that little, if any, residual

evidence of injury is seen on rebiopsy several months later. The principal morphologic changes are mild degrees of renal tubular necrosis and lymphocytic infiltrates, both of which are probably consequences of transient anoxia. It is also common to find some degree of renal edema as a result of interruption of renal lymphatic vessels. Clinically, there is usually a transient diminution in urine output and variable proteinuria, both of which correct themselves in a few weeks.

In the case of transplants between identical twins, if the original disease was nonimmunologic, i.e., nonglomerulonephritic, in nature the recipient usually can manage very nicely without immunosuppression. If, on the other hand, the initial disease was glomerulonephritis, a large proportion (11 of 19 in one series)<sup>61</sup> may develop recurrence of glomerulonephritis in the graft if immunosuppressive therapy is not given. In addition to those changes resulting from tissue anoxia, other alterations, sometimes of a severe nature, may be associated with perfusion of the kidney prior to transplantation. Both perfusion damage and the recurrence of glomerulonephritis will be discussed later.

#### **Pathology of Renal Allograft Rejection in Nonsensitized, Nonimmunosuppressed Recipients**

There are few instances of renal allografts in strictly nonimmunosuppressed recipients since, in most instances, renal transplantation is done in recipients with uremia. It has been well established that uremia is, in itself, immunosuppressive and that this is especially dramatic as it relates to cellular immune functions. However, by combining the results achieved in such human transplants with the observations made in untreated animals (largely dogs), it is possible to arrive at a general picture of the morphologic events in unmodified rejection of renal allografts.

In canine allografts, striking renal enlargement (three times normal size) caused by edema and inflammation becomes obvious within several days after transplantation.<sup>62,63</sup> By light microscopy the earliest alterations are within small blood vessels where lymphocytes can be identified adhering to the endothelium of peritubular capillaries.<sup>47</sup> The bulk of these early-appearing small lymphocytes are thought to be T lymphocytes. They show considerable interaction with the endothelium, the exact nature of which is not understood.<sup>50</sup> The affected endothelial cells may develop cytoplasmic basophilia due to increased numbers of polyribosomes and rough endoplasmic reticulum, and display occasional mitoses. Some of the endothelial cells swell and rupture, together with their underlying basement membranes, with leakage of fluid and cells into the interstitium.<sup>64</sup> Other lymphocytes pass directly through the endothelium into the inter-

stitium. The exudation of cells and fluid produced in this manner may so compromise renal blood flow that necrosis of renal tubules results, leading to oliguria. Although small lymphocytes comprise the bulk of the inflammatory cells seen earliest in the tissues, it is not long until these cells are joined by medium-sized lymphocytes and plasma cells, presumably originating from the B-lymphocyte series. Although neither vascular nor glomerular lesions are detected with ease in these kidneys, immunoglobulins may be found in arterial walls as early as 2 days after the onset of graft rejection.<sup>50</sup> By 15 days there is vivid staining on immunofluorescence of the medium-sized lymphocytes and plasma cells in the interstitium, primarily for IgG. Terminally, these kidneys may show extensive thrombosis of interlobular arteries and afferent arterioles, with resulting hemorrhage and infarction. Only at this final stage of graft rejections are significant numbers of granulocytes present.

As implied above, there are no entirely satisfactory studies of organ graft rejection in unmodified human recipients.<sup>65</sup> The best that can be offered for comparison are patients in whom uremia with or without small amounts of steroids served to suppress a portion of the host's immune response.<sup>66</sup> In these cases, the cellular infiltrate was similar to that described above in canine renal allografts, but the tempo of rejection in these patients was delayed, and vascular lesions were more prominent than might have been expected from the experiments using unmodified canine recipients.

### **Pathology of Renal Allografts in Sensitized Recipients**

Having examined, on the one hand, renal autografts and isografts where rejection does not occur and the course of unmodified graft rejection on the other, we can now look at the changes in renal allografts in recipients under immunosuppressive therapy. These, of course, constitute the overwhelming majority of transplant recipients. As described above, presensitization may derive from a number of sources other than the prospective donor. It may occur because of pregnancy, prior transfusion, prior infections (particularly streptococcal), and exposure to a variety of antigens, most prominent among which are the ABH and HL-A antigen groups. The tempo of graft rejection will, in general, be a function of the degree of host sensitization and the magnitude of mismatch between recipient and donor.

In considering graft rejection in these patients, it is important to discriminate between alterations of acute graft rejection and more chronic changes in the organ grafts. In addition, certain highly sensitized patients

form a separate category which can only be regarded as instances of hyperacute graft rejection.

It should be emphasized that, although most acute rejection crises occur in the first 2 months or so after transplantation, clear-cut episodes of acute rejection, both clinically and morphologically, can develop months and even years after transplantation. Therefore, the pathologic classification into hyperacute, acute, or chronic rejection is not based specifically upon the duration of the transplant but upon the nature of the inflammatory lesions seen on biopsy.

#### **Acute Rejection**

As was suggested earlier, acute graft rejection is a combined process in which both cellular and humoral tissue injury play important parts.<sup>25,47,49,64</sup> Interstitial edema may appear quite early, before significant cellular infiltration. Its effect in compromising and slowing the renal circulation has been proposed by some as part of the reason for the suppression of renal function seen in acute graft rejection. As is the case in unmodified recipients, the earliest cellular infiltrates are small lymphocytes among which medium-sized lymphocytes and plasma cells soon appear, together with occasional basophils. These latter cells may be responsible for liberating vasoactive substances both directly and through the mediation of platelet-activating factors (PAF). It must be emphasized that, contrary to what its name might suggest in terms of the concepts of general pathology, acute rejection is *not* marked by any significant number of granulocytes. For the most part, the cellular exudates appear about renal tubules (Figure 1). As in rejection in unmodified graft recipients, there may be extensive disruption of peritubular capillaries with interstitial edema and interference with renal blood flow. Even in the absence of rupture of the capillaries, there may be necrosis of the endothelium with or without associated capillary thrombosis. Lymphocytes may be seen invading the tubular lumens. The damaged tubular epithelium shows some regenerative activity with mitoses in the face of degeneration and necrosis, but should rejection not be checked, tubular atrophy is inevitable. The renal glomeruli are usually spared in this acute process, but on occasion there may be a mild proliferative glomerulitis, with prominence of the glomerular mesangial and epithelial cells. There may be an infiltration of the glomeruli by mononuclear cells originating from the blood and masses of fibrin and platelets may also be seen on occasion.<sup>67</sup> Isolated endothelial and mesangial necrosis may be encountered. Typically, the mononuclear cellular exudate, felt to represent cell-mediated injury, dominates the changes seen in these patients.

Necrosis of arterial vessels is variable in these cases. In some, only isolated smooth muscles display evidence of necrosis. In others, examination will often disclose evidence of vascular injury. Vascular endothelial cells may show varying combinations of lysis, fibrinoid necrosis, and hyperplasia. Accumulations of fibrin and lipid appear in macrophages in the subintimal regions of these blood vessels. There may be sharply circumscribed dissolution of the internal elastic lamina with fibrinoid necrosis in the underlying media. This necrosis may be marked only by loss of smooth muscle nuclei, with eosinophilic smudging of the cytoplasm, particularly in the earlier stages. Later, neutrophils may be prominent in and about the vessel wall, and thrombosis is common in such vessels. Lesions are commonest in afferent arterioles, and may occasionally be seen in glomeruli and capillaries but only rarely in larger vessels. Immunofluorescence will disclose deposits of immunoglobulins and complement in such vessels, confirming the humoral nature of the insult. Electron microscopic examinations of acute graft rejection are of value only in confirming the disruption of peritubular capillaries, recognition of isolated smooth muscle cell necrosis, and the heterogeneity of the cellular infiltrate.

#### **Chronic Rejection**

Since most of these instances of acute graft rejection are modified by appropriate antirejection therapy, it is not uncommon to find more chronic changes in renal allografts.<sup>25,47,49,64</sup> In going from acute to chronic, the balance shifts from a picture where interstitial cellular infiltrates predominate to one in which vascular lesions are the dominant feature. The cellular infiltrates persist in a peritubular location but are typically rather sparse. They are composed of an admixture of lymphocytes, histiocytes, and plasma cells. There is low-grade, slowly advancing damage to tubular epithelium and basement membranes, evidenced by lymphocytes in the tubular cells and tubular lumens. This results in progressive interstitial fibrosis with obliteration of much of the peritubular capillary bed.

Arterial and arteriolar narrowing are the most striking lesions morphologically and eventually the most significant functionally (Figure 2). Depending on the stage of development and the level of rejection activity, the vessels may present a variety of appearances from simple hyperplasia of intimal cells, as marked by nuclear prominence with some cytoplasmic basophilia, to frank proliferation with thickening, often massive, of the intima and reduplication of the elastica. In more recent or active lesions the thickened intima may be quite cellular. By electron microscopy, the

intima in such situations is seen to be composed of collagen fibrils and myointimal and smooth muscle cells, together with varying amounts of amorphous granular material. This intimal thickening arises as the result of repeated deposition of fibrin and platelet aggregates which become covered by endothelium and incorporated into the intima. This material breaks down and there is ingrowth of smooth muscle elements and of fibroblasts with collagen deposition (Figure 3). If sufficiently abundant, the smooth muscle not infrequently arranges itself circumferentially about the now greatly compromised vascular lumen to form a second media. Where the rejection process is more active, occasional mononuclear inflammatory cells may be found in the thickened intima, and lipid and lipid-laden macrophages (Figure 2) may be prominent. When yet more active, mononuclear cells and even granulocytes may be found in the media and adventitia as well, with development of frank arteritis. Disruption of the elastica may be seen as part of an arteritic lesion or may represent the residue of fibrinoid necrosis (more typically a part of acute rejection). Vessels with intimal thickening usually show intimal staining for fibrin<sup>46,50,66</sup> on immunofluorescence. In the smaller vessels, particularly, there may be staining of the entire wall in a through-and-through manner for complement and IgM, less frequently for IgG. The presence of immunoglobulins and or complement in these vessels during the first 2 months after graft rejection often portends a poor prognosis for the survival of the kidney. An acute arteritis may sometimes be superimposed on the chronic lesions. This is most readily seen in nephrectomy specimens, particularly in those patients where immunosuppression has been discontinued prior to excision of the graft.

Glomeruli in chronic graft rejection show no constant pattern of injury. They may be entirely normal in appearance, but the most common appearance is one of mild shrinkage of the glomerular tufts with variable thickening of the walls of the glomerular capillaries, with or without focal segmental increases in mesangial cells and glomerular matrix (Figure 2). The picture is very much that of early ischemic atrophy, and certainly ischemia must play a role in the pathogenesis of glomerular damage, especially in those cases with substantial arterial and arteriolar lesions. However, not typical of ischemia is the finding of extensive widening of the subendothelial spaces by deposits of amorphous, relatively electron-lucent material, believed to represent, in part, degradation products of fibrin. Immunofluorescence usually reveals an irregular, finely granular capillary and mesangial staining for IgM and C3; occasionally, IgG will stain the capillary loops in a continuous linear fashion. In the glomerulus there appears to be little correlation between the presence of deposits and

prognosis. The lesions appear generally indolent and may persist for long periods, even years, with little or no abnormality of renal function attributable to them. Eventually, with advancing arterial and arteriolar lesions, the glomeruli will become atrophic and sclerotic.

Some patients, however, will display a frank proliferative glomerulitis, with prominent mesangial proliferation and endothelial swelling with variable degrees of secondary epithelial response, even including crescent formation in the more florid cases.<sup>49,68</sup> Such a glomerulitis can usually be distinguished from a recurrent glomerulonephritis in that, although there may be substantial increase in mesangial tissues, even with circumferential subendothelial extensions, deposits are seldom present in significant numbers (*vide infra*).

The deposition of immunoglobulins and complement in vascular walls and glomeruli suggest that both the vascular lesions and those glomerular lesions not attributable to ischemia may be mediated in part by humoral antibodies with complement fixation and secondary activation of the clotting mechanism. The latter is evidenced directly by the increases in fibrin split products seen during clinical rejection episodes. The specificity of the antibodies deposited in glomeruli remains to be defined. They probably include antibodies directed, at least in part, against the histocompatibility antigens of the graft; but they may also include antibodies directed against bacteria and viruses, against antigens released from the renal parenchyma (analogous to the situation in so-called Heymann nephritis where the tubular brush border serves as the inciting antigen), and against horse antilymphocyte globulin when this is administered as part of the immunosuppressive regimen. Two observations, however, indicate that the possibility must remain open that, in addition to humoral immunity, cellular immunity may play a role in the vascular lesions and, by extension, in the glomerular lesions. The first observation is the sometimes very striking vascular and perivascular mononuclear infiltration, and the second is the fact that one may see cases in which vascular and glomerular lesions are quite extensive but immunofluorescence studies are totally negative.

In summary: The most significant lesion of chronic rejection, both in morphologic and in functional terms, is the gradual compromise and obliteration of the vascular bed at the arterial and arteriolar levels as well as at the glomerular and peritubular capillary levels. These vascular lesions, along with the rather indolent-appearing chronic inflammation, account for progressively worsening renal function reflected in replacement by fibrous tissue of destroyed renal parenchyma.

These special examples of graft rejection reflect the generalized re-



sponse of the host to foreign antigens. Although our interest is most appropriately concentrated on the kidney transplant, it should be commented that the responses of the reticuloendothelial system to antigens in this situation are similar to those observed when exposed to any antigen. In each instance both the lymph nodes regional to the graft and the spleen become hyperplastic, being populated by large pyroninophilic cells. These cells are most prominent about splenic arterioles and about post-capillary venules of lymph nodes. Observations of changes have been made systematically in rabbits receiving skin allografts. The changes in regional lymph nodes are striking at 4 days after transplantation with abundant transitional cells and striking germinal centers being evident. There is continued intensification of this process for the initial 9 days after grafting. Finally, with complete rejection of graft, the process subsides but regression of the hyperplastic lymphoid tissues is not complete until 25 days after grafting.<sup>69</sup>

#### **Hyperacute Rejection**

In the subjects described above, the renal grafts were carried out in recipients free of circulating antibodies directed against the allografts. But if antibodies against the donor are present in the host, accelerated graft rejection may be seen, similar to that in "second set" rejection, discussed above. For example, when renal grafts have been carried out in situations where the donor and recipient are mismatched with regard to major blood groups, it is common to see prompt loss of renal function.<sup>70-72</sup> In these cases, the antibodies of the host react with blood cells in the kidney as well as with blood group antigens present on the vascular endothelium of the kidney. The latter reaction leads to formation of intravascular platelet aggregates with widespread microthromboses and engorgement of the blood vessels with consequent swelling and discoloration of the kidney. When such grafts are removed and examined, they are boggy and, on microscopic examination, display masses of red blood cells, platelet aggregates, and fibrin in the renal vasculature; this was most strikingly demonstrated in the renal glomeruli.

Of less obvious cause are those instances in which antibodies are preformed in the host against donor histocompatibility antigens or other donor antigens.<sup>43,73-76</sup> In these cases the tempo of graft rejection is greatly accelerated and the term *hyperacute rejection* can be applied. Emphasis on the vascular aspects is key to this variant of graft rejection. There is binding of cytotoxic antibodies to antigens on the vascular endothelium, with prompt fixation of complement immediately after implantation of

the kidney. This is evidenced by linear deposition of IgG and C3 in glomerular and peritubular capillaries. Complement fixation results in chemotaxis of polymorphonuclear leukocytes and lysis of endothelial cells, laying bare the underlying basement membrane. This basement membrane then functions as a thrombogenic surface, leading to secondary vascular thrombosis. Biopsy as early as 1 hour posttransplantation reveals abundant polymorphonuclear leukocytes clinging to glomerular and peritubular capillary walls; in more severe cases, frank platelet and fibrin thrombi are seen. In addition, there may be swelling, vacuolization, and lysis of the endothelium of afferent arterioles and even of larger vessels. This process progresses rapidly to thrombosis and fibrinoid necrosis, with neutrophils being in evidence both in the vessel walls and in the parenchyma immediately surrounding the vessels.

In many cases this process of microthrombosis leads shortly to total cortical necrosis and to loss of the graft. In addition to the acute inflammatory exudate and infarcted tissues, abundant hemorrhages result from disruption of blood vessels. Graft rejection in cases of xenografts have an appearance similar to this. In spite of the extensive injuries seen in hyperacute graft rejection, surprisingly, kidneys do not invariably fail completely. In a number of instances an initial hyperacute rejection in which minute thrombi in multiple vessels were associated with renal failure was followed by eventual complete recovery of the kidney. On rebiopsy, up to a year after the initial episode of hyperacute rejection, no residual structural injury could be seen in such cases.<sup>76</sup>

Most of the early examples of hyperacute rejection occurred in situations where there was a positive cytotoxicity test between donor lymphocytes and recipient serum. In one study of 195 transplants with negative crossmatches, only 8 transplanted kidneys failed to function immediately, whereas 24 of 30 kidneys with positive crossmatches failed to function.<sup>77</sup> It was quickly realized that a positive crossmatch was a contraindication to transplantation and the practice of transplanting in the face of a positive crossmatch was abandoned in most centers. This alone should have very greatly reduced the incidence of hyperacute rejection, but the clinical and morphologic picture of hyperacute rejection has continued to be all too common. This has been attributed to insufficiently sensitive lymphocytotoxicity tests and in a few instances, it has been demonstrated that antibodies are present to donor kidney cells but not to donor lymphocytes, explaining the failure of function in the face of negative lymphocytotoxicity tests.<sup>77</sup> More and more often, however, lesions of perfusion-related injury are held to account for hyperacute rejection.<sup>78</sup>

### Perfusion-Related Renal Allograft Injury

A picture morphologically and clinically identical to that seen in hyperacute rejection may be produced in recipients of some machine-perfused cadaver kidneys.<sup>78</sup> These kidneys are preserved during the period between removal from the donor and implantation into the recipient by pulsatile perfusion in the cold on a Belzer or similar machine, usually employing a cryoprecipitated plasma mixture as the perfusate. Damage to the kidney may occur during perfusion by one or both of two mechanisms: first, in some instances, both experimental and clinical, it is possible to demonstrate cytotoxic antibodies in the cryoprecipitated plasma.<sup>79</sup> These antibodies attach to the kidney endothelium during perfusion, but it is only on implantation of the kidney that complement becomes available and is activated, the endothelium lysed, and thrombosis produced. In other instances,<sup>78</sup> it is possible on preimplantation biopsies to demonstrate rents in the endothelium, presumably arising either from mechanical damage to the kidney by the perfusion apparatus or in some instances from cellular degeneration related to an overly protracted warm ischemia time. Once again, these kidneys display the extent of their damage only on implantation into the recipient. In the one instance the endothelial damage derives from cytotoxic antibodies (analogous to hyperacute rejection except that there the antibodies come from the host and not from the perfusate). In the other instance, the endothelial damage is mechanical or degenerative. In both instances the thrombosis is secondary to endothelial damage and is nonspecific with regard to the immune system.

Morphologically such kidneys show lesions identical to those of hyperacute rejection—polymorphonuclear leukocytes and fibrin thrombi in glomeruli associated with vascular thrombosis and fibrinoid necrosis (Figure 4). However, it is important to distinguish clearly between these mechanisms, for perfusion-related injury is an acute self-limited injury which may resolve without much residual deficit in renal function, whereas true hyperacute rejection has an ominous prognosis and calls for different therapeutic maneuvers. The presence of abundant polymorphonuclear leukocytes and fibrin in an immediately posttransplant biopsy should no longer be taken as *prima facie* evidence of hyperacute rejection. The possibility that this constellation of morphologic alterations may represent perfusion-related injury must also be taken strongly into consideration.

### Differential Diagnosis of Renal Graft Rejection

The pathologist is frequently presented with material from a biopsy taken at a time of crisis in the patient's posttransplantation course, marked

usually by oliguria and varying degrees of azotemia. He is asked to determine if evidence of graft rejection is present and, if so, how severe. It is important in this situation to be able to distinguish graft rejection from a variety of nonimmunologic disorders which may befall the kidney. This may be difficult because many such disorders are marked by varying degrees of acute and chronic inflammation involving both vessels and interstitium, changes that can be seen in graft rejection as well.

Perhaps the most important disorder to be distinguished from graft rejection is acute tubular necrosis. Oliguria in the immediate post-transplant period may be due to graft rejection, acute tubular necrosis, or to a combination of the two. Both are marked by swelling and tenderness of the kidney, with interstitial edema, patchy areas of ischemia, and degeneration or necrosis (often extensive) of tubules. The distinction between the two is made on the basis of the paucity or absence of the characteristic features of rejection—interstitial nephritis, arteritis, or glomerular lesions. (If acute rejection is present, then the possibility of a superadded acute tubular necrosis, related perhaps to prolonged ischemia time, cannot be ruled out. But in this instance the distinction is not of great importance in immediate therapeutic terms.)

It is increasingly being recognized that varying degrees of acute tubular necrosis and acute renal failure may result from arteriography and excretory urography in the transplant patient.<sup>80,81</sup> In well-documented cases, diminution in urinary output typically begins within hours of the examination. It has long been recognized that acute tubular necrosis occurs sporadically in patients receiving iodinated contrast media, but the transplant patient seems particularly susceptible to the noxious effects of these agents. The tubular lesions so produced have little to distinguish them from acute tubular necrosis due to other causes. Their appearance, however, should trigger the pathologist to alert the clinician to this possibility. If the temporal relationships between onset of oliguria and prior urography are appropriate, the contrast medium may be implicated as the cause. (Often this is not possible because there has been some diminution of function before the examination which has, in fact, prompted the performance of the test.)

Arterial, venous, or ureteral occlusion and lymphocele are all recognized complications of transplantation.<sup>82</sup> For the most part, these complications are diagnosed by clinical approaches, principally arteriography and surgical exploration. Occasionally, however, a biopsy from such a kidney is given to the pathologist for study. These conditions may be marked by obvious infarcts, venous congestion with thrombosis, or interstitial edema, respectively. Or there may be little to indicate the nature of

the process. The crucial feature which will betray the presence of one of these processes, however, is the absence of indicators of acute rejection of sufficient magnitude to explain the more or less total urinary suppression which customarily accompanies such obstructions. The pathologist is thus alerted to search more diligently for minor evidences of such a process and to advise the clinician of its probable presence.

Progressing on to more purely inflammatory lesions, wedge biopsies of the kidney, especially those that are superficial, may result in some diagnostic confusion since the thickened capsules of transplanted kidneys are frequently associated with accumulations of mononuclear cells subjacent to the capsule. This sort of chronic inflammation can be distinguished from graft rejection because the cells are often localized to the immediate subcapsular zone and these infiltrates are often more homogeneous, being made up of small lymphocytes, than is the case of mononuclear cellular inflammation of graft rejection.

Similarly, infections of renal allografts may be troublesome since they usually are associated with interstitial infiltrates of acute or chronic inflammatory cells. In many instances these infiltrates are distinguishable from those of graft rejection because they contain significant numbers of polymorphonuclear leukocytes which are absent from all but the most florid acute and hyperacute rejection. In other instances, e.g., granulomatous infections, the classic morphology of the inflammatory change may identify the nature of the process. Fortunately, the issue is often readily resolved by the identification of the offending microorganism.

Less often, the renal biopsy may be difficult to interpret because of vasculitis accompanying graft rejection and the need for its distinction from a primary renal vasculitis. There have, as yet, been too few cases of this sort reported to feel comfortable in making this distinction with certainty in its various forms. However, our early experience suggests that the vasculitis of graft rejection is most common in small arteries and arterioles, in contrast to the spotty affliction of larger renal arterial vessels in many instances of primary vasculitis. It is our further impression that vasculitis usually occurs only in hyperacute rejection or florid rejection marked by abundant interstitial cellular infiltrates. Electron microscopy is, in these cases, not an especially useful modality in making the differentiation of graft rejection from these other disorders.

It should also be emphasized in this regard that studies of renal function do not permit separation of renal failure due to rejection from other disease processes. Because of this, Rowlands along with Bossen, Johnston, and Amatulli have studied the urinary sediment as it appears on Millipore filters stained with Papanicolaou stains in patients with renal trans-

plants.<sup>83-85</sup> As will be emphasized later, this technique is especially valuable in detecting certain viral infections which are common to recipients of immunosuppressive drugs. However, these studies, when carried out in recipients of renal allografts, proved very useful in detecting graft rejection and in distinguishing graft rejection from other types of kidney disease. Specifically, specimens collected by a membrane filter technique and stained by a modified Papanicolaou technique were scanned at various times during the course of a transplant. It was found that the presence of five of the following abnormalities—nuclear changes, casts, red blood cells, a “dirty background,” mixed cell clusters, lymphocytes, or tubular cells—permitted a diagnosis of graft rejection to be suggested. In 8 of 10 patients studied prospectively, graft rejection could be suggested 1 to 12 days before it became evident clinically. In the other 2 patients, the diagnosis could only be made cytologically when the diagnosis was also obvious clinically. Treatment of the patients undergoing graft rejection led to a prompt return of their urinary sediments to normal.

### **Survival of Human Renal Allografts**

It is appropriate at this point to put our comments on acute and chronic graft rejection into perspective by looking at survival rates among various categories of renal allografts, comparing graft rejection of kidneys with rejection of other organs, and methods of avoidance of graft rejection. Specific figures vary from series to series because of different methods of preservation, differing surgical techniques, and differing immunosuppressive therapy regimens. However, certain generalities may be made.<sup>86,87</sup> Living-related transplants do substantially better than cadaver transplants. Overall 2-year survival rates are on the order of 75% for living-related subjects, in contrast to approximately 40 to 50% for cadaver kidneys. Among the living-related donors, siblings appear to be better than parents. Although increased age of the donor is not an absolute contraindication to transplantation, a recent study<sup>88</sup> has demonstrated that there is a clear-cut diminution of graft survival with increasing age of the donors. This difference is of the proper magnitude to explain the differences of graft survival when grafts from parents are compared with those of siblings. There is no appreciable difference between transplantation using living-unrelated donors and transplantation using cadaver donors.

Among cadaver transplants, the mode of preservation has an important influence on graft survival. Clark<sup>89</sup> has published comparisons between cadaver kidneys preserved by simple hypothermia after washout with an electrolyte solution (Collins or Sachs) versus continuous pulsatile per-

fusion on a Belzer machine with a proteinaceous solution, usually cryoprecipitated plasma, as perfusate. He found that grafts preserved by simple hypothermia do substantially better (58% 1-year survival) than those perfused on the Belzer machine (48% 1-year survival). Possible reasons for this difference are discussed under Perfusion-Related Renal Allograft Injury (vide supra).

Aside from technical considerations, such as the method of organ preservation and the skill of the surgeon, the fate of the transplanted organ depends on antigenic differences between the donor and recipient of the organ graft. Two major groups of antigens account for sensitization of the host and graft rejection: the blood group ABH antigens and the leukocyte and tissue antigens of the HLA system.

A complete match of the donor and recipient with regard to these two groups of antigens such as that found in monozygotic twins is required for assurance of total compatibility so that organ and tissue transplants can be successfully carried out without need for the use of immunosuppressive agents. Although matches with regard to the ABH system can be made relatively easily in donor recipient combinations, satisfactory matching with regard to transplantation antigens is more difficult to achieve because of the polymorphism of the HLA system. For this reason, most recipients of organ allografts require immunosuppressive agents to retain their grafts free of obvious signs of rejection.

The HLA antigens appear to constitute the major histocompatibility system in man, but even so, their role in graft rejection is not completely understood. For example, it is an established fact that the individual HLA antigens may vary in their immunogenicity when examined from the standpoint of specific antibody induction in multiparous women, but there is no evidence that these differences affect graft rejection. Nevertheless, there is growing evidence that certain hosts do not respond well to histocompatibility antigens and it is in these subjects that prolonged graft survivals can be seen. Opelz *et al.*<sup>87</sup> have shown that whether or not a patient develops significant antibodies to histocompatibility antigens pretransplant, as the result of transfusion or during maintenance on hemodialysis, has significant predictive power in forecasting graft survival. Those who readily develop antibodies (responders) are presensitized and reject kidneys more readily than patients who do not develop them. As a further extension of this notion, it was found that patients who did not develop cytotoxins after more than 1 year on hemodialysis (nonresponders) had an overall graft survival rate of 81%, compared to 51% of the cadaver graft group as a whole. The obvious explanation that these nonresponders do well because they do not make significant antibodies to

their grafts is attractive, but the total explanation for this phenomenon remains to be worked out.

### Complications of Transplantation

There are two major types of complications that may be seen in recipients of organ grafts. The first, and most obvious, variety of complication is that of infection seen in patients who have been subjected to immunosuppressive therapy.<sup>90-93</sup> This is, of course, a consequence of the fact that the immunosuppressive agents in common use are not selective and serve to significantly reduce a wide variety of host defense mechanisms. In addition to this purposefully induced immunosuppression, those patients in whom an allograft is carried out ordinarily have severe uremia which is in itself immunosuppressive.

Certainly recipients of allografts who are under the influence of immunosuppressive agents are fair game for any of the more common infectious agents. However, the infections which have attracted most interest in these patients are opportunistic infections by organisms which are ordinarily saprophytic or rarely invasive. These include the fungi and many viruses. In addition, tuberculosis may be encountered in certain of these patients.

The site of infection is variable with the lungs appearing to be a rather frequent seat of infection. In many cases the infection becomes widely disseminated (e.g., meningitis) and may even involve the graft itself. Because of the extensive immunosuppression in these patients, the white cell population is greatly reduced so that the site of infection usually shows far fewer inflammatory cells than would be ordinarily seen.

In addition to bacteria and fungi, the graft recipients are often heavily laden with organisms such as cytomegalovirus and *Pneumocystis carinii*. Diagnosis of these infections has often proved difficult without biopsy material. However, the technique of collection of urinary sediment on Millipore filters described earlier has been found to be an especially useful measure for identifying patients having systemic infections with cytomegalovirus (CMV).<sup>83-85</sup> The apparent superiority of this method over that of using cells recovered by centrifugation may have to do with the decreased cellular injury produced using the Millipore techniques.

There is a high degree of association between herpesvirus (particularly cytomegalovirus) infections and clinical rejection episodes. It had been recognized for some time that CMV is found in a very high proportion of transplant recipients and that CMV infections were sometimes associated with a pneumonitis-, hepatitis-, or infectious mononucleosis-like pictures. General opinion has held that CMV is an incidental finding in most



transplant patients. However, Simmons *et al.*<sup>94</sup> and other groups<sup>95</sup> have noted the close association between febrile, presumably viral, illnesses and rejection episodes. Lopez *et al.*<sup>95</sup> isolated and carefully documented the time course of infectious and rejection manifestations and the subsequent appearance of antiviral antibodies. They feel they have demonstrated a clear-cut relationship between virus infections and rejection episodes. They propose that either a) the virus infection acts as an adjuvant and triggers allograft rejection or b) the rejection activates a latent virus infection. They state that no definitive evidence is available to allow them to choose definitively between these possibilities.

One of the additional observations made in these patients who have been subjected to immunosuppression is the striking increase in the incidence of neoplasms.<sup>96-98</sup> The most notable increase has been in neoplasms of the lymphoreticular system. Although the percentage increase is less, epithelial neoplasms actually constitute the largest number of transplant-related neoplasms. Skin neoplasms are most common, but lung, gastric, pancreatic, and other carcinomas have been reported. The reasons for the increased incidence of neoplasms in immunosuppressed individuals is not entirely clear although it has generally been attributed to defective immune surveillance mechanisms in these patients.

It is apparent that replacement of a diseased organ by a normal one is not necessarily corrective of the basic disease process. Because of this, it seemed reasonable to suppose that the same disease might reappear in certain of the transplanted kidneys,<sup>48,61,64,76,99-106</sup> especially since so many disorders which afflict the kidney depend on circulating humoral substances. This expectation was amply confirmed in the early experience with renal isografts between identical twins unmodified by immunosuppressive therapy, in which 11 of 19 graft recipients developed recurrent glomerulonephritis. In addition, the following diseases have definitely been documented to recur in renal allografts, at least on occasion: anti-glomerular basement membrane glomerulonephritis, IgG-IgA nephropathy, basement membrane dense deposit disease, lobular glomerulonephritis, florid Henoch-Schoenlein purpura, membranous nephropathy, and focal segmental glomerulosclerosis. It must be pointed out that all of these diseases have one feature in common, namely, the presence of some distinctive morphologic feature, such as mesangial deposits of IgA or dense deposits in the glomerular basement membranes, which when coupled with examination of the original kidney allows identification of recurrent disease to be made with fair certainty. In a very large number of cases, however, the original disease is more ambiguous in its nature, with variable degrees of nonspecific mesangial and epithelial proliferation and

sclerosis, and no distinctive identifying feature. Thus, when proliferative glomerular lesions are found in the transplant, it is impossible to know whether to ascribe them to recurrent diseases or to the glomerulitis described above which so frequently is a part of chronic rejection. (A third possibility, of course, is that the glomerulonephritis has developed *de novo*; this has been documented in patients whose antecedent disease was pyelonephritis or polycystic disease. Its frequency is unknown.) Thus the true incidence of recurrent glomerulonephritis is very hard to determine. Dixon *et al.*<sup>102</sup> have claimed a very high incidence of recurrent glomerulonephritis on the basis of immunofluorescence data, in 77% of patients with anti-GBM disease and 23% of patients with immune complex glomerulonephritis. Most authors suggest that, although significant, the actual incidence is much lower.

### References

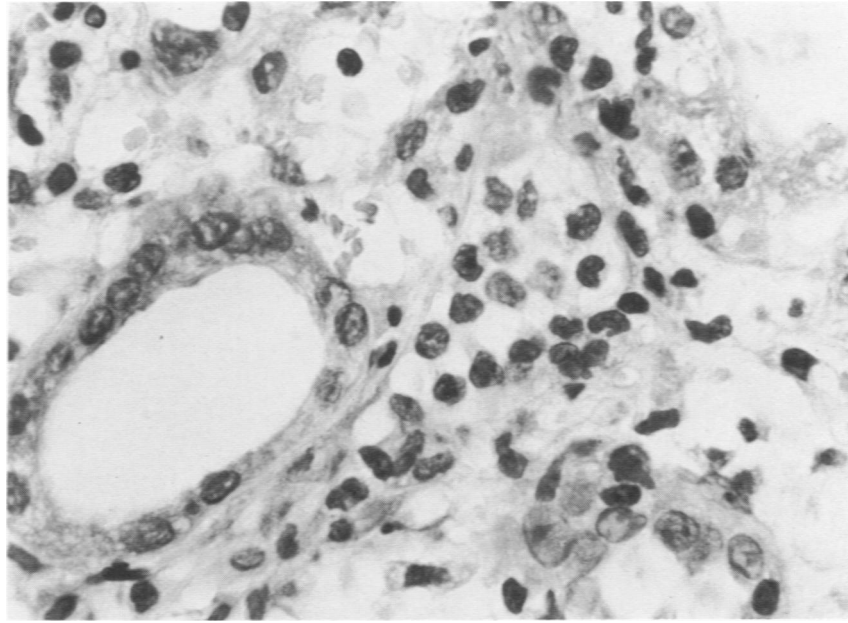
1. Gibson T, Medawar PB: The fate of skin homografts in man. *J Anat* 77:299-310, 1943
2. Medawar PB: The behavior and fate of skin allografts and skin homografts in rabbits. *J Anat* 78:176-199, 1944
3. Medawar PB: A second study of the behavior and fate of skin homografts in rabbits. *J Anat* 79:157-176, 1945
4. Medawar PB: Immunity to homologous grafted skin. I. The suppression of cell divisions in grafts transplanted to immunized animals. *Br J Exp Pathol* 27:9-14, 1945
5. Jensen CO: Experimentelle undersøgelser over krebs bei musen. *Centralbl Bacteriol Parasitol Infek* 34:28-34, 1903 (Abstr)
6. Gorer PA: The genetic and antigenetic basis of tumour transplantation. *J Pathol Bacteriol* 44:691-697, 1937
7. Gorer PA: The role of antibodies in immunity to transplanted leukaemia in mice. *J Pathol Bacteriol* 54:51-65, 1942
8. Stetson CA, Jensen E: Humoral aspects of the immune response to homografts. *Ann NY Acad Sci* 87:249-257, 1960
9. Batchelor JR: Antibody response of humans to allogeneic skin grafts: Histocompatibility testing, 1965. *Ser Haematol* 11:257-262, 1965
10. Amos B: Immunologic factors in organ transplantation. *Am J Med* 44:767-775, 1968
11. Dausset J: Iso-leuco-anticorps. *Acta Haematol* 20:156-166, 1958
12. Payne R, Rolfs MR: Fetomaternal leucocyte incompatibility. *J Clin Invest* 37:1756-1763, 1958
13. New Nomenclature for the HLA System. *J Immunol* 116:573-574, 1976
14. Histocompatibility testing international. *Nature* 256:696-698, 1975
15. Stulting DR, Ward FE: A computerized system for the selection of organ transplant recipients. *Transplantation* 19:27-35, 1975
16. Tanigaki N, Pressman D: The basic structure and the antigenic characteristics of HL-A antigens. *Transplant Rev* 21:15-34, 1974
17. Peterson PA, Cunningham BA, Berggard I, Edelman GM: B<sub>2</sub>-microglobulin a free immunoglobulin domain. *Proc Natl Acad Sci USA* 69:1697-1701, 1972
18. Dorf ME, Balner H, Benacerraf B: Mapping of the immune response genes in the

- major histocompatibility complex of the rhesus monkey. *J Exp Med* 142:673-693, 1975
19. Terasaki PI, Opelz G, Ting A: Tissue typing in kidney transplantation. *Immunological Aspects of Transplantation Surgery*. Edited by R Calne. New York, John Wiley & Sons, 1973, pp 92-111
  20. van Hooff JP, Schippers HMA, van der Steen GJ, van Rood JJ: Efficacy of HL-A matching in Eurotransplant. *Lancet* 2:1385-1388, 1972
  21. Advisory Committee to the Renal Transplant Registry: The 12th Report of the Human Renal Transplant Registry. *JAMA* 233:787-796, 1975
  22. Oliver RTD, Sachs JA, Festenstein H, Pergrum GD, Moorhead JF: Influence of HL-A matching, antigenic strength and immune responsiveness on outcome of 349 cadaver renal grafts. *Lancet* 2:1381-1384, 1972
  23. Opelz G, Mickey MR, Terasaki PI: Prolonged survival of second human kidney transplants. *Science* 178:617-619, 1972
  24. Cochrum K, Salvatierra O, Belzer FO: Correlation between MLC stimulation and graft survival in living related and cadaver transplants. *Ann Surg* 180:617-622, 1974
  25. Rowlands DT Jr, Bossen EH: Immunological mechanisms of allograft rejection. *Arch Intern Med* 123:491-500, 1969
  26. Russell PS, Monaco AP: *The Biology of Tissue Transplantation*. Boston, Little, Brown & Co., 1965
  27. Barker CF, Billingham RE: The role of regional lymphatics in the skin homograft response. *Transplantation (Lond)* 5 (Suppl): 962-966, 1967
  28. Medawar PB: The Croonian lecture: The homograft reaction. *Proc R Soc (Lond)* 149:145-166, 1958
  29. Medawar PB: Transplantation of tissues and organs: Introduction. *Br Med Bull* 21:97-99, 1965
  30. Perloff LJ, Bendan ML: Passenger cells: Their role in homograft rejection. *Curr Top Surg Res* 3:265-270, 1971
  31. Strober S, Gowans JL: The role of lymphocytes in the sensitization of rats to renal homografts. *J Exp Med* 122:347-360, 1965
  32. Elkins WL, Guttman RD: Pathogenesis of a local graft versus host reaction: Immunogenicity of circulating host leukocytes. *Science* 159:1250-1251, 1968
  33. Steinmuller D, Hart EA: Passenger leucocytes and induction of allograft immunity. *Transplant Proc* 3:673-675, 1971
  34. McGregor DD, Gowans JL: The antibody response of rats depleted of lymphocytes by chronic drainage from the thoracic duct. *J Exp Med* 117:303-320, 1963
  35. Billingham RE, Silvers WK, Wilson DB: Further studies on adoptive transfer of sensitivity to skin homografts. *J Exp Med* 118:397-420, 1963
  36. Rowlands DT Jr, Crowle AJ, Russe HP: Passively transferred delayed hypersensitivity reactions in mice and guinea pigs. *Int Arch Allergy* 28:328-335, 1965
  37. Elkins WL: Invasion and destruction of homologous kidney by locally inoculated lymphoid cells. *J Exp Med* 120:329-348, 1964
  38. McCluskey RT, Benacerraf B, McCluskey JW: Studies on the specificity of the cellular infiltrate in delayed hypersensitivity reactions. *J Immunol* 90:466-477, 1963
  39. Foker JE, Simmons RL, Najarian JS: Allograft rejection. Chapt 5. *Transplantation*. Edited by JS Najarian, RL Simmons. Philadelphia, Lea and Febiger, 1972, pp 72-73
  40. David JR: Macrophage activation by lymphocyte mediators. *Fed Proc* 34:1730-1736, 1975
  41. Lindquist RR, Guttman RD, Merrill JP, Dammin GJ: Human renal allografts: Interpretation of morphologic and immunohistochemical observations. *Am J Pathol* 53:851-881, 1968
  42. Kissmeyer-Nielsen F, Fjelborg O, Olsen S, Posborg Peterson V: Humoral anti-

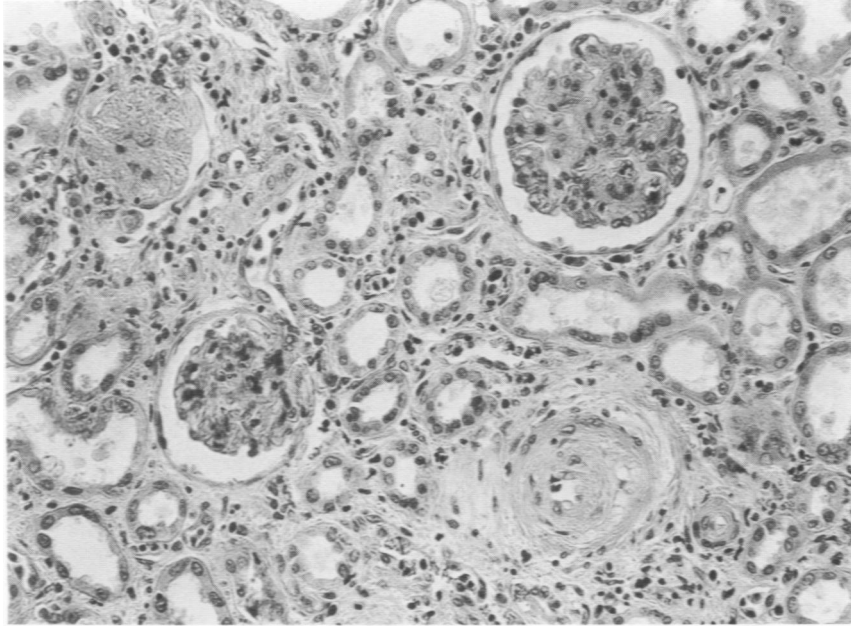
- bodies in human kidney allotransplantation. *Advances in Transplantation*. Edited by J Dausset, J Hamburger, G Mathe. Baltimore, Williams & Wilkins Co., 1967, p 415
43. Kissmeyer-Nielsen F, Olsen S, Posborg Peterson V, Fjeldborg O: Hyperacute rejection of kidney allografts, associated with preexisting humoral antibodies against donor cells. *Lancet* 2:662-665, 1966
  44. Milgrom F, Litvak BI, Kano K, Witebsky E: Humoral antibodies in renal homografts. *JAMA* 198:226-230, 1966
  45. Dempster WJ, Harrison CV, Shackman R: Rejection processes in human homotransplanted kidneys. *Br Med J* 2:969-976, 1964
  46. Horowitz RE, Burrows L, Paronetto F, Dreiling D, Kark AE: Immunologic observations on homografts. II. The canine kidney. *Transplantation* 3:318-325, 1965
  47. Porter KA: Morphological aspects of renal homograft rejection. *Br Med Bull* 21:171-175, 1965
  48. Porter KA, Rendall JM, Stolinski C, Terasaki PI, Marchioro TL, Starzl TE: Light and electron microscopic study of biopsies from thirty-three human renal allografts and an isograft 1½-2½ years after transplantation. *Ann NY Acad Sci* 129:615-636, 1966
  49. Porter KA: Renal transplantation. *Pathology of the Kidney*, Second edition, Vol 2. Edited by RH Heptinstall. Boston, Little, Brown & Co., 1974, pp 977-1041
  50. Busch GJ, Reynolds ES, Galvanek EG, Braun WE, Dammin GJ: Human renal allografts: The role of vascular injury in early graft failure. *Medicine* 50:29-83, 1971
  51. Cerilli J, Jesseph JE, Miller AC: The significance of antivascular endothelium antibody in renal transplantation. *Surg Gynecol Obstet* 135:246-252, 1972
  52. Rosenberg JC, Hawkins E, Rector F: Mechanisms of immunological injury during antibody-mediated hyperacute rejection of renal heterografts. *Transplantation* 11:151-157, 1971
  53. O'Connell TX, Mowbray JF: Effects of humoral transplantation antibody on the arterial intima of rabbits. *Surgery* 74:145-152, 1973
  54. Dossetor JB, Olsan LA: Evidence of latent sensitization to HL-A antigens. *Transplantation* 13:576-579, 1972
  55. Starzl TE, Lerner RA, Dixon FJ, Groth CG, Brettschneider L, Terasaki PI: Shwartzman reaction after human renal homotransplantation. *N Engl J Med* 278:642-648, 1968
  56. Stewart JH, Cook KM, Sharp AM, Johnston JM, Sheil AGR, Jeremy D, Baskir H: Tissue matching and early rejection of cadaveric-donor renal allografts: The importance of unidentified donor antigens. *Br Med J* 3:487-490, 1970
  57. Simmons RL, Thompson EJ, Kjellstrand CM, Yunis EJ, Candie RM, Mauer SM, Buselmeier TJ, Najarian JS: Parent-to-child and child-to-parent kidney transplants. *Lancet* 1:321-324, 1970
  58. Zmijewski C: Personal observation
  59. Bricker NS, Guild WR, Reardan JB, Merrill JP: Studies on the functional capacity of a denervated homotransplanted kidney in an identical twin with parallel observations in the donor. *J Clin Invest* 35:1364-1380, 1956
  60. Starzl TE, Brittain RS, Stonnington OG, Coppinger WR, Waddell WR: Renal transplantation in identical twins. *Arch Surg* 86:600-607, 1963
  61. Glasscock RJ, Feldman D, Reynolds ES, Dammin GJ, Merrill JP: Human renal isografts: A clinical and pathologic analysis. *Medicine* 47:411-454, 1968
  62. Williams MA, Morton M, Tyler HM: A biochemical approach to the study of rejection of canine renal homotransplants. II. Chemical analysis of kidney homogenates. *Br J Exp Pathol* 45:235-241, 1964
  63. Guttman RD, Lindquist RR, Parker RM, Carpenter CB, Merrill JP: Renal trans-

- plantation in the inbred rat. I. Morphologic, immunologic, and functional alterations during acute rejection. *Transplantation* 5:668-681, 1967
64. Rowlands DT, Jr, Burkholder PM: Pathology in allograft recipients. *Tissue Typing and Organ Transplantation*. Edited by EJ Yunis, RA Gaité, DB Amos. Academic Press, Inc., New York, 1973, pp 329-333
  65. Michon L, Hamburger J, Antoine B: Une tentative de transplantation rénale chez l'homme: Aspects médicaux et biologiques. *Presse Med* 61:1419-1423, 1953
  66. Hume DM, Merrill JP, Miller BF, Thorn GW: Experience with renal homotransplantation in the human: Report of nine cases. *J Clin Invest* 34:327-381, 1955
  67. Hinglais N, *et al.*: A study of arterial lesions in rejection. Unpublished data
  68. Corson JM: The pathologist and the kidney transplant. *Pathol Annu* 7:251-292, 1972
  69. Andre JA, Schwartz RS, Mitus WJ, Dameshek W: The morphologic responses of the lymphoid system to homografts. I. First and second set responses in normal rabbits. *Blood* 19:313-333, 1962
  70. Dempster WJ: Kidney homotransplantation. *Br J Surg* 40:447-465, 1953
  71. Starzl TE, Marchioro TL, Holmes JH, Waddell WR: The incidence, cause and significance of immediate and delayed oliguria or anuria after human renal transplantation. *Surg Gynecol Obstet* 118:819-827, 1964
  72. Starzl TE, Marchioro TL, Rifkind D, Holmes JH, Rowlands DT Jr, Waddell WR: Factors in successful renal transplantation. *Surgery* 56:296-318, 1964
  73. Williams GM, Hume DM, Hudson RP, Morris PJ, Kano K, Milgrom F: "Hyperacute" renal-homograft rejection in man. *N Engl J Med* 279:611-618, 1968
  74. Myburgh JA, Cohen I, Gecelter L, Meyers AM, Abrahams C, Furman KI, Goldberg B, van Blerk PJP: Hyperacute rejection in human-kidney allografts—Shwartzman or Arthus reaction? *N Engl J Med* 281:131-135, 1969
  75. Starzl TE, Beohmig HJ, Amemiya H, Wilson CB, Dixon FJ, Giles GR, Simpson KM, Halgrimson CG: Clotting changes, including disseminated intravascular coagulation during rapid renal-homograft rejection. *N Engl J Med* 283:383-390, 1970
  76. Rowlands DT Jr, Burkholder PM, Bossen EH, Lin HH: Renal allografts in HL-A matched recipients. Light, immunofluorescence, and electron microscopic studies. *Am J Pathol* 61:177-210, 1970
  77. Williams GM, de Planque B, Lower R, Hume D: Antibodies and human transplant rejection. *Ann Surg* 170:603-616, 1969
  78. Hill GS, Light JA, Perloff LJ: Pefusion-related injury in renal transplantation. *Surgery* 79:440-447, 1976
  79. Filo RS, Dickson LG, Suba EA, Sell KW: Immunologic injury induced by ex vivo perfusion of canine renal autografts. *Surgery* 76:88-100, 1974
  80. Light JA, Perloff LJ, Etheredge EE, Hill G, Spees EK: Adverse effects of meglumine diatrizoate on renal function in the early post-transplant period. *Transplantation* 20:404-409, 1975
  81. Light JA, Hill GS: I. Acute tubular necrosis in a renal transplant recipient complication from drip-infusion urography. *JAMA* 232:1267-1268, 1975
  82. Braun WE, Banowsky LH, Straffon RA, Nakamoto S, Kiser WS, Popowniak KL, Hewitt CB, Stewart BH, Zelch JV, Magalhaes RL, LaChance J-G, Manning RF: Lymphoceles associated with renal transplantation: Report of 15 cases and review of the literature. *Am J Med* 57:714-729, 1974
  83. Bossen EH, Johnston WW, Amatulli J, Rowlands DT, Jr: Exfoliate cytopathologic studies in organ transplantation. I. The cytologic diagnosis of cytomegalic inclusion disease in the urine of renal allograft recipients. *Am J Clin Pathol* 52:340-344, 1969
  84. Johnston WW, Bossen EH, Amatulli J, Rowlands DT Jr: Exfoliate cytopathologic

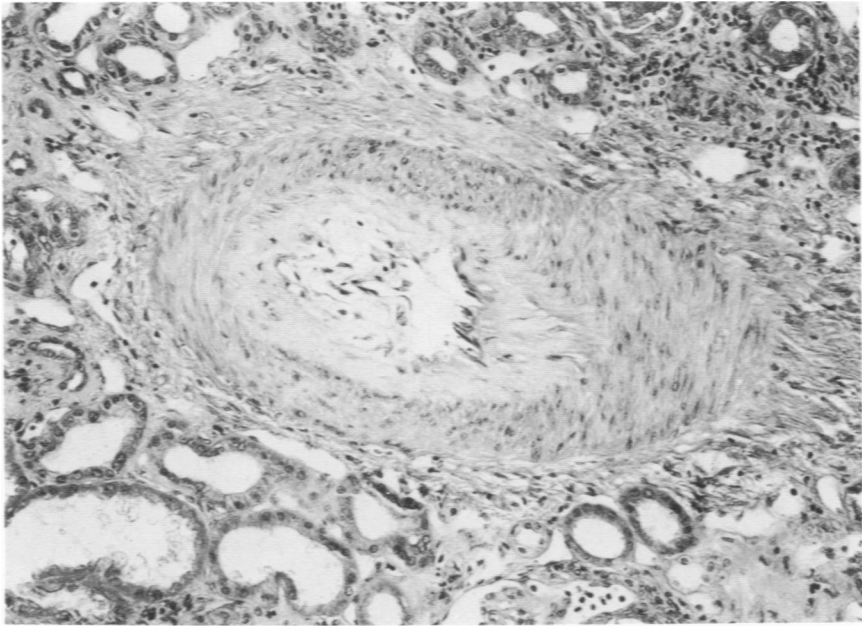
- studies in organ transplantation. II. Factors in the diagnosis of cytomegalic inclusion disease in urine of renal allograft recipients. *Acta Cytol* 13:605-610, 1969
85. Bossen EH, Johnston WW, Amatulli J, Rowlands DT Jr: Exfoliate cytopathologic studies in organ transplantation. III. The cytologic profile of urine during acute renal allograft rejection. *Acta Cytol* 14:176-181, 1970
  86. Advisory Committee to the Renal Transplant Registry: The 11th Report of the Human Renal Transplant Registry. *JAMA* 226:1197-1204, 1973
  87. Opelz G, Mickey MR, Terasaki PI: HL-A and kidney transplants: Reexamination. *Transplantation* 17:371-82, 1974
  88. Darmady EM: Transplantation and the ageing kidney. *Lancet* 2:1046-47, 1974
  89. Clark EA, Mickey MR, Opelz G, Terasaki PI: Evaluation of Belzer and Collins kidney-preservation methods. *Lancet* 1:361-363, 1973
  90. Hill RB Jr, Rowlands DT Jr, Rifkind D: Infectious pulmonary disease in patients receiving immunosuppressive therapy for organ transplantation. *N Engl J Med* 271:1021-1027, 1964
  91. Rifkind D, Starzl TE, Marchioro TL, Waddell WR, Rowlands DT Jr, Hill RB Jr: Transplantation pneumonia. *JAMA* 189:808-812, 1964
  92. Armstrong D, Balakrishnan SL, Steger L, Saidapet L, Bessie Yu, Stenzel H: Cytomegalovirus infections with viremia following renal transplantation. *Arch Intern Med* 127:111-115, 1971
  93. David DS, Millian SJ, Whitsell JC, Schwartz GH, Riggio RR, Stenzel KH, Rubin AL: Viral syndromes and renal homograft rejection. *Ann Surg* 175:257-259, 1972
  94. Simmons RJ, Weil R III, Tallent MB, Kjellstrand CM, Najarian JS: Do mild infections trigger the rejection of renal allografts? *Transplant Proc* 2:419-423, 1970
  95. Lopez C, Simmons RL, Mauer SM, Najarian JS, Good RA: Association of renal allograft rejection with virus infections. *Am J Med* 56:280-289, 1974
  96. Penn I, Starzl TE: A summary of the status of de novo cancer in transplant recipients. *Transplant Proc* 4:719-732, 1972
  97. Marshall V: Premalignant and malignant skin tumors in immunosuppressed patients. *Transplantation* 17:272-275, 1974
  98. McKhann CF: Immune suppression and the incidence of malignancy. *Tissue Typing and Organ Transplantation*. Edited by DB Amos, RA Gatti, EJ Yunis. New York, Academic Press, Inc., 1973, pp 281-282
  99. Hamburger J, Crosnier J, Dormont J: Observations in patients with a well tolerated hemotransplanted kidney: Possibility of a new secondary disease. *Ann NY Acad Sci* 120:558-577, 1964
  100. Porter KA, Dossetor JB, Marchioro TL, Peart WS, Rendall JM, Starzl TE, Terasaki PI: Human renal transplants. I. Glomerular changes. *Lab Invest* 16:153-181, 1967
  101. Porter KA, Andres GA, Calder MW, Dossetor JB, Hsu KC, Rendall JM, Seegall BC, Starzl TE: Human renal transplants. II. Immunofluorescent and immunoferritin studies. *Lab Invest* 18:159-171, 1968
  102. Dixon FJ, McPhaul JJ, Lerner R: Recurrence of glomerulonephritis in the transplanted kidney. *Arch Intern Med* 123:554-557, 1969
  103. Raij L, Hoyer JR, Michael AF: Steroid-resistant nephrotic syndrome: Recurrence after transplantation. *Ann Intern Med* 77:581-86, 1972
  104. Hamburger J, Berger J, Nighlais N, Descamps B: New insights into the pathogenesis of glomerulonephritis afforded by the study of renal allografts. *Clin Nephrol* 1:3-13, 1973
  105. Mathew TH, Mathews DC, Hobbs JB, Kincaid-Smith P: Glomerular lesions after renal transplantation. *Am J Med* 59:177-190, 1975
  106. Crosson JT, Wathen RL, Raij L, Andersen RC, Anderson WR: Recurrence of idiopathic membranous nephropathy in a renal allograft. *Arch Intern Med* 135:1101-1106, 1975



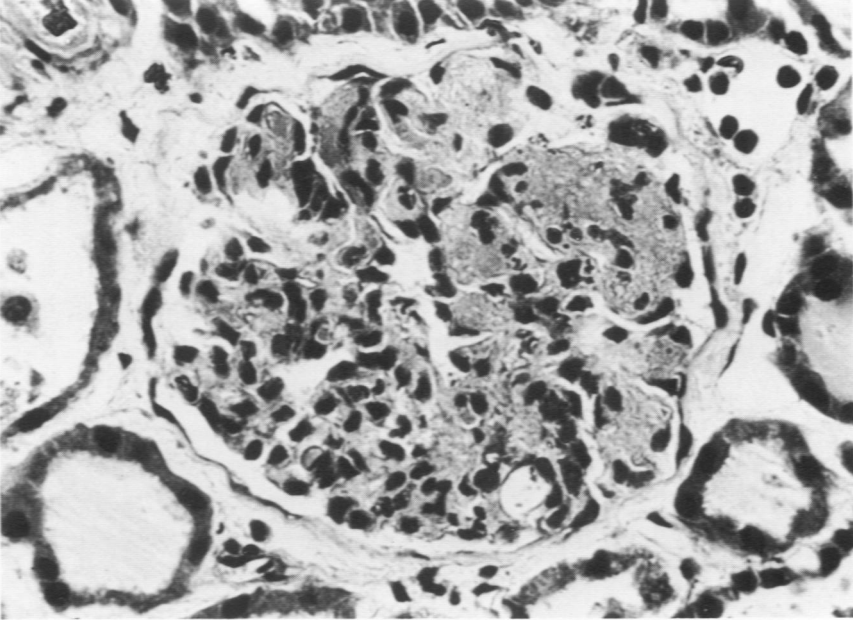
**Figure 1**—Photomicrograph of acute rejection showing a peritubular cellular infiltrate (H&E,  $\times 640$ ).



**Figure 2**—A histologic section showing arterial and arteriolar narrowing with foam cells in the media. There are numerous interstitial lymphocytes. (H&E,  $\times 150$ )



**Figure 3—A severely damaged artery showing a thickened fibrotic wall (H&E,  $\times 250$ ).**



**Figure 4—A glomerulus showing extensive fibrin thrombi and occasional polymorphonuclear leukocytes (H&E,  $\times 520$ ).**