

THE GLOMUS TUMOR *
INVESTIGATION OF ITS DISTRIBUTION AND BEHAVIOR, AND THE
IDENTITY OF ITS "EPITHELIOID" CELL

MARGARET R. MURRAY, Ph.D., and ARTHUR PURDY STOUT, M.D.

*(From the Surgical Pathology Laboratory of the College of Physicians and Surgeons,
Columbia University, and the Department of Surgery of the Presbyterian Hospital,
New York, N. Y.)*

The glomus tumor is reputed to be an enlarged caricature of the highly specialized glomic arteriovenous anastomoses which have been found only in certain parts of the hands and feet at the cutaneous-subcutaneous junction. Is it really true, as reported, that glomus tumors occur elsewhere in the body, and if so how can this be explained? Are glomus tumors always small encapsulated neoplasms or do they ever display infiltrative growth or metastasize? What is the nature of the "epithelioid" cells which are so characteristic of the glomus tumors? Certain observations have come to our attention which throw some light on these phases of glomus tumors. We propose to discuss them in the order given.

Distribution of Glomus Tumors

In 1935, Masson published a monograph entitled "Les glomus cutanés de l'Homme." In this he described the normal glomuses of the hands and feet and stated that his personal experience with glomus tumors included 27 cases: 14 in the fingers and hands, none in the feet and 13 in other parts of the upper and lower extremities. All of these involved cutaneous and subcutaneous tissues. He stated that their occurrence in places where normal glomuses have never been found might be explained in one of two ways: either glomuses exist in these areas but are so widely scattered that the chance of biopsies has never permitted their discovery, or else such glomus tumors come from heterotopic glomuses.

A survey of 240 cases reported in 89 different publications, including 33 personally observed cases, indicates that the distribution is much wider than this and that the tumors can arise in other zones beside the cutaneous-subcutaneous junction. Three tumors have been found in the face. Two of these were reported by Butz (1940) and one in the eyelid was studied in this laboratory and reported by Kirby (1941). Grauer and Burt (1939) found two on the penis; Gumpel (1939), one in the axilla; Roger and Alliez (1938), one on the lateral thorax in the region of the twelfth rib; Touraine, Solente and Renault (1936) and

* Received for publication, July 21, 1941.

Schulte and Isselstein (1935), several tumors scattered over the trunk; Lendrum and Mackey (1939) reported one on the buttocks (we also have observed one in this region), and Kirchberg (1936) reported one in the neck and another from the back. Fernández and Monserrat (1931) and Sannicandro (1936) reported finding them in the auricle but there is doubt whether these are true glomus tumors. Kolaczek (1875), Buzzi (1887), v. Hleb-Koszańska (1904) and Kofler (1936) have each reported a glomus tumor of Luschka's coccygeal glomus.

The evidence that glomus tumors can arise away from the cutaneous-subcutaneous junction and from Luschka's glomus is scanty but convincing. André-Thomas (1933) described a patient with two glomus tumors: one within the substance of the vastus internus muscle and the other in the region of the internal condyle of the femur adherent to the aponeurosis of the crureus muscle where it fuses with the vastus internus. These were accepted as glomus tumors by Oberling and Roussy and mentioned in 1935 by Masson. Hoffmann and Ghormley (1941) found a characteristic glomus tumor within the capsule of the knee joint. They were kind enough to permit us to examine a section and there can be no doubt about the diagnosis. The multiple tumors described by Bergstrand (1937) included one near the sheath of the peroneal tendon, another subfascial near the lateral malleolus, a third behind the malleolus in a hollow in the talus. Swenson's (1940) patient had a glomus tumor of the palmar surface of the left middle finger which lay deep to the fat pad almost on the periosteum. In Kulenkampff and Heilmann's (1940) case the glomus tumor thickened the wall of a vein which ran along the abductor pollicis longus and brevis muscles. We have studied a similar case in which the tumor surrounded a subcutaneous vein situated on the dorsal aspect of the base of the thumb. Iglesias de la Torre, Gomez-Camejo and Palacios (1939) have described a tumor of characteristic symptoms and morphology which lay buried within the terminal phalanx without any involvement of the tissues outside of it. The cases of Durante and Lemeland (1928) in the uterus and of Kirshbaum and Teitelman (1939) in the omentum are too questionable to be considered here.

The evidence just cited seems sufficient to warrant the belief that glomus tumors can develop not only in the junction of skin and subcutaneous tissue in regions of the body where no glomuses have ever been observed but they can develop also in deeper structures.

Infiltrative Growth, Recurrence and Metastasis

Almost all observers of glomus tumors have been impressed by the fact that they are simply enlarged, encapsulated caricatures of the normal glomus and that they are easily removed and do not recur.

Nevertheless, locally recurring tumors have been reported by Lewis and Geschickter (1935) in the forearm, by Meyers (1939) in the thigh and by Kirby (1941) in the eyelid, and we have studied three other recurrent cases beside that of Kirby—one in the knee region, a sub-ungual tumor of the finger and the third in the distal anterior closed space of a finger. It need not be supposed that these recurrent cases prove infiltrative growth, since they may be explained either as incomplete excisions or as the formation of new glomus tumors. It is now well established that individual patients may have multiple glomus tumors: Adair (1934), André-Thomas (1933), Bergstrand (1937), Davies, Hellier and Klaber (1939), Hval and Melsom (1936), Schulte and Isselstein (1935), Stout (1935), Touraine, Solente and Renault (1936), Weidman and Wise (1937).

So far as we are aware, there have been reports of only two tumors which have received the label of malignant glomus tumor. One was described by Kirshbaum and Teitelman (1939). It arose seemingly in the omentum, invaded the stomach and metastasized to the liver, and because it consisted of rounded cells collected into many layers about vascular endothelial-lined tubes, was called by the late R. H. Jaffé a malignant glomus tumor. The other case, a tumor of the pectoral region, was reported by Soiland (1937), and the reasons for calling it a glomus tumor do not appear in the text or illustrations. It seems to us that neither of these cases can be accorded unqualified acceptance as a glomus tumor.

Report of Case. Through the kindness of Dr. C. Zent Garber, pathologist of the New York Orthopaedic Hospital, we have had the privilege of studying a progressively infiltrating vascular tumor which we have good reason to believe is an authentic glomus tumor.

The patient was an Italian male. In December, 1927, at the age of 14, he began to have sharp pains below the right internal malleolus on weight-bearing, and also some tenderness. When examined a year later he had a slight foot drop, the foot was cool and damp and there was a vague soft tissue mass internal to the os calcis in the region of the calcaneo-astragaloid joint. The mass extended downward during the next 8 months and an abnormal pulsation was felt over it, with a rusty discoloration of the skin. A tumor measuring 5 by 2.5 cm., of indefinite outlines, was excised in August, 1929. It lay caudad to the posterior tibial vessels and nerves and did not appear grossly vascular. There was evidence of recurrence 2½ years later. The patient refused further treatment and was not seen until November 7, 1940, more than 11 years after the first operation, when he returned because of suddenly developed pain and tenderness in the tumor. Examination now showed extension of the tumor anterior to the malleolus onto the dorsum of the foot and also upward posterior to the ankle. There was marked atrophy of the leg and foot muscles, the foot was cold and blanched, it hung at 110° equinus and motion was possible only from 110° to 95°. A second attempt was made to excise the tumor on December 2, 1940. It extended widely in the tissues covering the medial and dorsal aspects of the tarsal bones, the medial malleolus and below it and behind the ankle joint. It was adherent to the posterior tibial nerve and artery and the

dorsalis pedis artery. As this operation obviously failed to remove all of the neoplastic tissue and the remaining tumor continued to grow, causing ulceration, an amputation was performed on February 5, 1941, through the upper third of the leg. The tumor now had extended 3 cm. above the insertion of the Achilles tendon which was surrounded by it.

Microscopically this tumor proved to be a vascular neoplasm of an infiltrative type. At its advancing margin the vessels which sometimes contained erythrocytes were simple tubes of endothelium often surrounded by collagen sheaths (Fig. 1A). Very quickly, however, rounded cells appeared in the vessel wall attached to the outer aspect of the tube. These surrounded the vessel in layers, as a rule from one to five cells thick (Figs. 1A and 1B). The cells in every way resembled the epithelioid cells of the glomus tumor. They were rounded with a centrally placed hyperchromatic nucleus, often a clear zone about the nucleus, and many of the cells were separated from their neighbors by delicate reticulin fibers. Occasionally the tumor cells with their nuclei were elongated and sausage-shaped, but this was uncommon. The sheathed vessels appeared scattered throughout the invaded tissues, which usually were not destroyed by them. At infrequent intervals tumor nodules were formed consisting of a tightly packed mass of sheathed vessels so arranged that the epithelioid cells of one vessel were in continuity with those of its neighbors and the nodule appeared like a solid mass of epithelioid cells with endothelial tubes scattered through it (Fig. 1C). The tumor vessels hardly ever formed straight tubes but twisted and turned sharply so that they were usually seen in cross and tangential sections. The tumor vessels were in continuity with arteries and veins but in none of the sections examined could any smooth muscle be demonstrated in the walls of tumor vessels nor could myofibrils be found in the epithelioid cells. None of the tissue was fixed in chloral hydrate so that no satisfactory neurite stains were obtained and we can furnish no information about this feature.

On histological grounds alone there is good reason for believing that this is an infiltrating glomus tumor. But further evidence in favor of this interpretation has been obtained from the study of tissue cultures made from this tumor and their comparison with cultures previously obtained from two ordinary glomus tumors. The study of these cultures has revealed some interesting facts about the "epithelioid" cells which we believe throw some light on their nature.

CHARACTERISTICS OF THE GLOMUS TUMOR IN VITRO

Infiltrated Area

Cultures made from the external, infiltrative zone of this tumor, which is composed almost entirely of meandering capillaries, produce an outgrowth of fibroblast-like cells. Often these form a membranous

sheet which, when treated with silver nitrate, shows sharply stained cement borders around cells in mosaic arrangement. The nuclei of these cells are greatly flattened, as is frequently the case with endothelium, rather poor in chromatin, and surrounded by a few perinuclear granules and a wide and greatly attenuated ectoplasmic zone (Fig. 10). Such a membrane usually grows over the surface of the clot, and often covers a stratum of spindle-shaped or fan-shaped fibroblasts which push their way through the clot and do not take the silver nitrate stain.

Tumor Nodules

When a tumor nodule composed mainly of epithelioid cells of the glomus type is cultivated *in vitro*, the so-called epithelioid cells show themselves to be far from epithelioid. Their habit is discrete, their cell-body is not voluminous, and they have many ramose processes. The progress and cellular constituents of such a culture handled by the Maximow method, are as follows:

1. During the first 24 hours macrophages and small lymphocytes make their appearance, as in cultures from the infiltrative zone. Some mast cells are present in the explant.

2. Within 48 hours there is to be seen at the edge of the explant a corona of fine hairlike pseudopodia leading out small cells with bulging nuclei. The compact nodule is observed to dissolve gradually into these small, branched, discrete cells which within a week have formed a reticular zone extending some distance out beyond the main body of the explant (Fig. 3). The reticular appearance of this zone is produced by the relatively uniform distance between the cell bodies, and by the frequent overlapping of their filamentous but branched processes. These processes do not actually unite, but are extended through the clot at different levels, so that no syncytial structure is formed. Because of these extensions in three dimensions, photography is rendered difficult. The cells under discussion bear no relationship to macrophages or monocytes, from which they can readily be distinguished by their morphology and staining reactions (Figs. 3 and 6). They are entirely unaffected by neutral red and lithium carmine, which are taken up readily by the macrophage and the monocyte. Because of their position with respect to the blood vessels of the tumor, and for other reasons which will be set forth later on, the cells emigrating from these "epithelioid" nodules will henceforth be referred to as "pericytes."

3. Mingled with the pericytes are a few fibroblast-like cells, and at the periphery of the pericyte zone are varying numbers of broad, flattened fibrocytes with numerous fine processes. Their origin is obscure; possibly they may stem from the macrophages, or possibly from the stroma of the tumor (Fig. 5-F).

4. In 10 or 12 days, capillary buds begin to push through from the explant into the zone of migrating pericytes. They advance at first as solid spikes, but later show themselves to be hollow tubes behind the foremost cells, with lumina sometimes containing blood cells (Figs. 2 and 5).

5. From the 12th day, when they appeared, to the 30th day (when cultivation was terminated), the capillary buds progressively became encrusted with pericytes. These begin to attach themselves to the capillaries as soon as the latter appear, and at some points pile up two deep. They are readily distinguishable from the endothelial cells by their smaller size and branching shape, and especially by their globular nucleus with its one or two nucleoli and richer chromatin network, as compared to the oval, paler nucleus of the endothelial cell with its larger complement of nucleoli (Figs. 2 and 5). The pericytes are indifferent to macrophages and to cotton fibers or other fortuitous inclusions in the medium, and probably also to fibroblasts in their flattened or fan-shaped form. The behavior of these cells *in vitro*, as well as their position encircling blood vessels in the sections, indicate that they are of the nature of vascular satellites. The ramose processes which characterize the pericytes are sometimes exceedingly delicate, so that they are hardly made visible by ordinary stains. But if an intensive staining method, such as silver impregnation, is used, much is brought to light that may not otherwise be seen. Compare Figure 7 made after prolonged treatment by the Bodian method for axis cylinders, with Figure 6 from a preparation stained with Mallory's phosphotungstic acid and hematoxylin. The fields are comparable and the magnifications equal. Nuclear inclusions in the form of clear, non-staining vacuoles are common among these cells, in both sections and cultures.

In addition to the infiltrative glomus tumor described above, we have cultivated two benign glomus tumors. In the latter there was not as great an amount of migration from the epithelioid areas as in the former, and the cultures did not produce encrusted capillaries. But in both, the characteristic cell composing the epithelioid trabeculae was shown to be the pericyte, discrete and branching (Fig. 8). We were not using silver impregnation methods on this tissue at the time of cultivating these benign glomus tumors, and so did not demonstrate any of the fine ramifications.

Masson, discussing the epithelioid areas in his descriptions of the normal and pathological glomus, stated that these cells form a syncytial network, interspersed by a framework of reticulin and elastin, and that they contain varying numbers of myofibrils, which sometimes extend from one cell to its neighbor, by way of their protoplasmic anastomoses.

Myofibrils are entirely absent from some of the glomus cells. According to Bailey (1935), there are no myofibrils in the glomus cells and only occasionally are groups of two or three nuclei seen without demonstrable cell boundaries.

In our cultures no reticulin was formed around the pericytes, though this was present in the sections. No myofibrils were observed in either sections or cultures of these tumors. In the cultures a few binucleate cells were seen, but, as has been stated previously, the cells were otherwise discrete and tended to range themselves at a distance from one another wherever there was room, except when in contact with a capillary, or with another pericyte upon a capillary. There seems to be a possibility that the processes of one cell passing over or wrapping around those of its neighbor in a compressed tumor nodule might produce the appearance of a syncytium such as Masson described.

DISCUSSION

Identification of the "Epithelioid" Cell of the Glomus Tumor as the Capillary Pericyte of Zimmermann

Students of the *normal* glomus agree that the characteristic cells enveloping this short-circuiting vessel between artery and vein pass through a regular series of transitional forms, from the typical spindle-shaped smooth muscle cell of the artery to the epithelioid cell, and on across the bridge to the smooth muscle cell of the vein. In the epithelioid cells, myofibrils are reputed to be sparse or absent, though they are numerous in the coverings of artery and vein. Nevertheless, because of the function which these cells perform in occluding the glomus vessel, as well as because of the gradations observed, they are generally regarded as modified smooth muscle cells.

The characteristic cell of the glomus *tumor* appears to be the epithelioid cell at the peak of its divergence from the smooth muscle of vessel walls. Though Masson has repeatedly reported the presence of myofibrils in the pathological glomus, the majority of other observers have not. Nevertheless a contractile function seems to be indicated for these cells in the pathological as well as in the normal glomus.

The spatial and morphological transition in the glomus, from smooth muscle to epithelioid cell and back again, finds a significant parallel in the investiture of capillaries in various organs, as described by Zimmermann in 1923. This comprehensive paper (*Der feinere Bau der Blutcapillaren*), dealing with all the classes of vertebrates as well as with man, sets forth the thesis that "in vertebrates in general the blood capillaries are wrapped around by a special kind of cell which in both directions—towards the arteries and towards the veins—passes over

gradually, through transitional forms, into smooth muscle fibers." To this cell, together with its transitional forms, he gives the name of "pericyte." Though they do not contain myofibrils, he regards them as contractile cells, which exercise a mild regulatory function upon the blood flow through the capillaries of various organs. In man, pericytes have been demonstrated in the kidney, the liver, the heart (where they are especially numerous), the lung, the gut, the tongue and the pia mater. They were not found in the spleen. Zimmermann did not investigate the skin or the extremities.

The pericytes of Zimmermann have a compact, usually rounded nucleus surrounded by a variable amount of cytoplasm from which extend exceedingly long, branching runners which embrace the capillary and sometimes extend from one capillary to another (Fig. 5B). These processes are so thin that they can be demonstrated only by some intensive and selective staining method; for this purpose Zimmermann employed variants of the Kopsch modification of Golgi's silver impregnation technic for nerve cells. The branching processes of the pericyte grasp the capillary wall tightly and adhere so closely that no solution can be forced between. According to Zimmermann, only the secondary branches contract and not the main runner which extends lengthwise along the vessel.

These pericytes are analogous in position to the epithelioid cells of the glomus, and in function also, if Zimmermann's conclusions are correct. The apparent difference in form between pericyte and glomus epithelioid cell obscured this relationship until cultivation *in vitro* brought to light the true form of the epithelioid cell. When our cultures were treated by a modification of Bodian's silver method and compared with Zimmermann's figures of pericytes treated by the Golgi method, there emerged a strong presumption that the two kinds of cell were identical (Figs. 7 and 4). Zimmermann's investigations of pericytes extended over some 40 years and were recorded in hundreds of figures. When these are compared with the epithelioid cells which our tissue cultures make available for study, there appears little doubt that we are dealing with the same type of cell, displaying its very delicate ramifications where the population is sparse, as on the capillaries, and *in vitro*, but having them obscured where there is crowding, as in the normal and pathological glomus nodules.

Our material throws no light on the function of the epithelioid cell or pericyte. These cells were never observed to contract spontaneously *in vitro*, as we have seen striated muscle and occasionally smooth muscle contract. They were not stimulated mechanically or electrically. In the early stages of their emigration from the tumor nodules they

were often unipolar or bipolar and spindle-shaped (Fig. 9), becoming ramose later. It is impossible to say whether their processes, once extended, contracted or were withdrawn over a long period of time; but there was no sudden change in form. There was no evidence of secretion, or of their functioning as *Quellzellen* (Schumacher, 1939). It should be borne in mind, however, that we have been dealing entirely with neoplastic cells, not with normal cells, and that they had no nervous connections.

The question naturally arises whether the pericyte is identical with the adventitial cell of mammalian capillaries, whose function and relationships have been the subject of much recent investigation. Zimmermann stated emphatically that the pericytes have nothing to do with the adventitial cells of the veins and arteries, which are fixed stellate connective tissue cells. They are distinct from the Kupffer cells of the bile capillaries. But since Zimmermann did not investigate the skin of the extremities, it is not possible to compare his data directly with the observations of Clark and Clark (1940) upon the blood vessels of the rabbit's ear.

From their observation of the living "extra-endothelial cells" of blood vessels by means of a transparent chamber in the ear, Clark and Clark concluded that the adventitial cells of the capillaries in this location develop from connective tissue cells in the vicinity. The longitudinally arranged adventitial cells on capillaries and small venules show no evidence of contractility. But as a capillary is transformed into an arteriole, these cells multiply and re-orient themselves transversely, becoming smooth muscle cells and contracting if they are reached by a regenerating vasomotor nerve.

In spite of the relationship of these adventitial cells to smooth muscle, there is little in Clark and Clark's figures or description to indicate that they were dealing with pericytes. In their living, unstained material they should have been able to see numerous branched processes as we see them on the pericytes in living cultures, if such processes were present on the adventitial cells. Indeed, while maintaining the general thesis that the adventitial cells of both amphibian and mammalian capillaries are inert and that the blood flow at the periphery is regulated by the smooth muscle cells of the larger vessels, Clark and Clark agreed that their evidence should not be applied to other forms and to other regions. In this connection they cited the work of Rouget (1873), Vimtrup (1922, 1923), and others on the nictitating and hyaloid membranes of amphibians, in which it appears that certain pronged adventitial cells (the Rouget cells) do exercise a contractile function and represent a primitive form of smooth muscle cell.

Two studies of normal blood vessels in tissue culture have come to our attention which suggest that the writers might have been dealing with pericytes; though this is not altogether clear, since they did not employ silver-impregnation methods. Herzog and Schopper (1931), cultivating the pia mater of guinea pigs, provided several suggestive figures; and Scriba (1935), in a study of circulatory growth in the 9-day chicken embryo, stated that adventitial cells appear in two forms: sometimes as large mesenchyme cells of fibroblastic type, and sometimes in a form resembling macrophages. A further study of such vascular satellites might prove profitable.

It seems likely that in the epithelioid cell of the glomus and in the pericyte which Zimmermann has demonstrated upon the capillaries of certain organs (and Schumacher has described on certain thyroid vessels and elsewhere), we are dealing with a type of cell which, though related to the common adventitial cell as investigated by Clark and Clark and others, is, in its differentiated form, distinct. It may possess contractility to a greater or lesser degree; but its form alone entitles it to separate consideration.

The identification of the so-called epithelioid cell of the glomus tumor as a pericyte has led us to review some of the other vascular tumors with cells arranged peripherally about the vessel wall, which are at our disposal. There are a number which on morphological grounds cannot be classified as glomus tumors and which on the other hand do not correspond with any of the accepted classes of vascular tumors. We believe that their cells may be classified either as pericytes or as adventitial cells and we propose to discuss these tumors in a future communication.

SUMMARY

Evidence has been adduced which provides information in answer to the three queries propounded at the beginning of this paper. Glomus tumors can form not only in the cutaneous-subcutaneous zone of those parts of the body where no normal glomuses have been identified but also in deeper tissues such as joint capsule and striated muscle. A glomus tumor which displayed progressive infiltrative growth has been described indicating that not all of these tumors are localized and encapsulated. However, we do not believe that sufficient evidence exists to establish the fact of metastasis. The "epithelioid" cell of the glomus tumor has been identified as the pericyte of Zimmermann. Since this cell has been demonstrated in many parts of the body, this identification offers a satisfactory explanation for the occurrence of glomus

tumors in those regions of the body where normal glomuses have never been found.

NOTE: We wish to acknowledge our indebtedness to Miss Irene Bokoff for her technical assistance in the preparation of the tissue cultures.

BIBLIOGRAPHY

- Adair, F. E. Glomus tumor. A clinical study with a report of 10 cases. *Am. J. Surg.*, 1934, **25**, 1-6.
- André-Thomas. Tumeurs comparables à des tumeurs glomiques développées dans les muscles de la cuisse à la suite d'un traumatisme. *Ann. d'anat. path.*, 1933, **10**, 657-668.
- Bailey, O. T. The cutaneous glomus and its tumors—glomangiomas. *Am. J. Path.*, 1935, **11**, 915-935.
- Bergstrand, Hilding. Multiple glomic tumors. *Am. J. Cancer*, 1937, **29**, 470-476. (Also *Nord. med. tidskr.*, 1937, **13**, 361-364.)
- Butz, A. Über Erscheinungsformen des Glomustumors. *Der Chirurg*, 1940, **12**, 97-104.
- Buzzi, Fausto. Beitrag zur Kenntniss der angeborenen Geschwülste des Sacrococcygealgegend. *Virchows Arch. f. path. Anat.*, 1887, **109**, 9-20.
- Clark, E. R., and Clark, E. L. Microscopic observations on the extra-endothelial cells of living mammalian blood vessels. *Am. J. Anat.*, 1940, **66**, 1-49.
- Davies, J. H. T.; Hellier, F. F., and Klaber, Robert. The glomus tumour: doubts and difficulties in diagnosis. *Brit. J. Dermat.*, 1939, **51**, 312-318.
- Durante, G., and Lemeland. Neuromyome artériel de l'utérus. *Ann. d'anat. path.*, 1928, **5**, 489-512.
- Fernández, A. A., and Monserrat, J. L. E. Nódulos doloros de la oreja (tumor glómico; neuro-mio-angioma). *Semana méd.*, 1931, **38**, 1693-1700.
- Grauer, R. C., and Burt, J. C. Unusual location of glomus tumor. Report of two cases. *J. A. M. A.*, 1939, **112**, 1806-1810.
- Gumpel, F. Über zwei Fälle von Glomustumoren. *Zentralbl. f. Chir.*, 1939, **66**, 2467-2470.
- Herzog, Georg, and Schopper, Werner. Über das Verhalten der Blutgefäße in der Kultur. *Arch. f. exper. Zellforsch.*, 1931, **11**, 202-218.
- Hoffmann, H. O. E., and Ghormley, R. K. Glomus tumor and intramuscular lipoma: report of two cases. *Proc. Staff Meet., Mayo Clin.*, 1941, **16**, 13-16.
- Hval, E., and Melsom, R. Multiple glomus tumors. *Med. rev., Bergen*, 1936, **53**, 545-558.
- Iglesias de la Torre, L; Gomez-Camejo, M., and Palacios, G. Consideraciones clínicas, anatómicas, radiológicas y quirúrgicas des glomus tumoral de Masson. *Cir. ortop. y traumatol., Habana*, 1939, **7**, 11-17.
- Kirby, D. B. Neuromyoarterial glomus tumor in the eyelid. *Arch. Opth.*, 1941, **25**, 228-237.
- Kirchberg, J. Beitrag zur Kenntnis der Geschwülste des Glomus neuromyoarterialis. Beschreibung von 6 Fällen. *Zentralbl. f. allg. Path. u. path. Anat.*, 1936, **65**, 228.
- Kirshbaum, J. D., and Teitelman, S. L. Malignant tumor of the greater omentum simulating a glomangioma. *Arch. Path.*, 1939, **27**, 95-103.
- Kofler, W. "Neuromyoarterieller Glomustumor" (Masson) des Nagelbettes und der "Steissdrüse." *Frankfurt. Ztschr. f. Path.*, 1936, **49**, 236-246.
- Kolaczek. Ein Myxo-Sarcoma perivasculara der Steissbeingegend. *Arch. f. klin. Chir.*, 1875, **18**, 342-344.
- Kulenkampff, D., and Heilmann, P. Über einen Glomustumor. *Zentralbl. f. Chir.*, 1940, **67**, 515-521.

- Lendrum, A. C., and Mackey, W. A. Glomangioma. A form of "painful subcutaneous tubercle." *Brit. M. J.*, 1939, **2**, 676-681.
- Lewis, Dean, and Geschickter, C. F. Glomus tumors (arterial angioneuromyoma of Masson). *J. A. M. A.*, 1935, **105**, 775-778.
- Masson, P. Les glomus cutanés de l'Homme. *Bull. Soc. franç. de dermat. et syph.*, 1935, **42**, 1174-1245.
- Meyers, M. P. Glomus tumor. A report of four cases. *J. Michigan M. Soc.*, 1939, **38**, 204-208.
- Roger, Henri, and Alliez, Joseph. Les petites tumeurs sous-cutanées bénignes à type d'hyperalgie hyperdiffusante (tumeurs glomiques de Masson). *Monde méd., Paris*, 1938, **48**, 71-75.
- Rouget, C. Mémoire sur le développement, la structure et les propriétés physiologiques des capillaires sanguins et lymphatiques. *Arch. de physiol., norm. et path.*, 1873, **5**, 603-663.
- Sannicandro, G. Tumore glomico dell'orecchio con particolari aspetti istologici. *Dermosifilografio*, 1936, **11**, 424-431.
- Schulte, G., and Isselstein, Th. Günstige Wirkung der Allgemeinbehandlung mit Grenzstrahlen bei heftigsten Schmerzen infolge von Gefäß-Nerventumoren. *Strahlentherapie*, 1935, **52**, 646-651.
- Schumacher, Siegmund. Grundriss der Histologie des Menschen. J. Springer, Wien, 1939, ed. 2, p. 63.
- Scriba, Karl. Explantationsstudien über das Gefäßwachstum bei 9 Tage alten Hühnerembryonen. *Arch. f. exper. Zellforsch.*, 1935, **17**, 68-77.
- Soiland, Albert. Sarcoma of the skin, malignant glomic tumors. A case report. *U. S. Nav. M. Bull.*, 1937, **35**, 85-86.
- Stout, A. P. Tumors of the neuromyo-arterial glomus. *Am. J. Cancer*, 1935, **24**, 255-272.
- Swenson, R. E. Glomus tumor. Report of a case. *New England J. Med.*, 1940, **223**, 1057-1058.
- Touraine, A.; Solente, and Renault, P. Tumeurs glomiques multiples du tronc et des membres. *Bull. Soc. franç. de dermat. et syph.*, 1936, **43**, 736-740.
- v. Hleb-Koszańska, Marie. Peritheliom der Luschka'schen Steissdrüse im Kindesalter. *Beitr. z. path. Anat. u. z. allg. Path.*, 1904, **35**, 589-626.
- Vimtrup, Bj. Beiträge zur Anatomie der Capillaren. I. Über contractile Elemente in der Gefäßwand der Blutcapillaren. *Ztschr. f. Anat. u. Entwicklungsgesch.*, 1922, **65**, 150-182. II. Weitere Untersuchungen über contractile Elemente in der Gefäßwand der Blutcapillaren. *Ibid.*, 1923, **68**, 469-482.
- Weidman, F. D., and Wise, F. Multiple glomus tumors of the order of telangiectases. *Arch. Dermat. & Syph.*, 1937, **35**, 414-426.
- Zimmermann, K. W. Der feinere Bau der Blutcapillaren. *Ztschr. f. Anat. u. Entwicklungsgesch.*, 1923, **68**, 29-109.

DESCRIPTION OF PLATES

PLATE 26

- FIG. 1. Photomicrographs of infiltrating glomus tumor.
- A. The peripheral zone with sprouted capillaries. Some capillaries are simple endothelial-lined tubes with a collagenous sheath; others have "epithelioid" cells (pericytes) adherent to the sheath.
 - B. Endothelial-lined tumor vessels surrounded by several layers of "epithelioid" cells (pericytes) with sharp cell margins and clear zones around their nuclei. There are reticulin fibers between the pericytes.
 - C. A circumscribed tumor nodule of collapsed endothelial tubes surrounded by massed "epithelioid" cells (pericytes). One of them shows a nuclear vacuole.

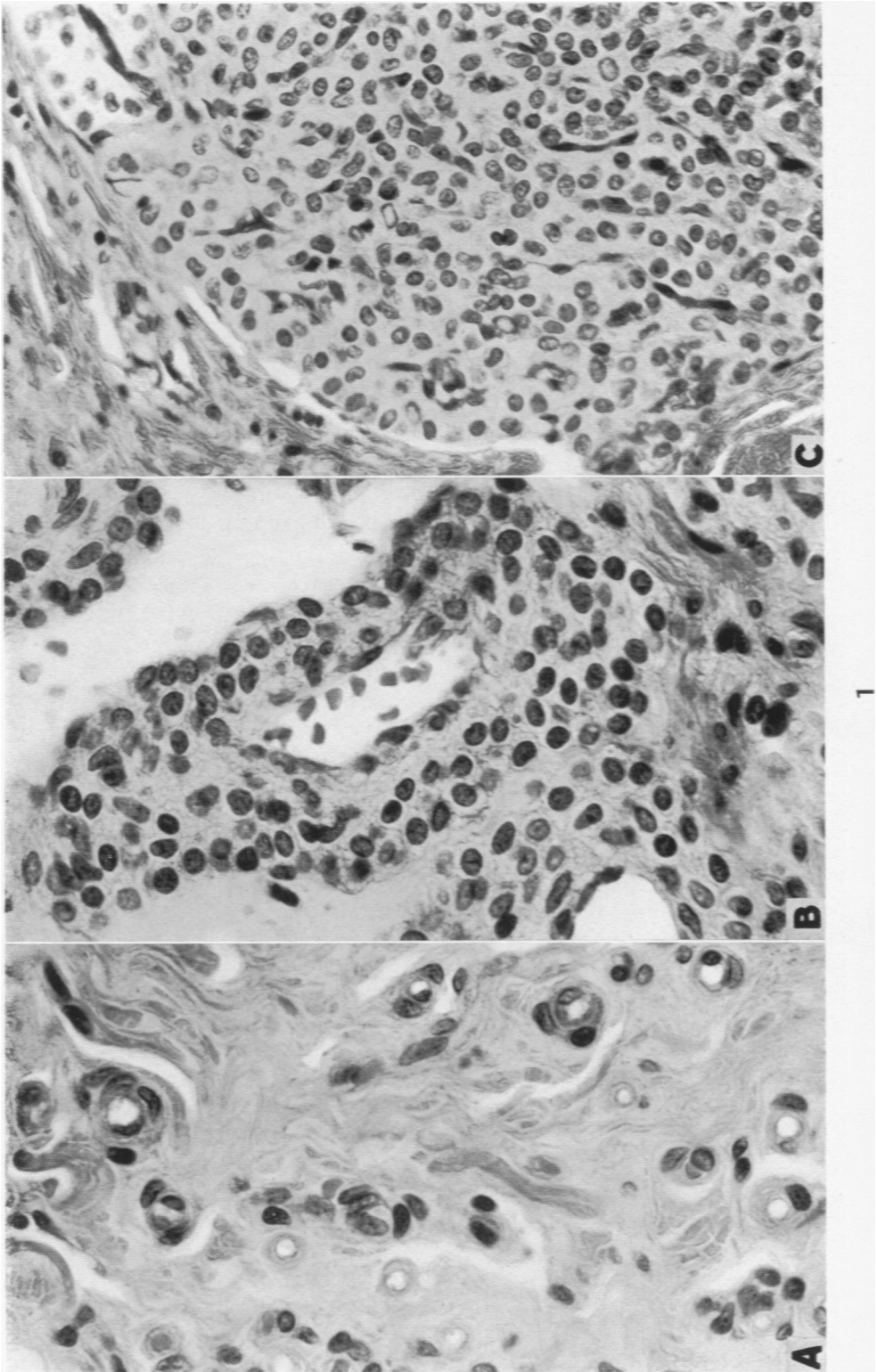
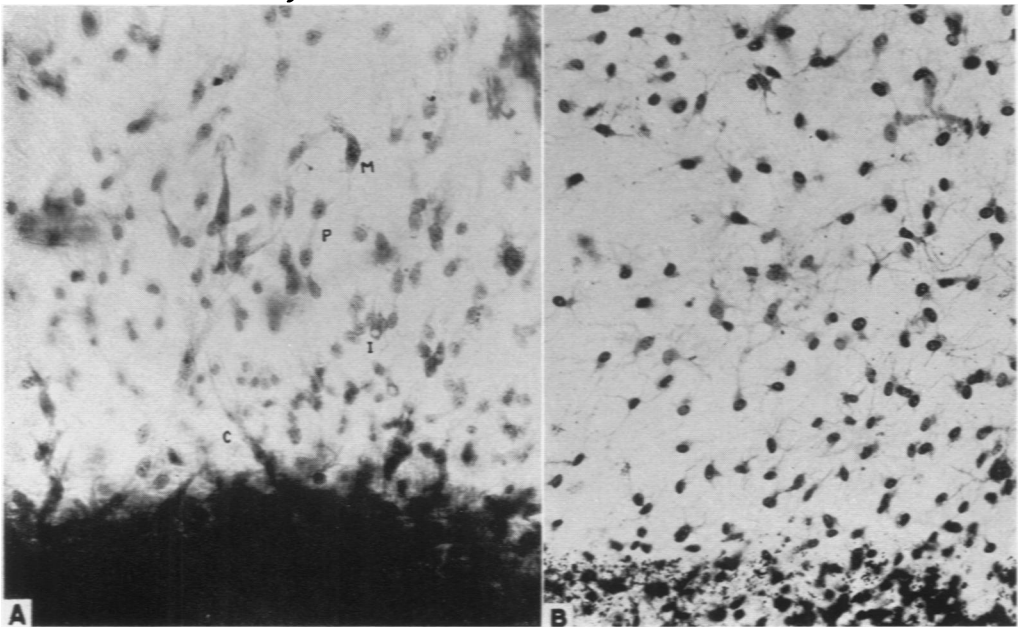
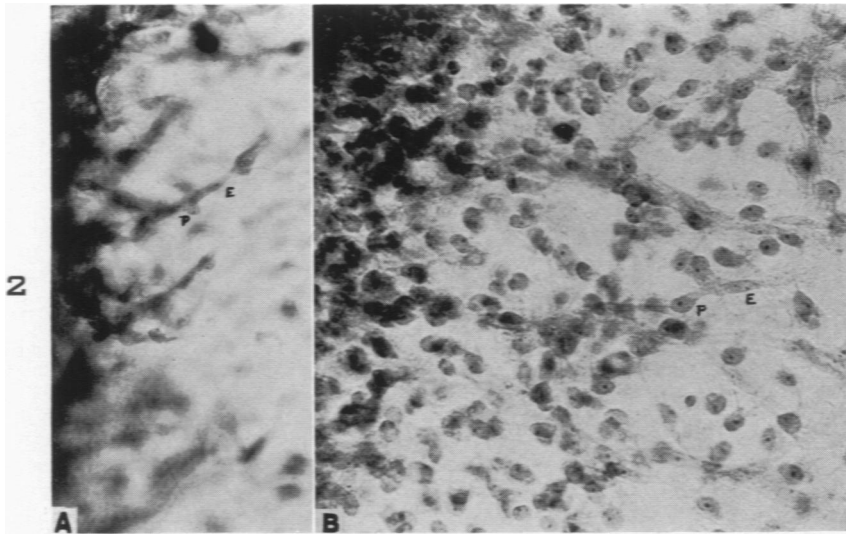


PLATE 27

- FIG. 2. A. Tissue culture from "epithelioid" nodule. Twenty days *in vitro*; Zenker's fixation, phosphotungstic acid hematoxylin stain.
- B. Similar material. Twenty-eight days *in vitro*. Kopsch fixative, phosphotungstic acid hematoxylin stain. E, endothelial nucleus; P, pericyte nucleus.
- FIG. 3. A. Tissue culture from tumor nodule composed mainly of "epithelioid" cells. Ten days *in vitro*; Zenker's fixation, phosphotungstic acid hematoxylin stain. C, capillary bud; I, nuclear inclusion body; M, macrophage; P, pericyte or "epithelioid" cell.
- B. Similar material. 24 days *in vitro*, 4 per cent formaldehyde solution, Bodian silver impregnation.



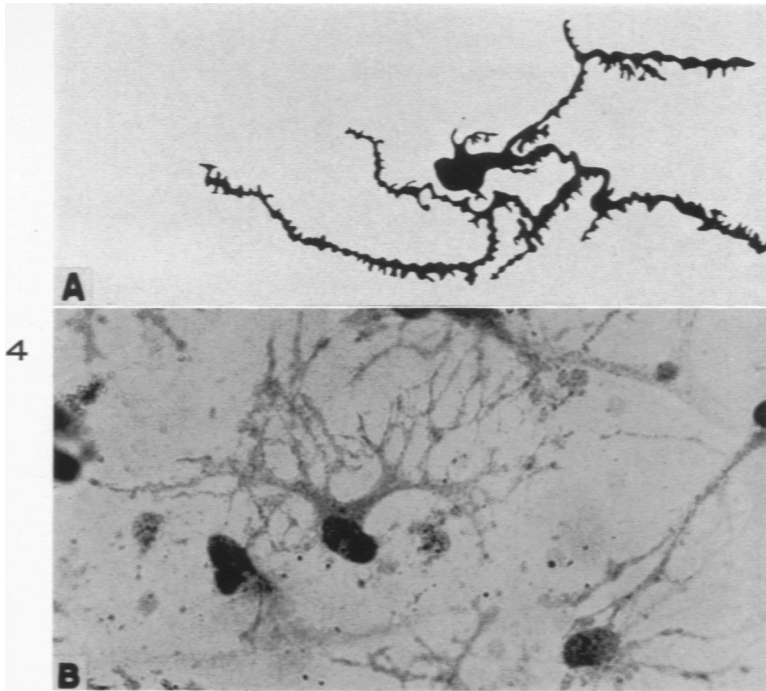
Murray and Stout

3

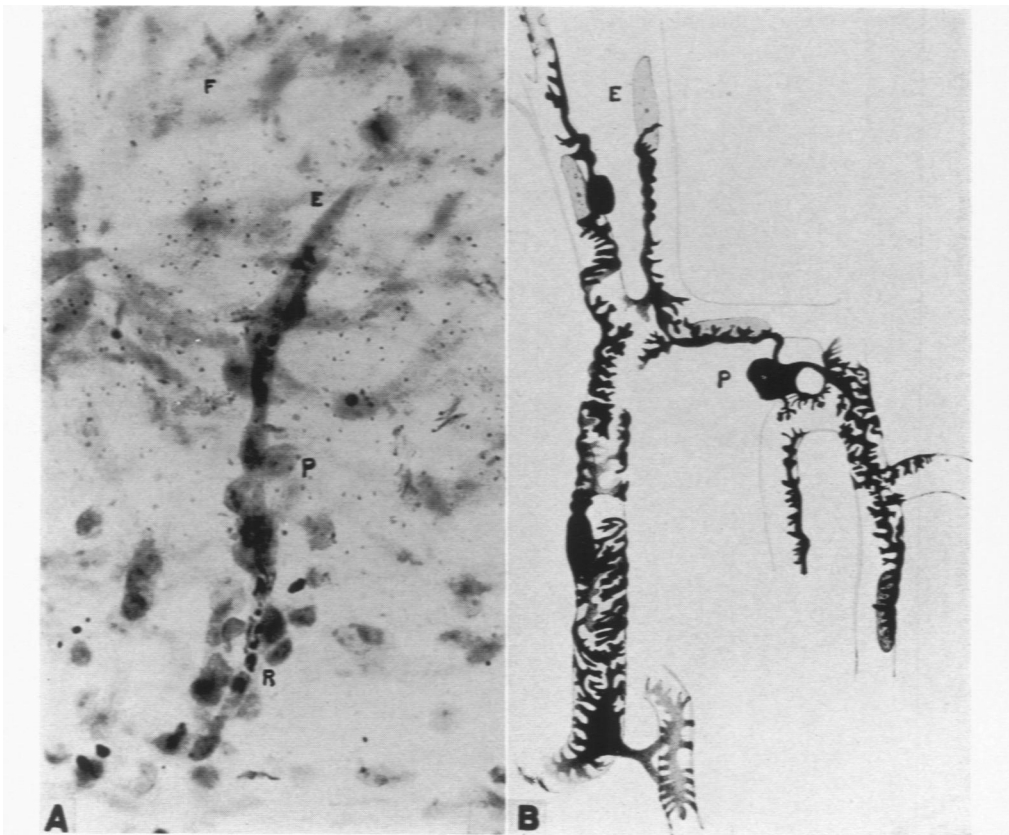
Glomus Tumor

PLATE 28

- FIG. 4. A. Redrawn from Zimmermann (1923). Capillary pericyte with secondary processes contracted; from heart of 43-year-old man.
- B. Pericytes from "epithelioid" nodule of infiltrating glomus tumor (18780). Twenty-four days *in vitro*, Bodian silver impregnation.
- FIG. 5. A. Tissue culture from "epithelioid" tumor nodule. Twenty-eight days *in vitro*; Kopsch fixative, toluidine blue stain. E, endothelial cell; F, fibrocyte; P, pericyte; R, red blood cell.
- B. Redrawn from Zimmermann (1923). Capillary and precapillary pericytes, in the heart of a 43-year-old man.



4



Murray and Stout

5

Glomerus Tumor

PLATE 29

- FIG. 6. Same culture as in Figure 3A; higher magnification.
FIG. 7. Same culture as in Figure 3B; higher magnification.

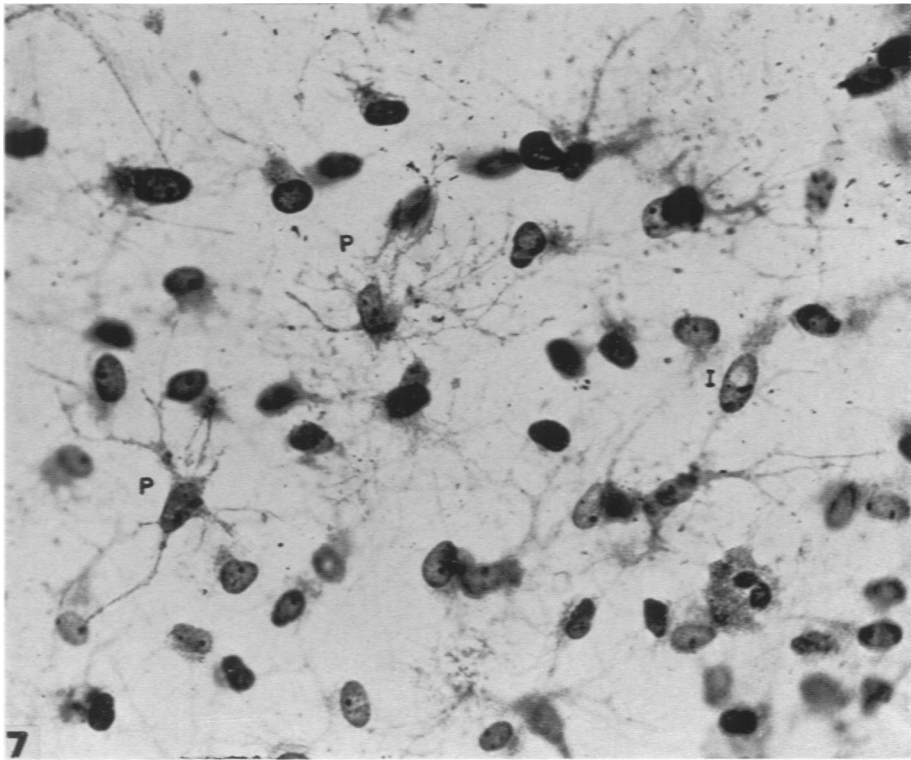
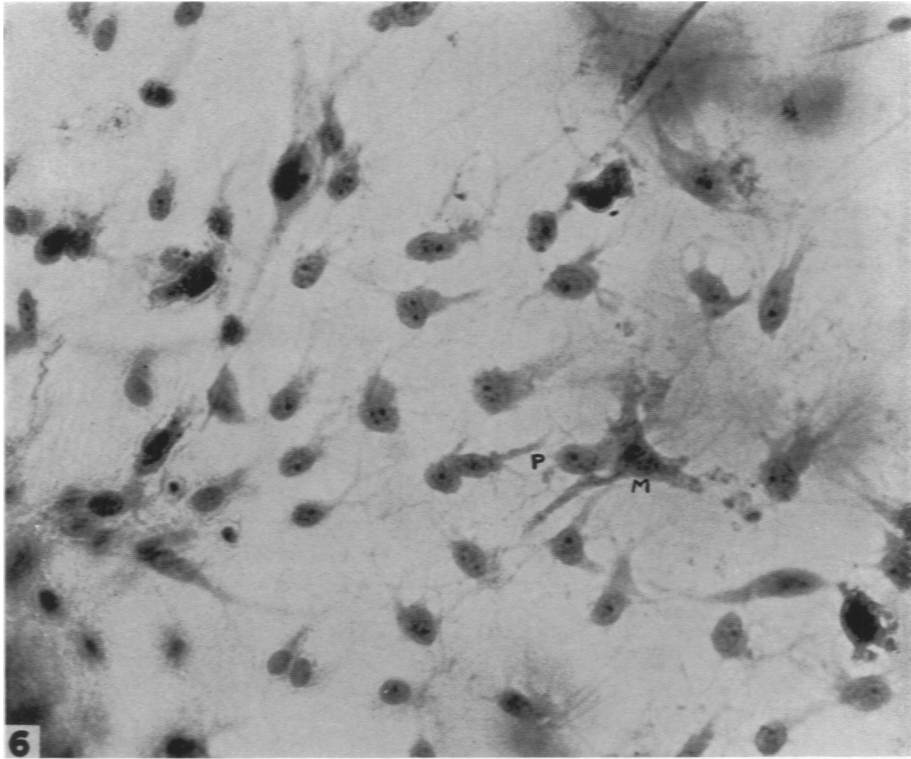
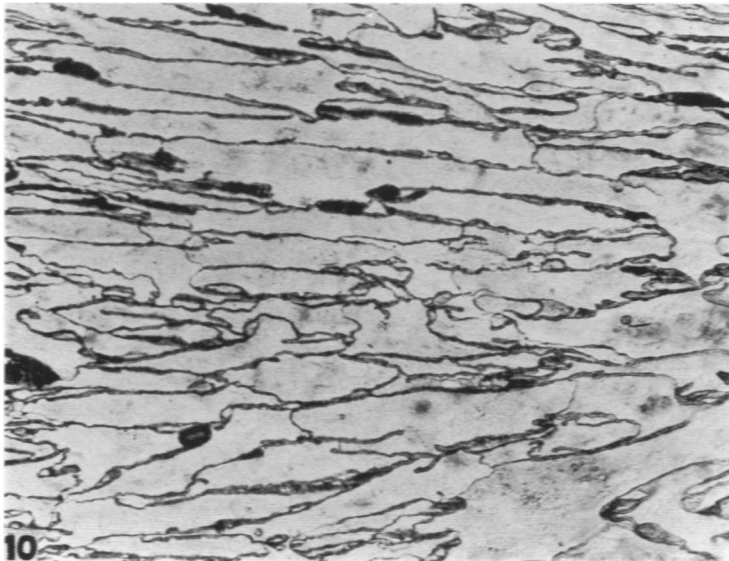
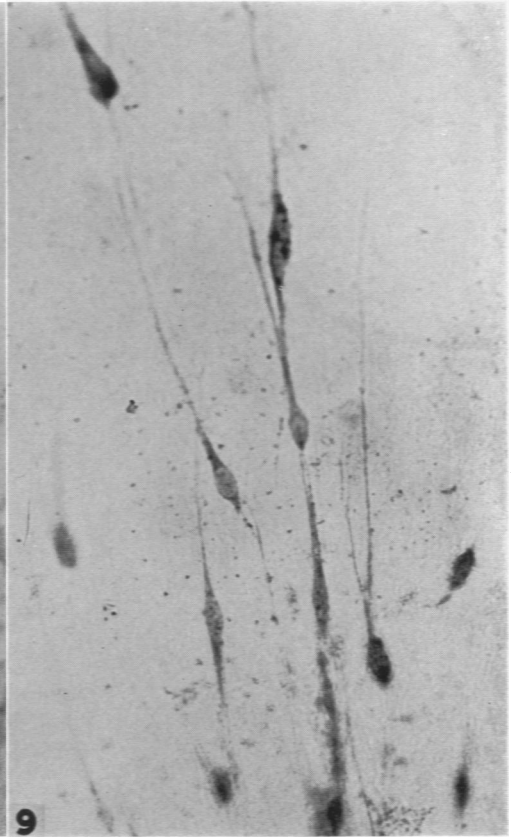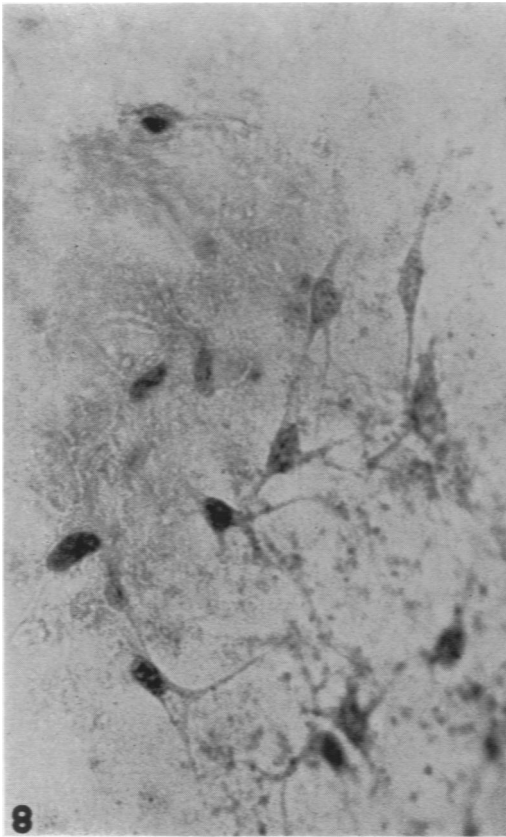


PLATE 30

- FIG. 8. Tissue culture from a benign, circumscribed glomus tumor from nail-bed of finger (72078). Six days *in vitro*; Zenker's fixation, phosphotungstic acid hematoxylin stain.
- FIG. 9. Tissue culture from infiltrating glomus tumor (18780), "epithelioid" nodule; showing pericytes in monopolar and bipolar spindle-shaped form. Five days *in vitro*; Zenker's fixation, phosphotungstic acid hematoxylin stain.
- FIG. 10. Tissue culture from external zone of infiltrating glomus tumor (18780). Twenty days *in vitro*; silver nitrate, toluidine blue.



Murray and Stout

Glomus Tumor