

SILICOSIS OF SYSTEMIC DISTRIBUTION*

KENNETH M. LYNCH, M.D.

(From the Department of Pathology, Medical College of the State of South Carolina, Charleston, S. C.)

The present conception of silicosis, in the words of the Committee on Pneumoconiosis and the Committee on Standards of the American Public Health Association, at a joint meeting in 1932, is that it "is a disease due to breathing air containing silica (SiO_2) characterized anatomically by generalized fibrotic changes and the development of miliary nodulation in both lungs."

Except for the associated deposit and similar fibrosis in peribronchial lymph nodes, which is an integral part of the lung disease, there has been no report of free silica deposit and associated anatomical changes in other viscera in naturally occurring silicosis.

Gardner and Cummings¹ have, however, demonstrated that by the injection of particulate free silica directly into the circulation in certain animals a state of experimental silicosis may be produced which is comparable in tissue damage and fibrosis to naturally occurring silicosis in man.

From a postmortem study, herein recorded, it may be concluded that the possible occurrence of silicosis should be widened to encompass the deposit of silica in such locations as the spleen, liver and kidney, with structural changes in at least the first two of these organs. Whether or not this may also entail consequential anatomical damage, especially in the case of the liver, or the possibility of other systemic effects of a toxic nature, can be no more than speculative at the present.

REPORT OF CASE

The following case study is presented as evidence that silica and silicosis are not necessarily confined to the pulmonary area.

The subject was a negro man, 30 years of age, who worked in a sand-drying plant "the majority of his time" for the 6 years prior to his illness. The information came from his physician, who provided the only account of this patient's exposure to dust and of his illness. It was said that in his work he was exposed to very dusty conditions, with no protective measures available, in that he was subjected to the inhalation of fine sand in quantity, blown by heated air.

He was first seen by a physician in March, 1937, and was treated for a fever, judged to be malaria, after which he returned to work for a few days. In April he was seen again, when he complained of fever and general bodily aching. His temperature was then 100°F ., his pulse rate was 100 and physical examination revealed nothing but "occasional inconstant râles" at the bases of both lungs. Malarial para-

* Received for publication, July 3, 1941.

sites were found in the blood, and after antimalarial treatment he returned to work for about 1 week. When seen again in June his condition was apparently the same, save that he stated that he had been coughing considerably and had apparently lost some weight. His temperature was then "slightly elevated" as was his pulse, and râles over both sides of the chest were constant. X-ray examination of the chest at that time was thought to show tuberculosis and he was put on appropriate treatment. The roentgenogram of the chest, seen by me after the autopsy, exhibited rather heavy but irregular shadows in the mid three-fourths or more of the lungs, appearing to follow bronchial markings generally. The apices and bases were comparatively clear. No definite nodules were seen. There was some obscurity laterally near the right apex. The diaphragm appeared high on both sides. The heart borders were obscured by lung densities. When the patient was seen again in November it was said that he gave the impression of an advanced case of tuberculosis, with râles over the entire lung area and friction rubs over both lungs anteriorly and posteriorly. Two months before he died there were signs of complete collapse of the left lung, with friction rubs and râles over the entire right lung area.

Since this man was not under close observation and conditions for thorough clinical study were not available, the clinical record of the case is inadequate. He died in March, 1938, about 1 year after he first became ill, and I made a postmortem examination about 24 hours later under conditions offering minimal facilities. The autopsy protocol (no. 46134-38-56) follows.

Gross Examination

The body was that of a male Negro of rather small stature, quite emaciated, apparently 20 to 30 years of age, in a state of good preservation, having been dead about 24 hours. There were no superficial abnormalities except that the fingernails were bluish, and there was very little fatty tissue. The fingers and toes showed no clubbing.

The right lung was collapsed so far as was possible because of adhesions and solidification. The pleural cavity contained air, the surfaces were shiny and there were a number of heavy pleural adhesions, particularly in the midregion both laterally and posteriorly. The base was free and there was only a small amount of clear brown fluid in the cavity. This lung was comparatively small and in a solidified, contracted state except at the margins and the apex, where, as well as occasionally over the solidified portion, there were air-bearing areas with large emphysematous blebs. The lung sectioned with distinct resistance, being fibrous and apparently gritty. The middle three-fourths, or more, was of a densely solid, dark gray mottled color, the surface being, in general, depressed, with some particularly retracted scars. At the apex the lung tissue was not solid but fibrous strands appeared in it. There were no cavities and no areas of recognizable necrosis.

The peribronchial nodes were enlarged, some to the size of a kidney bean, and had a dark gray marbled appearance.

The left pleural sac had a reddened rough surface, with some deposit

of fibrin upon it, and there were fewer fibrous adhesions than on the right, these being in the midportion and toward the apex but not at it, and laterally and posteriorly. There was about a teacupful of brown flocculent fluid in this cavity. The left lung was very much like the right in the solidified, resistant, gritty, dark gray marbled, densely solid state of the mid three-fourths or more, with depression of the surface and contracted scars in the solid area. There was also air-bearing tissue with large emphysematous bullae in the apex and margins. No areas of necrosis or cavitation were found.

The peribronchial lymph nodes were in a dark gray dense state similar to that of the nodes on the right.

The heart was enlarged laterally, the enlargement being due to hypertrophy of the right ventricle and to right-sided dilatation. The left ventricle, auricle, valves and vessels and the aorta were of normal appearance and the chambers were filled with currant jelly clot which was beginning to soften.

The liver, spleen, kidneys, pancreas, gastro-intestinal tract and other abdominal organs and structures were of normal appearance and position to superficial examination.

Microscopic Examination

Lung. The pleura was thickened by fibrillar and partly hyalinized connective tissue throughout, that of the left lung being covered by a layer of fibrin containing a few leukocytes. Sections from the right lung showed variable degrees of collapse of the vesicles in the relatively non-fibrosed portions. In the apex of the right lung some small vessels showed thrombosis and there was fresh hemorrhage, probably related to a rupture which caused the pneumothorax.

In the apices, with areas of emphysema, there were a number of rounded, laminated, hyaline nodules containing deposits of fine, granular dustlike particles. These nodules were in part separate but also occurred in groups. In addition there were deposits of black dust in a perivascular distribution. The alveoli in some areas showed an accumulation of edema fluid, and in this also there were scattered fine dust particles.

Sections from the lower parts of the lungs revealed a condition similar to that found in the apices, but greatly aggravated. Numerous single and grouped hyaline, laminated nodules, in which occurred deposits of fine dust particles, occupied a large portion of the lung space. In the periphery of these nodules, and between them when they were grouped, there was proliferation of young fibrous tissue. There was variable emphysema and collapse and in many open alveoli edema fluid discol-

ored by fine dust particles was encountered. In some sections practically all of the lung tissue was obliterated by masses of hyaline nodules, with intervening cellular fibrous tissue.

The bronchi in the dense fibrous areas were in a state of partial to complete collapse and the mucosa of the large bronchi showed epithelial metaplasia.

Liver. In addition to central lobular congestion and associated deposit of brown, granular, iron-bearing pigment, there were deposits of fine granular, opaque dustlike material, located also about the central lobular venules and in the adjacent sinusoids. In addition, this material was found in the connective tissue about the collecting veins. It was accumulated particularly in Kupffer cells in the central lobular, swollen zone, giving a grayish cast to these cells under low magnification. It also occurred in hyaline and fibrillar strands of apparently necrotic material in the central lobular zone, among which were scattered nuclear particles. Where focal deposits were heaviest and liver cells were degenerated or necrotic, there were a few leukocytes and also a few large spindle-shaped fibrous tissue cells. While there was no tissue change shown in the portal vein and bile duct, high magnification revealed some fine granular deposit in the surrounding connective tissues.

The picture given by the liver was that of foreign dustlike material which had been taken out of circulation by the Kupffer cells of the central zone and which, where deposited, had led to degeneration and necrosis of tissue, with hyalinization and early fibrous tissue proliferation. Since practically every lobule showed some deposit, the volume appeared to be considerable with a material loss of liver substance.

Spleen. The capsule was not materially altered. The walls of the arterioles of the malpighian corpuscles were usually, though not invariably, thickened and hyaline. The fibrous trabeculae were prominent and the walls of the vessels within them also showed hyaline thickening. The sinuses were generally full of blood and their walls were prominent and cellular, with the endothelial cells conspicuous. Within the walls of the sinuses, and especially in the endothelial cells, there was a deposit of fine, opaque, dustlike granules, so small that examination with the 16 mm. objective and the 10x ocular did not reveal them. Like material was also deposited in broad zones or in more or less rounded collections within the trabeculae, especially in the periphery of these structures, and within some of the malpighian bodies, here lying along the arteriole as a rule. In the trabeculae and malpighian bodies this material lay within more or less hyalinized tissue, which was neither especially rounded nor laminated, although in some instances there

was a suggestion of nodularity. Within this hyaline matrix were numerous, large, ovoid or spindle-shaped cells, more numerous at the periphery and fewer at the center of the malpighian body. Scattered about were nuclear fragments from necrotic cells. These also were more numerous in the periphery of the body.

The picture as a whole is that of deposit of very fine, opaque granular dust, in the endothelial cells of the sinuses and in nodular or band-like collections, stimulating connective tissue formation, hyalinization and even inducing necrosis, within malpighian bodies and the peripheral zone of the trabeculae.

Kidneys. cursory examination of the kidneys showed no particular abnormality save congestion and cellular degeneration, attributable to postmortem autolysis. Closer study, however, revealed the presence of very fine opaque granules scattered in the endothelial cells of the capillaries of the glomeruli. There was no apparent change associated with their presence, unless there may have been some hyalinization of the basement membrane.

Peribronchial Lymph Nodes. The lymphoid tissue of the nodes adjacent to the large bronchi was, to a large extent, replaced by masses of hyaline nodules of various sizes, containing fine deposits of particulate matter. The centers of some of the larger nodules were calcified.

In none of the organs was there found any evidence of tuberculosis, and no acid-fast bacilli could be found in appropriately stained sections of liver and spleen. The Prussian blue test failed to demonstrate iron in the particles in any of the tissues.

The diagnosis at autopsy was: Pulmonary silicosis; acute pleurisy, left; pneumothorax, right; hypertrophy and dilatation of right heart. After microscopic examination, to this diagnosis the following was added: silicosis of spleen, liver, kidneys and peribronchial lymph nodes. Because of conditions surrounding the autopsy and since there appeared to be no abnormality of any organ except lungs and heart, only blocks of other viscera were taken for microscopic study.

Both grossly and histologically the condition of the lungs was typically that of silicosis and the deposits in the spleen and liver appeared to be of the same material. However, since the natural occurrence of silicosis outside the pulmonary area had not been observed, it was important that the material concerned should be identified.

Microchemical methods of analysis* were devised by F. B. Culp, of the Chemistry Department, since the tissue taken from the liver,

* Mr. Culp proposes to publish his methods of these examinations in a separate article.

spleen and kidney was only that which was intended for histologic study. In this chemical examination the lung was found to contain 1.6 mg. of silica to each gram of wet tissue and 11.15 mg. of silica to each gram of dry tissue. By referring to the chemical examination for silica in lungs in health and disease by McNally,² this will be found to be a higher content of silica than was found in all but two of his eight workers in dusty atmospheres, and significantly greater than his findings in lungs of persons not so exposed. Control tests on three non-diseased lungs, selected to have had a minimum of dust exposure, gave 0.050, 0.019 and 0.031 mg. of silica to each gram of wet tissue and 0.50, 0.13 and 0.18 mg. to each gram of dry tissue, respectively.

The same analysis applied to liver tissue in the present case revealed 0.10 mg. of silica to each gram of wet tissue and 0.70 mg. to each gram of dry tissue, while control tests on two livers having no discoverable similar deposits disclosed 0.015 and 0.005 mg. of silica per gram of wet tissue and 0.08 and 0.02 mg. per gram of dry tissue, respectively.

In the spleen the chemical examination revealed 0.2 mg. of silica per gram of wet tissue and 1.40 mg. to each gram of dry tissue, as compared to 0.078 and 0.033 mg. per gram of wet tissue and 0.46 and 0.23 mg. per gram of dry tissue, respectively, in two normal spleens.

The kidney yielded 0.02 mg. of silica per gram of wet tissue and 0.14 mg. per gram of dry tissue, as compared to 0.013, 0.008 and 0.01 mg. per gram of wet tissue and 0.09, 0.04 and 0.05 mg. of silica per gram of dry tissue, respectively, in three normal kidneys.

As a further control, the formaldehyde solution in which the tissue was fixed contained 0.001 mg. of silica per cc. of fluid, as did also freshly made formaldehyde fixing fluid.

It is therefore seen that the content of silica of the tissues concerned was significantly higher in lung, liver and spleen than in normal controls and even in the kidney was higher than in the three controls used.

DISCUSSION

In spite of the difficulties attending positive identification of the dustlike particles in the spleen and liver as silica, there can be no question that it is the same material as seen in the lungs and, further, that there is actual and material damage to spleen and liver tissue by it.

It is interesting to note that the location of deposits in the liver is quite different from that found by Gardner and Cummings¹ in experimental silicosis of the liver, that being periportal in distribution and leading to a portal type of cirrhosis, while here the deposit is of central lobular location, associated prominently with Kupffer cells in the sinusoids and with degeneration and necrosis of liver cells and early fibrosis.

The material is not iron-bearing, it is morphologically like the dust deposits in the lung, the tissues containing it were shown to hold a significant amount of silica by chemical examination, the tissues damaged were in direct relation to the dustlike deposits, and neither the distribution, the tissue change, nor bacteriologic staining indicates that there is associated tuberculosis.

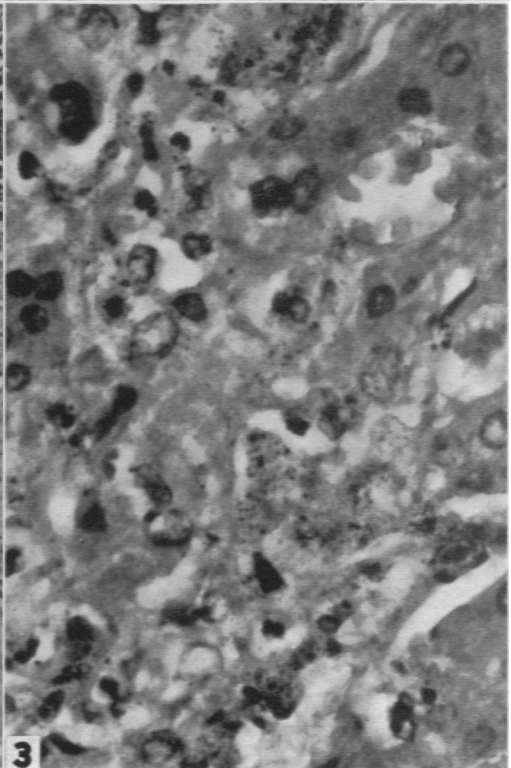
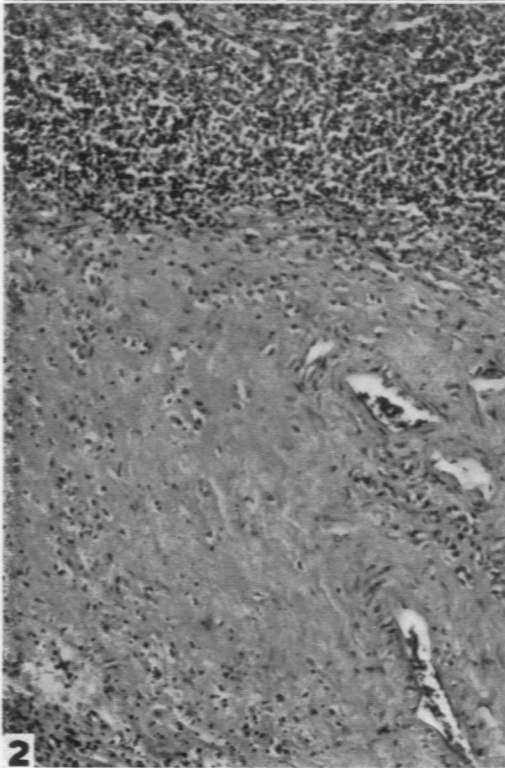
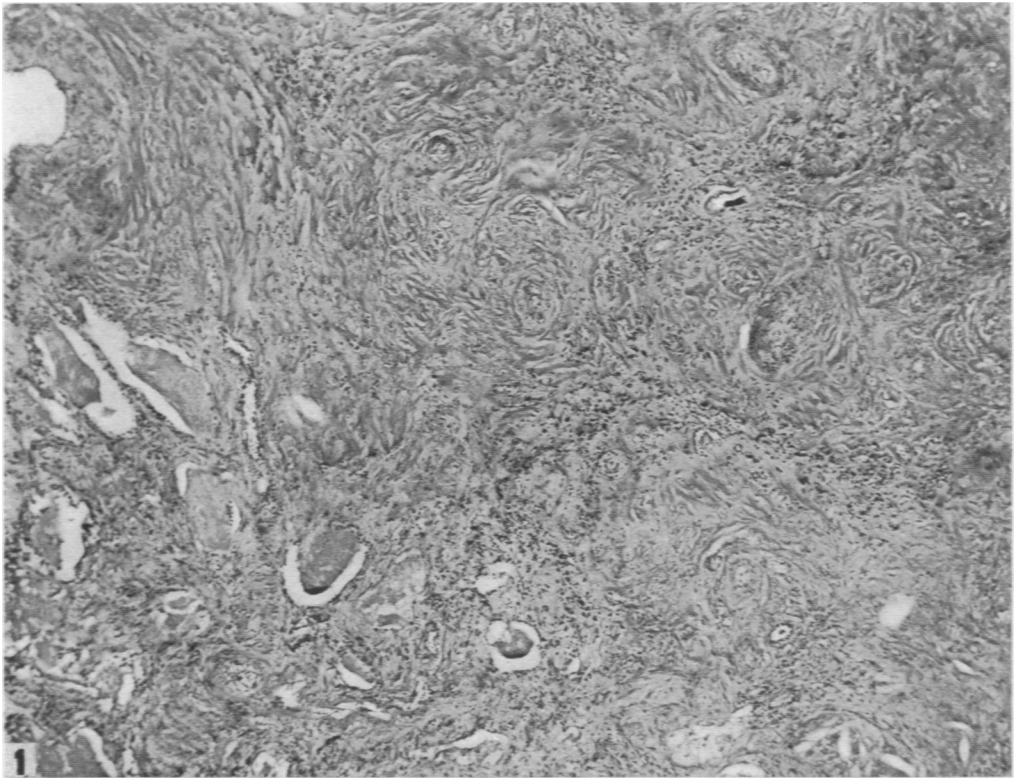
REFERENCES

1. Gardner, L. U., and Cummings, D. E. The reaction to fine and medium sized quartz and aluminum oxide particles. Silicotic cirrhosis of the liver. *Am. J. Path.*, 1933, supp. 9, 751-763.
2. McNally, W. D. Silicon dioxide content of lungs in health and disease. *J. A. M. A.*, 1933, 101, 584-587.

DESCRIPTION OF PLATE

PLATE 56

- FIG. 1. Hyaline fibrosis of lung. Silica particles too small to be seen at this magnification. $\times 67$.
- FIG. 2. Hyaline fibrous nodule in spleen, with particulate deposit. $\times 226$.
- FIG. 3. Deposit of particulate material with cellular degeneration in the liver in silicosis. $\times 744$.



Lynch

Silicosis of Systemic Distribution