

MESOTHELIOMAS OF THE UTERINE AND TUBAL SEROSA AND
THE TUNICA VAGINALIS TESTIS

REPORT OF FOUR CASES *

NEWTON EVANS, M.D.

(From the Pathology Laboratory of the Los Angeles County Hospital and the Department of Pathology, College of Medical Evangelists, Los Angeles, Calif.)

A degree of temerity is required in attempting to discuss neoplasms arising from endothelial and mesothelial tissues. It has even been maintained that no primary tumor of pleural endothelium or mesothelium has ever been demonstrated.¹ One obstacle in such a study is a certain disagreement as to the meaning of "endothelium" and mesothelium." Histologists are in nearly complete agreement that *endothelium* is the accepted term for the flattened cells lining the lumina of the blood vascular and lymph vascular channels, and that *mesothelium* is to be applied exclusively to the cells lining the serous cavities; *i.e.*, pleura, pericardium, peritoneum and tunica vaginalis testis. Moreover, it is recognized that the vascular channels and the cellular lining of the serous cavities have independent embryological origins and anatomically are not connected.² Yet many writers use the term "endothelioma" for primary tumors of the serous membranes.

In this report, "mesothelioma" is used to identify primary tumors taking origin from the lining cells of the serous membranes. In 37 case reports, in medical literature, of primary tumors of the pleura, pericardium, or peritoneum, 22 are called endotheliomas, 13 are designated as mesotheliomas, and 2 as celotheliomas.

This cursory tabulation of reports of primary serous-membrane tumors from the cumulative index for the past 5 years indicates that a much larger number of tumors regarded as endotheliomas, mesotheliomas, or celotheliomas are found in the pleura than in the other serous membranes; the pericardium coming next in order of incidence, as follows: pleura, 30; pericardium, 5; peritoneum, 2. No case reports were found of tumors so named in the tunica vaginalis. One lymphangioma of the tunica vaginalis is recorded. The great majority of these reported tumors are clinically and morphologically malignant.

The four cases here reported have been encountered recently. They constitute a small group of tumors of obviously similar or identical nature, two occurring in the female pelvis and two in the tunica vaginalis of the testicle. Clinically all of these appeared to be benign in character. The histological pattern is strikingly characteristic, apparently unique and readily recognized microscopically.

* Received for publication, August 17, 1942.

I have failed to find in medical literature any accounts of tumors similar to the one here reported involving the serosa of the uterus. Several reports of tumors of the epididymis and tunica vaginalis with the characteristic histological pattern are available, but these have not been previously considered as mesotheliomas or endotheliomas, and have been variously diagnosed.

REPORTS OF CASES

*Case 1**

H. F. (laboratory no. 936), married, white woman, age 52. Pelvic symptoms led to recognition of a tumor of the uterus. Abdominal supracervical hysterectomy was done. The patient made an uneventful recovery and has remained well.

The specimen consisted of an enlarged uterine body containing a rounded tumor mass about 7 cm. in diameter, intramural in position but extending to the serosa of the uterus. On section the greater part of the tumor appeared grossly to have the structure typical of leiomyoma, being firm and fasciculated. The serous surface presented several clear gelatinous cystic structures about 1 cm. in diameter, the surface between the cysts being somewhat roughened. The cut surface presented a distinct and peculiar zone about 8 mm. in thickness, covering that portion of the tumor immediately beneath the uterine serosa (Fig. 1). This zone appeared more homogenous and lighter in color than the remaining myomatous tumor.

Gross and microscopical examination of the tumor in its relation to the uterus made it clear that the peculiar tissue constituting the superficial zone was not confined to this area but penetrated deeply throughout the myomatous tissue. However, it did not invade the myometrium nor the endometrium. The histological features are described and discussed below. In brief, the structure was adenomatous in appearance.

Case 2†

L. L. (laboratory no. S. J. 735), was a white woman, age 45, who for 3 years had suffered from profuse menstria, resulting in pronounced secondary anemia. In September, 1941, subtotal hysterectomy was done by abdominal section, including the removal of both tubes and one ovary.

The body of the uterus after removal was moderately enlarged and contained multiple rounded fibromyomatous tumors. The endometrium presented a small (8 mm.), firm polyp, just above the level of the internal os. The right ovary was 3.4 cm. in its greatest diameter and contained small cysts.

* From the service of Dr. W. W. Holly, and Dr. Ralph Crumrine, pathologist.

† From the service of Dr. D. A. Harwood, and Dr. R. H. Osborne, pathologist.

The fallopian tubes were of normal appearance and size, except for the presence of a small, rounded tumor upon the wall of one tube. This was a firm, spherical nodule about 8 mm. in diameter with a granular surface and was almost white in color. Microscopically the sections presented neoplastic tissue with a glandular pattern similar to that seen in case 1. The surface was in places covered by a layer of cuboidal epithelium-like cells.

*Case 3 **

L. W. (laboratory no. W. M. H. 42-360), was a white male, age 66. At examination he presented a mass in the left scrotal sac, which had been first noted 22 years before and was slowly growing. The mass was hard, smooth and of globular shape, and was apparently attached by a narrow isthmus to the lower pole of the testicle, which was otherwise normal.

The tumor was removed surgically. It was found attached to the parietal layer of the tunica vaginalis adjacent to the lower pole of the epididymis. It was free in the tunica vaginalis, which contained about 20 cc. of clear fluid, except for its attachment by a pedicle about 1 cm. in diameter. Its surface was fairly smooth, and its shape was globular, measuring approximately 2.5 cm. in diameter (Fig. 2). About 2½ months later, the operative site was healed, without symptoms or abnormal findings. Microscopically the tumor presented a neoplastic pattern practically identical with that of case 1.

Case 4 †

W. D. (laboratory no. 18-C-42-36), was a white male, age 53. For about 3 years he had noticed a small nodule in the scrotum which was slowly growing and painless. Examination revealed a small, round, hard mass apparently attached to the lower pole of the left epididymis and freely movable within the scrotum.

The tumor was removed under local anesthesia. It was attached by a broad pedicle (one-fourth of its circumference) to the epididymis, and measured 1.7 cm. in diameter. The outer surface was fairly smooth. The cut surface was firm, whitish and somewhat fibrous, and at the periphery had an apparent capsule. Microscopically the structure of this tumor was strikingly similar to that of the neoplastic tissues of the previous cases. Following removal the operative site healed without incident.

HISTOLOGY

As indicated in the preceding brief case reports, these four tumors presented a striking uniformity in structure. The first impression was that of a tumor of adenomatous type. Careful study led to the conviction that the characteristic tumor cells were not epithelial in character, but were mesothelial.

* From the service of Dr. Theodore Bergman, and Dr. R. H. Osborne, pathologist.

† From the service of Dr. C. H. MacKay, and Dr. V. L. Andrews, pathologist.

The glandlike structures varied greatly in size and shape. The cells lining the acini, however, did not have the appearance of true glandular epithelium. They were markedly unequal in size and dissimilar in shape, varying from low, flat plates to a cuboidal or low-columnar form. The flat cell-forms had a tendency to take the "chain" appearance characterizing mesothelial cell membranes (Fig. 3). Many groups of cells were solid, lacking open lumina. A notable cellular characteristic was that a large proportion presented vacuolated cytoplasm, the vacuoles varying greatly in size and giving the cells a "signet-ring" appearance. These vacuoles apparently served as the origin of new glandlike acinar cavities. With the expansion of the cavity, a proliferation of the cell occurred resulting in a new acinus lined by multiple cells. Some of the rounded vacuoles and resulting lumina contained stringy or granular material which, with special stains, gave the tinctorial reaction of mucin (Fig. 4). Staining for fat showed the content of these vacuoles not to be lipid material.

The interstitial tissue framework varied in amount and was largely collagenous fibrous tissue. A moderately rich network of blood vessels was present. A striking feature was the presence of groups of lymphoid cells in certain areas, sometimes so aggregated as to suggest follicular formation (Fig. 5). Special stains for reticulum revealed an abundant network of reticular fibrils intimately related to the epithelium-like cells. Special stains for elastic fibers revealed a moderate amount of elastic tissue in the interstitial trabeculae around the cell groups.

The free surface of the tumor of the tunica vaginalis in case 3 was covered by a rather dense fibrous capsule, but in the other three tumors no definite capsule was present at the serous surface. The findings at the serous surface in the uterine tumor, case 1, were of particular significance. The surface presented multiple papillary and cystlike projections, the cysts being lined by characteristic mesothelial cells. The free surface was covered by mesothelial cells, which were manifestly hypertrophic in many areas, the cells being cuboidal or low-columnar in shape. These surface cells were seen to be continuous with the cells lining the glandlike structures in the body of the tumor through apertures into which the surface cells dipped. This finding is shown clearly in Figures 6 and 7. In the other three tumors the identity of the cell types lining the acini with the cuboidal mesothelial cells upon the tumor surfaces seems obvious. However, the demonstration of the direct connection of the surface mesothelium with the acinar cells is not so clear-cut as in the uterine tumor.

It is my impression, based upon the clinical histories of these cases

as well as the microscopical appearances, that they are essentially benign neoplasms.

COMMENTS

A search of the literature revealed reports,³⁻⁶ several with photomicrographic reproductions, of at least six tumors of the epididymis, of which the histories, gross descriptions and microscopical patterns indicate that they are of the same nature as the tumors here reported. These have been described under various diagnoses. One was called a cavernous lymphangioma. Three were regarded as grade I adenocarcinomas, and two as adenomas of the epididymis.

Oberndorfer³ described his case as a walnut-sized, firm white tumor which protruded into the cavum vaginale, resting on the lower pole of the right testis. Microscopically he described the tumor "meshes" as approximately the size of seminiferous tubules of the testis. He particularly described the numerous groups of lymphocytes scattered throughout the tumor. He regarded the glandlike structure as a lymphangioma.

Thompson,⁴ in his report of 13 tumors of the epididymis, included seven carcinomas. Of these seven, one was designated grade II, two as grade IV, and four were regarded as grade I adenocarcinomas. Of these last four, two were illustrated by photomicrographs which show them to be tumors of the same type as the two tumors of the tunica vaginalis in the present report. A third one was described by Thompson as being identical with the two of which photographs were shown.

DISCUSSION

Assuming, for purposes of discussion, that these tumors constitute a group which has not heretofore been clearly recognized as such, what are the possible histogenic classifications which should be considered?

1. *Epithelial Tumors (Adenomas or Adenocarcinomas)*. The cell morphology fails to correspond to any epithelial type with which I am acquainted. The location, and anatomical and histological relationships are inconsistent with an origin from any recognized normal epithelial structures. If, however, it should be assumed that these tumors are epithelial, are they benign adenomas or adenocarcinomas? The clinical course of all of the cases in my group, as well as those previously described, indicates a benign character. This corresponds to the histological picture, including absence of mitotic activity.

2. *Vascular Endothelial Neoplasms (Angio-endotheliomas)*. Lymphangiomas and hemangiomas are recognized groups of vascular tumors of greater or less cellularity, but in my study of such tumors, structures

of a pattern identical to that of those here described have not been seen. And, further, the demonstrated relationship of the spaces and channels in my present group to the serous surfaces precludes angiomatous character because of the recognized histological independence of the two structures.

3. *Mesonephromas*. Recently attention has been called⁷ to a group of tumors usually involving the ovaries which are regarded as originating from cell-rests arising in the mesonephros and recognized by the presence of structures suggesting imperfect glomeruli and Bowman's capsules. The view is held that their origin is from the embryonic mesonephros which lies in intimate relationship to the developing gonads, and that the presence of their kidneylike structures in the adult ovary is thus explained. It is admitted that there is a superficial similarity between the cellular structures here described and some of the appearances illustrated for the so-called ovarian "mesonephromas." A careful study, however, of the comparative histology fails to show any essential similarity.

4. *Mesotheliomas*. In view of the foregoing considerations, particularly the anatomical location of the tumors in immediate relationship to the serous membranes and the clear-cut continuity of the cells lining the acinuslike spaces with the lining mesothelial cells of the overlying serosa, it is held that these tumors should be denominated *mesotheliomas*.

That each of this small group of tumors was located in direct relationship to the generative organs suggests the possibility that the histogenic factors concerned may be related to the potentialities of the specialized mesothelium of the urogenital ridge, which in the embryo serves as the origin of the gonadal epithelial structures. It will be of interest to know whether tumors of this histological type may be found in the other serous cavities or in portions of the peritoneal cavity more remote from the urogenital ridge.

SUMMARY AND CONCLUSION

Four tumors of markedly similar microscopical structure, located in direct connection with the female or the male generative organs and involving their serous membranes, have been described and the fact pointed out that histologically similar tumors have been previously described, but have been variously classified.

It is concluded that these tumors represent a type not heretofore generally recognized, and that the facts presented justify the view that the characteristic cell structure is mesothelial and that the tumors may properly be considered to be mesotheliomas.

REFERENCES

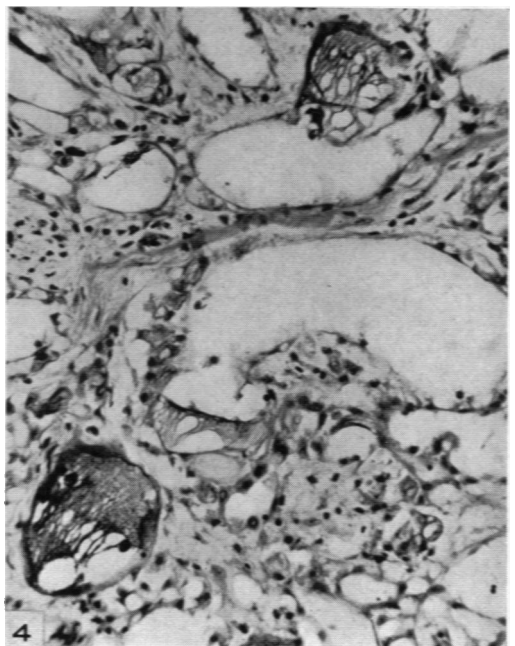
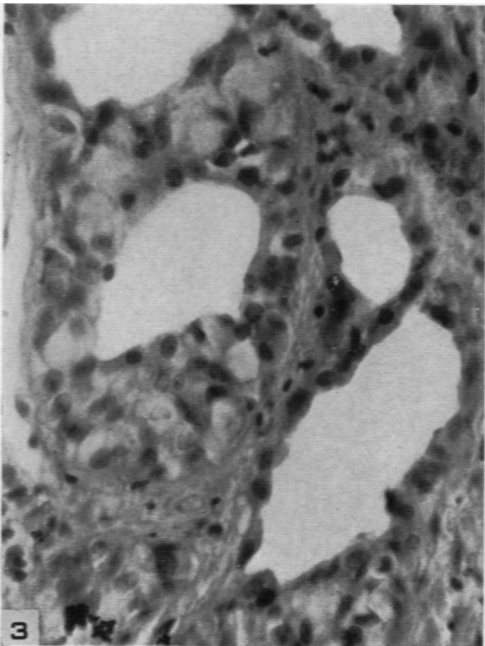
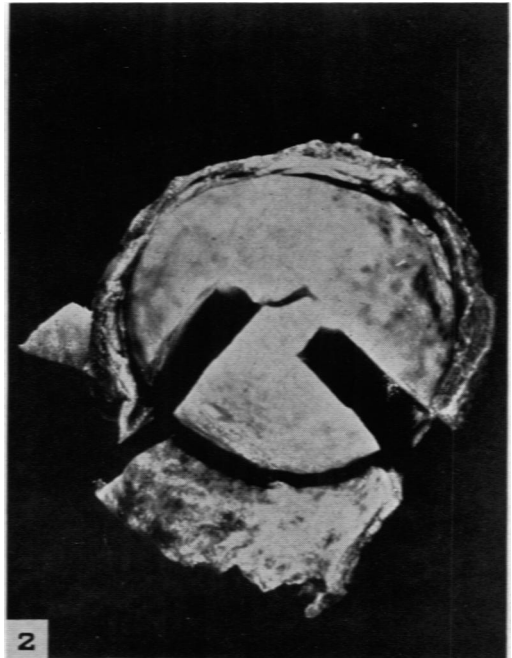
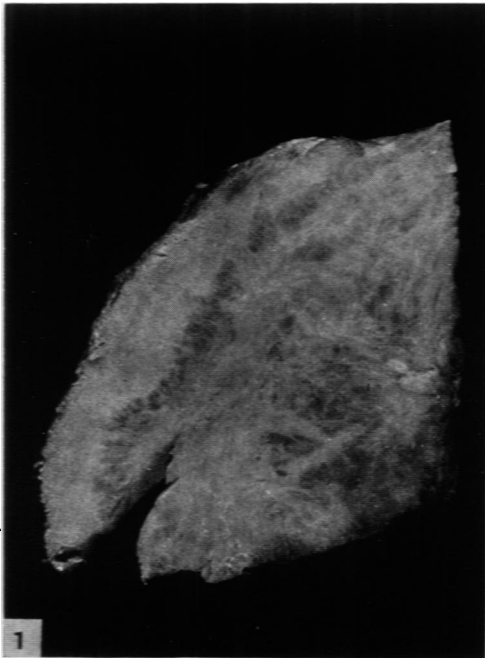
1. Robertson, H. E. "Endothelioma" of the pleura. *J. Cancer Research*, 1924, 8, 317-375.
2. Bremer, J. L. A Textbook of Histology. P. Blakiston's Son & Co., Philadelphia, 1936, ed. 5.
3. Oberndorfer, S. Die inneren männlichen Geschlechtsorgane. In: Henke, F., and Lubarsch, O. Handbuch der speziellen pathologischen Anatomie und Histologie. Julius Springer, Berlin, 1931, 6, pt. 3, 818-819.
4. Thompson, G. J. Tumors of spermatic cord, epididymis, and testicular tunics. Review of literature and report of 41 additional cases. *Surg., Gynec. & Obst.*, 1936, 62, 712-728.
5. Gordon-Taylor, Gordon, and Ormman-Davis, C. A case of adenoma of the epididymis, with a note on solid tumours of the epididymis. *Brit. J. Surg.*, 1941-42, 29, 260-262.
6. Blumer, C. E. M., and Edwards, J. L. Adenoma of the epididymis. *Brit. J. Surg.*, 1941-42, 29, 263-265.
7. Schiller, Walter. Mesonephroma ovarii. *Am. J. Cancer*, 1939, 35, 1-21.

[*Illustrations follow*]

DESCRIPTION OF PLATES

PLATE 47

- FIG. 1.** Case 1. A section of the tumor of the uterus showing a light colored zone at the serous surface. The peripheral zone is mesothelial neoplastic tissue. The deeper portions are composed of interlacing myoma and mesothelioma. $\times 134$.
- FIG. 2.** Case 3. The tumor of the tunica vaginalis showing a free rounded surface enfolded by the tunica, to which it was attached by a large pedicle. $\times 134$.
- FIG. 3.** Case 4. Mesothelial cells surround glandlike spaces. The largest lumen is lined on one side by "chainlike" cells. Adjacent is a lumen surrounded by cells in multiple layers. Several of these cells present a "signet-ring" appearance. $\times 315$.
- FIG. 4.** Case 3. Large spaces are lined by greatly flattened cells. Three collections of mucinlike material gave a characteristic coloring. Hoyer's stain. $\times 190$.

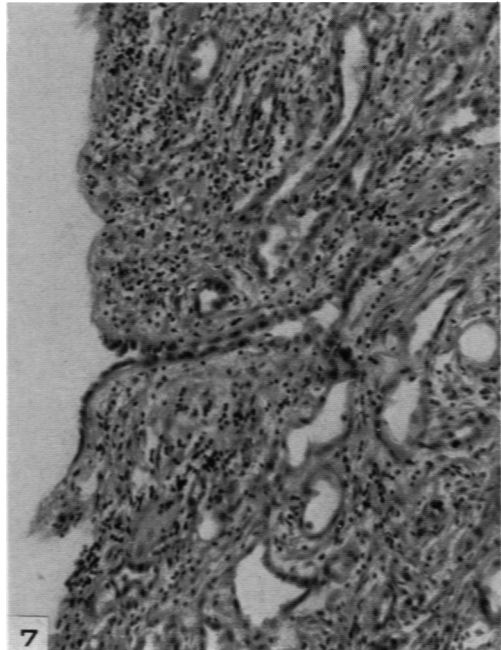
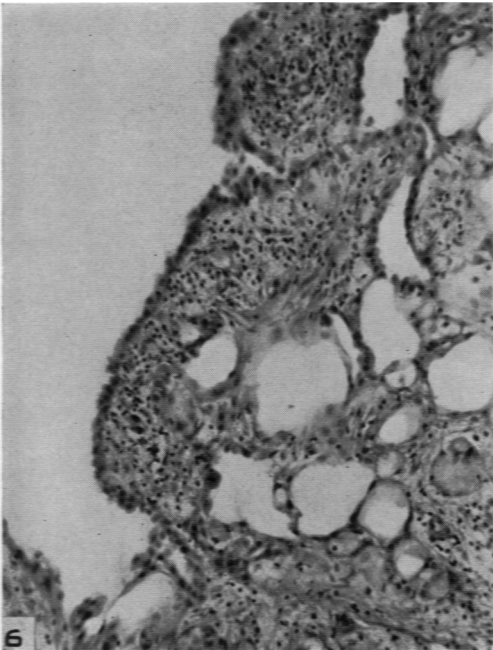
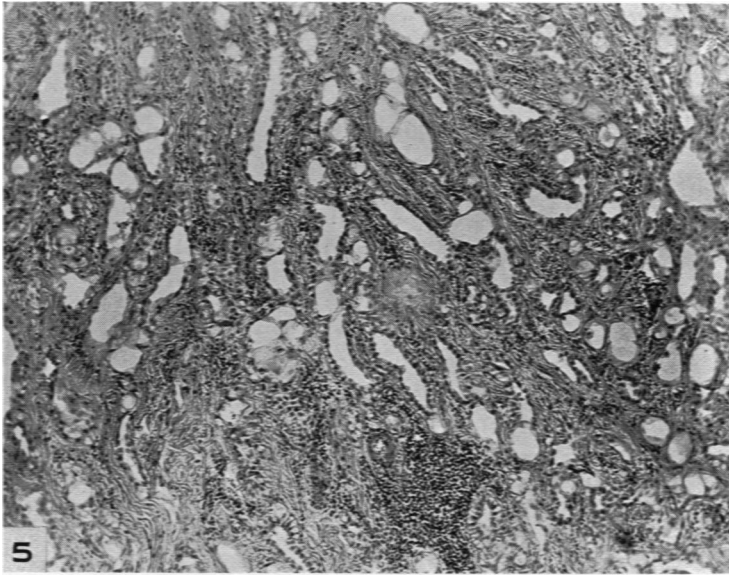


Evans

Mesotheliomas

PLATE 48

- FIG. 5. Case 3. Characteristic tumor pattern under low magnification showing abundant interstitial collagenous tissue and a collection of lymphocytes. $\times 60$.
- FIG. 6. Case 1. The surface of the uterine tumor covered by cuboidal mesothelial cells which are continuous through surface apertures with similar cells lining communicating spaces. $\times 120$.
- FIG. 7. Case 1. The communication of glandlike structure with surface mesothelium. The stroma near the surface contains many lymphocytes. $\times 140$.



Evans

Mesotheliomas