

## A QUANTITATIVE ASSESSMENT OF THE STRUCTURAL CHANGES IN THE RAT'S LIVER FOLLOWING OBSTRUCTION OF THE COMMON BILE DUCT

J. M. S. JOHNSTONE\* AND E. G. LEE

*From the Nuffield Department of Surgery, Radcliffe Infirmary, Oxford*

Received for publication August 18, 1975

**Summary.**—A study has been made of sequential changes in the rat's liver from 1 to 40 days after obstruction of the common bile duct. The qualitative changes have been described and illustrated. The volume proportions of hepatocytes, bile duct epithelium and biliary stroma have been quantified by histological analysis using a point counting technique. The proliferation of hepatocytes and bile duct cells have been measured by labelling with tritiated thymidine. The absolute quantity of hepatocytes in each liver has been estimated and expressed as a percentage of body weight.

Over 40 days there is a relative fall in the volume proportion of hepatocytes and an increase in bile duct cells and biliary stroma. These changes in volume proportions are related directly to the period of jaundice. Biliary stroma increases in support of new bile duct tissue and there is no excessive fibrosis. Hepatocytes proliferate at a greater rate than normal after obstruction of the common bile duct and the degree of proliferation reaches a maximum of 24 times that of normal 4 days after obstruction. Similarly, the proliferation of bile duct epithelium is increased in obstructive jaundice but in this instance it reaches a maximum of 50 times that of normal 24 h after ligation of the common bile duct. The absolute quantity of hepatocytes in the liver probably falls during the period of jaundice. However, the fall is less than anticipated from the volume proportion of hepatocytes because of the overall increase in liver size.

THERE IS considerable information on the structural changes in the liver of rats with obstructive jaundice. Cameron and Oakley (1932) described gross and light histological microscopical changes in the rat's liver following obstruction of the common bile duct after intervals from  $\frac{1}{2}$  h to 9 weeks. In a similar experiment Cameron and Hassan (1935) compared the structural changes with alterations in liver function. Steiner, Carruthers and Kalifat (1962) reported the ductular cell reaction of rat's liver in extrahepatic cirrhosis as seen under the electron microscope. More recently, close attention has been given to both changes in liver function and to systemic disturbance in obstructive jaundice. Lee, Ross and

Haines (1972) demonstrated gross disturbance of biosynthetic function in an isolated perfused rat's liver and Lee (1972) showed impairment of wound healing after ligation of the common bile duct.

There is no record of a quantitative assessment of structural changes in the liver following obstruction of the common bile duct to indicate whether or not deterioration in function is related to absolute loss of liver parenchyma. In this study, the structural changes in rat liver removed at different intervals after ligation of the common bile duct have been quantified. In particular, the volume proportions of hepatocytes, bile duct epithelium and supporting stroma in the portal areas have been measured. The

\* Present address: 23 De Montfort Street, Leicester LE1 7GX.

degree of proliferation of hepatocytes and bile duct epithelium has been estimated by the uptake of tritiated thymidine. The weight of hepatocytes in each liver has been calculated and expressed as a percentage of total body weight.

#### MATERIALS AND METHODS

All experiments were performed on male Wistar rats weighing between 120 and 160 g. Each rat was subjected either to ligation and division of the common bile duct (jaundiced rats) or to sham ligation of the ducts (sham rats).

The operations were performed under ether anaesthesia and with sterile conditions. A mid-line ventral incision was made through the linea alba. The duodenum was delivered through the wound so as to place the bile duct under tension. The first part of the bile duct was isolated and 2 ligatures placed around it. In the jaundiced rats the ligatures were tied and the duct divided, and in sham rats the ligatures were withdrawn leaving the bile duct intact. The wounds were closed with 40 silk to the peritoneum, linea alba and skin.

Half an hour before sacrifice the animals were anaesthetized and 1 mCi/g tritiated thymidine was injected into the tail vein. Each rat was killed by a blow to the head and then weighed. The abdominal incision was reopened and the peritoneum inspected. Animals with peritonitis or gross ascites were discarded. The liver was removed, weighed, divided into segments 0.5 cm thick, and placed in 5% formaldehyde in saline. After fixation, 5 pieces from each liver were taken at random and processed through graded alcohols, cleared in chloroform, impregnated and embedded in wax.

Sections 3 to 5  $\mu$ m were cut on a Leitz rotary microtome and stained by the haematoxylin and eosin, and Masson trichrome methods. One section from each liver was coated with Ilford G5 liquid emulsion using a dipping technique and exposed for 28 days. The slide was developed in Ilford plus X, fixed in 5% sodium thiosulphate, the section washed and post stained with light haematoxylin and eosin.

*Experimental procedure.* Thirty-two jaundiced rats and 21 sham animals were prepared. Four jaundiced and 2 sham animals were killed at 1, 2 and 4 days and thereafter at 4-day intervals to 28 days. Two jaundiced and one sham animal were killed at 32, 36 and 40 days. Two jaundiced and 1 sham animal in each group were injected with tritiated thymidine  $\frac{1}{2}$  h before sacrifice.

*Volume determinations.* The volume proportions of hepatocytes, bile duct epithelium, and

supporting stroma were estimated by quantitative analysis of histological sections (Dunnill, 1968). The area occupied by each component on the cut surface of the section was determined by a point sampling technique. This procedure depends on the fact that if a number of random points are placed on a section, the number of points falling on each component is proportional to the area of the component on the cut surface. According to the theorem of Delesse, the area of each component is proportional to the volume of that component.

Five Masson trichrome sections from each liver were analysed, one section being taken from each 5 blocks prepared from that liver. Each slide was projected with a Leitz microprojector onto a point counting grid, using the lowest magnification compatible with identification of the tissue. The first field was selected at random and by moving the mechanical stage a given distance, subsequent fields were chosen systematically. About 50 points were counted in each field and 10 fields in each section. For each liver, therefore, a total of 2500 points in 50 fields were counted. A summation average graph was constructed and showed that counting a larger number of fields failed to alter the mean values significantly.

*Determination of cell proliferation.*—To quantify the degree of proliferation of bile duct epithelial cells and hepatocytes, the number of cells labelled with tritiated thymidine was counted and expressed as a percentage of the total number of cells. One section from each liver, labelled with tritiated thymidine and counterstained with haematoxylin and eosin, was projected under high power onto a screen 15 by 10 cm and placed 50 cm from the projector. To assist counting, the screen was divided into 8 equal areas by light horizontal lines. The first field was selected at random and, by moving the mechanical stage a given distance, a further 23 fields were projected. The distance that the mechanical stage was moved between each field was regulated so as to allow the entire section to be uniformly scanned.

In each power field a count was made both of the total number of hepatocytes and bile duct epithelial cells and of labelled hepatocytes and labelled bile duct epithelial cells. The actual number of cells counted in each section varied considerably depending on the period of jaundice and, consequently, the extent to which hepatocytes had been replaced by biliary tissue. For example, in the normal liver, only 25 bile duct cells were counted in 24 fields. To obtain an accurate result, it was necessary to count at least 300 cells. If the number of cells in 25 fields fell below this minimum, scanning was continued until that figure was reached.

*Hepatocyte weight in each liver.* As the speci-

TABLE I.—*Volume Proportions of Parenchyma, Bile Duct Epithelium and Supportive Stroma in Jaundiced and Sham Rats*

Duration of jaundice in days	No. of animals in group	Volume proportions		
		Parenchyma	Bile duct	Supportive stroma
0 (Sham)	21	97	2	1
1	4	97	2	1
2	4	96	3	1
4	4	95	3	2
8	4	90	7	3
12	4	81	12	7
16	4	72	21	11
20	4	62	22	14
24	4	54	30	16
28	3	53	29	18
32	1	35	40	25
36	1	43	37	20
40	2	37	42	20

fic gravity of tissue was approximately 1, the weight of hepatocytes in each animal was calculated from the total weight of the fixed liver and from the volume of hepatocytes. To allow comparison between animals of vastly different size, the weight of liver has been expressed as a percentage of the total animal weight.

## RESULTS

The sequential morphological changes in the liver after obstruction of the bile duct are illustrated in Fig. 1a, b, c and 2a, b. The quantitative assessment of those changes are listed in Tables I, II and III and illustrated in histogram form in Fig. 5, 6, 7. The results can conveniently be considered in 3 groups, each group being defined by the period of

jaundice. In the first group, animals were jaundiced between 1 and 8 days; in the second between 9 and 28 days; and in the third between 29 and 40 days.

## 1-8 days

*Qualitative changes.*—Gross changes in the liver are minimal, the size and consistency are normal, there is a yellow green discolouration and bile is extruded from the cut surface. Histologically, at 4 and 8 days many hepatocytes are labelled and show mitotic activity. There is little evidence of sporadic cell degeneration; haemorrhagic and necrotic areas are seldom seen. The portal areas are prominent with large dilated bile ducts. Many

TABLE II.—*Percentage of Labelled Hepatocytes and Bile Duct Epithelium in Sham and Jaundiced Rats*

Duration of jaundice	No. of animals	Per cent cells labelled	
		Hepatocytes	Bile duct epithelium
0 (Sham)	12	0.17	0.5
1	2	0.5	23.7
2	2	2.1	11.1
4	2	4.0	10.4
8	2	1.8	6.0
12	2	1.2	4.6
16	2	0.8	2.1
20	2	0.8	2.9
24	2	0.7	5.0
28	2	0.8	3.2
32	2	1.0	5.8
36	2	1.3	3.8
40	2	0.5	4.2

TABLE III.—*Comparison of Hepatocyte Weight Expressed as a Percentage of Total Body Weight in Sham and Jaundiced Rats*

Days after operation	No. of animals		Hepatocyte weight % of body weight	
	Sham	Jaundiced	Sham	Jaundiced
	1	2	4	5.7
2	2	4	6.6	6.8
4	2	4	6.5	6.7
8	2	4	6.1	6.6
12	2	4	7.4	5.9
16	2	4	5.8	6.0
20	2	4	4.7	5.0
24	2	4	5.6	4.6
28	2	4	5.5	4.4
32	1	1	4.9	3.2
36	1	1	4.4	4.8
40	1	2	5.7	4.3

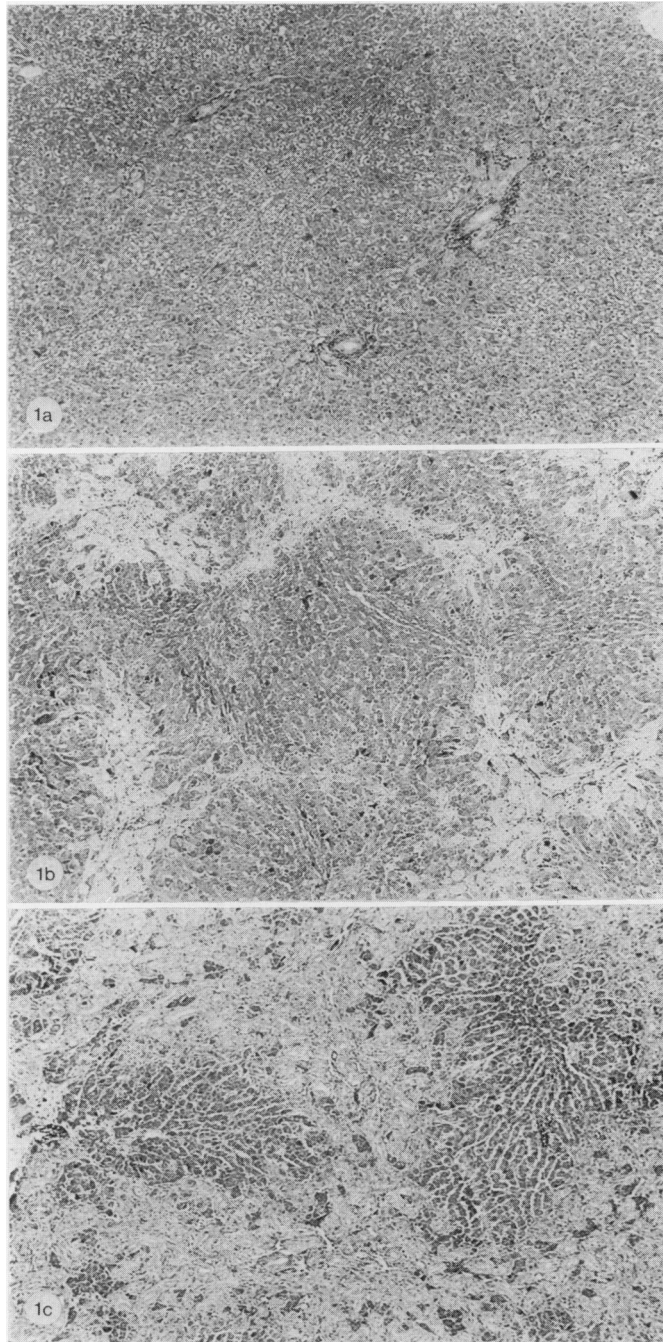


FIG. 1a, b, c.—Sequential changes in rats liver after obstruction of the common bile duct. Masson's trichrome.  $\times 48$ .

(a) After 4 days obstruction showing prominent portal areas.

(b) After 20 days showing bridging of portal areas.

(c) After 40 days showing dense interlobular proliferation of portal tissue with some preservation of the lobular pattern of hepatocellular tissue.

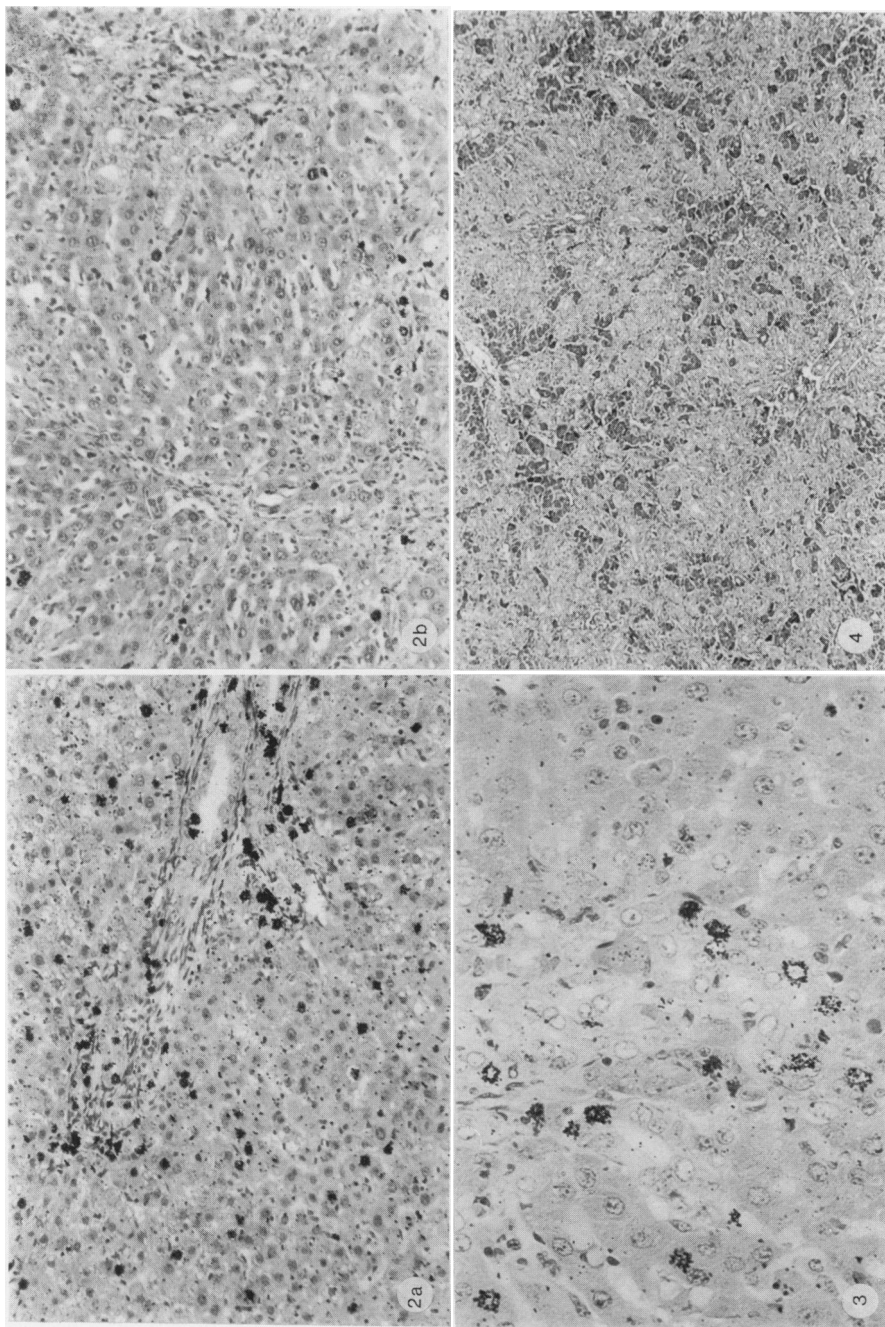


FIG. 2a, b.—Rat liver labelled with tritiated thymidine after obstruction of the common bile duct. H. and E.  $\times 130$ .

(a) After 4 days obstruction showing marked increase in labelling of both bile duct tissue and hepatocytes.

(b) After 20 days showing moderate increase in labelling.

FIG. 3.—Rat's liver after 8 days obstruction showing a border zone between proliferation portal tissue and hepatocytes. Newly formed ducts and pseudo ducts are present. Single bile duct cells lie in the sinusoids. H. and E.  $\times 300$ .

FIG. 4.—Rat's liver after 40 days obstruction showing hepatocytes broken into small islands by interlobular and intralobular spread of biliary tissue. Masson trichrome.  $\times 48$ .

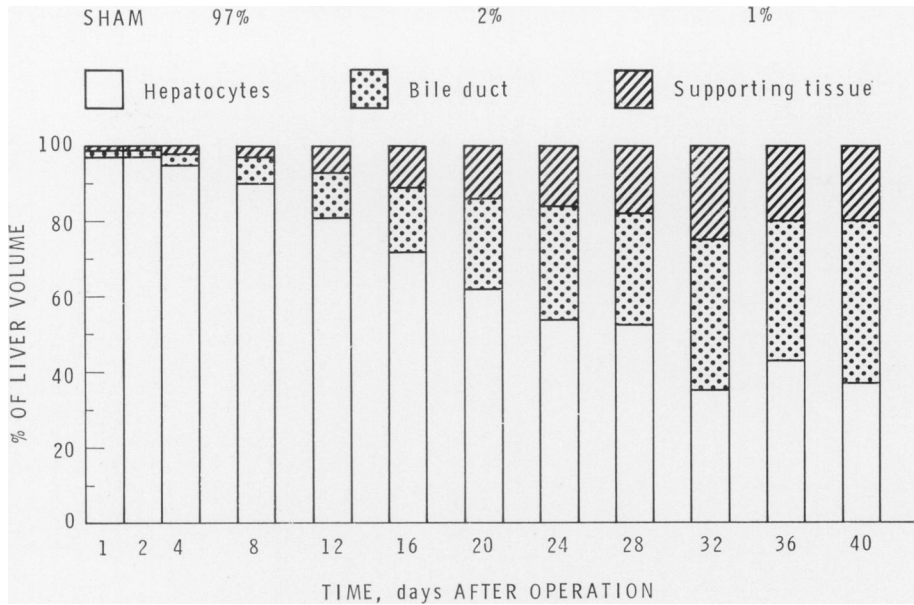


FIG. 5.—Histogram showing changes in volume proportions of components of the liver after obstruction of the common bile duct.

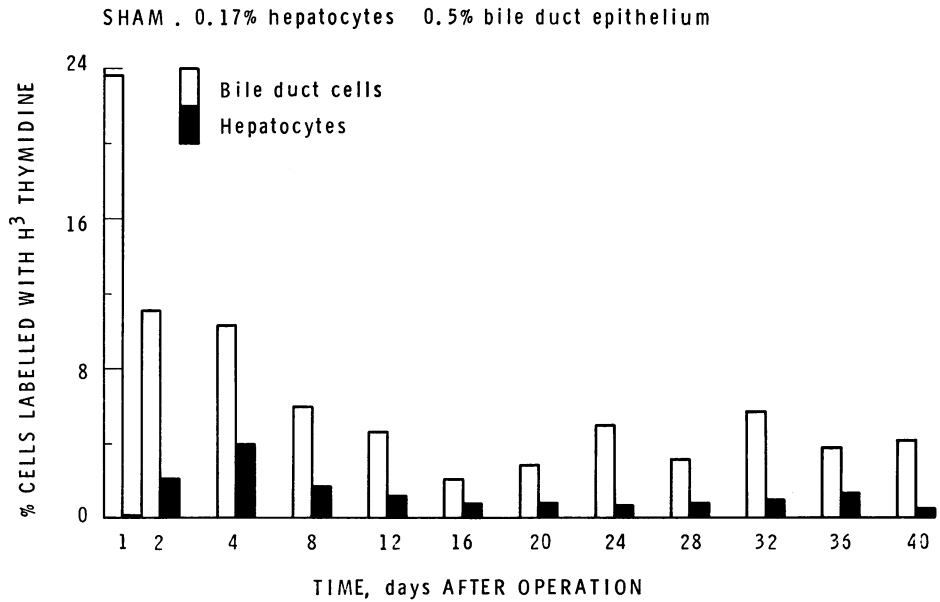


FIG. 6.—Histogram showing the percentage of hepatocytes and bile duct epithelial cell labelled with <sup>3</sup>H-thymidine after obstruction of the common bile duct.

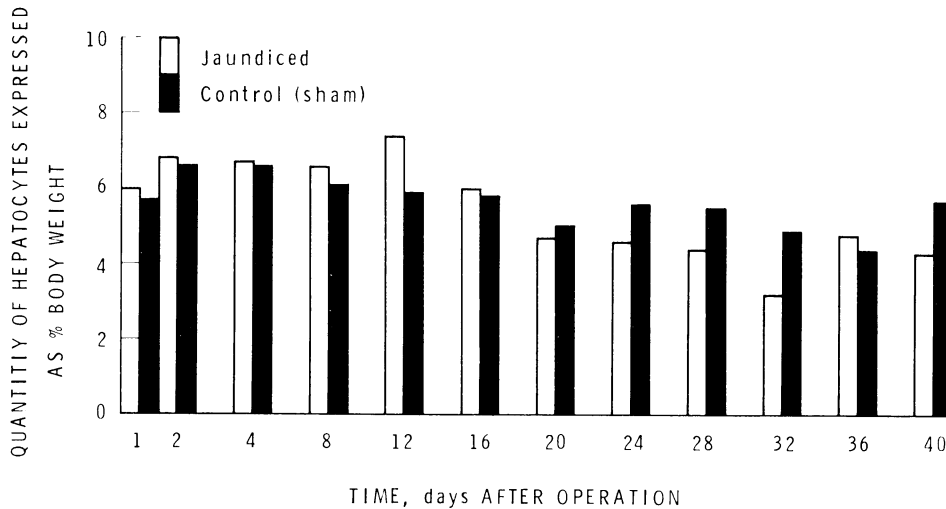


FIG. 7. Histogram showing the quantity of hepatocytes in the liver expressed as a percentage of body weight after obstruction of the common bile duct.

bile duct epithelial cells are labelled or show mitotic figures. The supportive stroma is oedematous and contains many lymphocytes and monocytes but only a few neutrophils. Fibroblastic activity in supportive stroma is increased, and many labelled cells are seen but they are not identifiable.

*Quantitative changes.*—The volume proportion of hepatocytes falls from 97% to 90%, bile duct epithelium is increased from 2% to 7% and the supportive stroma in the portal areas increased from 1% to 3%. The number of labelled hepatocytes is marginally increased to 0.8% after 1 day, rising to a maximum of 4% after 4 days, and falling again at 8 days to 1.8%. Hepatocytes expressed as a percentage of body weight fluctuate between 5.7% and 6.6%.

#### 9–28 days

*Qualitative changes.*—There is progressive enlargement of the liver, the yellow green tinge deepens and the cut surface continues to extrude bile. Some of the hepatocytes are labelled or show mitotic activity but this is less obvious than in the 1–8 day animals. There is further sporadic degeneration of hepatocytes, the

degeneration showing no apparent relationship to the peripheral or central areas of the lobule. Some bile canaliculi are dilated. There are zones of increased cellular activity which are related to strands of encroaching biliary tissue from the portal areas. The spread of portal tissue is both interlobular, with bridging between adjacent areas, and intralobular. There is an enormous increase in small bile ducts which have a tortuous appearance. A moderate number of bile duct epithelial cells are labelled or show mitotic activity, but again this is less obvious than in the 1–8 day animals. Numerous pseudoducts protrude from portal areas into sinusoids and individual bile duct epithelial cells are found just beyond these pseudoducts (Fig. 3). The supportive stroma is less oedematous, the cellular infiltrate consists predominantly of lymphocytes, monocytes and fibroblasts, only a few neutrophils being seen. New collagen is laid down in support of new bile ducts.

*Quantitative changes.*—Between 9 and 24 days the volume proportions of hepatocytes falls from 82 to 54%, epithelium increases from 12 to 13%, and stroma from 7 to 16%. The percentage of labelled hepatocytes shows no tendency

to increase or decrease during this period the results fluctuating between 0.2, and 0.7%.

#### 9-40 days

*Qualitative changes.*—The livers are by now obviously enlarged, firm, finely granular, with pale yellow green discolouration and little or no bile extrudes from the cut surface. The liver parenchyma is further divided by bile duct proliferation and moderate numbers of labelled hepatocytes and mitotic figures are present. Hepatocyte necrosis is more frequent, its distribution is sporadic and not obviously related to lobular architecture. Bile duct canaliculi are much dilated. Biliary tissue encroaches further into hepatocellular tissue in both interlobular and intralobular manner. Labelling and mitoses of biliary epithelial cells appear sporadic, suggesting localized areas of proliferation. Supportive stroma is again limited to new bile duct epithelium, there being no excessive fibrosis. The stroma appears less cellular, with only a few monocytes, occasional neutrophils and some mature fibroblasts.

*Quantitative changes.*—No definite quantitative pattern of change is recorded between 29 and 40 days. There is considerable variation in results between different animals; this variation is not obviously related to the period of jaundice. At 27 and 40 days, the volume proportions of hepatocytes are 52 and 39% respectively, bile duct epithelium 30 and 40%, and stroma 18 and 20%. The percentage of labelled hepatocytes fluctuates between 0.5 and 1.3%, and of labelled bile duct epithelial cells between 4.8 and 3.2%. Liver parenchyma varies between 4.8 and 3.2% of the total body weight.

#### *Sham animals*

The quantitative results in sham rats are as follows: the volume proportion of hepatocytes is 97%, bile duct epithelium 2% and stroma 1%; hepatocyte proliferation is 0.17% (s.d. 0.05), and bile duct

proliferation 0.5% (s.d. 0.12); hepatocyte weight expressed as a percentage of body weight is 5.5% (s.d. 1.8).

#### DISCUSSION

##### *Qualitative changes*

Structural changes in the liver of jaundiced rats were somewhat different from those described by Cameron and Oakley (1932). In animals killed between 1 and 8 days little evidence of focal necrosis, focal haemorrhage or early degenerative change in individual hepatocytes was found. There was minimal evidence of cholangitis, as judged by the small neutrophil infiltration in the portal areas and this may be the result of a low incidence of infection.

##### *Quantitative assessment of volume proportions*

Quantitative assessment confirmed that in the jaundiced animal, after a lag period of 2 days, biliary tissue increased relative to hepatocytes. Between 9 and 28 days, the loss of hepatocytes relative to portal tissue was directly related to the duration of the obstruction. The stroma increased with the bile duct epithelium in a ratio of 1:2 confirming the impression that newly formed stroma was essentially supportive and secondary to new bile duct formation, and that excessive fibrosis does not take place.

Between 29 and 40 days, the proportion of biliary tissue in the liver is less obviously related to the period of jaundice and there is considerable variation between individual animals for the same period. There is an impression that a proportion of hepatocytes in different animals is related to the way in which biliary tissue spreads (Fig. 1c, 4). At one extreme, condensed biliary tissue is predominantly interlobular, the lobules are preserved and there is sparing of hepatocellular tissue. At the other extreme, biliary tissue appears in a diffuse haphazard manner in an intralobular and interlobular position, the architecture of the lobule is totally



disrupted and hepatocytes are broken up into small islands. In any liver, biliary tissue spreads in both ways but one type predominates. There is no evidence of secondary cirrhosis as a result of obstruction. No bursts of hepatocellular proliferation are seen that might suggest regenerative nodules of hepatocytes and biliary stroma continues to increase in direct relation to the bile duct epithelium, there being no excessive fibrosis.

#### *Cell proliferation*

Between 1 and 8 days there is a marked proliferation of both hepatocytes and bile duct epithelium. Labelling of hepatocytes rises to a maximum of 24 times normal, 4 days after operation, whereas labelling of bile duct epithelium rises to a maximum of 50 times normal only 24 h after operation. An increase in the number of labelled cells lying in supportive stroma of portal tissue is obvious one day after operation but quantitation was not attempted because of the difficulty in identifying the cell type.

Between 9 and 40 days, estimates of the percentage of labelled bile cells confirm that proliferation of hepatocytes and bile duct epithelium continues at a greater rate than normal. The rate, however, is less than that seen during the first 8 days of obstruction.

#### *Hepatocyte weight*

It has been particularly difficult to assess the loss of hepatocyte weight as a result of biliary obstruction. It is probable that total hepatocyte weight falls during the period of obstruction but the fall is less than anticipated from the volume proportion of hepatocytes because of overall increase in liver size. Loss of hepatocellular tissue due to cell necrosis is to some extent compensated for by excessive proliferation of viable cells.

The hepatocyte weight has been calculated in both jaundiced and sham animals from the volume proportion of hepatocytes and the total liver weight.

To allow comparison of hepatocyte weight between jaundiced and sham animals, a correction is needed for the different size of each animal and for the increased fluid content in the liver of the jaundiced animal (Cameron and Oakley, 1932). To allow for difference in body weight, hepatocyte weight was expressed as a percentage of total body weight. To reduce the error due to fluid content, each liver was fixed before being weighed.

The mean results of hepatocyte weight expressed as a percentage of body weight in sham and jaundiced animals are remarkably similar, 5.5 and 5.4% respectively. It will be noticed, however, that the hepatocyte weight in jaundiced rats is greater than in the sham rats from Day 1 to 16 and less than in sham rats from Day 20 to 40.

#### *Extension of bile ducts into hepatocellular tissue.*

Between 9 and 28 days, zones of increased cell density are found within the lobules which appear to be extensions of spreading limbs of portal tissue. The appearance is due to an increased number of Küpffer cells, neutrophils, monocytes and fibroblasts in the sinusoids. If a sinusoid is traced back towards the biliary tissue, first individual duct epithelial cells are seen, then aggregates of 2 or 3 duct epithelial cells, and finally newly formed ducts with early periductular collagen deposition. Labelled cells in these zones include mature hepatocytes, individual cells in supportive stroma and mature bile duct epithelial cells, but rarely cells lying within the sinusoids. The impression given is that duct epithelial cells are pushed forward into the sinusoids by division of mature cells lying within formed ducts.

#### *Comparison of changes in rat and human liver*

It is interesting to note changes considered by Gall (1964) to be helpful

in distinguishing between obstructive jaundice, viral hepatitis and alcoholic cirrhosis. Features considered pathognomonic of early biliary obstruction in man were bile lakes, early degeneration of hepatocytes, foamy Küpffer cells, suppurative cholangitis, pyelophlebitis and concentric periductal lamination. In the present study, periductal lamination was seen in the 1-8 day animals and focal hepatocyte degeneration and foamy Küpffer cells in the 9-28 day animals, but there was scant evidence of pyelophlebitis and suppurative cholangitis.

Features which Gall considered suggestive of biliary obstruction, but also seen in viral hepatitis, were dilatation, tortuosity and proliferation of bile ducts, coarse plugs in Küpffer cells, focal necrosis with neutrophil reaction, heavy exudation of neutrophils into portal areas and pseudoductular formation. Of these, changes in bile ducts, pseudoductular formation and coarse plugs in Küpffer cells were seen in the 9-28 day animals but focal necrosis and neutrophil exudation were not obvious at any time.

I wish to thank Dr M. S. Dunnill for his advice and encouragement in preparing this paper, Miss Elena Dresler for preparing material for histology and Miss J. Newberry and Mrs J. Broadis for typing the manuscript.

#### REFERENCES

- CAMERON, G. R. & HASAN, S. M. (1958) Disturbances of Structure and Function in the Liver as the Result of Biliary Obstruction. *J. Path. Bact.*, **75**, 333.
- CAMERON, G. R. & OAKLEY, C. L. (1932) Ligation of the Common Bile Duct. *J. Path. Bact.*, **35**, 769.
- DUNNILL, M. S. (1968) *Recent Advances in Clinical Pathology*. Ed. S. C. Dyke. Series V. Chap. 22, p. 401.
- GALL, E. A. (1964) Hepatic Alterations in Obstructive Jaundice. *Am. J. clin. Path.*, **41**, 126.
- LEE, E. G. (1972) The Effect of Obstructive Jaundice on the Migration of Reticulo-endothelial Cells and Fibroblasts into early Experimental Granulomata. *Br. J. Surg.*, **59**, 875.
- LEE, E. G., ROSS, B. D., & HAINES, J. R. (1972) The Effect of Experimental Bile Duct Obstruction on Critical Biosynthetic Functions of the Liver. *Br. J. Surg.*, **69**, 564.
- STEINER, J. W., Carruthers, J. S. & KALIFAT, S. R. (1962) The Ductular Cell Reaction of Rat Liver in Extrahepatic Cirrhosis I. Proliferated Biliary Epithelial Cells. *Exptl. Molec. Pathol.*, **1**, 162.