

# A CRITICAL REVIEW OF THE CURRENT CONSERVATIVE THERAPIES FOR TENNIS ELBOW (LATERAL EPICONDYLITIS)

LEONARDO VIOLA Dip.(Ost.), Dip.(Acup), Grad.Dip.(Musc.Sc.), M.App.Sc.\*

**Abstract:** The pathogenesis, pathology, natural course, and in particular the treatment of lateral epicondylitis (tennis elbow) remains controversial. An extensive review of the scientific literature with respect to the conservative treatment of tennis elbow, revealed that acceptable epidemiological techniques of the prospective randomised control trials or case controlled studies are scarce. While administration of steroid compounds has traditionally been the mainstay of conservative treatment of tennis elbow, the high recurrence rate of side effects and structural tissue changes associated with steroid therapy, leaves this modality as the most controversial approach in the treatment of tennis elbow. In contrast, in some studies evidence in favour of a role for classical acupuncture, ultrasound and low level laser as effective therapeutic means in the treatment of tennis elbow has been provided. As these modalities have not been associated with any side effects, in view of the ease of application, low cost and good curative effects, their increased application has been suggested by some authors. This proposition, however, remains rather conjectural until it could be convincingly substantiated by future studies with appropriate epidemiological design.

**Key Indexing Terms:** Tennis elbow, conservative therapy, chiropractic, osteopathy.

## INTRODUCTION

The Term "Tennis elbow" was first used over a century ago to describe a painful condition observed in English lawn tennis players (1). As a group, tennis players are at a higher risk to develop lateral epicondylitis (2), and some 40 to 50% of them experience this disabling condition, at least once during their playing lifetime (3-6) and in 33% of the players the pain is severe enough to interfere with their tasks of daily living (4). The syndrome is usually restricted to the dominant arm (2), but the development of bilateral tennis elbow may be due to increased stress placed on the unaffected arm (7).

The word tennis elbow and lateral epicondylitis in this review paper have been used synonymously and they refer to lateral humeral epicondylitis which is a more common

and more serious problem than medial epicondylitis (4,8). In an epidemiological study lateral epicondylitis was reported to be 6 times more common than the medial epicondylitis, and right-sided epicondylitis was found to be twice as common as left-sided epicondylitis (9).

Patients with lateral epicondylitis can be categorised into two groups, a younger group with sport-related injury and an older group with work-related injury or overuse syndrome; the latter is much more difficult to treat (8,10-11). The condition is believed to be primarily a work related syndrome (12). Golfers, carpenters, bricklayers, squash players, violinists, housewives, dentists, surgeons or anyone involved in activities or occupations requiring repetitive rotation of the forearm, or wrist flexion or extensions, are prone to develop lateral epicondylitis (8,13). A similar condition has also been described in computer operators in case reports (14). This was suggested to be related to the use of standard keyboards at nonstandard heights and was reported to be associated with pain, swelling and disability necessitating a week off work.

The incidence of the tennis elbow has been reported in the general population to be 1-3% (7,15-17). Tennis elbow is seldom observed in subjects under the age of 30, and black people are apparently affected less frequently than whites (16). Tennis elbow has been reported to be four times more common in the fourth decade of life (18). The incidence rate has been shown to be similar in both sexes (9). However, in some studies a slight excess in women (19) or in men (20) has been reported.

The results of an epidemiological study in the general population showed a prevalence for tennis elbow of 1% in men and 4% in women for the population aged between 20 and 80, with the condition rare outside this age group. The prevalence of tennis elbow in women between 40 and 50 years of age was 10% (21). Cases of tennis elbow have been shown to increase with age in both men and women. This increase is most evident after the age of 40 when a 4-fold increase in prevalence among men and a nearly 2-fold increase among women is observed (3).

A recent estimate by the US department of the Interior indicates that, in the USA alone, more than 40 million people currently play tennis (13), half of whom are likely to suffer from the affliction known as "tennis elbow" (3). In general practice, however, only 5% of the cases are

\* Private Practice  
83 Marion Street, Leichhardt, N.S.W.. AUSTRALIA. 2040. Tel/Fax: (02) 9560-4597

## TENNIS ELBOW AND CONSERVATIVE THERAPY

### VIOLA

related to actual tennis playing (16,18). For this reason, some authors prefer to call the syndrome "epicondylalgia lateralis humeri" (22). In fact, most cases of this common condition are caused by occupational stress rather than racket sports (23). In continental Europe, the name lateral epicondylitis is often used for this condition, while in the English speaking Countries the condition is usually referred to as tennis elbow (21).

Chronic lateral epicondylitis is probably the most common problem treated in the orthopaedic office (24). Although the conservative treatment of this disabling condition has been the subject of a number of clinical studies, there is no unanimous agreement as to the most effective therapy in the management of tennis elbow.

Tennis elbow can produce a long-lasting and severe medical condition (24,25) and may lead to economic consequences such as sick leave, workers compensation claims, transfer to lower-paid jobs, and even early retirement (12).

The treatment of tennis elbow is often a frustrating experience for the clinicians due to the frequent failure of obtaining a symptomatic improvement in the patient. This failure is equally apparent in both conservatively and surgically treated patients. Therefore, the management of tennis elbow both at early and late stages has been suggested to be primarily a conservative approach (25). It is, therefore, important to substantiate an effective, non-invasive, conservative therapy for this disabling affliction.

Despite the fact that tennis elbow was first described more than 100 years ago, there remains considerable uncertainty and controversy regarding the pathogenesis, pathology, natural course and, in particular, treatment of this condition (26). This review article intends to provide an overview of current concepts in different aspects of this disabling condition, to critically evaluate the major therapeutic modalities in conservative management of tennis elbow and to assess the scientific validity of the clinical studies undertaken in this regard.

### ETIOLOGY

Controversy as to the exact etiology of the lesion on the lateral aspect of the elbow has continued through the past century (1). The onset of symptoms may be preceded by overexertion of the wrist extensor muscle due to repetitive gripping and twisting motion, which are beyond the adaptive capacity of the tissue (27). Cyriax has reported that these forceful contractions will result in irritation and partial tears of the involved musculature (28).

Although there is no unanimous agreement on the site of tissue degeneration, Cyriax has hypothesised that the site

of maximal tenderness is the site of injury and muscle ruptures most easily at its attachment to the bone rather than at the musculotendinous junction or the muscle belly (28). Conversely, it is suggested that muscular damage always occurs at the musculotendinous junction (29).

On the other hand, it is difficult to determine whether the extensor muscle origin or the annular ligament is responsible for the symptoms, as they are firmly attached to each other (30).

A comprehensive study conducted by Goldie found a degenerative tear of the attachment of the extensor carpi radialis brevis to the distal aspect of the lateral epicondyle to be the primary cause of tennis elbow (31). Recent studies have also provided supporting evidence in favour of these observations (18,32).

Although the etiology of tennis elbow is unclear, the primary factor is most likely to be a mechanical predisposition of the elbow associated with a force overload (33). Cabot believes that acute lateral epicondylitis has an inflammatory basis involving parts or all of the extensor tendon aponeurosis (24). Chronic lateral epicondylitis, however, is caused not only by the inflammation in the extensor tendons but also by contracture of the anterolateral elbow capsule (24).

As stated earlier, tennis elbow rarely occurs before the age of 30 (7), and most cases of tennis elbow begin to appear in middle thirties (6). Although, the reason for the peak incidence rate in mid-life group is a matter of conjecture (9), the observations that alterations in collagen content, lipid and ground substance of enthesis occur at this age (6) has led to the suggestion that a degenerative process occurs in the tendons and their insertions into bones making them prone to injury when stressed (4). However, pathological studies have failed to demonstrate any anatomical evidence of age-related degeneration among the people aged 11 to 60 at postmortem examination. It is possible that the change is physiological and tendons lose their elasticity with increasing age.

At present, the greater weight of evidence would indicate that lateral epicondylitis is the result of repetitive stress on certain muscles and tendons resulting in mucinoid degeneration and reactive granulation of the extensor carpi radialis brevis (1,34). Movements such as excessive pronation and supination of forearm with the wrist extended have been implicated as the cause of microtears and subsequent mucinoid degeneration of the tendinous origin and reactive granulation tissue in that space (33). The resulting granulated tissue contains large number of free nerve endings, and these may be largely responsible for the pain (33).

## **PATHOPHYSIOLOGY**

Considerable confusion concerning the pathoanatomy of tennis elbow has existed since the introduction of the term in the late 1880s (32). In 1936, it was hypothesised that the extensor brevis is the determinant anatomical site involved in tennis elbow (28). In 1973, evidence of pathological changes in tissues was presented. However, the anatomical site of these alterations was not clearly specified (18). The histological evidence of pathological changes in extensor carpi radialis brevis was first presented by the study of Nirschl and Pettrone (35). These initial observations have been confirmed by extensive studies in which the pathoanatomy of tennis elbow has been defined as an angiofibroblastic tendinosis in the lateral tennis elbow tendinosis (32).

Histopathologic examination of samples obtained from patients with chronic refractory lateral epicondylitis showed vascular proliferation and focal hyaline degeneration which is consistent with a degenerative rather than an inflammatory process (36). This may account for the lack of response to rest and anti-inflammatory medication. However, the possibility exists that the cortisone injection may have contributed to the microscopic feature of chronic refractory lateral epicondylitis as reported by authors. Furthermore, the interpretation of these findings does not allow a plausible explanation of the cause of the pain in this condition.

Histologic examination of the bone-tendon junction in patients with tennis elbow has shown evidence of a repair response of variable degree, the most frequent feature being mucopolysaccharide infiltration and bone formation. Fibrofatty degenerative changes were also present in some cases. However, there was no correlation between the intensity of the histologic reaction and the clinical outcome (37). It would seem that macroscopic tears and gross degenerative changes are present only in some cases of tennis elbow and may be a reflection of patient selection or referral methods (37).

## **SYMPTOMS AND SIGNS**

Lateral epicondylitis is characterised by painful inflammation of the common extensor tendon at the outer region of the elbow (6).

The condition may be gradual or acute in onset. The gradual type reaches a peak of pain 24 to 72 hours after activity and the patient may give a history of unaccustomed repetitive rotary movement of the hand and wrist frequently related to sports or work (4,10). In acute type, the patient can usually describe the exact time and condition at which the pain occurred. Although no explanation in the literature relates the underlying pathology to the mode of

onset, it is hypothesised that acute type may be related to moderate to major tear at the junction of tendon and bone, whereas those with gradual onset may have suffered from a microtear in the same region (4).

Patients with active lateral epicondylitis have tenderness over the lateral epicondyle of the elbow or over the origin of the extensor carpi radialis brevis (10,16,25). The pain is described as a "burning" pain, is of often radiating to the forearm (1) and is usually increased in response to extension of the elbow, by gripping, heavy lifting and simple tasks of daily life (12,38). Although articular and neurological signs are normal, grip strength may be decreased (16,34). Eventually, even shaking hands, picking up a milk carton, or carrying a briefcase may cause severe pain around the epicondyle (34). In severe cases, pain may occur at rest and is associated with reduced movement at the extremes of flexion and extension (16). Increased tenderness may be the result of repeated micro trauma causing inflammatory condition of the periosteum with granulation of tissue that contains large number of free nerve endings (16).

On clinical examination there are three important physical signs (a) tenderness to palpation at the anterior aspect of the lateral epicondyle (b) pain on passive stretching at the wrist with the elbow held in extension and the forearm prone (c) pain on resisted extension of the wrist while the elbow held in extension and the forearm prone (8).

## **DIAGNOSIS**

Although it is suggested that the diagnosis of tennis elbow is straight forward (10), others believe that an unreliable or pathognomonic sign exists (23). Clinical features do show some variability both with regard to the site of tenderness and degree of involvement of supination and pronation. Although these differences may have pathological significance, they do not appear to have prognostic importance (7).

Tennis elbow may be diagnosed based on the patients history and clinical examination. The onset of pain can be sudden or gradual and is usually localised to the lateral epicondyle of the elbow with possible distal or proximal radiation. Pain usually radiates down the forearms and up to the shoulder (39). Often, the tennis player complains of a weak grasp or increased pain on backhand shots (6).

Increased density and tenderness at the site of the common extensor tendon should be elicited on palpation of the lateral epicondyle (6), or at its close proximity [2.5-5 cm distally or on both sides (23)]. Usually, flexion and extension of the elbow are complete, but in some cases of chronic tennis elbow, the patient lacks 5 to 15 degrees of wrist extension (7,34).

## TENNIS ELBOW AND CONSERVATIVE THERAPY VIOLA

Examination by needle palpation indicates that, in most cases, the specific location of the pain is in the tenoperiosteal origin of the extensor carpi radialis brevis (ECRB)(22). In chronic tennis elbow measurable muscle atrophy may also be noted (7,34).

Resistance test of wrist extension and forearm supination will often increase the pain. One of the most reliable diagnostic tests is to extend the middle finger on the affected site against resistance. This action strains the ECRB which inserts at the base of the third metacarpal (6,10).

The "coffee cup" sign is a description in which patient will develop pain at the lateral epicondyle when he/she picks up a full cup of coffee (40). It is suggested that a heavy book (approximately 3kg in weight) can be useful both for diagnosis and for education of patient, on how to lift the objects (23). When the book is held with elbow flexed and adducted, the patient with tennis elbow does not experience any pain. However, grasping the book while the forearm is pronated causes immediate pain in the elbow, promptly followed by elbow adduction allowing the book to dip below the head of the radius.

Radiographic studies are of little assistance in the diagnosis of tennis elbow (1). However, infrared thermography of the affected elbow reveals a discrete localised area of increased heat near the lateral epicondyle in 98% of cases. Additionally, analysis of the gradient across the abnormal area shows correlation with the clinical severity (7). Despite this diagnostic benefit, thermography has little therapeutic or prognostic significance (4).

Similarly, magnetic resonance imaging (MRI) is very effective in eliciting the morphological and chemical causes of musculoskeletal injury (4). MRI in patients with chronic tennis elbow has shown an increased signal intensity of the anconeus muscle (41). Although this may indicate the involvement of the muscle, it does not provide conclusive evidence as to whether this increased signal intensity contributes to the chronicity of patient symptomatology or is associated with abnormal elbow motion because of the symptoms.

Ultrasonographic examination has also been suggested as a useful means in confirmation of diagnosis (42). Ultrasound examination at and around the lateral humeral epicondyle reveals enlargement of the proximal part of the tendon as well as the thickening of the peritendoneous lining. Intramuscular haematoma and bursitis could also be identified.

### DIFFERENTIAL DIAGNOSIS

Some of the most significant conditions to be considered in differential diagnosis of lateral epicondylitis include:

Degenerative arthritis of the elbow joint. The pain in this condition is often more diffused and not localised to the lateral aspect of the elbow. Loss of extension is the most common complaint and stiffness may be the dominant feature (43).

Tennis elbow is not usually associated with visible swelling. Therefore, presence of this sign may be an indicator of arthritis synovitis, infection, trauma or tumour (23).

To eliminate the possibility of arthritic changes at the radiohumeral articulation or tumour of the supinator muscle, radiography could be diagnostic (2).

Cervical osteoarthritis and cervical nerve root compression (C6-7) may also cause lateral elbow pain that mimics lateral tennis elbow (32). This condition, however, is presented with painful restriction of neck motion and absence of point tenderness (40).

It is often difficult to differentiate between simple lateral epicondylitis due to local inflammation and trauma and the early stage of radial tunnel syndrome as a result of radial nerve compression. Radial tunnel syndrome is often associated with radial paresthesia, radial paresis, and popping sensations (44). Conversely, numbness or paresthesias in the affected arm is not commonly associated with lateral epicondylitis (45). Figure 1 (46) illustrates the Arcade of Frohse.

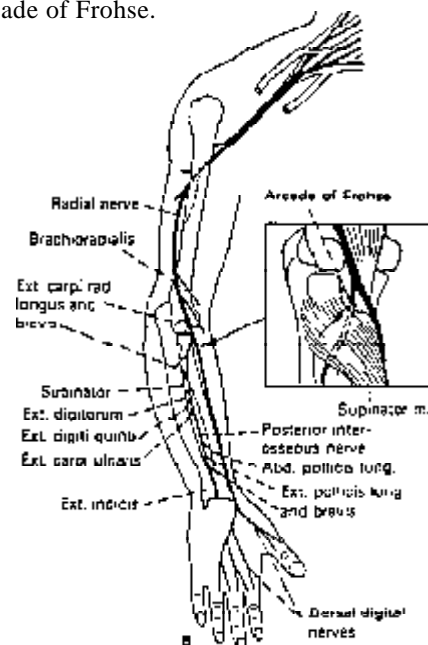


Fig 1- Entrapment syndromes of the radial nerve. The condition can involve the posterior interosseous nerve after it enters the supinator muscle under the arcade of Frohse, where it can be compressed by hypertrophied muscle or tumors, ganglia or synovitis.(46)

Adapted from Loeser (1990).

In radial tunnel syndrome, tenderness to palpation is most severe over the radial nerve palpated through the mobile muscle mass at and just distal to the radial head (25,44, 45, 47, 48). In contrast, in lateral epicondylitis the maximal tenderness is located within 1-2 centimetres of the lateral epicondyle (48) and pain on resisted extension of the wrist is considered as a true indicator of tennis elbow (27).

The role of posterior interosseous nerve entrapment (PIN) in tennis elbow is the subject of debate and controversy (49). This may be, at least in part, due to the fact that no electromyographical evidence for PIN compression in resistant tennis elbow has been found (50). Nerve conduction velocity studies are very reliable and the diagnosis of radial or posterior interosseous entrapment should not be made without a positive electrodiagnostic abnormality (4).

### CONSERVATIVE THERAPY

Prompt treatment of tennis elbow in acute case is critical and appears to have a better prognosis. Conversely, the longer the patient has had tennis elbow the more difficult the treatment (10).

Conservative management of tennis elbow includes: relief of pain, cessation of bleeding, control of inflammation, promotion of healing, rehabilitation and prevention of recurrence (4,10).

Ice and rest, supplemented by anti-inflammatory agents where necessary best reduce inflammation. Although ice is helpful in reducing pain when applied to an elbow at rest, during athletic activity the elbow should be kept warm (10). Ice is more soothing after the arm has been used and will help diminish swelling and inflammation whereas heat is very useful prior to activity (11).

In a retrospective study it was found that there is an inverse relationship between the treatment success and the duration of pain (13). Additionally, the degree of pain prior to treatment was found to be the most important predictor of complete recovery; the greater the pain the more likely the complete success of the treatments. Recurrence rate, six months to 19 months following treatment has been reported from 18% (51) to 29% (13), and in some circumstances up to 66%, (52). A retrospective epidemiological study has also found a recurrence rate of 24% (3). The majority of these recurrences will be in patients, who have not been fully rehabilitated prior to the return to full activity or in patients who have discontinued the prevention protocol. Many of the recurrent cases can be managed in a fashion similar to the primary cases, but a large percentage of these will be recalcitrant and require surgery. If a patient is able to continue with the preventive

protocol before actively engaging in a sporting activity, he or she can expect to have a relatively normal extremity for purpose of the sport (34).

### STEROID INJECTIONS

Injection of steroid preparation into the tender area around the elbow has been one of the commonly used approaches in treatment of tennis elbow (4). However, it is also the most controversial approach in treatment of lateral epicondylitis (1). While some authors claim that injection of a steroid preparation into the area of maximal tenderness can be the definitive treatment for the condition (51), critics believe that steroid injection, while efficient, has a recurrence rate as high as 50% (40,53) to 66%, six months after treatment (52). Moreover, it has been shown that treatment with an oral anti-inflammatory agent is as effective as steroid injection (38). Similarly, acupuncture treatment has shown to be more effective than steroid (54) and the great majority of the patients whose symptoms were not alleviated with steroid injection were treated effectively with other modalities such as deep frictions, ultrasound therapy and manipulation (55). However, the authors did not provide any information as to how these alternative methods were applied and their efficacy was evaluated.

It has been shown that recurrence of severe symptoms occurs almost exclusively in the patients treated with steroid injection (53). The lower recurrence rate, however, observed in ultrasound responsive patients which may reflect a true enhancement of healing.

Corticosteroid injection for the patients with disabling pain at initial presentation or in resistant tennis elbow may be useful. To avoid skin atrophy, it is recommended that a combination of crystalline steroid and local anaesthetic can be administered with a 25 gauge needle at the lateral epicondyle and in several other sites up to one inch distal to the epicondyle (23). The use of corticosteroids and anaesthetics into soft tissue, however, is thought by some authors to be risky, not uniformly effective and has been noted at surgery to leave a possible irritating chalky residues in the tissues of the elbow (10). Similarly, subcutaneous fat atrophy, skin pigmentation, tendon rupture, cartilage damage and infection have been reported as some of the most frequent side effects associated with steroid injections (56,57).

### ACUPUNCTURE

The ability of acupuncture to reduce pain is well known. The analgesic effect of acupuncture can be attributed partly to the release of b-endorphins in the lumbar spine (58,59) and increased 5-Hydroxy tryptophan level in the cerebrum (60).

## TENNIS ELBOW AND CONSERVATIVE THERAPY

### VIOLA

Studies with experimental animals have revealed that analgesic function of acupuncture derives from the clashing of the biochemical lines of acupuncture and those of the pain stimulus in the transmitting process of the central nervous system, the former override the latter. Researchers in Shanghai Institute of Physiology as cited by O'Connor and Bensky (61) have shown that when tiny electrodes were planted in single cells of animal's spinal cord or thalamus, the electrical response in the cell were diminished or disappeared following a strong pain stimulation. Therefore, the ability of acupuncture to suppress pain and anesthetize is thought to be derived from the capacity of the non-pain signals to override the pain signals (61). Similarly, it has been suggested that acupuncture has an effect on the structures of the brain stem and the limbic system of the cerebrum. It stimulates the sympathetic nerve centres of the hypothalamus and the sympathetic nerves mediate its functions. Furthermore, acupuncture effects are transmitted through the chemicals in the body fluids (61).

Another explanation for the effect of acupuncture is the traditional Chinese belief of "energy flows" or Qi through body channels. Qi moves blood and other body fluids throughout the body. When there is a blockage to this energy flow, or a reduction of Qi, dysfunction and pain will result.

For a patient presenting with pain, the acupuncturist initially does not need to be concerned with the etiologic factor of the condition. However, after symptomatic relief of pain, traditional acupuncture will also be applied to treat the cause of the pain.

Studies on clinical acupuncture trials in the treatment of tennis elbow are rare. Limited studies in the literature, as will be discussed later in this article, however have reported promising results. It was found the acupuncture to be an effective form of therapy for tennis elbow which was not associated with any side effects (54). The author utilised acupuncture as a therapeutic means in 37 patients (26 males, 11 females) of whom 70% had previously been given one or more steroid injection without showing any improvement. Additionally, a group of 26 patients (14 males and 12 females), that had not received any steroid injections prior to the study, were recruited as the control group and were treated with steroid injections. Sixty two percent of patients who had had pain more than six months, after acupuncture therapy were either pain free or felt much better on follow-up. However, the corresponding value for the control group was only 18%. Interestingly, none of the patients who underwent acupuncture reported worsening of the condition, whereas steroid injection worsened the condition of 4 patients in the control group, 3-6 or 6-12 months post treatment. Similar conclusions have been reached by other studies in

which acupuncture was considered as a simple and effective approach in the treatment of tennis elbow (62-64).

Furthermore, other workers have shown that not only acupuncture therapy for tennis elbow is not associated with any side effects, but also the preduration of pain had no correlation with the treatment outcome, suggesting that acupuncture could be utilised in both acute and chronic tennis elbow (65). Similar views have been expressed by other authors (66). Molsberger and Hille (66) in their well designed placebo control study, which is probably the most reliable study in English literature, have demonstrated an intrinsic analgesic effect of acupuncture in the clinical treatment of tennis elbow pain which exceeds that of placebo. They recruited forty eight patients, all volunteers, in the trial after satisfying the following criteria: chronic unilateral pain for more than 2 months, no current therapy involving pain killers, no systemic bone and joint disorders, no previous treatment with acupuncture, no overt psychiatric illness and the ability to speak, write and read German. Patients were randomly allocated to either the verum (n=24) or placebo groups (n=24). Both groups were comparable as far as important parameters such as age, sex, duration of illness, intensity of pain and attitude towards acupuncture were concerned. Patients of the verum group were treated at a non-segmental distal point on the fibulotibial joint of the homolateral leg. However, as needling the patient at any point is known to raise the b-endorphin levels, the authors refrained from inserting a needle in any patients in the placebo group. Only patients' back was stimulated with a pencil-like probe, the injection of a needle thus being feigned. Prior to treatment, an independent unbiased examiner (not the acupuncturist) assessed the patient's condition physically and assisted the patients in evaluating their personal pain level and the data were recorded in a questionnaire containing 11-point box scales. After treatment, an independent examiner who did not know whether the patient had been treated with verum or placebo acupuncture, again evaluated their personal pain level by physical examination and the degree of pain was recorded on the same scale. Furthermore, the duration of pain relief was evaluated by following the patients up for 72 hours. The study was designed in such a way that as soon as significantly different result between two groups with a type I error risk of less than 0.01 were obtained, to be stopped (sequential analysis). A rate of at least 50% pain relief, was considered as being successful. Seventy nine percent of verum group met this criteria. However, the corresponding value for placebo group was only 25% and the difference was statistically significant ( $p < 0.01$ ).

Similarly, the average duration of pain relief in verum group was 20.2 hours, whereas, that of placebo group was only 1.4 hours and the difference was statistically significant ( $p < 0.01$ ). Interestingly, immediate pain relief was 10% higher for patients with a positive attitude towards acupuncture (although not statistically significant). Although the patients entered the trial voluntarily thus the sample was self-selected, the authors suggest that the trial it could be considered representative because characteristic sample parameters of the trial match the parameters of the condition of tennis elbow as published by others (38).

Table 1 summarises the outcome of different clinical studies in which acupuncture has been utilised as a therapeutic means.

### ULTRASOUND

Ultrasound has become an accepted modality in the treatment of a athletic injury during the last 3 to 4 decades. Its use continues to become more judicious as we learn more about the healing process and the effect of ultrasound in that process (67).

Ultrasound therapy involves a series of electrical and mechanical phenomena that cause thermal and mechanical effect on cells at both superficial and deep level. Ultrasound falls under the classification of the acoustic spectrum. It is used as deep heating tissues modality, because it can reach a depth of 5cm or more. In general, the effect of ultrasound on tissue is thermal. Therefore, when a tissue is heated a number of changes are expected (67). These changes are shown in the following table.

Table 2: Thermal effects of ultrasound on tissues

- 1) increase extensibility of collagen tissue
- 2) decrease joint stiffness
- 3) increase pain threshold
- 4) reduce muscle spasm
- 5) assist in mobilising inflammatory infiltrates, oedema and exudates
- 6) increase blood flow
- 7) increase local metabolism
- 8) increase nerve conduction velocity

The effects of ultrasound in the treatment of tennis elbow have also been investigated in a few studies (19, 68-72). These studies (except that of 68) have generally provided evidence to show that ultrasound is also an effective therapeutic modality in the treatment of tennis elbow. However, the possibility that this therapeutic effect is superior to that of a placebo effect remains uncertain.

The results of different studies on the role of ultrasound in treatment of tennis elbow are shown in Table 3.

### LASER

Laser is an acronym for light amplification by stimulated emission of radiation. Because the production of laser is a relatively new field, the biologic and physiologic effects of the concentrated light energy are still under

Table 1: The effect of acupuncture in the treatment of tennis elbow.

Authors	Sample size	Method of treatment	Conclusion	Quality of Paper
Brattberg 1983 (54)	63	Acupuncture vs steroid injection	A higher success rate (62%) was observed for acupuncture compared to steroid injection (18%) on completion of the treatment and on follow-up to 1 year	Poor – variables not operationalised, selection bias, non-probability sample, poor internal validity lack of control for confounding variables, the possibility of type 1 error
Liping and Xuan 1988 (62)	58	Application of acupuncture to tennis elbow patient	92%, excellent results six months post treatment	Poor – absence of control group for statistical comparison, lack of information and inclusion or exclusion criteria, inappropriate design (quasi experimental design, lacking both randomisation and comparison groups) – selection bias, lack of control for potential confounders
Zhongying 1989 (64)	52	Application of acupuncture to tennis elbow patient	84.6% effectiveness (complete or marked relief of pain)	Poor – similar limitations as referred to the Liping and Xuan, 1988
Haker and Lundberg 1990 (65)	82	Classical acupuncture vs superficial needle insertion	Classical acupuncture was shown to be superior to superficial needle insertion in short symptomatic treatment of tennis elbow	Poor – lack of stratification, possibility of type 1 error, selection bias, lack of control for possible interaction
Molsberger and Hille 1994 (66)	48	Active acupuncture vs placebo acupuncture	Active acupuncture was significantly more effective ( $p < 0.01$ ) than placebo acupuncture	Good-limitations; independent variable was not operationalised, possibility of volunteer bias

## TENNIS ELBOW AND CONSERVATIVE THERAPY

VIOLA

Table 3: The effect of ultrasound in the treatment of tennis elbow.

Authors	Sample size	Method of treatment	Conclusion	Quality of the paper
Sinclair, 1965 (71)	75	Ultrasound, diathermy and manipulation vs steroid injection	51.4% recovery rate for ultrasound 84.6% for combining ultra-sound and diathermy and 91% for steroid injection	Poor – no stratification no statistical analysis, no follow-up
Binder et al 1985 (19)	76	Application of ultrasound vs placebo ultrasound	Ultrasound significantly ( $p < 0.01$ ) more efficient than placebo after treatment and at one year follow-up	Poor – no stratification, selection bias due to prior treatment with steroid, no control for potential confounders, no analysis on the possibility of type I error
Halle et al 1986 (69)	48	Placebo ultrasound vs ultrasound plus phonophoresis vs transcutaneous electrical nerve stimulation vs steroid injection	No significant difference ( $p < 0.05$ ) among groups	Poor – no stratification, small sample size selection bias, no analysis on the role of potential confounders, high possibility of type II error (in particular due to a small sample size), no follow-up
Lundberg et al 1988 (70)	99	Continuous ultrasound vs placebo ultrasound vs rest	Continuous and placebo ultrasound significantly ( $p < 0.01$ ) better than rest	Poor – no stratification, small sample size, no power analysis for estimation the possibility of type II error, no analysis for the role of potential confounders, selection bias.
Stratford et al 1989 (72)	40	Ultrasound and placebo ointments vs ultrasound and placebo ointment and friction vs phonophoresis vs phonophoresis with friction	No significant difference among groups ( $p < 0.05$ )	Excellent stratified randomised double blind controlled trial, adequate analysis for the role of confounders, power analysis for rejection the possibility of type II error limitation; no long term follow-up, small sample size (however the power analysis convincingly excluded the possibility that the findings may have been affected by small sample size)
Haker and Lundberg 1991 (68)	45	Pulsed ultrasound vs placebo	No significant difference	Poor – no stratification, however the two groups were similar in terms of important variables. A double blind randomised controlled study, small sample size, no power analysis for estimation the possibility of a type II error

investigation. The proposed physiologic effects of lasers include acceleration of collagen synthesis, increase in vascularisation, and reduction of pain and inflammation. The effects of low power laser are subtle, primarily occurring at a cellular level (73).

Some authors (68,74-75) have investigated the therapeutic benefits of laser in the treatment of tennis elbow. Although these studies have failed to find a significant effect of laser to be superior to that of placebo effect, these findings could not necessarily be accepted unequivocally because these studies are subject to serious methodological limitations. Lundberg et al, (75) in a double blind controlled study randomly allocated 57 patients with a history of at least, three months duration of pain in three groups. Group A (n=19) received placebo laser treatment. Group B (n=19) received infrared Gallium-Arsenide (Ga-As) pulsed laser radiation. Group C (n=19) received Helium-Neon (He-Ne) continuous laser radiation. The treatments were given over five to six weeks (two per week). The pain alleviating effects and therapeutic benefit of laser treatment were assessed, prior to and immediately after and on three months follow-up, by both standard pain scale and also by physical examination of patients in conjunction with weight test and grip strength test using a dynamometre. The rate of satisfactory outcome on objective testing both

at the end of treatment and during further follow-up in three groups was similar and did not show any statistically significant difference. Additionally, re-examination of the patients or assessing a postal questionnaire (completed by patients) at six months, revealed no difference in incidence of recurrence of severe pain among groups. The authors concluded that laser radiation is not superior to placebo on treatment of tennis elbow.

Although the authors claimed that the three treatment groups showed no significant difference in the main severity of any of the clinical variables on presentation, they did not provide sufficient information as to how they selected the subjects. Moreover, the patients were not stratified according to major and significant variables. Therefore, the possibility that selection and admission rate bias might have occurred could not be excluded. The possible role of potential confounders such as age, sex and interaction has not been discussed. Similarly, they did not specify what randomisation process they employed. More importantly, no power analysis was performed (particularly given the small sample size in the study) to ascertain to which extent their findings might have been affected by the sample size (Type II error). Another important issue with Lundberg et al, study (75) is the fact that they stated that the aim of their study was to investigate



Table 4: The effect of laser in the treatment of tennis elbow.

Authors	Sample size	Method of treatment	Conclusion	Quality of paper
Lundberg et al 1987 (75)	57	Pulsed laser vs placebo laser vs continuous laser on acupuncture point	No significant difference among groups	Poor – lack of stratification according to variables, the possibility of selection and admission rate bias, no power analysis, and thus the possibility of type 11 error
Haker and Lundberg 1990 (74)	49	Pulsed laser vs placebo laser on acupuncture point	No significant difference between groups	Similar methodological limitations to the above study
Haker and Lundberg 1991 (68)	60	Combination of pulsed and continuous laser vs placebo laser irradiated on area over the epicondyle as well as to the acupuncture points	No significant difference between groups	Similar methodological limitations to the above studies. Moreover, a large number of cases were lost from the study that were not accounted for. This introduce an additional possible source of bias
Vasseljen et al 1992 (76)	30	Active laser vs placebo laser	A significant improvement in the laser compared to the placebo on analog scale (p=0.02) and on grip strength test (p=0.03) four weeks after treatment	Good – a block-design controlled randomised double blind study limitations: 1) sample size was small 2) the irradiated area on the elbow was not clearly specified 3) the possibility of type 1 error could not be rejected although not discussed by authors

the effects of placebo versus laser on treatment of tennis elbow. However, in their experimental trial they irradiated the acupuncture points rather than the area affected by pain. One might argue that the design of the study was not appropriate to adequately answer the research question because it is possible that laser would be more effective if radiated on the painful area rather than the acupuncture point. In line with this proposition, the same authors in an unpublished observation, as cited in their 1991 paper, noticed that when the painful area is radiated, a significant difference between placebo and laser regarding the objective outcome favouring the laser treatment is found.

The authors in two additional studies (68,74) with similar designs (and thus similar methodological limitations) to that of Lundberg et al, (75) did not find any statistically significant difference between the laser group and the placebo group with respect to the subjective and objective outcome after 10 treatment or at the follow-up of 3 months and one year. Unlike their previous study (75), the design of this study (although generally poor) was, however, adequate to answer their research question.

The study of Vasseljen et al, (76) is probably the most reliable clinical study on the effect of laser radiation in treatment of tennis elbow. The authors in a block-design, double-blind, randomised controlled study assigned thirty patients equally to a laser (n=15) or placebo laser (n=15) group. The patients received eight treatments and were evaluated subjectively (by a visual analog scale) and objectively (by vigorimetry, weight test and goniometric measurements of wrist flexion) before, at the end of, and four weeks after treatment. The patients were also requested to complete a follow-up questionnaire on an average of five to six months after treatment. The authors reported a significant improvement in the laser compared to the placebo group both on visual analog scale (p=0.02)

and on grip strength (p=0.03) tests four weeks after treatment. Similarly, a tendency towards a better outcome in the laser compared to the placebo group also at five to six months follow-up was noted.

The results of different studies on application of laser in the treatment of tennis elbow are summarised in Table 4.

#### FRICITION MASSAGE

Transverse friction massage has been claimed to be helpful in rehabilitation of tennis elbow via mobilisation of soft tissue and possibly release or stretch any scar tissue impairing normal movement (77). However, animal studies have shown that deep transverse frictions do not promote repair of sprained ligaments. Similarly, histological features of treated and untreated sprained ligaments have been shown by Walker (78) to be similar. The author in his experiments, manually sprained the right knees of 18 rabbits; left knees served as controls. Deep transverse frictions were given five times to six animals; ten times to six animals. It was not possible on stained tissue sections to distinguish (p>0.05) either between sprained or unsprained ligaments, or between treated and untreated sprained ligaments. The author concluded that these findings does not support the hypothesis that deep transverse friction promote repair of sprained ligaments.

The possible therapeutic effects of this modality in the treatment of tennis elbow, therefore, awaits elucidation, as no published study in this regards could be found in the literature.

## TENNIS ELBOW AND CONSERVATIVE THERAPY

### VIOLA

#### TRIGGER POINT THERAPY

Tennis elbow is frequently considered as a dysfunction of myofascial tissues to which trigger point therapy can be effectively applied. Myofascial trigger point, is an hyperirritable spot, usually within a taut band of skeletal muscle or in the muscles fascia, that is painful on compression and that can give rise to characteristic referred pain, tenderness and anatomic phenomena (79). Trigger points can be inactivated by ischaemic compression, stretch, spray, injection and corrective actions. Ultrasound, laser and dry needle like acupuncture have also been used. In the absence of any scientific literature, however, further clinical research would be required to validate the use of this modality in the treatment of tennis elbow.

#### MILL'S MANIPULATION TECHNIQUE

Mill's manipulation technique has been suggested as an alternative before performing surgery. Wadsworth (16) reported that in more than 100 resistant cases over the last two decades, the rate of success by this technique was 99% with only six patients required more than one manipulation. The patient is fully relaxed under general anaesthesia. The patient is placed supine on the operating table and a mixture of 0.5 ml methylprednisolone and 0.5 ml 2% Xylocaine injected into the proximal tendon of the extensor carpi radialis brevis at the lateral epicondyle. Then the hand is grasped and the surgeon's other hand used to steady the arm above the elbow, with the forearm fully pronated and the wrist palmar flexed; the elbow is forcefully extended from the fully flexed position. Typically, there is an easily audible snap as full elbow extension is gained. The snapping sound can be attributed either to completion of a partial tear of the common extensor tendon-in effect a closed lateral release-or to breakdown of adhesions that have formed at the common extensor origin. The patient should be warned to avoid strain on the affected arm for at least 3 months (16).

#### NEW TREATMENT APPROACHES

Use of extra corporeal shock waves in the treatment of tennis elbow has recently been suggested to be associated with approximately 80% success rate (80). However, this remains to be convincingly demonstrated by further studies.

Radiotherapy has also been claimed to be a highly efficacious means of pain alleviation in tennis elbow (81). However, the potential risk associated with radiotherapy, the absence of confirmatory data, the fact that 50% of patients 2 months after treatment had objectifiable pain on exercise, and finally the absence of any control group in the study cast serious doubt on the accuracy of this claim.

More recently, a group of 14 patients with chronic treatment-resistant tennis elbow were treated with 20-40 units botulinum toxin (average 30 units) injected under electromyographic guidance into the extensor digitorum communis III and IV muscle (82). Nine patients reported a pain relief of more than 50% on a self assessment scale and pain disappeared completely in four patients. The relief of pain occurred within 2 to 4 weeks. Although the authors claim that their results are promising, the small sample size and absence of control group in the study cast doubt on plausibility of this claim.

#### SURGICAL TREATMENT

It has been reported that conservative therapy is effective in 90% of patients with tennis elbow, and only in a small percentage (about 10%) of cases (severe and refractory cases) the pain is resistant to all conservative treatment which may eventually require surgical intervention (1,8,47).

Surgical treatment has mainly been based on the authors view of the etiology of condition (1). Due to diverse views concerning the etiology of the condition, many different surgical procedures have been proposed in recent years. Although different authors have published studies reporting the efficacy of a particular surgical approach, to date no conclusive evidence has been presented to support the efficiency of one method over the other and there is not general agreement as to the preference of one procedure over another (83). Some of the most common surgical techniques for treatment of tennis elbow include:

- 1) Excision of part of the extensor origin together with excision of the orbicular ligament (30).
- 2) Denervation (84).
- 3) Distal tendon lengthening of the affected muscle (85).
- 4) Total release of the extensor musculature from the lateral epicondyle (24).

Surgery may be considered if any of the following exists: (A) partial or total rupture of tendon associated with persistent pain for more than six months to one year, (B) lack of success in pain control, promotion of healing, general conditioning and control of abusive overuse, (C) lack of response to two weeks of immobilisation, (D) failure to respond to three or more injection of cortisone or the existence of iatrogenic cortisone atrophy (23,32).

However, if a patient demonstrates progressive, although not complete, resolution of symptoms with conservative therapy, surgical intervention should be postponed (25).

The rate of success with surgery varies. Some authors have claimed an approximately 70% success rate (8). Others have shown that 25-81% of patients who undergo

surgery for tennis elbow achieve complete pain relief. However, 9-43% of these patients continue to experience occasional pain, up to 35% have moderate pain and up to 10% may get no benefit from surgery (86).

A retrospective study showed that surgical release of common extensor in patients with persistent or recurrent local pain and muscle weakness, non responsive to conservative measures for at least six months was associated with a complete pain relief in 73%. The failure rate was 9%. The gross histologic findings were consistent with a degenerative process (87).

The most popular surgical technique in recent years has been limited excision of the abnormal tissue from the extensor carpi radialis brevis tendon while leaving the surrounded unaffected structures intact (18,32). Nirschl claims an 85% success rate for surgery with an additional 12% of significant pain relief (32). The author, however, presents his own surgical experience based on the records of selected groups of patients with chronic symptoms of pain persisting for more than a year or those who have failed to respond to rehabilitation program, and no information as to the possible follow up protocols has been provided.

Conversely, some authors (86) have reported that 9-43% of patients who undergone surgery for tennis elbow continue to experience occasional pain, up to 35% suffer from moderate pain and up to 10% may get no benefit from surgery. Similar observations have been reported in patients who have taken up to a year to have a pain free elbow after surgery (4).

Simple lateral release treatment, as originally described by Bosworth (30) has also been supported by a number of other investigations in recent years (88,89).

Tan et al detach the common extensor origin and excise the orbicular ligaments capsule or synovium of the elbow joint (90). They claim a success rate of 91.7% (good or excellent postoperative results) based on the assessment scale of Nirschl. The procedure is called Bosworth's modified operation. Nirschl, however, believes that the surgical techniques of the extensor aponeurosis or orbicular ligament should be avoided as they do not address the concept of pathologic tissue and they often prove unsuccessful and potentially harmful (especially resection of the orbicular ligament) (32).

After surgery and before starting active resistive exercises and mobilisation of the extensor muscle mass, it is important that appropriate healing of the extensor origin be obtained. It is suggested that a posterior elbow splint at 90° with the inclusion of the wrist at 30 to 45 degrees of extension postoperatively for a total of 3 weeks. This

is followed by 3 weeks of wrist immobilisation splint alone in slight extension, and elbow range of motion exercises. At 6 weeks, gradually controlled strengthening is commenced and splinting is discontinued. No cases of elbow or wrist stiffness has been associated with this postoperative protocol (25).

Recently, it has been shown that pain relief was significantly better in those patients with the shorter duration of preoperative symptoms (86). Therefore, the authors proposed that prolonged period of conservative therapy in the management of tennis elbow should be avoided, and surgery for failed conservative management of tennis elbow should be offered at an earlier stage. However, the study is not of sufficient quality or statistical power to substantiate this proposition.

## **REHABILITATION**

Complete immobilisation of the extremity may be necessary for two to three weeks to obtain relief of symptoms. The criterion for healing is the defervescence of pain without medication. Once this has occurred the patient can begin a rehabilitation program (45).

While exercises to strengthen the forearm muscle, are often prescribed in the USA, emphasis is generally placed on resting the elbow in the UK (7). Rehabilitation is crucial to prevent relapse of tennis elbow (33) and its aim is to restore the strength and function of the muscles around the elbow to the state they were before tennis elbow. This includes a series of isometric and isotonic exercises, the use of a counterforce brace, pre and post play cryotherapy and anti-inflammatory medication and a graduated regime for returning to play. Similarly, the contributing factors to the onset of the injury such as biomechanics of stroke production and the type of equipment used by tennis player should also be considered in ultimate resolution of the injury (4).

The acute injury should heal in approximately 6 weeks. If there is a relatively pain-free range of motion at that time, an exercise program can be initiated. The prior activity level should be approached slowly (11,25). The patient should begin performing stretching exercises of the extensor forearm muscles. After passive stretching, the patient should start performing strengthening exercises for the forearm muscles by using a 1-lb weight (23), and building up gradually (up to 10 lbs depending on the patient, (8).

It is suggested that any involved muscle of the forearm, shoulder and cervical region is stretched and manually manipulated two to four times at weekly intervals to relieve protective muscular spasms restore tissue integrity and to maintain joint motion (6). In older patients, age-

## TENNIS ELBOW AND CONSERVATIVE THERAPY

### VIOLA

related changes in soft tissues and bones may cause further inflammation which complicate recovery. It is therefore essential that the older athlete restoring as much strength as possible to the injured site before resuming sport activities. However a young athlete may be able to resume sport activities without restoring full strength (91). The same principals may also be applicable to general population.

A device used in training by tennis players, called Marcy-Wedge-pro (MPW) provides objective and quantitative measures of the ability to exercise the forearm extensor muscle group and has been suggested as a useful tool in assessment of clinical improvement in tennis elbow (92).

### BRACING

Bracing is used as a counterforce mechanism to diminish the overload forces that have been suggested to precipitate and prolong the incidence of this clinical problem (93). It should be applied firmly around the forearm over the wrist extensor muscle mass at the elbow to prevent a full contraction of the muscle when patient contracts the wrist extensor thereby relieving tension on the attachment of the extensor tendon.

In healthy individuals, air cast bands when compared with standard bands have been shown to significantly reduce the EMG activity of ECRB and extensor digitorum communis (EDC), which are commonly involved in tennis elbow pathology. To determine whether wearing a band would be beneficial, it has been suggested that a blood pressure cuff can be placed on the symptomatic forearm and inflated to midway between systolic and diastolic blood pressures to simulate a tennis-elbow band. When the patient grasps a book a reduction in discomfort would demonstrate the utility of the band (23). Evidence about the effect of forearm straps on the electromyographic activity in the extensor muscles is conflicting (4). Using sophisticated electromyographic techniques, counterforce braces have been shown to produce lower muscular activity when serving or playing the back hand (94).

Although braces are commonly recommended and used, and provide many people with a feeling of confidence, some authors believe that they may be causing more harm than good. The brace functions to limit the motion of muscles and increases the chance of losing motion, which may never be regained. Compression of the forearm reduces circulation and does not protect the elbow joint from torsion (6).

### PREVENTION

With a disease of considerable prevalence and relapse rate, one would hope for an effective prophylaxis (95).

However at present there is little that could be offered. Cessation of the exercise that stresses the arm may seem as obvious to some clinicians as it is unacceptable by most patients.

Exercise is important for the following reasons (96):

- (a) to develop strength and endurance in a coordinated manner
- (b) to reinforce the proper technique
- (c) to improve the patient's skill level and
- (d) to increase muscle power which depends on the quick acting response of type (White) II muscle fibres.

Proper strengthening, stretching and warm-up before play are also essential elements for a preventive program. Exercise provides a full warming of the tissues before actual contact is made with the ball. Muscles, ligaments and tendons that have been thoroughly warmed up are likely to stretch, whereas those that are cold are likely to tear (6). Additionally, equipment modification has been suggested to be a determinant factor in prevention of this condition (34). It is believed that wooden rackets that absorb vibration more effectively may be better than modern rackets, which are made from metal, graphite and fibreglass (16). Similarly, frames made of materials that allow less vibration, such as graphite and various epoxies are beneficial in dampening the impact forces transmitted to the elbow. Less tightly strung rackets and playing on slower surfaces such as clay may help decrease impact forces (34). In contrast, some studies have shown that no significant variation in either incidence or recurrence of tennis elbow symptom was evident based on racket material or weight and warm up time was not noted to be a significant factor in the occurrence of tennis elbow. However, contributing factors to the incidence of tennis elbow were increased age, high playing time per day and large grip size (3).

The faulty technique in tennis playing appears to be excessive forearm pronation on the forehand stroke. Therefore, stroke modification has been suggested to result in permanent relief of elbow pain (34,97).

In occupational setting, the weight of the working tools and loads to be moved is a major concern. If a reduction in weight is not possible, the working pace has to be slowed down or regular pausing has to be introduced in order to allow the musculature time for relaxation (38).

### CONCLUSIONS

1) The choice and dose of steroid preparation in the treatment of lateral epicondylitis remain arbitrary, because there has been no comprehensive comparison of commonly used agents. The worth of corticosteroid injection treatment has not been established beyond

reasonable doubt and the relative merits of different preparations hardly scrutinised (98). Although the administration of steroid preparations in resistant tennis elbow may be useful, in view of the high recurrence rate, side effects and structural tissue changes associated with these compounds, their wide application in the treatment of tennis elbow requires further validation.

2) Studies on clinical acupuncture, despite their limitations, have generally provided evidence in favour of a role for classical acupuncture as an effective therapeutic means in the treatment of tennis elbow. However, there is clearly a need for further prospective randomised clinical trials with acceptable epidemiological design and larger sample sizes to further support these preliminary observations.

3) Studies on the role of ultrasound have shown significant improvement from baseline. Additionally, application of ultrasound in conjunction with friction massage or phonophoresis appears to offer no considerable therapeutic advantages over the ultrasound itself. However, as with acupuncture, more comprehensive studies with larger sample sizes and appropriate design (prospective randomised control trials with well defined inclusion and exclusion criteria) with adequate follow-up are clearly required to substantiate the therapeutic benefits of this treatment.

4) Studies concerning the effects of low level laser in the treatment of tennis elbow are not conclusive. While low level laser therapy has been shown by some authors to have an effect over placebo, others have failed to find a significant effect of laser to be superior to placebo. Further studies with larger sample sizes would be desirable to evaluate the efficacy of this method and to compare laser to other established therapeutic modalities (73).

## REFERENCES

1. Burgess RC. Tennis elbow. *J KY Med Assoc* 1990; 88: 349-54.
2. Noteboom T, Cruver R, Keller J, Kellogg B, Nitz AJ. Tennis elbow: a review. *J Orthop Sports Phys Ther* 1994; 19: 357-66.
3. Gruchow HW, Pelletier D. An epidemiologic study of tennis elbow, incidence, recurrence and effectiveness of prevention strategies. *Am J Sports Med* 1979; 7: 234-8.
4. Kamien M. A rational management of tennis elbow. *Sports med* 1990; 9: 173-91
5. Roetert EP, Brody H, Dillman CJ, Groppe JL, Schultheis JM. The biomechanics of tennis elbow: an integrated approach. *Clin Sports Med* 1995; 14: 47-57.
6. Schnatz P, Steiner C. Tennis elbow: a biomechanical and therapeutic approach. *J Am Osteopath Assoc* 1993; 93: 778, 782-8.
7. Chard MD, Hazleman BL. Tennis elbow - a reappraisal. *Br J Rheumatol* 1989; 28: 186-90.
8. Murtagh JE. Tennis elbow. *Aust Fam Physician* 1988; 17: 90-5.
9. Hamilton PG. The prevalence of humeral epicondylitis: a survey in general practice. *J R Coll Gen Pract* 1986; 36: 464-5.
10. Chop WM. Tennis elbow. *Postgrad Med* 1989; 86: 301-8.
11. Gellman H. Tennis elbow (lateral epicondylitis). *Orthop Clin North Am* 1992; 23: 75-82.
12. Dimberg L. The Prevalence and Causation of Tennis elbow (lateral humeral epicondylitis) in a population of workers in an engineering industry. *Ergonomics* 1987; 30: 573-80.
13. Gerberich SG, Priest JD. Treatment for lateral epicondylitis variables related to recovery. *Br J Sports Med* 1985; 19: 224-7.
14. Taylor HM, Bender BL. Tennis elbow and computers. *Can Med Assoc J* 1991; 144: 13-6.
15. Allander E. Prevalence, incidence and remission rates of some common rheumatic diseases or syndromes. *Scand J Rheumatol* 1974; 3: 145-53.
16. Wadsworth TG. Tennis elbow (Conservative, surgical and manipulative treatment). *Br Med J* 1987; 294: 621-4.
17. Wittenberg RH, Schaal S, Muhr G. Surgical treatment of persistent elbow epicondylitis. *Clin Orthop* 1992; 278: 73-80.
18. Coonrad RW, Hooper WR. Tennis elbow: its course, natural history, conservative and surgical management. *J Bone Joint Surg Am* 1973; 55: 1177-82.
19. Binder A, Hodge G, Greenwood AM, Hazleman BL, Thomas DP. Is therapeutic ultrasound effective in treating soft tissue lesions. *Br Med J* 1985; 290: 512-4
20. Lapidus PW, Guidotti FP. Lateral and medial epicondylitis of the humerus. *Ind Med Surg* 1970; 39: 30-2.
21. Verhaar JAN. Tennis elbow anatomical, epidemiological and therapeutic aspects. *Int Orthop* 1994; 18: 263-7.
22. Snijders CJ, Volkers ACW, Mechelse K, Vleeming A. Provocation of epicondylalgia laterals (tennis elbow) by power grip or pinching. *Med Sci Sports Exerc* 1987; 19: 518-23.
23. Foley AE. Tennis elbow. *Am Fam Physician* 1993; 48: 281-8.
24. Cabot A. Tennis elbow, a curable affliction. *Orthop Rev* 1987; 16: 69-73.
25. Katarincic JA, Weiss APC, Akelman E. Lateral epicondylitis (tennis elbow): a review. *RI Med* 1992; 75: 541-4.

## TENNIS ELBOW AND CONSERVATIVE THERAPY VIOLA

26. Labelle H, Guibert R, Joncas J, Newman N, Fallaha M, Rivard CH. Lack of scientific evidence for the treatment of lateral epicondylitis of the elbow. *J Bone Joint Surg (Br)* 1992; 74: 646-51.
27. Lee DG. Tennis elbow: A manual therapists perspective. *J Orthop Sports Phys Ther* 1986; 8: 134-41.
28. Cyriax JH. The pathology and treatment of tennis elbow. *J Bone Joint Surg* 1936; 18: 921-38.
29. Garrett WE, Duncan PW, Malone TR. Muscle injury and rehabilitation. In: Malone T R (ed), *Sports Injury Management. A Quarterly Series* 1988; 1: 1-42.
30. Bosworth DM. Surgical Treatment of Tennis elbow. *Bone Joint Surg Am* 1965; 47: 1533-6.
31. Goldie I. Epicondylitis laterally humeri (epicondylalgia or tennis elbow): a pathogenetical study. *Acta Chir Scand* 1964; 339: 104-9.
32. Nirschl RP. Elbow tendinosis/tennis elbow. *Clin Sports Med* 1992; 11: 851-70.
33. Wood M, Knight NC. Tennis elbow: its clinical course, etiology and treatment. *J Ark Med Soc* 1989; 85: 499-500.
34. Leach RE, Miller JK. Lateral and medial epicondylitis of the elbow. *Clin Sports Med* 1987; 6: 259-72.
35. Nirschl RP, Pettrone F. A tennis elbow: The surgical treatment of lateral epicondylitis. *J Bone Joint Surg (Am)* 1979; 61: 832-9.
36. Regan W, Wold LE, Coonrad R, Morrey BF. Microscopic histopathology of chronic refractory lateral epicondylitis. *Am J Sports Med* 1992; 20: 746-9.
37. Doran A, Gresham GA, Rushton N, Watson C. Tennis elbow: a clinicopathology study of 22 cases followed for two (2) years. *Acta Orthop Scand* 1990; 61: 535-8.
38. Kivi P. The etiology and conservative treatment of humeral epicondylitis. *Scand J Rehabil Med* 1982; 15: 37-41.
39. Doherty M. Common regional pain syndromes. *Practitioner* 1989; 233: 1380.
40. Coonrad RW. Tennis elbow. *Instr Course Lect* 1986; 35: 94-101.
41. Coel M, Yamada CY, Ko JMR. Imaging of patients with lateral epicondylitis of the elbow (tennis elbow): importance of increased signal of the anconeus muscle. *Am J Rontgenol* 1993; 166: 1019-21.
42. Maffulli N, Regine R, Carrillo F, Capasso J, Minelli S. Tennis elbow: an ultrasonographic study in tennis players. *Br J Sports Med* 1990; 24: 151-5.
43. Morrey BF. Primary degenerative arthritis of the elbow: ulnohumeral arthroplasty, In: Morrey BF (ed), *The elbow and its disorders*, 2nd edition, Philadelphia W B Saunders 1993; 774-83.
44. Moss SH, Switzer HE. Radial tunnel syndrome: a spectrum of clinical presentations. *J Hand Surg (Am)* 1983; 8: 414-20.
45. Creighton JJ, Idler RS, Strickland JW. Tennis elbow. *Indiana Med* 1990; 83: 476-7.
46. Loser JD. Cervicobrachial neuralgia In: Bonica JJ (ed), *The management of pain*, 2<sup>nd</sup> Edition, Lea and Febiger, 1990; 868-81.
47. Lister GD, Belsole RB, Kleinert HE. The radial tunnel syndromes. *J Hand Surg (Am)* 1979; 4: 52-9.
48. Nirschl RP. Tennis elbow. *Orthop Cli North Am* 1973; 4: 787-800.
49. Jalovaara P, Lindholm RV. Decompression of the posterior interosseous nerve for tennis elbow. *Arch Orthop Trauma Surg* 1989; 108: 243-5.
50. Heyse-Moore GH. Resistant tennis elbow. *J Hand Surg (Br)* 1984; 9: 64-6.
51. Nevelos AB. The treatment of tennis elbow with triamcinolone acetonide. *Curr Med Res Opin* 1980; 6: 507-9.
52. Clarke AK, Woodland J. Comparison of two steroid preparations used to treat tennis elbow, using the hypospray. *Rheumatol Rehabil* 1975; 14: 47-9.
53. Binder AI, Hazleman BL. Lateral humeral epicondylitis – A study of natural history and the effect of conservative therapy. *Br J Rheumatol* 1983; 22: 73-6.
54. Brattberg G. Acupuncture therapy for tennis elbow. *Pain* 1983; 16: 285-8.
55. Day BH, Govindasamy N, Patnaik R. Corticosteroid injections in the treatment of tennis elbow. *Practitioner* 1978; 220: 459-62.
56. Fadale PD, Wiggins ME. Corticosteroid injections: their use and abuse. *J Am Acad Orthop Surg* 1994; 2: 133-40.
57. Hill JJ, Trapp RG, Colliver, JA. Survey on the use of corticosteroid injections by orthopaedists. *Contemp Orthop* 1989; 18: 39-45.
58. Clement-Jones V, Tomlin S, Rees LH, Mc Loughlin L, Besser GM, Wen HL. Increased  $\beta$ -endorphin but not met-enkephalin levels in human cerebrospinal fluid after acupuncture for recurrent pain. *Lancet* 1980; 2(8201): 946-9.
59. Sjolund B, Terenius L, Eriksson M. Increased cerebrospinal fluid levels of endorphins after electroacupuncture. *Acta Physiol Scand* 1977; 100: 382-4.
60. Han JS, Terenius L. Neurochemical basis of acupuncture analgesia. *Ann Rev Pharmacol Toxicol* 1982; 22: 193-220.
61. O'Connor J, Bensky D. A summary of research concerning the effects of acupuncture. In: *Acupuncture: a comprehensive text*. Washington, Eastland Press, 1987; 529-45.
62. Liping H, Xuan W. Treatment of tennis elbow with heat needling: a clinical summary of 58 cases. *J Tradit Chin Med* 1988; 8: 129-30.
63. Zhiming W. Successful treatment of epicondylitis with chize-through tender point puncturing method. *J Tradi Chin Med* 1990; 10: 122-3.

64. Zhongying M. 52 cases of external humeral epicondylitis treated by acupuncture and moxibustion. *J Tradi Chin Med* 1989; 9: 3-4.
65. Haker E, Lundberg T. Acupuncture treatment in epicondylalgia: a comparative study of two acupuncture techniques. *Clin J Pain* 1990; 6: 221-6.
66. Molsberger A, Hille E. The analgesic effect of acupuncture in chronic tennis elbow pain. *Br J Rheumatol* 1994; 33: 1162-5.
67. Spiker JC. Ultrasound in: Coryell (ed). *Therapeutic modalities in sports medicine*, 2nd Edition, St Louis, Times Mirror/ Mosby College Publishing 1990; 129-47.
68. Haker EHK, Lundeberg TCM. Lateral epicondylalgia; Report of non-effective mid laser treatment. *Arch Phys Med Rehabil* 1991; 72: 984-8.
69. Halle JS, Franklin RJ, Karalfa BL. Comparison of four treatment approaches for lateral epicondylitis of the elbow. *J Orthop Sports Phys Ther* 1986; 8: 62-7.
70. Lundeberg T, Abrahamsson P, Haker E. A comparative study of continuous ultrasound, placebo ultrasound and rest in epicondylalgia. *Scand J Rehabil Med* 1988; 20: 99-101.
71. Sinclair A. Tennis elbow in industry. *Bri J Ind Med* 1965; 22: 144-8.
72. Stratford PW, Levy DR, Gaudie S, Miseferi D, Levy K. The evaluation of phonophoresis and friction massage as treatments for extensor carpi radialis tendinitis: a randomised controlled trial. *Physiother Can* 1989; 4: 93-9.
73. Saliba EN, Foreman SH. Low-power lasers in: Coryell P (ed), *Therapeutic modalities in sports medicine*, 2nd Edition, St Louis, Times Mirror/ Mosby College Publishing 1990; 185-209.
74. Haker E, Lundeberg T. Laser treatment applied to acupuncture points in lateral humeral epicondylalgia. A double-blind study. *Clin J Pain* 1990; 43: 243-7.
75. Lundeberg T, Haker E, Thomas M. Effect of laser versus placebo in tennis elbow. *Scand J Rehabil Med* 1987; 19: 135-8.
76. Vasseljen O Jr., Hoeg N, Kjeldstad B, Johnsson A, Larsen S. Low level laser versus placebo in the treatment of tennis elbow. *Scand J Rehabil Med* 1992; 24: 37-42.
77. Ingham B. Transverse friction massage for relief of tennis elbow. *The Physician and Sports Medicine* 1981; 9: 118.
78. Walker JM. Deep transverse friction in ligament healing. *J Orthop Sports Phys Ther* 1984; 6: 89-94.
79. Travell JG, Simons DG. *Supinator muscle: tennis elbow in: Myofascial pain and dysfunction: the trigger point manual*, Sydney, William and Wilkins, 1983; 510-22.
80. Haupt G. Use of extracorporeal shock waves in the treatment of pseudoarthrosis, tendinopathy and other orthopaedic diseases. *J Urol* 1997; 158: 4-11.
81. Heyd R, Schopohl B, Kirchner J, Strassmann G, Bottcher HD. Radiotherapy of tennis elbow. *Dtsch Med Wochenschr* 1997; 122: 247-52.
82. Morre HE, Keizer SB, Os JJV. Treatment of chronic tennis elbow with botulinum toxin. *Lancet* 1997; 349: 1746.
83. Friden J, Lieber RL. Physiological consequences of surgical lengthening of extensor carpi radialis brevis muscle-tendon junction for tennis elbow. *J Hand Surg (Am)* 1994; 19: 269-74.
84. Kaplan EB. Treatment of tennis elbow (epicondylitis) by denervation. *J Bone Joint Surg Am* 1959; 41: 147-51.
85. Garden RS. Tennis elbow. *J Bone Joint Surg (Br)* 1961; 43: 100-6.
86. Newey ML, Patterson MH. Pain relief following tennis elbow release. *J R Coll Surg Edinb* 1994; 39: 60-1.
87. Goldberg EJ, Abraham E, Siegel I. The surgical treatment of chronic lateral humeral epicondylitis by common extensor release. *Clin Orthop* 1988; 233: 208-12.
88. Clavert PT, Macpherson IS, Allum RL, Bently G. Simple lateral release in treatment of tennis elbow. *J R Soc Med* 1985; 78: 912-5.
89. Rosen MJ, Duffy FP, Miller FH, Krenchek EJ. Tennis elbow syndrome: results of the lateral release procedure. *Ohio State Med J* 1980; 76: 103-9.
90. Tan PK, Lam KS, Tan SK. Results of modified Bosworth's operation for persistent or recurrent tennis elbow. *Singapore Med J* 1989; 30: 359-62.
91. Brown M. The older athlete with tennis elbow. *Clin Sports Med* 1995; 14: 267-75.
92. Smith RW, Mani R, Cawley MID, Englisch W, Eckenberger P. Assessment of tennis elbow using the Marcy Wedge - pro. *Brit J Sports Med* 1993; 27: 233-6.
93. Snyder-Mackler L, Epler M. Effect of standard and aircast tennis elbow bands on integrated electromyography of forearm extensor musculature proximal to the hands. *Am J Sports Med* 1989; 17: 278-81.
94. Groppe JL, Nirschl RP. A mechanical and electromyographical analysis of the effects of various joint counterforce braces on the tennis player. *Am J Sports Med* 1986; 14: 195-200.
95. Ernst E. Conservative therapy for tennis elbow. *Br J Clin Pract* 1992; 46: 55-7.
96. Lafreniere JG. Tennis elbow evaluation, treatment and prevention. *Phys Ther* 1979; 59: 742-6.
97. Ilfeld FW. Can stroke modification relieve tennis elbow? *Clin Orthop* 1992; 276: 182-6.
98. Price R, Sinclair H, Heinrich I, Gibson T. Local injection treatment of tennis elbow - hydrocortisone, triamcinolone and lignocaine compared. *Br J Rheumatol* 1991; 30: 39-44.