MICROSCOPIC METASTASES IN THE THYROID GLAND *

CARL O. RICE, M.D., M.S.

(From the Department of Surgery, University of Minnesota School of Medicine, Minneapolis, Minn.)

Metastases from malignant growths to the thyroid gland, although somewhat infrequent, probably occur more often than has been supposed. In a series of 521 autopsies on patients dying from carcinoma Müller [1] found gross metastases in the thyroid gland in 1.5 per cent. In another group of 102 postmortem examinations on patients dying from sarcoma he found metastases in 3.1 per cent of the thyroid glands. Kitain [2] found metastases in 3.1 per cent of the thyroid glands from autopsies on individuals dying of carcinoma. In 170 consecutive autopsies on persons with malignant tumors Willis [3] found thyroid metastases in 5.2 per cent. He mentions that only by careful routine sectioning of the gland was it possible for him to find such a high incidence of metastases. In half of his 10 cases a casual bilateral section of the gland would have failed to disclose these metastatic areas. Wegelin [4] does not consider metastasis to the thyroid gland an exceptional rarity, for he found it frequently in the material examined at the Pathological Institute of the University of Bern.

It is a well known fact that certain types of malignant conditions select certain regions for their metastatic growths. Carcinoma of the thyroid, kidney and prostate seems to have a selective affinity for metastasizing to bone, whereas carcinoma of the breast has a tendency to metastasize to the lungs.

The causative factor for this peculiar type of selective metastasis is not definitely established. Various mechanical theories have been suggested to account for the lodgement of malignant cells in certain areas. Likewise, to chemical factors has been attributed the principle rôle in determining the sites for the development of metastatic growths. Paget [5] speaks of certain tissues as being "congenial soil," whereas Ewing [6] has expressed an opinion opposed to this when he mentions that no organ is more adapted than any other for the growth of embolic tumor cells.

* Received for publication December 1, 1933.

Among the 57 autopsies with secondary carcinomatous growths in the thyroid gland reviewed by Willis, the primary tumor was most frequent in the breast. Next in frequency were the malignant melanomas, and third, carcinoma of the lungs and bronchi. He suggested that the high incidence of this phenomenon secondary to carcinoma of the breast was in all probability due to the greater frequency of that disease. On this assumption it should be possible to give first and second place to malignant melanoma and carcinoma of the lungs, both of which are relatively infrequent types of malignancy in the thyroid. Kaufmann[7] and Eiselt[8] found a relatively high incidence in malignant melanoma. In 34 autopsies with thyroid metastases Wegelin found 6 arising from carcinoma of the esophagus, 5 from carcinoma of the lung, 5 from melanosarcoma, 4 from carcinoma of the stomach, and the others from a variety of sources. He mentions that in the majority of instances the metastatic growths in the thyroid are visible as definitely circumscribed nodules.

Of all the men who have reported cases of malignant disease with metastases to the thyroid, none of them has found metastases that were not grossly visible. This paper is written for the purpose of demonstrating that microscopic metastases may occur in the thyroid gland without any macroscopic evidence of their presence.

Among 89 postmortem examinations from the department of pathology of the University of Minnesota on patients dying from malignant tumors there were embolic tumor cells within the thyroid gland in 9. The thyroid glands from all these patients were examined grossly and microscopically. Five of these showed gross metastases: 2 were from patients dying of malignant melanoma, 1 from carcinoma of the lung, 1 from lymphosarcoma, and 1 from carcinoma of the breast. These carcinomatous nodules were easily identified on macroscopic inspection of the gland. The remaining 4 cases presented, on gross inspection, no evidence of any tumor tissue or anything else to suggest the presence of malignant invasion. The essential details in the case histories of these cases are reported in the following case reports.

Case Reports

Case 1. Mrs. E. F., (A–29–595), aged 44 years, was admitted to the Minnesota General Hospital on March 28, 1929. A radical operation for carcinoma of the breast had been performed 3 months previously. The patient died on April 17, 1929.

The postmortem examination revealed numerous metastatic nodules in the bones, liver and lungs. The thyroid gland weighed 34 gm., and appeared normal in structure, with the exception of a few small colloid nodules and one large parenchymatous nodule measuring 15 mm. in diameter. There was no area, on gross inspection, that suggested malignant tissue.

Microscopic examination of the thyroid tissue reveals normal acini. Scattered throughout in the interlobular septa there are groups of large, irregularly shaped, deeply stained, closely packed cells, among which occasional mitotic figures can be seen. The nuclei are large and the cells contain a small amount of cytoplasm (Figs. 1 and 2).

The histological structure of the metastatic nodules from the liver is similar to the carcinomatous tissue observed in the interlobular septa of the thyroid.

CASE 2. Mr. F. R., (A-29-1323), case history not available.

The thyroid gland weighed 27 gm. It was diffusely homogeneous in structure and appeared to be entirely normal. Neither nodules nor areas suggesting a malignant condition could be identified on gross inspection.

Microscopic examination reveals normal thyroid acini. Here and there in the interlobular septa can be seen groups of large, pale staining, round and polyhedral cells. Some of these have large vacuolated nuclei and a large amount of cytoplasm. Mitotic figures are moderately abundant (Figs. 3 and 4).

CASE 3. Mrs. J. E., (A-29-285), aged 67 years, was admitted to the Ancker Hospital on Feb. 14, 1929, complaining of difficulty in breathing, dyspnea and a productive cough of 5 days duration. The most pronounced symptom was the cough. Dyspnea became more severe 2 days prior to admission to the hospital. She also gave a history of having had an ulcerated lesion on the right malar region for the past 9 months.

On physical examination a superficial, ulcerated lesion 1 cm. in diameter was found over the right malar region and a similar lesion over the right mandible. Examination of the chest revealed coarse moist râles over both lungs, but no evidence of consolidation. The blood pressure was 230/120. A clinical diagnosis of acute bronchitis, laryngitis, hypertension and carcinoma of the cheek was made.

The X-ray report of the chest disclosed infiltration and fibrosis in both lungs. This was suggestive of pneumoconiosis, associated with tuberculosis, and possibly bronchiectasis in both apices.

The patient became rapidly weaker and died on Feb. 16, 1929.

The postmortem examination disclosed the indurated, ulcerated lesion on the cheek, but no section was made of this to determine its exact nature. The liver was enlarged. Some old adhesions were found in the pleural cavity. There were 400 cc. of fluid in the left pleural cavity and 200 cc. of blood-tinged fluid in the right pleural cavity. A large focus of consolidation was present in the right lung, and several large, anthracotic and caseous lymph nodes were present at the hilum of both lungs. Microscopic examination of these tissues shows carcinoma. The lung was considered to be the site of the primary lesion. Its gross appearance did not suggest carcinoma and its presence was not suspected until sections were examined. The thyroid gland weighed 22 gm. Its structure was uniform. There were no nodules or any areas that could be interpreted as malignant on gross inspection.

The microscopic structure of the thyroid acini appears to be normal. Scattered throughout, in the interlobular septa, are found groups of large clear cells with enlarged granular nuclei and a pale staining cytoplasm. Mitotic figures are occasionally seen. Intercellular bridges are not observed. The cells are similar to those found in the sections from the lungs (Fig. 5).

CASE 4. Mrs. L. K., (A-30-754), aged 47 years, was admitted to the Ancker Hospital on April 25, 1930, complaining of distention with gas, loss of appetite and exhaustion for the past 6 weeks. She had had no pain, nausea, vomiting, or food distress.

Physical examination disclosed a slight bilateral exophthalmos. The liver was found to extend 7 cm. below the costal margin. A systolic murmur was heard along the sternum in the second left interspace. The knee jerks were hyperactive; Babinski test, normal.

On May 1, 1930, palpation revealed fullness in the left upper quadrant of the abdomen. The patient was drowsy and very restless. On May 4th she became stuporous and could not be aroused. She developed a left sided hemiplegia and became incontinent. The knee reflexes became increased on the left. The Babinski test was positive on the left. On May 8th there was definite neck rigidity. Pure blood was found in the spinal fluid. Two hard lumps appeared on the head, one of which was located over the left frontal bone, the other in the right parietal region. On May 12th many fine râles were heard in the lungs. The temperature varied from normal to 102.4 F. The pulse ranged from 80 to 140. The hemoglobin was 55 per cent, erythrocytes 3,290,000, lymphocytes 5600, differential count normal.

The patient became progressively worse and died on May 12, 1930.

At the postmortem examination it was found that the two nodules on the head were metastases in the cranium, extending into the

cranial cavity. Numerous grayish white nodules, which proved to be metastatic tumor tissue, were found within the substance of the liver, occupying approximately one-fifth of the liver volume. The gall-bladder contained numerous faceted stones and its wall was definitely thickened and almost cartilaginous. This tissue proved to be carcinomatous and was thought to be the primary lesion. There was an area of pneumonic consolidation in the lower lobe of the left lung. Numerous metastatic nodules were found around the otherwise normal pancreas. The preaortic and mesenteric lymph nodes were invaded with metastatic tumor tissue. Pus was found beneath the arachnoid over the right hemisphere and there was softening of the entire right half of the brain. The thyroid gland was homogeneous in structure and appeared grossly to be entirely normal. There was nothing to indicate the presence of metastatic tumor tissue.

Microscopically the thyroid acini appear normal. Scattered throughout in the interlobular septa can be seen groups of large basophilic cells with large, round and polyhedral nuclei, and a moderate amount of pale staining cytoplasm. In other places these cells are darker and more spindle-shaped. Mitotic figures are abundant. The malignant cells are similar to those found in the gall-bladder, liver and lymph nodes (Fig. 6).

Discussion and Conclusions

These cases illustrate the occurrence of a type of metastasis that is often thought of as a precursor to the gross metastatic nodules, but which is infrequently seen in pathological specimens, probably because of the prevailing tendency to make histological sections only where gross pathological changes are visible.

In all these cases macroscopic inspection of the gross specimen failed to give any intimation that there were metastases in the thyroid gland. Although it is probable that this type of metastasis occurs frequently, a search of the literature has failed to reveal any reports of a similar nature.

The incidence of gross metastases in the thyroid gland, as reported by other writers, ranges from 1.5 per cent to 5 per cent. These figures compare favorably with those in this report when the cases with microscopic metastases are not included, but otherwise

the incidence approaches 10 per cent. It may be assumed then that microscopic metastases in the thyroid gland occur almost as frequently as gross metastases in this organ, and in all probability the incidence of metastasis is much greater than has been reported in the literature.

REFERENCES

1. Müller, M. Beitrag zur Kenntnis der Metastasenbildung malignen Tumoren. Inaug. Diss., Bern, 1892.
2. Kitain, H. Zur Kenntnis der Häufigkeit und der Lokalisation von Krebsmetastasen mit besonderer Berücksichtigung ihres histologischen Baus. *Virchows Arch. f. path. Anat.*, 1922, **238**, 289.
3. Willis, Rupert A. Metastatic tumors in the thyroid gland. *Am. J. Path.*, 1931, **7**, 187–208.
4. Wegelin, C. Die Schilddrüse. Handbuch der speciellen pathologische Anatomie und Histologie, Henke, F., and Lubarsch, O. J. Springer, Berlin, 1926, **8**, 1–547.
5. Paget, S. The distribution of secondary growths in cancer of the breast. *Lancet*, 1889, **1**, 571.
6. Ewing, James. Neoplastic Diseases. W. B. Saunders Company, Philadelphia, 1928, 86.
7. Kaufmann, E. Lehrbuch der pathologischen Anatomie. Translated by S. P. Reimann. P. Blakiston's Son & Co., Philadelphia, 1929, 537.
8. Eiselt, T. Ueber Pigmentkrebs. *Vierteljahrschr. f. d. prakt. Heilkunde*, 1861, **70**, 87–113; 1862, **76**, 26–58.

DESCRIPTION OF PLATE

Plate 106

Fig. 1. Case 1. Photomicrograph showing the microscopic structure of the thyroid gland with groups of deeply stained carcinomatous cells invading the interlobular septa.

Fig. 2. Case 1. High power magnification from the same section as Fig. 1, depicting a few of the groups of tumor cells. Two thyroid acini are seen at the right of the picture.

Fig. 3. Case 2. Photomicrograph showing interlobular septa filled with large and small groups of tumor cells. Thyroid acini normal.

Fig. 4. Case 2. High power magnification from the same section as Fig. 3. Mitotic figures are seen on the left side.

Fig. 5. Case 3. Photomicrograph showing thyroid acini which appear normal. The interlobular septa is occupied by groups of carcinomatous cells.

Fig. 6. Case 4. Photomicrograph showing interlobular septa filled with densely packed groups of tumor cells. Thyroid acini appear normal.

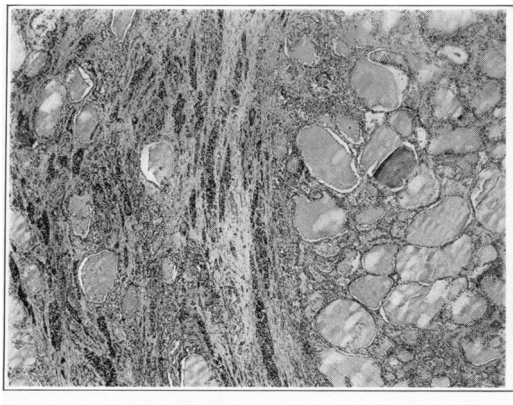

1

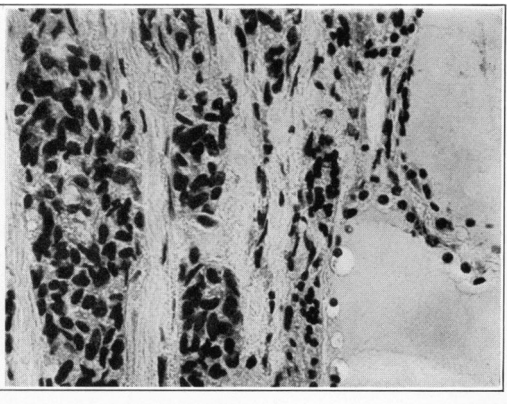

2

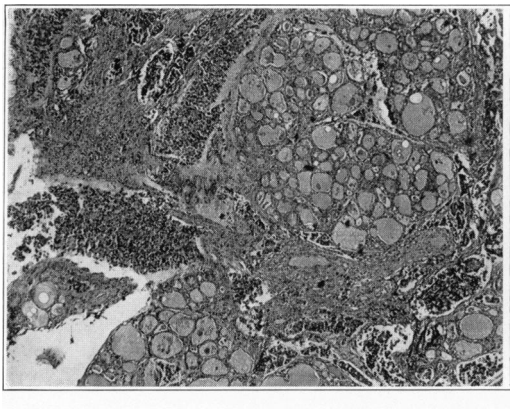

3

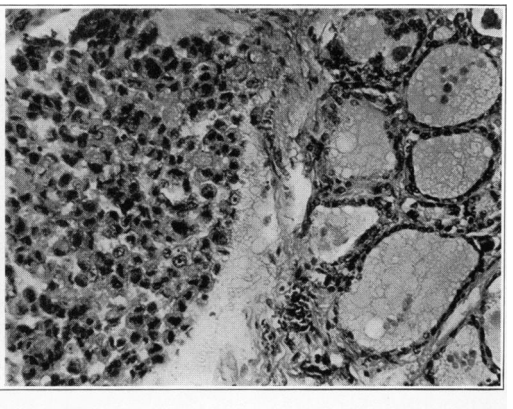

4

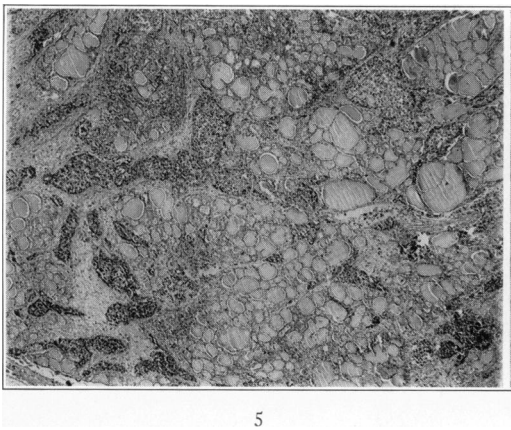

5

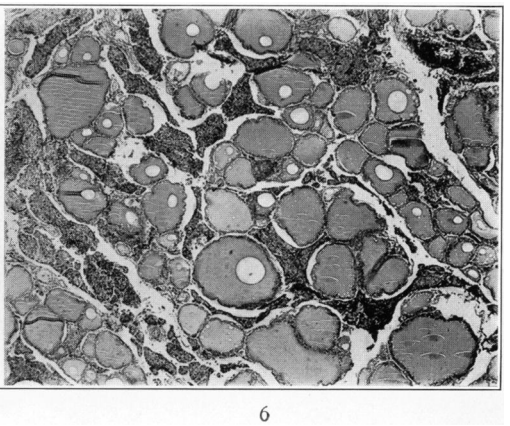

6