

Laboratory Diagnosis of Amebiasis

Mehmet Tanyuksel¹ and William A. Petri, Jr.^{2*}

*Department of Microbiology and Clinical Microbiology, Gulhane Military Medical Academy, Etlik, Ankara 06018, Turkey,¹
and Department of Internal Medicine, University of Virginia, Charlottesville, Virginia 22908-1340²*

INTRODUCTION	713
BACKGROUND (HISTORICAL PERSPECTIVE)	713
LIFE CYCLE AND BIOLOGY	714
REDESCRIPTION OF <i>E. HISTOLYTICA</i> AND <i>E. DISPAR</i>	714
Differentiation of <i>E. histolytica</i> / <i>E. dispar</i> / <i>E. moshkovskii</i> from <i>E. coli</i> and <i>E. hartmanni</i>	715
CLINICAL FEATURES	717
Asymptomatic Colonization.....	717
Amebic Colitis and Dysentery	717
Extraintestinal Amebiasis.....	717
EPIDEMIOLOGY	718
PATHOGENICITY	719
LABORATORY DIAGNOSIS.....	720
Microscopy	720
Biochemical Methods: Culture and Isoenzymes.....	720
Antibody Detection.....	721
ELISA	721
IHA.....	722
CIE.....	723
Antigen Detection.....	723
Molecular Biology-Based Diagnostic Tests and PCR.....	724
CONCLUSIONS	724
ACKNOWLEDGMENTS	725
REFERENCES	725

INTRODUCTION

The detection of *Entamoeba histolytica*, the causative agent of amebiasis, is an important goal of the clinical microbiology laboratory. This is because amebiasis is presently one of the three most common causes of death from parasitic disease. The World Health Organization reported that *E. histolytica* causes approximately 50 million cases and 100,000 deaths annually (13, 229). The vast majority of these infections are acquired in the developing world. For example, it was observed that 39% of children from an urban slum in Dhaka, Bangladesh, had a new *E. histolytica* infection during a 1-year study (81).

E. histolytica is a pathogen or invasive parasite, whereas *E. dispar* and *E. moshkovskii* are nonpathogenic and noninvasive parasites that are identical morphologically to *E. histolytica* (41, 58, 216). There are at least eight amebas (*E. histolytica*, *E. dispar*, *E. moshkovskii*, *E. coli*, *E. hartmanni*, *E. polecki*, *Iodamoeba bütschlii*, and *Endolimax nana*) which live in the human intestinal lumen (40, 64, 65, 80, 116). However, these are generally accepted as commensal organisms except for *E. histolytica* (61, 65, 116, 157). *E. polecki*, *Dientamoeba fragilis*, and *I. bütschlii* have occasionally been implicated as causes of di-

arrheal illness in humans (33, 34, 47, 103, 153). In the light of earlier reports about the prevalence of amebiasis in such subjects, interpretation is very difficult because older data did not differentiate between morphologically identical species, one that is noninvasive (*E. dispar*) and are that is invasive (*E. histolytica*), but they have a high degree of divergence (41, 43, 218). It is very important to keep in mind that according to the older data, many *E. histolytica* infections were most probably confused with *E. dispar* due to limited data obtained from microscopic examinations.

Microscopy, culture/zymodeme analysis, and molecular biology-based techniques are used for the diagnosis of *E. histolytica*. Each detection test has different advantages and disadvantages. The goals of this review are to describe *E. histolytica*, discuss what differentiates it from other *Entamoeba* species, and discuss recent advances in the diagnosis and management of amebiasis.

BACKGROUND (HISTORICAL PERSPECTIVE)

Amebiasis may have been first recognized as a deadly disease by Hippocrates (460 to 377 B.C.), who described a patient with fever and dysentery. Later, the *Old Testament* and Huang Ti's *Classic in Internal Medicine* (140 to 87 B.C.) made reference to dysentery (107). The early literature of *E. histolytica* research has been reviewed by Kean (107) and by Clark et al. (46). Milestones in the study of *E. histolytica* and amebiasis were its description by Losch in 1873, the delineation of ame-

* Corresponding author. Mailing address: Division of Infectious Diseases and International Health, University of Virginia Health System, MR4 Building, room 2115, Lane Rd., P.O. Box 801340, Charlottesville, VA 22908-1340. Phone: (434) 924-5621. Fax: (434) 924-0075. E-mail: wap3g@virginia.edu.

bic liver abscess and colitis by Osler and his colleagues in 1890, its axenic culture by Diamond in 1961, and differentiation of pathogenic (*E. histolytica* sensu strictu) from nonpathogenic (*E. dispar*) *E. histolytica* in 1979 (188). In 1828, James Annesley first hinted at an association of dysentery and liver abscess, stating "... hepatic disease seems to be induced by the disorder of the bowels" (107). A clinical syndrome suggestive of intestinal disease was first widely recognized in the mid-1800s, although a parasitic etiology was not determined at that time. Suggestion of a parasitic etiology was first recorded in 1855 from a case where amebas were observed in a stool sample from a child with dysentery in Prague. In 1875, Fedor Losch isolated *E. histolytica* from the stool specimen of a patient with dysentery (107, 211).

Leonard Rogers designated emetine as the first effective treatment for amebiasis in 1912 (184). In 1913, Walker and Sellards demonstrated the infective cyst form of *E. histolytica* (228). In 1925, Dobell described the life cycle of *E. histolytica*. Brumpt proposed that *E. histolytica* and *E. dispar* were identical morphologically but that only *E. histolytica* was pathogenic for humans (30). Diamond's first axenic culture of *E. histolytica* in 1961 was a major turning point in our understanding of the cell biology and biochemistry of *E. histolytica* (50). In 1978, Sargeant and colleagues reported that *E. histolytica* and *E. dispar* species can be differentiated using zymodeme analysis (198).

With the application of a number of new molecular biology-based techniques, tremendous advances have been made in our knowledge of the diagnosis, natural history, and epidemiology of amebiasis. As more is discovered about the molecular and cell biology of *E. histolytica*, there is great potential for further understanding of the pathogenesis of amebiasis.

LIFE CYCLE AND BIOLOGY

Humans are the primary known reservoir for *E. histolytica* (105). The main source of transmission is the chronically infected human. Stools infected with the cyst form of the parasite may contaminate fresh food or water. The other common source of transmission is oral-anal sexual contact (158, 167). In addition, there is a suggestion of zoonotic transmission, but this is not clear (21, 22, 113). Experimental infections with *E. histolytica* have been produced in some animals such as dogs, cats, rats, monkeys, and other laboratory animals. These animals may also acquire human strains as a result of close contact with humans. Natural *E. histolytica* infections with strains morphologically similar to *E. histolytica* have been found in monkeys (21, 22). In one study, *E. histolytica* was found microscopically in stained fecal smears from six species of locally available Kenyan nonhuman primates (137). There may be some animal reservoirs of *E. histolytica* (dogs, monkeys, and probably pigs), but they represent a very small source of human infection compared with humans themselves (60). The importance of wildlife (primates) in zoonotic infections was studied by Jackson et al., who used zymodeme analysis to investigate whether *E. histolytica* occurs as a true zoonosis (96). However, there are no reports of sporadic zoonotic transmission of cases between infected animals and humans, although *E. histolytica* is most commonly associated with animals (cats, dogs, nonhuman primates, etc.).

Infective cysts may be spread by arthropods such as cockroaches and flies, suggesting that these insects are able to play a rare but important role in transmission (93, 230).

The life cycle of *E. histolytica* is simple. It consists of an infective cyst stage and a multiplying trophozoite stage. Humans are infected by ingesting these infective cysts, which travel through the gut lumen to the small intestine (terminal ileum), where each excysts to form eight daughter trophozoites. The trophozoites are motile forms, which adhere to and invade intestinal epithelial cells which line the gastrointestinal tract. Trophozoites move by extending creeping projections of cytoplasm, called pseudopodia, which pull them along. They also use these projections to surround and engulf food particles. The cytoplasm frequently contains many red blood cells (RBCs) that have been ingested. The trophozoites of *E. histolytica* always have a single nucleus. Trophozoites are easily destroyed in the outside environment, degenerating within minutes.

The trophozoite of *E. histolytica* can convert to a precyst form with a nucleus (*E. coli* precysts have two nuclei), and this form matures into a tetranucleated cyst as it migrates down and out of the colon. The precyst contains aggregates of ribosomes, called chromatoid bodies, as well as food vacuoles that are extruded as the cell shrinks to become a mature cyst. It is the mature cyst that, when consumed in contaminated food or water, is infectious. In the process of becoming tetranucleated, the nucleus of the cyst divides twice. Chromatoid bodies and glycogen vacuoles cannot be seen at this stage (46, 64, 105).

Cysts can remain alive outside the host for weeks or months, especially under damp conditions (129), but are rapidly destroyed at temperatures under -5°C and over 40°C (93). Cysts are not invasive, but trophozoites can penetrate the gastrointestinal mucosa (46). From there, the trophozoites are able to migrate to other organs, causing extraintestinal infections.

Like other protozoa, *E. histolytica* appears incapable of de novo purine synthesis. Biochemical analysis has indicated that glutathione is not present. For this reason, *E. histolytica* is different from higher eukaryotes. It also uses pyrophosphate instead of ATP (133). The cytoplasm of the cyst is vacuolated with numerous glycogen deposits, visible by permanent stains such as iron-hematoxylin, that decrease in size and number as the cyst matures. Also visible are crystalline arrays of aggregated ribosomes in the cytoplasm of the trophozoite (89, 183).

The gene organization of *E. histolytica* seems quite distinct from that of other eukaryotes. Although the structure of *E. histolytica* chromosomes is not yet known completely, electrokaryotypic analysis suggests that the chromosomes range in size from 0.3 to 2.2 Mb and gives a total haploid genome size of approximately 20 Mb (235).

A complete sequence map of the ribosomal DNA (rDNA) episome has been successfully completed (23, 201). Sehgal et al. (201) and Bhattacharya et al. (23) found that *E. histolytica* circular DNA is 24.5 kb. This sequence has proved quite useful for genotyping of the different enteric amebae (43, 217).

REDESCRIPTION OF *E. HISTOLYTICA* AND *E. DISPAR*

Early in the 20th century, Brumpt proposed that *E. histolytica* and *E. dispar* were distinct and suggested that they should be named as pathogenic and nonpathogenic species (30). Then



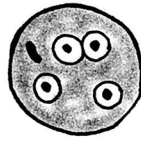
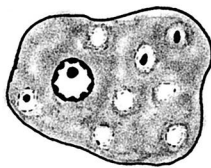
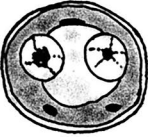
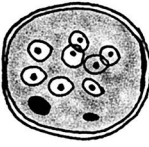
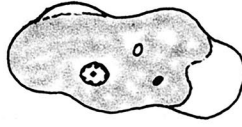


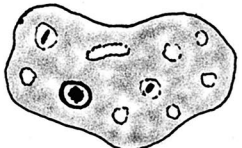
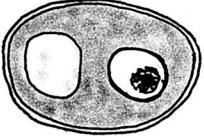
Organism	Trophozoite	Precyst	Cyst
<i>E. histolytica</i> <i>E. dispar</i> <i>E. moshkovskii</i>			
<i>E. coli</i>			
<i>E. hartmanni</i>			
<i>I. bütschlii</i>			

FIG. 1. Drawing of intestinal *Entamoeba* spp. showing morphological features. All illustrations are adapted from various sources.

Sargeant et al. demonstrated that these amoebas could be distinguished using isoenzyme typing and separated *E. histolytica* into pathogenic and nonpathogenic zymodemes (197). Later, Strachan et al. (212) showed that they were distinct immunologically, based on immunofluorescence with monoclonal antibodies. Finally, Tannich et al. (218) showed that pathogenic isolates of *E. histolytica* were genetically distinct from nonpathogenic isolates. Successive additions to the data indicating that they are distinct species resulted in the division of *E. histolytica* into *E. histolytica* sensu strictu and *E. dispar* (formerly called nonpathogenic *E. histolytica*) (14, 52).

E. histolytica (Schaudinn, 1903) and *E. dispar* (Brumpt, 1925) are currently recognized as distinct species (52), mostly based on genetic, biochemical, and immunological studies (52, 197, 212, 218). It is therefore possible to obtain more reliable and correct epidemiological data using molecular, biochemical, and immunological features, and these allow better diagnosis and treatment.

Clinically, *E. histolytica* is a cause of colitis and liver abscess but *E. dispar* is not. No cases have been documented where intestinal disease and colitis were caused by *E. dispar*. It cannot be forgotten that *E. moshkovskii* can colonize humans and is also identical in appearance to *E. histolytica*/*E. dispar* (80).

Differentiation of *E. histolytica* and *E. dispar* in stool samples is not easy on the basis of microscopy alone (52, 114, 218). Diagnosis of most of the previous infections as *E. histolytica* infections based on microscopic examination only can be re-

garded as defective and misleading. In reality, many of these organisms were probably genetically distinct from *E. dispar* (218). Currently, there are many molecular tools available to allow the differentiation *E. histolytica* from *E. dispar*, such as amoebic antigen and DNA detection enzyme immunoassay (EIA) and PCR (6, 28, 29, 59, 79, 178, 179, 192, 224, 238). Reclassification of *E. histolytica* and *E. dispar* is of great importance because it allow the clinician to focus on early identification and treatment of *E. histolytica* infection in the minority of patients who are at highest personal risk and pose a major public health problem (175).

Differentiation of *E. histolytica*/*E. dispar*/*E. moshkovskii* from *E. coli* and *E. hartmanni*

Commonly, description of *Entamoeba* species has depended on features of these parasites such as the size of the trophozoites and cysts, the number of nuclei in the mature cyst, the nuclear structure, etc. (Fig. 1; Table 1). *E. histolytica* is the only pathogenic *Entamoeba* species. It belongs to the subphylum Sarcodina, class Lobosea, and family Entamoebidae (119). *E. histolytica* exists in two morphologic forms: the tetranucleated hardy infective cyst (10 to 15 µm in diameter) and the more fragile, motile, vegetative and potentially pathogenic trophozoite (10 to 60 µm in diameter).

Mostly, trophozoites of *E. hartmanni* do not have a rounded form, are less than 12 µm in diameter, and are the smallest of

TABLE 1. Morphologic features and pathogenicity of intestinal amebae^a

Characteristics	<i>E. histolytica</i> , <i>E. dispar</i> and <i>E. moshkovskii</i> ^b	<i>E. hartmanni</i>	<i>E. coli</i>	<i>E. polecki</i>	<i>D. fragilis</i> ^c	<i>E. nana</i>	<i>I. bütschlii</i>
Trophozoites (size, nucleus, and movement)	15–20 µm; 1 nucleus; actively motile cytoplasmic protrusions, quickly finger shaped pseudopodium	8–10 µm; 1 nucleus; nonsuccessive	20–25 µm; 1 nucleus; slow movement, short and blunt pseudopodium	15–20 µm; 1 nucleus; motility resembles <i>E. coli</i>	7–12 µm; mono- and binucleate; pseudopodium hyaline broad leaflike serrated margins successive motility	7–9 µm; 1 nucleus, blunt and hyaline pseudopodium, slow movements	9–14 µm; 1 nucleus, slow movement, nonsuccessive, hyaline pseudopodium
Cysts (size, nucleus)	12–15 µm; mature cyst has 4 nuclei, immature cyst has 1 or 2 nuclei	6–8 µm; mature cyst has 4 nuclei; immature cyst has 1 or 2 nuclei; 2 nucleated cysts very common	15–25 µm; mature cyst has 8 nuclei, rarely 16 or more nuclei	10–15 µm; 1 nucleus, very rarely binucleate or quadrinucleate	No cyst stage	6–8 µm; 4 nuclei	10–12 µm; 1 nucleus
Appearance of trophozoites	Stained trophozoites fine, uniform granules of peripheral chromatin, and small central karyosome in nucleus; ingested RBC (<i>E. dispar</i> and <i>E. moshkovskii</i> are similar to <i>E. histolytica</i> trophozoites, sometimes ingested RBCs)	Nuclear structure similar to <i>E. histolytica</i> ; ingested bacteria; cytoplasm finely granular	Nuclear with irregular cluster of peripheral chromatin; large, irregular, eccentric karyosome	Nucleus with minute central karyosome, with fine granules of peripheral chromatin, finely granular cytoplasm; ingested bacteria	High percentage of binucleate trophozoites; nuclei without peripheral chromatin	Nucleus with large karyosome; no peripheral chromatin	Large central karyosome, granular cytoplasm
Appearance of cysts	Uniform size in having both karyosome and peripheral chromatin, typical nuclear structure, chromatoidal bars with squared or rounded ends	Typical nuclear structure, chromatoidal bars with rounded or squared ends	Typical nuclear structure, sliver-shaped or irregular chromatoidals	Mononucleate; large central karyosome; inclusion masses, chromatoid bars with pointed or angular ends	No cyst stage	Chromatin, 4 nuclei with large karyosomes and no peripheral chromatin	Large karyosome, eccentric refractile granules (basket nucleus), large compact glycogen, no peripheral chromatin
Pathogenicity	Pathogen (<i>E. dispar</i> and <i>E. moshkovskii</i> are nonpathogens)	Nonpathogen	Nonpathogen	Nonpathogen	Nonpathogen	Nonpathogen	Nonpathogen

^a Data from references 40, 64, 65, 80, and 116.^b *E. moshkovskii* is present in free-living protozoa.^c *D. fragilis* is a flagellate but resembles organisms within the amebae.

the *Entamoeba* trophozoites. Cysts are rounded, measuring less than 10 μm in diameter, and often contain only two nuclei. The cyst stage of *E. hartmanni* is characterized by a typical nuclear structure and many chromatoidal bars with rounded or squared ends in permanent stained smears of clinical specimens. Unstained cysts cannot be differentiated with any certainty from cysts of other species of *Entamoeba*. The nuclear structure of stained *E. hartmanni* trophozoites is similar to but smaller than that of *E. histolytica* trophozoites. Formerly, these parasites were known as a synonym of *E. histolytica* or "small-race" *E. histolytica*. Now they are known to be separate commensal or nonpathogenic parasites, and their infections do not need to be treated (129). Trophozoites of *E. coli* have large, irregular, and eccentric karyosomes, along with nuclei with irregular clumps of peripheral chromatin. Cysts of *E. coli* are spherical and have eight nuclei, irregular karyosomes, and peripheral chromatin (129). Trophozoites of both *E. coli* and *E. hartmanni* may include ingested bacteria.

CLINICAL FEATURES

The incubation period of intestinal amebiasis can vary, ranging from a few days to months or years (64, 105), but is generally 1 to 4 weeks (87). The wide spectrum of intestinal infection ranges from asymptomatic to transient intestinal inflammation to a fulminant colitis with an array of manifestations that may include toxic megacolon and peritonitis (175).

Asymptomatic Colonization

In up to 90% of *E. histolytica* infections, the symptoms are absent or very mild (71, 95). These patients have normal rectosigmoidoscopic findings, without a history of blood in stool samples. Cysts and trophozoites lacking ingested RBCs may be visible on microscopy (64). Interestingly, most individuals infected with *E. histolytica*, but not *E. dispar*, develop serum antibody responses to the parasite even in the absence of invasive disease (3). So far, *E. dispar* has never been recognized as a cause of colitis or amebic liver abscess, although infection with these amoebae is much more common than with *E. histolytica*, especially in developed countries. Unlike in Japan (143), where *E. histolytica* infection is a problem in men who have sex with men, in the United States and Europe, *E. dispar* has been identified in most of these infections (31, 220).

At present, the diagnosis of intestinal amebiasis in many countries relies commonly on microscopic examination of stool samples for the presence or absence of *E. histolytica/E. dispar*. Unfortunately, it is not clear what percentage of patients infected with *E. histolytica* are asymptomatic (114). It was thought that asymptomatic infection by *E. histolytica* is common; signs and symptoms of invasive amebiasis develop in approximately 10% of the infected population (68). Estimation of the true prevalence of amebiasis is not easy, because many studies were done with just one microscopic examination of a stool sample (13, 15, 98).

Asymptomatic *E. dispar* infections do not show evidence of disease or a serum anti-amebic antibody response, while symptomatic *E. histolytica* intestinal infection does show a systemic immune response (68).

Amebic Colitis and Dysentery

Although people can be asymptotically colonized with *E. histolytica*, they should be treated (92). Otherwise, some of these subjects, called cyst carriers, may be dangerous environmentally or may develop colitis after a period of months (68). Symptoms commonly attributed to *E. histolytica* colitis or dysentery are abdominal pain or tenderness and diarrhea (watery, bloody, or mucous). Diarrhea can occur with up to 10 (or even more) bowel movements per day, and fever occurs in one-third of the patients (175). Patients are often reluctant to eat, and one-fifth develop weight loss. The presence of Charcot-Leyden crystals, the lack of fecal leukocytes, and the presence of blood are the most common stool findings in the acute stage. A single stool examination has a low sensitivity of detecting the parasite (129). The best diagnostic method is detection of *E. histolytica* antigen or DNA in stool (78, 79). Clinical diagnosis of amebiasis is difficult because of the nonspecific nature of symptoms. It is easily confused with shigellosis (*Shigella dysenteriae* and *S. flexneri*) (83) and a number of other bacterial dysenteries (*Salmonella*, *Campylobacter*, and enterohemorrhagic and enteroinvasive *Escherichia coli*) that are common in tropical and subtropical countries (187). In addition, it is very important and difficult to differentiate the symptoms of noninfectious intestinal diseases (ischemic colitis, inflammatory bowel disease, diverticulitis, and arteriovenous malformations) from infectious diseases, in part because of the lack of fever in patients with amebic colitis (T. Dünzendorfer and J. Kasznica, Letter, Gastrointest. Endosc. 48: 450–451, 1998). Unfortunately, chronic nondysenteric intestinal amebiasis, which is characterized by intermittent diarrhea, flatulence, presence of seropositivity, and amoebae in the stool, can resemble ulcerative colitis, resulting in misdiagnosis and treatment with corticosteroids (171). Colonic findings in amebiasis have varied from thickening of the mucosa to flask-shaped ulceration (mostly in the cecum or appendix or near the ascending colon, but rarely in the sigmoidorectal area) (64).

The development of fulminant colitis (17, 88, 176), ameboma (8), cutaneous amebiasis (127, 134), and rectovaginal fistulas (126) can occur as complications of intestinal amebiasis. The mortality rate was found to be 29% in Bangladeshi children (231). An algorithm for the diagnostic approach to intestinal amebiasis is shown in Fig. 2.

Extraintestinal Amebiasis

Liver abscess is the most common manifestation of extraintestinal amebiasis. Amebic liver abscess (ALA) is associated with fever and abdominal pain in most patients. Right upper abdominal pain or tenderness occurs in the acute phase, while weight loss, fever, and more diffuse abdominal pain occur in the subacute phase (7). ALA occurs more commonly in adults than in children. *E. histolytica* has been identified microscopically in the stool samples of only a minority of patients (7, 102). Biochemically, many patients also have elevated peripheral white blood cell counts and alkaline phosphate levels (128, 139, 221). Unusual sites or complications of extraintestinal amebiasis include direct extension from the liver to the pleura (147) and/or pericardium (7, 24), brain abscess (49), and genitourinary amebiasis (130). Diagnosing liver abscess due to *E. histo-*

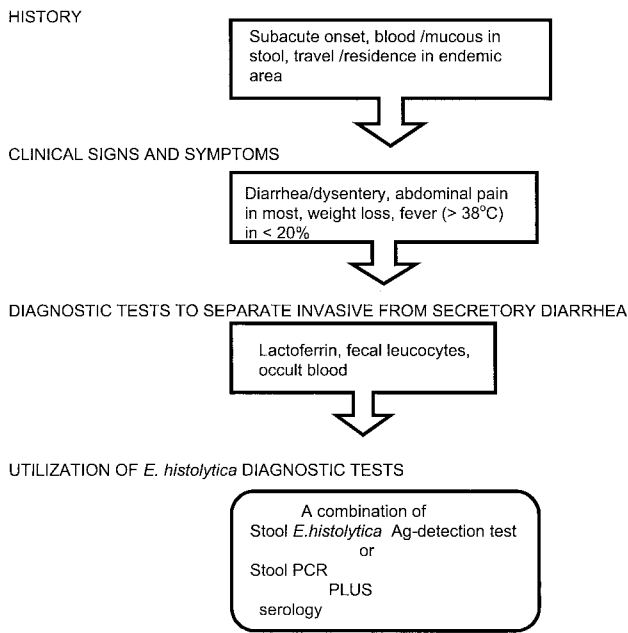


FIG. 2. Algorithm of intestinal amebiasis.

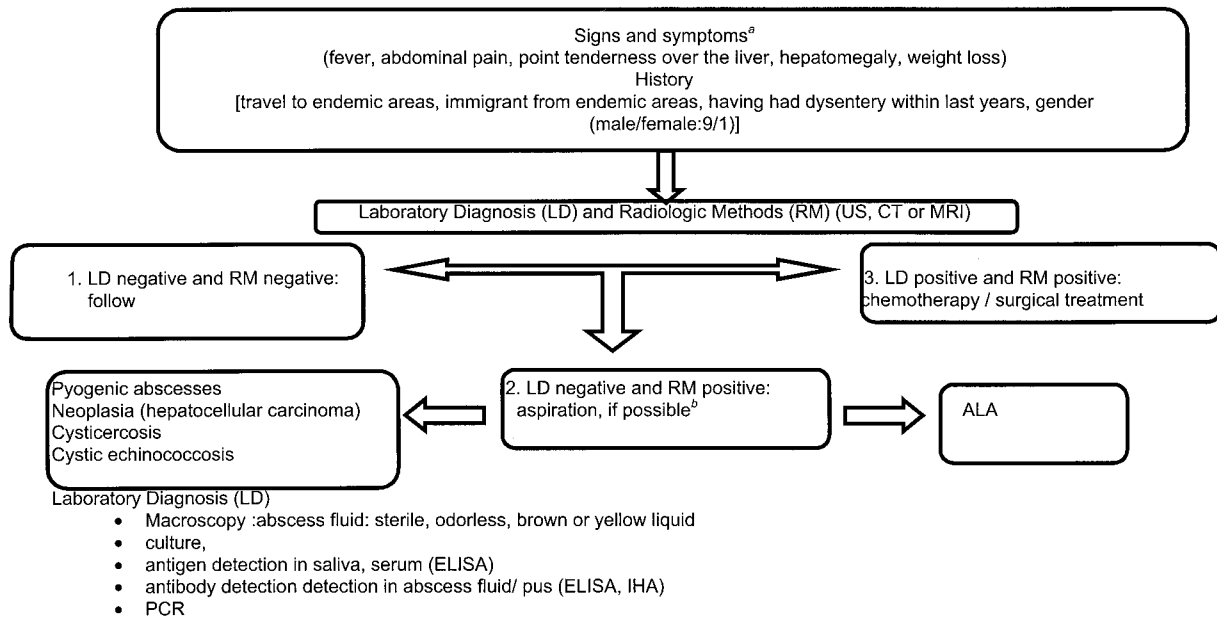
lytica may be difficult due to the lack of a history of intestinal disease within 1 year in many patients (7), coupled with lower than complete sensitivity of serologic analysis (102, 128) and the inability to distinguish amebic from pyogenic abscesses by imaging studies such as computed tomography or magnetic resonance imaging (7). The definitive diagnosis of ALA is

confirmed by positive serological tests for antibodies to *E. histolytica* and demonstration of the hepatic lesion by imaging techniques such as computed tomography ultrasonography, magnetic resonance imaging, and technetium-99 liver scan. For a more detailed discussion of ALA, the reader is referred to the recent review by Hughes and Petri (90). A diagnostic algorithm for patients with ALA is presented in Fig. 3.

EPIDEMIOLOGY

Amebiasis is responsible for approximately 100,000 deaths per year, mainly in Central and South America, Africa, and India, as well as for considerable morbidity manifested as invasive intestinal or extraintestinal clinical features (13, 15, 98). Worldwide, amebiasis is the third most common cause of death due to parasitic infection after malaria and schistosomiasis, as estimated by the World Health Organization (13, 229). Amebiasis infections are endemic in most temperate and tropical climates in the developing world. In some tropical countries, antibody prevalence rates (reflecting past or recent infection) exceed 50% (32, 36). The prevalence of amebiasis varies with the population of individuals affected, differing between countries and between areas with different socioeconomic conditions. Sometimes up to 50% of the population is affected in regions with poor sanitary conditions (32). It is thought that amebiasis directly affects over 50 million people, causing loss of manpower and subsequent economic damage (98).

In industrialized countries, amebiasis occurs in sexually active homosexual men (103, 140, 153, 232), immigrants (114), tourists who travel to areas of endemic infection (114, 232), institutionalized persons (35, 70, 138), and human immunode-



^a Acute clinical manifestations are associated with multiple amebic abscess
^b Aspiration contraindicated for cystic echinococcosis

FIG. 3. Practical algorithm for the patients with amebic liver abscess

FIG. 3. Practical algorithm for diagnosis of patients with amebic liver abscess.

TABLE 2. Virulence factors of *E. histolytica*

Virulence factor	Characteristics	Outcome	References
Cysteine proteinase	Degrade host proteins; provide attachment by degrading mucus and debris and stimulating host cell proteolytic cascades	These are fascinating possible targets for treatment of amebiasis due to their potential role in promoting invasion	108, 118, 125, 165
Amebapore	Stored in cytoplasmic granules, and released following target cell contact; forms ion channels in the membranes of both eukaryotic cells and phagocytosed bacteria	May be directly responsible for the cytolysis of host cells by the parasite	117, 118
Gal/GalNAc-binding lectin	Target cell adherence; contact-dependent cytotoxicity; complement resistance; capping and endocytosis; actin polymerization	This multifunctional virulence factor plays critical and important roles in the pathogenicity of parasite and is a particular candidate for use in diagnosis and vaccines	131, 168, 186

iciency virus HIV-positive individuals (124). The overall prevalence of *E. histolytica* infection in industrialized countries such as the United States has been estimated to be 4% per year in spite of the presence of some high-risk groups (171). *E. histolytica* and *E. dispar* have traditionally been classified by isoenzyme analysis (197, 198). Nowadays, in addition to this technique, typing by using monoclonal antibodies to surface antigens (antigen-based enzyme-linked immunosorbent assay [ELISA]) (78, 79, 161), PCR-specific analysis (59, 192, 224), and restriction fragment length polymorphism (ribotyping) (41) have been of great value in understanding the epidemiology of these parasites and in investigating disease outbreaks.

Epidemiological studies have shown that low socioeconomic status and unsanitary conditions are significant independent risk factors for infection. In addition, people living in developing countries have a higher risk and earlier age of infection than do those in developed regions (62). For example, in Mexico, 11% of the tested population aged 5 to 9 years was infected, with the prevalence of infection being higher in girls (9.34%) (32). Seroepidemiologic investigations of amebiasis in some tropical areas of Mexico indicate that while the prevalence of anti-amebic antibodies is relatively low in areas where epidemic transmission has not been reported, during epidemics an incidence rate of 50% is common, reaching as high as 80% during epidemics (129). Serosurveys suggest that long-term travelers residing in the developing regions where infection is endemic are at relatively increased risk of *E. histolytica* infection (152). In developed countries such as Italy, Japan, and United States, the prevalence of *Entamoeba* infection is between 4 and 21% in men who practice oral-anal sex with other men, but most infections are due to the noninvasive species, *E. dispar*, which does not require treatment (5, 11, 91; T. Takeuchi, E. Okuzawa, T. Nozaki, S. Kobayashi, M. Mizokami, N. Minoshima, M. Yamamoto, and S. Isomura, Letter J. Infect. Dis. **159**:808, 1989). Reported cases of invasive amebiasis in the homosexual population are rare, with most amebic infections in this population due to *E. dispar* (200).

PATHOGENICITY

About 90% of people who become infected with *E. histolytica* are asymptotically colonized (75). The factors that control the invasiveness of *E. histolytica* are incompletely understood. There are numerous possible virulence factors of *E. histolytica* such as cysteine proteinases, Gal/GalNAc-inhibit-

able lectin, and amebapore (reviewed in references 72 and 165) (Table 2). *E. histolytica* contains proteolytic enzymes (collagenase and neutral proteases) and cysteine proteases, which presumably facilitate its tissue invasion. The parasite also elaborates a range of enzymes on the amebic surface, including membrane-associated neuraminidase and β -glucosaminidase (166, 223, 234). There is a correlation between the virulence of *E. histolytica* and the secretion of electron-dense granules (26). Other components potentially necessary for pathogenesis of *E. histolytica* include a Ca^{2+} -binding protein and calmodulin (136, 237).

Infection occurs by ingestion of tetranucleated *E. histolytica* cysts. After a certain period of excystment, trophozoites colonize the large intestine. Trophozoites of *E. histolytica* adhere to the intestinal epithelium by interaction of the parasite Gal/GalNAc-inhibitable lectin with host-derived glycoproteins, which are high affinity ligands for amoebic lectin (162, 208). The Gal/GalNAc-binding lectin facilitates target cell adherence, complement resistance, and cytotoxicity (131). Monoclonal antibodies recognizing the lectin can strikingly affect both in vitro adherence and cytotoxicity (156, 185). The Gal/GalNAc lectin is a 260-kDa heterodimer consisting of heavy (170-kDa) and light (31- to 35-kDa) subunits linked by disulfide bonds (154, 155) and noncovalently associated with a 150-kDa intermediate subunit (40). The heavy, intermediate, and light subunits are encoded by multiple gene families (168). The heavy subunit is encoded by a family of five genes, *hgl1* to *hgl5* (168), located at five distinct loci, while the light subunit (31/35 kDa) is encoded by a family of six or seven *lgl* genes in the genome (132, 168, 217). Interestingly, the Gal/GalNAc lectins of *E. dispar* and *E. histolytica* have distinct structures and functions. The lectin of *E. dispar* shows decreased adherence, binding, and contact-dependent cytotoxicity (60, 154). So far, two heavy-subunit and four light-subunit genes have been observed in the lectin of *E. dispar* (54, 159). There is competition for binding to the c-Met hepatocyte growth factor receptor between the carbohydrate recognition domain and the hepatocyte growth factor. This interaction could explain the hepatotropism of *E. histolytica* (55).

Contact-dependent extracellular killing of neutrophils, macrophages, and erythrocytes by *E. histolytica* has been demonstrated (76, 189). The human colonic mucin layer may prevent the host cell from undergoing cytolytic activity by neutralizing the binding epitopes on the lectin during attachment. The

essential role of amebic lectin in adhesin and cytolysis was first implied in 1981 (173). Addition of Gal/GalNAc or galactose blocks the cytopathic effect on host tissue (76, 172).

LABORATORY DIAGNOSIS

We should ask ourselves about the extent to which improvement could be made in the performance of conventional or traditional diagnostic techniques. For several years, researchers have been searching for methods that will allow an accurate and reliable assessment of amebiasis. Laboratory diagnosis of amebiasis is usually based on microscopy and serological methods including enzyme-linked immunosorbent assay (ELISA), indirect hemagglutination assay (IHA), and latex agglutination. During the last decade, there has been remarkable development in molecular biology-based diagnostic procedures to detect *E. histolytica*, to the point where today they are the preferred approach. Accurate diagnosis is important not just for patients with dysentery but also for the 90% of *E. histolytica* infections that are asymptomatic, because infection may easily be transmitted from person to person, especially in developing countries which have poor hygienic conditions and inadequate water treatment (98).

Microscopy

Diagnosis of *E. histolytica* has historically relied on microscopic examination of protozoan morphology. Current microscopy- and histology-based identification frameworks, however, are unable to differentiate among protozoa with similar morphological features. Drawings of intestinal amebas (*E. histolytica*, *E. coli*, *E. hartmanni*, and *I. bütschlii*) showing their morphologic features are summarized in Fig. 1.

A separate problem is that the sensitivity and specificity of conventional microscopy on a single stool specimen for different species of *Entamoeba* have been shown in many studies to be less than optimal (64, 129). A "poor man's" way to distinguish *E. dispar* from *E. histolytica* microscopically is erythrophagocytosis.

Ingested RBCs in the cytoplasm may be visible; this finding is still considered diagnostic for *E. histolytica* in patients with dysentery. It may be used to distinguish between *E. histolytica* and *E. dispar*. Mostly, *E. histolytica* will be diagnosed on the basis of protozoan morphology without the presence of RBCs (64). In fact, classical microscopy does not allow of the invasive protozoan (*E. histolytica*) to be distinguished from the noninvasive one (*E. dispar*) unless erythrophagocytosis (the presence of ingested RBCs in trophozoites) is seen during microscopic examination. This classical feature has long been considered the definitive diagnostic criterion for *E. histolytica*.

Also, it must be kept in mind that RBCs may be ingested but do not frequently appear in chronic amebic infections (129). In an in vitro study, *E. histolytica* was found to have a significantly higher phagocytic rate of ingested RBCs than do the nonpathogenic *Entamoeba* species (*E. invadens* and *E. moshkovskii*) (222). González-Ruiz et al. (73) reported that the presence of *E. histolytica* organisms containing ingested RBCs is a diagnostic indication of active invasive amebiasis. However in some cases *E. dispar* is also observed to contain RBCs (85).

Trophozoites are more frequently observed in fresh stool

specimens that contain mucus, pus, and trace amounts of blood. In wet mounts, the trophozoite nuclei cannot easily be seen (164). Charcot-Leyden crystals (products of degenerated eosinophils) and clumped RBCs can be seen in a wet mount preparation (64, 105, 129). Definitive diagnosis of intestinal amebiasis requires high levels of skill and experience (86, 229); inadequate training and diagnostic testing may lead to misdiagnosis (64; L. Doganci, M. Tanyuksel, and H. Gun, Letter, *Lancet* **350**: 670, 1997). Motility of *E. histolytica* in fresh preparations usually occurs in a linear (not random) fashion, with the clear hyaline ectoplasm flowing to form blunt-ended pseudopodia, which guide the endoplasm containing the nucleus (164). If a fresh stool specimen cannot be examined immediately, it should be preserved with a fixative such as polyvinyl alcohol or kept cool (4°C). Occasionally motile trophozoites are seen even after 4 h at this temperature (170, 229), although the trophozoites generally disintegrate rapidly in unfixed stool specimens (164).

Stool specimens can be examined either unstained or stained with Lugol's or D'Antoni's iodine. Iodine stains make the nucleus perfectly visible. The appearance of chromatoid bodies is the same as in wet mount preparations (164). Although several other stains, including Giemsa, methylene blue, Chorzole black E, Wright's, and iodine-trichrome, may be used successfully, Wheatley's trichrome staining or one of the modified iron hematoxylin stains for permanent smears has been suggested for routine use in the diagnosis of *E. histolytica*/*E. dispar* (63, 64, 138a, 164, 171, 229). Shetty and Prabhu found that D'Antoni's iodine was much better than saline or buffered methylene blue for detection of *E. histolytica* cysts while saline and buffered methylene blue were equally good for detection of *E. histolytica* trophozoites (206). There are several factors that adversely affect the results of microscopy. These include lack of well-trained microscopists; delayed delivery to the laboratory (motility can cease and trophozoites can lyse within 20 to 30 min); difficulty in differentiation between nonmotile trophozoites and polymorphonuclear leukocytes, macrophages, and tissue cells; inadequate collection conditions (a clean, dry, wide-mouth plastic container not contaminated with urine and water is needed); interfering substances such as antibiotics (tetracyclines or sulfonamides), laxatives, antacids, cathartics (magnesium sulfate), antidiarrheal preparations, (kaolin or bismuth), or enemas (soap); inadequate number of specimens collected (at least three specimens are needed); lack of preservation of stool specimens with fixatives (polyvinyl alcohol, Schaudinn's fluid, merthiolate-iodine-formalin, sodium acetate-acetic acid-formalin, or 5 or 10% formalin is needed); and presence of other amebae (*E. dispar* and *E. moshkovskii* are identical and *E. coli* and *E. hartmanni* are similar in appearance to *E. histolytica*) (64, 114, 229).

Biochemical Methods: Culture and Isoenzymes

Boeck and Drbohlav first cultivated *E. histolytica* in a diphasic egg slant medium. Today, the National Institutes of Health modification of Locke-egg medium has been used in some research laboratories. However, Robinson medium (181) and TYSGM-9 of Diamond (51) are more often used for xenic cultivation of *E. histolytica*. After being used successfully axenic cultivation by Diamond, TYI-S-33 (53) is one of the most

widely used axenic media. This cultivation issue was reviewed in detail by Jensen (100) and by Clark and Diamond (45). It has been long accepted that culturing *E. histolytica* from stool or liver abscess samples and performing the isoenzyme analyses are mostly unsatisfactory and not useful in routine laboratory practice (202). Also, species identification based on culture and zymodeme analyses can never exclude the danger of one species outgrowing the other in cultures of specimens from mixed infections (59).

Molecular biology-based diagnosis (PCR) seems to be a modern research tool that may become the technique of choice in the future studies, because establishment of these protozoa in culture is not a routine process and is less sensitive than microscopy in detection. In contrast to bacteria, maintaining these protozoa in culture is not easy and requires labor-intensive effort in the diagnostic laboratory. In summary, it should be understood that cultures of *Entamoeba* are primarily research tools rather than diagnostic ones (45). Because of its emerging importance, especially with respect to diagnosis, it is appropriate to mention *E. dispar* here. It was previously called "nonpathogenic *E. histolytica*" but now is recognized as a distinct species (52). It can be grown in xenic culture just as easily as *E. histolytica*. However, most isolates grow poorly in monoxenic culture, and few have been reported in axenic culture (38, 111). Another problem is the elimination of unwanted organisms in the cultivation process. Some undesired organisms, especially *Blastocytis hominis*, can overgrow the culture, and *E. histolytica* is frequently missed on stool examination. Additionally, it is very important to remember that any culture giving a negative result may still contain *E. histolytica* (45).

Classically, to differentiate "pathogenic" and "nonpathogenic" forms, isoenzyme patterns obtained from amebic culture lysates were widely used (16, 69, 84, 194, 195, 198, 199). A total of 24 different zymodemes, composed of 21 zymodemes from human isolates (9 *E. histolytica* and 12 *E. dispar*) and 3 zymodemes from experimental culture amebic strains (25, 193, 196), have been recognized. These zymodemes consist of electrophoretic patterns of malic enzyme, hexokinase, glucose phosphate isomerase, and phosphoglucosmutase isoenzymes (194, 198). However, all but two zymodemes appear not to be reliable due to contributions of the zymodeme pattern from bacteria in the xenic culture (97). Zymodeme analysis is reliable in the differentiation of *E. histolytica* from *E. dispar*, however, because of genetic differences in hexokinase in the two species (145). Although the analysis has some disadvantages such as difficulty in performing the test and time-consuming procedures, use of the biochemical methods (identification of different zymodemes) in regions of endemic infection can lead to a better understanding of epidemiological condition (71).

Antibody Detection

Most people with intestinal amebic infection in areas of endemicity have been exposed to *E. histolytica* many times. Symptoms commonly attributed to *E. histolytica* may be absent in the majority of cases. This situation makes definitive diagnosis by antibody detection difficult because of the inability to distinguish past from current infection (32, 68). Serological tests are more helpful for the identification of *E. histolytica* infection in industrialized nations, where *E. histolytica* infec-

tion is not common (142, 227, 232). In all cases, the combination of serological tests with detection of the parasite (by antigen detection or PCR) offers the best approach to diagnosis (79).

Serum antibodies to *E. histolytica* can be detected in 75 to 85% of patients with symptomatic *E. histolytica* infection. Assays that have been used so far involve IHA (48, 91, 110, 149, 205, 210), counterimmunoelectrophoresis (CIE) (19, 66, 115, 177, 203, 205, 210), amoebic gel diffusion test (94), complement fixation (CF) (110, 123), indirect fluorescence assay (IFA) (48, 66, 94, 213, 219, 233), latex agglutination (48, 77, 110, 122, 123), and ELISA (10, 18, 27, 109, 110, 122, 123, 146, 148, 215) (Table 3).

Test for antibodies to *E. histolytica* should be done mostly by laboratories which can demonstrate technical expertise and understanding of the several serological tests that should be applied simultaneously with culture and PCR when extraintestinal amebiasis is suspected.

ELISA. ELISA is among the most popular methods used in diagnostic laboratories throughout the world. The kinetics of the antibody response to *E. histolytica* is known in detail. The technique is widely thought to be sufficient for clinical purposes (particularly in diagnosing ALA patients), since the value of specific antibodies detected in symptomatic patients is thought to be high. However, the lack of an accurately defined "gold standard" has hindered any objective assessment of the sensitivity of the antibody detection techniques currently in use. The sensitivity of detection of specific antibodies to *E. histolytica* in serum is reported to be near 100%, which is promising for diagnosis of ALA (110, 174, 239). Serum anti-lectin immunoglobulin G (IgG) antibodies could be present within 1 week after the onset of symptoms of patients with amebic colitis and ALA, with a value over 95% (1, 174). Serological test results are sometimes false positive (191), and the test should be repeated if the result is doubtful.

On the other hand, a decision about whether a person was recently infected is often made on the basis on serological tests using a single sample of serum. The presence of IgG antibodies in a single sample of serum does not indicate whether the infection was acquired before or during travel to an area of endemic infection (161). It is important to establish better diagnostic methods to distinguish recently acquired infections from those that occurred prior to returning from the area of endemicity. The presence of individual antibodies (IgG, IgM, and IgA) in a person living in an area of endemicity should be examined in addition to performing serological tests to determine when the infection occurred (4).

It is important to note that mucosal IgA anti-lectin antibodies are associated with immune protection against *E. histolytica* colonization and may not serve as indicators of antibody protective efficacy (81). Current PCR methods are considerably affected by fecal components and lack of uniformity. These samples also include many substances that inhibit PCR, yielding false-negative results (144). Of the recommended serological tests such as ELISA, those that demonstrate the presence of serum anti-lectin antibodies are the most frequently used for diagnosis of patients with ALA and asymptomatic *E. histolytica* infection (68, 78, 174). Accurate diagnosis of a recently acquired infection is crucial for clinical management of patients with invasive amebiasis. Moreover, the antibody detection tests

TABLE 3. Commercial assays used to identify *E. histolytica*

Assay	Sensitivity (%)	Specificity (%)	Manufacturer
Antigen detection			
TechLab <i>E. histolytica</i> II	100 ^a	~95 ^a	TechLab, Blacksburg, Va.
TechLab <i>Entamoeba</i> test	80 ^b –95 ^c	99 ^b –93 ^c	TechLab, Blacksburg, Va.
ProSpecT <i>Entamoeba histolytica</i> microplate assay	90.3 ^d	97.7 ^d	Alexon-Trend Inc., Ramsey, Minn.
<i>Entamoeba</i> CELISA-PATH	KP ^o (94)	KP (100)	Cellabs Pty Ltd., Brookvale, Australia
<i>Entamoeba</i> -CELISA-Screen	KP (87.7)	KP (98.3)	Cellabs Pty Ltd., Brookvale, Australia
Wampole <i>E. histolytica</i> Test	KP (94.7) ^e	KP	Wampole Laboratories, Cranbury, N.J.
Merlin Optimun S ELISA	100 ^f		Merlin Diagnostika, Bernheim-Hersel, Germany
Triage parasite panel	68.3 ^g	100 ^g	BIOSITE Diagnostics, San Diego, Calif.
	83.3 ^h	100 ^h	
	96 ⁱ	99.1 ⁱ	
Amibiase Ag EIA	NP ^p	NP	Biotrin Int., Dublin, Ireland
Antibody detection			
IHA Cellognost Amoebiasis	72.2 ^j –100 ^k	99.1 ^j –90.9 ^k	Behring Diagnostics, Marburg, Germany
Amibiase Serology Microwell EIA	92.5 ^l	91.3 ^l	LMD Laboratories Inc., Carlsbad Calif.
BLA-Bichrolatex-Amibe	98.3 ^m	96.1 ^m	Fumouze Diagnostics, Levallois-Perret, France
IHA	93.4 ^m	97.5 ^m	Fumouze Diagnostics, Levallois-Perret, France
The Melotest Amoebiasis EIA	NA ⁿ	NA ⁿ	Melotec, S.A., Barcelona, Spain

^a Compared to culture and isoenzyme analysis (78).

^b Compared to culture (85).

^c Compared to zymodeme analysis (85).

^d Compared to microscopy (99).

^e Correlation to zymodeme analysis.

^f Correlation of TechLab *E. histolytica* for detection of *E. histolytica*, but not *E. dispar* (161).

^g Compared to ProSpecT ELISA (160).

^h Compared to microscopy (160).

ⁱ Compared to O&P and permanent stains (67).

^j Reference 91.

^k Reference 161 (with use of *E. histolytica* antigen detection as the reference standard).

^l Reference 204.

^m Reference 180.

ⁿ Reference 182. NA, not available.

^o KP, kit prospectus.

^p NP, not published data.

seem to be time- and cost-effective (112). Another difficulty also exists for the detection of antibodies to *E. histolytica*: serological methods cannot be performed in a timely manner. The laboratory diagnosis of amebiasis is virtually based on the presence of anti-lectin IgG (which appears later than 1 week after onset of symptoms) or on the existence of positive *E. histolytica* IgM antibodies (especially during the first week of amebic colitis) (3). In diagnosis, lectin antigenemia is essential for detection anti-lectin antibodies. In a study including 100 patients with amebic colitis, anti-lectin IgM and anti-lectin IgG were measured by ELISA, and their sensitivities for the first week were found to be 45.1 and 5.6% respectively. They increased to 79.3 and 93.1%, respectively, for period longer than 1 week (3). Due to the potential pitfalls of relying solely on a low-specificity serological test, a discriminatory method to allow such distinctions has been reported by Jackson et al. (95) and by others (101) because patients with *E. dispar* infections can sometimes have high titers of anti-amebic antibodies.

When amebic cyst carriers contact HIV infection, latent amebiasis may become reactive, progressive, and invasive (121).

It was reported that innate immunity was associated with the absence of serum anti-*E. histolytica* IgG (82). Further studies are required to resolve this interesting findings, and the value of stool anti-CRD (carbohydrate recognition domain) IgA lectin antibodies in amebiasis patients at study enrollment was linked to a lower incidence of new *E. histolytica* infections (82).

IHA. Diagnosis of invasive amebiasis, particularly for HIV-infected patients (due to their declining T-cell immunity), is very important (91, 120, 121). Detection of *E. histolytica* antibodies by any serological test might facilitate this difficult diagnosis, which frequently is made too late. In a study, 18 patients with invasive amebiasis were diagnosed (13 with amebic colitis by histopathological techniques and 9 with ALA by imaging techniques), even though isoenzyme analysis was not performed (91) by use of IHA. IHA was shown to be a highly specific (99.1%) and helpful diagnostic tool in HIV-infected patients presenting with gastrointestinal symptoms (91). It has been observed that the sensitivity of IHA was 72.4% in patients with ALA 1 and 2 weeks after the onset of symptoms, but it was 86.9% at the end of week 3. Also, it was found by IHA that the average antibody concentration began to decrease in the sixth month (110). A PCR approach may be helpful if the serum IHA titer is not elevated significantly in HIV-infected patients with ALA (121).

In a study, 41 (82%) of 50 patients with ALA were positive by IHA. Three sera (12%) from other parasitic and miscellaneous controls gave false-positive reactions by IHA. The positive and negative predictive values of IHA were reported to be 93.1 and 83.9%, respectively (149).

Low sensitivity should be expected, since anti-amebic antibody might not be produced in HIV-infected patients. Al-

though IHA is easy to perform, its lower sensitivity may lead to false-negative results compared to ELISA (191).

Kraoul et al. (112) compared the sensitivity and specificity of three tests for the detection of antiamebic antibodies: IHA (Fumouze Diagnostics), latex agglutination (Fumouze Diagnostics), and ELISA (LMD Labs). They found the respective values for these tests to be 97.6, 90.7, and 93% sensitivity and 97, 95, and 100% specificity.

CIE. In the past, CIE and IE were most commonly used. In CIE, *E. histolytica* HK-9 antigen is reacted against heat-inactivated serum in 1% agarose plates. Visualization of a precipitin band(s) against *E. histolytica* antigen in the serum of a patient with amebiasis is evaluated as a positive reaction, and the absence of a precipitin band is interpreted as a negative reaction. A total of 110 serum samples (30 patients with ALA, 30 patients with amebic colitis, and 50 control serum samples) were studied by both ELISA and CIE. Anti-amebic antibodies were positive by ELISA in 10% of sera in patients with amebic colitis, whereas no antibody was detected by CIE. For all the control sera, both assays gave negative results. Sera of ALA patients gave 66.6 and 90% positive reactions by CIE and ELISA, respectively. It was concluded that countercurrent immunoelectrophoresis (CIE) was not more sensitive than ELISA in ALA diagnosis (177). A total of 153 patients with intestinal amebiasis were studied; 27 sera from 84 patients with early-confirmed cases and 12 sera from 69 patients with non-early-confirmed cases were positive for antiamebic antibodies by using CIE. Of the samples from the 30 ALA patients, 20 were positive, but for the 29 patients with nonconfirmed cases, 4 samples was also positive by CIE. In addition, 48 sera from patients with nonamebic dysentery, 100 sera from healthy controls, and 75 sera from asymptomatic cyst carriers were found to be negative by CIE (19). Sheehan et al. (203) reported that detection of antibody to extraintestinal *E. histolytica* by CIE was 100% sensitive in seven patients with invasive amebiasis and 25% sensitive in eight patients with asymptomatic intestinal amebiasis. The results showed that the CIE test may be specific in invasive amebiasis but has low sensitivity in intestinal amebiasis and is more time-consuming than ELISA. Traditionally, IHA has been used as the standard serological test, but ELISA has been proposed as an alternative that is rapid, simple, and more sensitive. One group reported the detection of *E. histolytica*-specific antibody in amebiasis patients with ALA using the gel diffusion precipitation test, IHA, and CIE. Of 21 clinically suspected cases of ALA investigated, all could be detected by CIE and IHA, with good correlation between all the tests, and showed a high degree of sensitivity. However, about 30% of control sera had *E. histolytica* antibodies by CIE and IHA (205). In one study, antibodies measured by CIE became detectable within 5 days (the seropositive rate was 66.7%) after the onset of clinical symptoms. The titers increased rapidly and reached a maximum by approximately 2 weeks (on day 11, the seropositive rate was 100%) (190).

Antibody titers do not appear to correlate with the severity of amebiasis or with the response to therapy. Vinayak et al. (225) reported that no correlation was found between high serological titers and severity of amebic disease. Even following successful treatment of ALA, a constant level of antibodies was observed commonly in serological tests (latex agglutination, IHA, and CF) (110, 151, 207). In CIE and agarose gel

diffusion, antibodies may persist for 6 months or much longer (94, 104, 209). The gel diffusion precipitin test detected antibodies for up to 4 years following infection (150).

Antigen Detection

Antigen-based ELISA have several significant advantages over other methods currently used for diagnosis of amebiasis: (i) some of the assays differentiate *E. histolytica* from *E. dispar*; (ii) they have excellent sensitivity and specificity; (iii) they are readily usable by even nonexperienced laboratory personnel; and (iv) the use of a 96-well plate format enhances their potential as large-scale screening tools in epidemiological studies, such as waterborne outbreak situations (74).

The Triage parasite panel (BIOSITE Diagnostics, San Diego, Calif.) is a single immunochromatographic strip coated with monoclonal antibodies specific for *E. histolytica*/*E. dispar* antigen (29 kDa) and for antigens of *Giardia lamblia* and *Cryptosporidium parvum* (67, 160). Garcia et al. (67) reported that the sensitivity and specificity of Triage were 96 and 99.1%, respectively, for *E. histolytica*/*E. dispar* in 99 stool specimens compared to a stool ova and parasite (O&P) examination. In another study, although the specificity of the Triage was very high (100%), the specificity was low (68.3%) compared to the Alexon ProSpecT ELISA (160). The Alexon ProSpecT ELISA shares with the Triage panel the inability to distinguish *E. histolytica* from *E. dispar*. Jelinek et al. reported that the sensitivity and specificity of the ProSpecT ELISA were 73.5 and 97.7%, respectively, compared to microscopy for *E. histolytica*/*E. dispar* in German travelers returning from vacation trips abroad (99).

Today, antigen-based ELISA kits that are reported to be specific for *E. histolytica* use monoclonal antibodies against the Gal/GalNAc-specific lectin of *E. histolytica* (*E. histolytica* test II; TechLab, Blacksburg, Va.) or monoclonal antibodies against the serine-rich antigen of *E. histolytica* (Optimum S kit; Merlin Diagnostika, Bornheim-Hersel, Germany). In addition to these clinical assays, research-based detection has included the use of a monoclonal antibody against a lysine-rich surface antigen (157), a lipophosphoglycan (135), a salivary 170-kDa adherence lectin antigen (2), and an uncharacterized antigen (236).

Long-term collaborative studies by our research group in Bangladesh, an area where *E. histolytica* is endemic, have led to the development of two diagnostic kits, the *Entamoeba* test (*E. histolytica*/*E. dispar* complex) and the *E. histolytica* test II for stool specimens (15). These tests are based on detection of the Gal/GalNAc lectin of *E. histolytica* or *E. dispar* within specimens. Several studies using the *Entamoeba* test (*E. histolytica*/*E. dispar* complex) and the *E. histolytica* test II found sensitivities and specificities varying from 80 to 99% and 86 to 98%, respectively (83, 85). Haque et al. (79) reported that the overall correlation between results of the TechLab antigen detection test and PCR from stool specimens for detecting *E. histolytica* infection was 94%.

Other specimens in which amebic antigens have been detected include saliva, serum, and abscess fluid. Haque et al. detected Gal/GalNAc lectin in the sera of most patients with ALA by using the TechLab *E. histolytica* test II kit (90). Abd-Alla et al. (2), using ELISA, detected the adherence lectin

TABLE 4. Sensitivity and specificity of tests of diagnosis for amebiasis^a

Test	Colitis		Liver abscess
	Sensitivity	Specificity	Sensitivity
Microscopy (stool)	<60%	10–50%	<10%
Microscopy (abscess fluid)	NA ^b	NA	<25%
Culture with isoenzyme analysis	Lower than antigen or PCR tests	“Gold standard”	<25%
Stool antigen detection (ELISA)	>95%	>95%	Usually negative
Serum antigen detection (ELISA)	65% (early)	>90%	~75% (late), ~100% (first 3 days)
Abscess antigen detection (ELISA)	NA	NA	~100% (before treatment)
Salivary antigen detection	Not done	Not done	70%
PCR (stool)	>70%	>90%	Not done
Serum antibody detection (ELISA)	>90%	>85%	70–80% (acute), >90% (convalescent)

^a Reprinted from reference 220 with permission of the publisher.

^b NA, not available.

antigen in saliva samples of ALA patients. This assay was found to be 22% sensitive and 97.4% specific. Amebic antigen was detected by ELISA (prepared with polyclonal antibodies) in 41 (97.6%) of 42 pus specimens from ALA patients (239). CIEP had low sensitivity (76%) compared to ELISA (93%) (226) and solid-phase radioimmunoassay (100%) (163) for detection of circulating antigen in liver abscess patients. Parija and Karki (149) evaluated the CIEP test for detection of amebic antigen in the serum in diagnosis of ALA. While the CIEP test detected amebic antigen in the sera of 38 (76%) of 50 ALA patients, it failed to detect antigen in 12 (24%) patients with ALA found positive for antibodies by the IHA test.

In summary, stool antigen detection tests today offer a practical, sensitive, and specific method for the clinical laboratory to detect intestinal *E. histolytica*. All of the current tests suffer from the fact that the antigens detected are denatured by fixation of the stool specimen, limiting testing to fresh or frozen samples. Detection of circulating antigen in the serum is a promising yet still experimental approach to the diagnosis of amebic liver abscess.

Molecular Biology-Based Diagnostic Tests and PCR

To circumvent the problems of microscopic or culture-based diagnosis and take advantage of the sensitivity, specificity, and simplicity of newer techniques, molecular biology-based technology has become commonly used.

The PCR method offers sensitivity and specificity for the diagnosis of intestinal amebiasis that rivals that of antigen detection (192). Its disadvantages are that it takes longer than EIA, is technically complex, and is costly (79). Thus, it may not yet be well suited for use in developing countries where amebiasis is endemic because of the specialized skills and equipment that it requires (79). However it potentially will become the “gold standard” by which other diagnostic techniques (microscopy, antibody detection, etc.) are measured. In research on genetic polymorphism of *E. histolytica*, PCR is a powerful tool (20). It should not be forgotten, however, that PCR is susceptible to cross-contamination and to false-negative results due to inhibitors of DNA polymerase in stool samples (59).

Many investigators have reported successful application of PCR to the diagnosis of amebiasis (6, 28, 29, 59, 79, 178, 179, 192, 224, 238). Some investigators have improved the PCR-solution hybridization enzyme-linked immunoassay technique

and have suggested that it is more practical in the study of the complex ecology of amebiasis (9, 28, 29, 224). PCR is also very helpful for ALA diagnosis when aspirated pus is available, since it appears not to require protease treatment for DNA isolation (238).

Methods of DNA extraction from stool specimens and specific primers are key to successful PCR diagnosis. A commercially available DNA isolation kit (Qiagen, Hilden, Germany) is recommended due to its ease and success (224). One major advantage seems to be that formalin-fixed stool specimens can be used for DNA extraction. This has the benefits of safe handling, storage and transportation (178, 179). With this technique, one *E. histolytica* trophozoite/mg of stool can be detected (106). Fixation with 1 to 10% formalin is very important in the storage, transportation, and fixation of stool specimen. No reduction in the ability to perform PCR amplifications of *E. histolytica* DNA fixed in 1 to 10% formalin was noted for 7 days (169). Núñez et al. (141) described multiplex PCR amplification for the detection and characterization of both *E. histolytica* and *E. dispar* in stool samples by using two pairs of specific primers combined in a single reaction mixture. This novel approach had 94% sensitivity and 100% specificity. It showed an *E. histolytica* and *E. dispar* coinfection rate of 24.5% in the Mexican children studied.

Riboprinting, the restriction site polymorphism analysis method involving amplification followed by restriction fragment length polymorphism analyses of the small- and large-subunit rDNA, is a very useful tool to evaluate different *Entamoeba* species. In this method, fragments can be seen in agarose gels after amplified rDNA is digested with restriction enzymes (37, 39, 41). Riboprints of *E. histolytica* can be easily distinguished from those of other amebas, especially *E. dispar*, by using the restriction enzymes *Xba*I, *Rsa*I, *Taq*I, *Sau*96I, and *Dde*I (39, 42, 44). Ribotyping has been of great value in understanding the epidemiology of *Entamoeba* species and in investigating disease outbreaks; however, the process of ribotyping is difficult and time-consuming.

CONCLUSIONS

Today the diagnosis of invasive amebiasis is most commonly attempted by a combination of stool O&P examination and serological testing and, where indicated, by colonoscopy and biopsy of intestinal amebic lesions or by drainage of liver ab-

scuss. While serological testing remains an important tool, numerous studies have demonstrated the inadequacies of microscopic examination for *E. histolytica* for diagnosis of both amebic colitis and liver abscess. Better approaches than O&P include either antigen detection or PCR to detect *E. histolytica* in stool. Current antigen detection tests suffer from the need to examine fresh or frozen (not preserved) stool specimens, while PCR techniques today remain impractical in many developing countries. The detection of amebic markers in the sera of patients with amebic colitis and liver abscess appear promising but is still just a research tool (Table 4). Rapid sensitive and appropriate techniques for the diagnosis of amebiasis remain a major public health priority for the developing world.

ACKNOWLEDGMENTS

We thank Shannon Beck and David Beck for reviewing the manuscript and Mehmet Yapar for contributing drawings.

REFERENCES

- Abd-Alla, M. D., A. M. el-Hawey, and J. I. Ravdin. 1992. Use of an enzyme-linked immunosorbent assay to detect anti-adherence protein antibodies in sera of patients with invasive amebiasis in Cairo, Egypt. *Am. J. Trop. Med. Hyg.* 47:800-804.
- Abd-Alla, M. D., T. F. Jackson, S. Reddy, and J. I. Ravdin. 2000. Diagnosis of invasive amebiasis by enzyme-linked immunosorbent assay of saliva to detect amebic lectin antigen and anti-lectin immunoglobulin G antibodies. *J. Clin. Microbiol.* 38:2344-2347.
- Abd-Alla, M. D., T. G. Jackson, and J. I. Ravdin. 1998. Serum IgM antibody response to the galactose-inhibitable adherence lectin of *Entamoeba histolytica*. *Am. J. Trop. Med. Hyg.* 59:431-434.
- Abd-Alla, M. D., and J. I. Ravdin. 2002. Diagnosis of amoebic colitis by antigen capture ELISA in patients presenting with acute diarrhoea in Cairo, Egypt. *Trop. Med. Int. Health* 7:365-370.
- Aceti, A., A. Pennica, G. Ippolito, D. Moretto, G. Rezza, F. Titti, and C. A. Perucci. 1987. Antiamebic antibodies in homosexual men. *N. Engl. J. Med.* 316:692.
- Acuña-Soto, R., J. Samuelson, P. De Girolami, L. Zarate, F. Millan-Velasco, G. Schoolnick, and D. Wirth. 1993. Application of the polymerase chain reaction to the epidemiology of pathogenic and nonpathogenic *Entamoeba histolytica*. *Am. J. Trop. Med. Hyg.* 48:58-70.
- Adams, E. B., and I. N. MacLeod. 1977. Invasive amebiasis. II. Amebic liver abscess and its complications. *Medicine* 56:325-334.
- Adams, E. B., and I. N. MacLeod. 1977. Invasive amebiasis. I. Amebic dysentery and its complications. *Medicine* 56:315-323.
- Aguirre, A., D. C. Warhurst, F. Guhl, and I. A. Frame. 1995. Polymerase chain reaction-solution hybridization enzyme-linked immunoassay (PCR-SHELA) for the differential diagnosis of pathogenic and non-pathogenic *Entamoeba histolytica*. *Trans. R. Soc. Trop. Med. Hyg.* 89:187-188.
- Agundis Mata, C., F. Blanco, J. Toledo, F. Reta, J. Kumate, and A. Isibasi. 1996. Identification of a 35 kDa glycoprotein from *Entamoeba histolytica* by sera from patients with amebic liver abscess and with mouse monoclonal antibody. *Immunol. Investig.* 25:519-529.
- Allason-Jones, E., A. Mindel, P. Sargeant, and P. Williams. 1986. *Entamoeba histolytica* as a commensal intestinal parasite in homosexual men. *N. Engl. J. Med.* 315:353-356.
- Reference deleted.
- Anonymous. 1997. Amoebiasis. *Wkly. Epidemiol. Rec.* 72:97-99.
- Anonymous. 1997. WHO/PAHO/UNESCO report. A consultation with experts on amoebiasis. *Epidemiol. Bull. PAHO* 18:13-14.
- Anonymous. 2001. International Centers for Tropical Research Network. 10th Anniversary Research Beyond Boundaries. National Institutes of Health, Bethesda, Md.
- Ardic, N., M. Tanyuksel, L. Doganci, and H. Gun. 1998. Evaluation of zymodemes of pathogen and non-pathogen *Entamoeba histolytica*. *Flora* 3:125-133. (in Turkish).
- Aristizabal, H., J. Acevedo, and M. Botero. 1991. Fulminant amebic colitis. *World J. Surg.* 15:216-221.
- Attia, R. A., H. Rizk, and S. Motawea. 1995. Importance of *E. histolytica* antigen in serodiagnosis and follow up of patients with amebic liver abscess. *J. Egypt. Soc. Parasitol.* 25:485-490.
- Bapat, M. M., and G. G. Bhawe. 1990. Counterimmunoelectrophoresis in the immunodiagnosis of amoebiasis. *J. Postgrad. Med.* 36:124-127.
- Barker, R. H., Jr. 1994. Use of PCR in the field. *Parasitol. Today* 10:117-119.
- Beaver, P. C., R. C. Jung, and E. W. Cupp. 1984. *Clinical parasitology*. Lea & Febiger, Philadelphia, Pa.
- Belding, D. L. 1952. *Textbook of clinical parasitology*, 2nd ed. Appleton-Century-Crofts, Inc., New York, N.Y.
- Bhattacharya, S., I. Som, and A. Bhattacharya. 1998. The ribosomal DNA plasmids of *Entamoeba*. *Parasitol. Today* 14:181-185.
- Blackett, K. 1988. Amoebic pericarditis. *Int. J. Cardiol.* 21:183-187.
- Blanc, D., R. Nicholls, P., and G. Sargeant. 1989. Experimental production of new zymodemes of *Entamoeba histolytica* supports the hypothesis of genetic exchange. *Trans. R. Soc. Trop. Med. Hyg.* 83:787-790.
- Bracha, R., and D. Mirelman. 1984. Virulence of *Entamoeba histolytica* trophozoites. Effects of bacteria, microaerobic conditions, and metronidazole. *J. Exp. Med.* 160:353-368.
- Braga, L. L., A. A. M. Lima, C. L. Sears, R. D. Newman, T. Wuhib, C. A. Paiva, R. L. Guerrant, and B. J. Mann. 1996. Seroepidemiology of *Entamoeba histolytica* in a slum in northeastern Brazil. *Am. J. Trop. Med. Hyg.* 55:693-697.
- Britten, D., S. M. Wilson, R. McNeerney, A. H. Moody, P. L. Chiodini, and J. P. Ackers. 1997. An improved colorimetric PCR-based method for detection and differentiation of *Entamoeba histolytica* and *Entamoeba dispar* in feces. *J. Clin. Microbiol.* 35:1108-1111.
- Britten, D., S. M. Wilson, R. McNeerney, A. H. Moody, P. L. Chiodini, and J. P. Ackers. 1997. Detection and differentiation of *Entamoeba histolytica* and *E. dispar* using an improved colorimetric polymerase chain reaction method. *Arch. Med. Res.* 28:S279-S281.
- Brumpt, E. 1925. Étude sommaire de l' "*Entamoeba dispar*" n. sp. Amibe à kystes quadrinuclées, parasite de l'homme. *Bull. Acad. Med. (Paris)* 94:943-952.
- Burchard, G. D., F. T. Hufert, and D. Mirelman. 1991. Characterization of 20 *Entamoeba histolytica* strains isolated from patients with HIV infection. *Infection* 19:164-169.
- Caballero-Salcedo, A., M. Viveros-Rogel, B. Salvatierra, R. Tapia-Conyer, J. Sepúlveda-Amor, G. Gutiérrez, and L. Ortiz-Ortiz. 1994. Seroepidemiology of amebiasis in Mexico. *Am. J. Trop. Med. Hyg.* 50:412-419.
- Chacin-Bonilla, L. 1992. *Entamoeba polecki*: human infections in Venezuela. *Trans. R. Soc. Trop. Med. Hyg.* 86:634.
- Chan, F., N. Stewart, M. Guan, I. Robb, L. Fuite, I. Chan, F. Diaz-Mitoma, J. King, N. MacDonald, and A. Mackenzie. 1996. Prevalence of *Dientamoeba fragilis* antibodies in children and recognition of a 39 kDa immunodominant protein antigen of the organism. *Eur. J. Clin. Microbiol. Infect. Dis.* 15:950-954.
- Cheng, H. S., and L. C. Wang. 1999. Amoebiasis among institutionalized psychiatric patients in Taiwan. *Epidemiol. Infect.* 122:317-322.
- Choudhuri, G., V. Prakash, A. Kumar, S. K. Shahi, and M. Sharma. 1991. Protective immunity to *Entamoeba histolytica* infection in subjects with antiamebic antibodies residing in a hyperendemic zone. *Scand. J. Infect. Dis.* 23:771-776.
- Clark, C. G. 1993. PCR detection of pathogenic *Entamoeba histolytica* and differentiation from other intestinal protozoa by riboprinting, p. 468-474. In D. H. Persing, T. F. Smith, F. C. Tenover, and T. J. White (ed.), *Diagnostic molecular microbiology. Principles and applications*. American Society for Microbiology, Washington, D.C.
- Clark, C. G. 1995. Axenic cultivation of *Entamoeba dispar* Brumpt 1925, *Entamoeba insolita* Geiman and Wichterman 1937 and *Entamoeba ranarum* Grassi 1879. *J. Eukaryot. Microbiol.* 42:590-593.
- Clark, C. G. 1997. Riboprinting: a tool for the study of genetic diversity in microorganisms. *J. Eukaryot. Microbiol.* 44:277-283.
- Clark, C. G. 1998. *Entamoeba dispar*, an organism reborn. *Trans. R. Soc. Trop. Med. Hyg.* 92:361-364.
- Clark, C. G., and L. S. Diamond. 1991. Ribosomal RNA genes of "pathogenic" and "nonpathogenic" *Entamoeba histolytica* are distinct. *Mol. Biochem. Parasitol.* 49:297-302.
- Clark, C. G., and L. S. Diamond. 1992. Differentiation of pathogenic *Entamoeba histolytica* from other intestinal protozoa by riboprinting. *Arch. Med. Res.* 23:15-16.
- Clark, C. G., and L. S. Diamond. 1993. *Entamoeba histolytica*: a method for isolate identification. *Exp. Parasitol.* 77:450-455.
- Clark, C. G., and L. S. Diamond. 1997. Intraspecific variation and phylogenetic relationships in the genus *Entamoeba* as revealed by riboprinting. *J. Eukaryot. Microbiol.* 44:142-154.
- Clark, C. G., and L. S. Diamond. 2002. Methods for cultivation of luminal parasitic protists of clinical importance. *Clin. Microbiol. Rev.* 15:329-341.
- Clark, C. G., M. Espinosa Castellano, and A. Bhattacharya. 2000. *Entamoeba histolytica*: an overview of the biology of the organism, p. 1-45. In J. I. Ravdin (ed.), *Amebiasis*. Imperial College Press, London, United Kingdom.
- Cuffari, C., L. Oigny, and E. G. Seidman. 1998. *Dientamoeba fragilis* masquerading as allergic colitis. *J. Pediatr. Gastroenterol. Nutr.* 26:16-20.
- Cummins, A. J., A. H. Moody, K. Laloo, and P. L. Chiodini. 1994. Rapid latex agglutination test for extraluminal amoebiasis. *J. Clin. Pathol.* 47:647-648.
- De Villiers J. P., and G. Durra. 1998. Case report: amoebic abscess of the brain. *Clin. Radiol.* 53:307-309.

50. Diamond, L. S. 1961. Axenic cultivation of *Entamoeba histolytica*. *Science* **134**:336.
51. Diamond, L. S. 1982. A new liquid medium for xenic cultivation of *Entamoeba histolytica* and other lumen-dwelling protozoa. *J. Parasitol.* **68**:958-959.
52. Diamond, L. S., and C. G. Clark. 1993. A redescription of *Entamoeba histolytica* Schaudinn, 1903 (Emended Walker, 1911), separating it from *Entamoeba dispar* Brumpt, 1925. *J. Eukaryot. Microbiol.* **40**:340-344.
53. Diamond, L. S., D. R. Harlow, and C. C. Cunnick. 1978. A new medium for the axenic cultivation of *Entamoeba histolytica* and other *Entamoeba*. *Trans. R. Soc. Trop. Med. Hyg.* **72**:431-432.
54. Dodson, J. M., C. G. Clark, L. A. Lockhart, B. M. Leo, J. W. Schroeder, and B. J. Mann. 1997. Comparison of adherence, cytotoxicity, and Gal/GalNAc lectin gene structure in *Entamoeba histolytica* and *Entamoeba dispar*. *Parasitol. Int.* **46**:225-235.
55. Dodson, J. M., P. W. Lenkowski, Jr., A. C. Eubanks, T. F. Jackson, J. Napodano, D. M. Lyerly, L. A. Lockhart, B. J. Mann, and W. A. Petri, Jr. 1999. Infection and immunity mediated by the carbohydrate recognition domain of the *Entamoeba histolytica* Gal/GalNAc lectin. *J. Infect. Dis.* **179**:460-466.
56. Reference deleted.
57. Reference deleted.
58. Edman, U., M. A. Meraz, S. Rausser, N. Agabian, and I. Meza. 1990. Characterization of an immuno-dominant variable surface antigen from pathogenic and nonpathogenic *Entamoeba histolytica*. *J. Exp. Med.* **172**: 879-888.
59. Evangelopoulos, A., G. Spanakos, E. Patsoula, N. Vakalis, and N. Legakis. 2000. A nested, multiplex, PCR assay for the simultaneous detection and differentiation of *Entamoeba histolytica* and *Entamoeba dispar* in faeces. *Ann. Trop. Med. Parasitol.* **94**:233-240.
60. Faust, E. C., P. F. Russell, and R. C. Jung. 1970. Craig and Faust's clinical parasitology, 8th ed. Lea & Febiger, Philadelphia, Pa.
61. Fritsche, T. R., and J. W. Smith. 2001. Medical parasitology, p. 1196-1239. In J. B. Henry (ed.), Clinical diagnosis and management by laboratory methods. The W. B. Saunders Co., Philadelphia, Pa.
62. Fuchs, G., G. Ruiz-Palacios, and L. K. Pickering. 1988. Amebiasis in the pediatric population, p. 594-613. In J. I. Ravdin (ed.), Amebiasis: human infection by *Entamoeba histolytica*. John Wiley & Sons, Inc., New York, N.Y.
63. Garcia, L. S. 1990. Laboratory methods for diagnosis of parasitic infections, p. 776-861. In E. J. Baron, L. R. Peterson, and S. M. Finegold (ed.), Bailey's & Scott's diagnostic microbiology. The C. V. Mosby Co., St. Louis, Mo.
64. Garcia, L. S., and D. A. Bruckner. 1997. Diagnostic medical parasitology, 3rd ed. ASM Press, Washington, D.C.
65. Garcia, L. S., and D. A. Bruckner. 1999. Taxonomy and classification of human parasites, p. 1329-1335. In P. R. Murray, E. J. Baron, M. A. Pfaller, F. C. Tenover, and R. H. Tenover (ed.), Manual of clinical microbiology, 7th ed. ASM Press, Washington, D.C.
66. Garcia, L. S., D. A. Bruckner, T. C. Brewer, and R. Y. Shimizu. 1982. Comparison of indirect fluorescent-antibody amoebic serology with counterimmunoelectrophoresis and indirect hemagglutination amoebic serologies. *J. Clin. Microbiol.* **15**:603-605.
67. Garcia, L. S., R. Y. Shimizu, and C. N. Bernard. 2000. Detection of *Giardia lamblia*, *Entamoeba histolytica*, *Entamoeba dispar*, and *Cryptosporidium parvum* antigens in human fecal specimens using the Triage parasite panel enzyme immunoassay. *J. Clin. Microbiol.* **38**:3337-3340.
68. Gathiram, V., and T. F. Jackson. 1987. A longitudinal study of asymptomatic carriers of pathogenic zymodemes of *Entamoeba histolytica*. *S. Afr. Med. J.* **72**:669-672.
69. Gathiram, V., and T. F. Jackson. 1990. Pathogenic zymodemes of *Entamoeba histolytica* remain unchanged throughout their life-cycle. *Trans. R. Soc. Trop. Med. Hyg.* **84**:806-807.
70. Gatti, S., C. Cevini, L. Marchi, S. Novati, and M. Scaglia. 1995. *Entamoeba histolytica* autochthonous isolates from mentally retarded Italian patients. *Parasitol. Res.* **81**:148-151.
71. Gatti, S., G. Swierczynski, F. Robinson, M. Anselmi, J. Corrales, J. Moreira, G. Montalvo, A. Bruno, R. Mascrati, Z. Bisoffi, and M. Scaglia. 2002. Amebic infections due to the *Entamoeba histolytica*-*Entamoeba dispar* complex: a study of the incidence in a remote rural area of Ecuador. *Am. J. Trop. Med. Hyg.* **67**:123-127.
72. Gilchrist, C. A., and W. A. Petri, Jr. 1999. Virulence factors of *Entamoeba histolytica*. *Curr. Opin. Microbiol.* **2**:433-437.
73. González-Ruiz, A., R. Haque, A. Aguirre, G. Castañón, A. Hall, F. Guhl, G. Ruiz-Palacios, M. A. Miles, and D. C. Warhurst. 1994. Value of microscopy in the diagnosis of dysentery associated with invasive *Entamoeba histolytica*. *J. Clin. Pathol.* **47**:236-239.
74. Gonzalez-Ruiz, A., R. Haque, T. Rehman, A. Aguirre, A. Hall, F. Guhl, D. C. Warhurst, and M. A. Miles. 1994. Diagnosis of amebic dysentery by detection of *Entamoeba histolytica* fecal antigen by an invasive strain-specific, monoclonal antibody-based enzyme-linked immunosorbent assay. *J. Clin. Microbiol.* **32**:964-970.
75. Guerrant, R. L. 1986. Amebiasis: introduction, current status, and research questions. *Rev. Infect. Dis.* **8**:218-227.
76. Guerrant, R. L., J. Brush, J. I. Ravdin, J. A. Sullivan, and G. L. Mandell. 1981. Interaction between *Entamoeba histolytica* and human polymorphonuclear neutrophils. *J. Infect. Dis.* **143**:83-93.
77. Haider, Z., and A. Fayyaz. 1978. Latex agglutination test for amoebiasis in Pakistani patients with chronic 'obscure' liver enlargements. *J. Trop. Med. Hyg.* **81**:13-15.
78. Haque, R., N. U. Mollah, I. K. M. Ali, K. Alam, A. Eubanks, D. Lyerly, and W. A. Petri, Jr. 2000. Diagnosis of amebic liver abscess and intestinal infection with the TechLab *Entamoeba histolytica* II antigen detection and antibody tests. *J. Clin. Microbiol.* **38**:3235-3239.
79. Haque, R., I. K. M. Ali, S. Akther, and W. A. Petri, Jr. 1998. Comparison of PCR, isoenzyme analysis, and antigen detection for diagnosis of *Entamoeba histolytica* infection. *J. Clin. Microbiol.* **36**:449-452.
80. Haque, R., I. K. M. Ali, C. G. Clark, and W. A. Petri, Jr. 1998. A case report of *Entamoeba moshkovskii* infection in a Bangladeshi child. *Parasitol. Int.* **47**:201-202.
81. Haque, R., I. M. Ali, R. B. Sack, B. M. Farr, G. Ramakrishnan, and W. A. Petri, Jr. 2001. Amebiasis and mucosal IgA antibody against the *Entamoeba histolytica* adherence lectin in Bangladeshi children. *J. Infect. Dis.* **183**: 1787-1793.
82. Haque, R., P. Duggal, I. M. Ali, M. B. Hossain, D. Mondal, R. B. Sack, B. M. Farr, T. H. Beaty, and W. A. Petri, Jr. 2002. Innate and acquired resistance to amebiasis in Bangladeshi children. *J. Infect. Dis.* **186**:547-552.
83. Haque, R., A. S. G. Faruque, P. Hahn, D. M. Lyerly, and W. A. Petri, Jr. 1997. *Entamoeba histolytica* and *Entamoeba dispar* infection in children in Bangladesh. *J. Infect. Dis.* **175**:734-736.
84. Haque, R., A. Hall, and S. Tzipori. 1990. Zymodemes of *Entamoeba histolytica* in Dhaka, Bangladesh. *Ann. Trop. Med. Parasitol.* **84**:629-632.
85. Haque, R., L. M. Neville, P. Hahn, and W. A. Petri, Jr. 1995. Rapid diagnosis of *Entamoeba* infection by using *Entamoeba* and *Entamoeba histolytica* stool antigen detection kits. *J. Clin. Microbiol.* **33**:2558-2561.
86. Healy, G. R. 1988. Diagnostic techniques for stool samples, p. 635-649. In J. I. Ravdin (ed.), Amebiasis human infection by *Entamoeba histolytica*. John Wiley & Sons, Inc., New York, N.Y.
87. Healy, G. R., and L. S. Garcia. 1995. Intestinal and urogenital protozoa, p. 1204-1228. In P. R. Murray, E. J. Baron, M. A. Pfaller, F. C. Tenover, and R. H. Tenover (ed.), Manual of clinical microbiology, 6th ed. ASM Press, Washington, D.C.
88. Hsu, Y. B., F. M. Chen, P. J. Lee, S. C. Yu, K. M. Chen, Y. T. Yaoi, and H. C. Hsu. 1995. Fulminant amebiasis: a clinical evaluation. *Hepato-Gastroenterol.* **42**:109-112.
89. Huber, M., L. Garfinkel, C. Gitler, D. Mirelman, M. Revel, and S. Rozenblatt. 1988. Nucleotide sequence analysis of an *Entamoeba histolytica* ferredoxin gene. *Mol. Biochem. Parasitol.* **31**:27-33.
90. Hughes, M. A., and W. A. Petri. 2000. Amebic liver abscess. *Infect. Dis. Clin. North Am.* **14**:565-582.
91. Hung, C. C., P. J. Chen, S. M. Hsieh, J. M. Wong, C. T. Fang, S. C. Chang, and M. Y. Chen. 1999. Invasive amoebiasis: an emerging parasitic disease in patients infected with HIV in an area endemic for amoebic infection. *AIDS* **13**:2421-2428.
92. Iruen, E. M., T. F. H. G. Jackson, and A. E. Simjee. 1992. Asymptomatic intestinal colonization by pathogenic *Entamoeba histolytica* in amebic liver abscess—prevalence, response to therapy, and pathogenic potential. *Clin. Infect. Dis.* **14**:889-893.
93. Ivey, M. 1980. Phylum Protozoa, p. 2081-2093. In A. C. Sonnenwirth and L. Jarett (ed.), Gradwohl's clinical laboratory methods and diagnosis. The C. V. Mosby Co., St. Louis, Mo.
94. Jackson, T. F., C. B. Anderson, and A. E. Simjee. 1984. Serological differentiation between past and present infection in hepatic amoebiasis. *Trans. R. Soc. Trop. Med. Hyg.* **78**:342-345.
95. Jackson, T. F., V. Gathiram, and A. E. Simjee. 1985. Seroepidemiological study of antibody responses to the zymodemes of *Entamoeba histolytica*. *Lancet* **i**:716-719.
96. Jackson, T. F., P. G. Sargeant, P. S. Visser, V. Gathiram, S. Suparsad, and C. B. Anderson. 1990. *Entamoeba histolytica*: naturally occurring infections in baboons. *Arch. Investig. Med.* **1**:153-156.
97. Jackson, T. F., and S. Suparsad. 1997. Zymodeme stability of *Entamoeba histolytica* and *E. dispar*. *Arch. Med. Res.* **28**(Suppl.):304-305.
98. Jackson, T. F. H. G. 2000. Epidemiology, p. 47-63. In J. I. Ravdin (ed.), Amebiasis. Imperial College Press, London, United Kingdom.
99. Jelinek, T., G. Peyerl, T. Löscher, and H.-D. Nothdurft. 1996. Evaluation of an antigen-capture enzyme immunoassay for detection of *Entamoeba histolytica* in stool samples. *Eur. J. Clin. Microbiol. Infect. Dis.* **15**:752-755.
100. Jensen, J. B. 1983. Lumen dwelling protozoa: *Entamoeba*, *trichomonads*, and *Giardia*, p. 67-109. In J. B. Jensen (ed.), In vitro cultivation of protozoan parasites. CRC Press, Inc., Boca Raton, Fla.
101. Jetter, A., B. Walderich, D. Britten, O. Mete, V. Goral, G. D. Burchard, and J. Ackers. 1997. An epidemiological study of *Entamoeba histolytica* and *E. dispar* infection in eastern Turkey using a colorimetric polymerase chain reaction. *Arch. Med. Res.* **28**(Suppl.):319-321.

102. Johnson, J. L., J. S. Baird, T. V. Hulbert, and L. M. Opas. 1994. Amebic liver abscess in infancy: case report and review. *Clin. Infect. Dis.* **19**:765–767.
103. Jokipii, L., P. G. Sargeant, and A. M. Jokipii. 1989. Coincidence of deficient delayed hypersensitivity and intestinal protozoa in homosexual men. *Scand. J. Infect. Dis.* **21**:563–571.
104. Juniper, K., Jr., C. L. Worrell, M. C. Minshew, L. S. Roth, H. Cypert, and R. E. Lloyd. 1972. Serologic diagnosis of amebiasis. *Am. J. Trop. Med. Hyg.* **21**:157–168.
105. Katz, M., D. D. Despamnier, and R. W. Gwadz. 1989. *Parasitic diseases*. Springer-Verlag, New York, N.Y.
106. Katzwinkel-Wladarsch, S., T. Loscher, and H. Rinder. 1994. Direct amplification and differentiation of pathogenic and nonpathogenic *Entamoeba histolytica* DNA from stool specimens. *Am. J. Trop. Med. Hyg.* **51**:115–118.
107. Kean, B. H. 1988. A history of amebiasis, p. 1–10. In J. I. Ravdin (ed.), *Amebiasis: human infection by Entamoeba histolytica*. John Wiley & Sons, Inc., New York, N.Y.
108. Keene, W. E., M. E. Hidalgo, E. Orozco, and J. H. McKerrow. 1990. *Entamoeba histolytica*: correlation of the cytopathic effect of virulent trophozoites with secretion of a cysteine proteinase. *Exp. Parasitol.* **71**:199–206.
109. Kelsall, B. L., T. G. Jackson, V. Gathiram, S. B. Salig, M. Vaithilingum, R. D. Pearson, and J. I. Ravdin. 1994. Secretory immunoglobulin A antibodies to the galactose-inhibitable adherence protein in the saliva of patients with amebic liver disease. *Am. J. Trop. Med. Hyg.* **51**:454–459.
110. Knobloch, J., and E. Mannweiler. 1983. Development and persistence of antibodies to *Entamoeba histolytica* in patients with amebic liver abscess. Analysis of 216 cases. *Am. J. Trop. Med. Hyg.* **32**:727–732.
111. Kobayashi, S., E. Imai, H. Tachibana, T. Fujiwara, and T. Takeuchi. 1998. *Entamoeba dispar*: cultivation with sterilized *Criethidia fasciculata*. *J. Eukaryot. Microbiol.* **45**:3S–8S.
112. Kraoul, L., H. Adjmi, V. Lavarde, J. F. Pays, C. Tourte-Schaefer, and C. Hennequin. 1997. Evaluation of a rapid enzyme immunoassay for diagnosis of hepatic amoebiasis. *J. Clin. Microbiol.* **35**:1530–1532.
113. Krauss, H., H. Weber, B. Enders, H. G. Schifer, W. Slenczka, and H. Zahner. 1997. *Zoonosen, Von Tier zu Menschen übertragbare Infektionserkrankheiten, 2. Überarbeitete und erweiterte Auflage*. Deutscher Ärzte-Verlag GmbH, Cologne, Germany.
114. Krogstad, D. J., H. C. Spencer, Jr., G. R. Healy, N. N. Gleason, D. J. Sexton, and C. A. Herron. 1978. Amebiasis: epidemiologic studies in the United States, 1971–1974. *Ann. Intern. Med.* **88**:89–97.
115. Krupp, I. M. 1974. Comparison of counterimmunoelectrophoresis with other serologic tests in the diagnosis of amebiasis. *Am. J. Trop. Med. Hyg.* **23**:27–30.
116. Leber, A. L., and S. M. Novak. 1999. Intestinal and urogenital amebae, flagellates, and ciliates, p. 1391–1405. In P. R. Murray, E. J. Baron, M. A. Pfaller, F. C. Tenover, and R. H. Tenover (eds.), *Manual of clinical microbiology*, 7th ed. ASM Press, Washington, D.C.
117. Leippe, M., S. Ebel, O. L. Schoenberger, R. D. Horstmann, and H. J. Müller-Eberhard. 1991. Pore-forming peptide of pathogenic *Entamoeba histolytica*. *Proc. Natl. Acad. Sci. USA* **88**:7659–7663.
118. Leippe, M., E. Tannich, R. Nickel, G. van der Goot, F. Pattus, R. D. Horstmann, and H. J. Müller-Eberhard. 1992. Primary and secondary structure of the pore-forming peptide of pathogenic *Entamoeba histolytica*. *EMBO J.* **11**:3501–3506.
119. Levine, N. D., J. O. Corliss, and F. E. G. Cox. 1980. A newly revised classification of the protozoa. *J. Protozool.* **27**:37–58.
120. Li, E., and S. L. Stanley, Jr. 1996. Protozoa. Amebiasis. *Gastroenterol. Clin. North Am.* **25**:471–492.
121. Liu, C. J., C. C. Hung, M. Y. Chen, Y. P. Lai, P. J. Chen, S. H. Huang, and D. S. Chen. 2001. Amebic liver abscess and human immunodeficiency virus infection: a report of three cases. *J. Clin. Gastroenterol.* **33**:64–68.
122. Lotter, H., T. F. H. G. Jackson, and E. Tannich. 1995. Evaluation of three serological tests for the detection of antiamebic antibodies applied to sera of patients from an area endemic for amebiasis. *Trop. Med. Parasitol.* **46**:180–182.
123. Lotter, H., E. Mannweiler, and E. Tannich. 1993. Crude or recombinant proteins applied to latex agglutination, complement-fixation and enzyme-linked immunosorbent assays for the serodiagnosis of invasive amebiasis. *Trop. Med. Parasitol.* **44**:277–280.
124. Lowther, S. A., M. S. Dworkin, and D. L. Hanson. 2000. *Entamoeba histolytica/Entamoeba dispar* infections in human immunodeficiency virus-infected patients in the United States. *Clin. Infect. Dis.* **30**:955–959.
125. Luaces, A. L., and A. J. Barrett. 1988. Affinity purification and biochemical characterization of histolysin, the major cysteine proteinase of *Entamoeba histolytica*. *Biochem. J.* **250**:903–909.
126. Lysy, J., J. Zimmerman, Y. Sherman, R. Feigin, and M. Ligumsky. 1991. Crohn's colitis complicated by superimposed invasive amebic colitis. *Am. J. Gastroenterol.* **86**:1063–1065.
127. Magaña-García, M., and A. Arista-Viveros. 1993. Cutaneous amebiasis in children. *Pediatr. Dermatol.* **10**:352–355.
128. Maltz, G., and C. M. Knauer. 1991. Amebic liver abscess: a 15-year experience. *Am. J. Gastroenterol.* **86**:704–710.
129. Markell, E. K., D. T. John, and W. A. Krotoski. 1999. *Lumen-dwelling protozoa*, 8th ed. The W. B. Saunders Co., Philadelphia, Pa.
130. Mayhew, K. M., M. Dundoo, E. F. Dunne, B. G. Dwinell, and J. K. Stephens. 2000. Inguinal lymphadenitis caused by *Entamoeba histolytica*: case report and literature review. *Mayo Clin. Proc.* **75**:513–516.
131. McCoy, J. J., B. J. Mann, and W. A. Petri, Jr. 1994. Adherence and cytotoxicity of *Entamoeba histolytica*, or how lectins let parasites stick around. *Infect. Immun.* **62**:3045–3050.
132. McCoy, J. J., B. J. Mann, T. S. Vedvick, and W. A. Petri, Jr. 1993. Sequence analysis of genes encoding the light subunit of the *Entamoeba histolytica* galactose-specific adhesin. *Mol. Biochem. Parasitol.* **61**:325–328.
133. McLaughlin, J., and S. Aley. 1985. The biochemistry and functional morphology of the *Entamoeba*. *J. Protozool.* **32**:221–240.
134. Mhlanga, B. R., L. O. Lanoie, H. J. Norris, E. E. Lack, and D. H. Connor. 1992. Amebiasis complicating carcinomas—a diagnostic dilemma. *Am. J. Trop. Med. Hyg.* **46**:759–764.
135. Mirelman, D., Y. Nuchamowitz, and T. Stolarsky. 1997. Comparison of use of enzyme-linked immunosorbent assay-based kits and PCR amplification of rRNA genes for simultaneous detection of *Entamoeba histolytica* and *E. dispar*. *J. Clin. Microbiol.* **35**:2405–2407.
136. Munoz, M. de L., M. A. Moreno, J. N. Perez-García, G. R. Tovar, and V. I. Hernandez. 1991. Possible role of calmodulin in the secretion of *Entamoeba histolytica* electron-dense granules containing collagenase. *Mol. Microbiol.* **5**:1707–1714.
137. Muriuki, S. M., R. K. Murugu, E. Munene, G. M. Karere, and D. C. Chai. 1998. Some gastro-intestinal parasites of zoonotic (public health) importance commonly observed in old world non-human primates in Kenya. *Acta Trop.* **71**:73–82.
138. Nagakura, K., H. Tachibana, Y. Kaneda, H. Suzuki, K. Sasaoka, S. Kobayashi, and T. Takeuchi. 1990. Amebiasis in institutions for the mentally retarded in Kanagawa Prefecture, Japan. *Jpn. J. Med. Sci. Biol.* **43**:123–131.
- 138a. National Committee for Clinical Laboratory Standards. 1993. Procedures for the recovery and identification of parasites from the intestinal tract; proposed guideline. Document M28-P. National Committee for Clinical Laboratory Standards, Villanova, Pa.
139. Nazir, Z., and F. Moazem. 1993. Amebic liver-abscess in children. *Pediatr. Infect. Dis. J.* **12**:929–932.
140. Nozaki, T., S. R. Motta, T. Takeuchi, S. Kobayashi, and P. G. Sargeant. 1989. Pathogenic zymodemes of *Entamoeba histolytica* in Japanese male homosexual population. *Trans. R. Soc. Trop. Med. Hyg.* **83**:525.
141. Nuñez, Y. O., M. A. Fernandez, D. Torres-Nuñez, J. A. Silva, I. Montano, J. L. Maestre, and L. Fonte. 2001. Multiplex polymerase chain reaction amplification and differentiation of *Entamoeba histolytica* and *Entamoeba dispar* DNA from stool samples. *Am. J. Trop. Med. Hyg.* **64**:293–297.
142. Ohnishi, K., and M. Murata. 1997. Present characteristics of symptomatic amebiasis due to *Entamoeba histolytica* in the east-southeast area of Tokyo. *Epidemiol. Infect.* **119**:363–367.
143. Ohnishi, K., M. Murata, and E. Okuzawa. 1994. Symptomatic amebic colitis in a Japanese homosexual AIDS patient. *Intern. Med.* **33**:120–122.
144. Orlandi, P. A., and K. A. Lampel. 2000. Extraction-free, filter-based template preparation for rapid and sensitive PCR detection of pathogenic parasitic protozoa. *J. Clin. Microbiol.* **38**:2271–2277.
145. Ortner, S., B. Plaimauer, M. Binder, O. Scheiner, G. Wiedermann, and M. Duchêne. 1995. Molecular analysis of two hexokinase isoenzymes from *Entamoeba histolytica*. *Mol. Biochem. Parasitol.* **73**:189–198.
146. Osorio, L. M., T. Pico, and A. Luaces. 1992. Circulating antibodies to histolysin, the major cysteine proteinase of *Entamoeba histolytica*, in amebic liver abscess patients. *Parasitology* **105**:207–210.
147. Ozbay, B., Y. Cesur, E. Kirimi, I. Yalçinkaya, S. Arslan, I. Demirtas, and H. Yilmaz. 1997. The changing picture of empyema in childhood and adulthood in the east of Anatolia. *Eur. Respir. J.* **10**(Suppl):25.
148. Pal, S., K. Sengupta, B. Manna, S. Sarkar, S. Bhattacharya, and P. Das. 1996. Comparative evaluation of somatic and excretory-secretory antigens of *Entamoeba histolytica* in serodiagnosis of human amoebiasis by ELISA. *Indian J. Med. Res.* **104**:152–156.
149. Parija, S. C., and B. M. Karki. 1999. Detection of circulating antigen in amebic liver abscess by counter-current immunoelectrophoresis. *J. Med. Microbiol.* **48**:99–101.
150. Patel, A. S., and P. H. DeRidder. 1989. Amebic colitis masquerading as acute inflammatory bowel disease: the role of serology in its diagnosis. *J. Clin. Gastroenterol.* **11**:407–410.
151. Patterson, M., G. R. Healy, and J. M. Shabot. 1980. Serologic testing for amebiasis. *Gastroenterology* **78**:136–141.
152. Pearson, R. D., and E. L. Hewlett. 1988. Amebiasis in travelers, p. 556–562. In J. I. Ravdin (ed.), *Amebiasis: human infection by Entamoeba histolytica*. John Wiley & Sons, Inc., New York, N.Y.
153. Peters, C. S., R. Sable, W. M. Janda, A. L. Chittom, and F. E. Kocka. 1986. Prevalence of enteric parasites in homosexual patients attending an outpatient clinic. *J. Clin. Microbiol.* **24**:684–685.
154. Petri, W. A., Jr., M. D. Chapman, T. Snodgrass, B. J. Mann, J. Broman,

- and J. I. Ravdin. 1989. Subunit structure of the galactose and *N*-acetyl-D-galactosamine-inhibitable adherence lectin of *Entamoeba histolytica*. *J. Biol. Chem.* **264**:3007–3012.
155. Petri, W. A., Jr., R. D. Smith, P. H. Schlesinger, C. F. Murphy, and J. I. Ravdin. 1987. Isolation of the galactose-binding lectin that mediates the in vitro adherence of *Entamoeba histolytica*. *J. Clin. Investig.* **80**:1238–1244.
156. Petri, W. A., Jr., T. L. Snodgrass, T. F. Jackson, V. Gathiram, A. E. Simjee, K. Chadee, and M. D. Chapman. 1990. Monoclonal antibodies directed against the galactose-binding lectin of *Entamoeba histolytica* enhance adherence. *J. Immunol.* **144**:4803–4809.
157. Petri, W. A., Jr., and U. Singh. 1999. Diagnosis and management of amoebiasis. *Clin. Infect. Dis.* **29**:1117–1125.
158. Phillips, S. C., D. Mildvan, D. C. William, A. M. Gelb, and M. C. White. 1981. Sexual transmission of enteric protozoa and helminths in a venereal-disease-clinic population. *N. Engl. J. Med.* **305**:603–606.
159. Pillai, D. R., D. Britten, J. P. Ackers, J. I. Ravdin, and K. C. Kain. 1997. A gene homologous to *hgl2* of *Entamoeba histolytica* is present and expressed in *Entamoeba dispar*. *Mol. Biochem. Parasitol.* **87**:101–105.
160. Pillai, D. R., and K. C. Kain. 1999. Immunochromatographic strip-based detection of *Entamoeba histolytica*-*E. dispar* and *Giardia lamblia* coproantigen. *J. Clin. Microbiol.* **37**:3017–3019.
161. Pillai, D. R., J. S. Keystone, D. C. Sheppard, J. D. MacLean, D. W. MacPherson, and K. C. Kain. 1999. *Entamoeba histolytica* and *Entamoeba dispar*: epidemiology and comparison of diagnostic methods in a setting of nonendemicity. *Clin. Infect. Dis.* **29**:1315–1318.
162. Pillai, R., and K. C. Kain. 2000. Recent developments in amoebiasis: the Gal/GalNAc lectins of *Entamoeba histolytica* and *Entamoeba dispar*. *Microbes Infect.* **2**:1775–1783.
163. Pillai, S., and A. Mohimen. 1982. A solid-phase sandwich radioimmunoassay for *Entamoeba histolytica* proteins and the detection of circulating antigens in amoebiasis. *Gastroenterology* **83**:1210–1216.
164. Proctor, E. M. 1991. Laboratory diagnosis of amoebiasis. *Clin. Lab. Med.* **11**:829–859.
165. Que, X., and S. L. Reed. 2000. Cysteine proteinases and the pathogenesis of amoebiasis. *Clin. Microbiol. Rev.* **13**:196–206.
166. Que, X. C., and S. L. Reed. 1997. The role of extracellular cysteine proteinases in pathogenesis of *Entamoeba histolytica* invasion. *Parasitol. Today* **13**:190–194.
167. Quinn, T. C., L. Corey, R. G. Chaffee, M. D. Schuffler, F. P. Brancato, and K. K. Holmes. 1981. The etiology of anorectal infections in homosexual men. *Am. J. Med.* **71**:395–406.
168. Ramakrishnan, G., B. D. Ragland, J. E. Purdy, and B. J. Mann. 1996. Physical mapping and expression of gene families encoding the *N*-acetyl D-galactosamine adherence lectin of *Entamoeba histolytica*. *Mol. Microbiol.* **19**:91–100.
169. Ramos, F., R. Zurabian, P. Morán, M. Ramiro, A. Gómez, C. G. Clark, E. I. Melendro, G. García, and C. Ximénez. 1999. The effect of formalin fixation on the polymerase chain reaction characterisation of *Entamoeba histolytica*. *Trans. R. Soc. Trop. Med. Hyg.* **93**:335–336.
170. Ravdin, J. I. 1995. Amoebiasis. *Clin. Infect. Dis.* **20**:1453–1464.
171. Ravdin, J. I. 2000. *Entamoeba histolytica* (amoebiasis), p. 2798–2810. In G. L. Mandell, J. E. Bennett, and R. Dolin (ed.), *Mandell, Douglas and Bennett's principles and practice of infectious diseases*, 5th ed. Churchill Livingstone, Inc., Philadelphia, Pa.
172. Ravdin, J. I., B. Y. Croft, and R. L. Guerrant. 1980. Cytopathogenic mechanisms of *Entamoeba histolytica*. *J. Exp. Med.* **152**:377–390.
173. Ravdin, J. I., and R. L. Guerrant. 1981. Role of adherence in cytopathogenic mechanisms of *Entamoeba histolytica*. Study with mammalian tissue culture cells and human erythrocytes. *J. Clin. Investig.* **68**:1305–1313.
174. Ravdin, J. I., T. F. Jackson, W. A. Petri, Jr., C. F. Murphy, B. L. Ungar, V. Gathiram, J. Skilogiannis, and A. E. Simjee. 1990. Association of serum antibodies to adherence lectin with invasive amoebiasis and asymptomatic infection with pathogenic *Entamoeba histolytica*. *J. Infect. Dis.* **162**:768–772.
175. Reed, S. L. 2000. Clinical manifestations and diagnosis, p. 113–126. In J. I. Ravdin (ed.), *Amoebiasis*. Imperial College Press, London, United Kingdom.
176. Rennert, W., and C. Ray. 2000. Fulminant amoebic colitis in a ten-day-old infant. *Pediatr. Infect. Dis. J.* **19**:1111–1112.
177. Restrepo, M. I., Z. Restrepo, C. L. E. Villareal, A. Aguirre, and M. Restrepo. 1996. Diagnostic tests for amoebic liver abscess: comparison of enzyme-linked immunosorbent assay (ELISA) and counterimmunoelectrophoresis (CIE). *Rev. Soc. Bras. Med. Trop.* **29**:27–32.
178. Rivera, W. L., H. Tachibana, and H. Kanbara. 1999. Application of the polymerase chain reaction (PCR) in the epidemiology of *Entamoeba histolytica* and *Entamoeba dispar* infections. *Tokai J. Exp. Clin. Med.* **23**:413–415.
179. Rivera, W. L., H. Tachibana, M. R. A. Silva-Tahat, H. Uenura, and H. Kanbara. 1996. Differentiation of *Entamoeba histolytica* and *E. dispar* DNA from cysts present in stool specimens by polymerase chain reaction: its field application in the Philippines. *Parasitol. Res.* **82**:585–589.
180. Robert, R., C. Mahaza, C. Bernard, C. Buffard, and J. M. Senet. 1990. Evaluation of a new bicolored latex agglutination test for immunological diagnosis of hepatic amoebiasis. *J. Clin. Microbiol.* **28**:1422–1424.
181. Robinson, G. L. 1968. The laboratory diagnosis of human parasitic amoebae. *Trans. R. Soc. Trop. Med. Hyg.* **62**:285–294.
182. Roche, J., and A. Benlto. 1999. Prevalence of intestinal parasite infections with special reference to *Entamoeba histolytica* on the island of Bioko (Equatorial Guinea). *Am. J. Trop. Med. Hyg.* **60**:257–262.
183. Rodriguez, M. A., M. E. Hidalgo, T. Sanchez, and E. Orozco. 1996. Cloning and characterization of the *Entamoeba histolytica* pyruvate:ferredoxin oxidoreductase gene. *Mol. Biochem. Parasitol.* **78**:273–277.
184. Rogers, L. 1912. The rapid cure of amoebic dysentery and hepatitis by hypodermic injection of soluble salts of emetine. *Br. Med. J.* **1**:1424.
185. Saffer, L. D., and W. A. Petri, Jr. 1991. Role of the galactose lectin of *Entamoeba histolytica* in adherence-dependent killing of mammalian cells. *Infect. Immun.* **59**:4681–4683.
186. Saffer, L. D., and W. A. Petri, Jr. 1991. *Entamoeba histolytica*: recognition of alpha- and beta-galactose by the 260-kDa adherence lectin. *Exp. Parasitol.* **72**:106–108.
187. Sakata, T., Y. Niwa, H. Goto, Y. Hirooka, T. Hayakawa, N. Ohmiya, and S. Kobayashi. 2001. Asymptomatic inflammatory bowel disease with special reference to ulcerative colitis in apparently healthy persons. *Am. J. Gastroenterol.* **96**:735–739.
188. Saklatvala, T. 1993. Milestones in parasitology. *Parasitol. Today* **9**:347–348.
189. Salata, R. A., and J. I. Ravdin. 1986. The interaction of human neutrophils and *Entamoeba histolytica* increases cytopathogenicity for liver cell monolayers. *J. Infect. Dis.* **154**:19–26.
190. Samrejongroj, P., and S. Tharavanij. 1985. Assessment of validity of counterimmunoelectrophoresis and ELISA in the routine diagnosis of amoebiasis. *S. E. Asia J. Trop. Med. Public Health* **16**:365–370.
191. Sánchez-Guillén, M. C., M. Velázquez-Rojas, H. Salgado-Rosas, E. Torres-Rasgado, R. Pérez-Fuentes, J. Martínez-Munguía, and P. Talamás-Rohana. 2000. Seroprevalence of anti-*Entamoeba histolytica* antibodies by IHA and ELISA assays in blood donors from Puebla, Mexico. *Arch. Med. Res.* **31**:S53–S54.
192. Sanuki, J., T. Asai, E. Okuzawa, S. Kobayashi, and T. Takeuchi. 1997. Identification of *Entamoeba histolytica* and *E. dispar* cysts in stool by polymerase chain reaction. *Parasitol. Res.* **83**:96–98.
193. Sargeant, P. G. 1985. Zymodemes expressing possible genetic exchange in *Entamoeba histolytica*. *Trans. R. Soc. Trop. Med. Hyg.* **79**:86–89.
194. Sargeant, P. G. 1987. The reliability of *Entamoeba histolytica* zymodemes in clinical laboratory diagnosis. *Parasitol. Today* **3**:40–43.
195. Sargeant, P. G., T. F. Jackson, and A. Simjee. 1982. Biochemical homogeneity of *Entamoeba histolytica* isolates, especially those from liver abscess. *Lancet* **i**:1386–1388.
196. Sargeant, P. G., T. F. Jackson, S. R. Wiffen, and R. Bhojnani. 1988. Biological evidence of genetic exchange in *Entamoeba histolytica*. *Trans. R. Soc. Trop. Med. Hyg.* **82**:862–867.
197. Sargeant, P. G., and J. E. Williams. 1979. Electrophoretic isoenzyme patterns of the pathogenic and non-pathogenic intestinal amoebae of man. *Trans. R. Soc. Trop. Med. Hyg.* **73**:225–227.
198. Sargeant, P. G., J. E. Williams, and J. D. Grene. 1978. The differentiation of invasive and non-invasive *Entamoeba histolytica* by isoenzyme electrophoresis. *Trans. R. Soc. Trop. Med. Hyg.* **72**:519–521.
199. Scaglia, M., S. Gatti, A. Bruno, C. Cevini, L. Marchi, and P. G. Sargeant. 1991. Autochthonous amoebiasis in institutionalized mentally-retarded patients: preliminary evaluation of isoenzyme patterns in three isolates. *Ann. Trop. Med. Parasitol.* **85**:509–513.
200. Seeto, R. K., and D. C. Rockey. 1999. Amoebic liver abscess: epidemiology, clinical features, and outcome. *West. J. Med.* **170**:104–109.
201. Sehgal, D., V. Mittal, S. Ramachandran, S. K. Dhar, A. Bhattacharya, and S. Bhattacharya. 1994. Nucleotide sequence organisation and analysis of the nuclear ribosomal DNA circle of the protozoan parasite *Entamoeba histolytica*. *Mol. Biochem. Parasitol.* **67**:205–214.
202. Sehgal, R., M. Abd-Alla, A. H. Moody, P. L. Chioldini, and J. P. Ackers. 1995. Comparison of two media for the isolation and short-term culture of *Entamoeba histolytica* and *E. dispar*. *Trans. R. Soc. Trop. Med. Hyg.* **89**:394.
203. Sheehan, D. J., E. J. Bottone, K. Pavletic, and M. C. Heath. 1979. *Entamoeba histolytica*: efficacy of microscopic, cultural, and serological techniques for laboratory diagnosis. *J. Clin. Microbiol.* **10**:128–133.
204. Shenai, B. R., B. L. Komalam, A. S. Arvind, P. R. Krishnaswamy, and P. V. Subba Rao. 1996. Recombinant antigen-based avidin-biotin microtiter enzyme-linked immunosorbent assay for serodiagnosis of invasive amoebiasis. *J. Clin. Microbiol.* **34**:828–833.
205. Shetty, N., P. Das, S. C. Pal, and T. Prabhu. 1988. Observations on the interpretation of amoebic serology in endemic areas. *J. Trop. Med. Hyg.* **91**:222–227.
206. Shetty, N., and T. Prabhu. 1988. Evaluation of faecal preservation and staining methods in the diagnosis of acute amoebiasis and giardiasis. *J. Clin. Pathol.* **41**:694–699.
207. Stamm, W. P., M. J. Ashley, and K. Bell. 1976. The value of amoebic serology in an area of low endemicity. *Trans. R. Soc. Trop. Med. Hyg.* **70**:49–53.

208. **Stanley, S. L., Jr.** 2000. Prevention and potential of new interventions, p. 137–162. In J. I. Ravdin (ed.), *Amebiasis*. Imperial College Press, London, United Kingdom.
209. **Stanley, S. L., Jr., T. F. Jackson, S. L. Reed, J. Calderon, C. Kunz-Jenkins, V. Gathiram, and E. Li.** 1984. Serodiagnosis of invasive amebiasis using a recombinant *Entamoeba histolytica* protein. *JAMA* **266**:1984–1986.
210. **Stevens, D. L., R. G. Taylor, E. D. Everett, L. Owensby, and T. R. McNitt.** 1979. Amebic liver abscess. Report of a case presenting with nonreactive serologic tests for *Entamoeba histolytica*. *Am. J. Gastroenterol.* **72**:234–238.
211. **Stilwell, G. G.** 1955. Amebiasis: its early history. *Gastroenterology* **28**:606.
212. **Strachan, W. D., P. L. Chiodini, W. M. Spice, A. H. Moody, and J. P. Ackers.** 1988. Immunological differentiation of pathogenic and non-pathogenic isolates of *Entamoeba histolytica*. *Lancet* **i**:561–563.
213. **Tachibana, H., S. Kobayashi, K. Nagakura, Y. Kaneda, and T. Takeuchi.** 2000. Asymptomatic cyst passers of *Entamoeba histolytica* but not *Entamoeba dispar* in institutions for the mentally retarded in Japan. *Parasitol. Int.* **49**:31–35.
214. **Reference deleted.**
215. **Tandon, A.** 1981. Use of enzyme linked immunosorbent assay in intestinal and extra-intestinal amoebiasis (amoebic liver abscess). *Trans. R. Soc. Trop. Med. Hyg.* **75**:574–575.
216. **Tannich, E., and G. D. Burchard.** 1991. Differentiation of pathogenic from nonpathogenic *Entamoeba histolytica* by restriction fragment analysis of a single gene amplified in vitro. *J. Clin. Microbiol.* **29**:250–255.
217. **Tannich, E., F. Ebert, and R. D. Horstmann.** 1992. Molecular cloning of cDNA and genomic sequences coding for the 35-kilodalton subunit of the galactose-inhibitable lectin of pathogenic *Entamoeba histolytica*. *Mol. Biochem. Parasitol.* **55**:225–227.
218. **Tannich, E., R. D. Horstmann, J. Knobloch, and H. H. Arnold.** 1989. Genomic DNA differences between pathogenic and nonpathogenic *Entamoeba histolytica*. *Proc. Natl. Acad. Sci. USA* **86**:5118–5122.
219. **Tanyuksel, M., S. Erguven, B. Tanriover, O. Baylan, and H. Gun.** 1995. Comparison of the serologic tests (IFA, ELISA) with microscopy using for the diagnosis of amoebiasis. *Acta Parasitol. Turc.* **19**:476–482. (In Turkish.)
220. **Tanyuksel, M., H. Tachibana, and W. A. Petri, Jr.** 2001. Amebiasis, an emerging disease. p. 197–212. In W. M. Scheld, W. A. Craig, and J. M. Hughes (ed.), *Emerging infections 5*. ASM Press, Washington, D.C.
221. **Thompson, J. E., Jr., and A. J. Glasser.** 1986. Amebic abscess of the liver. Diagnostic features. *J. Clin. Gastroenterol.* **8**:550–554.
222. **Trissl, D., A. Martinez-Palomo, M. de la Torre, R. de la Hoz, and E. Perez de Suarez.** 1978. Surface properties of *Entamoeba*: increased rates of human erythrocyte phagocytosis in pathogenic strains. *J. Exp. Med.* **148**:1137–1145.
223. **Udezulu, I. A., and G. J. Leitch.** 1987. A membrane-associated neuraminidase in *Entamoeba histolytica* trophozoites. *Infect. Immun.* **55**:181–186.
224. **Verweij, J. J., J. Blotkamp, E. A. T. Brienen, A. Aguirre, and A. M. Polderman.** 2000. Differentiation of *Entamoeba histolytica* and *Entamoeba dispar* cysts using polymerase chain reaction on DNA isolated from faeces with spin columns. *Eur. J. Clin. Microbiol. Infect. Dis.* **19**:358–361.
225. **Vinayak, V. K., S. Sawhney, P. Jain, S. Chugh, S. R. Naik, and R. N. Chakravarti.** 1981. Virulence of *Entamoeba histolytica* in rat and its comparison with the serological responses of the amoebic patients. *Trans. R. Soc. Trop. Med. Hyg.* **75**:32–37.
226. **Vinayak, V. K., R. K. Shandil, V. Bansal, K. Singh, D. K. Bhasin, and U. Kaur.** 1990. Uses and limitations in the demonstration of specific circulating immune complexes in patients with amoebiasis. *J. Med. Microbiol.* **32**:87–91.
227. **Walderich, B., A. Weber, and J. Knobloch.** 1997. Differentiation of *Entamoeba histolytica* and *Entamoeba dispar* from German travelers and residents of endemic regions. *Am. J. Trop. Med. Hyg.* **57**:70–74.
228. **Walker, E. L., and A. W. Sellards.** 1913. Experimental amoebic dysentery. *Philipp. J. Sci. B. Trop. Med.* **8**:253.
229. **Walsh, J. A.** 1986. Problems in recognition and diagnosis of amebiasis: estimation of the global magnitude of morbidity and mortality. *Rev. Infect. Dis.* **8**:228–238.
230. **Walsh, J. A.** 1988. Transmission of *Entamoeba histolytica* infection, p. 106–119. In J. I. Ravdin (ed.), *Amebiasis: human infection by Entamoeba histolytica*. John Wiley & Sons, Inc., New York, N.Y.
231. **Wanke, C., T. Butler, and M. Islam.** 1988. Epidemiologic and clinical features of invasive amebiasis in Bangladesh: a case-control comparison with other diarrheal diseases and postmortem findings. *Am. J. Trop. Med. Hyg.* **38**:335–341.
232. **Weinke, T., B. Friedrich-Janicke, P. Hopp, and K. Janitschke.** 1989. Prevalence and clinical importance of *Entamoeba histolytica* in two high-risk groups: travelers returning from the tropics and male homosexuals. *J. Infect. Dis.* **161**:1029–1031.
233. **Welch, J. S., C. Dobson, and S. Chopra.** 1986. Immunodiagnosis of *Entamoeba histolytica* and *Ascaris lumbricoides* infections in Caucasian and aboriginal Australians. *Trans. R. Soc. Trop. Med. Hyg.* **80**:240–247.
234. **Werries, E., P. Nebinger, and A. Franz.** 1983. Degradation of biogenic oligosaccharides by beta-N-acetyl-glucosaminidase secreted by *Entamoeba histolytica*. *Mol. Biochem. Parasitol.* **7**:127–140.
235. **Willhoeft, U., and E. Tannich.** 1999. The electrophoretic karyotype of *Entamoeba histolytica*. *Mol. Biochem. Parasitol.* **99**:41–53.
236. **Wonsit, R., N. Thammapalerd, S. Tharavanij, P. Radomyos, and D. Bunnag.** 1992. Enzyme-linked immunosorbent assay based on monoclonal and polyclonal antibodies for the detection of *Entamoeba histolytica* antigens in faecal specimens. *Trans. R. Soc. Trop. Med. Hyg.* **86**:166–169.
237. **Yadava, N., M. R. Chandok, J. Prasad, S. Bhattacharya, S. K. Sopory, and A. Bhattacharya.** 1997. Characterization of EhCaBP, a calcium binding protein of *Entamoeba histolytica* and its binding proteins. *Mol. Biochem. Parasitol.* **84**:69–82.
238. **Zaman, S., J. Khoo, S. W. Ng, R. Ahmed, M. A. Khan, R. Hussain, and V. Zaman.** 2000. Direct amplification of *Entamoeba histolytica* DNA from amoebic liver abscess pus using polymerase chain reaction. *Parasitol. Res.* **86**:724–728.
239. **Zengzhu, G., R. Bracha, Y. Nuchamowitz, W. Cheng-I, and D. Mirelman.** 1999. Analysis by enzyme-linked immunosorbent assay and PCR of human liver abscess aspirates from patients in China for *Entamoeba histolytica*. *J. Clin. Microbiol.* **37**:3034–3036.