

THE MICRO-ANATOMY OF THE LYMPH NODE OF GERM-FREE PIGLETS

J. C. ANDERSON

*From the Agricultural Research Council, Institute for Research on Animal Diseases,
Compton, Newbury, Berkshire*

Received for publication June 30, 1971

SUMMARY.—Lymph nodes from germ-free piglets were examined by conventional histological techniques. Lymph nodes of germ-free piglets draining the site of injection of carbon particles were also examined. Germinal centres were not observed in the germ-free piglets. The results are discussed and it is suggested that, although the medullary and cortical tissue are reversed in position, the lymph node of the pig does not differ fundamentally from lymph nodes in other mammalian species.

SEVERAL features make the architecture of the lymph node of the pig unique. The cortical and medullary tissue are reversed in position, the denser lymphocyte-rich tissue occupying a central position, while the more loosely arranged medulla-like tissue is located peripherally (Calhoun and Smith, 1964). The afferent lymphatic vessels penetrate the capsule at only a few points and travel into the body of the node in the trabeculae; the efferent lymphatic vessels arise in the medulla and leave the node at several points on the surface (Trautmann and Fiebiger, 1957). Germinal centres are found in the lymphocyte-rich tissue corresponding to the cortex and Hunt (1968) has observed that, in the pig, the cap of lymphocytes over the light zone of the germinal centre is on the central aspect rather than towards the periphery.

The reported studies concerned observations on pigs born and maintained under conventional conditions. In the present study the lymph nodes of germ-free piglets were examined in an attempt to explain these unusual features of the pig lymph node.

MATERIALS AND METHODS

Germ-free piglets were obtained by hysterotomy (Tavernor *et al.*, 1971) and maintained in flexible plastic isolators (Trexler, 1971). The piglets were monitored at weekly intervals and before removal from an isolator for the presence of micro-organisms using a modification of the procedure of Wagner (1959). Lymph nodes were obtained from 20 piglets killed at various times between 7 and 31 days of age. The nodes were fixed in 10 per cent neutral buffered formalin, paraffin embedded, sectioned and stained by Giemsa's method, methyl-green pylonin, Crossman's method for connective tissue and by Gordon and Sweet's method for reticulin.

Two 7-day-old germ-free piglets were injected subcutaneously in the flank with 2 ml of 1 per cent v/v India ink (Pelikan brand) in sterile saline. These piglets were removed from the isolator at 4 and 20 hr after injection, killed and the draining prefemoral lymph node processed for histological examination.

Lymph nodes from conventional piglets of similar age range were also examined histologically.

RESULTS

No germinal centres were seen in any of the lymph nodes from these germ-free piglets.

The substance of the lymph node was clearly divided into a lymphocyte-rich area corresponding to the cortex and a lymphocyte deplete area corresponding to the medulla. The node was surrounded by a capsule of connective tissue and a sub-capsular sinus was clearly visible. The capsule penetrated into the node in the form of trabeculae together with the sub-capsular sinus which became the sub-trabecular sinus. Islands of trabeculae were common and in all cases were surrounded by sub-trabecular sinus (Fig. 1). The sub-capsular and sub-trabecular sinus was not easily seen in the lymph nodes from conventional piglets because of the large number of lymphocytes surrounding the trabeculae. In the lymph nodes of germ-free piglets lymphatic channels containing valves were seen in the larger trabeculae and these appeared to open into the sub-trabecular sinus. The lymphocyte-rich cortical tissue was always found adjacent to the sub-trabecular sinus and in many cases cortical tissue was seen adjacent to sub-capsular sinus so that in these circumstances the cortex occupied the characteristic peripheral position.

Germinal centres in the lymph nodes of conventional piglets were found in the cortical tissue whether sub-trabecular or sub-capsular. Thus germinal centres were not uncommonly seen at the periphery of the node. The cap of lymphocytes over the germinal centre, when seen, was on the aspect of the centre nearest to the sub-trabecular or sub-capsular sinus. In this respect, germinal centres deep in the substance of the node showed the cap of lymphocytes on the deep aspect of the germinal centre relative to the capsule.

Four hours after injection of germ-free piglets with India ink, the carbon particles were seen in the draining lymph node. The particles were found in the phagocytic cells lining the sub-trabecular and sub-capsular sinus (Fig. 2). Twenty hours after injection the carbon particles were seen in the same cells though many were so engorged with carbon that the nucleus was almost obscured.

DISCUSSION

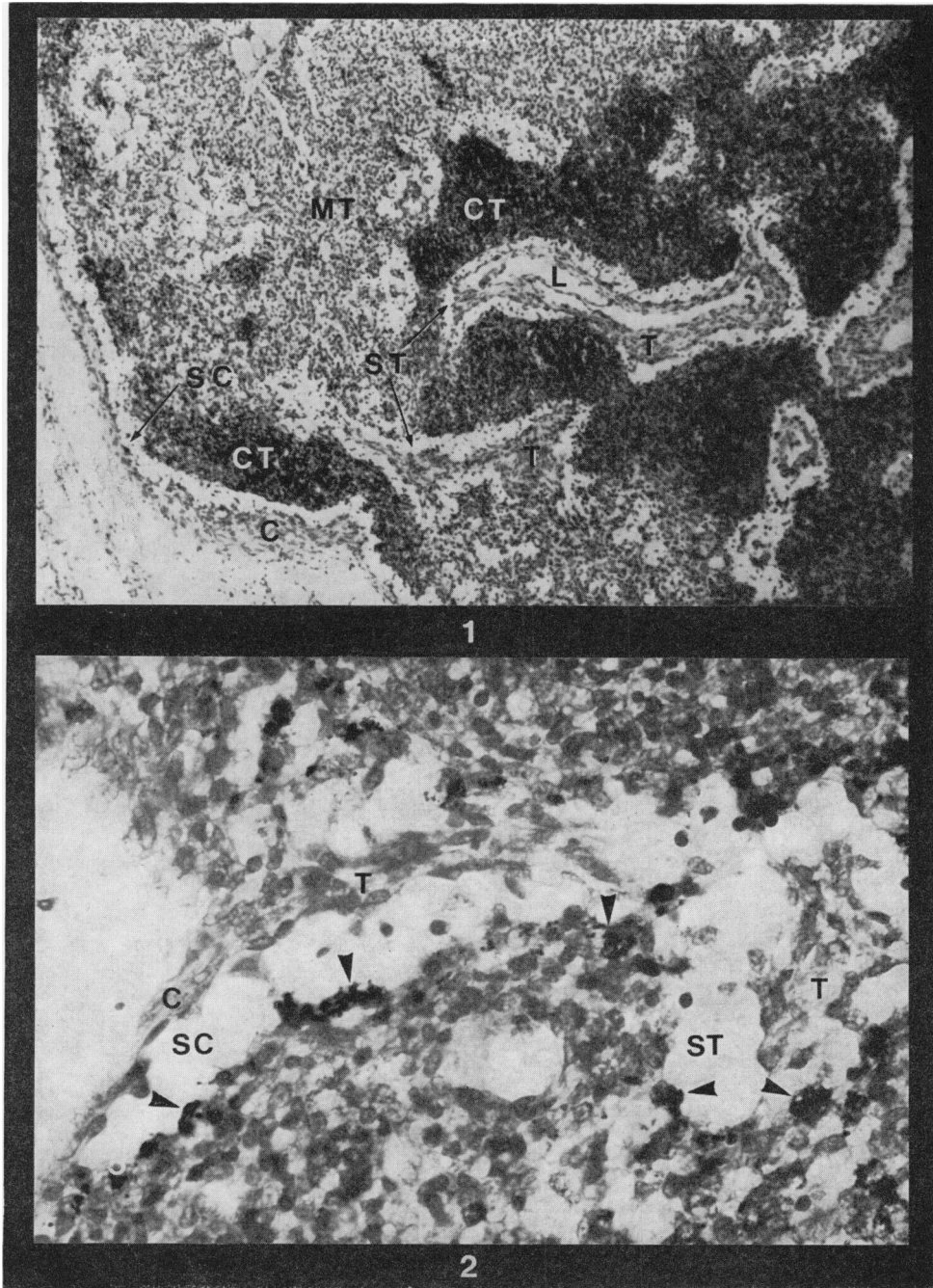
The germ-free state is characterized histologically by a reduction in the number of germinal centres and in the number of lymphocytes in the circulation and in the tissues (Luckey, 1963). The absence of germinal centres and the paucity of lymphocytes in the lymph nodes of the germ-free piglets examined are therefore consistent with the germ-free condition.

The low number of lymphocytes in these nodes results in the architecture of the node being more readily observed. Thus a prominent sub-capsular sinus is visible which is in continuity with the sub-trabecular sinus. It is further seen that the lymphocyte-rich cortex is always in apposition to this sinus and in this respect

EXPLANATION OF PLATES

FIG. 1.—Lymph node of germ-free piglet. MT = medullary tissue. CT = cortical tissue. C = capsule. T = trabeculum. L = lymphatic in trabeculum. SC = sub-capsular sinus. ST = sub-trabecular sinus. Giemsa \times 28.

FIG. 2.—Lymph node of germ-free piglet showing carbon particles (arrows) in phagocytic cells lining the sub-capsular (SC) and sub-trabecular (ST) sinus. C = capsule. T = trabeculum. Giemsa \times 170.



Anderson.

the cortex is in many cases related to the periphery of the node. It is suggested that the trabeculae, instead of passing through the cortex into the substance of the node, have been accompanied by cortical tissue into the node. Thus, in cross-section, islands of trabeculae are seen surrounded by cortex while in other areas trabeculae invested with cortex are seen extending from the capsule into the node. In the lymph nodes from conventional piglets germinal centres may be seen in any of these cortical areas.

In the lymph nodes of other mammals the afferent lymphatics pass through the capsule and drain into the sub-capsular sinus. In the pig the afferent lymphatics, though fewer in number, pass through the capsule or along the trabeculae and empty, as the drainage of carbon showed, into the sub-capsular and sub-trabecular sinus. The cap of lymphocytes over the germinal centre in the cortex is thus orientated towards the lymphatic draining area (Hunt, 1968).

The sequence of tissues in the non-porcine mammalian lymph node, commencing at the external surface, is capsule, sub-capsular sinus, cortex and medulla. In the pig, both conventional and germ-free, the sequence of tissues appears the same except that it is repeated most frequently in the substance of the node. The effect of this re-arrangement is to increase the volume of the cortex. This may be of importance in the ability of the pig lymph node to respond to an immunogen.

The author is indebted to Mrs M. N. Hoare for performing the hysterotomies, to Mr D. P. Robinson for rearing the germ-free piglets and to Mr P. F. Dennis and Mr B. Turfrey for histological preparations.

REFERENCES

- CALHOUN, M. L. & SMITH, E. M. (1964) Hematology and Hematopoietic Organs. In *Diseases of Swine*, 2nd Ed., ed. H. W. Dunne. Ames: Iowa State University Press. p. 38.
- HUNT, A. C. (1968) Micro-Anatomy of the Lymph Nodes of the Pig. *Br. J. exp. Path.*, **49**, 338.
- LUCKEY, T. D. (1963) *Germ-free Life and Gnotobiology*. New York: Academic Press.
- TAVERNOR, W. D., TREXLER, P. C., VAUGHAN, L. C., COX, J. E. & JONES, D. G. C. (1971) The Production of Gnotobiotic Piglets and Calves by Hysterotomy under General Anaesthesia. *Vet. Rec.*, **88**, 10.
- TRAUTMANN, A. & FIEBIGER, J. (1957) *Fundamentals of Histology of Domestic Animals*. New York: Comstock.
- TREXLER, P. C. (1971) Microbiological Isolation of Large Animals. *Vet. Rec.*, **88**, 15.
- WAGNER, M. (1959) Determination of Germfree Status. *Ann. N.Y. Acad. Sci.*, **78**, 89.