

ULTRASTRUCTURE OF PHAGOCYTOSIS OF *SALMONELLA CHOLERAE-SUIS* BY PULMONARY MACROPHAGES *IN VIVO*

A. BASKERVILLE*, C. DOW, W. L. CURRAN AND J. HANNA

From the Veterinary Research Laboratories, Stormont, Belfast BT4 3SD

Received for publication August 21, 1972

Summary.—Phagocytosis of virulent *Salmonella cholerae-suis* in the lungs of pigs was studied by electron microscopy during the period 6 hours–14 days after intranasal infection. All bacteria were phagocytosed by polymorphonuclear leucocytes (PMN) and pulmonary macrophages soon after arrival in distal airways and alveoli. Many organisms were destroyed but some survived and later multiplied within phagocytes. Bacteria were also carried in phagocytic cells to lymphatics and pulmonary capillaries, thereby establishing bacteraemia. Between the 5th and 7th days bacteria caused necrosis of the phagocytes and were released into the tissues in very large numbers. Destruction of all types of lung cell was widespread during this period but the *Salmonellae* did not penetrate pulmonary cells. From the 9th day onwards bacteria in the lung were restricted to circumscribed abscesses and lymphoid tissue developed throughout the lungs. These latter changes coincided with the appearance of circulating specific antibody.

BACTERIAL pneumonia occurs commonly in man and animals but there have been few reports published on the ultrastructure of the interaction between such organisms and the lung tissue (Loosli and Baker, 1962; Merckx, Brown and Karlson, 1964; Finegold, 1969). Pneumonic salmonellosis in the pig provides a useful and naturally occurring model for the study of acute pneumonia due to Gram-negative bacteria in man and other animals. It is also a suitable condition for investigation of phagocytosis of these organisms *in vivo* and supplements previous *in vitro* studies on the phagocytosis of *Salmonellae* (Furness, 1958; Morello and Baker, 1965; Friedberg and Shilo, 1970). Salmonellosis in the pig is caused mainly by *Salmonella cholerae-suis*, and the disease often occurs primarily as a purulent pneumonia associated with septicaemia. Although human infection with *Salm. cholerae-suis* is not common, when it does occur the organism produces a severe and often fatal disease in which purulent pneumonia is frequently a feature. Experimental studies (Baskerville and Dow, *in press*) indicate that pneumonic salmonellosis in pigs is probably initiated by infection of the nasal mucosa, followed by direct spread of the organisms from the upper respiratory tract into the lungs. The clinical features of the disease and the histology of the pneumonia produced in these experiments have already been described (Baskerville and Dow, *in press*). In order to examine the fate of the organisms and their role in the development of the pulmonary lesions, lung tissue was examined in the electron microscope from pigs killed at intervals from 6 hours to 14 days after

* Present address: Microbiological Research Establishment, Porton Down, Salisbury, Wilts.

intranasal infection with *Salm. cholerae-suis*. This communication describes the ultrastructure of the uptake of *Salm. cholerae-suis* by pulmonary macrophages and examines the changes which subsequently occur in the lung.

MATERIALS AND METHODS

Twenty 5-week old pigs of either sex were used. They were reared conventionally in the laboratory's herd of minimal disease Large White pigs which were free from evidence of *Salm. cholerae-suis* infection. Repeated serological examination of the herd over a period of 10 years has failed to show any significant titres to this organism. The organism used for infection was from a pool of freeze-dried *Salm. cholerae-suis* var. Kunzendorf originally isolated in this laboratory from a pig with natural salmonellosis. Sixteen of the animals were infected by instilling into each nostril 2 ml of a suspension of the organism in physiological saline containing 0.25% mucin. The number of viable organisms in the inoculum was 10^9 per ml, estimated by the method of Miles and Misra (1938). Pigs were killed by rapid intravenous injection of sodium pentobarbitone at 6, 7, 8, 9, 10, 18 and 24 hours post-inoculation, at daily intervals from 24 hours to 7 days, and on the 9th, 11th and 14th days after infection. The 4 remaining pigs served as controls. These were inoculated intranasally with 4 ml of sterile physiological saline containing 0.25% mucin and they were killed at daily intervals from 1 to 4 days after inoculation.

In addition to material taken for histological examination (Baskerville and Dow, in press), portions of pneumonic lung tissue approximately 1 mm³ in size were excised and placed in cold 4% glutaraldehyde buffered at pH 7.2 with cacodylate for electron microscopy. Small areas of discolouration were visible in the lungs 7 hours after infection and consolidation was evident at all the later stages. In the case of the 6-hour stage, no gross changes were apparent and a large number of portions of the lung was therefore taken from the right apical and right cardiac lobes, regions which consistently showed pneumonic lesions later. The lung tissue was stored in 5% buffered sucrose for not longer than 4 days, post-fixed in 1% osmium tetroxide and embedded in Araldite. Sections cut on an LKB Ultratome III were stained for 15 min with uranyl acetate and subsequently for 5 min with lead citrate (Reynolds, 1963), and they were examined in an AEI EM6B electron microscope.

RESULTS

6 hours-4 days

No organisms could be found in any situation in the lungs of the pig killed 6 hours after infection, even though sections from a large number of blocks were examined. There was also no evidence of a cellular reaction either by light or electron microscopy and the lung tissue was entirely normal. At 7 hours a moderate number of polymorphonuclear leucocytes (PMN) and fewer pulmonary macrophages were present in the lumina of small airways and in alveoli, and many of these cells were engulfing bacteria. Only a relatively small number of organisms was still free at this time. Free bacteria had a similar ultrastructure to that of some other species of *Salmonella* recorded by earlier workers (Yamamoto, 1966; Takeuchi, 1967). The bacteria were ingested by encirclement by cytoplasmic processes of PMN and macrophages, the apposed tips of which then fused so that initially the limiting membrane of the phagosome was continuous with the plasma membrane at the cell surface. The pseudopodia of macrophages were in general much longer than those of PMN.

Numerous organisms were seen cut in many different planes of section within phagosomes of PMN and macrophages at all stages from 7 hours to 4 days (Fig. 1). The phagosomes contained either single bacteria (Fig. 2) or groups of a few or as many as 20 (Fig. 1). Multiplying bacteria were present in phagosomes in macrophages and PMN as early as 7 hours after infection and at most later stages (Fig. 3). Organisms undergoing division were almost twice as long as non-dividing cells and

clearly showed a constriction of the cell formed by ingrowth of the wall (Fig. 3). This was accompanied by the formation of an internal equatorial septum which was observed in varying stages of development in different bacteria. By 8 hours post-infection only isolated bacteria were found free in alveoli, and there were now many more PMN and macrophages here and in the lumina of bronchioli. The intensity and extent of this cellular response increased progressively throughout this phase. PMN were the predominant cell type up to the 4th day, but the number of macrophages present gradually increased.

Degranulation of PMN occurred in association with phagocytosis of organisms, and many PMN which contained large numbers of organisms had few or no visible granules. In some sections the granules of PMN and the lysosomes of macrophages were observed discharging their contents into the cavity of a phagosome. In addition to organisms, many of the phagosomes contained myeloid whorls and other aggregations of membranes (Fig. 4). Frequently the limiting membrane of a phagosome was itself being destroyed, and well-defined breaks in the membrane were visible, adjacent to which were single or multiple curls of unit membranes (Fig. 5 and 6). The outer wall of a bacterium appeared to have fused with the membrane of the phagosome in a few cells. Macrophages often contained autophagosomes consisting of sequestered myeloid whorls and degenerating cell organelles separated by a unit membrane from the rest of the cytoplasm. Other macrophages, particularly from the 4th day, had engulfed fibrin as well as organisms into separate vacuoles.

Although a large number of phagocytosed bacteria were morphologically intact, degenerative changes were seen in many others by 7 hours and also at all other stages. These changes consisted of loss of ribosomes, leaving a few clumps both centrally in the bacterial cell and at its periphery (Fig. 4 and 7), and shrinkage of the cytoplasmic components away from the cell wall (Fig. 7). Reduction in the quantity of ribosomal material made the fibrillar network of the organism prominent. The cell wall often became grossly distorted, forming undulations and large projections, and these irregularities were followed by complete breakdown of the wall and cytoplasm into fragments of electron-dense material (Fig. 7). Degenerative changes seen in a few PMN and macrophages containing organisms during this phase were vacuolation of the cytoplasm, disruption of mitochondria and gross distension of the perinuclear space with margination and eventually loss of nuclear chromatin (Fig. 8). In some PMN the nuclear changes were first apparent in one lobe of the nucleus only (Fig. 8).

Organisms did not penetrate the epithelial cells of bronchioli nor those of alveoli, but they were present within mononuclear phagocytes which were migrating through the epithelium by entering at intercellular junctions and passing between the cells. By this means intracellular bacteria reached the loose connective tissue of the airways and interalveolar septa.

5-14 days

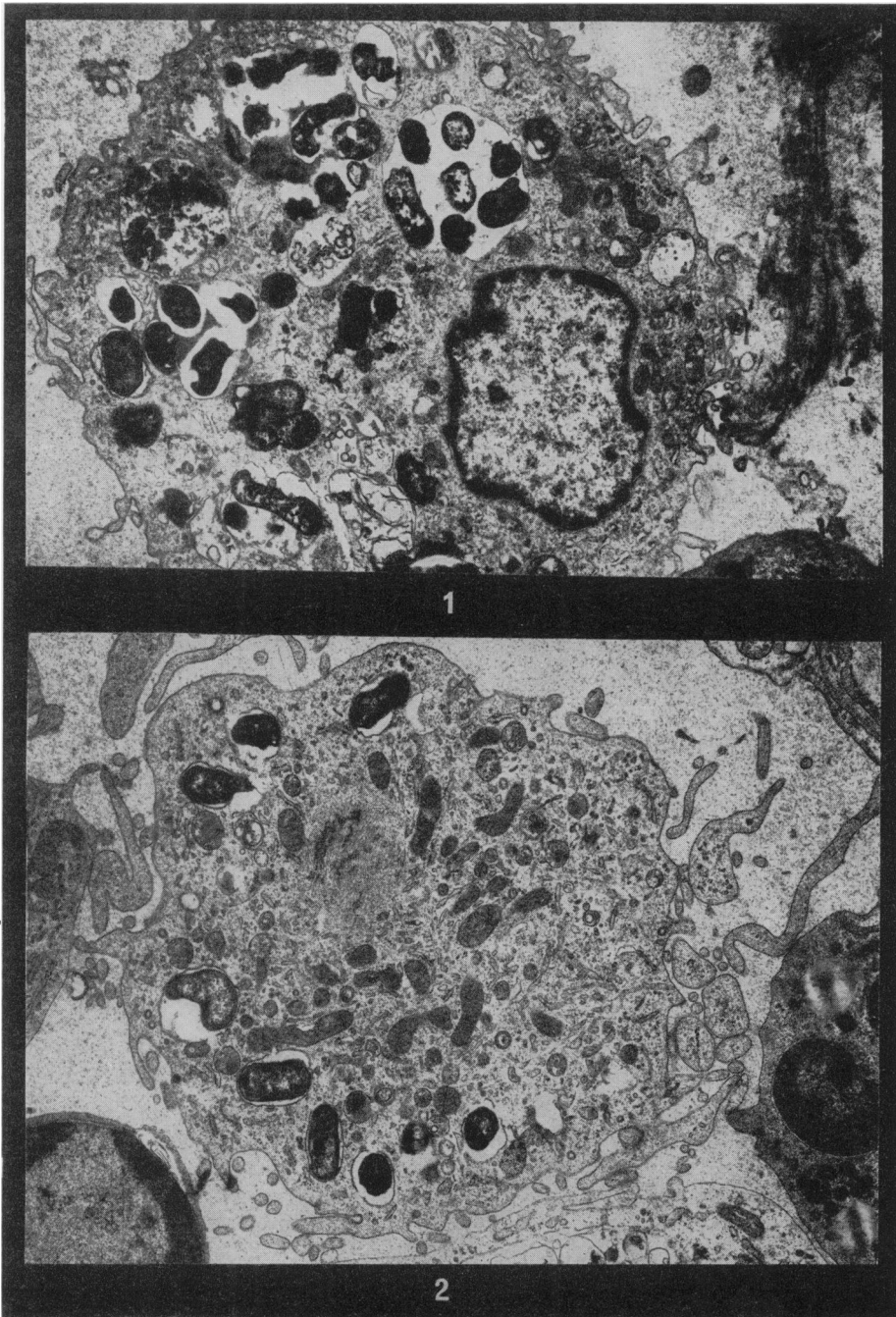
The striking change from the 5th to the 7th day was that bacteria were now being liberated in large numbers from disintegrating phagocytes packed with organisms in all situations in the lungs (Fig. 9 and 10). Numerous free organisms showing no morphological evidence of degeneration were scattered amongst debris and oedema fluid in the lumina of small airways and alveoli, and some

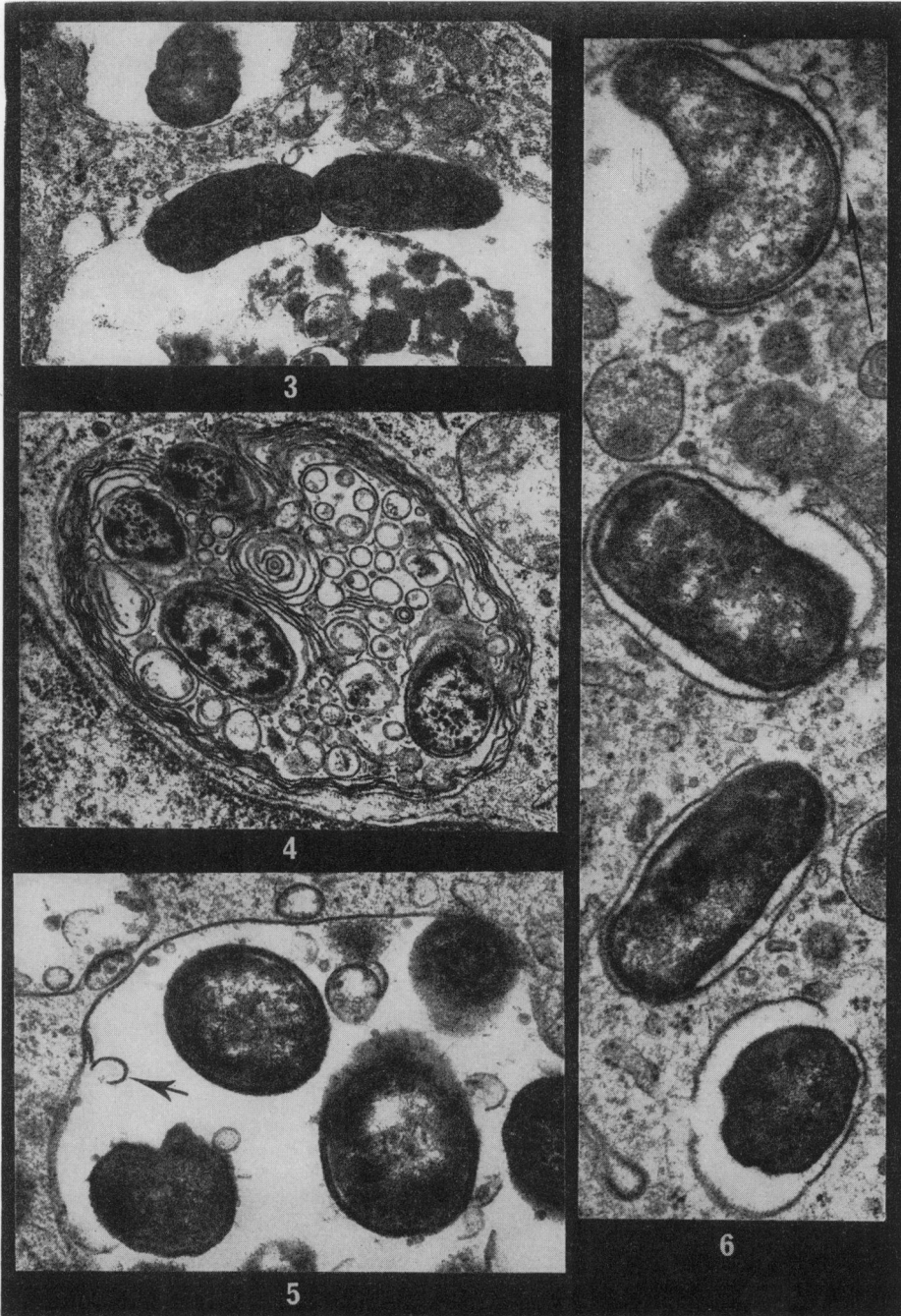
bacteria were undergoing division (Fig. 11). Smaller numbers of free bacteria were also present in peribronchiolar lymphatics and within alveolar capillaries. Organisms were observed within phagosomes of mononuclear phagocytes circulating in capillaries (Fig. 12) and in similar cells and PMN trapped in mixed platelet-leucocyte thrombi in alveolar capillaries, and in thrombi in pulmonary lymphatics. Numerous vacuoles, large myeloid figures and lipid droplets were present in the cytoplasm of degenerating phagocytes, and the plasma membrane of such cells disintegrated to release clumps of amorphous granular cytoplasmic constituents. Histologically, the pneumonia from the 5th to the 7th day was characterized by widespread destruction of the walls of small airways and interalveolar septa, and by lymphatic and alveolar capillary thrombosis. This subsequently led to the formation of large abscesses. Electron microscopy showed that during this period destruction of the epithelium and connective tissue cells of small airways and interalveolar septa was not the result of penetration by bacteria, nor even of the attachment of organisms to their surfaces. Bacteria were never seen within or in contact with cells other than PMN or macrophages.

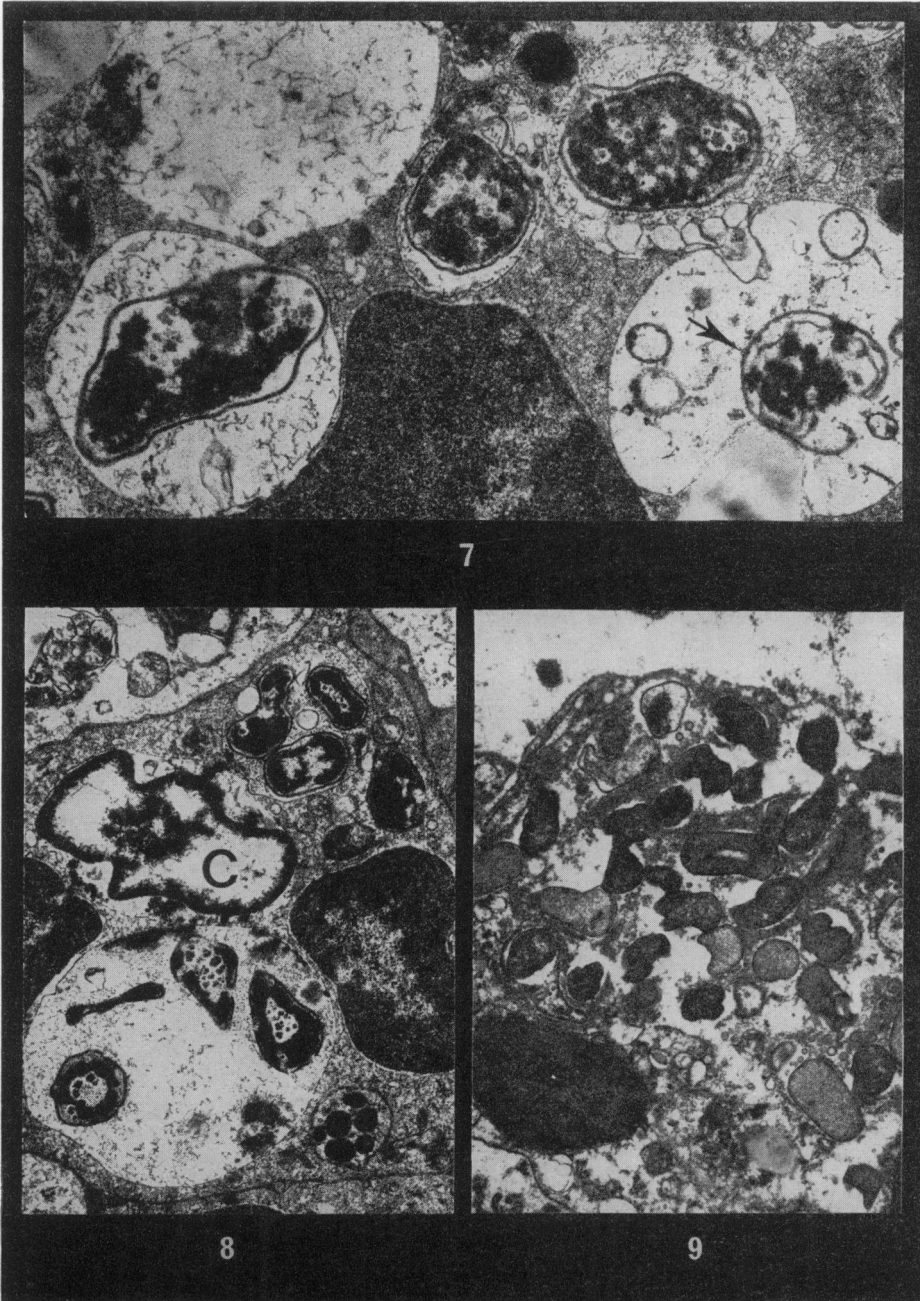
From the 9th to the 14th days bacteria, both free and within degenerating PMN and macrophages, were present in large numbers in abscesses and many of them were undergoing degeneration and disintegration. Organisms were rarely found free in other sites and only relatively small numbers of macrophages containing degenerating bacteria could be located. These macrophages were situated in densely cellular regions of interalveolar septa thickened by the presence of many lymphoid and plasma cells, and in enlarged peribronchiolar lymphoid nodules which showed mitotic activity. In these areas cells with the fine structure of reticulum cells also contained degenerating bacteria within phagosomes.

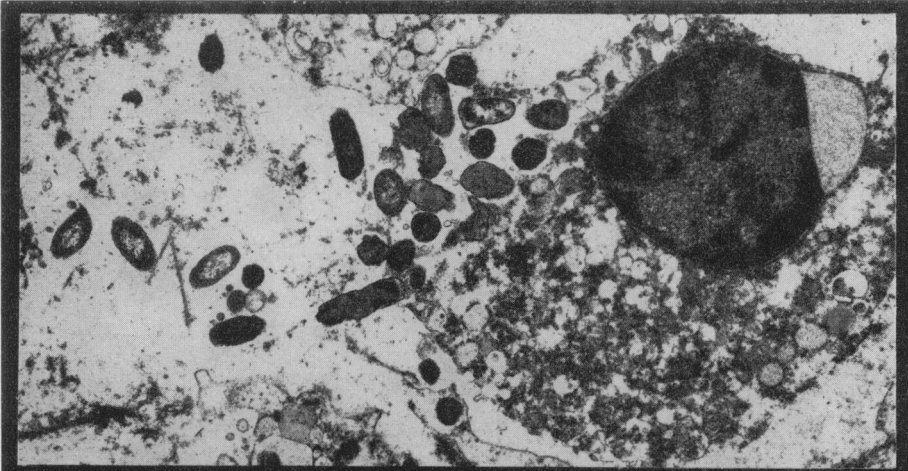EXPLANATION OF PLATES

- FIG. 1.—Pulmonary macrophage 7 hours after infection. A number of the phagosomes contain groups of bacteria. $\times 12,500$.
- FIG. 2.—Macrophage in alveolus showing phagosomes each apparently containing a single organism. $\times 11,250$.
- FIG. 3.—Dividing *Salmonella* with a macrophage phagosome at 7 hours. The upper phagosome contains an organism sectioned transversely. $\times 22,500$.
- FIG. 4.—Degenerating bacteria in phagosomes of pulmonary macrophage. Some ribosomal material has been lost, revealing a fibrillar network. The remainder of the phagosome is filled with layers of membranes. $\times 26,250$.
- FIG. 5.—Early degeneration of limiting membrane of phagosome. A portion of the membrane has become detached (arrow). The phagosome contains 5 *Salmonellae*. $\times 46,500$.
- FIG. 6.—Degeneration of phagosome membranes in a macrophage. There are well-defined breaks in the unit membranes and in the phagosome at the top of the picture there is apparent fusion of the bacterial cell wall with the phagosome membrane (arrow). $\times 43,000$.
- FIG. 7.—Destruction of bacteria phagocytosed by a polymorph. The cell wall of the organism on the extreme left is distorted and its cytoplasm is disintegrating. The bacterium on the right (arrow) has been almost completely destroyed. $\times 27,000$.
- FIG. 8.—Polymorph containing ingested *Salmonellae*. The central lobe of the nucleus (C) exhibits margination and overall loss of chromatin and its perinuclear space is considerably distended. Note the paucity of cytoplasmic granules. Phagocytosed organisms show degenerative changes. $\times 14,500$.
- FIG. 9.—Pulmonary macrophage filled with bacteria 7 days after infection. The nucleus and cytoplasmic organelles show extreme degeneration. $\times 12,500$.
- FIG. 10.—Release of *Salmonellae* from a disintegrating intra-alveolar macrophage at 7 days. $\times 9,200$.
- FIG. 11.—Extracellular dividing *Salmonella cholerae-suis* showing typical constriction of the cell wall. $\times 40,000$.
- FIG. 12.—Bacteria within phagosomes of a mononuclear phagocyte circulating in a pulmonary capillary at 5 days. $\times 9,200$.

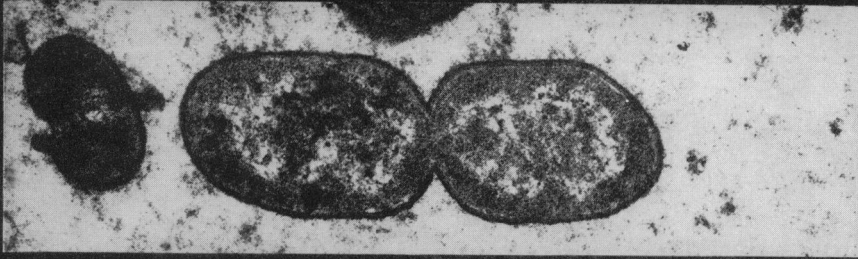




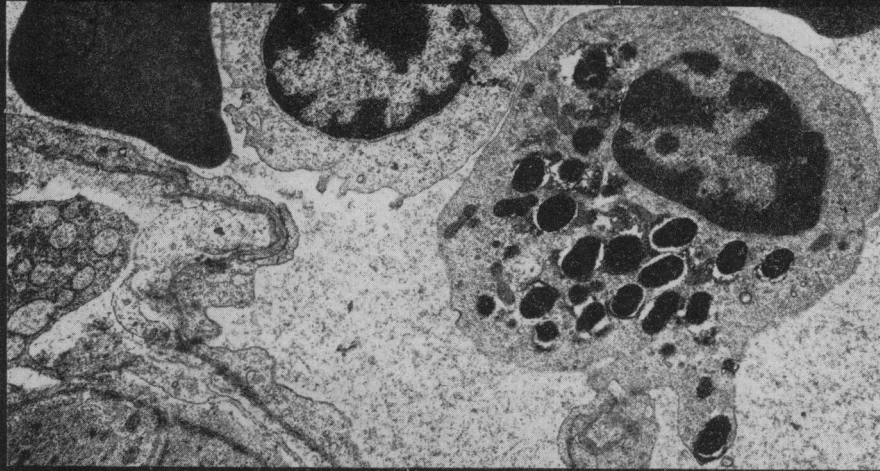




10



11



12

Control animals

No lesions were detected in the lungs of any of the 4 pigs grossly or on histological and electron microscopical examination.

DISCUSSION

There have been no previous reports on the structure of *Salm. cholerae-suis* in thin sections, either *in vitro* or *in vivo*, but the morphology of the organism in the lung was identical with that of other species of *Salmonellae* (Yamamoto, 1966; Takeuchi, 1967) and with that of *Salm. cholerae-suis* from the same pool grown in the same manner and sectioned (Baskerville and Curran, unpublished observations). The striking feature of the behaviour of *Salm. cholerae-suis* in the lung was that the organism did not invade the epithelium of bronchioli or alveoli, nor did it become attached to the surface of the epithelial cells. This is in contrast to the behaviour in the intestine of *Salm. typhimurium*, which penetrates the columnar epithelial cells and thus gains entry to the lamina propria and its lymphatics (Takeuchi, 1967; Takeuchi and Sprinz, 1967). The spread of *Salm. cholerae-suis* from the lumina of airways and alveoli into connective tissue, lymphatics and capillaries of the lung was achieved only indirectly, by being carried within migrating phagocytes. Since no electron microscopical studies have been carried out on the pathogenesis of enteritis caused by *Salm. cholerae-suis*, it is not known whether the organism behaves in a similar way to *Salm. typhimurium* in the intestine and its mode of action modified in the different environment of the lung, or whether *Salm. cholerae-suis* is incapable of direct penetration of epithelium under all circumstances. The only reports which exist concerning the ultrastructure of experimental bacterial pneumonia show that neither *Pasteurella pestis* (Finegold, 1969) nor pneumococci (Loosli and Baker, 1962) penetrate the epithelium of the lower respiratory tract.

In the present experiment the organism employed was highly virulent and the experimental animals were completely susceptible. The resulting disease was therefore of maximum severity and not modified in favour of phagocytosis and destruction of the bacteria, as is the case in bacterial disease in animals possessing circulating specific antibody. Since a significant number of organisms had not arrived in the distal lung tissue at 6 hours, but by 7 hours the majority of a large number had been phagocytosed, the phagocytic efficiency of the cells was obviously high and the organisms, though virulent, were unable to inhibit phagocytosis. Although many of the *Salmonellae* were killed within phagocytes, some probably within 1 hour of ingestion, large numbers of them were able to survive and multiply and later cause necrosis of the cells which had engulfed them. This finding is in agreement with the work of Furness (1958), who showed that *in vitro* the virulence of *Salm. typhimurium* influenced the capacity of the bacteria to multiply within phagocytes but not the rate of their ingestion. In addition to the virulence of the organism, another factor affecting the outcome of phagocytosis is the bactericidal efficiency of the phagocyte. It is possible that each phagocytic cell has a limit to its metabolic capabilities for producing lysosomes and at any time can deal effectively with only a certain number of organisms. Consequently, if the cell ingests more bacteria than it is competent to deal with the excess organisms can survive and multiply. In this respect there was no detectable difference between the phagocytic and bactericidal powers of PMN and of macro-

phages. The ability of *Salm. cholerae-suis* to grow in and destroy host cells is also shared by virulent strains of *Salm. enteritidis* and *Salm. typhimurium* (Yamamoto, 1966; Mackaness and Blanden, 1967) and it is well known that most *Salmonellae* multiply readily, and even preferentially, within macrophages (Mackaness, 1964).

Damage to phagocytes was probably the result of endotoxins released from the cell wall of ingested organisms, and evidence of this was disintegration of the limiting membrane of many phagosomes which contained bacteria. Endotoxin produced by phagocytosed bacteria is known to damage lysosomal membranes, and by the resultant release of enzymes causes autolysis of the affected cells (Weissman, 1964). In the present study, the phase of intracellular growth and multiplication ended between the 5th and 7th days with necrosis of the host phagocytes and the spectacular release of large numbers of organisms. This coincided with the establishment of septicaemia and the maximum destruction of lung tissue, in which bacteria were numerous and widespread. From the 9th day onwards there was progressive containment of the pneumonia and almost complete restriction of bacteria to circumscribed abscesses. This change in the pathological process and the subsequent clinical recovery of the animal can be correlated with the appearance of circulating specific antibody, which is first detectable in infected pigs on the 7th day (Lawson, 1965).

Damage to bronchiolar epithelium and to alveolar epithelial cells was not the result of invasion by the organisms, nor of their attachment to the cell surface, though degenerating cells commonly had bacteria in their immediate vicinity. The effects on the lung tissue must therefore have been brought about indirectly, possibly by diffusible substances produced by the *Salmonella*. *Salmonellae* can affect cells at a distance without physical contact, as was strikingly demonstrated by Takeuchi (1967), who showed that when *Salm. typhimurium* approached to within a critical distance of the intestinal epithelium the brush border degenerated. Takeuchi did not identify the substance mediating this effect, but a similar agent may well be responsible for the necrosis of pulmonary cells in infection with *Salm. cholerae-suis*. Since endotoxins are components of the bacterial cell wall and are liberated only on its destruction, it is unlikely that they are liberated from intact extracellular organisms, which are those apparently associated with tissue destruction. This suggests that either toxins similar in type to those elaborated by pathogenic strains of *E. coli* (Smith and Halls, 1967) are produced by *Salm. cholerae-suis* or that mechanisms, at present unknown, other than toxin production may be responsible for the pathogenic activity of this organism.

We are grateful to Miss L. G. Hewitt for skilled technical assistance.

REFERENCES

- BASKERVILLE, A. & DOW, C. (1972) The Pathology of Experimental Pneumonia in Pigs produced by *Salmonella cholerae-suis*. *J. comp. Path.* In press.
- FINEGOLD, M. J. (1969) Pneumonic Plague in Monkeys. An Electron Microscopic Study. *Am. J. Path.*, **54**, 167.
- FRIEDBERG, D. & SHILO, M. (1970) Role of Cell Wall Structure of *Salmonella* in the Interaction with Phagocytes. *Infect. Immun.*, **2**, 279.
- FURNESS, G. (1958) Interaction between *Salmonella typhimurium* and Phagocytic Cells in Cell Culture. *J. infect. Dis.*, **103**, 272.
- LAWSON, G. H. K. (1965) Ph.D. Thesis, Queen's University of Belfast.

- LAWSON, G. H. K. & DOW, C. (1965) The Pathogenesis of Oral *Salmonella cholerae-suis* Infection in Pigs. *J. comp. Path.*, **75**, 75.
- LOOSLI, C. G. & BAKER, R. F. (1962) Acute Experimental Pneumococcal (Type I) Pneumonia in the Mouse: the Migration of Leucocytes from the Pulmonary Capillaries into the Alveolar Spaces as Revealed by the Electron Microscope. *Trans. Am. clin. clin. Ass.*, **74**, 15.
- MACKANESS, G. B. (1964) The Behaviour of Microbial Parasites in Relation to Phagocytic Cells *in vitro* and *in vivo*. In *Microbial Behaviour in vivo and in vitro*. Ed. H. Smith and J. Taylor. London: Cambridge University Press. p. 213.
- MACKANESS, G. B. & BLANDEN, R. V. (1967) Cellular Immunity. In *Progress in Allergy*, Vol. 11. Ed. P. Kallos and B. H. Waksman. Basel: Karger. p. 89.
- MERCKX, J. J., BROWN, A. L. & KARLSON, A. G. (1964) An Electron Microscopic Study of Experimental Infections with Acid-fast Bacilli. *Am. Rev. resp. Dis.*, **89**, 485.
- MILES, A. A. & MISRA, S. S. (1938) The Estimation of the Bactericidal Power of the Blood. *J. Hyg., Camb.*, **38**, 732.
- MORELLO, J. A. & BAKER, E. E. (1965) Interaction of *Salmonella* with Phagocytes *in vitro*. *J. infect. Dis.*, **115**, 131.
- REYNOLDS, E. S. (1963) The Use of Lead Citrate at High pH as an Electronopaque Stain in Electron Microscopy. *J. Cell Biol.*, **17**, 208.
- SMITH, H. W. & HALLS, S. (1967) Studies on *Escherichia coli* Enterotoxin. *J. Path. Bact.*, **93**, 531.
- TAKEUCHI, A. (1967) Electron Microscope Studies of Experimental Salmonella Infection. I. Penetration into the Intestinal Epithelium by *Salmonella typhimurium*. *Am. J. Path.*, **50**, 109.
- TAKEUCHI, A. & SPRINZ, H. (1967) Electron Microscope Studies of Experimental Salmonella Infection in the Preconditioned Guinea-pig. II. Response of the Intestinal Mucosa to the Invasion by *Salmonella typhimurium*. *Am. J. Path.*, **51**, 137.
- WEISSMAN, G. (1964) Labilization and Stabilization of Lysosomes. *Fed. Proc.*, **23**, 1038.
- YAMAMOTO, I. (1966) Ultrastructural Changes in Mesenteric Lymph Nodes of Mice Infected with *Salmonella enteritidis*. *J. infect. Dis.*, **116**, 8.
-