

AN ELECTRON MICROSCOPE STUDY OF THE RESPONSE OF MESOTHELIAL CELLS TO THE INTRAPLEURAL INJECTION OF ASBESTOS DUST

J. M. G. DAVIS

From the Institute of Occupational Medicine, Edinburgh

Received for publication October 3, 1973

Summary.—Studies of the pleural mesothelium in rats, mice, and guinea-pigs following the intrapleural injection of asbestos dust, showed that for 6 months at least this dust did not induce mesothelial hyperplasia. During the first few days after injection some areas of mesothelial cells became rounded and less clearly attached to one another, and a few were found to contain small numbers of asbestos fibres. During this period there was evidence of the penetration of asbestos fibres between the mesothelial cells, into the submesothelial connective tissues. Later in the studies the mesothelium covering most of the pleural cavity returned to normal, but where mesothelium covered asbestos granulomata, the cells were found to be extremely flattened, and without surface microvilli. Usually the mesothelial covering was complete, but in some areas pores were found penetrating the mesothelial cell cytoplasm and leaving areas of connective tissue in direct contact with the pleural cavity. In a few cases mesothelial cells were found lining clefts within the connective tissue of asbestos granulomata.

SINCE the discovery by Wagner, Sleggs and Marchand (1960) that the development of pleural and peritoneal mesotheliomata in humans was often associated with exposure to asbestos dust, a large number of experimental studies have been undertaken in order to determine the degree of carcinogenicity of different types of asbestos and the types of tumour that could be produced by this dust. Wagner *et al.* in 1969 showed that after intrapleural injection the dust was extremely carcinogenic for rats and reported the production of mesotheliomata in as many as 60% of the animals injected. Similar figures were produced by Stanton, Blackwell and Miller (1969) and Stanton and Wrench (1972). Both these workers and Smith *et al.* (1965) showed that asbestos induced tumours exhibited the same very variable histological patterns that are characteristic of human mesotheliomata, and reported that tumours frequently showed areas containing cells of both epithelial and connective tissue type. The connective tissue cells were usually spindle shaped but the epithelial elements could exhibit either a medullary, papillary or tubulo-papillary pattern. These experimental studies were aimed primarily at determining the degree of carcinogenicity of a variety of asbestos or other mineral fibre samples and did not involve a detailed study of the exact site and method of tumour induction. For this reason it was decided to undertake separate studies involving the injection of asbestos samples into the pleural and peritoneal cavities of rats, mice and guinea-pigs and to use a combination of light microscope and electron microscope methods in an attempt to elucidate these points. The early

fibrogenic effects of these dusts were reported by Davis (1970) and a report on the formation of tumours in this group of animals is now awaiting publication (Davis, unpublished). In this latter study it was found that primary tumours of the peritoneal cavities of rats and mice at least, did not develop from the single layer of mesothelial cells lining the cavity, as had been originally believed, but from connective tissue cells below the mesothelial surfaces. The present paper reports on the initial effects of injected asbestos on the mesothelial cells lining the pleural cavities of experimental animals and on their behaviour during the first 6 months of the experiments.

MATERIALS AND METHODS

The dust samples administered in these experiments were supplied by Dr P. F. Holt of Reading University and had been prepared for use in his inhalation chambers. The milling apparatus used was described by Holt and Young (1960). The dust consisted almost entirely of fibrous asbestos material which varied in size from large bundles 100 μm long and up to 10 μm in diameter down to single crystals less than 1 μm long. The majority of the dust however was in the form of crystal bundles less than 5 μm in length and between 0.1 μm and 1 μm in diameter. The animals examined in this study were taken from the population used in a study of the ultrastructure of experimental mesotheliomata (Davis, 1973). They consisted of groups of 20 guinea-pigs (Bernard Hartley strain) 20 rats (Wistar strain) and 20 mice (Balb/C strain). Ten animals from each group were injected intrapleurally with crocidolite and 10 with chrysotile. In each case the doses were 25 mg for guinea-pigs and rats, suspended in 1 ml of distilled water, and 10 mg for mice, suspended in 0.5 ml of distilled water. These animals were killed at intervals from 7 days to 6 months after dust injection and tissue was taken for both light microscope and electron microscope examination. Light microscope specimens were fixed in formol saline and sections were stained with either haematoxylin and eosin, Van Gieson's method for collagen or Gordon Sweet's method for reticulin. Electron microscope specimens were fixed in buffered osmium tetroxide, embedded in Araldite, and after sectioning were stained with lead citrate.

RESULTS

When large doses of either crocidolite or chrysotile asbestos were injected into the pleural cavities of experimental animals most of the dust was quickly incorporated in large cellular granulomata which were fully formed by 14 days after dust injection, and which did not increase in size after this time. Guinea-pigs, rats and mice produced similar cellular reactions to both crocidolite and chrysotile although crocidolite dust tended to spread more rapidly after injection and crocidolite granulomata tended to be smaller although more numerous and widely scattered than those produced in response to chrysotile dust. The earliest cellular response to dust in all cases consisted of an accumulation of macrophages, but giant cells and fibroblasts were present in the granulomata within a few days, although giant cells were much more abundant in the lesions of guinea-pigs than those found in rats and mice (Davis, 1970). In some instances the asbestos granulomata were coated with a distinct capsule of fibrous tissue from a few days after the start of the experiment, but all the granulomata eventually became less cellular with time and some were eventually converted to areas of acellular fibrous tissue. A small amount of dust never became involved in the granulomata and the fate of this was variable. Some was transported to the local lymph nodes. A few particles were taken up by mesothelial cells, and some was found in single macrophages lying in the submesothelial connective tissue.

The mesothelial cells themselves did not exhibit any signs of hyperplasia at any stage of these studies (Davis, unpublished), but while always present as a single

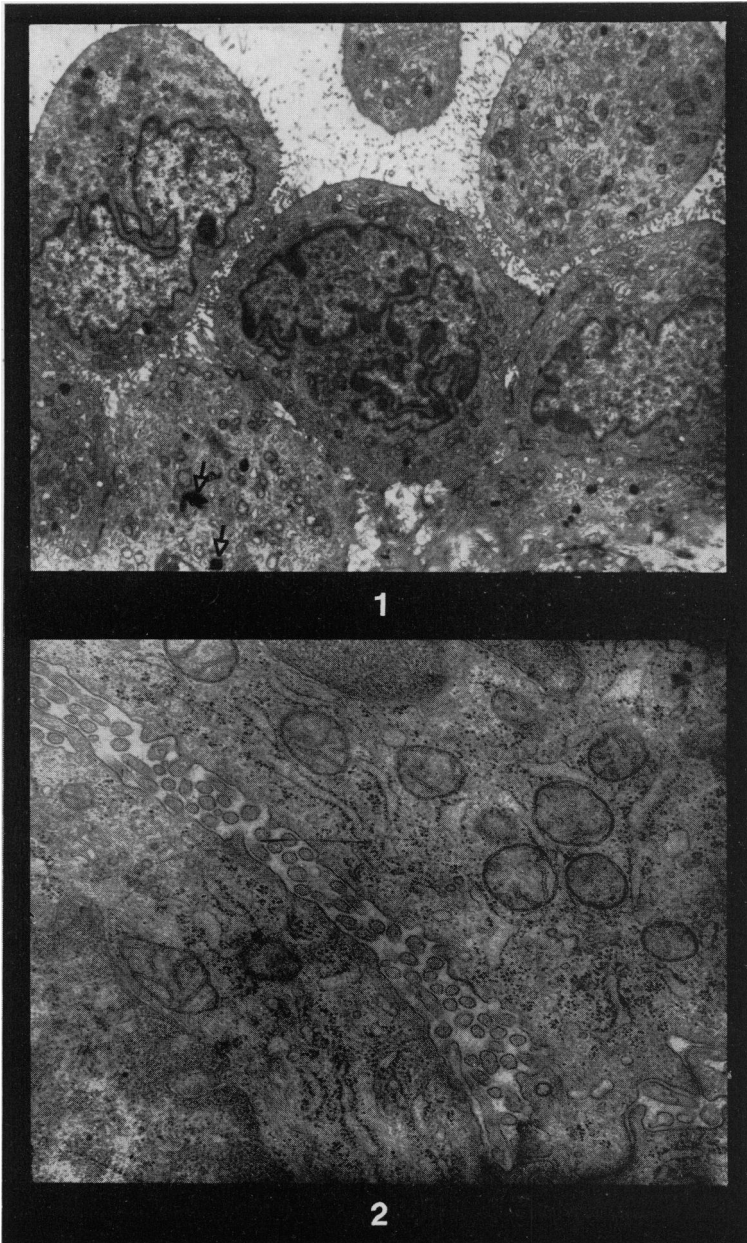
layer, some of these cells assumed a more cuboidal form than usual during the first weeks after dust injection. They soon resumed their flattened appearance, however, and in some cases, where the cells covered areas of fibrous tissue or the surfaces of the granulomata themselves, mesothelial cells were extremely extended and their cytoplasm was difficult to see with the light microscope. From 6 weeks after dust injection no changes were observed in any of the mesothelial surfaces. The last animals were killed 6 months after the start of the experiment.

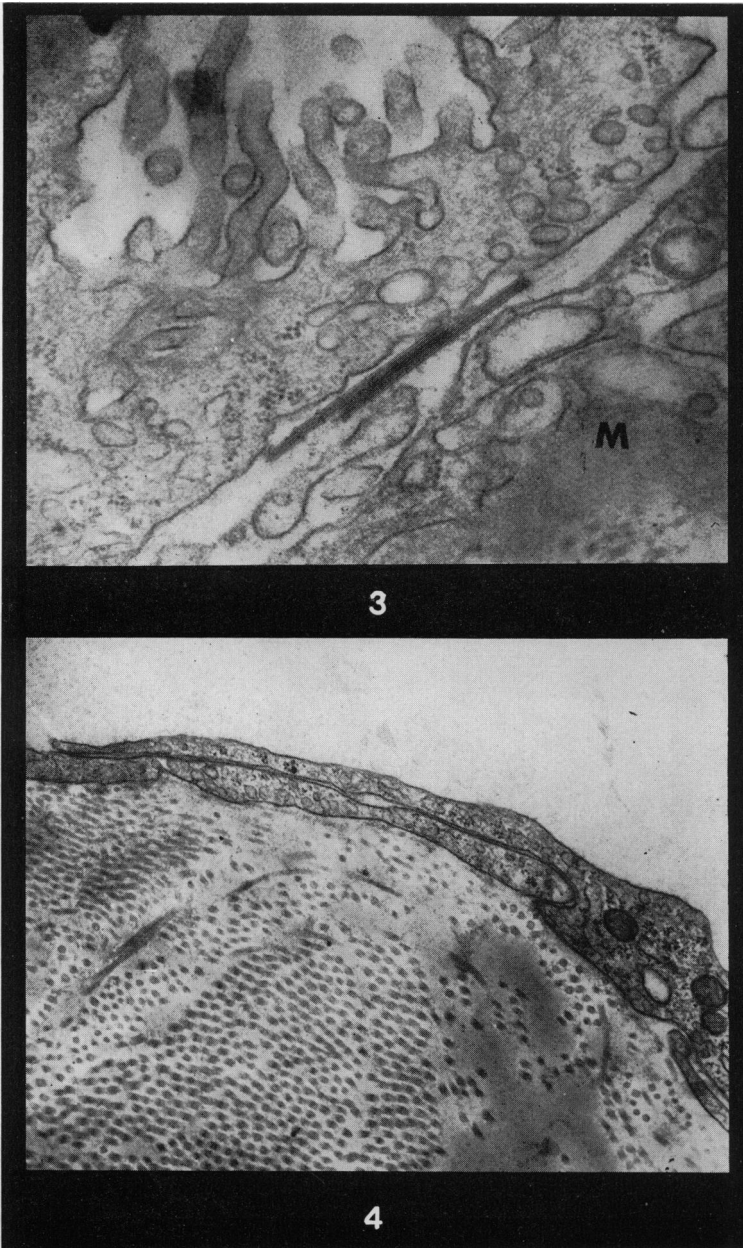
Electron microscope examination of pleural surfaces from control animals showed that the mesothelial cells from these species had an almost identical structure and this was similar to that described by Oder (1954) and by Baradi and Hope (1964) for rats and rabbits respectively. The mesothelial cells were attached to a distinct basement membrane, and their free surfaces possessed numerous elongated microvilli approximately 100 nm in diameter and from 0.5 to 2 μ m in length. The cell cytoplasm contained numerous short lengths of granular endoplasmic reticulum, mitochondria were numerous, and frequently bundles of cytoplasmic microfilaments were found. The outline of the cell nucleus was often extremely irregular and in some cases the nucleus was divided into a series of lobes. Laterally the cells were firmly attached to one another by membrane, tight junctional complexes and occasional desmosomes.

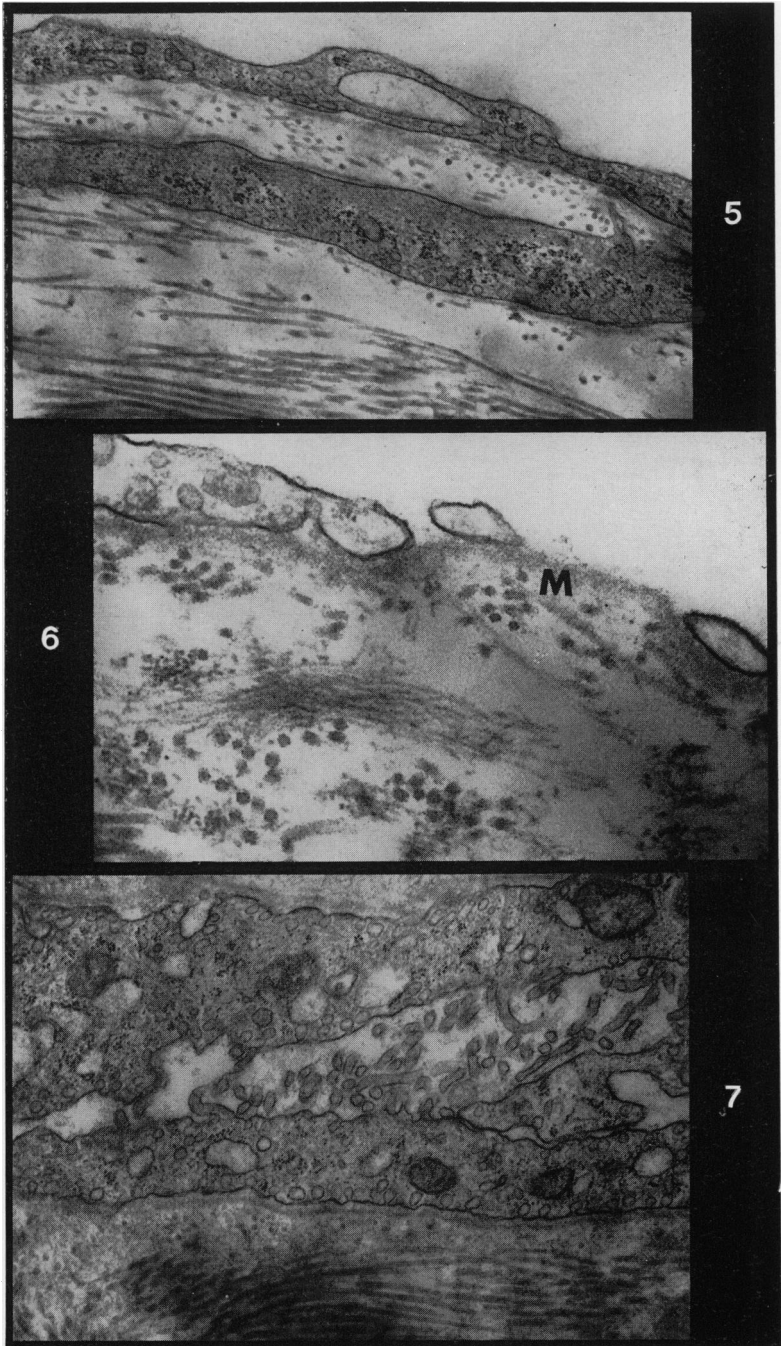
After dust injection the mesothelial cells in some areas became more rounded than usual and electron microscope examination showed that a few of these cells contained small particles of asbestos dust (Fig. 1). These dust particles were not contained in distinct cytoplasmic vacuoles like macrophage phagosomes, but

EXPLANATION OF PLATES

- FIG. 1.—A tangential section of the mesothelial surface of a guinea-pig 2 weeks after the intrapleural injection of chrysotile asbestos. Most of the cells are rounded and have numerous microvilli on their surface membranes. The lateral contact between the cells is very loose and although some desmosomes are present, the cells are for the most part separated by loosely interdigitated microvilli. In this field one cell contains a few very small particles of chrysotile dust (arrowed). $\times 3250$.
- FIG. 2.—A high magnification photograph of the contact zone between two rounded mesothelial cells from a guinea-pig pleural cavity 2 weeks after the injection of chrysotile asbestos dust. The cells are widely separated by microvilli. Within the cell cytoplasm a well developed granular endoplasmic reticulum is present, and bundles of microfilaments also occur in the lower cell. $\times 27,500$.
- FIG. 3.—Overlapping areas of cytoplasm from two mesothelial cells from the pleural cavity of a guinea-pig 2 weeks after the injection of chrysotile asbestos dust. Two crystals of chrysotile have penetrated into the intercellular space between the cells. Numerous microvilli are present on the free surface of the upper cell. The basement membrane beneath the lower cell is marked M. $\times 37,500$.
- FIG. 4.—Overlapping areas of cytoplasm from two mesothelial cells covering an asbestos granuloma within the pleural cavity of a rat 3 months after the intrapleural injection of chrysotile asbestos. The cytoplasm of both cells is extremely extended and no surface microvilli are present. There is no apparent basement membrane beneath the cells. $\times 24,000$.
- FIG. 5.—Cytoplasm from cells covering the surface of an asbestos granuloma from the pleural cavity of a rat 3 months after dust injection. Both cells appear very similar in structure, but one forms the surface coating of the granuloma while the other is embedded in fibrous tissue. No microvilli are present on the free cell surfaces. $\times 24,000$.
- FIG. 6.—An area of cytoplasm from a cell covering the surface of an asbestos granuloma in the pleural cavity of a guinea-pig 5 months after the intrapleural injection of chrysotile dust. In this case the covering of the granuloma is incomplete and large pores extend through the thin cytoplasmic layer. In this area a basement membrane (m) is present. $\times 34,000$.
- FIG. 7.—Areas of cytoplasm from two mesothelial cells lining a cleft within the fibrous tissue of an asbestos granuloma. This lesion was found in the pleural cavity of a rat 5 months after dust injection. Numerous microvilli are present on the free surfaces of both cells. $\times 23,000$.







usually they were surrounded by a single closely opposed membrane which separated the dust from the cytoplasmic organelles. It was not possible to determine whether or not the dust was taken up by the mesothelial cells by a process of active phagocytosis or whether forced physical contact with the dust had caused some particles to be pushed deep into the cells. The latter seems more likely, however, since no mesothelial cells were ever found with more than three or four dust particles in their cytoplasm, and by far the majority of mesothelial cells examined contained no dust at all. Apart from the presence of asbestos dust the cytoplasm of the rounded mesothelial cells showed no structural changes (Fig. 2). Tangential sections of layers of mesothelium showed, however, that cell contact was much looser than usual, cytoplasmic processes were often found on the whole circumference of the cell, and frequently there was continuity between the pleural cavity and the basement membrane below the mesothelial cells. In some instances the spaces between the mesothelial cells became wide enough for the penetration of asbestos fibres and these were able to penetrate between the cells into the submesothelial connective tissues (Fig. 3). Very similar results were obtained both from animals injected with chrysotile or crocidolite dust. The presence of crocidolite dust in tissues, however, makes sectioning for electron microscopy extremely difficult and it was not possible to obtain high definition photographs from this material. For this reason all the illustrations in the present paper show tissues from animals treated with chrysotile.

Dust containing mesothelial cells were not found more than 6 weeks after dust injection and it seems likely therefore that these cells die off quite rapidly. In most cases the rounded mesothelial cells quickly returned to normal, but exceptions to this rule were found on the surfaces of granulomata and their surrounding fibrous tissue. On these surfaces it was usual to find that the mesothelial cell cytoplasm was greatly extended so that they were able to cover large areas with a very thin layer. In many cases these extended cells were not associated with a normal basement membrane and cytoplasmic processes were not present on their free surfaces. These extremely flattened mesothelial cells usually showed large areas of overlap between their cytoplasmic extremities, and the membranes of the cells involved were very closely opposed to one another (Fig. 4). Moreover, while a complete mesothelial covering layer was usually present, some cases were found where cytoplasmic pores extended through the mesothelial cells leaving areas of collagen or basement membrane in direct contact with the body cavities (Fig. 6). Although the actual mesothelial covering layer on the granuloma surfaces was never more than one cell thick, some areas were found where parallel layers of cells similar to the surface cells were embedded in the submesothelial connective tissue (Fig. 5). Within the granulomata, one further modification was found in the usual pattern of the mesothelial cell layers. In some cases, near the surfaces of granulomata, narrow clefts were found lined with mesothelial cells. These cells were of normal thickness, could be associated with a basement membrane and possessed normal microvilli on their free surfaces (Fig. 7). It was not possible to determine whether these clefts were all continuous with the body cavity or whether they represented isolated islands of mesothelial cells overtaken by the cellular reaction to the asbestos dust.

DISCUSSION

This study has shown that asbestos dust injected into the pleural cavities of

experimental animals has relatively little effect on the mesothelial lining of these cavities. The majority of mesothelial cells appeared normal for the full duration of the study and no areas of mesothelium showed any signs of hyperplasia. It was not surprising, therefore, that a continuation of these experiments (Davis, 1973) showed that when tumours were produced, the site of tumour genesis was in the submesothelial connective tissues. The initial tumour cell type was similar to primitive mesenchyme and these cells were later able to differentiate into spindle cell or epithelial cell types which gave rise to the variable histological patterns normally associated with mesotheliomata. This finding goes a long way to explain how asbestos taken in by inhalation or perhaps ingestion is able to stimulate tumours in the linings of the body cavities. It has always been extremely difficult to understand how the dust was able to reach and damage the single layers of mesothelial cells, since the presence of asbestos dust in any tissue causes the rapid accumulation of phagocytes which enclose all dust and isolate it from all other tissue elements. If a dust is able to stimulate the phagocytic cells themselves to tumour production, however, then the only difficulty which remains is to explain why the resulting connective tissue tumours appear to be particularly associated with the lining of the body cavities. Roe, Walter and Harington (1967) originally suggested that asbestos injected subcutaneously into mice was easily transported throughout the body and appeared to be selectively deposited in the submesothelial connective tissues. Later studies by Kanazawa *et al.* (1970) and Morgan, Holmes and Gold (1972) have failed to confirm this observation but have shown that dust can be transported from the subcutaneous position to many organs and that some of this is deposited in the submesothelial tissues.

It may be that asbestos is not carcinogenic to fully mature macrophages but only to primitive mesenchyme cells and that these cells, which can give rise to macrophages (Libansky, 1966), only form part of the cellular reaction to dust in submesothelial tissues. Davis (1970) showed that in intrapleural granulomata the asbestos dust was often passaged through several generations of cells. It is possible therefore that mature macrophages might carry dust to the submesothelial tissues, where on its release it is taken up by mesenchymal cells.

Extremely flattened mesothelial cells with no microvilli on their free surfaces have not been reported from the pleural cavity or from many of the peritoneal surfaces. However, both Felix and Dalton (1956) and Fukata (1963) have reported that the mesothelial cells covering the omentum have very few surface processes, and that the cell cytoplasm can be extremely extended. The finding of mesothelial cells without surface processes covering granulomata and areas of fibrous tissue is not therefore unique. It is interesting, however, to consider why the pattern of mesothelial cells should change in areas reacting to the presence of asbestos dust. Dalton reported that mesothelial cells covering the omentum were often not associated with a basement membrane, and this can also apply to the cells covering asbestos lesions. It may be, therefore, that the mesenchymal cells that give rise to the mesothelial covering in both these instances differ from those in other areas in that they have difficulty in producing either mature mesothelial cells or a basement membrane. In the case of the asbestos lesions it is possible that mesenchymal cells involved in the dust reaction may lose some of their powers of differentiation. It is also possible that certain surface conditions are necessary before a covering of mesothelial cells can mature fully and these conditions are not present on the surfaces of asbestos lesions.

The ability of mesothelial cells to take up particulate matter has been studied for some time, but with variable results. A number of workers including Oder (1956), Fukata (1963) and Cotran and Karnovsky (1968) have demonstrated that very fine particulate material is taken up by the cytoplasm of mesothelial cells, but Felix and Dalton (1956) found no melanin granules within mesothelial cells after intraperitoneal injection of this material. It seems likely that extremely small particles (less than 10 nm in diameter) can be transported across the cytoplasm of mesothelial cells by the normal stream of pinocytotic vesicles, but that larger particles cannot use this system. This would indicate that the process of active phagocytosis as seen in macrophages is essentially different from the membrane pinocytosis which can be seen in many cell types. The finding of a very few particles of asbestos dust in mesothelial cells following intrapleural injections does not seriously conflict with the observations of Felix and Dalton. All macrophages in contact with asbestos can take up large numbers of dust particles and in comparison with this, the finding of very few dust particles in a very small number of mesothelial cells merely underlines the fact that the mesothelial cells have little, if any powers of phagocytosis.

This study was undertaken as part of the research programme supported by the British Asbestosis Research Council.

REFERENCES

- BARADI, A. F. & HOPE, J. (1964) Observations on the Ultrastructure of Rabbit Mesothelium. *Expl Cell Res.*, **34**, 33.
- COTRAN, R. S. & KARNOVSKY, M. J. (1968) Ultrastructural Studies on the Permeability of the Mesothelium to Horseradish Peroxidase. *J. Cell Biol.*, **37**, 123.
- DAVIS, J. M. G. (1970) The Long-term Fibrogenic Effects of Chrysotile and Crocidolite Asbestos Dust Injected into the Pleural Cavity of Experimental Animals. *Br. J. exp. Path.*, **51**, 617.
- FELIX, M. D. & DALTON, A. J. (1956) A Comparison of Mesothelial Cells and Macrophages in Mice after the Intraperitoneal Inoculation of Melanin Granules. *J. biophys. biochem. Cytol.*, **2** (Suppl.), 109.
- FUKATA, H. (1963) Electron Microscopic Study on Normal Rat Peritoneal Mesothelium and its Changes in Absorption of Particulate Iron Dextran Complex. *Acta path. jap.*, **13**, 309.
- HOLT, P. F. & YOUNG, D. K. (1960) A Dust Feed Mechanism Suitable for Fibrous Dust. *Ann. occup. Hyg.*, **2**, 249.
- KANAZAWA, K., BIRBECK, M. S. C., CARTER, R. L. & ROE, F. J. C. (1970) Migration of Asbestos Fibres from Subcutaneous Injection Sites in Mice. *Br. J. Cancer*, **24**, 96.
- LIBANSKY, J. (1966) The Source of Mononuclears at a Site of Inflammation. *Blut*, **13**, 20.
- MORGAN, A., HOLMES, A. & GOLD, C. (1971) Studies of the Solubility of Constituents of Chrysotile Asbestos *In Vivo* Using Radioactive Tracer Techniques. *Envir. Res.*, **4**, 558.
- ODER, L. D. (1954) Observations of the Rat Mesothelium with Electron and Phase Microscopes. *Am. J. Anat.*, **95**, 433.
- ODER, D. L. (1956) Uptake and Transfer of Particulate Matter from the Peritoneal Cavity of the Rat. *J. biophys. biochem. Cytol.*, **2** (Suppl.), 105.
- ROE, F. J. C., WALTER, R. L. & HARINGTON, J. S. (1967) The Pathological Effects of Subcutaneous Injections of Asbestos Fibres in Mice. Migration of Fibres to Submesothelial Tissues and Induction of Mesotheliomata. *Int. J. Cancer*, **2**, 628.

- SMITH, W. E., MILLER, L., CHURG, J. & SELIKOFF, I. J. (1965) Mesotheliomas in Hamsters following Intraperitoneal Injection of Asbestos. *J. Mt Sinai Hosp.*, **32**, 1.
- STANTON, M. F., BLACKWELL, R. & MILLER, E. (1969) Experimental Pulmonary Carcinogenesis with Asbestos. *Am. indust. Hyg. Ass. J.*, **30**, 236.
- STANTON, M. F. & WRENCH, C. (1972) Mechanisms of Mesothelioma Induction with Asbestos and Fibrous Glass. *J. natn. Cancer Inst.*, **48**, 797.
- WAGNER, J. C., SLEGGS, C. A. & MARCHAND, P. (1960) Diffuse Pleural Mesotheliomata and Asbestos Exposure in the North Western Cape Province. *Br. J. indust. Med.*, **17**, 260.
- WAGNER, J. C., BERRY, G. & TIMBRELL, V. (1969) Mesotheliomas in Rats. In *Pneumoconiosis* (Proceedings of the International Conference, Johannesburg). Ed. H. Shapiro. London: Oxford University Press. p. 216.