

therapeutic agents for a case which is generalized and at the same time to use irradiation locally for an obvious mass. It has not been shown, however, that the simultaneous routine combination of chemotherapy with radiotherapy in the early case improved the average survival time of patients compared with that of patients treated with radiotherapy alone.

Pregnancy occurring during Hodgkin's disease is a complication which may prejudice treatment. This possibility should be excluded before embarking on treatment, as it is inadmissible to irradiate the foetus or to subject it to chemotherapy. Depending on the condition of the patient, it may be advisable to terminate the pregnancy and thereafter institute treatment. If termination is not possible or desired, treatment should be limited to radiotherapy which excludes the abdomen and groins until after the birth of the child. Further radiotherapy or chemotherapy may then be used.

### Home Care

Both these treatments, chemotherapy and radiotherapy, are better carried out by those with specialized experience. In spite of this the general practitioner undoubtedly carries the heavier burden. On him lies the responsibility of keeping the patient comfortable for the intervals between courses of treatment, and in keeping clearly in his mind that his purpose should be to try to prolong each interval to the maximum and not have the patient go running back to hospital for each new minor symptom or new lump. Expectant treatment of symptoms becomes, therefore, the keynote; this may include the aspiration of pleural fluid. Great attention should be paid to maintaining the general health of the patient. Fresh air and rest are important, and some form of iron should be prescribed. While skin irritation is alleviated either by x-radiation of abdominal nodes or by chemotherapeutic means, the relief in severe cases is sometimes disappointingly brief. In these circumstances local applications of calamine with phenol may be of value; the antihistamine preparations are not. In the terminal case with a rapidly falling haemoglobin a temporary improvement may be obtained by a transfusion of whole blood, or by the use of A.C.T.H. or cortisone.

### Prognosis

Academically it is true that Hodgkin's disease is incurable, but the statement must be read with due regard to the prolongation of life now possible, using modern treatment to the full. The Table gives the five-year survival of a num-

*Hodgkin's Disease: Five-year Survival Rate (Crude) of 256 Treated Cases (1934-47)*

Clinical Findings	Male	Female	Total
Disease initially localized .. ..	44%	64%	51%
.. .. generalized .. ..	12%	21%	15%
All cases together .. ..	21%	34%	25%

ber of cases treated at this hospital. As will be seen, it compares reasonably with the five-year survival of some of the more treatable cancers. A useful fraction of cases can be kept going for anything from five to ten years, most of them in a tolerable state of health for the greater part of the time. Clinically, both the extremes of short survival and long survival are found. Acute cases are usually atypical in having the distribution of lesions mainly in the viscera. There is almost from the beginning a high temperature and severe prostration. In such cases, which occur generally in young people, the duration may be only a few months, and response to chemotherapy is slight. The really chronic type of case, on the other hand, may be kept in reasonable health for periods of up to and exceeding ten years, during most of which time the patient remains able to attend to his business.

## OBSERVATIONS ON THE AETIOLOGY OF IDIOPATHIC STEATORRHOEA

### JEJUNAL AND LYMPH-NODE BIOPSIES

BY

J. W. PAULLEY, M.D., M.R.C.P.

*Physician to the Ipswich Hospitals*

I have previously reported the finding of emotional factors influencing the onset and relapses of idiopathic steatorrhoea, and of personality traits much like those found in ulcerative colitis and Crohn's disease (Paulley, 1949a, 1949b, 1950, 1952a, 1952b, 1952c). This was unexpected, and led me to wonder how these factors might cause such a disturbance of small-bowel function. With colitis and ileitis in mind, the most likely possibility was a form of jejunitis. That there might be mucosal oedema seemed probable from a study of small-bowel meals, which usually show broadening of the valvulae conniventes in idiopathic steatorrhoea. The interesting observation by French (1949, 1950-1) and Frazer *et al.* (1949) that the cause of the phenomenon of "clumping" in small-bowel barium examinations was flocculation of the barium by excess mucus seemed to lend support to the idea of a low-grade chronic inflammation or irritation of the small gut. The chief difficulty about this theory was that since Thaysen's (1932) monograph it had been, and still is, accepted that the jejunal mucosa is normal in sprue and idiopathic steatorrhoea, and that any abnormality found should be attributed to post-mortem change. As a result, for twenty years those interested in this field have ignored the possibility of a mechanical hindrance to absorption and have sought, without success, for causes ranging from vitamin deficiency to adrenal dysfunction. However, on studying Thaysen's evidence carefully I was unconvinced by it (Paulley, 1949a), based as it was on necropsy studies of two cases of his own—one sprue and one non-tropical sprue—and a rather one-sided view of the literature.

The only certain way of testing the jejunitis hypothesis was to obtain biopsy material, and in the past five years I have been present at five laparotomies on patients with steatorrhoea. One was found to have Whipple's disease (Paulley, 1952a) and is still alive and well; the other four are described in this paper. The series is not large, but the indications for laparotomy in steatorrhoea are limited, though the finding of a case of Whipple's disease and an x-ray negative case of Crohn's disease in so small a series may suggest that it should be done more often.

### Review of the Literature

Thaysen's monograph also dealt extensively with sprue, and it will also be necessary to refer to some of the old ideas about that disease here. Thaysen's observations led him to the conclusion that there were no characteristic morbid histological changes in the intestinal wall in either condition. He dismissed, much strong evidence to the contrary advanced by previous workers (Faber, 1904; Beneke, 1910; Justi, 1913; Manson-Bahr, 1915, 1924) of inflammation and ulceration of the intestinal mucosa, because they had not been found constantly or were autolytic. Elsewhere, however, he was less downright, and said: "It must be correct to interpret these intestinal changes as being of secondary nature, either produced by relatively low virulent micro-organisms that have nothing to do with the aetiology of sprue, or resulting from irritation of the mucous membrane owing to abnormal acidity of the intestinal content, or as a result of both agents."

Thaysen quotes only four cases of idiopathic steatorrhea in which microscopy of the intestines had been carried out—those of Blumgart (1923), Holst (1927), Rosendahl (1927), and one of his own. Inflammatory changes in the intestine were noted in two of these cases, and, in one case, in the mesenteric glands. In one case the inflammation was dismissed by Thaysen as due to radiation, but this may well not have been the cause. Blumgart's case has since been included in the group of cases of Whipple's disease, but the evidence is inadequate, and it is more probable that this was a case of idiopathic steatorrhea.

Schein (1947) and Adlersberg and Schein (1947) have noted abnormal histology in the mucosa and lymph nodes of patients dying of idiopathic steatorrhea. Some of these changes agree closely with the findings of older workers and those to be recorded in this paper. However, studies of their photomicrographs suggest that they too were hampered by the problem of post-mortem change. In view of the similar histological findings in sprue and idiopathic steatorrhea by the older observers, the following descriptions of sprue are quoted for comparison with cases in this paper. Manson-Bahr (1924) reported "a general atrophy of the villi due to fibrosis, and a diffuse round-cell infiltration of the whole of the mucosa. There is also a general fibrosis of the submucosa and dilatation of the capillary vessels." Justi (1913) stated that the villi were broad, somewhat short, and considerably swollen, and in their free half the stroma contained an abnormally large number of cells, either lymphocytes or plasma cells, or due to the villi being filled with a very cellular fibrillary connective tissue that gave them a "stiff" appearance. Beneke (1910), seeing the same specimen, also noted the shallow crypts and atrophy of the villi, found no "marked" phenomena of inflammation, but observed very numerous goblet cells.

It is hard to deny the likeness of these old observations on the tropical disease to the histology of the cases described below, and it is tempting to suggest that research workers in sprue might find it worth while reopening the question, which has remained closed since Fairley's negative mucosal studies in 1936. The epidemiology of sprue sets it apart as a quite separate disease from idiopathic steatorrhea; nevertheless I think a low-grade jejunitis may also be present but for different reasons than in idiopathic steatorrhea.

### Case 1

A man aged 56 was admitted to the Middlesex Hospital in May, 1948. In March he had had diarrhoea, and six weeks before admission he began passing frequent, pale, foul stools and also suffered central abdominal colicky pain. He lost 28 lb. (12.7 kg.) in two months and was weak—weight 96 lb. (43.5 kg.). He was a small man and stated that he had suffered from much ill-health in childhood, but did not know the cause. (The possibility that he was a coeliac child cannot be excluded.) In 1916 he had "shell shock," in 1918 pneumonia, and subsequently frequent winter coughs.

On examination patches of brown pigmentation were found over his trunk. His parotid glands and submaxillary glands were palpable. Coarse rales were present at both lung bases posteriorly. The abdomen was distended and tympanic. He was very fully investigated, and had a slight iron-deficiency anaemia, faecal fats of 41.0%, splitting 98% on a daily intake not exceeding 70 g., a flat glucose-tolerance curve, and a small-bowel meal which showed very coarse irregular mucosal folds in the lower duodenum and jejunum. Malignancy was suspected and a laparotomy was carried out. The jejunum was dilated and thickened, and the serosa was inflamed. Enlarged lymph nodes were present in the jejunal mesentery, and one was taken for section. The rest of the small gut was normal, as was the pancreas. He made a good recovery from the operation. Histological examination of the lymph node showed chronic inflammatory changes with much destruction by fibrosis. No fat was seen in the gland substance.

### Case 2

A man aged 39. In 1944, when in the Army in France, he had dysentery. Other members of his unit were also affected. Subsequently he had frequent relapses of diarrhoea. His weight, which was 182 lb. (82.5 kg.) in 1944, was 119 lb. (54 kg.) in 1948. His stools were large, frothy, foul, and pale. At times he noticed blood in them.

On examination he was pigmented and hypotensive (100/70). A barium-meal examination on January 10, 1951, showed numerous fluid levels in the small intestine; irregularity of the mucosal pattern was evident. The appearances suggested a small-intestinal obstruction. Faecal fats: 68% of dried weight, 77% split on a daily intake not exceeding 70 g. Fat balance over four days revealed absorption of less than 25%—so low, in fact, that its authenticity was doubted. Blood counts in 1951 tended towards a macrocytosis. Occult blood tests were strongly positive.

Laparotomy was carried out on February 15, the possible diagnosis being multiple tuberculous strictures, Crohn's disease, and gastro-colic fistula. The whole of the peritoneal surface of the gut was excessively "wet" and glistening. The mesentery of the small gut appeared to be oedematous, and many enlarged lymph nodes were present in it. No evidence of obstruction was found. The bowel itself appeared thin-walled and transparent. Biopsy specimens of gland from various sites and a wedge of jejunum were taken. The patient made an excellent recovery, improving considerably because of, or in spite of, his operation, which he thought was a great success. His subsequent course was up and down, and despite the usual therapy he died a year later in a Ministry of Pensions hospital. Necropsy was performed without significant findings. Some sections of his gut were kindly made available, but they were valueless on account of autolysis.

*Histology.*—The biopsy specimens showed broadening of the jejunal villi, which were packed with plasma cells and eosinophils. The inflammatory changes extended into the submucosa, where dilated lymph spaces were seen, possibly the site of oedema noted macroscopically. The sinuses of the jejunal glands were full of histiocytes, some of which appeared to be foamy. The pathologist's report was "an extreme form of sinus catarrh." It is worthy of note that ileal, ileo-caecal, and omental glands were regarded as being within normal limits.

### Case 3

The patient, a woman aged 42, had been investigated at St. Bartholomew's Hospital, London, in July, 1951, following a period of evening pyrexia, lassitude, diarrhoea, and amenorrhoea for twelve months. Her faeces then contained 67% fat, of which 54% was split. The secretin test was equivocal, giving rather low volumes of juice. (Personal experience has shown this test to be unreliable—a view supported by Elman and Hollender, 1952.) She was treated with iron, folic acid, high-protein low-fat diet, and pancreatin, and was discharged on this regimen. The conclusion was that she had grossly abnormal small-bowel function, and that it was impossible to say whether this was the primary lesion or whether it was secondary to subacute pancreatitis. She was admitted to Ipswich Borough General Hospital on March 4, 1952, having become steadily worse following temporary improvement after being in St. Bartholomew's. She said her stomach first troubled her during the war, when she did not want to see anybody or to go out. Large, loose, offensive stools had been present on and off for two years.

On physical examination she was pigmented, wasted, and hypotensive (90/70). Her tongue was red and raw on admission. Faecal fat on a diet of less than 70 g. a day was 60% of dried faeces and splitting 80%. She was not anaemic. Plasma proteins: albumin, 1.6 g.%; globulin, 3.4 g.%; potassium, 18 mg. per 100 ml. E.C.G. No evidence of potassium deficiency. Occult blood tests were positive. The small-bowel meal showed some dilatation of jejunum and coarsening of the jejunal folds. Laparotomy was carried

out on April 16, when her condition had slightly improved. There was a little free fluid in the abdomen. The serosa of the upper jejunum was injected, the lower jejunum and upper ileum were oedematous, and the serosal vessels were prominent. The lower ileum had a crenated appearance externally, and the colon was normal. The mesentery of the jejunum in particular was thickened and contained numerous enlarged lymph nodes. A Meckel's diverticulum was found and removed. No evidence of small-bowel destruction was seen, and the pancreas was palpated and seemed to be normal. Biopsy specimens of lymph nodes and jejunum were taken.

**Histology.**—Many of the villi were broad-ended and full of chronic inflammatory cells, mainly plasma cells and eosinophils. In the submucosa there were collections of inflammatory cells in the perivascular lymphatics. The jejunal lymph nodes showed invasion of the sinuses with chronic inflammatory cells and there were hyperplastic lymph follicles.

The patient was treated with the B vitamins, a high-protein diet, and supportive psychotherapy with definite but undramatic effect. Her stools became less troublesome and she gained some weight. A.C.T.H. was not available to us when she was in hospital.

#### Case 4

A woman aged 58 was first seen in 1950, when she presented with gross iron-deficiency anaemia which had resisted oral iron treatment for several years. She was wasted and extremely small, 4 ft. 10 in. (147 cm.), being easily the smallest of her family. Marked glossitis was present, and she gave a history of sore tongue on and off since her teens. On interrogation she admitted bouts of pale foul diarrhoea which had become more frequent and more severe for five years. She had suffered from diarrhoea and sickness attacks since the age of 2, and her brothers and sisters pulled her leg about her "big tummy."

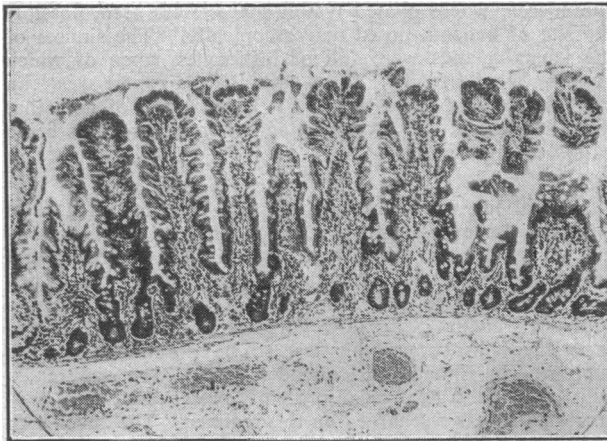


FIG. 1.—Jejunal mucosa. Normal control. ( $\times 50$ .)

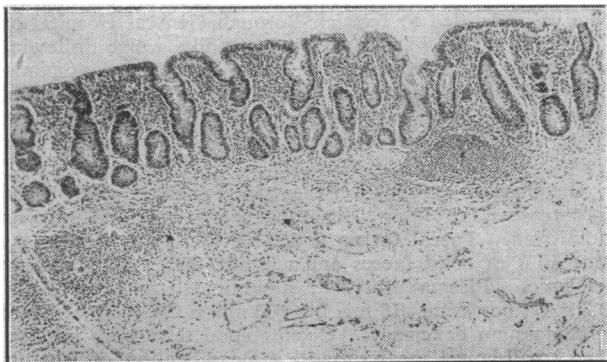


FIG. 2.—Jejunal mucosa. Case 2, steatorrhea. ( $\times 50$ .)

On intravenous iron and psychotherapy she had a remission, and later received folic acid, riboflavine, and liver injections. Early in 1952 her condition deteriorated; "tween 80" was tried without success. She lost much weight. Steatorrhea was severe and continuous. In August, 1952,

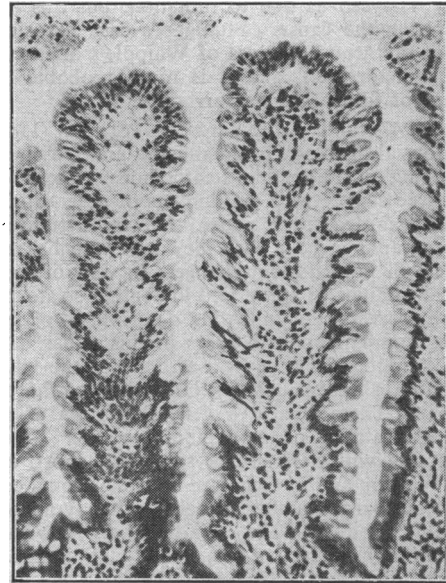


FIG. 3.—Jejunal mucosa. Normal control. ( $\times 140$ .)

she was readmitted. Small-bowel meals showed to a greater degree the dilated loops seen previously. In addition fluid levels were now present. Occult blood tests were positive, and thoughts turned to tuberculosis, Crohn's disease, and carcinoma superimposed on her steatorrhea. Her general condition was so bad that it was decided to try A.C.T.H. before surgery. Efforts had been made to rouse her from her apathy and withdrawn state of mind without success.

Within six hours of beginning A.C.T.H. she felt better; within twenty-four hours she was getting out of bed and asking for more food. The distension and eructation began to improve. Her mental outlook was utterly changed. Cheerful optimism and energy replaced apathetic misery. She gained 14 lb. (6.4 kg.) in five weeks, though she had a minor relapse in the middle when dosage was tailed too drastically. She wanted to go home, but repeated occult blood tests were still strongly positive and she had developed a macrocytic anaemia for the first time. The Hb was 70%; R.B.C., 2,480,000; M.C.V., 125 cubic microns. Surgery was advised, and at operation a terminal ileitis with stenosis was present. This was resected. The gut above was somewhat distended. The jejunum was studded with diverticuli, and small glands were present in the jejunal mesentery. The jejunal serosa was not inflamed macroscopically. She made an uneventful recovery. Her anaemia was treated with vitamin B<sub>12</sub>; she then became iron-deficient and responded to iron given intravenously.

**Histology.**—The jejunal mucosa was moderately reduced in thickness. In general the villi were widely spaced and some of their terminal portions were enlarged. There was infiltration of the mucosa by plasma cells, sometimes extending into muscularis mucosa, but no lymphatic dilatation. Both muscle coats showed hypertrophy, and there was a very pronounced paranuclear infiltration by golden-brown fine pigment, apparently lipofuscin, probably of no significance though of unusual extent.

#### Discussion

The rare opportunity for obtaining jejunal and mesenteric gland biopsy specimens in idiopathic steatorrhea has presented itself four times in the past five years. In three

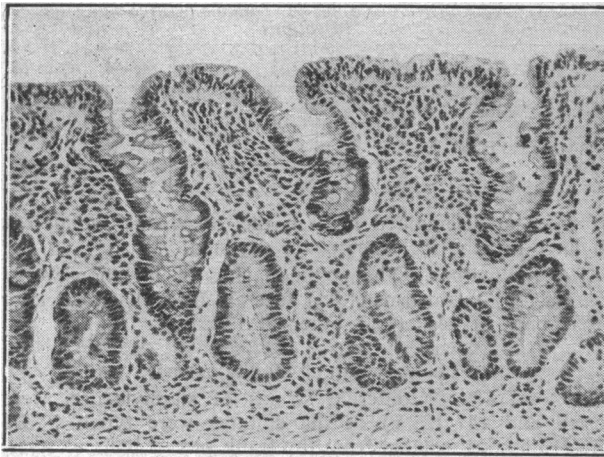


FIG. 4.—Jejunal mucosa. Case 2, steatorrhoea. ( $\times 140$ .)

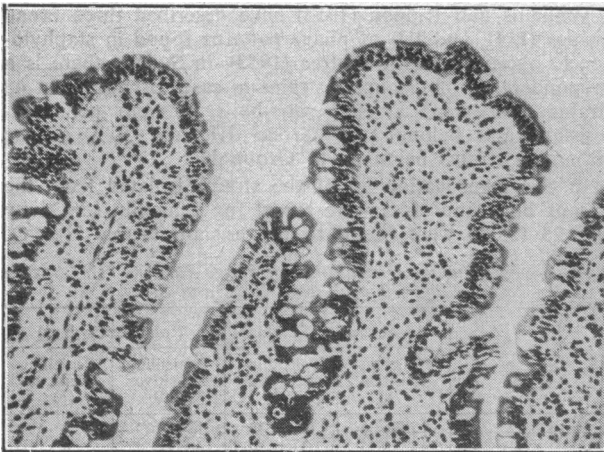

FIG. 5.—Jejunal mucosa. Case 3, steatorrhoea. ( $\times 140$ .)

cases inflammatory changes have been found in the upper small bowel and related lymph nodes at operation. In a fourth case of steatorrhoea dating from coeliac disease in childhood similar changes were found, though of a lesser degree, and in this case may have been due to stasis from a terminal ileitis, believed to be of relatively recent origin. A factor to be taken into account here was that this patient had completed a five-weeks course of A.C.T.H. by the time of operation, with a weight gain of 14 lb. (6.4 kg.) and great improvement in the stools and in well-being. The mucosal histology of these cases was striking in itself, but appeared doubly so when compared with normal jejunal mucosa taken at the time of operation for partial gastrectomy. It will be seen (Figs. 1-5) that the steatorrhoea villi were approximately double the width of the controls. Other obvious differences are in the shape and cellularity of the villi, the presence of large numbers of inflammatory cells in the mucosa and extending into the submucosa, fibrosis, and dilatation of the lymphatics. In Case 2 the inflammatory process had advanced to a stage of atrophy and fibrosis, and the villi were short and thick. There was also some histological evidence of the oedema noted at laparotomy, and the delicate conifer-like appearance of the normal jejunal mucosa as seen in the control material was missing. Goblet cells appeared more prominent in the steatorrhoea cases than in the controls.

So seldom have pathologists been confronted with biopsies of human jejunum that it is doubtful if the normal appearances are much known. The shape, stroma, and cellularity of the normal as opposed to the abnormal villus is likely to be difficult to interpret and to call for experience at present

lacking. It is therefore not hard to understand why these mucosal changes have been found only inconsistently in the past with occasional material, and that usually severely damaged by autolysis. The photomicrographs of much of Thaysen's material and of Schein's show post-mortem changes of the mucosa despite the fact that every effort was made to prevent it, and I suspect that in some cases in which the agonal period is prolonged, autolysis of intestinal mucosa may begin even before death. If this is so, early formalin treatment of the gut will be useless.

To summarize, it seems likely that the inconsistency of the mucosal findings in the past may have been due to (1) ignorance of the normal appearances, (2) differences in stage of disease, (3) post-mortem or even ante-mortem changes making reliable interpretation impossible, or (4) no biopsy material available.

### Summary

Psychosomatic findings in idiopathic steatorrhoea very similar to those in colitis and Crohn's disease led to the hypothesis of jejunal inflammation as an intermediate cause of idiopathic steatorrhoea.

Thaysen's negative observations on the morbid histology of the jejunal mucosa tended to shut out older views to the contrary. Some doubt is cast on Thaysen's deductions.

The literature dealing with the intestinal pathology of idiopathic steatorrhoea is surveyed. Some references to sprue are made inevitably.

Three cases of idiopathic steatorrhoea and a doubtful fourth case are described in which biopsy material was taken at laparotomy. All showed chronic inflammation of the jejunum and lymph nodes. Photomicrographs of the jejunum of two of these are presented with control sections taken at the time of the operation for partial gastrectomy. The differences are apparent.

An attempt has been made to explain the previous inconstant histological findings in this field. The difficulty of obtaining satisfactory post-mortem material and the possibility of autolytic changes before death would suggest that biopsy material is necessary to further research in this subject.

I wish to thank Dr. A. B. Lintott and Dr. T. H. Shaw, pathologists to the Ipswich Hospitals, for the histological reports and their interest and advice, and Dr. A. M. Barratt, of Cambridge, for the photomicrographs. I am most grateful to Dr. H. L. Marriott for asking me to see Case 1 and for allowing me to take it over post-operatively, and to Dr. Ronald Jones for access to Case 2.

### REFERENCES

- Adlersberg, D., and Schein, J. (1947). *J. Amer. med. Ass.*, **134**, 1459.  
 Beneke, K. (1910). *Vehr. dtsch. path. Ges.*, p. 132.  
 Blumgart, H. L. (1923). *Arch. intern. Med.*, **32**, 113.  
 Elman, R., and Hollender, L. (1952). *Gastroenterology*, **22**, 519.  
 Faber, K. (1904). *Arch. VerdauKr.*, **10**, 333.  
 Fairley, N. H. (1936). *Trans. roy. Soc. trop. Med. Hyg.*, **30**, 9.  
 Frazer, A. C., French, J. M., and Thompson, M. D. (1949). *Brit. J. Radiol.*, **22**, 123.  
 French, J. M. (1949). *Gastroenterologia (Basel)*, **75**, 23.  
 — (1950-1). *Ibid.*, **76**, 343.  
 Holst, J. E. (1927). *Acta med. scand.*, **66**, 74.  
 Just, K. (1913). *Arch. Schiffs- u. Tropenhyg.*, **17**, 505.  
 Manson-Bahr, P. (1915). *A Report on Researches on Sprue in Ceylon, 1912-1914*. Camb. Univ. Press, London.  
 — (1924). *Lancet*, **1**, 1148.  
 Paulley, J. W. (1949a). *Proc. roy. Soc. Med.*, **42**, 241.  
 — (1949b). *Gastroenterologia (Basel)*, **75**, 30, 33.  
 — (1950). *Gastroenterology*, **16**, 566.  
 — (1952a). *Ibid.*, **22**, 128.  
 — (1952b). *Gastroenterologia (Basel)*, **78**, 361.  
 — (1952c). *Trans. roy. Soc. trop. Med. Hyg.*, **46**, 594.  
 Rosendahl, G. (1947). *Med. Rev., Bergen*, **44**, 145.  
 Schein, J. (1947). *Gastroenterology*, **8**, 438.  
 Thaysen, T. E. H. (1932). *Non-tropical Sprue*. Oxford Univ. Press, London.