

persistently negative. C.S.F. total protein 200 mg.% without pleocytosis. X-ray evidence of erosion of femoral condyles, without change in joint spaces or articular cartilages. Normal E.C.G. Normal pyruvate tolerance. Bilateral high-tone deafness of perceptive type. Absence of myelinated nerve fibres, without lamellar hypertrophy of Schwann cells or amyloid deposits, in biopsy specimen of interdigital nerve of foot.

The case corresponds closely to the syndrome described by S. Refsum in 1946 (*Acta psychiat., Kbh.*, Suppl. 38) and named by him as above. It is to our knowledge the first case so diagnosed in Britain.

Multiple Angiolipomata and Hypersomnia.—HELEN DIMSDALE, M.D., F.R.C.P.

History.—S. V., male, aged 51. For two years has had attacks of hypersomnia. May occur day or night, incidence about one a month, duration two to three days. Headache and mild polyuria on waking. Disturbance of sleep rhythm, drowsy and lethargic during the day, difficulty in sleeping at night. Duration of sleep three and a half to five hours, wakes up frequently. Mildly depressed. Shaves daily. Weight decreased since onset of symptoms, with diet and Dexedrine.

Family history.—Married, 2 children. Brother, aged 44, died of a brain tumour (glioblastoma multiforme).

Past illnesses.—For the past thirty years he has had a number of subcutaneous swellings.

On examination.—Moderate obesity. No hypotrichosis. No hypogonadism. Numerous subcutaneous lipomata, about $\frac{1}{2}$ in. to $2\frac{1}{2}$ in. in diameter on forearms, lower abdomen, flanks and thighs. C.N.S.: Fundi normal. Fields full. Pupils moderately contracted. Left slightly larger than the right. Bilateral ptosis. Condition during attack resembles deep normal sleep, but patient is sometimes unrousable. Eyelids ptosed, and eyes turned upwards. Limbs hypotonic.

Investigations.—C.S.F. normal pressure and constituents. Blood W.R. negative. X-ray skull and chest: N.A.D. Air encephalogram: N.A.D. Third ventricle and basal cisterns appear normal. Resting E.E.G. normal. High (i.e. normal) threshold to Metrazol and photic stimulation. Record during an attack characteristic of early stages of sleep, showing well-marked "spindling".

Biopsy (Royal Free Hospital): Swelling from right arm and abdominal wall. Both are angiolipomata.

Comment.—Hypersomnia may be due to an angiolipoma in the region of the posterior hypothalamus.

Progressive Exophthalmoplegia with Muscular Atrophy, Myasthenia, and Thyrotoxicosis.—

REDVERS IRONSIDE, F.R.C.P.

S. J., male, aged 54. Caterer.

Ten years' history of exhaustion, with profuse sweating at night and in hot weather; loss of $2\frac{1}{2}$ stones (16 kg.) weight in past fourteen months. Fourteen months ago diplopia with variable ptosis in right eye, sometimes complete ptosis for weeks. Twelve months ago admitted to Atkinson Morley Hospital and found to have bilateral progressive external ophthalmoplegia (unresponsive to Prostigmin). Slight right facial weakness and wasting of the small muscles of right hand (Fig. 1). Fasciculation in shoulder-girdle muscles and left extensor plantar response. C.S.F., skull X-ray and E.E.G. normal (26.2.50).

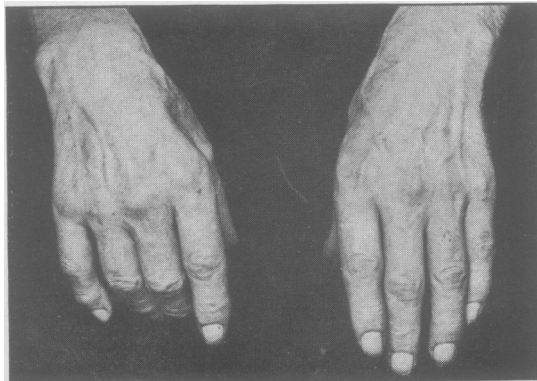


FIG. 1.—To show wasting of small muscles of the hand, and dropping of the fingers (right).

Nine months ago his memory began to fail, and this was for a time associated with euphoria. Later difficulty in articulation, chewing and swallowing, dropping of lower jaw and fingers, and difficulty in elevating upper limbs.

No family history of ophthalmoplegia, muscular wasting or goitre. One son, aged 24, is mentally defective.

On examination.—No palpable thyroid enlargement. Pulse 70–90/min. Right exophthalmos with ptosis. Variable lid-retraction in left eye. All external ocular movements grossly restricted but some elevation possible. No diplopia. Pupils normal. No periocular oedema. Fundi normal. Masseters and temporals wasted, smile feeble and face expressionless in repose. Wasting and weakness of trapezii, spinati, deltoids and rhomboids, and slighter global weakness and wasting of the muscles of lower limbs, especially the dorsiflexors of feet. Occasional fasciculation in shoulder-girdle muscles. No sensory changes. All tendon reflexes elicited. Left plantar response equivocal. Abdominals present.

Blood W.R. negative. Other routine examinations normal.

Prostigmin test: 3 p.m., atropine gr. 1/100; 3.20 p.m., Prostigmin 2.5 mg. 3.30 p.m., colic; 3.35 p.m., diplopia; 4.20 p.m., marked improvement in the grips (tested by repetitive handgrips and dynamometer), in power of deltoids, extensors of fingers and iliopsoas group. Eye movements returned to 50% of normal (Fig. 2).

Patient has been given oral Prostigmin which is losing its effect.

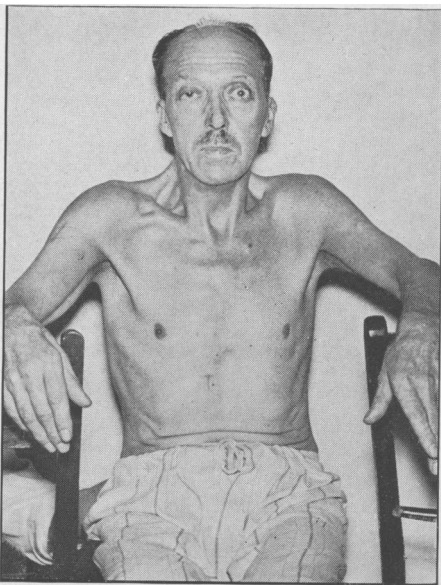


FIG. 2A.—Before Prostigmin.

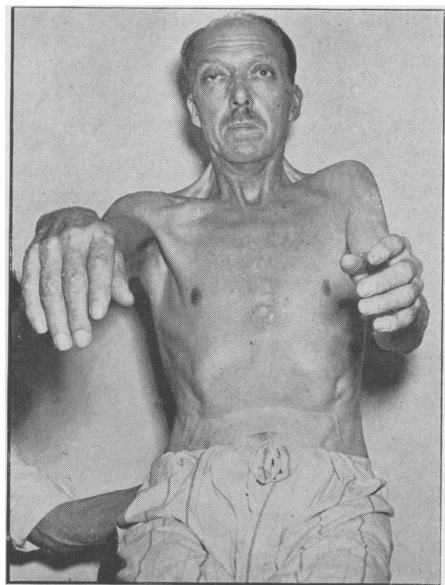


FIG. 2B.—Ten minutes after intramuscular injection of atropine gr. 1/100, Prostigmin 2.5 mg.

Radioactive iodine test, 13.1.51 (Drs. Russell Fraser and Q. J. G. Hobson):

Time	Urinary excretion of I^{131}	
	Subject	Normal
0–8 hr.	10.6%	25–50%
8–24 „	1.1%	7–20%
24–48 „	1.1%	0–10%
Total	12.8%	
8–48 hr.	2.2%	

i.e. the excretion of radio-iodine is greatly reduced, as in thyrotoxicosis (confirmed by subsequent test).

POSTSCRIPT (July 1951).—The patient died on 9.3.51 in a state of partial respiratory paralysis.

At post-mortem (Dr. J. Vaughn, St. Bartholomew's Hospital) a few lymphocytes were seen in the calf muscles, but the external ocular muscles were microscopically normal. The thyroid gland showed no hyperplastic changes; the thymus was represented by a small residuum of fibro-fatty tissue. (Histological investigation is not yet complete.)