

periods varying from four to seven months with beneficial effect. Some patients who experienced a return of symptoms when maintenance treatment was stopped obtained further relief by restarting cyclophosphamide. Somewhat similar conclusions were reached by Larionov (1956) using novoembichin.

Side-effects following upon the administration of cyclophosphamide have been inconspicuous in the present series. Alopecia has not proved troublesome, no venous thromboses occurred at the site of injections, and nausea and vomiting were infrequent. One male patient noticed a reduction in beard growth. In general, side-effects such as alopecia, sterile cystitis, gastrointestinal disturbances, and transient fall in the haematocrit are met with more often when amounts in excess of 200 mg. of cyclophosphamide are given daily. Thrombocytopenia is said not to occur even at the higher levels of dosage (Haar *et al.*, 1960). In four of our patients, however, low platelet counts were found after treatment; two of these were suffering from myelomatosis.

The fact that of the 17 patients suffering from Hodgkin's disease 11 (65%) were objectively improved and that 15 (88%) benefited subjectively (Table II)

TABLE II

Diagnosis	No. of Cases	No. Improved	
		Objectively	Subjectively
Hodgkin's disease	17	11	15
Lymphoid follicular retic.	1	0	1
Lymphosarcoma	3	2	2
Reticulum-cell sarcoma	1	0	1
Myelomatosis	14	5	6
Chronic lymphocytic leukaemia	5	3	3
Polycythaemia rubra vera	1	1	1
Other tumours	3	0	1
Total	45	22 (49%)	30 (67%)

deserves note. Similar figures were obtained in other series (Gross and Lambers, 1958; Petrides and Moncke, 1958; Brichta *et al.*, 1958). Improvement may be expected 10 to 14 days after the beginning of treatment, the control of fever being a notable feature.

It is encouraging to find a 36% objective improvement rate in myelomatosis. Case 26 shows a particularly good remission, the serum calcium being reduced from 18.6 to 10.5 mg./100 ml. This patient gained 11 lb. (5.5 kg.) in weight; her haemoglobin rose from 6.2 to 9.2 g./100 ml. and has been maintained at the latter level. 11 (79%) cases of myelomatosis showed leucopenia during treatment, in contrast to the other groups treated.

Partial remission of chronic lymphocytic leukaemia was achieved in three out of five of our patients. However, Haar *et al.* (1960) could find evidence of marrow remission in only one out of their five cases that responded to treatment with cyclophosphamide.

Cyclophosphamide has been tried in a wide variety of other malignant tumours with variable effect (Lemke *et al.*, 1959; Baumann 1959; Coggins *et al.*, 1959). In one series (Coggins *et al.*, 1959), 18 out of 47 "evaluable" cases responded, the average duration of remission being two months. No improvement occurred in our three patients.

Summary and Conclusions

45 patients with malignant disease were treated with cyclophosphamide. 42 suffered from diseases of the haemopoietic or reticuloendothelial systems, three had disseminated malignant disease of other types.

Cyclophosphamide has proved a valuable addition to the chemotherapeutic drugs available for the treatment of malignant diseases of the haemopoietic and reticuloendothelial systems. It was found particularly effective in Hodgkin's disease, lymphosarcoma, chronic lymphocytic leukaemia, and myelomatosis, and it promises well in the treatment of polycythaemia rubra vera.

Side-effects are minor, although some depression of the white-cell count usually accompanies effective therapy. Maintenance treatment is safe, worth while, and simple, as the drug can be administered in tablet form. White-cell-count control is essential. Usually, while patients are on maintenance therapy, a count every three to four weeks will suffice.

We thank Dr. J. M. Simister, of Ward, Blenkinsop and Co., Ltd., for supplies of cyclophosphamide.

REFERENCES

- Arnold, H., Bourseaux, F., and Brock, N. (1958a). *Nature (Lond.)*, **181**, 931.
 ——— (1958b). *Naturwissenschaften*, **45**, 64.
 Baumann, E. (1959). *Medizinische*, **1**, 659.
 Brichta, G., Kühböck, J., and Reimer, E. E. (1958). *Wien. Z. inn. Med.*, **39**, 306.
 Brock, N. (1958). *Arzneimittel-Forsch.*, **8**, 1.
 ——— and Wilmanns, H. (1958). *Dtsch. med. Wschr.*, **83**, 453.
 Burkert, H. (1958). *Asta Nachrichten*, No. 18.
 Coggins, P. R., Ravdin, R. G., and Eisman, S. H. (1959). *Cancer Chemother. Rep.*, **3**, 9.
 Gilman, A., and Philips, F. S. (1946). *Science*, **103**, 409.
 Goodman, L. S., and Gilman, A. (1955). *The Pharmacological Basis of Therapeutics*, 2nd ed., p. 1416.
 Gross, R., and Lambers, K. (1958). *Dtsch. med. Wschr.*, **83**, 458.
 Haar, H., Marshall, G. J., Bierman, H. R., and Steinfeld, J. L. (1960). *Cancer Chemother. Rep.*, No. 6, p. 41.
 Lane, M. (1959). *J. nat. Cancer Inst.*, **23**, 1347.
 ——— and Kelly, Margaret G. (1959). *Proc. Amer. Ass. Cancer Res.*, **3**, 35.
 Larionov, L. F. (1956). *Brit. med. J.*, **1**, 252.
 Lemke, J., Stange, H. M., and Rumphorst, K. (1959). *Landarzt*, **20**, 724.
 Petrides, P., and Moncke, C. L. (1958). *Mitt. Ges. Bekämpf. Krebskr. Nord-Westfall.*, **2**, No. 6.
 Ross, W. C. J. (1953). *Advanc. Cancer Res.*, **1**, 397.
 Wilkinson, J. F., and Fletcher, F. (1947). *Lancet*, **2**, 540.

MEGALOBlastic MADNESS

BY

A. D. M. SMITH, M.B., M.R.C.P., B.Sc.

Medical Registrar, Central Middlesex Hospital, London

The occurrence of mental symptoms in association with pernicious anaemia has been known for many years and been commented upon by various authors (McAlpine, 1929; Samson *et al.*, 1952; MacDonald Holmes, 1956; Wiener and Hope, 1959). Langdon (1905) drew attention to a group of cases in which nervous and mental symptoms preceded the onset of anaemia and described a great variety of neurotic and psychotic manifestations. Latterly (Wiener and Hope, 1959) the extreme variability of the symptoms has been stressed, and it is obvious that anything from a mild mood disorder to grossly psychotic behaviour may be encountered. Epilepsy, urinary and faecal incontinence in the absence of overt spinal lesions, dysphasia, and confusional states are also mentioned (MacDonald Holmes, 1956). Furthermore, it is well recognized that vitamin-B₁₂ deficiency may give rise to optic atrophy, and it has been shown that tobacco amblyopia may be cured by administration of this vitamin (Heaton *et al.*, 1958).

The exact nature of the defect in cerebral metabolism which is produced by deficiency of vitamin B₁₂ is not

understood. Studies of the cerebral blood flow and oxygen consumption by the nitrous oxide method (Scheinberg, 1951) show that the cerebral symptoms are due to the deficiency state and are not related to the degree of anaemia. Electroencephalographic studies of patients with pernicious anaemia (Walton *et al.*, 1954) show that abnormalities are common and that there is no correlation of the abnormalities either with the haemoglobin level or with age. Also, an abnormal E.E.G. was frequently obtained in anaemic patients who showed no evidence of subacute combined degeneration of the cord. The tracings in this series tended to improve 7 to 10 days after the beginning of treatment.

The occurrence of subacute combined degeneration of the cord prior to the onset of anaemia is well recognized and clinicians are now fully alive to this possibility. The time-lag may be considerable and may give rise to diagnostic difficulty unless this situation is constantly borne in mind. Owing to the many tragedies that have resulted from unawareness, with subsequent irreversible cord damage, it is now unusual to come across cases of this nature. It is quite obvious, however, that the importance of avitaminosis B₁₂ in the production of cerebral symptoms, either localized or generalized, still needs to be increasingly thought of. The necessity for making the correct diagnosis cannot be overstressed, as delay is extremely dangerous and the condition eminently treatable, provided cerebral demyelination has not occurred. The histopathology of the cerebral lesions has been well established (Adams and Kubik, 1944), and it has been shown that they are essentially the same as those found in the spinal cord in subacute combined degeneration.

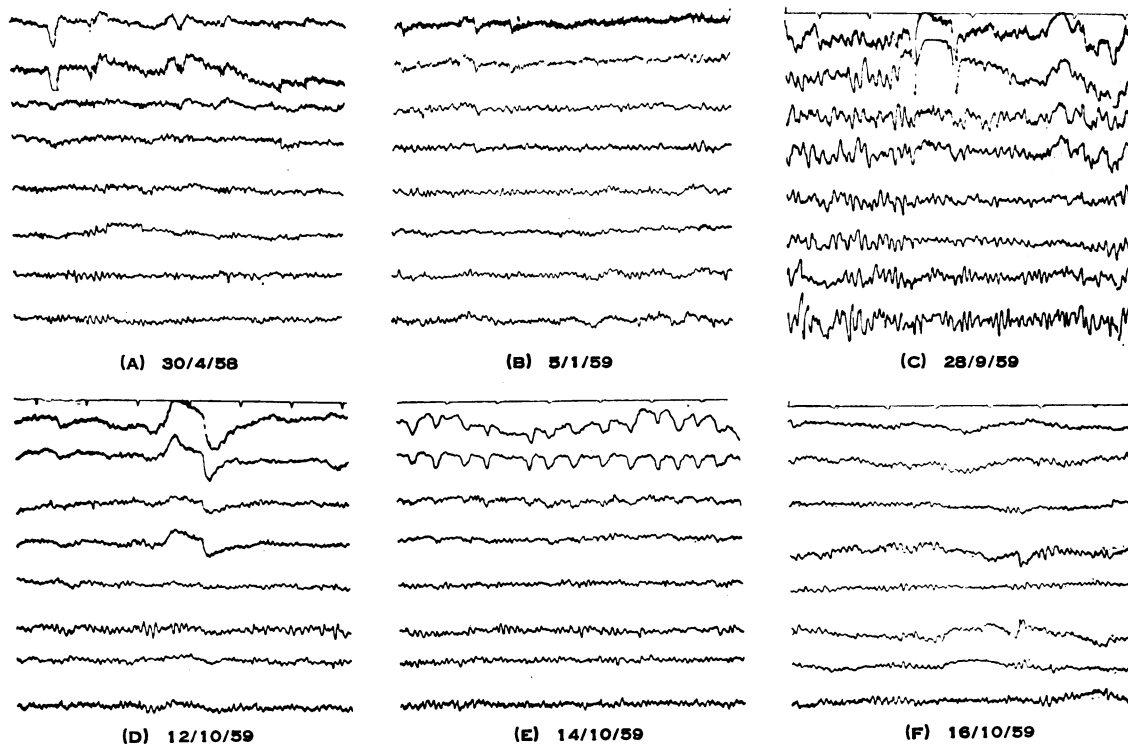
The following cases are presented as a reminder of the diagnostic difficulties that may be encountered when dealing with the cerebral manifestations of vitamin-B₁₂

deficiency. It is also hoped to provide pointers on how the diagnosis may be made prior to the onset of anaemia, cord damage, or peripheral neuritis. It will be shown quite conclusively that absence of the diagnosis results not only in a steady deterioration of the patient's condition but also in considerable iatrogenic trauma, both mental and physical.

Case 1

A woman aged 48 was referred to the out-patient department in April, 1958, with a history extending over the previous nine years. Initially her symptoms had followed the death of her first baby at 6 weeks of age after 18 years of marriage. They consisted of sleeplessness, giddiness, and a feeling as if she was walking on air. In association with these generalized complaints she also described attacks in which she developed pain over the right eye, numbness of the face and right arm, and an inability to see properly because of a glaze across the right eye. Her tongue felt swollen, and she was unable to hold things in the right arm because of the numbness and pins-and-needles. During these focal phenomena she felt confused and unable to think clearly. These localized attacks would last for two to three days and then pass off.

At the beginning of this history the episodes were very infrequent indeed and she had remained fairly well until a few months prior to being seen as an out-patient. Her sister had recently died of bronchial asthma and the patient had nursed her through the terminal stages. After the sister's death the attacks became more frequent and were accompanied by severe depression. She was full of remorse, and insisted that her sister had died because she had not looked after her properly. Full physical examination at this time failed to reveal any abnormality. The haemoglobin was 92%, and an x-ray film of the chest normal. The diagnosis was thought to be depression with associated atypical migraine. However, an E.E.G. showed a definite generalized abnormality, maximal in the left hemisphere, with variable focal distribution. It was felt the possibility of multiple lesions (? vascular, ? neoplastic) should be



Case 1.—Serial E.E.G.s taken before and after treatment. Note the progressive generalized abnormality culminating in (C). Treatment was started on 10/10/59, and within 48 hours a striking improvement occurred (D).

considered. In spite of the abnormal E.E.G. the bulk of her symptoms were attributed to a guilt reaction connected with the death of her sister, and she was referred to the psychiatric department. The psychiatrist felt that time was the only thing likely to lessen her feeling of guilt, but asked the general practitioner to refer her again if her condition deteriorated.

She was not seen again until January, 1959, when referred to the psychiatric out-patient department. At this time she was in a confused state, unable to give a coherent account of herself and disorientated in time and space. The clinical picture was thought to be due to an organic confusional state, and the patient was accordingly admitted to a neurological bed.

On admission to the ward she said that during the previous week she had been suffering from severe headache affecting both frontal regions. These headaches were severe and had kept her awake. They were accompanied by transient attacks of dysphasia. She had felt suicidally depressed. The family history revealed that her father had died in his forties of paralysis of unknown nature and that one brother, in his thirties, had become paralysed, again without a known cause. Furthermore, a sister had died about 25 years earlier from "anaemia" while still in her twenties. Unfortunately the significance of these facts was not appreciated.

Examination at this time failed to reveal any definite physical signs in the central nervous system, apart from one observer commenting that joint position sense appeared to be defective in both upper and lower limbs. This was felt to be incapable of precise interpretation because of her confused state, and therefore ignored.

X-ray examination of the chest and skull, N.A.D. Haemoglobin 83%, with a normochromic film showing some anisocytosis only. Lumbar puncture, normal in all respects. Serum cholesterol, 200 mg./100 ml.; total serum lipids, 565 mg./100 ml. An E.E.G. showed a well-marked increase in abnormality compared with the previous record. The alpha rhythm was of lower voltage and more disorganized, while random intermediate slower components were more prominent in all areas and at times sharp waves were also present. The abnormal components now had a paroxysmal character. Maximum abnormality was clearly seen in the left sylvian region. It was reported that in view of the essentially diffuse disturbance and the deterioration a diffuse pathological disturbance was at work. An air encephalogram and a left carotid arteriogram were normal. The possibility of chronic hypoglycaemia was considered, but fasting blood sugars were all within normal limits and a glucose-tolerance curve showed no abnormality. She was placed on a high-carbohydrate diet, given small doses of anticonvulsant drugs, and discharged.

For three months she claimed to feel much better on this regime. Then further deterioration began and she complained of attacks of paroxysmal nocturnal dyspnoea. These sounded asthmatic in type, and a precautionary E.C.G. was entirely normal. Although mentally she was generally better, it was felt that she should be readmitted to hospital for further investigation. There was a six-weeks delay before this could be arranged.

Examination now revealed no change in the physical signs except that she looked a little pale. She was fasted for 24 hours and an E.E.G. performed, with a blood sugar of 70 mg./100 ml. The record showed a considerable increase in abnormality over the previous one, with left hemisphere preponderance. An injection of 50% glucose given during the tracing failed to change the pattern. A blood count performed on the same day showed a haemoglobin of 53% and a W.B.C. of 1,800. The film was reported as showing anisocytosis with some macrocytosis and marked polychromasia. Comment: "Film suggestive but not diagnostic of pernicious anaemia." In view of this a fractional test meal examination was made, revealing a histamine-fast achlorhydria. Sternal marrow showed characteristic megaloblastic haemopoiesis. The serum vitamin B₁₂ level was 45 µg. "Cytamen" 100 µg. daily

was given and a maximum reticulocyte response of 22% was obtained six days after the initial injection.

Serial E.E.G.s were performed after the injection of vitamin B₁₂. On the second day it was reported that the E.E.G. was more stable than the one performed just before treatment (see Fig.). Two days later the E.E.G. showed a further slight but definite improvement (see Fig.). This improvement was maintained, although the left hemisphere showed a greater abnormality than the right. Isolated "sharp" elements were present in the left temporo-parietal region. Four weeks after the beginning of treatment the E.E.G. showed still further improvement, although some mild residual paroxysmal instability persisted in the left hemisphere.

The patient has been maintained on a dosage of 250 µg. of cytamen every 14 days. She remains very well from the mental and haematological point of view but continues to get nocturnal dyspnoea on occasion. Some 12 months after the commencement of therapy her E.E.G. remains improved although the mild abnormality in the left cerebral hemisphere persists.

Case 2

This patient, a woman aged 43, had been ill for 18 months with a depressive state. Six months after the onset of her symptoms she was seen by an experienced psychiatrist, who commented that although she was undoubtedly depressed he felt that there was a physical basis for her symptoms. He could find no underlying psychopathology to account for her depression and referred her to a general physician for a complete overhaul. Her main complaints were of headaches, sleeplessness, malaise, loss of appetite, and lack of interest in life in general. No organic basis was found for her symptoms, and admission was arranged to a mental hospital, where she was given a course of E.C.T. The E.E.G. at this time was normal.

It was stated that after this treatment she improved considerably. While under the care of the psychiatrists her haemoglobin was 82% and the film was reported as showing mild iron deficiency. She then returned home, but after three months broke down again and was readmitted to the mental hospital, where a further course of E.C.T. was given, again with an apparently good effect. After this improvement she was once more sent home, but her symptoms soon recurred, and it was noticeable that throughout this phase of fluctuation her weight had fallen steadily by at least a stone (6.4 kg.). Furthermore, she had become increasingly breathless, and on questioning admitted to having had attacks of paroxysmal dyspnoea for the preceding eight years. The past history revealed that four years prior to being taken ill with her present symptoms she had developed a moderate iron-deficiency anaemia with a haemoglobin of 55%. There had been no depression or other mental abnormalities associated with this, and it had responded effectively to oral iron. The cause of this anaemia had not been satisfactorily explained. The family history revealed that her mother had died of "thrombosis" at the age of 63 and there was a vague suggestion that she too was anaemic. Unfortunately further details were not available.

By now the patient was palpably anaemic, with a haemoglobin of 32% and film suggesting pernicious anaemia. Urgent admission was arranged, and the diagnosis confirmed by a megaloblastic bone-marrow, histamine-fast achlorhydria, and a serum vitamin-B₁₂ level of only 25 µg./ml. Jejunal biopsy was negative. An E.E.G. showed a medium- to high-voltage alpha-rhythm of about 9 c/s dominant. This was disturbed by random lower components, which were seen in mild degree throughout both hemispheres and which were increased moderately by over-breathing. The record was non-specific, but was considered to be compatible with a diffuse encephalopathy.

Treatment with vitamin B₁₂ produced a reticulocyte response, reaching a maximum of 27% on the fifth day. On the second day the E.E.G. remained unchanged, but five days later there was a slight general improvement,

although the record still showed a mild and diffuse instability. Improvement was maintained, and after one month the record returned to normal.

Mentally she made great progress and her depression lifted. For the first time for 18 months she felt as if she had something to live for. Apart from minimal residual agitation she was well after the institution of vitamin-B₁₂ therapy and continued to improve. However, this improvement was not maintained, and in spite of massive therapy she again began to deteriorate and remained in a perpetual state of mild agitation, although her haemoglobin was 92% and an E.E.G. completely normal.

Case 3

A 34-year-old woman was admitted to hospital as an emergency case in 1954. The general practitioner commented in his letter that she was complaining of severe depression, a sore tongue, and a sensation of electricity in the limbs. He queried whether vibration sense was lost below the knees. After admission it was discovered that she had been behaving peculiarly for some months. For a few weeks before admission this had culminated in marked ideas of reference and a refusal to leave the house. She was convinced that she smelt offensively, and consistently warned her children not to eat the food she had prepared. On the evening of admission she had made an attempt at suicide by drowning. She admitted to auditory hallucinations but was unable to give a coherent account of her voices. Her stepdaughter volunteered the information that a month previously she had "fainted" several times. The past history contained no illnesses of significance. The family history revealed that her father committed suicide by coal-gas.

On examination she was agitated and tearful, and in view of the profound mental disturbance it was felt wisest to transfer her to the mental observation ward. A note was made that she was not clinically anaemic and that the spleen was not palpable. Sensory testing of the C.N.S. proved impossible, but no qualitative changes in the reflexes were noted. She continued to show severe mental disturbance, and this resulted in her being certified and transferred to a mental hospital, where she was admitted in a semi-stuporous state and unable to give an adequate account of herself. A diagnosis of depression was made.

A course of E.C.T. was started and after about 12 applications she appeared to be improving, the personality emerging being of a cheerful and contented nature. After five months she was thought to be well enough to start going on leave. This was extended at the patient's request. But when seen again as an out-patient one month later she complained of dizziness, headaches, and not feeling well generally. Further investigation was refused.

Shortly after this she was readmitted to an acute medical bed and found to be severely anaemic with a haemoglobin of 28%. A diagnosis of pernicious anaemia was fully substantiated by the usual investigations and a maximum reticulocyte response of 32% obtained to intramuscular vitamin B₁₂. Her mental state greatly improved after the institution of treatment, and apart from some residual hypochondriacal anxiety she remained well five years later. Questioning revealed that she went grey at the age of 22 years.

Case 4

A woman aged 64 was admitted to hospital in May, 1954. Her previous history revealed that pernicious anaemia had been diagnosed 20 years earlier and a course of liver sandwiches commenced. She had failed to tolerate these and remained under the care of her general practitioner on iron therapy alone.

In 1949 she had been admitted to a mental hospital suffering from "atypical depression." Here the diagnosis of pernicious anaemia was substantiated, but it was considered that her mental symptoms justified a course of

E.C.T., and this was given. Intramuscular "anabaemin" was begun. She remained in the mental hospital for six months and was then discharged as much improved. After discharge her mental state was considered to be quite normal, apart from periods of "excitement" which she related to the liver injections. These periods of mental disturbance were so profound that she had felt justified in refusing further injections about 12 months prior to the present admission.

Examination now revealed her to be anaemic (haemoglobin 42%) and mentally strange. No abnormalities were detected in the central nervous system. Although orientated in all spheres she was prone to talk nonsense. Intramuscular vitamin B₁₂ was started and a maximum reticulocyte response of 27% obtained. She was placed on a maintenance dose of 250 µg. every two months and followed as an out-patient. Two months after discharge she felt very well and seemed mentally better. However, one month later she was again admitted to the observation ward as a case of mania, certified, and transferred to a mental hospital. At this time she was very disturbed indeed and displayed a well-marked flight of ideas. She apparently improved rapidly after a short spell in the mental hospital and discharged herself. When seen again as an out-patient one month later she ascribed her manic phase as being due to the cytamen injections, which she said were mescaline. Her haemoglobin was 88%.

She continued to attend as a out-patient, and in 1955 had a further nervous breakdown, for which she again entered the mental hospital and received E.C.T. Some improvement was said to follow this, and she was once more discharged but continued to attend as an out-patient. Mental fluctuation persisted. Two-and-a-half years after the beginning of cytamen therapy the dosage was increased to 400 µg. every two months. Since then she has remained perfectly well and her nervous symptoms have been completely eradicated.

Case 5

This case is only briefly mentioned. A man of 56 who had a previous history of partial gastrectomy for peptic ulceration was referred to the out-patient department because of headaches. The headaches formed a small portion of a bizarre symptomatology which was felt to be depressive in nature, but in view of his previous operation estimations of a full blood count and serum vitamin B₁₂ were ordered. The blood count was normal in every respect, but the vitamin B₁₂ was found to be only 105 µg./ml. As this figure was below the accepted lower normal of the laboratory in which the investigation was made, the test was repeated on a separate occasion and the figure confirmed. Sternal marrow showed a normoblastic reaction.

Questioning of the patient revealed that since his gastrectomy he had been generally unwell apart from one occasion when his doctor had given him liver injections for six weeks on a purely empirical basis. Numerous placebos had failed to influence his symptoms.

Treatment with massive doses of cytamen (1,000 µg.) was started, and four days later the patient claimed to be symptom-free. At the time of writing it is far too early to say whether this improvement is going to be maintained.

Case 6

A woman aged 46 was admitted from a mental hospital with gross signs attributable to subacute combined degeneration of the cord. She had previously been leucotomized for depression without any improvement in her mental state being produced. Unfortunately, the rather bizarre symptomatology which her cord damage and peripheral neuritis had produced was considered to be part of the pattern of her mental illness, and a long delay ensued before the correct diagnosis was established. By the time of her admission to a general hospital she had a spastic paraplegia with enormous sacral bedsores and a megaloblastic

blastosis in the peripheral blood. In spite of massive supportive and remedial therapy deterioration steadily continued until her death.

Discussion

No excuses are offered for re-emphasizing the importance of diagnosing megaloblastic madness. Although the condition is mentioned by many authors, there has been little documentation of cases presenting with clinical manifestations in the absence of anaemia or subacute combined degeneration of the cord. The six cases described in this paper have been drawn from a much larger number in order to illustrate the various points thought worthy of mention.

In Case 1 the history extended back 10 years and the presenting features were a mixture of depression and peculiar focal attacks. There appeared to be adequate psychopathology to account for her depression, which was initially felt to be the predominant feature of the illness and led to referral to the psychiatric department. The only abnormal finding at this time was the generalized E.E.G. abnormality, and the importance of this was overlooked. A delay of nine months then ensued before it became obvious on clinical grounds that she was suffering from an organic condition. Further deterioration in the E.E.G. in the absence of focal neurological signs or anaemia led to many diagnoses being considered and appropriate investigations undertaken. The importance of the family history was overlooked and, although commented upon at the time, the association between anaemia, obscure paralyses, and the patient's clinical condition and grossly abnormal E.E.G. was not appreciated.

It is well known that sufferers from pernicious anaemia look and feel much better the day after the initial injection of vitamin B₁₂. This, of course, bears no relation to improvement in the haematological picture. In Case 1 a similar improvement was noted, and there was a striking reduction in the E.E.G. abnormality on the second day after the commencement of treatment. Although the E.E.G. continues to show serial improvement a suggestion of a left temporal focus still remains, and it seems probable that an area of cerebral demyelination has occurred. This focus is compatible with the focal attacks of which she complained, although these have now completely cleared up. It is possible that her persisting attacks of nocturnal dyspnoea have a temporal-lobe aetiology, and it is of interest that Case 2 also gave a history of this symptom without an obvious cause being found.

Case 2 emphasizes further pointers to the consideration of the correct diagnosis. "Nervous breakdowns" occurring with a previously good mental history and a negative family history of mental instability should encourage the observer to think very hard. Furthermore, there was no obvious psychopathology to account for her symptoms, and a very experienced psychiatrist was of the opinion that the patient was physically ill. In this particular case the initial E.E.G. was normal, and it is obvious that the diagnosis could only have been made by having a healthy clinical suspicion that avitaminosis B₁₂ might be the cause.

The psychosis exhibited by Case 3 was obviously of such a nature as to overshadow any consideration of an underlying organic cause. Nevertheless, in retrospect, there were several signposts in the history that pointed the correct clinical path. These facts were ignored on admission, and owing to her disturbed mental

state it was impossible to obtain the patient's co-operation in full neurological examination.

Case 4 illustrates a pattern of mental illness occurring within a known diagnosis of pernicious anaemia. Here the patient had failed to maintain her treatment because she developed a fixation about her injections. When finally "redialysed" she was placed on a maintenance dose of 250 µg. of vitamin B₁₂ every two months. In spite of this she continued to display abnormal mental behaviour, although her haematological picture was normal. When the intake of vitamin B₁₂ was doubled she became mentally well and has remained so. The importance of giving increased doses of vitamin B₁₂ to sufferers from subacute combined degeneration of the cord is well recognized, and it seems logical, and necessary, that those with evidence of cerebral vitamin-B₁₂ deficiency should be treated likewise. This fact, however, may not be fully appreciated.

In the absence of signs or symptoms of cord or nerve damage the importance of assessing the patient's mental state before dosage is evaluated is often overlooked. Mental changes may be attributed to the anaemia *per se* and inadequate therapy result in irreversible cerebral damage. It seems probable that Case 2 has been left with a degree of cortical damage that no amount of treatment will eradicate. The past history of this case revealed an iron-deficiency anaemia which had responded fully to oral iron. Recent work (Cox *et al.*, 1959) shows that low serum vitamin-B₁₂ levels may be associated with iron-deficiency anaemia and a normoblastic bone-marrow, and, furthermore, that the vitamin-B₁₂ level rises with the correction of the anaemia by iron alone. Normoblastosis with vitamin-B₁₂ levels of under 120 µg./ml. is a new concept, but it adds weight to the fact that the symptoms of which Case 5 complained were in some way related to a chronic insufficiency of the vitamin.

Our present concept of normal and abnormal serum vitamin-B₁₂ levels has been built up by consideration of the presence or absence of pernicious anaemia and/or subacute combined degeneration of the cord. Most workers accept a lower limit of normal as lying between 100 and 150 µg./ml. This is almost certainly untrue, as a mean level of 218 µg./ml. was found in tobacco amblyopia (Heaton *et al.*, 1958), as opposed to a level of 538 µg./ml. in normal controls. Unfortunately, bone-marrow studies were not performed in this series, but it seems probable that normoblastosis would have been found in most of the cases, although damage to the central nervous system was being produced. The high percentage of the population who smoke renders it possible that this fact may play a part in the production of other manifestations of vitamin-B₁₂ deficiency. These may be subtle, and be confined to the cerebrum and easily dismissed as psychiatric disorders.

The efficacy of vitamin B₁₂ as a tonic is a matter of scientific dispute. Nevertheless its use as a panacea of all ills has probably been founded on some sort of evidence, and it seems likely that its reputation in this connexion has been due to the fact that occasional sufferers from deficiency of the vitamin have received it as part of a blunderbuss or psychotherapeutic regime and dramatic improvements duly noted. Depression after gastrectomy for peptic ulceration is well recognized by psychiatrists, and it may well be that these patients are suffering from a chronic insufficiency of vitamin B₁₂. In this type of case there is a danger of accepting

the patient's mental symptoms as being due to the "ulcer type" or that he is being "difficult" after the operation.

Finally, it is emphasized that the diagnosis is difficult to establish in many cases in spite of a healthy clinical suspicion. Present-day "normal" levels of serum vitamin B₁₂ are inadequate to cope with a wider concept of deficiency of the vitamin, but blind administration is to be deprecated unless injections are to be continued for life if the patient improves.

Summary

Attention is drawn to the pre-macrocytic (? pre-megaloblastic) state, and six cases are presented to illustrate the pitfalls in diagnosis.

Apart from the mental state, an abnormal E.E.G. may be the only positive finding and suggest exclusion of the diagnosis.

Much larger doses of vitamin B₁₂ are needed when treating this type of case, and care must be taken to ensure that an associated encephalopathy is not missed in a patient who presents with severe anaemia. Attribution of the mental symptoms to the anaemia may result in undertreatment, with subsequent cerebral demyelination as the physician's reward.

It is probable that both exogenous and endogenous factors may modify the body's need and demand for vitamin B₁₂. The role of smoking as a possible factor in the production of syndromes other than tobacco amblyopia is worth future consideration. Our present concept of normal levels of the vitamin needs constant re-scrutinization and evaluation in order that treatment may be planned on a scientific basis.

I thank Dr. R. J. Porter and Dr. Richard Asher for much helpful criticism and advice; Dr. D. L. Mollin, of the Postgraduate Medical School, who estimated the serum vitamin-B₁₂ levels by the *Euglena gracilis* method; and Dr. C. C. Evans, who interpreted the E.E.G. findings.

REFERENCES

- Adams, R. D., and Kubik, C. S. (1944). *New Engl. J. Med.*, **231**, 1.
 Cox, E. V., Meynell, M. J., Gaddie, R., and Cooke, W. T. (1959). *Lancet*, **2**, 998.
 Heaton, J. M., McCormick, A. J. A., and Freeman, A. G. (1958). *Ibid.*, **2**, 286.
 Holmes, J. MacD. (1956). *Britt. med. J.*, **2**, 1394.
 Langdon, F. W. (1905). *J. Amer. med. Ass.*, **45**, 1635.
 McAlpine, D. (1929). *Lancet*, **2**, 643.
 Samson, D. C., Swisher, S. N., Christian, R. M., and Engel, G. L. (1952). *A.M.A. Arch. intern. Med.*, **90**, 4.
 Scheinberg, P. (1951). *Blood*, **6**, 213.
 Walton, J. N., Kiloh, L. G., Osselton, J. W., and Farrall, J. (1954). *Electroenceph. clin. Neurophysiol.*, **6**, 45.
 Wiener, J. S., and Hope, J. M. (1959). *J. Amer. med. Ass.*, **170**, 1038.

On August 31 this year, the number of children in the care of London County Council was 8,830 (5,083 boys and 3,747 girls). This figure was 200 more than on August 31 last year. The largest increase was in children under 5 years of age (2,100 compared with 1,999 on August 31, 1959). Of the children in care 939 were "short stay" children—that is, they were in care for such temporary causes as the illness or confinement of a parent—compared with 852 "short stay" children last year. Considerable success has been achieved in finding foster homes. This year it was possible to board out 2,061 children compared with 1,884 last year. (L.C.C. Council Meeting, November 22, 1960.)

MILD HEREDITARY SPHEROCYTOSIS —A FAMILY STUDY

BY

M. F. CARRUTHERS, M.B., B.S.

Department of Haematology, Royal Perth Hospital, Western Australia

The clinical features and laboratory findings of typical hereditary spherocytosis are well known and have been reviewed by Dacie (1954). The condition may also occur in a mild form, when clinical and laboratory findings are minimal (Gänsslen, Zipperlen, and Schütz, 1925; Campbell and Warner, 1926). Families suffering from mild hereditary spherocytosis have been described by Discombe (1948) and by Young, Izzo, and Platzer (1951). Affected members in these families showed similar manifestations of the disease.

There is fairly general agreement in the medical literature that the disease, whether in the severe or the mild form, is transmitted as a Mendelian dominant characteristic (Race, 1942). However, some families show irregularity in the pattern of inheritance. Thus Race found a significant shortage of affected sibs compared with the expected ratio. Young (1955) described five families in each of which both parents of an affected child seemed to be haematologically normal. In at least two of these families, mutation could be excluded as another member of the kindred also suffered from spherocytosis. Young concluded that carriers might occur in families with hereditary spherocytosis who could transmit the genetic defect but themselves appear normal. Ham (1955) confirmed Young's observations, and pointed out that minor increases in mean corpuscular haemoglobin concentration or osmotic fragility of incubated red cells might be important in detecting the carrier state.

The present paper describes three generations of a large family with mild hereditary spherocytosis. In this family two carriers were identified who appeared to be haematologically normal when first examined. Repeated testing of one of these carriers disclosed an abnormality on the fourth occasion. The difficulties in diagnosis offer one explanation for the shortage of affected sibs found by Race.

Family Study

The proband was a 26-year-old man (Fig. 1, Subject II 4) with no significant past history except "failure to thrive." He was admitted to hospital suffering from a fractured pelvis sustained in a motor-vehicle accident. The amount of blood loss was uncertain, as a large haematoma of the thigh was present. The haemoglobin value of his blood three days after admission was 7.6 g./100 ml. and he was given a transfusion of 1 litre of whole blood. At this time spherocytes were noted in the blood film. No operative procedures were performed. Four days later the haemoglobin value was 9.4 g./100 ml., haematocrit 27%, and reticulocytes 8.6%. The serum bilirubin was 1.5 mg./100 ml. and red-cell osmotic fragility was increased. The direct Coombs test on his red cells gave a negative reaction. Further clinical examination revealed slight icterus; the spleen was not palpable. Apart from short stature, the patient was normally developed.

No specific therapy was given for the anaemia after the initial blood transfusion, and the haemoglobin value returned to normal during the next few weeks. However, reticulocytosis, spherocytosis, and increased osmotic