

T H E
Journal of Medical Research.

(NEW SERIES, VOLUME XXII.)

VOL. XXVII., No. 3. JANUARY, 1913.

Whole No. 135.

BENIGN EPITHELIAL TUMORS OF THE THYROID GLAND.*

DAVID MARINE, M.D.

*(From the Laboratory of Experimental Medicine, Western Reserve
University, Cleveland.)*

I.

INTRODUCTION. — Among the most interesting and certainly the least understood of the thyroid tissue reactions is the development of benign epithelial tumors — the so-called adenomas.

It is the purpose of this paper to review the morphological characteristics of these tumors; to present our observations on the percentage iodine contents in relation to their anatomical structure; to offer a classification that embodies both the morphological and physiological data and, lastly, to discuss the possible bearing of these results on Cohnheim's hypothesis of tumor origin.

CLASSIFICATION. — The accumulation of this material has extended over a period of several years, for the reasons (1) that human material only can be used and (2) that these tumors as we see them at autopsy or operation so frequently represent terminal conditions as cysts, fibroid or calcified masses that pure types are relatively rare. Thus out of a total of six hundred and seventeen pathological specimens of human thyroid one hundred and forty-one consisted of or contained benign epithelial tumors and of these only ninety-three were sufficiently free from complications or destructive changes to be used. Many of these

* Received for publication Sept. 30, 1912.

ninety-three specimens were slightly complicated either by hemorrhage, mild cyst formation, calcification or fibrosis, but sufficient tumor tissue was preserved uninjured for purposes of study and classification. Several of these ninety-three cases were tumors accidentally found at autopsy or in specimens removed for other causes as exophthalmic goiter or simple goiter.

By thyroid adenoma one ordinarily means a circumscribed, localized, and encapsulated growth of glandular tissue which retains more or less of the anatomical characteristics of the parent tissue, although the term was formerly used by Rokitsansky,¹ Virchow,² and Wölfler³ to include symmetrical hyperplasias of the whole gland (*e.g.*, "colloid adenoma"). While at present there is a tendency to sharply distinguish morphologically between adenomas and diffuse overgrowths of the thyroid (goiter) and to criticise the earlier observers' use of the term "adenoma;" nevertheless, the more extensive one's acquaintance with these growths becomes the more one is convinced that the point of the earlier writers was well taken; that there is not the sharp division between benign epithelial tumors and diffuse overgrowth that some have been led to expect either anatomically or functionally. There are all gradations, anatomically, from the one to the other and functionally it is known that the development of these benign tumors is constantly associated with hyperplasia of the physiologically adult thyroid tissue, or that the development of these tumors is a part of a general physiological disturbance which causes the gland as a whole to enlarge.


The experimental demonstration of a physiological cycle characterized by developmental, involutionary and colloid or resting phases was a most important aid in the sequential grouping and classification of the almost innumerable degrees of progressive and regressive changes in the hyperplasias of the fully differentiated thyroid tissue.

This cycle of cell changes can easily be reproduced experimentally and the progressive or developmental phase was first clearly demonstrated by Halsted⁴ in his classical experiments with partial extirpation. In 1909⁵ we were able to

demonstrate experimentally one of the regressive phases — involution — by showing that the experimental compensatory hyperplasia of Halsted began to involute spontaneously as soon as the physiological compensation was complete, and further that this involutionary process in dogs could be hastened by the use of iodine. These facts have also been demonstrated in spontaneous thyroid overgrowth (goiter). A second form of regressive change — atrophy — is frequently demonstrated in spontaneously occurring myxedema.

So that in interpreting the thyroid changes in goiter one must bear in mind this simple thyroid cycle which, beginning with the normal cell, consists of progressive changes through all degrees of hypertrophy and hyperplasia and regressive changes either (1) throughout all degrees of atrophy, or (2) throughout all degrees of involution to the resting or colloid or nearest normal state that such thyroids can again assume which have once undergone hyperplasia.

The cycle may be represented schematically as follows:



This conception has made it possible to interpret the many gradations of thyroid reactions found in diffuse overgrowths of the thyroid (goiter), and now one looks upon any given specimen of thyroid reaction as a phase of this cycle and not as an entity either anatomically or physiologically.

Virchow,⁶ from his acquaintance with these tumors, recognized three anatomical groups depending on the predominance of (1) gland follicles, (2) stroma, (3) blood vessels.

This was followed by Wölfler's classical studies,³ and his classification has been the basis for all subsequent attempts.

Both Virchow and Wölfler were unable to solve the problem of deciding what enlargements were to be considered as tumors and what were merely diffuse overgrowths of physiologically adult tissue. This difficulty, as will be shown later, can now be partially overcome by studying the effect of iodine on these tumors during life. He recognized the following groups :

- | | | |
|-------------------------------|---|--|
| (1) adenoma fetalis | { | acinosum
fibrosum
vasculosum
cavernosum
papilliforme |
| (2) adenoma gelatinosum | { | interacinosum
cysticum |
| (3) adenoma myxomatosum | | |
| (4) adenoma cylindrocellulare | | |

While Wölfler was familiar with all the morphological characteristics of these tumors and gives excellent discussions as to their modes of origin and terminations one cannot agree that fetal adenoma and myxomatous adenoma are of the same value as basic types or that colloid adenoma is a form of degeneration. The term "colloid adenoma" is not used to-day as synonymous with colloid goiter. Neither is it proper to designate a colloid goiter composed merely of enlarged follicles as "cystic adenoma" or "cystic goiter."

Confining ourselves for the moment to the histological structure of relatively uncomplicated tumors, it has long been known that certain broad groups could be made. Thus the "fetal adenoma group" has been a well recognized morphological group since the studies of Stromeyer,⁷ B. Beck,⁸ Joh. Müller,⁹ and Billroth.¹⁰ Then there is a more or less defined group of "simple adenomas" (colloid adenomas of Wölfler) so called on account of their close resemblance in structure (epithelium, colloid, size of follicles, etc.) to the simple diffuse hyperplasia — differing from it largely in being encapsulated. Between the fetal adenomas on the one hand

and simple adenomas on the other, most observers have noted intermediate forms.

In our material these general groups could be distinguished or better, perhaps, the series showed all gradations from the type closely resembling simple thyroid hyperplasia to the true fetal adenoma type. Adding to this series of morphological gradations dependent on the anlagen from which the tumors develop the conception that the tumor developing from each anlage undergoes its cycle of cell changes (progressive and regressive) and it can be seen that the morphology of these tumors may vary both with the type of cell from which the tumor took origin and also with the phase of the physiological cycle of the tumor cells at the time of the examination.

This being true it is clear that studies in morphology alone could not estimate the significance of morphological variations dependent upon physiological activity.

We therefore attempted to ascertain whether anything comparable to the physiological cycle of the non-tumor tissue could be made out in the tumor tissue by comparing the iodine contents of these tumors with their histological structure and studying the effect of the administration of iodine to patients with these tumors. The results will be referred to again in detail and it suffices here to state that the percentage iodine content was found to bear a relation to the structure—being lowest in the growing and highest in the resting or colloid phases, and that the administration of iodine affects these tumors to some extent—the effect being least in the fetal adenomas and greatest in the simple adenomas.

These observations suggest that these tumors have a physiological cycle of cell changes consisting of a growing, involutionary and colloid or resting phases much modified but in general comparable to that which occurs in the fully differentiated thyroid tissue and if represented schematically would be:

Adenoma anlage	}	hypertrophy—hyperplasia	{	atrophy destructive metamorphosis involution to colloid or resting state.
-------------------	---	-------------------------	---	---

In the light, therefore, of definite morphological evidence of variation in the type of tumor depending on the degree of differentiation possessed by the cells of the tumor anlage and of definite physiological evidence of variation in structure, depending on the functional phase (progressive or regressive) of the tumor, we would submit the following scheme of classification :

THYROID GLAND.

I.	II.	III.	IV.
Hyperplasia from Physiologically Differentiated Thyroid (Simple or Parenchymatous Goiter).	Simple Adenoma.	Intermediate Adenoma.	Fetal Adenoma.
(1.) Growing phase.	Growing phase.	Growing phase.	Growing phase.
(2.) Involutionary phase.	Involutionary phase.	Involutionary phase.	Involutionary phase.
(3.) Colloid phase.	Colloid phase.	Colloid phase.	Colloid phase.

We have divided the benign epithelial overgrowths of the thyroid tissue into four primary groups, using as fixed points the simple hyperplasias (ordinary goiter) or the most differentiated of all thyroid hyperplasias as one end of the series and the fetal adenoma group or the least differentiated of benign thyroid hyperplasias as the other end. Between these two fixed and constant groups one encounters all gradations which for the sake of simplicity and convenience of description we have divided into two only, — simple and intermediate adenomas. We have also divided the physiological cycle of cell changes of each of the four primary groups into three phases, using as our fixed points the growing stage and the colloid or resting stage. Between these two relatively constant there are all intermediate stages which, for the sake of simplicity, may be collected into one group — involutionary.

Group I. comprises the simple hyperplasias which develop from the most differentiated thyroid tissue. These hyperplasias are in no sense tumors. They are the ordinary

thyroid tissue overgrowths seen in all developing goiters in all animals from fish to man. We have introduced this best known group of thyroid tissue overgrowths into the scheme in order to show its relations both anatomical and physiological to the localized and encapsulated epithelial overgrowths.

Group II. comprises the simple adenomas, that is, circumscribed masses of thyroid hyperplasia which in their morphological characteristics and their reactions with iodine closely resemble the ordinary hyperplasias of Group I. These tumor-like masses are never seen in glands which are not also the seat of a general hyperplasia, and in a large series of thyroid examinations one finds all gradations between the simple hyperplasias of Group I. and strictly encapsulated hyperplasias. Many of these masses can be classed as tumors morphologically only in the sense that they have fibrous capsules (often very rudimentary) (see Figure 17). Physiologically they are always affected by iodine, occasionally to the same degree as the non-tumor thyroid tissue. So that areas of encapsulated hyperplasia which morphologically are often classed as simple adenomas physiologically may not be tumors. The dividing line then between simple diffuse hyperplasia and simple adenoma lies somewhere between Groups I. and II. and the exact status of any given mass can only be determined by its reaction with iodine.

Group III. comprises the intermediate adenomas—an arbitrary grouping to include encapsulated masses of epithelial hyperplasia not differentiated sufficiently to be included under Group II. and more differentiated than the fetal adenomas. These growths are undoubtedly tumors, since morphologically they are composed of small rounded follicles sometimes closely and at others loosely placed in a scanty stroma within a well formed fibrous capsule and are not notably influenced by iodine within the time limits in which simple hyperplasia is affected.

Group IV. comprises the true fetal adenomas. Wölfler included under fetal adenoma both our Groups III. and IV.

They are the least differentiated of all benign thyroid epithelial overgrowths and the most perfectly encapsulated. They are also the least affected by iodine and are therefore the most autonomous of the benign epithelial overgrowths.

In each of these four groups there is a well defined cycle of cell changes characterized by a growing, an involuntary, and a colloid or resting stage. This cycle is regular and constant in the simple hyperplasias of Group I. and becomes more irregular and less constant through Groups II., III., and IV. The growing phase is characterized anatomically by an increased vascularity of the tissue, an increase in the size and number of the gland cells, becoming columnar from a previously cuboidal state and a decrease in the stainable colloid. Physiologically, this change is characterized by a decreasing percentage iodine content. The involutory stage is characterized by a decreasing blood supply, a decrease in the size of the epithelial cells from columnar toward cuboidal and an increase in the stainable colloid. Physiologically there is an increasing percentage iodine content.

In the colloid stage the blood supply, the epithelium, the stainable colloid and the percentage iodine content approach and may coincide with the strictly normal gland tissue. This physiological cycle though present throughout the tumor groups is progressively less pronounced morphologically and physiologically as one passes from the simple hyperplasias to the simple adenomas, to the intermediate adenomas, and is least pronounced in all its characteristics in the fetal adenomas.

II.

THE RELATION OF THE PERCENTAGE IODINE CONTENTS TO THE ANATOMICAL STRUCTURE AND TO THE PHYSIOLOGICAL PHASES OF THESE TUMORS.

Of the ninety-three tumor masses used in this study, iodine determinations were made on eighty-seven, of which thirty-six were grouped, anatomically, under fetal adenomas;

twenty-five under intermediate adenomas, and twenty-six under simple adenomas.

We were fortunate in obtaining sufficient non-tumor thyroid tissue in fifty-six of the ninety-three cases to make histological studies and iodine determinations. Of these fifty-six, twenty-five were from cases in the fetal adenoma group, fourteen from cases in the intermediate adenoma group, and seventeen from cases in the simple adenoma group.

In analyzing these iodine determinations one of the most important factors to have accurate knowledge of would be whether iodine had been used in the treatment or not. The tumor material being of necessity all human, it is impossible to obtain this knowledge for all cases and we will therefore discuss separately those cases which were given iodine either to our personal knowledge or from whom very positive statements were obtained. There were twenty-three such cases, of which eight had been given syrup of ferrous iodide for from two weeks to two years (intermittently) under our personal direction. The remaining fifteen had been given several preparations, including potassium iodide, sodium iodide, hydriodic acid and Lugol's solution.

In one case (H. 454) not included in these twenty-three, desiccated thyroid was given for two weeks before operation. The iodine content of the non-tumor thyroid was .53 and of the tumor .11 milligram iodine per gram dried.

As others in addition to those twenty-three cases may have received iodine in some form at one time or another a detailed analysis loses much of its value. We have, however, made three analytic groups: (1) the eighty-seven cases as a whole, (2) the sixty-four cases which had not taken iodine recently, to our or the patient's knowledge, and (3) the twenty-three cases which to our knowledge had received inorganic iodine.

A factor which modifies the value of the iodine determinations of the non-tumor thyroid tissue is that owing to stretching and atrophy by pressure from the enlarging tumor, its physiological activity is greatly impaired and often completely destroyed when the surrounding non-tumor tissue is

reduced to layers of fibrous tissue (false capsule of tumor). This modifying factor has been partially eliminated by excluding all (six) cases where there was general destruction of the follicles histologically.

TABLES OF AVERAGES.
Iodin per gram of dried gland in milligrams.

No. 1.....	Of all cases = 87.					
	Fetal Adenomas.		Intermediate Adenomas.		Simple Adenomas.	
	Non-tumor Thyroid.	Adenoma.	Non-tumor Thyroid.	Adenoma.	Non-tumor Thyroid.	Adenoma.
(1) Growing	1.02	0.09	1.01	0.23	1.31	0.59
(2) Involutionary..	0.89	0.25	1.93	0.46	0.77	0.35
(3) Colloid	1.02	0.94	0.98	0.45	1.08	0.65
No. 2.....	Of cases not fed iodine = 64.					
(1) Growing	0.46	0.11	0.75	0.22	0.43	0.18
(2) Involutionary..	0.60	0.25	0.44	0.45	0.77	0.35
(3) Colloid	0.14	0.78	0.74	0.36	0.69	0.46
No. 3.....	Of cases fed iodine = 23.					
(1) Growing	2.02	0.06	1.28	0.32	1.75	0.80
(2) Involutionary..	1.76	0.26	3.05	0.47		
(3) Colloid	1.47	1.05	1.93	1.03	1.95	2.22

(1.) As can be seen in the complete charts or in the complete iodine tabulations (appended at the end of the paper) or in the tables of averages above, the percentage iodine content of the non-tumor thyroid tissue bears no evident relation to that of the tumor in the growing phase of either of the three groups. Thus the percentage iodine

content may be relatively high in the non-tumor tissue and iodine measurably absent from the tumor, or both may be low. The percentage iodine content of the tumor is in most instances far less than that of the non-tumor tissue, although this is not necessarily so, as is easily intelligible when one recalls that in infants' thyroids normally and in marked hyperplasias of physiologically adult tissue the percentage iodine content may be very low or iodine measurably absent.

Another feature of physiological significance is that the growing stage of fetal adenomas has the lowest percentage iodine content, the growing stage of intermediate adenomas the next lowest, and the growing stage of simple adenomas the highest. The growing simple adenomas, therefore, approach most closely the growing simple non-tumor hyperplasias in this capacity for iodine.

Taking up the three functional phases (growing, involutory, and colloid) as grouped according to structure, the most striking feature is that the growing phases of all three groups have in general distinctly lower percentage iodine contents than the involutory phases, and the involutory phases in general have lower percentage iodine contents than the colloid or resting phases. This is quite striking when one considers that the grouping is purely on the basis of structure and that in human material many of the most important aids are lost on account of our ignorance of the life history of the individual tumors. This loss is compensated for in a way by the detailed experimental knowledge of the analogous functional phases of the non-tumor thyroid tissue which undergoes a similar cycle of growing, involutory, and colloid or resting phases.

(2.) Cases which had not received iodine recently to our or the patient's knowledge: This tabulation differs from the first only in being minus the twenty-three cases known to have taken inorganic iodine. As one could prophesy from previous knowledge of the behavior of the physiologically adult thyroid tissue in the presence of iodine, the greatest difference between the two tabulations occurs in the percentage iodine contents of the non-tumor thyroid tissue

which is distinctly lowered, while those of the tumors are but slightly modified. Apart from this feature the same general relations are evident.

(3.) Those cases which, to our knowledge, received iodine: The twenty-three cases in this tabulation are equivalent to experiments. They lack iso-controls so that we can compare them only in a general way with those cases not known to have received iodine recently.

First and most striking is the relatively high iodine content of the non-tumor thyroid tissue which, considering the smallness of the series, is singularly constant through the three groups of adenomas and the three physiological phases of these groups. This finding is only confirmatory of the well known characteristic of thyroid tissue, viz., that a rapid storage of iodine takes place in the thyroid following the administration of iodine.

The next feature of importance is the relative independence of the tumor and the non-tumor tissues as regards ability to take up iodine. This independence is practically complete in the growing phase of the fetal adenomas as judged by comparison of the percentage iodine contents of the same group of tumors in Tabulation 2, but seems to become less marked as one passes to the intermediate and to the simple adenomas. The probable explanation of this is that with the increasing anatomical differentiation there is also increased physiological differentiation (as judged by capacity for iodine). In the simple adenomas it clearly approaches the degree of iodine handling function exhibited by the non-tumor or physiologically adult tissue.

So also the differences in the percentage iodine contents between the tumor and the non-tumor tissue become less as one passes from the growing phases through the involutionary to the colloid or resting phases. In the colloid phases of all three tumor groups the percentage iodine contents closely approach those of the non-tumor tissue and in individual cases may exceed that of the non-tumor tissue as is the case in the colloid phase of the simple adenomas. One sees, therefore, an increased storage of iodine varying directly with

the structural differentiation of the tissue anlage from which the tumor started and also varying directly with the physiological phase of the tumor.

Another feature that is suggested in Tabulation 2 and here more clearly illustrated by the iodine reaction is that as the tumor grows (whether from the starting point of fetal, intermediate or simple adenoma) it tends to differentiate functionally as well as morphologically. In other words, the thyroid tissue of these benign tumors tends to and does undergo a modified cycle of cell changes similar to that which the fully differentiated tissue undergoes and differing from it only in degree. This degree depends on the anatomical and physiological differentiation of the anlage from which the tumor takes origin. Thus a tumor starting from the fetal thyroid tissue or the lowest anatomically and physiologically differentiated tissue of our tumor groups would, under the usual conditions obtaining in an animal, undergo a more modified and therefore a more independent cycle than would a tumor starting from a relatively well differentiated anlage as represented in the anlage of a simple adenoma. By the phrase "under the usual conditions obtaining in an animal" we refer to the fact that usually there is an abundance of growing non-tumor thyroid tissue where there is a growing adenoma, but if it were possible to obtain an animal in which these tumors occurred where these conditions could be experimentally altered, as, for example, by removing all the non-tumor thyroid tissue and preserving an adenoma with its blood supply, it is highly probable that such an adenoma, even though it were of the lowest type (fetal), would undergo morphological and physiological differentiation more rapidly than it would do or does in the presence of more highly differentiated thyroid tissue which could have the effect of inhibiting the differentiation of the tumor tissue.

Summing up the evidence obtained from these tabulations of the percentage iodine contents arranged according to structure, one sees that just as the non-tumor thyroid tissue shows a variable anatomical state in association with the

several groups of tumors so also the iodine contents are variable. There is, however, in the non-tumor thyroid tissue a definite relation between structure and iodine content just as in the physiological hyperplasias of all mammals and in the tumors a similar relation exists. That is, the percentage iodine contents are lowest in the growing phases and highest in the colloid or resting phases.

There is a physiological cycle for these tumors as determined by the iodine contents just as there is an anatomical cycle as determined by their structure and this physiological cycle, just as the anatomical cycle, differs from the corresponding cycle of the non-tumor tissue only in degree. That is, the tumor tissue is, under natural conditions, not capable of producing as highly differentiated a type of hyperplasia as the non-tumor tissue and its hyperplasia is not under the strict physiological control that the non-tumor thyroid hyperplasia is. Thus simple hyperplasia of differentiated thyroid tissue is constantly and quickly modified by iodine both in structure and iodine content, while the tumor hyperplasia is neither quickly nor constantly modified. In true fetal adenomas there is, as a rule, no evidence of any effect of iodine in the usual time (2-6 weeks), in which non-tumor thyroid tissue is markedly changed as shown in five examples (H. 239, 240, 242, 348, and 359), in which inorganic iodine was used. In each of these cases the surrounding non-tumor tissue was markedly affected both in structure and in iodine content.

As one passes from these least differentiated (fetal) adenomas to the more differentiated intermediate and to the still more differentiated simple adenomas, there is evidence of increased iodine action both on structure and on iodine content, as shown in Nos. H. 447, 508, 526, and 555, examples of growing simple adenomas fed iodine.

Between the simple hyperplasias and the simple adenomas there are intermediate gradations both in structure and in the action of iodine, and by means of their iodine reactions it is possible to state that there are certain masses of epithelial overgrowth with the physical characteristics of benign

tumors which are physiologically not tumors but parts of the general functional overgrowth of the gland which in growing had acquired a kind of encapsulation. In other words, the diagnosis of benign thyroid tumors on the basis of anatomical structure leads to error unless controlled and checked by some physiological test, just as the overgrowth of the thyroid in bony fish exhibits certain anatomical peculiarities which by purely anatomical standards we would recognize as malignant epithelial infiltration while by physiological tests they belong to clearly benign physiological overgrowths.

Finally the question arises: Do these benign tumors functionate? From all evidence at present available we must conclude that they have function. In the first place these tumors are never seen in thyroids which are not also or have not been the seat of a general hypertrophy or hyperplasia. Secondly, one must recognize a complete gradation of these tumors anatomically from the least differentiated or fetal type through the intermediate and simple adenomas to the strictly physiological hyperplasias of physiologically adult or highest type of thyroid tissue. Thirdly, one finds all gradations in the percentage iodine contents from the lowest (occasionally measurably absent) in the fetal adenomas through the intermediate and simple adenomas to the highest in the physiologically adult hyperplasias. Fourthly, the administration of iodine does influence these tumors. This influence is least (ordinarily unrecognizable in 2-6 weeks) in the fetal adenomas, then gradually increases through the intermediate and the simple adenomas and reaches its fullest physiological effect in the simple diffuse hyperplasias. Fifthly, each tumor tends to undergo a physiological cycle in that it has its growing, involuting and colloid or resting phases just as does the hyperplasia of physiologically adult tissue. This cycle is least evident in the fetal adenomas (which may persist throughout a long life with but little change) and progressively becomes more evident in the intermediate and in the simple adenomas.

In the absence of direct experimental proof of function, which is at present impossible, we believe that this evidence

can scarcely be interpreted otherwise than that these tumor-like masses are only partially independent of the function of the gland as a whole.

III.

ANATOMICAL DESCRIPTION OF THE GROUP TYPES.

Group I. — The series of changes that take place in fully differentiated thyroid tissue as it passes from the normal through the many stages of active hyperplasia and on toward atrophy or involution have already been fully described in previous publications¹¹ and need not be reviewed here. Photomicrographs illustrating the normal thyroid (Figure 1), the hyperplastic phase (Figure 2), the involutionary phase (Figure 3), and the colloid or resting phase (Figure 4) are added for comparison with the corresponding phases of the tumor groups.

Group II. — These masses are most frequently seen in the so-called "nodular goiters" and make up a large proportion of "struma Knotchen," which occur commonly in the goiters of late childhood and puberty in endemic goiter districts. They are always multiple, rounded masses of varying sizes and in their growing phases always form integral parts of the general enlargement, but in their late stages may become more distinct and isolated through secondary metamorphoses. The true capsule is normally thin, often rudimentary, while in their late stages a false capsule of stretched atrophic non-tumor tissue may form a laminated covering several millimeters in thickness.

(a.) (See Figure 5.) Histologically, the growing stage of a characteristic specimen is composed of follicles of variable size and often much larger than those of the non-tumor tissue. The lining epithelium is columnar and in the larger follicles has infoldings and plications similar to the non-tumor hyperplasia. Between the larger follicles there are usually numerous smaller ones less completely differentiated. Colloid material, poorly staining and granular, is commonly present in all the larger follicles.

The stroma is less developed than in the non-tumor tissue and trabeculæ are absent. The blood supply in small tumors is in all respects similar to that in non-tumor tissue, but as the larger arteries run in the capsular tissues, growth, as Wölfler showed, occurs in the peripheral zone.

(*b.*) (See Figures 6a and 6b.) The central area of the mass is the oldest and shows the earliest involutionary changes. These consist of a decreased blood supply with hyaline changes in the scanty stroma; accumulation of colloid in the larger follicles and atrophic changes in the smaller follicles. The epithelium usually remains columnar.

(*c.*) (See Figure 7.) In the colloid phases, when uncomplicated, all the follicles appear relatively larger and more rounded, due to the return of the columnar epithelium to the cuboidal type and to the filling up of the follicular spaces with normally staining colloid. In tumors that have outgrown their blood supply the smaller follicles of the central area may be reduced in number and the larger ones acquire distortions in the hyalinized stroma so that it is difficult to distinguish colloid, and the epithelial cells may appear imbedded in a nearly uniform matrix. The blood vessels become thickened and much of the capillary structure of the interior may disappear.

Group III.— The intermediate tumors were grouped by Wölfler under fetal adenomas. We have arbitrarily introduced the group and under this name in order to emphasize the fact that between simple adenomas and the fetal adenomas there are many gradations.

These tumors are usually multiple and on section quite distinct in appearance from the non-tumor thyroid in that they are more cellular. They share the same variations in size and number that simple adenomas do, but have distinct well formed fibrous capsules.

(*a.*) (See Figure 8.) In the growing phase the mass is grayish red in color. The parenchyma is soft, friable and composed of follicles closely set and more uniform in size than those of the simple adenomas. The lining epithelium

may have slight infoldings and plications. The epithelium is high cuboidal or low columnar and usually regular in form. Colloid when present is granular and stains poorly. The stroma is less developed than in the simple adenomas. There are no trabeculæ. The largest vessels lie in the capsule and the larger vessels of the stroma have poorly developed coats. As growth proceeds hyaline degeneration and atrophy are more likely to take place in these than in the simple adenomas with their better organized blood supply.

(*b.*) (See Figure 9.) In the involutionary phase the follicles are more in evidence as colloid accumulates and the lining epithelium becomes more cuboidal.

As in the simple adenomas, the earliest involutionary changes take place in the central zone. Here there are larger colloid filled follicles surrounded by smaller atrophic follicles. The stroma is relatively increased and usually hyaline. In the sub-capsular zone there is also accumulation of colloid and in (*c*) (see Figures 10a and 10b) the colloid phase all the larger follicles are filled with uniformly staining colloid. The lining epithelium is low cuboidal and the larger vessels of the capsule are thickened. Atrophic or undeveloped follicles become more distinct as the stroma expands and in late stages may assume the appearance of a myxomatous adenoma (Wölfler).

Group IV. — Fetal adenomas are the best known and most distinct type. They are usually multiple and when their growth is arrested early may persist with but little change until old age. I have seen two autopsies in individuals over sixty years old where multiple adenomas from one to eight or ten millimeters in diameter have persisted with but little change (see Figures 11a, 11b, and 11c).

(*a.*) In gross appearance the growing stage of the minute tumors are indistinguishable from large lymph foci that may be present. The larger tumors are round, firm, and on section grayish opaque in color, usually in sharp contrast with the non-tumor thyroid. The tumor tissue is

friable, very cellular, and there is no visible colloid. The capsule is well developed in all stages and there are no trabeculæ. Microscopically the stroma is very scant and undeveloped. The follicles are of uniform size, very small, closely set, rounded, and in most instances have visible lumina, though occasionally tumors are seen where this degree of differentiation has not occurred. The epithelial cells are small, cuboidal, uniform in size, and with hematoxylin the cytoplasm is usually tinged with blue. As a rule stainable colloid is absent. Wölfler³ has shown that the blood supply is similar to that of normal fetal thyroid in richness and distribution about the follicles.

(*b.*) (See Figures 12a and 12b.) In the involutionary stage the follicles become more variable in size owing to different growth rates. The epithelium remains cuboidal and distinct lumina are present in all the more developed follicles. Colloid also appears in the follicular spaces. As with the other tumor groups differentiation is most advanced in the older central portion of the tumor mass and owing to the gradual reduction in blood supply the central areas show considerable variation in the number of follicles as a result of atrophy, hyaline degeneration and edema of the stroma, which in marked degrees correspond to Wölfler's myxomatous adenoma.

(*c.*) (See Figure 13.) The colloid phase is characterized by further accumulation of colloid in the follicles which may approach normal colloid in staining reactions. The follicular epithelium becomes low cuboidal. The blood supply is further reduced and secondary changes are most frequently seen in this group owing to their poorly developed blood supply.

To summarize the major features of the three tumor groups it is found that all have true capsules — often rudimentary in the simple adenomas, and progressively more prominent and distinct in the intermediate and fetal groups. The stroma is poorly developed and scanty in all — being least developed in the fetal adenomas. No trabeculæ are present, hence no lobulation as in the non-tumor tissue.

The larger well formed vessels lie in the capsules for the most part, while those of the parenchyma have poorly developed muscular and adventitial coats. As these tumors grow from the periphery their central portions are more and more removed from their blood supplies — an outgrowing of the blood supply, so to speak, which leads to atrophy, degeneration, and other more destructive metamorphoses. This tendency is most pronounced in the fetal adenomas and least so in the simple adenomas where the blood vessels are better developed.

The follicles are largest and most irregular in the simple adenomas and progressively become smaller and more regular toward the fetal adenomas. The epithelium in the growing phase is distinctly columnar in the simple adenomas and becomes more cuboidal in the intermediate and fetal adenoma groups. In the colloid phase all groups have cuboidal epithelium as the ruling type. Infoldings and plications are the rule in the simple adenomas, while they are rarely present in the intermediate and are absent from the fetal adenomas. The colloid content is much reduced during the growing phases of all groups and usually absent in the fetal adenomas, while in the colloid phases all developed follicles contain normally staining colloid.

IV.

SECONDARY AND TERMINAL METAMORPHOSES.

The frequency of complicating and destructive metamorphoses in these tumor-like masses has already been mentioned, but in order that one may not gain the impression from the earlier part of this paper, when we were considering as nearly uncomplicated examples as possible, that uncomplicated forms are the rule, we would repeat that as these tumors are seen at operation and at autopsy some secondary metamorphosis is usually present.

The same types of regressive changes are seen as well in the diffuse non-tumor thyroid overgrowths as in the strictly localized overgrowths. The frequency and extent of these

changes progressively increase, however, as one passes from the diffuse non-tumor overgrowth through the simple, the intermediate, and the fetal adenomas. Just as destructive and degenerative changes are infrequently seen in the simple hyperplasias during their actively hyperplastic or growing stages, so with the tumor groups. It is during the regressive stages — involutory and colloid — that these degenerative changes most frequently occur. Hence these changes are for the most part the result of old age, of decreased functional activity, and of failing nutrition in a tissue that normally is most active in early life. Mild degrees of these degenerative changes may normally be present in the senile gland. The frequency and extent to which they occur depend on the degree of thyroid overgrowth at the time when the increased physiological needs of the organism for thyroid activity are suddenly withdrawn. Thus mild degrees of thyroid hyperplasia, whether of tumor or non-tumor nature, may complete their physiological cycles without complications. This cycle for the non-tumor hyperplasia has been described elsewhere,¹² and for tumor it has been described under "Anatomical Descriptions of Tumors."

Of the strictly pathological metamorphoses occurring in tumors, hemorrhage (see Figure 16a) is the most common. As many observers, and particularly Wölfler, have shown, the capillaries of these tumors are, like normal thyroid capillaries, dilated and sinusoid with ampulla-like enlargements and thin walls. Through trauma, pressure, venous congestion, and failing nutrition these capillaries rupture ("Capillary Apoplexy" of Wölfler) and extravasations of blood take place, which when extensive may result in necrosis. Hemorrhages more commonly occur in the central portion of the tumor and the subcapsular zone usually is spared. If the hemorrhage is slight the stroma remains, from which healing by scar formation takes place and stellate scars of various sizes are of common occurrence in the centers of these tumors. Calcification often follows in these scars. When the destruction of tissue is extensive cyst formation

results. The cysts may be single or multiple. Cysts of this origin are the surgical cysts of the thyroid as Bloodgood¹³ and others have pointed out. Secondary hemorrhages into these cysts are relatively common even to the extent of producing large tumors.

Necrosis and cyst formation may also result from venous or arterial obstruction of the vessels as they pass through the capsule, either by thrombosis or by greatly increased capsular tension. In such cases there is acute, almost total necrosis associated clinically with sudden onset of pain and rapid enlargement in a few days. Examination of two such masses has shown the usual features of infarctions with liquefaction and extensive exudate into the encapsulated mass.

Edema is not uncommon and probably is dependent partly on peculiar locations of these tumors and, in consequence, the production of certain forms of circulatory stases—lymphatic and venous. If this edema is of long duration the stroma becomes myxomatous in type (see Figure 16b) and the gland acini often unduly separated. These are the myxomatous adenomas of Wölfler and others. Adenomas removed by enucleation are frequently edematous owing to venous stasis during operation, and this should not be confounded with spontaneous edema.

Atrophy (see Figure 15) of the alveoli is of frequent occurrence. There are all degrees of thinning out of the epithelial elements from slight rarefaction to total absence. This condition results from a slow impairment of nutrition through a relative or absolute decrease in the blood supply. It is always most marked at the center and gradually decreases toward the periphery, where often a zone of active, closely-set follicles is preserved. When the atrophy is complete, as occasionally occurs, one sees what some observers have called fibroma. The existence of true fibroma is acknowledged by some¹⁴ and denied by others. I have seen three tumors that might be classed as fibroma, but considering all the facts they were without doubt fibromas

through the persistence of the harder tissue. There is little doubt that adenomas in certain locations cause a cessation of their growth by their own growth mechanically interfering with the blood supply and thus bring about fibrosis and atrophy.

The major cause of fibrosis and atrophy is probably the result of a systemic or physiological decrease in the blood supply which affects the gland as a whole.

Of the degenerations, hyaline (see Figures 14 and 15) is very common in the regressive phases of these tumors in association with atrophy of the glandular elements, with edema and with all the chronic impairments of nutrition. Like other evidence of failing nutrition affecting these tumors hyaline changes are usually more extensive in the center. As the blood vessels and gland alveoli disappear, the stroma assumes a firm, translucent, homogeneous appearance, which as Virchow pointed out may resemble cartilage grossly. Here and there blood spaces occur with only the endothelium intact and scattered extravasations of blood cells are seen. Alveoli, widely separated and distorted, are often present in the more hyaline areas and may appear as if the fatty epithelial cells were set directly in the hyaline matrix.

Amyloid infiltration is stated by many to be of common occurrence in these tumors. As it is not readily distinguishable from the extensive hyaline changes, there is some doubt as to its frequency.

Deposition of lime salts. — Carbonates, oxalates, and soaps are among the commonest of degenerative changes. There may be only the slightest traces of lime soaps in the hyaline stroma or the entire tumor nodule may be a single calcified mass. More commonly the carbonate deposits take place in the walls of large vessels in the capsule and of the capsule itself as in some cysts where the walls may be rigid and brittle from extreme lamellar calcification. The most common site for calcified areas is the central core either in the scar of a healed hemorrhage or in hyaline, fibrotic stroma

secondary to atrophy of the gland follicles and may appear as single, pronged, solid or cavernous masses. More rarely in the early stages one may see a calcified meshwork outlining the stroma, in the meshes of which are well preserved gland follicles.

Infections. — Considering the favorable soil offered by these tumors in their many degrees and phases of failing nutrition, abscess formations are relatively rare, though they probably make up a majority of the acute thyroid abscesses. One of the older methods of treatment of these tumors was by the introduction of a seton which was followed by infection, suppuration and healing by scar formation. In influenza, scarlet fever, pneumonia, typhoid fever, tonsillitis, etc., these degenerating tumors are occasionally the seat of abscess formations.

Finally the development of malignant tumors, sarcoma, and carcinoma is in some way occasionally associated with these progressive and regressive tissue changes, especially of the adenomas. The so-called malignant adenoma is the most common type of thyroid carcinoma and is believed to originate in many cases from these tumors.

Summing up, then, it is found that the more common destructive metamorphoses include hemorrhage, necrosis, cyst formation; degenerations — amyloid, hyaline, calcareous, fatty; impairment of the blood supply and lymphatic drainage leading to necrosis in acute forms and to edema and atrophy in chronic stages, with myxomatous or simple fibrous changes secondary to atrophy of the glandular elements; and rarely infectious and malignant tumors.

These metamorphoses are common to both the tumor and the non-tumor tissue. They are seen for the most part in the functionally regressive stages. They are more common in the fetal adenomas and progressively decrease as one passes through the intermediate and simple adenomas to the simple hyperplasias.

V.

GENERAL DISCUSSION ON THE OCCURRENCE, DISTRIBUTION,
AND ETIOLOGY OF THESE TUMORS.

These tumor-like masses occur with great frequency in man in all regions where endemic goiter occurs. In striking contrast one does not see them in the sheep, ox, pig, dog, cat, rabbit, or guinea-pig, although goiter is quite common in these animals in all goitrous regions. Bircher¹⁵ has observed the development of "struma Knötchen" in rats during his "Kropfwasser" experiments. I have examined some of his preparations and there were many examples of circumscribed more or less encapsulated areas of hyperplasia closely resembling ordinary hyperplasia which could be classed morphologically as simple adenomas. The reaction with iodine had not been tried.

In the examination of large series of trout goiters one occasionally sees circumscribed areas of thyroid hyperplasia, but I have never seen them completely encapsulated as in man. To our knowledge these tumor-like masses have so far never been observed in monkeys, horses, goats, or any of the more accessible animals where considerable series of glands have been obtained. It is therefore singular that these tumor-like growths should be of such frequent occurrence in human goiter and so rare, if not absent, in the common domestic animals where the thyroid reactions are otherwise similar to those of man.

The age limits within which these tumors develop is of general etiological importance in that they develop only in early life, although they may be present (persistent) in the oldest individuals either as millet seed or pea-sized masses or reach considerable proportions. Tumors are occasionally seen well developed at birth as in cases reported by Wm. Müller.¹⁶ Their development is believed to occur during all the years up to and including puberty. After puberty it is not probable that any new benign tumor anlagen arise and it is the belief of many that no new tumor anlagen arise after a much earlier period than puberty. The growth of

existing tumor masses after puberty is subject to great variations just as simple hyperplasia. The factor of age is also related to the type of tumor. Thus the fetal type is the earliest to develop, although it may persist to old age. The simple adenomas are tumors of the more differentiated thyroid of childhood and possibly may develop up to and during the period of puberty. The age incidence of these tumors is also closely interwoven with the age incidence of hyperplasias in general. That is, both types of thyroid overgrowth occur most frequently between birth and puberty, and it is certain, as Virchow recognized, that these benign tumor-like masses do not occur in glands which are not also the seat of an universal hypertrophy or hyperplasia. The reverse, however, is not true, as one sees uniform hyperplasias at birth or at any time during life without the presence of tumors and in the hyperplasias after puberty as in pregnancy, exophthalmic goiter, menopause, etc., new tumors probably do not arise.

The incidence of sex is clinically that of goiter in general, hence the tumors under discussion are more common in the female. The sex differences are in large part due to the fact that the stimulus for tumor growth is the same or coincident with the stimulus for overgrowth of the gland as a whole and not that potential tumor anlagen are not equally common in both sexes in the developmental stages of the thyroid.

Of importance in this connection is the question whether tumor masses that have remained quiescent for a period can undergo a second period of growth just as the physiologically adult thyroid tissue commonly does. With what we know of their relations and the fact that they do undergo a modified cycle it is probable that they may undergo a second active hyperplasia in association with a second hyperplasia of the non-tumor thyroid, but as yet this has not been observed.

The question whether the stimulus to the growth of these tumors is identical with that which affects the whole gland

can be answered positively with our present facts. The constant association of the generalized hyperplasia with their developmental stage, the age coincidence of both tumor and hyperplasia, the fact that they undergo a modified cycle of cell changes similar to that seen in the non-tumor tissue, the fact that these "Knotchen" develop in rats' thyroids as part of the general thyroid reaction, the fact that there are all gradations from the simple hyperplasias on the one hand to fetal adenomas on the other, the fact that the percentage iodine content relations and the effect of the administration of iodine are similar to those of the non-tumor thyroid overgrowth — all these facts favor the view that the stimulus to tumor growth is the stimulus that excites the thyroid as a whole to overgrowth.

Another question that may be discussed here is: What theory offers the simplest explanation of the mode of origin of this group of new growths? Billroth, Virchow, Wölfler, and all recent writers accept as the most probable explanation of the origin of fetal adenomas that they arise from embryonic cell rests. Groups of atrophic or undifferentiated cells lying in the stroma are familiar to all students of thyroid tissue and Wölfler was the first to point out their possible pathological significance. I think one can conclude on the evidence at hand that if fetal adenomas arise from these cell rests then all these circumscribed epithelial growths have a similar origin and the conception generally known as Cohnheim's hypothesis of tumor origin from cell rests as applied by Wölfler offers the clearest understanding of these particular growths. There are some modifications and restrictions to be mentioned. The thyroid has its embryomas (teratomas) and possibly tumors from "misplaced embryonic thyroid rests," but their modes of origin, as well as that of malignant tumors, are problems quite foreign to the one under discussion. These particular overgrowths are epithelial tumors which originate from true thyroid tissue and within the limits of the normal thyroid anlage. If one accepts the view that it is the same physiological stimulus which acts on both the tumor and non-tumor hyperplasia

then it follows that one has to account only for the occurrence of cell rests of different degrees of anatomical differentiation from which these tumors arise. We must suppose that normally the size of the thyroid is determined by the physiological needs of the organism and as is well known this varies with the individual animal — its food, environment, geographical location, etc. The thyroid anlage in the course of its growth as with other body tissues is potentially capable of producing much more tissue than is usually needed, and in the course of its growth groups of cells from time to time become arrested in their growth just as is well known in the sex glands, muscles, etc. Normally these groups of cells are wholly absorbed in the course of time, but at any given period in the development of the thyroid there would be unabsorbed cell rests of different physiological ages and should a stimulus for increased functional activity become active during the period in the thyroid's life when these atrophic cell rests were still viable, then the whole gland would respond by both increased function and increased growth. The type of growth resulting would depend on the degree of physiological differentiation of the tissue from which the sudden and rapid growth began. Thus one could postulate that groups of cells were being arrested at all levels of physiological differentiation from the least in the fetal type to the highest in the fully differentiated adult type and a stimulus for increased activity would excite all these different physiological ages of thyroid cells to increased growth, which growth would take the form and function of the cell rest from which the growth started.

Such a view offers the most logical conception of the development of these growths and is the simplest conception that includes all the essential facts. It would presuppose that in the development of the thyroid, groups of cells were being continually marked for destruction either from the survival of the fittest, or through the physiological reduction of excess factors of safety, and there is evidence that something of this nature takes place. Thus the thyreoglossal tract normally is absorbed, but it frequently persists in

goitrous districts with more or less thyroid tissue in its walls. So with the pyramidal lobe whose size and existence is directly related to the functional activity and overgrowth of the thyroid at an early period in life. In the dog the isthmus normally disappears, but in goitrous pups it usually persists.

Further, this theory would imply that these tumor-like masses functionate in proportion to the degree of differentiation and the evidence for this has already been stated.

This theory would imply that these growths took place only in early life if these cell rests normally undergo absorption as the thyroid differentiates. There is no evidence that thyroid overgrowths developing from normal glands after puberty as, for example, the overgrowths of pregnancy, menopause, exophthalmic goiter, infectious diseases, ever develop adenomas. The theory would also imply that there should be all gradations histologically from the lowest or fetal type to the highest or fully differentiated overgrowth. There are such gradations.

This conception would explain the usual occurrence of multiple tumors and often the occurrence of tumors of different physiological ages in the same gland. It would also imply that fetal adenomas are less commonly observed and simple adenomas are more commonly observed as age advances up to the age when no new tumor formations develop. There is no experimental proof as yet, but the clinical evidence tends to support these age variations.

Of objections to the modification of Cohnheim's hypothesis applied to these particular thyroid growths the strongest to my mind is the fact that similar tumors are not found in the ordinary domestic animals, and on the basis of such an hypothesis how do they escape, since their thyroids in other reactions are so similar to those of man? The same question would arise also in the case of fibromyomata of the uterus — why they should be so uncommon in the lower animals whose uteri have many anatomical and physiological attributes in common with the human uterus?

Finally the question arises, are these benign, encapsulated, epithelial growths to be considered as tumors? The physiological overgrowth of fully differentiated thyroid tissue is in no sense tumor, while the fetal adenoma lacks many of the attributes associated with the fully differentiated tissue and there is a continuous gradation between these two extremes.

If the fetal adenoma is a tumor, as most observers agree, then we must recognize different degrees of tumor, — “partial tumors,” so to speak, depending on the degree of physiological independence of the growth. On such a basis all these growths are only partial tumors since all have attributes in common with each other and in common with non-tumor thyroid overgrowths.

Of the two means at present of recognizing these tumors, (1) morphology and (2) the reaction with iodine, we would lay more stress on the more delicate and constant iodine reaction and would tentatively group as tumors all encapsulated epithelial growths which did not react with iodine in the time limits in which the non-tumor tissue reacted. We therefore recognize these growths as benign or “partial tumors,” in the sense that they are functionally only partially independent structures.

VI.

TABULATION NO. 4. ALL CASES.

Iodin per gram of dried gland in milligrams.

	Non-tumor Thyroid.	Adenoma.
I. Fetal adenomas.		
(1) Growing phase: extremes	2.78	0.31
	0.17	0.00
20 cases { mean	0.65	0.07
{ average	1.02	0.09
(2) Involutionary phase: extremes	2.18	0.69
	0.21	0.05
15 cases { mean	0.82	0.18
{ average	0.89	0.25
(3) Colloid phase: extremes	1.62	1.31
	0.14	0.32
5 cases { mean	1.31	1.07
{ average	1.02	0.94
II. Intermediate adenomas.		
(1) Growing phase: extremes	1.28	0.37
	0.75	0.08
8 cases { mean	0.22
{ average	1.01	0.23
(2) Involutionary phase: extremes	4.67	0.81
	0.38	0.15
11 cases { mean	2.14	0.41
{ average	1.93	0.46
(3) Colloid phase: extremes	1.93	1.03
	0.50	0.09
8 cases { mean	0.74	0.36
{ average	0.98	0.45

TABULATION NO. 4. — *Continued.*

	Non-tumor Thyroid.	Adenoma.
III. Simple adenomas.		
(1) Growing phase: extremes	2.14	1.63
	0.43	0.06
6 cases { mean	1.57	0.28
{ average	1.31	0.59
(2) Involutionary phase: extremes	0.54
	0.20
3 cases { mean	0.31
{ average	0.77	0.35
(3) Colloid phase: extremes	2.31	2.50
	0.06	0.18
17 cases { mean	1.00	0.52
{ average	1.08	0.65

BENIGN EPITHELIAL TUMORS OF THYROID GLAND. 261

TABULATION NO. 5. CASES NOT FED IODIN.

Iodin per gram of dried gland in milligrams.

	Non-tumor Thyroid.	Adenoma.
I. Simple adenomas.		
(1) Growing phase: extremes	0.43	0.29
	0.43	0.06
2 cases { mean		
{ average	0.43	0.18
(2) Involutionary phase: extremes	0.54
	0.20
3 cases { mean		0.31
{ average	0.77	0.35
(3) Colloid phase: extremes.....	1.34	0.77
	0.06	0.18
14 cases { mean	0.62	0.48
{ average	0.69	0.46
II. Intermediate adenomas.		
(1) Growing phase: extremes	0.37
	0.08
7 cases { mean		0.20
{ average	0.75	0.22
(2) Involutionary phase: extremes	0.54	0.79
	0.38	0.23
7 cases { mean	0.41	0.41
{ average	0.44	0.45
(3) Colloid phase: extremes.....	1.15	0.86
	0.50	0.09
7 cases { mean	0.66	0.35
{ average	0.74	0.36

TABULATION NO. 5.— *Continued.*

	Non-tumor Thyroid.	Adenoma.
III. Fetal adenomas.		
(1) Growing phase: extremes	0.96	0.31
	0.17	0.00
15 cases { mean	0.34	0.09
{ average	0.46	0.11
(2) Involutionary phase: extremes	1.11	0.69
	0.21	0.05
13 cases { mean	0.57	0.16
{ average	0.60	0.25
(3) Colloid phase: extremes.....	1.25
	0.32
2 cases { mean
{ average	0.14	0.78

BENIGN EPITHELIAL TUMORS OF THYROID GLAND. 263

TABULATION NO. 6. CASES FED IODIN.

Iodin per gram of dried gland in milligrams.

	Non-tumor Thyroid.	Adenoma.
I. Simple adenomas.		
(1) Growing phase: extremes	2.14	1.63
	1.54	0.27
4 cases { mean	1.65	0.65
{ average	1.75	0.80
(2) Involutionary phase:		
0 cases.		
(3) Colloid phase: extremes	2.31	2.50
	1.58	1.85
3 cases { mean	2.31
{ average	1.95	2.22
II. Intermediate adenomas.		
(1) Growing phase:		
1 case — average	1.28	0.32
(2) Involutionary phase: extremes	4.67	0.81
	2.14	0.15
4 cases { mean	2.69	0.47
{ average	3.05	0.47
(3) Colloid phase.		
1 case — average	1.93	1.03

TABULATION No. 6. — *Continued.*

	Non-tumor Thyroid.	Adenoma.
III. Fetal adenomas.		
(1) Growing phase: extremes	2.78	0.14
	1.19	0.00
5 cases { mean	1.46	0.07
{ average	2.02	0.06
(2) Involutionary phase: extremes	2.18	0.31
	1.34	0.20
2 cases { mean
{ average	1.76	0.26
(3) Colloid phase: extremes	1.62	1.31
	1.31	0.77
3 cases { mean	1.07
{ average	1.47	1.05

TABLE NO. 7.

Series No. Pathological No.	Autopsy or Surgical, Hospital.	Simple Adenomas.				Anatomical State of the Non-tumor Thyroid Tissue.	Iodin Contents. In milligrams per gram dried.		Remarks.
		Growing Phase.	Involution- ary Phase.	Colloid Phase.	Complication.		Non-tumor Thyroid.	Adenoma.	
H. 337. 1820 P.W.S. Female.	Surgical. Lakeside.	+			None in the tumor mass used.	Colloid, early, gland- ular hyperplasia, complicated.	0.43	0.06	Long-standing goiter with multiple adenomas. Some show extensive degenerative changes.
H. 447. 2629 P.W.S. Female.	Surgical. Lakeside.	+			None.	Colloid.	1.54	0.27	One lobe removed, several adenomas. Fed iodine. No action on tumors.
H. 508. 8285. Female.	Surgical. Lakeside.	+			None.	Colloid.	1.69	0.44	One lobe removed containing one adenoma. Undoubtedly has had iodine. No history.
H. 519. 8403. Female.	Surgical. Lakeside.	+			Hemorrhagic, cystic center.	Atrophic (tension) colloid, early, glandular hyper- plasia.	0.43	0.29	Cystic adenoma 5 x 6 cm. with small bit of original thyroid.
H. 526. 8452. Female.	Surgical. Lakeside.	+			None.	Colloid.	1.61	1.63	One adenoma 4 x 4 cm. from a lobe containing several. Fed iodine for 2 weeks.
H. 555. 8709. Male.	Surgical. Lakeside.	+			Fibrous core.	Colloid complicated.	2.14	0.85	Clinically "Graves disease." Fed iodine. Long-standing multiple adenomas.
H. 517. 8368. Female.	Surgical. Lakeside.		+		None.	—	—	0.20	Adenoma size of golf ball, enucleated.
H. 540. 8589. Female.	Surgical. Lakeside.		+		Extensive hemor- rhage, recent.	—	—	0.31	Multiple small adenomas. Extensive hemorrhage.
H. 588. Male.	Surgical. Lakeside.		+		None.	Very atrophic col- loid.	0.77	0.54	Several adenomas in the lobe removed. Entire gland enlarged.
H. 375. 1957 P.W.S. Female.	Surgical. Lakeside.			+	Calcification, old hemorrhagic cystic changes.	—	—	0.60	Old adenoma 8 x 8 cm., enucleated. General thyroid enlargement.
H. 378. 4362 G.S. Male, 13.	Surgical. Lakeside.			+	Hemorrhage, cystic changes, calcified.	—	—	0.19	Cystic adenoma 6 x 6 cm., enucleated.
H. 409. 2277 P.W.S. Female.	Surgical. Lakeside.			+	None.	Pure colloid.	2.15	1.85	Small adenoma in slightly enlarged thyroid. Fed iodine for some months.
H. 412. 2218 P.W.S. Female.	Surgical. Lakeside.			+	None.	—	—	0.48	Adenoma size of tennis ball, enucleated. Slight general thyroid enlargement.
H. 413. 2215 P.W.S. Female.	Surgical. Lakeside.			+	Hemorrhage, calci- fication.	—	—	0.48	Highly complicated goiter with multi- ple adenomas.
H. 417. 2303 P.W.S. Female.	Surgical. Lakeside.			+	Hemorrhage, cystic center.	—	—	0.38	Enucleation of large colloid adenoma.
H. 435. 2495 P.W.S. Female.	Surgical. Lakeside.			+	Highly complicated, hemorrhage, cal- cification, cyst for- mation.	Colloid.		0.52	Highly complicated, long-standing goiter with multiple adenoma.
H. 449. 2685 P.W.S. Female.	Surgical. Lakeside.			+	Cystic center.	Colloid, early, gland- ular hyperplasia, complicated.	0.38	0.23	One lobe removed, containing adenoma 5 x 5 cm.
H. 452. 4908 G.S. Female.	Surgical. German Hos- pital.			+	Cystic, calcified cap- sule.	—	—	0.23	Large adenoma 8 x 8 cm., enucleated.
H. 478. Female.	Surgical. Lakeside.			+	None.	Colloid, much lymph- oid tissue.	1.34	0.18	Clinically "Graves disease." One lobe removed. Tumor 5 x 5 cm.
H. 502. 8285. Female.	Surgical. Lakeside.			+	Hemorrhage, cyst formation.	Tension atrophy, col- loid.	0.62	0.92	Entire lobe containing large cystic adenoma. Tension atrophy of origi- nal thyroid.
H. 512. 8339. Female.	Surgical. Lakeside.			+	Calcification of cap- sule, hyaline de- generation.	Colloid, early, gland- ular hyperplasia.	0.77	0.38	Very large, long-standing goiter and multiple adenomas.
H. 513. 8357. Male.	Surgical. Lakeside.			+	Calcified, cystic.	Colloid.	1.58	2.31	Large old colloid goiter and multiple colloid adenomas. Fed iodine.
H. 523. 8437. Female.	Surgical. Lakeside.			+	Calcification and hy- aline necrosis.	Tension atrophy, col- loid.	0.6	0.77	Two large colloid adenomas in stretch- ed atrophic original thyroid.
H. 580. 8867. Female.	Surgical. Lakeside.			+	None.	Colloid.	2.31	2.50	Multiple adenomas. Fed iodine long time.
H. 582. 8862. Female.	Surgical. Lakeside.			+	Old hemorrhage, cyst formation.	Colloid.	1.23	0.54	Several encapsulated areas of thyroid tissue in large goiter. All are uni- formly colloid containing.
H. 610. Female.	Surgical. Lakeside.			+	Edema, slight hem- orrhage.	Atrophic colloid and many adenomas.	0.37	0.54	One much enlarged lobe containing many adenoma-like masses of all sizes.

TABLE NO. 8.

Series No. Pathological No. Sex, Age.	Autopsy or Surgical, Hospital.	Intermediate Adenomas.				Anatomical State of the Non-tumor Tissue.	Iodin Contents. In milligrams per gram dried.		Remarks.
		Growing Phase.	Involution- ary Phase.	Colloid Phase.	Complication.		Non-tumor Thyroid.	Adenoma.	
H. 291. 4090 G.S. Female, 30.	Surgical. Lakeside.	+			None.	—	—	0.23	Enucleation of adenoma from right lobe on account of deformity.
H. 87. Female.	Surgical. Charity.	+			Beginning cyst formation, hemorrhage, calcification.	—	—	—	
H. 142. — Male, 65.	Autopsy No. 802. Lakeside.	+			None.	Moderate glandular hyperplasia.	—	—	Dead of peritonitis secondary to operation for artificial anus. Multiple adenomas in thyroid, general thyroid enlargement.
H. 442. 2552 P.W.S. Female.	Surgical. Lakeside.	+			Practically a cyst with thin zone of adenoid tissue, subcapsular.	—	—	0.08	Tumor, enucleated, 8 x 8 cm.
H. 459. 2778 P.W.S. Male, 41.	Surgical. Lakeside.	+			None.	—	—	0.37	Old adenoma in generally enlarged thyroid.
H. 544. 8620. Female.	Surgical. Lakeside.	+			None.	Colloid.	1.28	0.32	Clinically exophthalmic goiter. Ligated superior thyroid arteries and later removed lobe. Given iodine.
H. 549. 8668. Female.	Surgical. Lakeside.	+			Cystic center.	—	—	0.20	Enucleated, orange-sized adenoma.
H. 294. — Female, 33.	Autopsy No. 981. Lakeside.		+		None.	Colloid.	2.92	0.15	General peritonitis secondary to ectopic gestation. Two cherry-sized adenomas. General thyroid enlargement.
H. 329. 1797 P.W.S. Female, 34.	Surgical. Lakeside.		+		None.	—	—	0.79	Two adenomas, enucleated, roughly 3 x 3-4.5 x 4 cm.
H. 460. 2807 P.W.S. Female.	Surgical. Lakeside.		+		Hyaline degeneration of stroma, edemas.	Colloid, early, glandular hyperplasia.	0.54	0.31	Much enlarged lobe containing an adenoma 5.5 x 6 cm.
H. 466. 2870. Female.	Surgical. Lakeside.		+		Dense hyaline scar-like core.	—	—	0.38	Thick capsuled adenoma 7 x 7 cm. Enucleated.
H. 480. 8043. Female.	Surgical. Lakeside.		+		Cystic, zone of adenoid tissue, 1-2 cm.	Colloid.	4.67	0.81	Fed iodine for long time. Moderately enlarged lobe removed.
H. 546. 8662.	Surgical. Lakeside.		+		None.	—	—	0.54	Uniform involuting adenoma, enucleated.
H. 566. Female, 34.	Surgical. Charity.		+		Slight hemorrhage, early cystic change.	—	—	0.49	Three small adenomas, enucleated.
II. 543. 8619. Female.	Surgical. Lakeside.		+		Hemorrhagic, cystic.	Atrophic colloid, early.	0.41	0.23	One lobe removed contains one large adenoma, cystic, and several smaller ones.
H. 565. 8746. Female.	Surgical. Lakeside.		+		Cystic, hemorrhage, calcification.	Colloid.	2.14	0.23	One lobe removed, slightly enlarged. Fed iodine.
H. 372. 1945 P.W.S. Female.	Surgical. Lakeside.			+	Hyaline degeneration, multiple cystic areas.	Colloid.	1.15	0.25	One lobe removed containing adenoma 6 x 6 cm. Much lymphoid tissue throughout stroma of gland.
H. 340. — Male, 55.	Autopsy No. 1007. Lakeside.			+	Calcified fibrous core in each adenoma.	Colloid.	1.93	1.03	Patient dead of arteriosclerosis and myocarditis. Symmetrical colloid goiter and two adenomas. Given potassium iodid for some time.
H. 436. 2486 P.W.S. Female.	Surgical. Lakeside.			+	Hemorrhagic, cystic, calcareous changes.	Colloid.	—	0.35	Highly complicated. Multiple adenomatous goiter.
H. 430. 2445 P.W.S. Female.	Surgical. Lakeside.			+	Extensive cysts, scars and degenerations.	Colloid, early glandular hyperplasia.	0.74	0.09	Entire lobe much enlarged. Exceedingly complex pathological changes, atrophy degeneration, tumors, etc.
H. 492. 8778. Female, 48.	Surgical. Lakeside.			+	Calcification of capsule, several hemorrhages.	—	—	0.86	Three adenomas, enucleated. Iodine for six months under my direction. Duration of adenomas over forty years.
H. 563. 8748.	Surgical. Lakeside.			+	Calcified, fibrous core.	—	—	0.38	Two calcified adenomas, enucleated.
H. 575. 8826. Female.	Surgical. Lakeside.			+	Very large follicles, slight hemorrhage.	Atrophic colloid, early glandular hyperplasia.	0.57	0.46	Old complicated adenomatous goiter.
H. 590. 8897. Female.	Surgical. Lakeside.			+	Slight hemorrhage.	Atrophic colloid.	0.50	0.18	Old multiple adenomas in generally enlarged thyroid.
H. 607. 9018. Female.	Surgical. Lakeside.		+		Colloid visible, some calcification.	Atrophic (tension) colloid.	0.38	0.41	Old long-standing goiter. Lobe contains five adenomas in different stages of involution.
H. 612. 9042. Female.	Surgical. Lakeside.	+			Very slight extravasation of blood (recent).	Atrophic colloid.	0.75	0.20	Adenoma 4 x 5 cm. Soft, gray-red friable tissue. Only one in the tissue removed.
H. 611. 9041. Male.	Surgical. Lakeside.		+		None.	Pure colloid.	2.46	0.71	Lobe enlarged. Nodule contains two adenomas, (1) 1.5 x 1.5 and (2) 3 x 3 cm.

TABLE No. 9.

Series No. Pathological No. Sex, Age.	Autopsy or Surgical Hospital.	Fetal Adenomas.				Anatomical State of the Thyroid Tissue.	Iodin Contents, In milligrams per gram dried.		Remarks.
		Growing Phase.	Involution- ary Phase.	Colloid Phase.	Complications.		Non-tumor Thyroid.	Adenoma.	
H. 3. — Female, 50.	Autopsy No. 651. Lakeside.	+			None.	Colloid.	—	—	Gland symmetrically enlarged, multi- ple small adenomas.
H. 11. 859 P.W.S. —	Surgical. Lakeside.	+			Cystic center.	Colloid.	—	—	Tumor 6 x 4 cm., cyst wall 1 mm. Zone of glandular tissue beneath capsule 0.5-1.0 cm. thick.
H. 66. — Female, 42.	Autopsy No. 658. Lakeside.	+			Early diffuse calcifi- cation of tumor stroma.	Moderate, glandular hyperplasia.	—	—	Multiple small adenomas in a slightly enlarged thyroid. Patient dead of peritonitis.
H. 239. P.W.S. Female, 35.	Surgical. Lakeside.	+			None.	Colloid.	1.19	0.14	Clinically a "mild Graves," tumor size of hen's egg in right lobe, parts of both lobes removed.
H. 240. Male, 45.	Autopsy No. 934. Lakeside.	+			None.	Colloid, senile, atro- phy, sclerosis.	1.46	0.01	Small atrophic thyroid with five pea- sized adenomas.
H. 242. Male, 68.	Autopsy. City Hospital.	+			Calcification of thy- roid arteries, ex- tensive.	Colloid, senile.	2.78	0.07	One egg-sized adenoma, several large "colloid cysts."
H. 348. Female.	Surgical. Lakeside.	+			None.	Normal, colloid.	1.92	0.00	Entire lobe removed, tumor size of golf ball.
H. 359. 1893 P.W.S. Female.	Surgical. Lakeside.	+			None.	Colloid.	2.77	0.08	Slight general thyroid enlargement. Tumor 3 x 3 cm. Fed iodine.
H. 370. 1928 P.W.S. Female.	Surgical. Lakeside.	+			Cystic center, hem- orrhagic, edema- tous.	—	—	0.07	Cystic adenoma 7 x 7 cm., enucleated.
H. 434. Female.	Surgical. Lakeside.	+			None.	Normal, colloid.	0.96	0.03	One lobe, weight 10 grams, containing adenoma 2 x 2 cm. Clinically — "Exophthalmic goiter."
H. 438. 2904 P.W.S. Male.	Surgical. Lakeside.	+			Cystic center, hya- line necrosis, cal- cification.	Colloid, early, mod- erate glandular hyperplasia.	0.34	0.14	Entire lobe removed. Cystic adenoma 5 x 5 cm.
H. 440. 4751 G.S. Female.	Surgical. Lakeside.	+			None.	—	—	0.00	Enucleated.
H. 446. 2682 P.W.S. Female.	Surgical. Lakeside.	+			None.	Tension atrophy, colloid.	0.31	0.00	Right lobe removed. Adenoma 6 x 6 cm. imbedded in lobe.
H. 454. 4913 G.S. Female.	Surgical. Lakeside.	+			None.	Colloid, early, gland- ular hyperplasia.	0.53	0.11	Fed desiccated thyroid. Adenoma 4 x 4 cm. imbedded.
H. 457. 2733 P.W.S. Male, 69.	Surgical. Lakeside.	+			Acute hemorrhage into adenoma.	Colloid, early, mod- erate glandular hyperplasia.	0.31	0.01	Right lobe removed. Recent hemor- rhage into adenoma already cystic.
H. 461. 2899 P.W.S. Female.	Surgical. Lakeside.	+			None.	Colloid.	0.77	0.18	One lobe removed, very slightly en- larged. Two fetal adenomas and much lymphoid tissue in stroma.
H. 482. 8047. Female.	Surgical. Lakeside.	+			Hemorrhage, hya- line necrosis, cal- cification.	Colloid, early, gland- ular hyperplasia.	0.38	0.18	Adenoma size of goose egg with arbo- rescent calcification of stroma.
H. 506. 8285. Female.	Surgical. Lakeside.	+			Almost completely cystic.	—	—	0.04	Enucleated large cystic adenoma and thin subcapsular zone of adenoma tissue.
H. 534. 8542. Female.	Surgical. Lakeside.	+			Cystic center, hya- line necrosis, hemorrhage.	Tension atrophy.	0.34	0.24	Large hemorrhagic cystic adenoma in an otherwise slightly adenomatous gland.
H. 536. 8586 Male.	Surgical. Lakeside.	+			Old fibrous core.	Almost complete tension atrophy.	0.17	0.31	Large hard fibroid adenoma. Non- tumor thyroid, almost wholly fibrous tissue from pressure atrophy.
H. 141. 3434 G.S. Female, 11 yrs.	Surgical. Lakeside.		+		None.	Early, moderate glandular hyper- plasia.	—	—	Right lobe removed. Adenoma 5 x 5 cm. Whole thyroid enlarged.
H. 217. 1450 P.W.S. Female, 41.	Surgical. Lakeside.		+		None.	Colloid.	1.34	0.20	Whole lobe slightly enlarged, removed. Capsule thick, stroma of adenoma is hyaline, thickened and possibly edematous.
H. 336. 1825 P.W.S. Female, 30.	Surgical. Lakeside.		+		Hemorrhage, cystic center.	Colloid, early, gland- ular hyperplasia.	0.82	0.17	Old highly complicated goiter and one cystic adenoma.
H. 377. —	Surgical. German Hos- pital.		+		Large, firm, fibrous, scarlike center.	—	—	0.05	Encapsulated old adenoma 7 x 7 cm., enucleated.
H. 380 4401 G.S. Male, 35.	Surgical. Lakeside.		+		Edematous, fibrous center.	Colloid.	—	0.07	Enucleation of tumor with a small bit of original thyroid tissue for his- tology.
H. 423. 2300 P.W.S. Female.	Surgical. Lakeside.		+		Cyst wall and sub- capsular zone of adenoma.	—	—	0.15	Enucleation of cystic adenoma con- taining much changed blood and cholesterin.
H. 465. 2845 P.W.S. Female.	Surgical. Lakeside.		+		Hyaline degenera- tion, calcified cen- tral scar, edema.	Colloid, early, gland- ular hyperplasia, tension atrophy.	0.82	0.31	Highly complicated old adenoma.
H. 484. 8084 G.S. Female.	Surgical. Lakeside.		+		None.	Colloid.	2.18	0.31	Patient was given iodine for 3 weeks before operation.
H. 514 8356. Female.	Surgical. Lakeside.		+		Hyaline degenera- tion, cystic areas.	—	—	0.31	Enucleated, 5 x 5 cm. Some colloid visible.
H. 528. — Female.	Surgical. German Hos- pital.		+		Highly hemorrhagic, hyaline necrosis, fibrotic core.	Colloid, marked ten- sion atrophy.	0.32	0.15	Entire right lobe containing adenoma 8 x 8 cm. Original thyroid stretched and atrophic about this mass.
H. 567. — Female.	Charity Hos- pital. Surgical.		+		Hemorrhagic, edem- atous.	—	—	0.46	Three adenomas enucleated.
H. 570. 8774. Female.	Surgical. Lakeside.		+		Slight fibrosis.	Stretched atrophic colloid.	0.31	0.11	Very large, long-standing, goiter and several adenomas in various phases.
H. 599. 8058. Female.	Surgical. Lakeside.		+		General hyaline ne- crosis and fibrosis, calcification.	Colloid.	1.11	0.15	Right lobe removed. Slight general enlargement. Adenoma 4 x 4 cm.
H. 600. Female, 40.	Surgical. Charity.		+		Slight hemorrhage and cyst forma- tion.	—	—	0.34	Two adenomas were enucleated from a generally enlarged thyroid; also excellent thyroglossal tract from hyoid bone to thyroid isthmus.
H. 453. 4900 G.S. Female.	Surgical. Lakeside.			+	None.	—	—	1.07	Fed iodine for 18 months. Several adenomas present in gland.
H. 488. 8178. Female, 48.	Surgical. Lakeside.			+	Cystic center.	Atrophic colloid.	1.62	0.77	One lobe removed. Moderately en- larged adenoma 6 x 6 cm.
H. 558. 8729. Female.	Surgical. Lakeside.			+	None.	—	—	1.25	Adenoma 4 x 4 cm., enucleated. No complication.
H. 521. 8414. Female.	Surgical. Lakeside.			+	Fibrous core, hem- orrhage.	Very atrophic, ten- sion atrophy.	0.14	0.32	Adenoma size of indoor baseball sur- rounding thyroid, highly atrophic.
H. 568. 8780. Female.	Surgical. Lakeside.			+	Multiple small ade- nomas.	Colloid.	1.31	1.31	Fed iodine off and on for two years. Slight general thyroid enlargement.
H. 613. 9034. Male.	Surgical. Lakeside.		+		Cystic, calcified.	Colloid, early, mod- erate glandular hyperplasia.	0.21	0.69	Adenoma 6 x 6 cm. single, cystic, with zone of adenoma tissue 1.5 cm. thick beneath capsule, calcified.

VII.

SUMMARY.

There are all gradations between strictly non-tumor, simple parenchymatous overgrowths at one end and true fetal adenomas at the other end of the series.

By comparing the percentage iodine contents of these tumors with their structure, a general relationship can be made out which is similar to that noted in the non-tumor overgrowths in that they have growing, involutionary, and colloid or resting phases.

Neither the structure of the tumor nor its iodine content bear any essential relationship to the non-tumor tissue of the same gland save that these tumors are not seen apart from a general hypertrophy or hyperplasia and therefore are not strictly independent growths. The most marked evidence of independence is seen in the fetal adenomas and progressively lessens toward the non-tumor hyperplasias.

Cohnheim's conception offers the best explanation of the origin of these tumors when one enlarges it to include the conception (1) that there are potential tumor anlagen formed at different physiological ages of the development of the main thyroid mass and (2) that the stimulus for tumor growth is the same as for that of the thyroid as a whole. These growths may tentatively be considered as "partial tumors."

[I am indebted to Profs. C. F. Hoover, W. T. Howard, George W. Crile, Carl A. Hamann, and Drs. C. E. Briggs and H. A. Becker, both for the anatomical material and for many courtesies and privileges in their clinics in obtaining these data.]

[I am indebted to Prof. G. N. Stewart, Director of the Laboratory, for his criticisms and suggestions.]

REFERENCES.

1. Zur Anatomie des Kropfes, Wien, 1849.
2. Die Krankhafte Geschwülste, 1863, iii, 13.
3. Archiv. f. klin. Chir., 1883, xxix, 1-97.
4. Johns Hopkins Hosp. Reports, 1896, i, 373.
5. Johns Hopkins Hosp. Bul., 1909, xx, 131.

6. Die Krankhaften Geschwülste, 1863, iii, 13-21.
7. Archiv. f. Physiol. Heilk., 1850, ix, 85.
8. Archiv. f. Physiol. Heilk., 1849, viii, 136.
9. Ueber den feineren Bau der Geschwülste, 1838, S. 55.
10. Müller's Archiv. f. Anat. and Physiol. u. Wissensch. Med., 1856, 144.
11. Archives of Internal Med., 1909, iv, 440, and *Ibid.*, 1911, vii, 506.
12. Archives of Int. Med., 1911, vii, 506.
13. Surg. Syn. and Obstet., 1906, ii, 121.
14. Delore. Rev. de Chir., Paris, 1903, xxii, 712-.
15. Deutsches Zeitschr. f. Chir., 1911, cxii, 368.
16. Jenaische Zeitschr., 1870-71, vi, 454.
17. Streckeisen. Beiträge zur Morphologie der Schilddrüse. Virchow's Arch., 1886, ciii, 131.

EXPLANATION OF PLATES.

PLATE XV., FIG. 1. — Normal adult thyroid. x 90.

FIG. 2. — Active hyperplasia from physiologically adult thyroid tissue. x 90.

FIG. 3. — Involution of active hyperplasia. Note relative enlargement of follicles; accumulation of colloid. x 90.

FIG. 4. — Colloid or resting state — complete involution. Note cuboidal epithelium, uniform colloid. x 90.

FIG. 5. — Growing or actively hyperplastic stage of simple adenoma. x 75.

(a) Capsule.

(b) Parenchyma of tumor.

FIG. 6. — Involutionary stage of simple adenoma. Note thin vacuolated colloid and enlarged irregular follicles with high cuboidal epithelium. x 90.

(a) Capsule.

(b) Parenchyma of tumor.

PLATE XVI., FIG. 7. — Colloid or resting phase — complete involution of simple adenoma. x 90.

(a) Capsule.

(b) Parenchyma of tumor.

FIG. 8. — Growing or actively hyperplastic stage of intermediate adenoma. x 90.

(a) Non-tumor thyroid.

(b) Capsule.

(c) Parenchyma of tumor.

FIG. 9. — Involutionary stage of intermediate adenoma. x 75.

(a) Non-tumor thyroid.

(b) Capsule.

(c) Parenchyma of tumor.

FIG. 10a. — Colloid or resting stage of intermediate adenoma, slight edema, and early hyaline degeneration of stroma. x 75.

FIG. 10b. — Colloid or resting stage of intermediate adenoma, more quiescent type. x 75.

FIG. 11. — Growing or actively hyperplastic stage of fetal adenoma. x 75.

- (a) Non-tumor thyroid.
- (b) Capsule.
- (c) Parenchyma of tumor.

PLATE XVII., FIG. 12a. — Involutionary stage of fetal adenoma. x 75.

- (a) Non-tumor tissue.
- (b) Capsule.
- (c) Parenchyma of tumor.

FIG. 12b. — Involutionary stage of fetal adenoma (myxomatous adenoma (Wölfler)). x 75.

FIG. 13. — Colloid or resting stage of fetal adenoma. Note variation in size of follicles and follicles containing full colloid content. x 75.

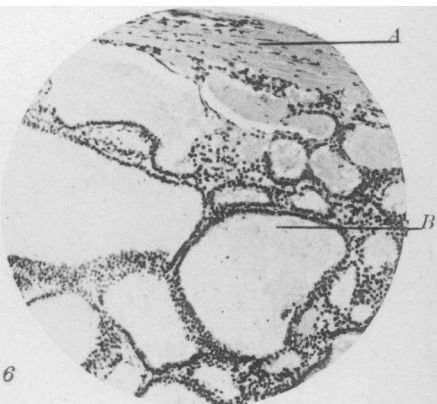
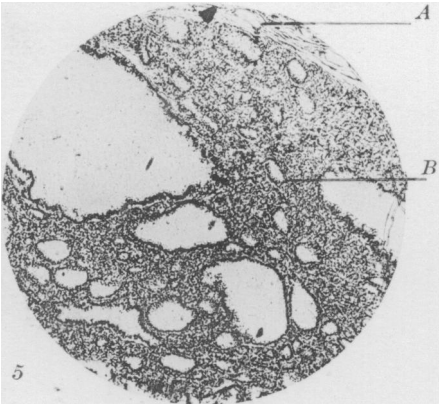
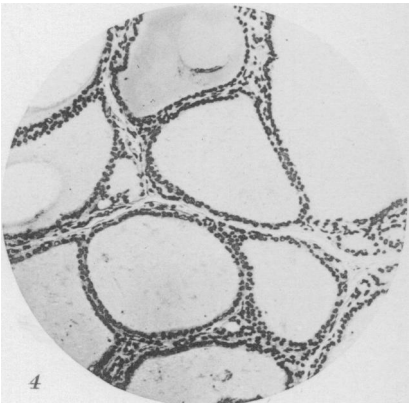
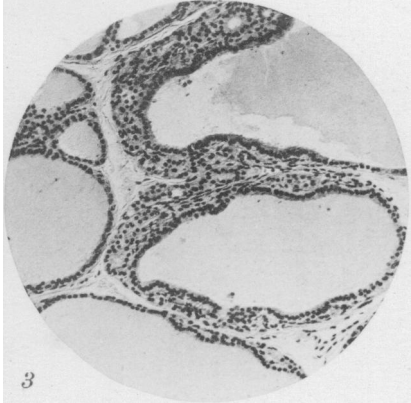
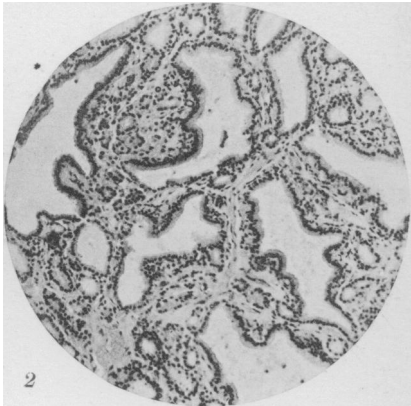
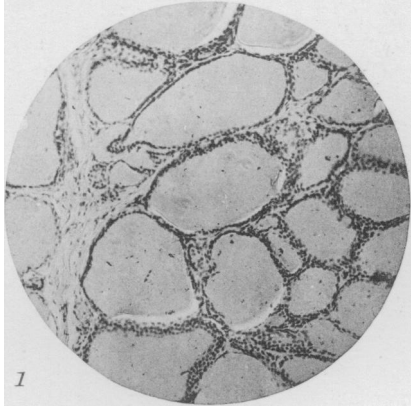
FIG. 14. — Marked hyaline degeneration of stroma with atrophy of follicles from central portion of an involutionary fetal adenoma. x 75.

FIG. 15. — Growing stage of fetal adenoma, x 75, showing:

- (a) Hemorrhage.
- (b) Atrophic zone.
- (c) Zone of closely set follicles.

FIG. 16. — Circumscribed area of thyroid overgrowth in colloid stage from a generally enlarged goitrous gland; not tumor. x 50.

- (a) Non-tumor thyroid.
- (b) Adenoma-like formation.



Marine

Tumors of Thyroid

