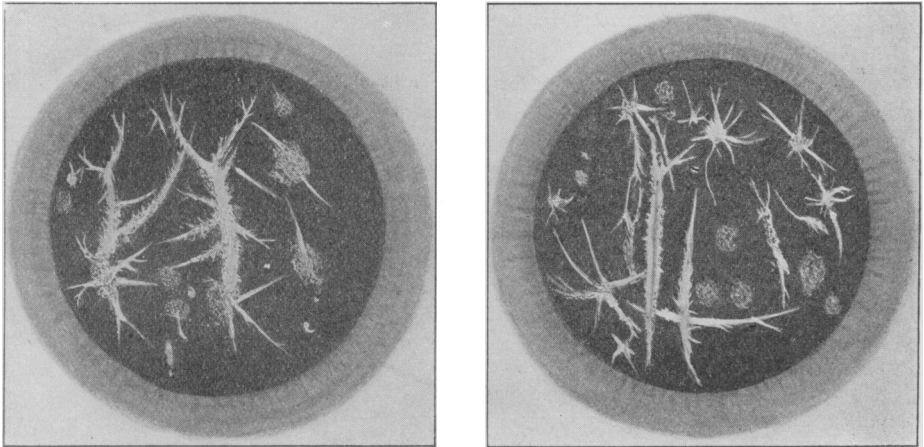


Reticular Opacity of the Cornea.

By ADRIAN CADDY, F.R.C.S.

ILLUSTRATION of case shown at the Meeting of the Section held November 11, 1927.¹

CORRIGENDUM.

Proceedings, xxi, (Sect. Ophth.), 30. By a printer's error, Dr. Kenneth Smith's degree was incorrectly stated. For "M.B., B.S.," read "M.D., B.S."

¹ For full notes of this case, see *Proceedings*, xxi (Sect. Ophth.), 12.