

ON  
FATTY DISEASES OF THE HEART.

BY  
RICHARD QUAIN, M.D.  
ASSISTANT PHYSICIAN TO THE HOSPITAL FOR CONSUMPTION  
AND DISEASES OF THE CHEST.

COMMUNICATED BY  
C. J. B. WILLIAMS, M.D. F.R.S.

---

Received January 22d.—Read March 12th, 1850.

---

THE subject of Fatty Diseases of the Heart was brought under my notice five years ago, by the sudden death of a gentleman, in whose body no sufficient explanation of that event could be found. A peculiar fatty condition of the heart was observed and recorded during the examination. The occurrence, soon afterwards, of two similar cases, led to the conclusion, that the presence of this fatty matter in the heart's texture bore some important relations to the structure and functions of the organ.

On referring to books, they were found to afford but imperfect information on the subject, and to contain very contradictory statements. The investigation, the results of which are herein comprised, was then commenced, and continued at such intervals as other avocations and the materials required permitted. Since the period referred to, the attention of other inquirers has been directed to the subject, and some most interesting and valuable essays have been published upon it. These essays, and I hope nearly all that had been previously written on the subject, I have examined with care; I have compared my own observations with their contents, when possible, and I shall with pleasure acknowledge in the course of this Essay any information thus

derived. The pursuit of the inquiry has been both pleasing and instructive to myself; and it is with the hope that the Fellows of this Society may derive the like feelings from the exposition of its results, that they are now respectfully submitted to their consideration.

The following appears to be the most convenient form for the arrangement and consideration of the subject :

- I.—*The varieties of Fatty Diseases of the Heart, and their respective characters.*
- II.—*An account of preceding observations on these Diseases.*
- III.—*A consideration of the circumstances under which they occur—their causes.*
- IV.—*Their effects on the Structure and Functions of the Heart.*
- V.—*Their Symptoms and Diagnosis.*
- VI.—*The Indications for their Treatment.*

Appended will be found Tables containing the abbreviated histories of eighty-three cases, in which fatty disease of the heart existed. Of these cases twenty-five are derived from original sources,<sup>1</sup> and the others from different publications, with additions, in several, derived from inquiries made of the authors. Drawings illustrative of the morbid conditions described are also annexed.

I.—THE VARIETIES OF FATTY DISEASES OF THE HEART, AND THEIR RESPECTIVE CHARACTERS.

There are two forms under which fat presents itself as a disease of the heart. In one of these forms the fat, composed of large cells containing oil, identical with the fat found in other parts of the body, grows upon and extends

<sup>1</sup> I have to express my most sincere acknowledgments to the kind friends whose names are appended to the several cases which they have given me. A few of the cases thus obtained have appeared in the journals from time to time since they were placed in these tables. Mr. Paget's and Dr. Ormerod's valuable cases have been published so recently, and in so distinct a form, that I have not taken the liberty of introducing any of them here.

over the surface of the heart; it then encroaches on, and insinuates itself between, the muscular fibres, in some cases to such an extent as to completely conceal them when the examination is made with the unassisted eye. In the other form of disease, a fatty matter, composed of granules and small oil-globules, occupies and fills the sheath of what was previously muscular fibre. In the one form of disease fatty tissue *grows* on and outside the fibre, in the other the muscular fibre itself *degenerates* into molecular fatty matter, (compare figures 1, 2, 3, 4, Plate III.) A distinction thus broadly marked in the anatomical characters of these two forms of disease, and in their mode of origin, requires to be clearly expressed in the designations given them. It will, therefore, be well to apply the term *fatty growth* to all cases in which fat tissue constitutes the morbid condition, even though it may encroach so far on the muscular fibres as to cause their apparent transformation into fat; whilst the term *fatty degeneration* will be limited, as in strictness it should be, to those cases in which the muscular fibre degenerates into molecular fatty matter. The necessity for this distinction will be evident as we proceed.

*a. Fatty growth on the heart.*—The fat found external to the heart's fibres consists, as already stated, of oily matter contained in cells, and is nearly identical with the fat in other parts of the body. These cells are found oval, spherical, or polygonal, the forms being dependent on accidental circumstances, and when full-sized they measure about  $\frac{1}{500}$  of an inch in diameter. The yellow tissue composed of these cells, blood-vessels, &c., is first seen, and is always most abundant in the groove between the auricles and ventricles. The distribution of fat here bears a relation, as it does in other parts, to that of the blood-vessels. Thus it first appears in the course of the primary branches of the coronary vessels, then in that of the secondary branches, that is, in the groove over the septum, which marks the boundaries between the ventricles, and lastly follows the distribution of the smaller lateral branches. These branches are more superficial over the right ventricle than over the left, hence

the right is always found first and most abundantly covered with fat. A fringe of this substance is also found at the apex of the heart and frequently around the margins of the auricles. The course of the fat has been described by Senac,<sup>1</sup> Haller,<sup>2</sup> Laennec,<sup>3</sup> M. Bizot,<sup>4</sup> M. Rokitansky,<sup>5</sup> Mr. Paget,<sup>6</sup> and others. The fat may so completely envelope the heart, that none of the muscular tissue can be seen on its external surface. A mass of fat of this nature may of itself be sufficient to oppress and embarrass the heart's action; but fat rarely exists in such abundance on the surface of the organ without insinuating itself between and encroaching on the heart's fibres. In this way the muscular parietes of the organ become thinner and thinner, until the columnæ carneæ appear to arise from a mass of fat, as they are described to do by both Laennec and M. Bizot. This state constitutes what some writers have regarded as fatty degeneration, what M. Rokitansky has called "fatty metamorphosis," but which is, in reality, nothing more in many cases than an hypertrophy of fat. In hearts or parts of hearts less affected, that is where the fat is not very abundant, simple striæ of yellow tissue will be observed lying amongst the fibres. This appearance is common in the auricles.

When portions of the heart suffering from fatty growth in a high degree are examined with the microscope, it will be found, that where the growth is most advanced, that is always the external surface, few muscular fibres can be seen, and the wide intervals between them are occupied by fat cells. (See fig. 4, Plate III.) Proceeding inwards, we find the fibres become more evident, the fat cells fewer, and finally we have the fibres beneath the endocardium with a

<sup>1</sup> *Traité de la Structure du Cœur*, 1749, vol. i, p. 187.

<sup>2</sup> *Elementa Physiologiæ*, 1757, lib. iv, sec. 3, p. 324.

<sup>3</sup> *On Diseases of the Chest*. Translated by Dr. Forbes. 4th edition; London, 1834, p. 583.

<sup>4</sup> *Mémoires de la Société Méd. d'Observation*; Paris, 1837, vol. i, p. 351.

<sup>5</sup> *Handbuch, der Pathologischen Anatomie*. Von Carl Rokitansky. Wien, 1846, band iii, p. 459.

<sup>6</sup> *Medical Gazette*, vol. ii, 1847, p. 229.

few cells lying here and there amongst them. It is deserving of attention, that the fibres, even though they are overwhelmed with fat, may still retain their organization, (see fig. 4, Plate III;) but in all cases, the course and direction of the fibres are more or less modified and distorted. Thus, then, there is of necessity neither a degeneration nor metamorphosis of the muscle, but a growth or hypertrophy of fat upon it, though in many cases some of the fibres will be found degenerated. The fibres still existing, though concealed, explain the persistence of the heart's action in those cases in which the muscular walls appear to a greater or less extent replaced by fat.

A curious appearance, sometimes presented by the fatty tissue forming little masses within the heart, should be mentioned here. These little masses appear beneath the endocardium, and are raised above the surface of the ventricle. They are in size from that of a pin's-head to that of a pea, and they have been accurately described by Lancisi,<sup>1</sup> M. Bizot,<sup>2</sup> and Dr. Peacock. I have seen these little fatty tumours in two cases. There was a considerable but not an excessive amount of fat on the surface of the heart in both these cases.

*b. Fatty degeneration of the heart's texture.*—The general characters of this morbid change will be more readily comprehended after the alterations which the fibres undergo, as shown by the microscope, have been described. When a portion of the heart thus diseased is examined, the first thing which meets the eye is a want of the transverse striæ which mark the fibres of all the voluntary, and less distinctly those of the heart amongst the involuntary muscles. When a portion of the object in which the disease has but commenced is examined, it will be observed, that in addition to the faintness with which the cross markings are seen, a number of dark small dots stud the fibres in many points, evidently situated within the fibre. A few such dottings do not appear inconsistent with a tolerably healthy state of fibre, and they are frequently found in hearts which have well performed their

<sup>1</sup> De Motu Cordis Romæ, 1728, p. 55.

<sup>2</sup> Mémoires de la Société, &c., p. 357.

functions. As the observer, however, approaches the seat of more decided disease, he finds that the cross markings have in many points disappeared, and that the black dots have increased in size and number; some of the dots are now found to be transparent in the centre, and to assume some order in their arrangement. Sometimes the centre of a fibre is occupied by a long row of opaque points, forming a continuous line in the course of the filament; sometimes two or three lines lie side by side, the dark lines being broken by transparent apertures or circles. Less frequently the lines lie transversely to the fibre. These appearances are well represented in fig. 3, Plate III. Thus may be traced, as Mr. Paget has described, the change from the particle of molecular fat, the black dot in the fibre to the large oil globule with its transparent centre. These granules and globules become more numerous, they finally occupy the whole fibre, and cause it to present the appearance well shown in fig. 2, Plate III, or in a still more marked manner by a higher magnifying power, and in a more advanced form of disease, in fig. 1, Plate IV. The fibres, then, as shown in fig. 2, Plate III, present much the appearance of, and cannot be compared to a more like object, than the tubules of the kidney, when the cells of that organ are the seat of fatty degeneration. This fat, be it remembered, is not in the ordinary fat-cells, such as are found on the surface of the heart or amongst the fibres. The fat globules placed within the fibre are much smaller, appear to have a mere albuminous envelope, and are extremely like the oil globules of milk. They often escape from the broken fibres, float as free oil globules, or lodge between the fibres, and give the appearance, as M. Rokitansky believed, of being partially placed external to them. Mr. Paget and Dr. Ormerod have fully confirmed the observation, that they are situated within the fibre itself. It will be further observed, that the diseased fibres are so friable, that they break up readily into small disunited fragments or short masses. In making a section, it is sometimes possible to obtain a small diseased point occupying two or three fibres surrounded by tolerably healthy texture. In such a specimen the whole series of

changes may be followed until we arrive at the centre, where the disease is fully developed, and where we find the fibre broken up, and the field almost entirely occupied by oil globules. The size of the globules of fatty matter rarely exceeds that of the blood corpuscles, that of the black dots may be, in the first instance, not more than one tenth of this measurement. That these particles and globules are composed of fat is demonstrated by their highly refractive properties, and by the action of ether upon them, when they have escaped from the sarcolemma. All parts of the heart's muscular fibre are liable to this change, but not equally so. Thus it is most frequently found in the left ventricle, next in the right ventricle, then in the right auricle, and least frequently in the left auricle. It is generally more evident in the columnæ carneæ, and inner layers of the muscular fibres than elsewhere. As already stated, the heart may be affected throughout, or the change may be limited to a portion of either side. Of twenty-two cases in this series, in which the seat of the disease is expressed, in ten both ventricles were affected, in eight cases the left, and in four the right.

*General appearance of a heart affected by fatty degeneration.*

When we recollect, that the firm, highly organized muscular tissue, is nearly replaced by a fluid or semi-fluid substance possessing the characters of oil or soft fat, we can readily form a correct idea of the nature of the appearances which the examination of the heart itself will present. (See Plate VI.) Thus we invariably find a change in the colour and consistence of the organ. The colour is pale, sometimes being as pale as the "palest dead leaf;" more generally it is of a yellowish brown, a buff, or muddy pink colour. This appearance is not uniform. It is generally in spots or patches, and though the whole heart may be pale, the spots being still more so, when seen beneath the endocardium, give the tissue a mottled or spotted appearance. The spots are of infinite variety of size and form, such as lines, crescents, circles, &c. They may also be seen beneath the pericardium, and in the substance of the heart. As the disease advances, the spots

run together and give portions of the heart an uniform buff coloured appearance. This appearance may be confined to a portion of the heart, the rest presenting the ordinary healthy characters. The consistence varies also. It may amount to a mere softness or flabbiness, or be such as to permit the heart to be torn like "wet brown paper." The organ then feels like a piece of wet chamois leather, or "a wet glove." In some cases the heart thus affected retains, in appearance, much of its ordinary solidity, but the tissue breaks down by pressure exactly as would a lung consolidated by pneumonia. This state more frequently occurs in hypertrophied hearts. These differences in the amount of change in the colour and consistence appear to be connected with the causes on which the diseased condition depends, when this can be referred to a local modification of nutrition—such as obstruction of the coronary arteries—a small portion only of the heart may be affected but in the highest degree. It is then that the fatty degeneration occurs to a limited extent, but in its most marked form. Such is the condition which appears to have been noticed by Laennec particularly. When, however, the origin of the disease can be referred to a more extended lesion of the nutritive function, a greater extent of the heart may become diseased, but in a less degree. In the one case we have complete and extreme fatty degeneration, in the other merely the pale soft flabby heart, which has been described as granular degeneration of the organ. Thus, then, we have two forms of degeneration of the muscular fibre fundamentally the same, and differing merely in extent and degree. Between these two forms I make no essential distinctions, save those of extent and degree. In addition to the changes of colour and consistence, we also may remark other appearances in connection with this morbid process. The fibrous character of the heart's structure even to the naked eye disappears, and in some cases the tissue resembles that of a fatty or boiled liver. In other cases, the cut or torn surface has a granular aspect not unlike that of the surface of the lung in an early stage of grey hepatization. These different appearances may be in some measure due to the greater or less



fluidity of the oily matter present, as well as to the extent and degree to which the disease has advanced. In one case which came under my notice during frosty weather, the torn surface of the fibres presented the granular glistening character of the fractured ends of a piece of steel. Varieties also in appearance are caused by the presence of a greater or less quantity of blood or its colouring matter in the heart's texture or in its cavities, by which the lining membrane may, in the latter case, be dyed of a deep purple colour. These lesser modifications do not, however, interfere with the leading characters of the disease, which are paleness, softness, peculiar mottling, and friability of the heart's texture, changes which, with the altered character of the fibres as shown by the microscope, will leave no doubt, when present, of the existence of this morbid change. These alterations must, however, in some cases be looked for with care. In those cases in which the disease is much advanced, the quantity of fat present is so considerable, that the greasy appearance is at once evident to the naked eye. The scalpel used in cutting the tissue is greased, and so is blotting paper when applied to the cut surface. In other cases, however, in which the disease is far more extended, perhaps, but less advanced, these ordinary characters of the presence of fat may be so obscure, that they may escape notice in a superficial examination, and it is this fact which has caused the disease to be overlooked in the absence of those more efficient means which are now used for ascertaining the presence of these minute changes in structure. When possible, these means (I allude to the microscope) should always be applied to the investigation of this disease. The specimens should be examined in as nearly a recent state as they can be obtained; and different portions of the heart, if soft and easily broken, or paler than natural, should be examined without reference to the existence or non-existence of spots or mottling. The pale soft flabby hearts, which have been described by many writers, are without doubt examples of this degeneration.<sup>1</sup> In all

<sup>1</sup> The nature of this softened state of the heart has been a source of considerable difference of opinion amongst pathologists. Kreysig, and M. Bouillaud (*Malad. du Cœur*, tom. ii, p. 292) connect this condition

their characters, they resemble those in which the disease has been traced with the microscope. With the view of comparing the two classes of cases, I have placed all the latter cases in a separate series. Thus we shall have of fatty degeneration, fully recognised, thirty-three cases. Of flabby soft hearts, thirty-five cases; and of fat heart, fifteen cases; in all, eighty-three cases.

I am not aware that any chemical analysis has been made of any of these degenerated hearts. It is not very necessary. The action of æther, and the refractive properties of the granules, readily testify to their nature. Moreover, the extent to which the heart is affected with the disease, rather than the degree thereof, is the measure of its effects: hence chemical analysis could give but little additional information on the subject, beyond that above stated.

with carditis, and describe a red, a pale, and a yellow softening. Hope (*Diseases of the Heart*, 4th edit., p. 310) follows M. Bouillaud, but thinks the pale and yellow varieties may sometimes occur in the absence of inflammation. Laennec (*Diseases of the Chest, &c.*, p. 565) describes this state of heart well. He says, the pale softening resembles in all respects the fatty degeneration which he also describes, save in not greasing paper. He denies the connection between this softening (in the absence of endo- or pericarditis) and inflammation, and attributes its origin to cachexia of the system. Akenside (*Philosophical Transactions*, vol. liii, p. 353) gives the history of a remarkable case, which he calls "gelatiniform softening." It occurred, as fatty degeneration frequently does, in a heart which had been the seat of former pericarditis. The subject was aged 14 years. Yet M. Chomel (*Dict. de Méd.*, 2d edit., art. *Ramolissement du Cœur*), rendering the matter more confused, states this softening, in a youth of 14, to be the same thing as that described by M. Blaud (*Bibliothèque Med.*, t. lxxviii, p. 364) as "senile softening" of the heart. One cannot read the details of the cases given by these different writers without feeling convinced that, in the majority of cases, they are describing the same thing, and that this is fatty degeneration. Every sound pathologist knows that true carditis, by itself, is excessively rare (*Meckel. Hist. de l'Academie*, vol. xii, p. 33; and *Baillie, Morbid Anatomy*, 3d edit., p. 19), if it ever occurs. In low forms of fever the heart is softened, the cohesive power of its molecular elements is diminished; the markings on its fibres are faint; and the tissue is easily crushed. It seems to me, highly probable, that all these varieties of softening, except that just mentioned, are more or less intimately connected with this fatty change in the fibre. M. Blaud, indeed, offers no other

## II.—OF PRECEDING OBSERVATIONS ON THESE DISEASES.

1. *Fatty growth on the heart.*—The older writers appear to have recognised many of the effects which have since been found connected with this condition of the heart. For example: Hippocrates,<sup>1</sup> in one of his Aphorisms, quaintly says, “Those who are naturally very fat are apt to die earlier than those who are slender.” Celsus<sup>2</sup> pointedly refers to the difficulty of breathing and sudden death to which such individuals are liable.

These effects appear, however, not to have been traced to the state of the heart in particular, a diminished capacity of the vessels for the reception of the *pneuma*, or vital spirit, being the explanation given by Galen<sup>3</sup> and subsequent writers. The discovery of the circulation of the blood, and the evident

objection to such an idea in reference to his cases, than that fat is not seen overloading the fibres. Even M. Cruveilhier (*Anat. Pathol.*, tom. i, liv. iii) is astray here. In describing “apoplexy of the heart,” he notices the fragility and discoloration of the fibres; and two of his colleagues, in whom he placed much confidence, express their belief, that the cause of this state of things is fatty degeneration. Still this eminent pathologist does not agree with them, simply because he does not believe “that fat causes fragility of the heart.” This latter opinion must now be entirely rejected. Moreover, Mr. R. W. Smith (*Dublin Journal of Med. Science*, vol. ix, 1838) compares his own specimens of fatty degeneration to this illustration of M. Cruveilhier, which is, in truth, a good representation of the disease. Thus we have sufficient evidence to show, that very erroneous ideas have existed as to the nature of this softened state of heart, and that our present view of it is likely to prove the correct one. It is curious to observe that Corvisart (*Compend. de Méd. Pratiq.*, tom. ii, p. 370), who states that he had never seen a case of fatty degeneration of the heart, in describing pale softening, suggests that this probably has been on a superficial examination confounded with fatty degeneration, the general appearance of which it resembles. The use of the microscope has now reversed Corvisart’s idea; for in all the flabby hearts which I have thus examined, fatty degeneration has been found.

<sup>1</sup> Genuine Works of Hippocrates. By Francis Adams, LL.D., Surgeon. *Denham Soc.’s edit.*, vol. ii, p. 713.

<sup>2</sup> *De Re Medica*, lib. ii, s. 1.

<sup>3</sup> See the Commentary of Dr. Adams: *The Genuine Works, &c.*; and *Methodus Medendi*, lib. xiv, c. 15.

necessity for the free and unembarrassed action of the heart, directed attention to the state of this organ in these and similar cases. Harvey<sup>1</sup> himself, in recording the appearances found in the body of Parr, describes the heart as being much covered by fat. He did not, however, as incorrectly quoted by Schœffer,<sup>2</sup> attribute the old man's death to this cause. In nearly all the systematic writers on the morbid anatomy of the heart, from the age of Harvey to the present time, cases and references illustrative of the effects of the accumulation of fat on the heart will be found. Amongst these writers may be named Bonetus,<sup>3</sup> Lancisi,<sup>4</sup> Senac,<sup>5</sup> Morgagni,<sup>6</sup> Lieutaud,<sup>7</sup> Fothergill,<sup>8</sup> Portal,<sup>9</sup> Parry,<sup>10</sup> and nearly all those who have written on the heart since the commencement of the present century. Illustrative examples, recorded by some of these writers, will be found in the Third Series of Collected Cases which accompany this communication. The fat accumulated on the heart is supposed to act mechanically, and by its pressure on the muscular fibres, on the nerves, and on the blood-vessels, to impede its function, embarrass its nutrition, and produce those effects which we shall subsequently have occasion to describe.

2. *Fatty degeneration of the heart.*—The knowledge which we possess of the nature of this important disease is of a comparatively recent date. Lancisi, whose writings on the heart, and on various subjects connected with hygiene and pathology, are deserving of more attention than they receive, evidently recognised and described this condition, when he said of fat particles, “sub formâ cinerearum macularum

<sup>1</sup> The Works of William Harvey, M.D. By R. Willis, M.D.; Sydenham Soc.'s edit., p. 590.

<sup>2</sup> Nova Acta Acad. Nat. Curios., 1761, tom. ii, p. 107.

<sup>3</sup> Sepulchretum; Lugd., 1700, lib. ii, § xi, Obs. 16, 17.

<sup>4</sup> De Subit. Mortibus, Romæ, 1707, p. 176.

<sup>5</sup> Traité de la Structure, &c., 1774, vol. i, c. iv.

<sup>6</sup> De Sedibus et Causis, &c., 1765, Epis. 3, 27, 35.

<sup>7</sup> Hist. Anat. Med., 1767, vol. ii, p. 19.

<sup>8</sup> Medical Observations and Inquiries; London, 1776, vol. v.

<sup>9</sup> Mémoires de l'Académie des Sciences; Paris, 1784.

<sup>10</sup> On Syncope Anginosa, 1799, p. 7, &c.

sparsim internas tunicas variegant.”<sup>1</sup> The “ash-coloured spots,” which are now described as characterising the disease, had evidently attracted his attention. Lancisi, however, did not look on this condition as essentially morbid. Morgagni<sup>2</sup> more nearly approaches a correct estimate of its pathological effects, when, in describing the fatty condition of the heart in an aged female who had died from rupture of the organ, he asks, “Does the fat . . . . preserve the fibres in the vessels, and their contexture very lax, and make them give less resistance to the distraction from each other, if any considerable distension be brought on?” To our own countrymen belongs the credit of having first directed attention to the nature of the disease. Dr. Andrew Duncan, jun., in an interesting communication on certain Diseases of the Heart, published in the ‘Edinburgh Medical and Surgical Journal’ in 1816, asks, “why the muscles of the heart should not become the seat of fatty degeneration as muscles in other parts of the body?” and then describes the appearance of a heart which he believed to be in this state. Dr. Cheyne,<sup>3</sup> of Dublin, soon after recorded, in the ‘Dublin Hospital Reports,’ a similar case, and referred to the “only observation” previously published, that of Dr. Duncan. Several cases were subsequently contributed to the same journal by Mr. Adams.<sup>4</sup> The specimens taken from these cases I had recently an opportunity of examining, through the courtesy of Mr. Adams. The subject seems to have been felt as one of peculiar interest by the Dublin School, and many illustrations have been furnished by the researches of Dr. Townsend,<sup>5</sup> Mr. Smith,<sup>6</sup> Dr. Stokes,<sup>7</sup> and more recently by those of Dr. Bellingham<sup>8</sup> and Dr. H. Kennedy.<sup>9</sup> On the Continent we

<sup>1</sup> De Motu Cordis ; Romæ, 1728, p. 55.

<sup>2</sup> De Sedibus et Causis, &c., Epistola 27, Obs. 2.

<sup>3</sup> Vol. ii, 1818.

<sup>4</sup> Vol. iv, 1827.

<sup>5</sup> Dublin Journal, 1832, vol. i, p. 165.

<sup>6</sup> Ibid., 1838, vol. ix.

<sup>7</sup> Ibid., 1846, vol. i, N. S., p. 491.

<sup>8</sup> Dublin Medical Press, vol. xxi, 1849.

<sup>9</sup> Ibid., vol. xxii, 1849.

find Corvisart<sup>1</sup> stating, probably a little before the period at which Dr. Duncan's observation was published, that he had not himself seen what was called fatty degeneration of the heart; but as he had heard of other observers having done so, some of the cases would probably soon be published.

Laennec,<sup>2</sup> in his work on the 'Diseases of the Chest,' devotes a chapter to "fatty diseases of the heart." In it he describes the accumulation of fat on the heart and amongst its fibres. In these cases, the fibres, he says, "may become atrophied and replaced by fat, so that the columnæ carneæ seem held together by the lining membrane only." Still this, he adds, "is not the condition which I wish to denote by the name of '*Fatty degeneration of the heart.*'" "This is an actual transformation of the muscular substance into a substance possessing all the chemical and physical properties of fat." The natural red colour of the heart is then replaced by a pale yellow, like that of a dead leaf; the tissue is soft and greases paper." Laennec here evidently refers to the true degeneration of the fibre, though he does not attempt to show the nature of the change, beyond comparing it "to the fatty degeneration of the voluntary muscles described by Haller and Vicq D'Azyr."<sup>3</sup> In fact, as fatty degeneration

<sup>1</sup> *Maladies du Cœur*, Paris; and *A Treatise on Diseases of the Heart*, &c. Translated by Hebb. London, 1812, p. 166.

<sup>2</sup> *On Diseases of the Chest*, 4th edit., p. 583. Translated by Dr. Forbes.

<sup>3</sup> Fatty degeneration of voluntary muscles has long attracted the attention of anatomists, and its characters in connection with those of the disease in question here claim our notice. This change is observed in the muscles of the aged, in unused and paralysed muscles; it seems to occur also occasionally spontaneously, or without an evident cause, in the muscles of both man and the lower animals. Vicq D'Azyr (*Œuvres*, par Moreau, tom. v, p. 365) has given in detail the results of an examination made of a paralysed lower extremity, and he refers to the observations of Aristotle, Albinus, Leeuwenhoek, Haller, and Thual on the subject. He found the fat cells situated not between the lamina (*les lames*), but in the elements of the fibre; the fibres themselves being replaced by others thinner, finer, and more analogous to ligamentous tissue. I have examined this so-called fatty degeneration of voluntary muscles in four cases:

1st. The fatty muscle of over-fed prize cattle,—that which Vicq

of the liver was long recognised before the actual changes in the tissue were described by Mr. Bowman,<sup>1</sup> so this fatty degeneration of the heart had been recognised by Laennec

D'Azyr states that Aristotle described in the 'Historia Animalium.' "*Vertitur,*" he says, "*in pingue quoties pabuli copia suppetit.*" The muscular fibres were present in this instance nearly unchanged, but everywhere covered with fat cells, which lay in rows upon the fibre.

2d. The muscles of a paralysed youth, whose case is described by Mr. Partridge (Med. Gazette, Nov. 1847, p. 944). Drawings, illustrative of the appearances shown in this case, are presented. The fibres are shown in one (Plate IV, fig. 3) overwhelmed with fat; in the other (Idem, fig. 4) the fibres remain apparently very little altered, the fat having been removed by ether.

3d. The lumbar muscles of a paralysed sheep.—The preparation had long been kept in a closed bottle. (See some Account of an uncommon Appearance in the Flesh of a Sheep. By Dr. Vaughan. London, 1813.) The soft waxy substance was composed chiefly of fat cells, of obscure granular fibres, and of other fibres composed of delicate filamentous, but strong tissue; and, lastly, where the disease had least advanced, the muscular fibres remained.

4th. The intercostal muscles taken from between the ribs of a man.—The ribs had, for a long time, been rendered fixed by an accidental injury. I found the fat cells very abundant, and the striated muscles in many points. In other parts, the fine filamentous tissue seemed to have replaced the muscular fibres. There were also some granular fibres.

From these observations I am disposed to think, that the tendency of voluntary muscles is to degenerate into a fibrous tissue mixed with fat, rather than into granular fatty matter. This observation applies to paralysed muscles; it is not improbable, that in the flabby muscles of those suffering from scurvy and other diseases of mal-nutrition, a change similar to fatty degeneration of the heart may be found. We have, however, in the heart itself a change analogous to the fibrous degeneration just described. The tissue, then, is of a fawn colour, has a firm leathery feel, and in it we find fibrous tissue, fat cells, and muscular fibres. Dr. Williams has described this fibrous degeneration. M. Rokitansky has also described this change, but he regards the fibrous tissue as unstriated muscular fibre which has been developed amongst the ordinary fibres of the heart. For further information on the fatty degeneration of voluntary muscles, consult Beclard (Anat. Générale, § 168), Mr. Paget's Lectures (Med. Gazette, vol. ii, 1847), and Mr. Hallett (Edinb. Med. and Surg. Journal, 1846, vol. ii, p. 6); also (Idem, 1849, vol. i, p. 269).

<sup>1</sup> Lancet, vol. i, 1842.

and the writers above named, before its true character was ascertained. Laennec, however, was wrong in saying that the disease proceeded from without inwards, and also that it was confined to the apex of the heart.

MM. Bouillaud,<sup>1</sup> Andral,<sup>2</sup> Grisolle,<sup>3</sup> and other French writers, seem to have adopted the views of Laennec, and to have compared this change, without inquiry, to the fatty degeneration of the voluntary muscles. The increasing accuracy required in pathological investigations, and the improved appliances for conducting them, soon rendered this ambiguous term of comparison unsatisfactory. Hence the seat of the fatty matter, and its relation to the tissue in which it was found, were examined. Dr. Williams,<sup>4</sup> whose name I cannot mention here without a respectful tribute of thankfulness, for the valuable assistance and advice which he has given me during the progress of this inquiry, as on many other occasions, states in his work on 'Diseases of the Chest,' published in 1840, that in true "sebaceous degeneration, the fatty matter is deposited in, and not on, the muscle of the organ, which thereby becomes changed in nature, and impaired in functions." Thus is marked the first step in this inquiry. In the same year, some cases fell under the notice of Dr. Peacock, with the notes of which he has kindly favoured me, and which were subsequently published in the 'Monthly Journal of Medical Science,' for 1844. In these cases Dr. Peacock describes the tissue of the heart as being pale, soft, mottled, and greasy, resembling fatty liver. The change he describes as being most evident in the interior of the heart,<sup>5</sup> the organ being destitute of fat on the surface. The microscopic examination of the tissue, showed the fibres almost or entirely

<sup>1</sup> *Malad. du Cœur*, vol. ii, p. 294.

<sup>2</sup> *Anatomie Pathologique*, 1820, tom. ii, p. 318.

<sup>3</sup> *Traité de Pathologie Interne*, vol. ii, p. 387.

<sup>4</sup> *The Pathology and Diagnosis of the Diseases of the Chest*; London, 1840, p. 279.

<sup>5</sup> The presence of fat in the internal portions of the heart's texture has been described by Dr. Elliotson, (*Lect. on Med.*, London, 1839, p. 36; and *Diseases of the Heart*, p. 32.)



deprived of their transverse striæ, and covered with small oil globules. M. Rokitansky's<sup>1</sup> more extended investigations have added greatly to our knowledge on the subject. He describes three forms of fatty disease: 1st, excessive accumulation on the surface; 2d, intrusion of fat amongst the fibres, constituting what he calls fatty metamorphosis; and 3d, degeneration of the fibre, which presents varieties, according to the extent, seat, and degree of the evil. M. Rokitansky, however, left much to be added, and something to be corrected. To Mr. Paget<sup>2</sup> the English Pathological School is indebted, for his introduction to it of the views of the last-named writer, but still more for his own more accurate and more extended investigation into the nature and anatomical characters of this morbid process; to which he has added some illustrations of one of the most striking of its effects, viz., sudden death. Dr. Ormerod<sup>3</sup> has recently followed the footsteps of his learned colleague, and greatly enhanced our knowledge of the subject, by a series of cases exhibiting the variety of circumstances under which this disease may occur. In addition to the preceding, individual cases of considerable interest have been recorded by Mr. Mead,<sup>4</sup> Dr. Hughes Bennett,<sup>5</sup> Dr. Latham,<sup>6</sup> Dr. Crisp,<sup>7</sup> Mr. Stallard,<sup>8</sup> Mr. Corfe,<sup>9</sup> and other observers, abstracts of whose cases will be found in the annexed table.

Lastly, this disease has been observed amongst lower animals. Mr. Kent<sup>10</sup> has given a description of a rupture of the heart in a mare. The right ventricle and the auricle had undergone fatty degenerations, and old adhesions of the

<sup>1</sup> Handbuch der Pathologischen Anatomie. Von Carl Rokitansky. Wien, 1842. Band iii, p. 462.

<sup>2</sup> Medical Gazette, vol. ii, 1847, Lecture vi.

<sup>3</sup> Ibid., vol. ii, 1849.

<sup>4</sup> Ibid., 1846.

<sup>5</sup> Edinb. Monthly Journal.

<sup>6</sup> Clinical Medicine; London, 1846, vol. ii, p. 169.

<sup>7</sup> Trans., Path. Soc. of London, vol. i.

<sup>8</sup> Transactions of the Provincial Assoc., 1847, vol. iii, N. S., p. 105.

<sup>9</sup> Medical Times, vol. i, 1848-49, p. 142.

<sup>10</sup> Lancet, vol. i, 1847, p. 125; and Veterinary Record.

pericardium existed. During life, the animal had exhibited several of the symptoms which characterise the disease in man. I have also received the histories of two very similar cases: one, that of a fat ox; the other, of a London dairy-cow; but it is not necessary to detail them now.

III.—A CONSIDERATION OF THE CIRCUMSTANCES UNDER WHICH FATTY DISEASES OF THE HEART OCCUR,—THEIR CAUSES.

1. *Fatty growth on the Heart.*—In every inquiry of this kind we are met by the unsolved problem, Why are certain individuals and certain parts of the body more prone to the formation of fat than others? We can ascertain, with some degree of certainty, the circumstances which will promote the formation of fat in general;<sup>1</sup> and, as the facts shown in the Table tell us, that when fat forms throughout the system, the heart will partake largely of the accumulation, we must, therefore, at present content ourselves by recollecting what the nature of these influences of extended operation is. Thus, in the first instance, we know that the material of the fatty tissue must be derived, directly or indirectly, from the blood,<sup>2</sup>

<sup>1</sup> See Obesity, by Dr. Williams (Cyclopædia of Practical Medicine; London, 1833); and Adipose Tissue, by Dr. Craigie (Cyclopædia of Anat. and Physiol.; London, 1836). And since this essay was presented, Lectures on Obesity, by Dr. T. K. Chambers (Lancet, vol. i, 1850).

<sup>2</sup> All *healthy blood contains fat*, as shown by the researches of Chevreul, Lecanu, Boudét, Trail, Christison, Babington, Davy, Simon, and others. It is found in the serum, in the fibrin, and in the globules. (See Cyclopædia of Anatomy, as quoted above, pp. 59-60: Simon's Chemistry, Sydenham Soc.'s edit., by Dr. Day, 1845, vol. i, pp. 163, 177, 188, 195.) This fat is in a diffused or saponified form, and does not admit of recognition by mere examination, as in the case of milky-looking blood. It is said, however, that in some of these cases of "fatty degeneration" the fat is so abundant in the blood, as to be seen floating in it like oil. Such is Mr. R. W. Smith's description, (Dublin Journal, vol. ix.) Dr. Stokes (Idem, vol. i, N. S.) seems to confirm the observation. Haller (Elementa Physiol.) refers to Malpighi, Glisson, and Ruysch as having observed free oil globules in the blood. Dr. Gale (Payne's Letters on the Cholera, p. 151) describes a similar appearance in the blood of persons dead of this disease. In making these observations, care must always be taken, that the oil flowing from the divided tissue and mixing with the blood, does not become a source of error.

and that the quantity of the one must bear a relation to the supply of material from the other.

Secondly, we know that the quantity of fatty matter in the blood is in direct relation with that supplied by the food on the one hand,<sup>1</sup> and on the other with the greater or less freedom which exists for the free elimination of its elements in the respiratory process.<sup>2</sup> We, therefore, feel, that if the food is deficient in the materials which readily constitute fat, and the respiratory process is accelerated and increased by abundant exercise, little fat can be formed. Equally true is the converse, that those who fare luxuriously and lead sedentary lives will grow fat. In the one case, neither the body nor the heart will suffer; in the other, in the general accumulation, the heart will certainly participate. Beyond these general principles I fear we cannot go, and even to these there are exceptions.

Thus the Table, Series III, shows, that of fifteen cases of extreme fatty growth on the heart, eleven occurred in very fat individuals, and only one in a person who is described as being thin. M. Bizot found nine fat hearts in fourteen fat females; but he also found fourteen fat hearts in twenty-nine thin females. In males, the numbers were still fewer. Such cases are illustrations of the exceptions referred to; and further illustrations, though they are somewhat more apparent than real, are found in cases of phthisis. To these it is not possible to refer now. We observe, that age marks a decided influence over the formation of fat on the heart. It is very scanty in infancy, and is rarely present in any quantity

<sup>1</sup> For observations and experiments on the presence of *fat in the blood derived from the food*, see Notes to Hewson's works by Mr. Gulliver, Sydenham Soc.'s edit., 1846, p. 35; also Simon's Chemistry, vol. i, pp. 192 and 202 (in blood of vena portæ); and also more recent experiments by M. Millon (Med. Gazette, vol i, 1850, p. 127).

<sup>2</sup> For information on the circumstances which influence *the elimination of carbon* in the process of respiration, see Simon's Chemistry, vol. i, p. 128; also on the elimination of fatty matter by the lungs, see Comptes Rendus (Juil. 1847), which contain some curious results, as to the quantity of fatty matter obtained from the lungs according as the respiratory process is more or less free.

before the 30th year.<sup>1</sup> Thus of the fifteen cases comprised in this series, thirteen were above fifty years of age, and one only under that age. Males, too, according to this collection of cases, are more liable to this excessive accumulation of fat than females, the numbers being as twelve to three. M. Bizot's observations as to sex are different from mine. He finds that females are more liable to have a large amount of fat on the heart than males; still, as his observations do not apply to this extreme condition, but to a mere greater or less quantity of fat, they can scarcely be said to be contradictory of those now enumerated.

2. *Fatty degeneration of the Fibre itself.*—In the following observations I seek to establish the fact, that the molecular fatty matter in the fibre is the result of a chemical or physical change in the composition of the muscular tissue itself, independent of those processes which we call vital.

Anatomists are well acquainted with the substance named adipocere, and with the facility with which it frequently forms in dead animal tissues excluded from the air and exposed to moisture.<sup>2</sup> Much difference of opinion has existed amongst chemists as to the origin of this substance. All admit the great quantity of fatty matter in its composition. One class, however, which includes Gay-Lussac, and Bérzelius, believes that "the compound results entirely from the fat originally present in the substance, and that the fibrin is completely destroyed by putrefaction."<sup>3</sup> The other class, which includes

<sup>1</sup> Corvisart (*Maladies du Cœur*) quotes from Kercking the case of a child whose heart seemed wanting, so great was the quantity of fat in which it was imbedded.

<sup>2</sup> Haller (*Elemen. Physiol.*, p. 29) mentions the names of Ruysch, Beecher, Bruckman, and others, as familiar with this substance. Mr. G. S. Gibbes, in a communication addressed to the Royal Society (*Philos. Trans.*, 1794-95), directed attention to the formation of adipocere, and adds that Sir Thomas Brown, in his '*Hydriotaphia*,' had described it, and also Lord Bacon in the '*Sylva Sylvarum*.'

<sup>3</sup> See Adipocere, by Mr. Brande, '*Cyclop. Anat. and Physiol.*,' vol. i, p. 56.

Dr. Thomas Thomson<sup>1</sup> and Mr. Brande, believes "that the fatty matter is an actual product of the decay, and not merely an educt or residue." The correctness of the latter opinion is shown by the following observations: A piece of this substance, obtained from the muscular part of the thigh of a horse, (portions of the specimen are in the British Museum and in that of the Royal College of Surgeons,) was submitted to examination. In its general appearance it resembles spermaceti. It is rather darker coloured and more fragile. Its surface is marked by irregular outlines of a red colour, evidently the boundaries of the fasciculi of the muscular fibres; it emits a strong ammoniacal odour, floats on water, and is nearly all dissolved in ether. The ether, when allowed to evaporate, leaves a large quantity of granular and fatty matter.

The trifling undissolved residue presents, when floating in water, a delicate flocculent appearance. Examined with the microscope, the flocculent matter is found composed of delicate filaments forming a cellular web. In some parts the filaments presented something of a longitudinal arrangement, in others the web appeared perforated by regular foramina.

A microscopic section of the adipocere itself, unacted on by any agent, (the section being made with a knife slightly warmed, required by the fragility of the substance,) showed the following appearances:—1st. Bands running longitudinally, as in the arrangement of the muscular fibres, (see Plate V, fig. 2.) These bands are dark coloured and opaque, except at the broken edges or extremities; at these points they are seen to be composed of small crystalline scales. The wavy outlines of the blood-vessels or nerves are sometimes seen between the fibres or fasciculi. In the intervals may be observed flat discs composed of radiating acicular crystals. These appearances vanished on putting ether on the specimen, and the merest particle of the filamentous substance remained.

<sup>1</sup> Annals of Philosophy, vol. ii, 1818. "The quantity of fatty matter, in this instance, was by far too great to suppose it to have pre-existed in the living body."

From these observations I conclude, that whatever be the nature of the process, the places of the muscular fibres, the blood-vessels and nerves are occupied by fatty matter, which could not have existed in them during life. This opinion is confirmed by experiments on what may be called the artificial formation of adipocere. Mr. Gibbes, whose communications to the Royal Society have been just mentioned (note, page 140), states that Lord Bacon had indicated the mode of converting the waste flesh of animals into fat, which might be used for various domestic purposes. Mr. Gibbes, acting on this idea, succeeded by different processes, including exposure to running water, to nitrous acid, &c., in converting large quantities of animal flesh, even the carcase of a whole cow, into fatty matter. The difficulty which the experimenter met with in freeing this substance from colour and smell, or his death, appears to have prevented the communication of his further proceedings, which he had promised to the Society, and neither his nor Lord Bacon's discoveries have been made useful in supplying fat from waste flesh. To the pathologist they afford information of peculiar interest in connection with the following experiments:—A little more than two years ago I obtained, for the purpose of examining the healthy structure of the tissue, the healthy heart of a healthy child who had died a few hours previously from the shock of a severe burn. Having satisfied myself on the required point, I placed the specimen in weak spirit and water (one part to eight or nine), for the purpose of future examination. On looking at the specimen after a few weeks, I found it greatly changed; it had a confused granular aspect, to such an extent, indeed, as to lead me to feel, that there must be some error in previous observations on the specimens of true degeneration, as portions of a healthy heart now exhibited characters so similar. I found, however, that this change existed in all parts of a heart, which I had no doubt had been healthy, in some parts at least, when previously examined. I mentioned the observation to Dr. Williams, and was gratified at hearing from him, that the fact of this change was an illustration of an experiment which he had suggested to his clinical assistant, Mr. Edward

Palmer, some time previously, viz., to try whether fatty matter was not formed after death by a molecular change in animal tissues kept excluded from the air but exposed to moisture.<sup>1</sup> He suggested further observations of this specimen, and some further experiments. These have been made, and the result has been, that the heart first described presents the most marked and universal character of true fatty degeneration. It is of a pale cream colour, it is soft, portions of it float in water, and when examined with the microscope exhibit the most advanced state of degeneration, differing from that which occurs during life in this respect alone,—that it is universal. Every fibre is fatty, whilst in that degeneration, which occurs during life; many fibres retain their healthy organization.

A specimen of a sound sheep's heart, placed in very diluted nitric acid,<sup>2</sup> has been traced through a series of similar changes; but as a shorter interval has elapsed, it has reached a less advanced stage. The specimens have been examined by Dr. Williams, Mr. Quekett, and Mr. Toynebee,<sup>3</sup> and others. Illustrations of the appearances presented will be found in Plate V, fig. 1. The blood-vessels and nerves participate in this change. It does not appear necessary to illustrate further the conversion of these tissues after death, external to the body, into fatty matter,<sup>4</sup>—we shall therefore turn to

<sup>1</sup> The same idea has been entertained and clearly expressed by Dr. Hodgkin, in the Seventh Report of the British Association, and will also be found in his 'Lectures on the Morbid Anatomy of the Serous and Mucous Membranes,' vol. ii, part i, 1840, p. 539. The fact of finding a fatty liver in a preparation which did not seem to be such when taken from the body, contributed to the formation of this view.

<sup>2</sup> Mr. Brande (loc. cit.) states, that "the action of very diluted nitric acid on some modifications of albumen, is also attended by their conversion into an adipoceros substance."

<sup>3</sup> Mr. Paget also kindly examined these specimens shortly before this communication was read.

<sup>4</sup> Mr. Gulliver (loc. cit.) mentions examples of the apparent conversion of albuminous matter into oil, as being noticed by Sir H. Davy, Dr. Davy, and himself. Wurtz has formed butyric acid from the decomposition of fibrin (Simon's Chemistry, vol. i, p. 79); and it is stated in Dr. Garrod's Lectures in the 'Lancet,' that Guckelberger has found the protein textures capable of affording, by their decomposition, a variety of compounds similar to those which belong to the amylaceous series.

inquire whether like changes do not occur within the body and before death. Dr. Babington<sup>1</sup> has apparently observed the formation of fatty matter in the blood at the expense of the albumen. Dr. Williams, in the first edition of his 'Principles of Medicine,'<sup>2</sup> recognises the presence "of fat in softened tubercle, pus, atheroma, and gangrene of the lungs, as being derived from the debris of animal matter, as in the conversion of flesh into adipoceros matter." In a subsequent edition of the same valuable work<sup>3</sup> further illustrations of this process, and of the circumstances under which it occurs, are clearly given. M. Rokitansky<sup>4</sup> mentions several instances in which fat may be found (as in masses of fibrin, in non vascular tumours, in the walls of arteries, &c.), in situations in which its presence could not be deemed the result of a deposition from the blood. Mr. Paget<sup>5</sup> mentions a striking example of this change observed by him in some masses of what had been medullary cancer of the liver, "certain parts of which, when examined, were found to consist almost entirely of oil globules." I have seen the same appearance in the central softened portion of a large mass of tubercle from the kidney, the fatty globules being there infinitely more numerous than in those parts where the softening had not commenced. Dr. Copland has recently communicated to me the particulars of a case of chronic inflammation of the membranes, covering the spinal cord, which caused paraplegia. The patient finally died from the paralysis extending to the muscles of respiration. After death, the recent effusion of plastic matter which existed on the upper part of the cord was found to pass inferiorly where the inflammation had first commenced and ceased, into a soft fatty matter. The same learned authority mentioned to me at the same time another case, in which the central portions of some large bands of adhesions, found in a case of chronic peritonitis, consisted of

<sup>1</sup> Cyclopædia of Anatomy and Physiology, vol. i, 1836, p. 423.

<sup>2</sup> London, 1843, p. 321.

<sup>3</sup> Second edit., 1848, p. 371 et seq.

<sup>4</sup> Op. cit., band i, Wien, 1846; and British and Foreign Med.-Chirur. Review, vol. i, 1848, p. 169.

<sup>5</sup> Lectures, loc. cit., p. 149.



fat. I find a case recorded without particular reference to this point by Dr. Archibald Hall,<sup>1</sup> in which the fibrin of a hæmorrhagic effusion into the theca vertebralis consequent on a fall was found, after an illness of some months' duration, changed into fat.<sup>2</sup> The fatty matter here formed independently of a direct connection with the vascular system, is, at least in such of the cases as have been examined with the microscope, and they have all been but the two last-mentioned, found to be in all its characters analogous to the granular fatty matter observed not only in degenerated muscular fibre, but in various other organs which are the seat of fatty degeneration. Here, then, a most important question arises,—Is the fatty matter which is found in the degenerated muscle of the heart derived from a molecular change in the texture, or is the fat deposited from the blood? In answer to this question we refer to the preceding facts. We have seen the substances analogous to muscle in composition converted both in and out of the body into this same fatty matter. We have traced also the muscular fibre itself undergoing (external to the body, and thus beyond the reach of deposition or the influence of the nutritive process), a change perfectly identical with that which it undergoes in the living body. There is, therefore, a presumption in favour of the view which holds, that the processes in both cases are identical; that, in fact, when these protein compounds, albumen and fibrin, are effused in a form which is not readily susceptible of organization, when even they enter into the composition of tissues and textures, the organization of which is imperfect from inherent depravity, from natural decay, or from a deficient supply of those elements and influences, in the absence of which nutrition fails, that in these cases I say those substances degenerate and pass into fatty matter. In other words, that when the vital power which belongs to these higher pro-

<sup>1</sup> British American Journal of Medical Science, vol. iv, p. 61.

<sup>2</sup> Senac (*Traité de la Structure*, quoted in Dr. A. Duncan's *Essay*) describes a case from Weitbrecht, in which a substance resembling lard occupied the pericardium; the result, apparently, of this fatty change in effused fibrin.

ducts of animal organization is weakened or destroyed, they yield to the physical and chemical influences which surround them, and by an inherent principle descend into a class which is shared by them in common with plants and minerals.<sup>1</sup> It would be highly interesting to illustrate this argument by facts drawn from the multitude of instances in which different observers have recently found this fatty degeneration. Some of these facts no doubt readily suggest themselves, though perhaps less in the case of the heart than in other organs. It is this organ, however, which claims our attention here. An interesting observation made by Mr. Paget supplies a most important step in this inquiry. It is now pretty well established, that a cell germ, or nucleated cell, is an essential element in the nutritive process of all tissues. The first change that can be traced in the process of degeneration of the heart's fibres, and it requires care to observe it, is the destruction of these cell germs in the tissue. Mr. Paget<sup>2</sup> writes: "When the change is least marked, and but little fatty matter has collected within the sarcolemma, the outlines of the nuclei look dim, and they lose their colour. In the further advanced stage, the nucleus of the fibre cannot be seen at all; its former place is indicated, if at all, only by some out of the narrow column of yellow granules, and in a yet later stage, or when the sarcolemma appears nearly full of fatty particles, all trace of both the nucleus and these granules is lost."

Thus we have evidence, that the nutrition of the heart is impaired, and that those powers are weakened, by which it is enabled to resist the influences which tend to the disintegration of its tissue. A review of the circumstances under which this degeneration occurs, is further confirmatory of the view adopted here. These circumstances exhibit impairment of general and local nutrition.

1. *Fatty degeneration, dependent on general or con-*

<sup>1</sup> The origin of the valuable hydrocarburet—coal from vegetable matter suggests something very analogous, in the transformation which occurs, to the formation of adipocere from animal matter.

<sup>2</sup> Lectures, loc. cit., p. 145.

*stitutional causes*, is found in persons who have suffered from a variety of exhausting diseases. Amongst the cases recorded by Dr. Ormerod,<sup>1</sup> some striking illustrations of this will be found. Of twenty-five cases, three had suffered from hemorrhage, three from phthisis, one from delirium tremens, one from cancer, two from fever. These cases are taken chiefly from hospital practice, and illustrate better than the cases which I have collected, and which are derived from different sources, the relation of this disease to general impairment of nutrition; still amongst my cases will be found several similar to those now mentioned. Thus, one is that of a child, who, having been long in bad health, died of cancrum oris; another is that of a young woman, who had suffered from long-continued gastric irritation and chronic phthisis; a third from hæmaturia. Several other examples, in which the nutritive functions were equally impaired, will be found amongst the cases presented with this communication, and which it is unnecessary therefore to refer to here. But besides this class of cases, there is another, in which we find degenerations going on simultaneously in other organs, for example in the walls of arteries, in the liver, in the kidneys, &c., giving evidence, likewise, of an imperfect nutritive function, acting widely, and shared in by the heart.<sup>2</sup> Of this state, illustrations, which more careful observation might have rendered more numerous, will be found in the tables. This degeneration of arteries, which Mr. Gulliver has long since shown to be fatty, has already been recognised by Dr. Bellingham, as being frequently associated in the form of aneurism, with this analogous condition of the heart.<sup>3</sup> And it is of considerable interest in connection with the second condition, viz. :

2. *Fatty degeneration connected chiefly with a local modification of nutrition.* In thirteen of the thirty-three cases of degeneration of the heart (Series I) the coronary arteries

<sup>1</sup> Medical Gazette, vol. ii, 1849.

<sup>2</sup> The simultaneous existence of the *arcus senilis*, or fatty degeneration of the cornea, with this affection of the heart, will be subsequently referred to as an aid to the diagnosis of the latter.

<sup>3</sup> Dublin Medical Press, vol. xxi, 1849, p. 290.

were more or less ossified or obstructed, likewise in seven of the second series, and in five of the third.

In all the cases which I have myself examined on this point (except in a case of phthisis, and some cases allied with it), I have found more or less obstruction of these vessels. I have seen the coronary artery extremely ossified, going directly to the only part of the heart affected. (See Case 26, Series I.) A nearly similar condition will be found reported as having existed in several other cases in both series. At least, arteries proceeding to the principal seat of disease, are found more or less obstructed. (See Cases 9 and 26, Series I; and cases 2 and 3, Series II.) In the last case, the coronary artery was single and ossified. This connection between fatty softened heart and obstructed arteries suggests an analogy with softening of the brain, in which a like condition of the vessel is known to exist.<sup>1</sup>

Dr. Abercrombie<sup>2</sup> has, indeed, compared this cerebral softening to dry gangrene, and he was not wrong, when the difference in the relation of the parts to external influences is remembered.

There are two causes which contribute in a marked degree to the frequent association of diseased arteries with fatty degeneration of the heart:<sup>3</sup> one of these is, that the disease of the arteries is itself an evidence of the existence of a more or less impaired state of nutrition throughout the system. The other is a fact mentioned by Mr. Swan,<sup>4</sup> in a recent communication 'On the Blood-vessels of the Heart.' It is,

<sup>1</sup> Since the presentation of this communication to the Society, a highly interesting observation has been published by Mr. Paget, showing that fatty degeneration of the small cerebral arteries exists in many cases of cerebral apoplexy.

<sup>2</sup> Diseases of the Brain.—Edinb. 1828, pp. 25 and 269.

<sup>3</sup> M. Bizot finds ossification of the coronary arteries more frequently in males than females, and rarely before 40 years of age. These facts correspond as to the sex in, and age at, which fatty degeneration most frequently occurs. He likewise found the left coronary artery more frequently ossified than the right, as the left ventricle is also more frequently the seat of degeneration than the right.

<sup>4</sup> Medical Gazette, vol. xlii, p. 751.

that there is not a free communication between the coronary arteries; that one of them cannot be readily injected from the other, hence obstructions from any cause in one, will not admit of the deficiency being compensated for by the supply from the other. Another local modification of nutrition, caused by the previous occurrence of endo- or pericarditis, is found connected with fatty degeneration. Dr. Williams<sup>1</sup> has long since observed this association; he says: "a pallid yellowish appearance of the substance due to an altered state of nutrition, is not at all an uncommon accompaniment of other lesions of the heart, such as accumulation of fat and adhesion of the pericardium connected with partial obstruction of the coronary arteries."

M. Rokitansky goes so far on this point as to say, that this degeneration "most frequently occurs in hypertrophied hearts, in combination with the remains of endo- and pericarditis." And here it might be stated, that this author<sup>2</sup> believes the fatty degeneration to depend on an impairment of the nervous power of the heart. In hypertrophied hearts he says, "the balance is lost between the nervous powers and the volume of the muscles; therefore, in those parts where a paralysis, so to speak, exists, this change occurs, as in the muscles of animal life."

This eminent pathologist seems to have overlooked a fact, which will presently be further illustrated, that the disease occurs in hearts which are unchanged, or actually diminished, in size; and secondly, if his idea were correct, all hypertrophied muscles, in which a similar loss of balance occurs, must, on the same principle, suffer in the same way. It is well known that they do not do so.

Mr. Paget<sup>3</sup> pointedly describes the effects of inflammation in producing atrophy and degeneration, not only of the heart, but also of the kidneys, liver, &c.

The mode in which the inflammation acts in these cases

<sup>1</sup> The Pathology and Diagnosis of Diseases of the Chest, 1840, p. 245.

<sup>2</sup> Loc. cit., p. 463.

<sup>3</sup> Lectures, loc. cit., p. 148.

will be found also fully discussed by Dr. Williams<sup>1</sup> in his 'Principles of Medicine,' under the head "Degenerations."

Endo- or pericarditis had previously existed in six cases in Series I, and in eleven in Series II. Lastly, it appears, that in some cases dilatation of the right side of the heart, and congestion of the coronary veins, may promote degeneration of the fibres. Thus, then, we trace the diseased state of the heart's texture to a variety of causes, all of which appear to act in the same way; that is by interfering with the supply from the blood, either in quantity or quality of those elements, which are essential to the healthy nutrition of this organ, and which should, no doubt, be in relation to the high degree of organization and vitality which its peculiar functions require. These disturbing influences we trace in all those too-familiar agencies which produce impaired health, and premature decay, as likewise in the progress of life, from natural decay. A variety of circumstances connected with the origin and progress of this disease, including the diseased condition, with which it is observed to be connected, will be found in the Tables of Cases and the accompanying Abstract (pp. 166 and 193). To recapitulate these circumstances here would be tedious and unnecessary; it will suffice to say that, in reference to *sex*, the disease is more frequent in males than females, in the proportion of twenty-four to nine (in Dr. Ormerod's cases the proportions are similar, being fifteen to seven). In reference to *age*, one individual only is under 20 years of age, four are between 20 and 30, the same number between 30 and 40, and fifteen, or nearly half, are over 60. Twelve of thirty-three cases are described as having occurred in fat individuals, and nine in those who were thin. And here it would be well to remark, that the quantity of fat on the heart itself was more than usual in twenty-one cases of thirty-three, and less than usual in four, being nearly absent in three of these. In reference to the *class in society*, in which the disease occurred, nine of thirty-three belonged to the higher ranks, eight to the middle, and sixteen to the lower; whereas, in mere fatty growth

<sup>1</sup> Principles of Medicine, 2d edition.

on the heart, the proportions are reversed : seven of fifteen belonged to the first class, six to the second, and only two to the third. Fatty degeneration and fatty growths thus contrasted are seen, in a great degree, to arise from different causes, the one is the result of an accumulation in the blood of the elements of fat, the other is the result of decay and disintegration. Fatty growth may occur alone, so may fatty disintegration ; but as both are the results of a degraded and bad nutrition, both may be often found in combination.

#### IV.—THE EFFECTS OF FATTY DISEASES ON THE STRUCTURE AND FUNCTIONS OF THE HEART.

1. *Of fatty growth.*—In a preceding part of this communication, the opinions which have been held as to the effects of fatty growth in excess on the heart, have been mentioned. These effects may be briefly enumerated, as being languid and feeble circulation,<sup>1</sup> a sense of uneasiness and oppression in the chest, embarrassment and distress in breathing, coma, syncope, angina pectoris, sudden death, rupture of the heart, &c. Thus amongst fifteen cases, difficulty of breathing was present in nine ; syncope or faintness in eight ; giddiness and coma in five ; pain in the region of the heart existed in six ; and in four of these, amounted to angina pectoris. Of the fifteen cases, fourteen died suddenly, of which ten may be said to have died by syncope, three by rupture of the heart, one by coma ; one died by disease of other organs. This catalogue of evils, in a series of cases in which no other lesion of the heart's texture is stated to exist, not even softening, save simple accumulation of fat, would suffice to place this in a prominent position as the source of very

<sup>1</sup> The impaired contractile power of the heart, and the immediate source on which this depends, cannot be more clearly expressed than in the following words of Haller, when describing the condition of the voluntary muscles in a state of "fatty degeneration." He says, "Deinde inter fibras musculosas congestus eas a se invicem ita separat ut pene evanescent, et ex parallelo situ divulsæ, inque nimis molli medio natantes vim suam contractilem desinant exercere." (Elem. Physiol., lib. i, § 4.)

serious results. But we are in this difficulty, that we are not quite sure that, in these cases, some unrecognised degeneration of the fibres did not co-exist. We shall now see, that in this latter condition, these effects occur in an equally striking degree; it will, therefore, be well, not to dwell too much on such effects, as proceeding from fatty growth alone.

2. *Fatty degeneration.*—The effects of fatty degeneration of the fibre on the structure and function of the heart might almost, *à priori*, be inferred, when it is recollected, that the firm contractile muscular flesh is more or less replaced by an inert fatty matter, and that this change represents, at the same time, impaired constitutional powers. All these effects may be comprised under these heads: *a*, Impairment of structure; *b*, Impairment of function. Many of these effects being capable of recognition during life, may be said to be symptomatic of the disease.<sup>1</sup>

A. *Effects on the structure of the heart.*—*a. The size.*—That hypertrophy of the heart and fatty degeneration are frequently associated, has been already mentioned. This condition is recorded as being present in twenty-three of thirty-three cases in Series I, and in sixteen of thirty-five in Series II. The size of the heart is stated to have been unchanged in eight cases of these two series, and to have been diminished below the natural standard in four. It is, therefore, perfectly clear, that fatty degeneration frequently occurs in hypertrophied hearts; not, I should say, as

<sup>1</sup> It should be stated, that many cases are recorded, in which patients have died, and in whose hearts this condition has been unexpectedly found. Some of these cases are said to have been previously in the enjoyment of perfect health, others have been ailing, but not in connection with the heart; others ailing likewise, and the heart being suspected has been examined, and failed to give evidence of the existence of the disease, which post-mortem examination has subsequently shown to be present. I have not met with such cases. On the contrary; even in some instances in which the individual dying suddenly was said to be in good health, I have found, on inquiry, that symptoms, more or less marked, had existed, and might have been previously recognised, if attention had been called to them.



M. Rokitsansky supposed, from a disturbance in the balance of nervous power,<sup>1</sup> but from these enlarged hearts requiring a larger supply of the materials for nutrition, which we have already seen so materially interfered with, or from the elements of which these enlarged hearts are composed, being in themselves more susceptible of change. It may be worth suggesting, whether the hypertrophy may not, in some of these cases, be the result of a natural effort to compensate for loss of power. In one case (No. 4, Series I), the heart weighed twenty-two ounces, and there was no obstruction, nor other disease, save this degeneration, which could account for the hypertrophy. The heart is said to have been dilated in six cases of Series I, in three of these in association with hypertrophy. The heart retaining its size, or being less than natural, does not call for special remark.

*b. The texture.*—The softness and fragility of the heart's tissue have already been described. They are the source of some of the severest and most fatal lesions to which the organ is liable, viz. *rupture*. This lesion will be found recorded in eight cases of thirty-three in Series I, and in seventeen of thirty-five in Series II;<sup>2</sup> or in twenty-five cases in sixty-eight. The rupture was complete, that is to say, it perforated the walls of the heart, so as to permit hæmorrhage into the pericardium in all the cases except six. One of these cases was a rupture of the septum of the ventricles; in two, there existed ruptures within the substance of the wall of the left; in one, within that of the right ventricle; in one, there was a partial rupture of the internal fibres of the right auricle; and in another, a partial rupture of some

<sup>1</sup> The only case in which I have found disease of the heart stated to be connected with disease of the nerves, is a case of softened heart, mentioned by Joseph Frank (Præleos. Med. Univ. Præcepta, vol. viii, part ii, § liv, p. 316; and Encyclographie des Sciences Méd., vol. viii, p. 188), in which the vagus nerves were diseased.

<sup>2</sup> This disproportion in these series is due to the fact, that the cases in Series I have been taken as they occurred; whilst those in Series II have generally been recorded in consequence of some peculiarity. Such, for example, as this very lesion.

fibres on the external surface of the heart. All these cases were fatal within a short period after the accident was supposed to have occurred. The narratives of the cases suggest many points of interest in connection with this lesion, which may, on a future occasion, occupy attention. It will suffice now to say, that from the time when Harvey adduced a case of rupture of the ventricle, and the effusion of blood into the pericardium, as proofs of his then much doubted theory, this accident has attracted the notice of many pathologists, and its cause has received a variety of explanations. The actual friability of the heart appears to be quite sufficient to account for the lesion in any case in which fatty degeneration can be found; and that degeneration, I find good reason for believing, exists in the greater number, if not all, the specimens in museums which I have examined, and likewise in very many of the recorded cases of this accident, besides those from which the preceding numbers are taken. Amongst the lesions resulting from a partial rupture, are some which claim separate mention. One of them is the appearance described by Cruveilhier,<sup>1</sup> as *cardiac apoplexy* (Case 2, Series II), and caused by hemorrhage into a portion of the heart's walls. One of the cases in the Table is a good illustration of this form of hemorrhage into the wall of the right ventricle, a situation in which M. Cruveilhier states it never occurs. (See Case 15, Series I.) An extremely interesting example of this disease has been recorded by Mr. Stallard,<sup>2</sup> (Case 14, Series I.) The case recorded by Mr. Stallard affords also an illustration of another appearance produced by this partial rupture and hemorrhage. It is when the accident has not been immediately fatal, the coagulum loses its colour, producing an appearance like an *encysted abscess* in the walls of the heart. These appearances have been fully noticed and described by Meriadec Laennec.<sup>3</sup> He refers to the "ingenious opinion," as he calls it, of M. Cruveilhier, that *consecutive false aneurism* of the heart may result, as no doubt it in some cases does, from

<sup>1</sup> Anat. Pathol., vol. ii, Maladies du Cœur, and livr. iii, pl. i.

<sup>2</sup> Trans. Prov. Med. and Surg. Association, N. S., vol. iii, 1847, p. 105.

<sup>3</sup> Diseases of the Chest. Translated by Dr. Forbes, 1834, note, p. 581.

these so-called abscesses communicating with the ventricle. The origin of *aneurism of the heart* is unquestionably often connected with degeneration. It may be formed in the mode just described, or by a portion of the heart more soft than the rest yielding to pressure, and bulging outwards.<sup>1</sup>

Four examples of this lesion, besides that first mentioned, will be found amongst the cases recorded here, (viz. 7, 19 and 27, Series I; and 25, Series II.) Leaving these textural changes for the present, we must now pass on to consider :

B. *The effects of fatty degeneration on the functions of the heart.*<sup>2</sup>—The most prominent of these effects are those which exhibit the deficient powers of the organ.

a. *Coma.*—Several writers have described coma, preceded or not by giddiness in connection with enfeebled powers of the circulation. Mr. Adams,<sup>2</sup> whose cases have been previously mentioned, observed as many as twenty attacks of coma in one of them. Mr. R. W. Smith and Dr. Stokes<sup>3</sup> have made similar observations. The explanation of these attacks is this, that the power of the heart is reduced, and thus it is rendered incapable of readily sending on the blood which it receives,—hence arises obstruction to the circulation and unequal pressure on the brain. The explanation is no doubt correct. Case 32, Series I, may be received as a confirmatory illustration. In this case there was much degeneration and fatty growth on the right side of the heart, the left being comparatively healthy. The right cavities were filled with blood. The patient, an old lady, had died from meningeal apoplexy consequent, apparently, on the obstruction to the free return of blood from the brain. In the Table, four of the first, and two of the second, series of cases died by coma.

b. *Syncope.*—Cardiac syncope is a term properly and more frequently used by the older writers<sup>4</sup> than by ourselves, notwithstanding the arguments of Bichat<sup>5</sup> on the subject.

<sup>1</sup> As described by Dr. Latham, loc. cit.

<sup>2</sup> Dublin Hospital Reports, vol. iv.

<sup>3</sup> Dublin Journal, vol. i, N. S., p. 491.

<sup>4</sup> Bonetus, Sepulchretum, &c.

<sup>5</sup> Sur la Vie et la Mort, art. 5.

Dr. Burrows,<sup>1</sup> in his interesting work on the Cerebral Circulation, has clearly established the fact, that syncope is due to a deficiency of that pressure within the skull which is essential to the performance of the functions of the brain. On this principle we can explain the frequency with which this symptom is found to occur in fatty disease of the heart. Numerous illustrations of the fact will be found in the Tables.

The case of an old man who fell under the notice of Dr. Williams and myself is very remarkable. I was one day suddenly called to him, and found him, as I myself and others believed, dead. He had been in his usual state, and taking his dinner a few moments previously. Though neither pulse nor respiration could be perceived, nor in a hurried examination could the sounds of the heart be heard (Case 6, Series I), I felt from something about his appearance that he was not dead. An electro-magnetic apparatus was set to work from the spine to the region of the heart; other stimuli were made use of, and after several minutes he slowly recovered. These fits, in a slighter form, recurred almost daily for two years, when he died in one exactly like the first. The heart exhibited fatty degeneration. In some cases this feeling amounts to nothing more than a sense of faintness, a feeling that the person must fall if he does not lay hold of something; and in some instances, as in a case at present under my care, this slight faintness is accompanied by an impression that he is about to die. Such persons do die. In the Table before us, death thus occurred by, as I propose to call it, *syncope lethalis*<sup>2</sup>—fatal syncope,—in thirteen cases out of thirty-three in Series I, and in eight out of thirty-five in Series II. This mode of death is in many cases instantaneous, in other cases death, though sudden, is not so rapid in its occurrence, the fatal faintness is progressive, and death may not occur for several minutes after its onset. (See Case 28, Series I.) Facts within my knowledge lead me to think, that many distinguished men have thus died, and that in this condition has lain the hidden and

<sup>1</sup> On Disorders of the Cerebral Circulation.—London, 1846.

<sup>2</sup> See Paulus Ægineta, Syden. Soc.'s edition, vol. i, p. 502; also Lancisi for Apoplexia Syncopalis. De Subit Mort, Romæ, 1707, p. 176.

frequent cause of many sudden deaths.<sup>1</sup> The paleness of the features, the unaltered state of the pupils, the absence of stertor, and the feeble action of the heart, enable us to distinguish these cases from apoplectic seizures when we see them before death. The age also at which apoplexy occurs most frequently, is not that at which we most frequently find fatty degeneration of the heart. For example, of forty-nine cases of apoplexy, forty-two occurred in persons under sixty, and seven only in those over sixty;<sup>2</sup> whereas, in seventy-nine cases of fatty degeneration of the heart, forty-one were above sixty years of age.

In the thirteen cases dead by syncope, mentioned in Series I, both sides of the heart were affected in five cases, the left side in seven, the right in one. Syncope, therefore, is connected chiefly with disease of the left side of the heart; in some of these cases the left side was flabby, dilated, and contained much blood. In two cases in which there was hypertrophy of the left ventricle, and the fatty degeneration had but little advanced, I found the ventricle rigidly contracted. It appeared as if the diseased fibres had permitted or excited an irregular action, "a spasm," in fact, "of the heart," and death by syncope from deficient pressure, equally in this case as the other, resulted.

*c. Shortness of breathing* is recorded as having been present in about one half the cases in each Series. In some cases it appears as a sense of choking or suffocation,—the person feels as if breathing through a sponge. In some instances the difficulty of breathing is so slight, that it is scarcely regarded; in others so severe, that the slightest effort, particularly in mounting ascents, is most distressing. A peculiarity was observed in two subjects, one of which still lives, viz., that reading aloud caused no inconvenience, whilst it was distressing to ascend a gentle height.

<sup>1</sup> See several cases of sudden death, the heart in each being flaccid, flabby, and its cavities empty, described by M. T. Chevalier in the Transactions of the Society, vol. i, 2d edition, 1812, p. 156. He called the mode of death *asphyxia idiopathica*.

<sup>2</sup> See Observations on Cerebral Apoplexy, by the author.—London Journal of Medicine, vol. i, 1849.

*d. Pain* is another amongst the recorded phenomena connected with fatty degeneration of the heart. It was present in twelve cases of Series I, and fourteen of Series II. In eight of the first Series, and in eight of the second, it was confined to the region of the heart. In four of each Series it extended as in *angina pectoris* more or less over the chest and down the arm. The pain in some cases immediately preceded death, and was then, in nearly all the cases, found to be connected with rupture of the fibres of the heart. There is some evidence to show that rupture of a few fibres may occasionally occur without being fatal, and cause pain; but in the majority of cases, the pain appears to be due to over-distension of the cavities with blood on the one hand, or to the spasmodic contraction just alluded to on the other, it being remembered, that though the heart in health does not possess common sensibility, it may in diseased conditions acquire this property. These latter phenomena, that is to say, syncope, breathlessness, and pain may occur separately, or two or all of them may be present at the same time; their combination gives us the characters of the disease known as *syncope anginosa*, or *angina pectoris*. The symptoms or phenomena of this disease were very well recognised,<sup>1</sup> even before Heberden<sup>2</sup> or Rougnon,<sup>3</sup> who wrote at the same time, described them as constituting a special disease. Still, from that period to the present, the immediate condition on which they depend has been a source of great doubt. It would lead us from our present object to mention all the opinions on the subject. I shall refer to but a few, and those by some of the chief writers, which appear to be directly connected with the view now presented.

1. It is said, that the phenomena may occur in the absence of any lesion of the heart which can be recognised; such was Heberden's<sup>4</sup> opinion, and such is that of many other writers. It is very easy to conceive, that fatty degeneration,

<sup>1</sup> Amongst others, see Lancisi, *De Subit Mort*, 1707, p. 46.

<sup>2</sup> *Medical Transactions*; London, vol. iii, 1772.

<sup>3</sup> *Lettre à Lorry sur une Maladie Nouvelle*; Besançon, 1768.

<sup>4</sup> *Commentaries*, 4th edit.; London, 1816.

which has been overlooked so long, and by so many, might have been present in these cases. Indeed, Dr. Forbes<sup>1</sup> anticipates some such latent condition, when he says: "It is easy to overlook slight misproportions in the different cavities, and also various morbid conditions of the muscular fibre of the heart, which may have sufficed, nevertheless, to occasion the greatest distress or disorder in the action of the organ."

2. Ossification of the coronary arteries has been regarded by Jenner, Parry, Wall, Black, Burns, Jurine, Kreysig, and others, as one of the most frequent causes of angina pectoris. We have seen the close relation which exists between this condition and fatty degeneration. Different opinions have been entertained as to the mode in which the ossification of these vessels and the symptoms were connected. Some believe that the ossified vessels acted as mere mechanical irritants; others that the nutritive function of the heart and its power were impaired by the state of its blood-vessels. Jenner, Parry, Baillie, and Hodgson entertained this opinion.

3. Fothergill attributed the disease to the simple accumulation of fat.

Lastly, Frank, Jurine, and some others connected it with accumulation of blood in the cavities of the heart and great vessels. It appears to me, from a review of these opinions, which find a connecting link in the affection of the heart's texture now described, and from the general character of the symptoms, that its phenomena may depend on any cause which can produce irregular distension, or irregular contraction of either of the ventricles, and thus, whilst it tends to disturb the circulation through the lungs, can at the same time lessen the amount of pressure which should exist within the skull. This is not the place to discuss all the causes which may produce these effects. For the present, it is sufficient to show, as has been already done, that this degenerated condition of the heart's fibres is a very sufficient source in itself of the several phenomena, (viz. breathlessness, faintness, and pain,) which are recognised under the name of *angina pectoris*, or *syncope anginosa*. Many facts in reference to the age,

<sup>1</sup> Art. Angina Pectoris; Cyclop. of Pract. Medicine.

sex, and habits of life, under which these conditions respectively occur, confirm this opinion. Lastly, in the Tables of cases, five cases of true angina in connection with this state of heart will be found, viz. Cases 13 and 15, Series I, and Cases 2, 16, and 25, Series II, and I might add a sixth, recently communicated to me by Dr. Copland. Four other cases, recorded by Fothergill and Parry, will be found in Series III. With these remarks, I conclude what I have to say on the effects of fatty degeneration of the heart, on the structure and functions of the organ. The influence of *hereditary predisposition*, and the *duration of the disease*, are points still open to future investigation. I have found nothing which bears on the former subject in the recorded cases. In one of the cases recorded by myself, a sister had died suddenly in the street, it was said of diseased heart. In another case, the father of a gentleman who is living, but in whose heart I have no doubt the disease exists, died under similar circumstances.<sup>1</sup> In regard to the duration of the disease, it is not improbable, that its progress may be rapid in some cases in which the general nutrition is greatly depraved; in other cases, however, in those particularly which occur in advancing life, it is evidently slow in its progress. Thus some cases in the Table would seem to show, that it may have existed for two, five, ten, twelve, or fifteen years respectively.

#### V.—THE DIAGNOSIS OF FATTY DISEASES OF THE HEART.

It would be a refinement at present to seek to distinguish during life between the presence of fatty growth and fatty degeneration; I shall, therefore, allow what I have to say on the diagnosis of fatty degeneration to apply to fatty growth. I have already referred (in a note, p. 152) to the fact, that fatty degeneration of the heart is said to be frequently found after death, where its existence had not been suspected during

<sup>1</sup> Since the presentation of this paper, a case of fatty degeneration of the heart has come under my notice, in which the brother and uncle died suddenly of "diseased heart." It was said on post-mortem examination, that excess of fat on the heart was the cause of death in one of them.



life, and I have expressed an opinion, that such cases would not often be met with, if a full inquiry could be made into their symptoms. I feel the truth of this observation more particularly in those cases which occur in the progress of advancing life, when, whilst the system generally keeps up its powers tolerably well, the heart suffers from some local cause, such as diseased coronary vessels. In those cases, the balance between the system and the heart is lost, and phenomena, as clear and as pointed as any that can indicate the nature and seat of disease, are developed. Again, on the other hand, in those exhausting diseases in which the heart participates, it is quite possible, that the requirements of the system may not be disproportioned to the powers of the heart, and death may come on slowly and insidiously without our attention being attracted to the state of this organ. In the former class of cases we find, as *symptoms* of the disease, various modifications of the phenomena of drowsiness, coma, faintness, syncope, breathlessness, and pain in the region of the heart, as previously described. A patient complains, in the earliest ages, of being easily exhausted, particularly by mounting heights; he feels, he says, faint, when he gets to the top of the stairs; though not giddy, he feels as if he must fall; and, though not breathless nor panting, sighs deeply, and seeks the air. Any unusual excitement, a heated or a close atmosphere, produces the same effects; at the same time, there is often experienced an uncomfortable feeling of choking, or fulness in the chest. In the intervals, the individual is pretty well. As the disease advances, the attacks become more frequent and severe, and often disturb and distress the patient at night. The temper has been observed to become irritable; in several cases, the expression of the features appears anxious, and frequently the countenance is sallow;<sup>1</sup>

<sup>1</sup> It has been recently demonstrated by Mr. Canton, that the *arcus senilis* of the cornea is a fatty degeneration of this texture. Dr. Williams has observed, that this appearance is very frequently associated with the phenomena here described as characterising the presence of fatty degeneration of the heart; and in one deeply interesting case, at the post-mortem examination of which I assisted, the diseased condition of the heart, to the

œdema of the legs, and copious perspirations from very slight causes, appear amongst the associates of the disease. The pulse is generally affected, but the mode in which it is so depends no doubt on the part of the heart affected, and on the extent and degree of the disease. Irregularity is one of its most frequent alterations, weakness is another, slowness a third. They are mentioned respectively, as having been noticed, seven, five, and four times in Series I; and, six, nine, and four times in Series II. The pulse is described as being regular only five times in the three series, never as being strong. It is mentioned as being full (three times), once as being hard, and once wiry and small, in a few cases as being quick or easily excited. In general, weakness, irregularity, and slowness<sup>1</sup> of the pulse, are the characters which we most frequently find. The irregularity may not be constant; I have seen it present during the slight attacks above described. I have seen it disappear altogether while the patient was in tolerable health, to return, as the effect of any depressing

diagnosis of which the state of the cornea contributed, was most marked. Mr. Canton has further informed me, that he has constantly observed the degenerated condition of the heart in the cases of well-marked *arcus senilis*, which he had an opportunity of examining. (See also the 'Lancet,' vol. i, 1850, p. 561.) Thus, then, when the signs and symptoms of fatty degeneration of the heart are present, this appearance of the cornea will greatly aid in the diagnosis. It must not, however, be forgotten, that fatty degeneration of the heart may occur under circumstances and at an age when we would not expect to find this lesion of the cornea; so likewise, but in a much less degree, we may expect to find the change in the cornea independently of change in the heart. Dr. Williams attributes the arcus to the pressure of the lids on the upper and lower margins of the cornea. The shape and mode of formation confirm this idea.

<sup>1</sup> The slowness of the pulse is sometimes quite remarkable. In one case (No. 6, Series I), the pulse was as slow as twenty-four in a minute when the patient was lying down, and never above thirty-two. There is an interesting communication by Dr. Stokes in the 'Dublin Journal,' August 1846, p. 73, in which he seeks to show the connection between slow pulse and disease of the aorta, or its orifice. I am disposed to think that the soft, flabby, feeble, if not fatty, state of the heart, which was present in all his cases, is more intimately connected with the state of the pulse than the aortic disease, which does not appear to have assumed a constant or uniform character in any of the cases.

cause, the more marked because that cause may be far too inefficient to affect a sound heart. As the disease advances, the symptoms become more marked, the various effects of languid and feeble circulation show themselves; angina pectoris is perhaps fully developed, or the patient is cut off suddenly by some one of the effects connected either immediately or remotely with the lesion itself. Of the eighty-three cases comprised in the three Series, sixty-eight died suddenly! The *physical signs* which characterise the disease are few, but very distinct in some instances. They are a feeble impulse of the heart, proportioned to the extent and degree of the disease; a feeble first sound, scarcely audible in some cases; and when the heart is enlarged, there is extended dullness. M. Rokitansky suggests, that disease of the columnæ carneæ may cause imperfection in the action of the valves with which they are connected, and thus give rise to a murmur. In two cases, the second sound is said to have been feeble or imperfect. This, it appears to me, may depend on the dilatation and fulness of the ventricle, preventing a perfect action of the semi-lunar valves. Taking these symptoms and physical signs together, and ascertaining at the same time the absence of other causes which may produce some more or less like phenomena, we can, I am satisfied, generally form a very correct diagnosis as to the presence of the disease.

#### VI.—THE TREATMENT OF FATTY DEGENERATION OF THE HEART.<sup>1</sup>

We have no evidence to show, that we can restore muscular fibres which have been destroyed; all, therefore, that we can hope for in these cases, and that not always, is to arrest, or

<sup>1</sup> On the treatment of fatty growth on the heart, I have nothing to add to those general principles which may be founded on the causes which produce the disease as already described, p. 138. See, for the effects of alkalis, 'Dict. de Méd. et de Chir. Pratiq.,' art. *Obesité*, by M. Roche; and also, Dr. Fothergill, on the Effects of Abstinence &c., 'Med. Observ. and Inquiries,' vol. v; and the article "Obesity," by Dr. Williams, 'Cyclopædia of Practical Medicine.'

suspend for a time, the progress of the disease by improving the quality of the blood, and thus supporting the vigour of those portions of the heart still uninjured. The nervous powers being at the same time strengthened, and the blood itself rendered a better stimulant. The effect of treatment calculated to promote these objects is often very striking. I have found attention to the digestive organs, in the first instance, useful; bitter tonics, with alkalies, and subsequently iron in different forms, seemed to act most advantageously. I need not, in a communication already so prolonged, enumerate the habits of life, change of air and scene, dietetic regulations, &c., by which the general health, and with it the part most in need of it, may be improved. In reference to some of the symptoms, I might mention, that I have seen in two or three cases great relief from pain experienced by the repeated application of three or four or more leeches over the region of the heart, followed by a blister. In one case, which I saw with Mr. James W. Ilott, of Bromley, some short time ago, attacks of distressing angina ceased for several months, (when the patient died of another disease,) after the application of leeches three or four times, and the internal use of iron. Exercise has recently been recommended in the treatment of these affections. The patients cannot take it, if it were desirable that they should do so. If exercise can be taken in the early stages of the disease, it should always be short of producing fatigue. Case 19, Series II, illustrates the ill effects of over exercise, even as a curative agent. Cases 23 and 25 show in a different way the dangerous effects of over-exertion. It may well be borne in mind, that narcotics are given with risk in these cases. One death occurred after an accustomed dose of morphia; another during the inhalation of chloroform. On the other hand, it is needless to indicate the usefulness of antispasmodics in these cases during paroxysmal attacks.

Such, then, are the chief results of my investigation on the subject of fatty diseases of the heart; and on looking back at the catalogue of evils which we have traced in connection with a disease which has hitherto almost escaped

observation, I cannot help saying, with one of our illustrious predecessors,<sup>1</sup> “Vides novum exemplum humanæ calamitatis! ubi insons blandus pinguis humor . . . tam diros, tam mirabiles, tam insanabiles morbos, mortem-que tandem ipsam produxit.”

In concluding these observations, I have to apologise for the length to which they have extended, and to plead the importance of the subject itself, as well as its numerous relations. I trust that the difficulty of doing justice to such a subject in an essay, even of this length, will be found a sufficient explanation of such imperfections as it contains, and that these imperfections will be attributed to this cause, and not to any want of zeal on my part, in rendering it worthy of acceptance by this distinguished Society.

<sup>1</sup> Boerhaave. *Atrocis rarissimique morbi historia altera.*

SERIES I.—Containing the abbreviated histories of Thirty-three cases of Fatty Degeneration of the Muscular Tissue of the Heart.

No.	Record.	Sex.	Age.	Previous history.	Cause or mode of death.	State of the heart.	Remarks.
1.	Dr. Peacock, Edin. Journ. of Medical Science. 1844.	M.	48	A horsekeeper, of intemperate habits, was suddenly seized with great prostration, constant vomiting, coldness of the extremities, and died in eighteen hours.	In a state of prostration.	Pericardium adherent. The heart enlarged, and much covered with fat. Fatty degeneration of the muscular parietes of both ventricles. The fibres being studded with oil-globules, and the striae being absent or scarcely traceable. There existed an aneurism of the ascending portion of the arch of the aorta, communicating with the right auricle by two openings, each the diameter of a large bougie, and surrounded by a belt of granular lymph.	In the other organs there was nothing very peculiar. The pylorus was contracted.
2.	Idem.	F.	29	Died whilst labouring under an attack of pleuro-pneumonia. No further history had been kept.	Pleuro-pneumonia.	The heart weighed 11½ oz. No fat externally. The walls of L. V. were mottled, and in some parts of a pale yellowish-brown colour. The musculi pectinati of R. V. and columnæ carneæ of L. V. were of a pale clay colour. No trace of striae of the muscular fibres, which were converted into fatty matter. The tissue was greasy and resembled an advanced stage of fatty liver.	The liver large and fatty. The spleen pale. The kidneys large, pale, and greasy looking. No tubercles in the lungs.
3.	Idem.	F.	30	Suffered from dyspnœa on exertion, from slight jaundice, and dropsical symptoms. Dullness more extended than natural in the region of the heart, and a murmur with the first sound.	Comatose.	The condition of this heart similar to the last. The presence of fat, and the change in the muscular fibres, were distinctly followed. No blood in the cavities.	Liver large and fatty. The kidneys mottled. No tubercles in the lungs.

4. Dr. R. Quain, M. 1845.	55	Of sedentary occupation, and subject to palpitations for ten years. During the last two years of his life the heart's action was irregular—not constantly, but particularly after going upstairs. For four years had occasional pain at one spot near the apex, this point was tender on pressure. Dyspnoea very distressing during last nine months of his life. Urine bloody and albuminous. Anasarca. Signs of hypertrophy. No murmur. Death from exhaustion.	Heart large (estimated at 18 or 20 oz.) Atheromatous Little or no fat beneath the pericardium. Deposits in the Left V. hypertrophied, and its cavity dilated. L. A. dilated—much dark-coloured coagula in both. The R. V. not much dilated nor hypertrophied. Much black blood in both R. A. and R. V. No valvular disease. Orifices all free. The muscular substance felt firm, but was pale, mottled with spots of a lighter colour, which, when examined with the microscope, were found composed of granular fatty matter.
5. Idem. 1845. M.	60	A gentleman, very stout, declined going on the outside of an omnibus, not feeling well. He got inside, his head was observed to droop, and he died instantly.	Much fat under the integuments. Rather more serum than usual within the skull. Lungs healthy.
6. Dr. Williams and Dr. R. Quain, 1845.	84	A tailor, very thin and feeble; complained of weakness, cough, and shortness of breathing. Extended dullness existed in the region of the heart, also feeble impulse: first sound not loud, second distinct. He was seized one day with a singular attack of syncope, from which he was with difficulty aroused by the use of the electro-magnetic apparatus. He had two or three fits in the course of the week following, less severe. His pulse, whilst under observation, did not exceed 32, and was as low as 24. After two years he was	The heart weighed 17 oz., and was covered with yellow fat. Its substance soft, of a pinkish-yellow, mottled hue, and its cavities contained bloody and fibrous coagula, more in left than right. Atheromatous deposits on the mitral valve, in the coronary arteries, and along the aorta. The transverse stræ were obscurely seen, and there was much oily matter in the tissue.

No.	Record.	Sex.	Age.	Previous history.	Cause or mode of death.	State of the heart.	Remarks.
7.	Mr. Meade, Med. Gaz., vol. xxxviii, 1846.	M.	88	seen again—he had been constantly subject to the same kind of fits. He was now much feebler, and died in one of them. A very fat old gentleman had for two months before his death complained of cough, and weakness—his pulse full, but jerky. On the morning of the day he died, he had walked half a mile to church, and back. He died suddenly, after getting into bed.	Rupture of the heart.	The pericardium covered with fat. The muscular substance degenerated, and (towards the apex of L. V.) of a dirty-yellow colour; soft, and quite fragile. The lower part of the ventricle had bulged out, so as to form a sort of pouch. The internal membrane and muscular substance having given way previously to the pericardium having done so. There was a rupture here (at the back of L. V.) about three quarters of an inch in length. Mitral and aortic valves ossified.	The Lungs healthy. No free fat noticed in the blood.
8.	Mr. Crisp, Pathol. Soc. of London, Nov. 1846.	M.	73	Had been treated for diseased prostate. He complained of pain and uneasiness in the region of the heart,—experienced relief, and died suddenly, after six hours.	Rupture of the heart.	L. V. hypertrophied. Adipoceros matter mixed with the fibres. Rupture through the back part of L. V.	Liver granular.
9.	Dr. R. Quain, 1846.	M.	72	A gentleman, very corpulent, had in consequence of an accident taken limited exercise for the last twelve years. He had long suffered from stricture of the œsophagus. For the last two years he slept badly, was restless, irritable, and complained of pain in the lower part of the chest. His tongue dry and brown. His pulse full, regular, not strong. During a few weeks preceding his death, he felt	Rupture of the heart.	The heart weighed 18 or 20 oz., and was loaded with fat. The muscular substance of a pinkish-yellow hue, very soft and friable. Spots of mottling appearing under the lining membrane. The muscular fibres had undergone, over the greater part of the L. V., fatty degeneration, and also in the right, but to a less extent. A rupture across the fibres in posterior wall of L. V., about three quarters	Body very fat. Limbs less so. Liver large, coarse in texture.



10.	F. Mr. Key and Mr. Woolaston.	<p>feebleness, and in walking a short distance was obliged to stop frequently, as if for breath. The heart's sounds were both feeble, particularly the first. His pulse was intermittent at the last. He died during the night, having gone to bed in his usual state.</p> <p>Of irritable temperament. Suffered principally from headache, and languor of the circulation. Her complexion was sallow, and she frequently complained of being "bilious." She died in a moment.</p>	Syncope.	<p>of an inch long—internally it was circular, about a quarter of an inch in diameter, and situated between the muscular bands. The wall here was eight lines in thickness. A large branch of the coronary artery, leading to the rupture, was almost entirely obliterated by ossific deposit.</p> <p>The heart small, and much covered by fat. Its tissue pale, soft, and exceedingly friable. The fibres had undergone fatty degeneration.</p>	<p>Liver about the usual size, presented the characters of cirrhosis in a moderate degree.</p>
11.	M. Mr. Cadge.	<p>A physician, retired from practice, fat, robust, general health good; of sedentary habits. Complained of uneasiness in the region of the heart, which led him to say that he would die from heart disease. On going up stairs, after breakfast, he fell down insensible,—his breathing oppressed, but not stertorous. He died in eleven hours.</p>	Coma.	<p>Heart large, and somewhat loaded with fat. Muscular structure softened, fatty, and easily torn, of a leaden hue, more resembling boiled liver than muscular tissue. The coronary arteries extensively ossified throughout their whole length.</p>	<p>No appearance of disease in the brain.</p>
12.	M. Dr. Latham, Clinical Medicine, vol. ii, 1846, p. 169.	<p>Crippled for several years, by the effects of gout. Never intemperate, now abstemious, but fat. He had severe pain for two or three days across the chest,—his pulse, as usual, hard and incompressible. The pain continued next day,—heart's impulse extended. The pain ceased for three days, then returned more violent than previously. He was pale, cold, heart's action regular, murmur for the first time</p>	<p>After eighteen hours' suffering, by rupture of the septum.</p>	<p>The heart, larger than natural, was encased in fat, chiefly at the right side. The muscular substance thin and flabby, but retaining its colour and character. The L. V. dilated and hypertrophied, the muscular substance healthy, whilst that of the septum had undergone fatty degeneration, and in it there was a rent an inch and a half long at the left side, and a point merely at right side, the ventricles thus</p>	<p>Interior structures loaded with fat.</p>

No.	Record.	Sex.	Age.	Previous history.	Cause or mode of death.	State of the heart.	Remarks.
13.	Dr. Peacock, 1846.	F.	60	A nurse, had cough, and remarkably characteristic symptoms of angina pectoris. The heart's sounds were not well pronounced. Pulse very feeble; irregular. She died in a paroxysm.	Syncope. Anginosa.	The coronary arteries were pervious, but contained atheromatous deposits.	Aorta extensively diseased.
14.	Mr. Stallard, Trans. of Provincial Association, vol. iii, N. S. 1847, p. 105.	M.	60	An inmate of a workhouse, short, thick-set, of florid complexion, was suddenly seized, whilst at work, with coma, cyanosis, and great prostration. Pulse full, feeble, 60. Respiration slow. Heart's sounds feeble. He was next day better, remained so for two days, and was then found dead.	Sudden.	The heart was increased in size, and loaded with fat, particularly at the right side. The muscular substance had undergone fatty degeneration in a marked degree. It was most evident towards the inner surface of the L. V., and amongst the musculi pectinati and columnæ carneæ of the right side. The tissue was quite soft in the wall of L. V. Beneath the lining membrane of R. V. were some portions of pure fat. The coronary arteries were extensively ossified and obstructed.	Cavities of pleura contained dark coloured serum. The organs presented the appearance of a sented the pleura contained bloody, purulent-looking fluid, mixed with blood. Liver soft. Kidneys contained dark-coloured, fibrinous material, and some of these communicated with the cavity. The coronary arteries were much ossified.

15.	Dr. R. Quain, 1847.	M.	47	A tailor, of temperate habits, had for several years complained of pain in the region of the heart; being worse than usual one evening, he sought advice from a surgeon, who gave him some ether, with a view of relieving "angina pectoris." He walked home, felt better, but was found dead next morning.	Sudden. Cardiac apoplexy.	Considerable amount of fat on the surface of the heart. No enlargement. Fatty degeneration of both ventricles, but chiefly of the upper part of the R. V. Effusion of berucleous blood in the degenerated tissue. Ossification and diminution of the caliber of the right coronary artery.	Body not fat. Brain not diseased. Old tuberculous disease of lungs. No disease of the abdominal organs.
16.	Mr. Savage, Provincial Medical and Sur. Journ., 1847, p. 131.	M.	Aged	Of intemperate habits. No symptoms appear to have preceded death, which occurred suddenly after walking.	Rupture of the heart.	Heart enlarged—coated with fat. The muscular fibres degenerated, having lost their cross markings—fat in abundance. Rupture through lower part of L. V. in front—coronary arteries ossified.	Body fat; the liver enlarged.
17.	Mr. Sankey, Pathological Soc., June 1847.	M.	44	Had been ill for five days, and then admitted to the Fever Hospital. His complexion sallow; slight anasarca, petechiæ, relaxed bowels. Death on the fifth day.	Not stated.	Enlarged. Spots of fatty degeneration in both ventricles.	Slight em- physema of the lungs. Some ulcers in the colon. Kidneys healthy.
18.	Mr. Corfé, Med. Times, Dec. 9, 1848.	M.	50	Stout, well formed, had been in good health, but complained one morning of slight pain across the abdomen, which he thought to work off in running stones after paviers. He reeled, fell, and died, after being two hours at work.	Syncope. (?)	All the chambers contained dark fluid blood—the whole organ was dilated in its cavities—the L. V. dilated to half its natural capacity. The walls of L. V. pale, soft, flabby, friable; the cavity collapsed when laid open, as did also those of the right.	Congestion and ecchymotic spots on several parts of the ali- mentary mem- brane.
19.	Dr. Jenner, Med. Gaz., Dec. 15, 1848.	M.	70	Of intemperate and indolent habits. Two years before his death was suddenly seized one evening with a sense of faintness, dyspncea, &c. He had a similar attack next day,—then relief. His pulse was irregular for several months (if not longer) before his death,—stated to have	Coma.	The left ventricle thickened from deposit of fat on its surface, presented the characters of fatty degeneration. There was a well-marked aneurism at its apex. The degenerated texture appeared spread out on and then lost on the walls of this small sac. Atheromatous deposit on the	

No.	Record.	Sex.	Age.	Previous history.	Cause or mode of death.	State of the heart.	Remarks.
20.	Dr. Beck.	F.	24	<p>had suppression of urine, and this to have been the cause of coma.</p> <p>Stout, of bustling habits, suffered from oppression at the chest and difficulty of breathing, having sometimes to stop when walking and gasp for breath. After an easy confinement, suffered from symptoms of peritoneal inflammation, for which she was bled to the extent of 10 oz. in a sitting posture without feeling faint: felt better during the day. She died the same night suddenly.</p> <p>Very corpulent, sedentary, temperate. Suffered from shortness of breathing, vertigo, and frequent faintings. Pulse small, regular. Complained one summer-day of great heat, and of distress in breathing. In half an hour afterwards he was found dead in a chair.</p>	Syncope.	<p>valves, no appearances of inflammation having previously existed.</p> <p>Much fat on the surface of the heart.</p> <p>Substance soft, discoloured, of a brown-paper colour, mottled on the inner surface nitis. Liver and —seen to be infiltrated with fat, when examined with the microscope.</p>	Evidence of general peritonitis. Liver and kidneys fatty.
21.	Dr. Waters.	M.	72	<p>Suffered from shortness of breathing, vertigo, and frequent faintings. Pulse small, regular. Complained one summer-day of great heat, and of distress in breathing. In half an hour afterwards he was found dead in a chair.</p> <p>Appeared to have been in good health, lived regularly, more confined to an office for some time before his death than previously. He died suddenly whilst inhaling chloroform previously to the extraction of a tooth. "The quantity of chloroform could not have exceeded twenty minims."</p>	Syncope.	<p>Enlarged—cavities dilated, particularly the left ventricle, and full. The muscular substance pale, soft, with spots of "fatty degeneration." Coronary arteries healthy (?).</p>	Liver enlarged: nothing particular in the other organs.
22.	Idem.	M.	22	<p>Appeared to have been in good health, lived regularly, more confined to an office for some time before his death than previously. He died suddenly whilst inhaling chloroform previously to the extraction of a tooth. "The quantity of chloroform could not have exceeded twenty minims."</p>	Sudden.	<p>The heart about the ordinary size—not particularly fat on the surface. The muscular substance pale and flaccid. The tum cavities contained clots of dark grumous blood. Wall of L. V. thin and "inter-verged greatly enlarged with fatty degeneration." Mitral valves unequal at the edges, and rugose. Some roughness on inner surface of aorta.</p>	Abdominal pained: fat-omen-tum contained much fat. Liver greatly enlarged, and in a state of fatty degeneration. Vessels of brain congested. Other organs healthy.

<p>23. Dr. R. Quain, M. 1848.</p>	<p>60</p> <p>A clergyman, very irritable, had suffered for several years from disease of the urinary organs, his urine generally abundant, occasionally contained a little albumen. Accustomed to take a small dose of morphia every night to relieve pain. One night, after his usual dose, retired to his room, and was found on the following morning dead in his chair.</p>	<p>Syncope (?)</p>	<p>Not much fat on the surface. Six oz. of bloody serum in the pericardium. Left ventricle hypertrophied and firmly contracted. Fatty degeneration of the co-lumne carnee, and probably of other parts of the ventricle. The left auricle contained some blood—the right cavities much more. The coronary arteries were not examined.</p>	<p>Nothing in the brain to account for death. The kidneys enlarged, contained cysts. The liver soft and mottled. Some crystalline scales obtained from the blood were believed to be urea: the prostate enlarged. Bladder much thickened.</p>
<p>24. Dr. Peacock, M. Proceedings of the Pathological Soc., 1849.</p>	<p>32</p> <p>An intemperate man: had suffered ten or twelve years before his last illness from rheumatism. Six or seven weeks before his reception into hospital, he was stated to have had another attack. When seen he was sinking; he was delirious or semi-comatose at intervals: had urgent attacks of difficult breathing, and was dropsical. Dullness extended over the heart's region, double murmur at the base. Died comatose.</p>	<p>Coma.</p>	<p>Old lymph on the pericardium. Heart weighed 16 oz. One of the aortic semi-lunar valves destroyed, and the fibrous portion of the septum almost perforated. Signs of recent as well as old pericarditis. Fatty degeneration of the fibres of both ventricles.</p>	<p>Kidneys in a state of advanced disease.</p>
<p>25. Dr. Parkes and Mr. Cadge, 1848.</p>	<p>54 (?)</p> <p>A porter, temperate, not fat, had for fifteen years suffered from winter cough. Last two winters worse, and he suffered from extreme dyspnoea; also from faintings. His pulse then slow (30), irregular, and</p>	<p>Syncope.</p>	<p>Larger than natural, and rather more than usually covered with fat. A white patch over right V. and A. The walls of the ventricles were soft, friable, and interspersed with yellow spots, which proved the</p>	<p>Rather more serum than usual in the ventricles of the brain.</p>

No.	Record.	Sex.	Age.	Previous history.	Cause or mode of death.	State of the heart.	Remarks.
26.	Mr. Avery and Dr. R. Quain, 1849.	M.	76	<p>unequal. These symptoms became worse; his pulse permanently and remarkably feeble and irregular; and any exertion brought on the faintings. There were signs of moderate emphysema and of slight enlargement of the heart. The first sound was short; both sounds low and muffled, sometimes remarkably so. He dropped dead suddenly. (Dr. Parkes.)</p> <p>A well-proportioned man, of regular habits, not fat; was known to have suffered much from distress in breathing, and was found dead on a door-step, a short distance from his home. Marks of a blister on his chest.</p>	Rupture of the heart.	<p>Serum and coagula, exceeding a pint and a half, were found in the pericardium. The heart about the usual size, with the ordinary amount of fat on the surface. The muscular substance <i>everywhere healthy</i> in colour, &amp;c., <i>except at the back of the left ventricle, where there was a large fawn-coloured patch</i>, close to the septum, extending upwards, from the apex towards the base. Through the substance of this patch, a rupture of the tissue had occurred, implicating some of the muscular bands at the apex. <i>The fawn-coloured tissue presented marked degeneration of the fibre, and the coronary artery leading directly to it was extremely ossified.</i> (Dr. Quain.)</p>	<p>to be oily particles. The fibres, so far as Lungs emphysema recognised, had lost their strise, and were sematous. Aorta studded with atheroma. Right kidney and the right coronary artery especially contained two large cysts. Both kidneys otherwise healthy.</p>
27.	Dr. Fletcher, Provincial Medical and Surgical	M.	44	Thin, nervous, active in business. Seized with severe pains across the chest, which extended to the back, and slightly to the arms, with a distressing sense of suffocation.	Sudden.	The heart dilated, but not hypertrophied. Much fat over R. ventricle. Fatty degeneration, with disappearance of the transverse striæ in the muscular fibres of the gans.	Nothing very remarkable in the other organs.

Journal, 1849, p. 606.	<p>location. His pulse and the heart's action then excessively irregular. These fits recurred at frequent intervals, with some modification, for eight days, when he died suddenly. In the period between the fits, he was free from suffering; his pulse regular (74). Nothing peculiar in the heart's sound.</p> <p>A stout man, of an anxious expression, temperate in eating and drinking, more sedentary in his habits last few years of his life than formerly, and stouter last five. (One of his sisters died, at 48, suddenly, in the street.) Healthy, save attacks of bronchitis. Last eighteen months has felt frequently a sensation of faintness or sinking; and, on any excitement, felt violent pain in the chest, and down the left arm. Sweated profusely on any exertion, and at night. Died suddenly, having complained of pain across the umbilicus. He remained conscious during the few minutes which preceded death, the pulse becoming gradually fainter.</p>	<p>L. V. On the internal surface of the apex of this ventricle, the muscular substance was softened and disorganized, and it contained a clot, firm and fibrinous (<math>\frac{1}{2}</math> oz. in weight), such as is found in an aneurismal sac. Both coronary arteries diseased and contracted.</p>	
28. Mr. West and Dr. R. Quain, 1849.	<p>Syncope. (?)</p>	<p>The heart enlarged, dilated, especially L. V., and much covered with fat. The muscular substance of L. V. (much less of skin. Ossified right) soft, flabby, of a dull, brownish-red colour, mottled with buff-coloured spots, in which fatty degeneration was clearly traced. Both sides of the heart contained some blood, the quantity not ascertained. Both coronary arteries much obstructed by deposits.</p> <p>Right kidney soft, enlarged, contained a good deal of granular matter. Nothing remarkable in brain or liver.</p>	<p><math>1\frac{1}{2}</math> inches of fat beneath the ossified deposits in aorta. Left kidney much atrophied; a large calculus in its hilus.</p>
29. Dr. Parkes, F. 1850.	<p>Out of health for some time. Had cough and enlarged cervical glands; then suffered from cancrum oris, implicating the whole of the left side of the face. She died on the sixth day, a partial separation of the slough having occurred. Pulse quick, not irregular.</p>	<p>The whole muscular substance of the heart studded with buff-coloured specks, and bronchial seen beneath the endocardium and in the parietes. The buff-coloured spots were found to consist of oil-globules, within the sarcolemma. The heart otherwise healthy.</p>	<p>Recent fibrinous deposits in the spleen.</p>

No.	Record.	Sex.	Age.	Previous history.	Cause or mode of death.	State of the heart.	Remarks.
30.	Dr. Lankester, 1850.	M.	34	A carpenter, of temperate habits, had long suffered from a variety of symptoms of a nervous character. He was frequently seized with a sensation of faintness and giddiness, accompanied by palpitation and a sensation of choking in the throat. Pulse slow and small, often as if about to stop, but easily quickened by any excitement. Subject to profuse perspiration on exertion, and at night. He died suddenly, whilst drawing a truck.	Rupture of the heart.	Heart about the usual size, and well covered with fat. Pericardium filled with serum and coagula. The walls of all the cavities attenuated, particularly those of right auricle. Through the walls of this cavity, across the fibres, a rupture, $\frac{1}{4}$ of an inch in length, had occurred. Fatty degeneration of the fibres of this auricle and ventricle was found in several spots. The left cavities were not examined.	The other organs were healthy.
31.	Dr. R. Quain, 1850.	F.	26	A servant, had for many years suffered from dyspepsia. Two years before her death she had profuse, dark-coloured hæmoptysis. Subsequently, symptoms of tubercular disease presented themselves, and became chronic. She was thin naturally, and did not lose much flesh. Menses irregular and scanty. Dyspeptic symptoms continued. A month before her death, she complained of great distress in breathing on exertion. In the week following, she daily or nightly experienced an attack of faintness, giddiness, and sense of suffocation. Having spent the day as usual, she found herself at night very faint, lay on the bed, and died "as if in a sleep."	Syncope.	The heart of good size, as a whole, and no scarcity of fat on the surface. Inner layer of muscular tissue of the L.V. was of a dull red or buff colour. It presented throughout an early stage of fatty degeneration. The tissue of R. V. was thin, of a tawny colour and leathery feel; was also degenerated. The right auricle and ventricle filled with coagula.	The body thin. The lungs presented all the characters of chronic phthisis. The liver large and fatty-left kidney large, pale, and soft. Other organs healthy. (The heart alone was obtained for microscopic examination.)
32.	Dr. R. Quain, 1850.	F.	65	A lady extremely fat, lived temperately, but took very little exercise in consequence	Apoplexy.	Heart large, covered with fat, particularly the right side, where the fat	meningeal apo-



<p>of a painful bunion. Suffered from an attack of liver disease six months before her death. Frequently complained of "spasmodic pains in the stomach." She suffered from difficulty of breathing and from headache, and for a few days before her death from a dull pain in the region of the heart. She died suddenly after some slight exertion.</p>	<p>A lady had long suffered from shortness of breathing (always worse when weakened from any cause), supposed by practitioners who had previously seen her to be due to dyspepsia. In the autumn had suffered from slight illness, with a feeling of discomfort in left side. In the middle of December, whilst walking against a cold wind, was seized with, and suffered subsequently for three weeks from, pain in the left side, palpitation, dyspnoea, and a feeling of hurry and uneasiness, with flatulent distension. The pulse irregular, extremities cold,—signs of moderate hypertrophy, with loud systolic murmur beneath the left breast. She suffered from sickness and faintness at the close; had several attacks of syncope, in one of which she died.</p>	<p>Syncope.</p> <p>The heart increased in size rather, and more than usually covered with fat. Fatty degeneration in the fibres of the right ventricle. Evidences of old endocarditis in the left ventricle,—the cordæ tendinæ of anterior lamina of mitral valve being destroyed. There were deposits of fibrous tissue, like firm lymph, in the walls of the left ventricle, near the apex. Mixed with this, and in many of the muscular fibres, were particles of molecular fat. The tissue of both ventricles was of a pale tawny colour, and all the cavities contained blood. There was an effusion of recent lymph to a slight extent in the internal and external surface of the posterior wall of the left auricle.</p>
<p>had greatly intruded on its walls. The plexus was found fibres were traced with the microscope, in the head: buried in the fat. This ventricle and the chest small. auricle were filled with coagula. The Old tubercles muscular fibres were in several points de- in the lungs. generated, so also in the L. V.; this was The liver large comparatively empty, it felt firm, the and soft—cal- right soft and flabby. Atheromatous culi in gall bladder, which was ulcerated. The kidney large and soft, and contained much granular matter.</p>	<p>The other organs could not be particularly examined.</p>	

33. Dr. Williams and Dr. Young, 1850.

SERIES II.—*Containing the abbreviated histories of Thirty-five cases in which the tissue of the Heart is described as being pale, soft, flabby, or friable, with more or less deposit of fat on the surface.*

No.	Record.	Sex.	Age.	Previous history.	Cause or mode of death.	State of the heart.	Remarks.
1.	Dr. Wade, Med. Obs. and Inquiries, vol. iii, 1767, p. 69.	M.	52	Having led an active life, he became indolent. Was attacked with hæmoptysis, and then had difficulty of breathing and of swallowing. Pulse slow, but excitable. His breathing was rendered distressing by any movement, but he could read aloud or call out without inconvenience. Subject to giddiness in the head. He became restless, anasarous, and died under an aggravation of his preceding symptoms.	Gradual.	Much fat in the anterior and posterior mediastina. The heart was buried in external fat, the muscular substance flaccid and withered.	No remarkable external corpulence. Abdominal viscera loaded with fat. Liver large. Probable duration five years.
2.	Mr. Hodgson, Diseases of the Arteries, 1815. Case 8.	F.	70	A corpulent lady had for six years suffered from difficulty of breathing. In 1811 she had an attack apparently apoplectic. The difficulty of breathing then increased. She had constant pain under the sternum, a small intermitting pulse, and syncope on the least exertion. Six months after the attack above mentioned, she felt intense pain in the region of the heart—her breathing hurried and difficult; she died suddenly after eighteen hours.	Rupture of the heart.	The heart abounded in soft fat. Its muscular fibres attenuated and flaccid, more especially at the seat of a rupture situated on the anterior surface of the left ventricle near the apex. This was an inch in length internally, a quarter of an inch externally. The coronary artery distributed to the left side of the heart was obliterated by ossification.	The lungs healthy.
3.	Idem. Case 6.	F.	Elderly.	Had suffered from palpitations, irregular action of the heart, vertigo, and swoonings. She died suddenly.	Sudden.	The heart small. The muscular substance of a pale brown colour, and so soft as to be easily torn by the finger. The coronary artery (there was but one) was extensively ossified.	—

4.	F. Dr. Duncan, Edin. Med. Sur. Journ., vol. xii, 1816, p. 59.	22	Attacked with rheumatism and symptoms of pectoral disease. Relief of the former in ten days. Persistence of the cough; expectoration, and great pain in the region of the heart. Dyspnoea on any exertion. Relief. Return of the symptoms in an aggravated form, with inability to lie down. Anasarca, quick pulse. Death in little more than a month after the return.	Exhaustion.	Evidences of old and recent pericarditis, pericardial surfaces being adherent. The heart larger than usual, was covered with lymph. Under this two thirds of the heart's walls were converted into a substance having the physical properties of condensed fat. The remaining third had almost lost its muscular appearance. Mitral valve beset with ossifications.	The lungs healthy. Marks of chronic pleuritis.
5.	M. Fischer en Hufeland's Journal, der Pract. Heilkunde, Decem. 1819.	68	Having been a prey to profound grief, whilst walking was seized with intense pain at the epigastrium, this extended to the region of the heart and left shoulder—had intermissions and increased severity. Pulse irregular—death on the fourth day. The left arm had been "numbed" for last two days of life.	Rupture of the heart.	Pericardium covered with fat. A thick layer surrounded the base. The tissue of the heart pale and soft. A rupture in left ventricle, which was in length one and a half inch externally, and about half an inch internally.	Muscles of the body generally softer than natural. The viscera were healthy.
6.	M. Mr. Adams, Dublin Hosp. Reports, vol. ii, 1827, p. 396.	68	A man of full habits; in consequence of distress in breathing and cough was unable to use exertion. Oppressed by stupor; his breathing irregular, his pulse 30. Subject to repeated attacks of coma (no paralysis) and stertor, cedema of the feet, and final aggravation of these symptoms.	Sudden, in a state of coma.	The walls of right and left ventricles, and the septum, were almost entirely composed of fat, which showed in spots beneath the lining membrane. The muscular tissue of L. V. not more than a line (lung seemed in thickness (resembled liver) was soft and easily torn. Much fluid blood in the heart—aortic valves rigid.	Some fluid beneath the membranes of the brain. Left ventricle seemed soft and impervious to the air. Liver seemed healthy.
7.	F. Idem, p. 402.	60	A lady of corpulent habit was seized with pain at the epigastrium, which continued for twenty-four hours. She was seized with vomiting; when this ceased she sighed and expired.	Rupture of the heart.	The heart unusually loaded with fat, and the muscular substance remarkably soft. A rupture one inch in length in anterior wall of L. V.	Much subcutaneous fat. Liver enlarged and irregular on the surface. Gall bladder contained six calculi—one in the mouth of cystic duct.

No.	Record.	Sex.	Age.	Previous history.	Cause or mode of death.	State of the heart.	Remarks.
8.	Mr. Adams, Dublin Hosp. Reports, vol. ii, 1827, p. 403. Idem, p. 443.	M.	—	Marked apoplectic symptoms, was bled and had an issue inserted. Died in a week after in the water-closet.	Rupture of the heart.	The whole surface of the heart was coated with fat. The muscular substance soft and flabby. A rupture in anterior and upper part of L. V. Vessels of heart healthy.	Brain, &c., sound.
9.		M.	68	A physician living freely had, during ten years, been subject to attacks of syncope. Had a cough for six weeks, and was then seized with pain and numbness in the region of the heart. No pulse to be felt in the right arm,—very weak in the left. Then not to be felt anywhere. His breathing oppressed. Restlessness came on. After seven weeks, died in a state of stupor.	In a state of stupor.	Large, flabby, and of a yellow colour, from fatty deposit. All the cavities distended with fluid blood. Aortic valves ossified, and the coronary arteries most extensively so.	Slight œdema of legs—slight old pleurisy of right side. Probable duration ten years. Mr. Adams considers that partial paralysis of the heart consequent on impaired nutrition connected with the coronary artery may have been the cause of the chief symptoms in this case.
10.	H. Simeons Heidelberg Klinisch Annalen, 1827.	F.	50	Her father syphilitic. Herself of a scrofulous habit, and very subject to rheumatism. Sleepless—easily fatigued. Subject to faintings. Pulse frequent—regular. A sense of burning heat internally, (within chest?) Lividity of hands and face. Feeble pulsation of the heart. Aggravation of these symptoms and death.	In a state of exhaustion.	Adhesions between the pericardial surfaces. Two thirds of the substance of the heart's walls were formed by a fatty substance of a dirty yellow colour.	Adhesions of the spleen enlarged.

<p>11. M. Cruveilhier, <i>Anat. Pathol.</i>, vol. i., Liv. iii., Planche i., 1827-36.</p>	<p>F. Aged. An aged inhabitant of the Salpêtrière, presented for some years the signs of dilatation, with hypertrophy of the heart, and died suddenly.</p>	<p>Sudden, by cardiac apoplexy.</p>	<p>The substance of the heart paler than natural, and more fragile. A rupture of some fibres in the substance having taken place, the change as spots of hemorrhage are seen constituting fatty degeneration, but a cardiac apoplexy."</p>	<p>physician in whose opinion he placed confidence, declared it to be so. M. C.'s objection to this is merely, that "as fat does not cause fragility of the heart, this could not be a fatty degeneration," an opinion which is contrary to facts.</p>
<p>12. Idem, vol. ii.</p>	<p>F. 75. Died suddenly.</p>	<p>Rupture of the heart.</p>	<p>The L. V. hypertrophied. The tissue fragile and yellowish, as if infiltrated with of the calf pus. A perforation in L. V. at one inch fatty and very from the apex. "M. Bergeon considered similar in appearance to the case of fatty degeneration."</p>	<p>The muscles of the calf and very fatty and very similar in appearance to the heart.</p>
<p>13. Idem.</p>	<p>F. — Had a fall three days before death, and was never well subsequently.</p>	<p>Rupture of the heart.</p>	<p>Hypertrophy of the L. V. Fragility and yellow discoloration at the seat of rupture, one inch from the apex in front. Fibrous deposits in posterior wall of L. V.</p>	<p>—</p>
<p>14. Dr. Townsend, <i>Dub. Journ.</i>, vol. i, 1832, p. 165.</p>	<p>F. 90. An inmate of a workhouse, and in the enjoyment of good health. At 88, she fractured her thigh, but recovered. Died suddenly two years afterward whilst at chapel.</p>	<p>Rupture of the heart.</p>	<p>Heart loaded with fat. Substance pale, soft and flabby. A rupture rather larger on inner than on outer surface, through anterior wall of L. V., at one inch from the apex. Coronary arteries diminished in diameter by deposit.</p>	<p>—</p>

No.	Record.	Sex.	Age.	Previous history.	Cause or mode of death.	State of the heart.	Remarks.
15.	Idem, p. 166.	M.	84	An inmate of a workhouse, after a life of activity. Had good health, with the exception of occasional pain and uneasiness in the region of the heart. These attacked him severely one night; they were relieved in the morning. He died suddenly immediately after a meal.	Rupture of the heart.	Heart rather large. L. V. thickened. R. V. thinner than usual; loaded with fat. Substance pale, soft, flabby. Rupture in front of L. V. near the apex: one of the fleshy columns torn across and projecting into the rent. The coronary arteries were ossified even to their terminations.	—
16.	Dr. Stephens, Medico-Chirur. Rev., 1833, p. 670.	M.	61	Enjoyed good health, and was rather corpulent. He was accustomed to take exercise freely. Suddenly seized with acute pain across the sternum and down the arms. His pulse regular, 72, moderately full. Relief. Three relapses. Death in forty-eight hours from first seizure.	Rupture of the heart.	The base of the heart loaded with fat. The muscular substance resembled the liver; it was pale, soft, and broke beneath the touch. A rupture in front of L. V. toward the apex. The heart thinned here.	Body rather fat.
17.	Mr. Smith, Dub. Journ., vol. ix, 1838.	F.	90	Debility. Sudden death.	Rupture of the heart.	The heart covered with fat. The muscular substance of a pale yellow colour, as if infiltrated with pus, (Mr. Smith says it resembles exactly M. Cruveilhier's drawing,) flaccid. The knife was greased after cutting it.	The subcutaneous cellular tissue was loaded with soft fat. Liver very soft. Oil poured from the vena cava and the other divided vessels.
18.	Idem.	F.	70	No history, she was found in a dying state.	—	Surface of the heart covered with a layer of fat, quarter of an inch thick. Muscular substance soft, pale, and flaccid.	Oil floating on the surface of the blood.

19.	Dr. Hope, Diseases of the Heart, 1839, p. 343.	M.	<p>Very fat; had for six or seven years intermittent pulse, and hurried breathing on exertion. Three years before death had jaundice. Fatty heart being suspected, too much exercise was taken, with the view of remedying it. He became worse, had palpitation, dyspnoea, and sleeplessness. Pulse weak, small, irregular. General languor of the circulation. Impulse of heart, a flutter and an occasional bound of greater force. Sound weaker than natural. Heart's contractions from 130 to 140; pulse 40 to 60. The symptoms became worse, and he died in a fortnight.</p>	Gradual.	<p>Heart greatly enlarged. Muscular substance hypertrophied, dark coloured, but very soft. External third of the wall of R. V. replaced by fat.</p>	Pulmonary apoplexy.
20.	Idem, p. 351.	M.	<p>Stout and fat. Three years before death had inflammation of the heart; and subsequently occasional oppression in this region, and pain down the left arm. He could mount ascents without difficulty. Pulse irregular. Impulse of heart unequal. Sounds both dull. He was bled, had liquor potassæ, and lived carefully. He got better. In eight months his liver became enlarged, he lost much flesh and died.</p>	Gradual.	<p>Heart enlarged, and much covered with fat. Muscular substance hypertrophied, but soft and flabby.</p>	Liver not enlarged, but of the nutmeg character.
21.	Mr. Bedington, Provincial Med. & Surg. Journal, Nov. 1843.	M.	<p>Had been complaining for a week or ten days. In the morning had a "stitch in the side," which became an intense pain in the chest during the day. This continued, and extended along the arms to the wrists. The pulse slow and feeble. Death on the same night.</p>	Rupture of the heart.	<p>The heart, of the usual size, was loaded with fat; the muscular substance softened from fatty degeneration, and thinner at the seat of rupture, viz. in front of L. V. There were two ruptures externally, and but one internally.</p>	—

No.	Record.	Sex.	Age.	Previous history.	Cause or mode of death.	State of the heart.	Remarks.
22.	Dr. MacLagan, Edin. Mon. Journal, 1845, p. 42.	F.	75	A lady, in good health, but unable to ascend heights, was seized with faintness. She then complained of uneasiness, tightness, and weight in the chest. Her surface was cold. She was almost pulseless. There was extended dullness, and feeble impulse in the region of the heart. She died in an hour.	Hemorrhage into pericardium.	Heart rather large, loaded with fat; the muscular substance soft, as from "chronic inflammation." There were two superficial lacerations on the outer surface of the heart, one of which communicated with a branch of the coronary vein.	—
23.	Dr. Andrews, Idem, p. 481.	M.	60	A gentleman, in pretty good health, but unable from dyspnoea to use active exercise, was engaged for many hours during three successive days in preparing some official returns. After a short walk, he fell dead.	Sudden.	Heart enlarged to three times its natural size, and loaded with fat. The softness of the muscular substance of the right auricle, right ventricle, and upper two thirds of left ventricle, was such that, in handling, it was difficult to avoid lacerating it. The right auricle dilated, attenuated, and its fibres torn in three places; blood was extravasated amongst them. The pericardium alone prevented a complete rupture. The heart preternaturally large. The muscular substance soft, and of a dirty-yellowish hue. Rupture (in L. V.?).	—
24.	Mr. L Davies.	F.	56	Of intemperate habits. After being received in prison, she was suddenly seized with illness, her breathing was oppressed, and her countenance livid. She died suddenly.	Rupture of the heart.		Body fat.
25.	Dr. Latham, Clinical Medicine, vol. ii, 1846, p. 149.	M.	70	Convivial, and in good health. After considerable exertion, he was seized with difficulty of breathing, and sense of sinking or fainting,—pulse frequent and feeble. Relief. The heart's impulse feeble, but felt over a large space. He died suddenly, on the eighth day.	Sudden.	Pericardium unusually vascular. The heart large. The muscular substance pale, flabby, and lacerable, which seemed to arise from its partial conversion into fat,—this tissue being mixed up with the fibres, particularly on the external surface. A commencing cardiac aneurism was found at the	A pint and a half of serum in each pleura. The liver twice the natural size. Atheromatous de-



26.	Dr. Stokes, Dubl. Journ. vol. i, N. S. 1846, p. 491.	50	Seemed to suffer more from want than disease. He experienced great distress from the least effort, and seemed to lie in a state of lethargy. The action of the heart, and both sounds, were feeble. He died without a struggle. Pulse small, and compressible.	Lethargic.	apex of L. V.,—it was the result of softening and attenuation of the heart's substance at that point,—the endocardium being destroyed. Pericardial surfaces adherent. Much fat about the heart. The muscular substance of L. V. flabby, degenerated, and its cavities dilated. The substance of R. V. atrophied. Much fat on its surface, and about the <i>origin of the chordæ tendinæ</i> (?).	—
27.	Mr. Harrison, Provincial Med. & Surg. Journal, 1848, p. 590.	67	Moderately stout, but flabby. Always enjoyed good health. Complained, for a day or two, of pain and oppression in the precordial region. Having been engaged all day in business fell dead. His features were pale.	Syncope.	The heart pale, soft, flaccid, of a dirty-yellow colour. It appeared a mass of fat. "A fatty transformation and infiltration of the muscular substance, it could be moulded like putty." The ventricular walls thin. L. V. dilated, auricles and large vessels gorged with blood. Coronary arteries normal.	All the viscera loaded with fat.
28.	Dr. Binney, Med. Gaz., vol. i, 1849.	67	Lived abstemiously for twenty years, in consequence of suffering lumbar pains. Had an attack of pleurisy, and was found to be the subject of heart-disease when examined. He felt giddy, and complained of a sensation of sinking when riding, walking, or going up stairs, he also suffered from violent painful palpitations of the heart at night. After walking three miles, and getting wet in doing so, he was seized with pains in abdomen, sickness, and diarrhoea. The latter symptoms were relieved by next day; but he appeared excited, and his pupils were contracted;	Rupture of the heart.	Pericardium contained "two ounces and a half of bloody serum." Heart natural in size, covered with fat. Wall of right ventricle thinned, soft, and fatty. A small opening existed at the base, into the cavity of the right ventricle. The mitral valves were healthy—one of the aortic valves was ossified; the other studded with atheroma. The aorta dilated and similarly studded.	Adhesions of the left pleura. Granular disease of the kidneys. Congestion of the aortic vessels of the brain. Four oz. of serum, found in the arachnoid, when the brain was removed.

No.	Record.	Sex.	Age.	Previous history.	Cause or mode of death.	State of the heart.	Remarks.
29.	Mr. Robbs, Med. Gaz., vol. ii, 1849.	M.	—	<p>during the night he was found comatose; breathing stertorously; and he died in about thirty-six hours from first.</p> <p>Was stated to have enjoyed an ordinary state of health. After eating dinner hurriedly, adjourned to a public-house, to procure some ale. Whilst in conversation, fell dead.—Mr. Robbs says, from "angina pectoris."</p>	Syncope.	<p>Pericardial surfaces firmly adherent. Much fat on the surface of the heart, adhesions of heart greatly hypertrophied. The auricles large, distended with blood; their walls flabby and soft. The walls of the ventricles thick, soft, easily broken, and greasy. The mitral valves thickened. Aortic valves fibro-cartilaginous. The heart rather larger than natural. The cavities dilated. The muscular parietes were so soft, that they felt like a piece of wet wash-leather.</p>	Universal old
30.	Dr. Henry Bennett.	F.	23	<p>A lady, of lymphatic constitution, passed through her pregnancy in tolerably good health, only casually complaining of difficulty of breathing. Slight hemorrhage occurred, owing to a partial placental presentation, and returned to a slight extent after delivery. Chloroform in small quantity had been used. She rallied, but remained weak, her pulse being weak and small. On the 21st day she died instantaneously, without any evident cause.</p>	Syncope.	<p>Heart larger than natural; "fatty." Valves healthy. Dr. Kennedy refers to the recent investigations on fatty degeneration.</p>	Body fat. Vessels of brain congested.
31.	Dr. H. Kennedy, Dublin Med. Press, vol. xxii, 1849, p. 370.	M.	59	<p>A clergyman, treated twice for gout and thrice for cyanache tonsillaris; subject for several years to attacks of syncope, in which he did not lose his consciousness, but "in which the feeling of death itself was strong upon him." Pulse slow (56); no intermission. Temperature of body low.</p>	Sudden.	<p>Heart larger than natural; "fatty." Valves healthy. Dr. Kennedy refers to the recent investigations on fatty degeneration.</p>	Body fat. Vessels of brain congested.

32.	Idem.	M.	<p>A gentleman, a large eater, at 27, changed from an active to a sedentary life, and became very corpulent. Soon after (at 33), suffered from a "thickness in," or slight difficulty of, breathing; always worse on taking cold, or when dyspeptic. For the dyspepsia used carbonate of soda. After some time, seized with a fit. He was in a state of faintness or collapse; conscious; face pale; surface cold, particularly feet and legs. Pulse and heart's action extremely weak. Breathing oppressed. These fits recurred frequently for some years, when he died of diarrhoea.</p>	Diarrhoea.	<p>Heart larger than natural; more fat than usual on its surface. Its muscular substance pale and flabby.</p>
33.	Mr. Woollaston.	F.	<p>56 A lady, living luxuriously, taking little exercise, sallow complexion, fat, had suffered from indigestion, impaired health, pain in the region of the heart, short breath, and a distressing sense of faintness. Last three or four years of life there was slight paralysis of the left leg. She died suddenly.</p>	<p>56 Syncope, from hemorrhage into the pleura.</p>	<p>The heart small, and much fat about its vessels. The tissue pale and soft, loaded with fat. Coronary artery ossified and cartilaginous, to the extent of an inch and a half. Atheromatous deposits on the aortic valves. The left lung gorged, the pleura containing much coagulated blood, which had escaped from a rupture of the tissue of the lung. Liver hard, granular. Kidneys pale, soft, and small.</p>
34.	Catalogue, R. C. S. Museum, No. 1520.	F.	<p>The patient was a lady, and the rupture produced sudden death.</p>	<p>Rupture of the heart.</p>	<p>A heart generally enlarged, invested by an unnatural quantity of fat. The muscular tissue is thin and pale. A rupture through anterior wall of L. V. at an inch from the base.</p>

No.	Record.	Sex.	Age.	Previous history.	Cause or mode of death.	State of the heart.	Remarks.
34 a.	Catalogue, R. C. S. Museum, No. 1521.	F.	68	<p>Corpulent, sedentary for six years,—had suffered from dyspnoea. Five months before her death had a slight apoplectic fit, followed by permanent numbness of the left arm and legs, and increase of the dyspnoea. Pulse hard, small, intermittent. The least acceleration of the heart's action producing a state like syncope. Sixteen hours before death was awakened by a violent pain in the region of the heart. She was relieved by a small bleeding, but continued restless and died suddenly.</p>	Rupture of the heart.	<p>The muscular substance pale and flaccid, and nearly covered by a thick layer of soft fat. Earthy deposits in coronary arteries, by which the left is obliterated. A rupture in front of left ventricle about two inches from the apex.</p>	<p>This case is presumed to be the same as that already recorded, No. 2, in this Series.</p>
35.	Idem, No. 1522.	M.	47	<p>A robust plethoric man. Inflammation of the heart occurred during an attack of acute rheumatism of the hands and feet, and he died suddenly on the fourth day.</p>	Rupture of the heart.	<p>The heart was natural in size—there were no signs of old organic disease, but indications were found of recent endo- and pericarditis. The heart was thickly invested with fat, and the muscular substance thin towards the apex of R. V., through which two small ruptures have occurred.</p>	<p>The specimen is from Mr. Langstaff's collection; and Mr. Hodgson's case, of which the details are nearly the same, was obtained from Mr. Langstaff. The results, therefore, are not included in the abstract made from these histories. It is given with a view of showing the nature of the cases which appear to have been overlooked when this was first recorded.</p>

SERIES III.—Containing the abbreviated histories of Fifteen cases of Excessive Accumulation of Fat on the surface of the Heart.

No.	Record.	Sex.	Age.	Previous history.	Cause or mode of death.	State of the heart.	Remarks.
1.	Lancisi, De Subit. Mort. 1707, p. 176.	M.	50	A very corpulent man, addicted to indulgence at table,—suffered from pain at the base of the chest, and difficulty of breathing. His pulse irregular. Being seized with an irritating eruption of the skin, he exposed himself to cold, and died suddenly.	"Apoplexia syncopealis."	Everywhere loaded with fat.	The body fat. The brain congested. The liver a little enlarged. The gall-bladder ulcerated. Lancisi ascribes the death to "syncopeal apoplexy."
2.	Schæffer, Nov. Act. Acad. Nat. Curios. 1761, p. 108.	M.	30	Having little occupation, gave himself up to enjoyment, and became so fat as to be unable to move without distress.	Sudden.	Pericardium contained some clear serum. Heart loaded with fat.	The body everywhere loaded with fat. The liver enlarged.
3.	Morgagni, De Sedibus, &c. Epist. iii. 1765, Obs. 20.	M.	Aged.	Died after an apoplectic seizure of some days' duration. Little previous history.	By cerebral hemorrhage.	Heart so covered with fat, that none of its muscular substance could be seen.	Body not fat. Ossification of the falx cerebri. Hemorrhage in the brain.
4.	Idem, Epist. xxvii, Obs. 2.	F.	75	Had been subject, for some months, to vertigo,—frequent swoonings. Breathing stertorous. Sudden death.	Rupture of the heart.	The heart was loaded with fat. The muscular substance thin beneath it. A rupture at the back of the left ventricle, near the apex. A ring of bone surrounded the left auric. vent. opening.	The body generally contained much fat. The aorta was much ossified.
5.	Idem, Epist. xxxv. Obs. 18.	F.	54	"A great princess" suffered from severe pain in the abdomen, and of diarrhoea. After each two laudable strokes of the pulse, followed two low, and of unequal celerity.	By gangrene of the intestines.	Pericardium and heart overloaded with fat.	The abdomen fat—not much fat on the limbs.

No.	Record.	Sex.	Age.	Previous history.	Cause or mode of death.	State of the heart.	Remarks.
6.	Licetaud, Hist. Anat. Medica, vol. ii, 1767, p. 19.	M.	50	A very fat man — suffered from difficulty of breathing and sleepless nights, being unable to lie down.	Sudden. Syncope?	Heart large, loaded with fat.	The lungs small.
7.	Dr. Fothergill, Medical Observations, &c. vol. v, 1776.	M.	58	Regular in habits — disposed to corpulency. Subject to giddiness, then to pain and tightness in the chest, aggravated by exercise. Pulse irregular. Breathing difficult, especially after exercise. A well-marked case of angina pectoris. Had been subject to difficulty of breathing. After a journey she was seized with colicky pains, and her breathing became more difficult. The same night she called aloud for aid, and died.	Sudden, in a paroxysm.	Much fat beneath the pericardium. White spots on the apex, resembling a cicatrix.	Fluid in both pleurae. Much fat in abdomen.
8.	Portal, Mémoires de l'Acad. des Sciences, 1784.	F.	Not stated	Inclined to corpulency. Had been subject to rheumatism. For two or three years felt a pain, or tightness across the chest, on walking fast: this increased, and the slightest exertion caused dyspnoea. He was slightly relieved by bleeding. Towards the end had a cough. Pulse not irregular, but small. He died in a fit.	Rupture of the heart.	The heart covered with a thick layer of fat. The muscular substance said not to have been softened. Rupture at the base near the aorta.	The body enormously covered with fat. The muscles were penetrated with this tissue.
9.	Dr. Wall, Trans. of Coll. of Physicians, vol. iii, 1785, p. 12.	M.	66	Inclined to corpulency. Had been subject to rheumatism. For two or three years felt a pain, or tightness across the chest, on walking fast: this increased, and the slightest exertion caused dyspnoea. He was slightly relieved by bleeding. Towards the end had a cough. Pulse not irregular, but small. He died in a fit.	Sudden.	The heart, of uncommon size, was covered with a great quantity of fat. There was fluid in the pericardium. The semilunar valves were ossified.	Fluid in the pleura. The lungs firm. Aorta enlarged, and ossified.
10.	Dr. Parry, On Syncope Angiosa, 1799, p. 7.	M.	56	Robust and corpulent; of irregular but sedentary habits; suffered from symptoms of angina pectoris—sense of stricture in the chest, pain, diffi-	Sudden.	Abundance of fat on the pericardium and heart. The coronary arteries thickened, cartilaginous, and filled to their extremities with a sub-	Liver pale. Other viscera covered with fat. Two quarts of coloured serum in the pleura.

<p>11.</p>	<p>Idem, p. 14.</p>	<p>M. 63</p> <p>culity of breathing, irregular pulse, &amp;c. He continued subject to these paroxysms for a year, when they became more severe, and he died very suddenly, in a fortnight from this time. The pain had ceased some time before his death.</p> <p>Inclined to corpulency; a hearty eater, but temperate in drinking. Accustomed to take much exercise out of doors, until, by an accident, he was obliged to remain in-doors, and to exercise with weights. He became more corpulent, and restless at night. Seven years before his death, he had slight symptoms of angina pectoris, with a cough; they disappeared, but returned in eighteen months. He then had a return of the pain, and afterwards a fit of syncope. Pulse not to be felt, but, on recovering, it was irregular, and he complained of a dull pain from the mamma to the sternum. <i>No other affection.</i> He died the same night, in an attack nearly similar.</p>	<p>Sudden.</p> <p>The heart large, and loaded with fat. The cavities full of blood. The coronary arteries extensively ossified.</p>	<p>stance like the lymph of croup. No blood in the cavities of the heart.</p>	
<p>12.</p>	<p>Idem, p. 20.</p>	<p>M. 77</p> <p>Moderately fat, of sedentary and temperate habits. During a residence in India was attacked with slight syn-angina pectoris, and was liable to pains, attacking successively the head, chest, limbs, &amp;c., with cramps in the legs. He was not subject to any distress of breathing, or to</p>	<p>The integuments fat. No fluid in the pleura. The lungs sound. The aorta dilated. 2654 small gall-stones in the gall-bladder.</p>	<p>The heart buried in fat, and of a moderately firm texture. The blood was fluid, and flowed out when dilated. The vessels were cut across. Considerable ossification of the coronary arteries.</p>	<p>The lungs healthy. No effusion. Aorta not dilated.</p>

No.	Record.	Sex.	Age.	Previous history.	Cause or mode of death.	State of the heart.	Remarks.
13.	Dr. Francis, Guy's Hospital Reports, vol. iii, 1838.	M.	71	<p>palpitation. He was suddenly seized with a sense of suffocation, and pain in the chest. In about twelve months this returned, and he had several attacks, as of syncope, with pain, and died.</p> <p>Subject to a chronic cough. Whilst walking one day quickly across a workhouse yard, after eating a hearty supper, he lost his breath, seized some railings, glided to the ground, and was dead in a few moments.</p>	Sudden.	Heart covered with fat, which also surrounded the pericardium and great vessels. The right side was loaded with blood,—the left side empty.	The lungs were emphysematous.
14.	Dr. Stroud, Med. Gazette, vol. xxvi, 1840.	M.	29	<p>Suffered from mental distress, and, on the cessation of an habitual nasal hemorrhage, had slight cerebral symptoms,—was seized with giddiness, vomiting, insensibility. Pulse imperceptible. He was bled freely, and, having rallied a little, complained of weight and tightness in the region of the heart. Died same night.</p>	By rupture.	Heart large, loaded with fat,—an opening through the wall of the right auricle, just below the insertion of the vena cava. Substance not ulcerated nor thinned.	—
15.	Dr. Latham, Clinical Medicine, vol. ii, 1846, p. 387.	M.	55	<p>Returned from India with unimpaired health, but with a tendency to fatness. After exercise, whilst in his usual health, felt pain (after dinner) in the region of the heart. The pain got better, but he was found dead in a few hours afterwards.</p>	Sudden.	Muscular substance thin, and encroached on by fat.	—



GENERAL ABSTRACT, showing the principal facts in the histories of Eighty-three cases of Fatty Disease of the Heart,—contained in the Three preceding Series.<sup>1</sup>

Clinical History.		Ser. I.	Ser. II.	Ser. III.	Total.
Number of cases	Males . . . . .	24	19	12	55
	Females . . . . .	9	16	3	28
<i>Ages.</i>					
Under 20	Males . . . . .	0	0	0	0
	Females . . . . .	1	0	0	1
20 to 30	Males . . . . .	1	0	1	2
	Females . . . . .	3	3	0	6
30 " 40	Males . . . . .	2	0	0	2
	Females . . . . .	2	0	0	2
40 " 50	Males . . . . .	4	1	0	5
	Females . . . . .	4	0	0	4
50 " 60	Males . . . . .	1	4	6	11
	Females . . . . .	0	2	1	3
60 " 70	Males . . . . .	5	8	2	15
	Females . . . . .	2	1	0	3
70 " 80	Males . . . . .	5	1	2	8
	Females . . . . .	0	5	1	6
80 " 90	Males . . . . .	2	1	0	3
	Females . . . . .	0	2	0	2
" Aged"	Males . . . . .	1	0	0	1
	Females . . . . .	0	2	1	3
Not stated	Males . . . . .	0	3	0	3
	Females . . . . .	0	2	1	3
All	Both sexes . . . . .	33	35	15	83
<i>Class in Society.<sup>2</sup></i>					
Higher	Males . . . . .	7	8	5	20
	Females . . . . .	2	6	2	10
Middle	Males . . . . .	6	7	5	18
	Females . . . . .	2	2	1	5
Lower	Males . . . . .	11	4	2	17
	Females . . . . .	5	8	0	13
<i>Conformation.</i>					
Fat persons . . . . .		12	11	11	34
Thin ditto . . . . .		9	0	1	10

<sup>1</sup> The cases from which this Abstract is taken, being recorded by a number of different observers who had no special views to illustrate, possess the advantage of presenting the more striking phenomena of each case so far as they were ascertained, but fail in affording all the positive and negative information which would be valuable in completing the details.

<sup>2</sup> Inferences as to the habits of living, may be derived from knowing the station in life. They are positively stated in too few instances to deserve attention here.

Clinical History.	Ser. I.	Ser. II.	Ser. III.	Total.
<i>Habits.</i> <sup>1</sup>				
Active . . . . .	2	0	0	2
Sedentary . . . . .	14	5	3	22
<i>Symptoms.</i> <sup>2</sup>				
Giddiness . . . . .	3	2	3	8
Fits of coma . . . . .	2	5	2	9
Syncope . . . . .	8	7	8	23
Short breath . . . . .	17	16	9	42
Pain, long continued . . . . .	7	7	5	19
" a short time before death . . . . .	5	7	1	13
" intermittent . . . . .	8	4	5	17
" local . . . . .	8	8	6	22
" extended to the arms . . . . .	4	4	4	12
<i>Physical signs.</i>				
Pulse weak . . . . .	5	9	2	16
" strong . . . . .	0	0	0	0
" slow . . . . .	4	4	0	8
" quick . . . . .	0	3	0	3
" regular . . . . .	1	3	1	5
" irregular . . . . .	7	6	4	17
Impulse of the heart, weak . . . . .	5	5	0	10
" " strong . . . . .	2	0	0	2
" " extended . . . . .	5	2	0	7
Extended dullness . . . . .	5	1	0	6
First sound, feeble . . . . .	4	2	0	6
Second sound, ditto . . . . .	3	2	0	5
Murmur, <sup>3</sup> first sound . . . . .	4	0	0	4
" second sound . . . . .	1	0	0	1
<i>Mode of death.</i> <sup>4</sup>				
Sudden . . . . .	28	26	14	68
Prolonged . . . . .	4	8	1	13
By syncope <sup>5</sup> . . . . .	13	8	5	26
By coma . . . . .	4	2	1	7
By rupture of the heart . . . . .	8	17	3	28
By other diseases . . . . .	7	3	1	11
Not stated . . . . .	1	5	5	11

<sup>1</sup> Four individuals, in SERIES I, were always sedentary. Ten became sedentary after a life of activity. In SERIES II, four out of the five became sedentary after an active life.

<sup>2</sup> Two individuals are stated, in SERIES I, to have been in good health up to the moment of the fatal seizure. In two other cases, the previous state of health was not clearly ascertained. In SERIES II, six are stated to have been in good health.

<sup>3</sup> In one case, nothing to explain the source of the murmur is recorded.

<sup>4</sup> The mode of death is not stated in one case in SERIES I, and not in another in SERIES II.

<sup>5</sup> Five other individuals, in SERIES III, appear to have died by syncope, but as it is not clearly stated, they are not included here.

Morbid Appearances.	Ser. I.	Ser. II.	Ser. III.	Total.
<i>State of the heart.</i>				
Size <sup>1</sup> increased . . . . .	23	16	4	43
„ diminished . . . . .	1	3	0	4
Consistence diminished <sup>2</sup> . . . . .	19	32	0	51
Tissue discoloured <sup>3</sup> . . . . .	20	32	0	52
Fatty growth on the heart more than usual	21	22	15	58
„ „ less than usual <sup>4</sup>	4	0	0	4
Degeneration, both ventricles . . . . .	10	8	0	18
„ right ventricle . . . . .	4	1 <sup>5</sup>	0	5
„ left ventricle . . . . .	8	0	0	8
Coronary arteries ossified or obstructed <sup>6</sup>	13	7	5	25
Valvular disease, chronic, endo, or peri- carditis . . . . .	6	11	0	17
<i>Liver.<sup>7</sup></i>				
Large . . . . .	8	4	0	12
Fatty or soft . . . . .	5	1	0	6
Granular, small or mottled . . . . .	5	5	0	10
Jaundice . . . . .	1	1	0	2
Gall-stones . . . . .	1	1	2	4
Ulceration of gall-bladder . . . . .	1	0	1	2
<i>Kidneys.<sup>8</sup></i>				
Large . . . . .	5	0	2	7
Fatty . . . . .	2	0	0	2
Granular, mottled, &c. . . . .	6	2	1	9
<i>Spleen.</i>				
Enlarged, or deposits in . . . . .	1	1	0	2

<sup>1</sup> The volume was not changed in five cases of SERIES I, and not in three of SERIES II.

<sup>2</sup> In three cases of SERIES II, the tissue is described as being fragile.

<sup>3</sup> In one case, in SERIES I, the pale buff colour was limited to a portion towards the apex of the left ventricle; in one case, in SERIES II, the tissue is described as being dark coloured.

<sup>4</sup> In the other cases, the quantity of fat is not stated, or is said to be usual.

<sup>5</sup> The extent of the degeneration is too indefinitely mentioned in the other cases to justify its limitation.

<sup>6</sup> Healthy in one. Not examined in several of SERIES I. Healthy in two of SERIES II.

<sup>7</sup> The liver was diseased, in one form or other, in fifteen cases of SERIES I; and in eight of those in SERIES II.

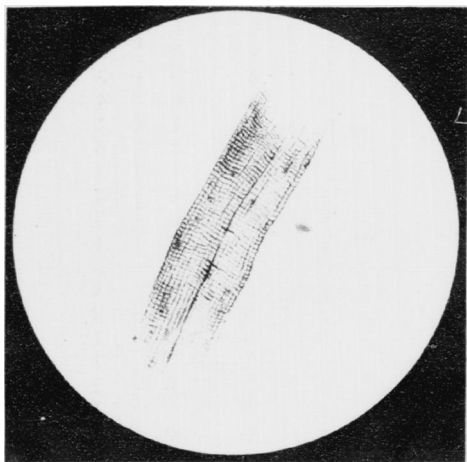
<sup>8</sup> The kidneys were diseased in eight cases in SERIES I; in one case said to be healthy.

<i>The chief diseased conditions not already mentioned here, which coexisted with that of the heart, and in some cases caused death.</i>	Ser. I.	Ser. II.	Ser. III.	Total.
Death by apoplexy . . . . .	1	1	1	3
Serous effusion on brain . . . . .	3	2	0	5
Mental irritability . . . . .	3	0	0	3
Paralysis . . . . .	2	2	0	4
Nasal hemorrhage . . . . .	0	0	1	1
Aorta, diseased, or aneurism . . . . .	4	1	3	8
Bronchitis . . . . .	2	0	1	3
Emphysema . . . . .	2	0	1	3
Pneumonia (chronic) . . . . .	1	1	0	2
Pleuro-pneumonia . . . . .	1	0	0	1
Pleuritic adhesions . . . . .	0	5	0	5
Inhalation of chloroform <sup>1</sup> . . . . .	1	0	0	1
Old tubercles . . . . .	2	0	0	2
Phthisis . . . . .	1	0	0	1
Hæmoptysis . . . . .	0	1	0	1
Pulmonary congestion, or apoplexy . . . . .	0	2	0	2
Cancrum oris . . . . .	1	0	0	1
Stricture of œsophagus . . . . .	1	0	0	1
Indigestion . . . . .	2	1	0	3
Peritonitis . . . . .	1	0	0	1
Hæmaturia . . . . .	1	0	0	1
Renal calculus . . . . .	1	0	0	1
Diseased prostate . . . . .	3	0	0	3
After delivery . . . . .	2	0	0	2
Anasarca . . . . .	4	4	0	8
Gout . . . . .	1	1	0	2
Rheumatism . . . . .	2	2	1	5
Petechiæ . . . . .	1	0	0	1
Prostration or debility . . . . .	2	3	0	5
Muscles of the body, fatty . . . . .	0	2	1	3

<sup>1</sup> Some doubt has been expressed by Dr. Snow, as to whether the death in this instance (Case 22, Series I) was due to the chloroform, or to a mental impression acting on a weak heart. (See Medical Gazette, 1848.)

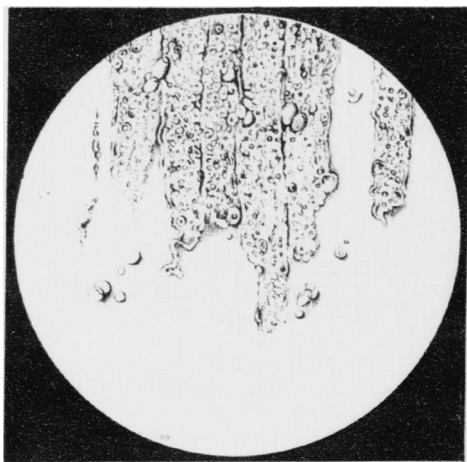
Whilst these pages are passing through the press, a similar event has occurred at Guy's Hospital. A man, 35 years of age, having been narcotised by chloroform, died suddenly whilst undergoing an operation on the hand. After death, marks of cupping were noticed over the heart. This organ was found "feeble and flabby," and having much more fat than usual on the surface. (Lancet, July 6th, 1850.) These cases, whether the deaths were caused by the chloroform, by the mental impression, or by the shock of the operation, equally suggest the importance of ascertaining the state of the heart before such influences are suffered to come into operation.

Fig 1




Muscular fibres of the healthy human heart (x400)

Fig 2



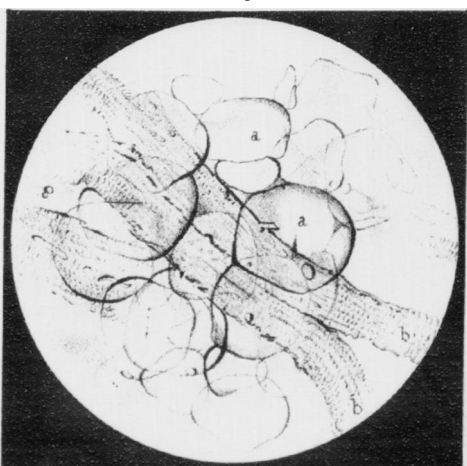
Fatty Degeneration of the fibres of the human heart (x400)

Fig 3



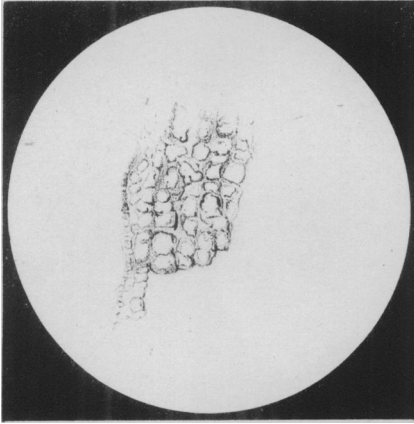
Fatty Degeneration of the fibres of the human heart (x400)  
 a: Early stage b: More advanced

Fig 4



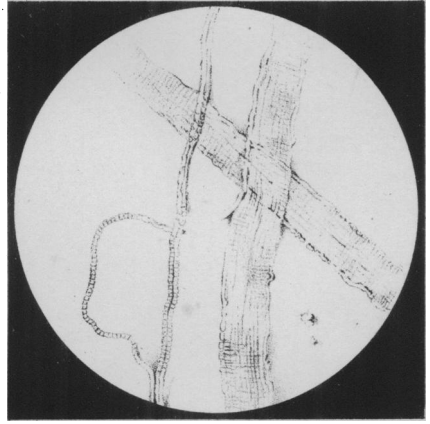
Fatty growth amongst the fibres of the human heart (x400)  
 a: Fat cells b: Muscular fibres

Fig. 1



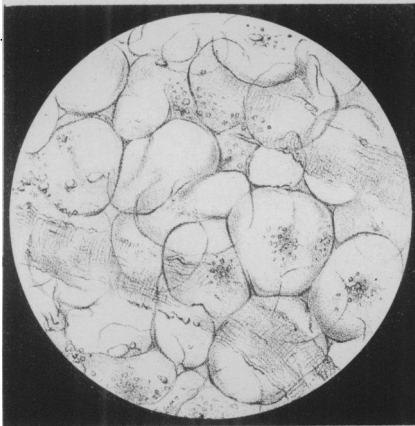
Extreme Fatty degeneration of the fibres of the heart. (4700)

Fig. 2



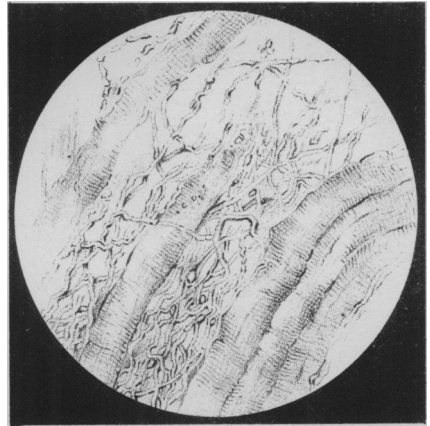
Human Muscular fibre (450) healthy.

Fig. 3



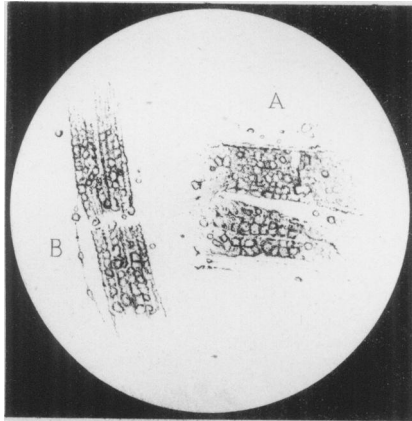
Human Muscular fibre (450) in a state of fatty degeneration.

Fig. 4



The same (as 3) after the action of Sulphuric Ether.

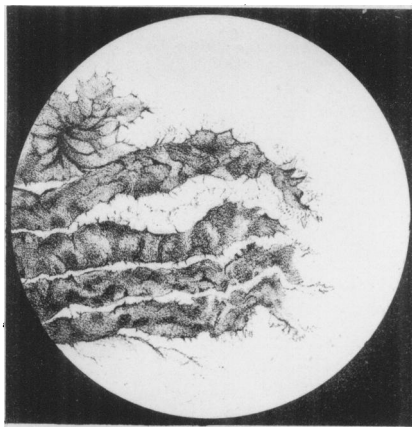
Fig 1



**Artificial fatty Degeneration of Muscular fibre (x450)**

- A. From a healthy child's heart, kept in weak spirit and water.
- B. From a sheep's heart, kept in diluted nitric acid.

Fig 2



Adipocere, from the muscles of the thigh of a horse (x75) showing the fibres as opaque laminae composed of crystalline scales.

Fig 1

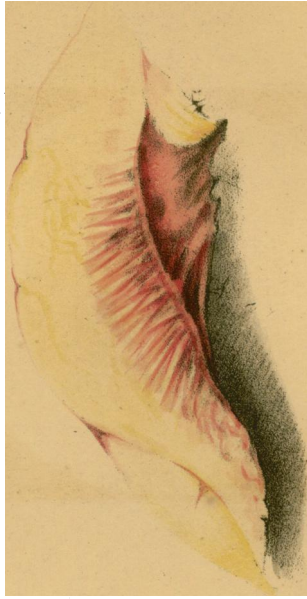

Fig 1, shews fatty growth on and amongst the muscular fibres of the right ventricle of the heart.

Fig 2

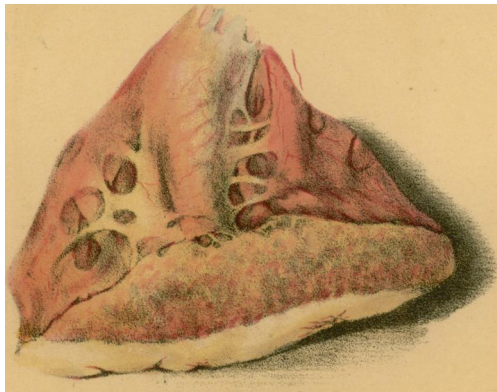


Fig 2, shews fatty degeneration of the muscular fibres of the left ventricle of the heart.