

**FUNCTIONAL EVIDENCE FOR THE  
EXISTENCE OF A THIRD CELL  
TYPE IN THE RENAL GLOMERULUS**

**Phagocytosis of Filtration Residues  
by a Distinctive "Third" Cell**

**MARILYN G. FARQUHAR, Ph.D., and GEORGE E. PALADE, M.D.**

From The Rockefeller Institute. Dr. Farquhar's present address is Department of Pathology, University of California School of Medicine, San Francisco

**ABSTRACT**

Two types of cells can be recognized on the luminal side of the glomerular basement membrane: the superficial endothelial cells which directly line the lumen and are comparable to endothelia lining the capillaries of other tissues, and the deep cells, ordinarily not in contact with the lumen, which are distinguished by their long cytoplasmic arms extending for some distance in several directions along the capillary wall, numerous spinous processes, and occasional intraluminal pseudopodia. Experiments carried out with electron-opaque tracers indicated that a functional distinction, based on extent of phagocytosis, can be made between the superficial and deep cells, thus supporting the existence of a distinctive "third" cell (in addition to endothelium and epithelium) in the renal glomerulus.

Ferritin, colloidal gold, or thorotrast was administered intravenously to normal and, in the case of ferritin, to nephrotic rats. Kidney tissue was fixed at selected intervals from 1 hour to 10 days after the injection and studied by electron microscopy. Within 1 to 4 hours after tracer administration, the particles which did not traverse the glomerular capillary wall gradually accumulated in the less compact, inner strata of the basement membrane and the large spongy areas of axial regions. After 1 day the concentration of circulating tracer declined and the peripheral areas of the capillaries became relatively free of particles while large accumulations developed in the axial regions. During this period increasing quantities of ferritin were taken up by the deep cells and were found within large and small sized invaginations of their cell membrane or concentrated within cytoplasmic vesicles, vacuoles, multivesicular and dense bodies. At the same time the deep cells showed increased numbers of intraluminal pseudopodia. Within 2 to 4 days the deposits in the spongy areas were cleared and concomitantly increased quantities of tracer appeared in the deep cells within dense cytoplasmic bodies, some of which were more compact than before. When ferritin was given to nephrotic animals the sequence of events was generally the same except that the ferritin deposits at any given period were more massive, their incorporation into the deep cells occurred primarily by means of large pockets 1 to 2  $\mu$  in diameter and their clearance from the spongy areas was slower. In normal as well as in nephrotic animals, the phagocytic activity of the superficial endothelium was negligible when compared to that of the deep cells.

The findings suggest that the deep cells may function in the incorporation and disposal of filtration residues as well as in the degradation of the inner, less compact layers of the basement membrane. On the basis of their location and relationship to the basement membrane, and by virtue of their phagocytic activity, the deep cells closely resemble the fixed pericytes of other capillaries. The highly controversial question as to the existence of a distinctive type of "mesangial" or "intercapillary" cell in the glomerulus is reviewed and discussed in relation to these findings.

For several years we have been using electron-opaque tracers (*e.g.* ferritin, colloidal gold, and thorotrast) to investigate pathways and mechanisms involved in transport across the wall of glomerular capillaries in the rat. Results concerning certain aspects of this work have already been reported (1-5). Evidence bearing on another facet—namely, the existence of a "third" cell type in the renal glomerulus—is dealt with here.

During the course of our studies it was observed that filtration residues (*i.e.* tracer particles which do not traverse the glomerular capillary wall) gradually pile against the luminal surface of the basement membrane, are concentrated in the axial<sup>1</sup> regions of the capillaries, and are ultimately phagocytized, primarily by the "deep" cells found in these areas. On the basis of these findings it was tentatively suggested (5) that a functional distinction, based on extent of phagocytosis, can be made between the superficial endothelium and the deep cells of the axial regions. The purpose of this paper is to give a detailed account of our findings on the uptake of filtration residues by the deep cells and to discuss the relationship of the latter to the so-called "mesangial" cells.

#### MATERIALS AND METHODS

Observations on normal and nephrotic rats given ferritin form the primary basis of this study. For comparative purposes more limited observations were made on normal rats given colloidal gold or thorotrast.

#### Tracer Solutions

The source and mode of preparation of the several ferritin solutions used have previously been discussed in detail (5); their concentration varied from 20 to 100 mg/ml. Colloidal gold was obtained through the courtesy of Abbott Laboratories, North Chicago,

<sup>1</sup> The term "axial," although widely used, is rather misleading. It does not refer to the geometrical axis of the capillary or glomerulus, but to the vascular axis, *i.e.*, the common stems of the glomerular tuft. "Central" and "centrolobular" (29, 39) have been used synonymously for "axial" in the literature.

Illinois, as "decayed radioactive gold," and was concentrated 3:1 (approximately 60 mg dry weight/ml) in a flash evaporator prior to injection. Thorotrast (consisting of a 25 per cent solution of thorium dioxide in dextran) was used directly as obtained from Testagar and Company, Inc., Detroit, Michigan, or diluted 1:4 in saline.

#### Animals

A total of 89 young Sprague-Dawley rats, weighing 150 to 200 grams, were used in these experiments. Of these, 57 were normal animals and the remainder nephrotic. Nephrosis was induced by nine daily injections of the aminonucleoside of puromycin (1.67 mg/100 gm body weight (5)), the tracers being injected on the 10th day after initiation of treatment.

#### Experimental Procedures

The general experimental protocol was as follows: 1.0 to 2.0 cc of a given tracer solution (ferritin, colloidal gold, or thorotrast) were administered to animals under light ether anesthesia *via* the saphenous or femoral vein, over a period of 3 to 5 minutes. The dose injected corresponded roughly to 1 cc of tracer solution per 100 gms body weight. Kidney tissue was fixed at selected intervals of 2 minutes to 10 days following the end of the injection and subsequently processed for electron microscopy.

There were four experimental groups: (a) normal rats given ferritin; (b) normal rats given colloidal gold; (c) normal rats given thorotrast; and (d) nephrotic animals given ferritin. Table I gives a detailed list of the time points investigated as well as the number of animals in each of these groups.

#### Preparation of Tissue

Tissue specimens were fixed in acetate-veronal buffered osmium tetroxide (pH 7.6) and embedded, in each case, in methacrylate and in Epon (6). All thin sections prepared for electron microscopy were stained with lead hydroxide. The methacrylate sections were subsequently "sandwiched" with a carbon film, whereas Epon sections were examined directly. Details of the techniques for initiating fixation of the kidney *in situ* and for processing of tissue were given elsewhere (3).

## Electron Microscopy

Micrographs were taken either with an RCA, EMU-2B electron microscope, or a Siemens Elmiskop I at original magnifications of 3000 to 15,000.

## OBSERVATIONS

### Morphological Observations

The organization of the normal glomerular capillary wall was described in detail previously (*cf.* 3). Remarks will be limited here to a description of the arrangement of the deep cells of the axial regions and their relationship to the basement membrane and superficial endothelium. According to the terminology followed up to now we have designated as "endothelial" all cells located on the luminal side of the basement

TABLE I

Number of Animals, Type of Tracer, and Time Intervals between Tracer Administration and Fixation of the Kidney

Injection	2 min. to 1 hr	2 to 6 hrs	1 to 2 days	4 to 10 days
Normal rats given ferritin	10	4	6	8
Normal rats given gold	16	1	2	—
Normal rats given thorotrast	6	2	1	—
Nephrotic rats given ferritin	15	7	7	3

membrane and have distinguished among them "superficial" cells which are clearly in contact with the capillary lumina and "deep" cells which usually are not.

### 1. SUPERFICIAL ENDOTHELIUM

The superficial endothelium directly lines the lumina and is therefore comparable to the endothelium of capillaries from other tissues and organs (7-9). It consists of a single layer or sheet of flattened cells whose nuclei and perikarya are usually located in the axial regions (Figs. 3 and 5), whereas the attenuated periphery lines the peripheral part of the vessels. Axial<sup>1</sup> regions are defined as those segments of the glomerular capillaries which are located deep within the glomerular tuft, near the point of origin of the vessels from the afferent arteriole, or their point

of confluence into the efferent arteriole. In this respect they can be opposed to the peripheral portions of the capillaries which have access to the surface of the tuft and face Bowman's capsule. The outer surface of the superficial endothelial cells is in direct contact with the basement membrane except in the region of the perikarya (Fig. 3), where they commonly face a deep cell as described below. Their cell bodies contain the usual cytoplasmic components (*i.e.*, rough and smooth surfaced elements of the endoplasmic reticulum, free ribonucleoprotein (RNP) particles, Golgi elements, two centrioles, mitochondria, small vacuoles, multivesicular bodies, and occasional dense bodies). A well known characteristic of these cells is the extensive fenestration of their peripheral cytoplasm (*cf.* 3) (Figs. 3, 4 and 11). Although a few pinocytotic vesicles occur in the cytoplasm, they are not nearly so numerous as in the endothelial cells of capillaries with a continuous endothelium (8). The rim of each superficial cell is slightly thicker than the attenuated fenestrated part. Along this rim (Fig. 11) the cell is joined to its neighbors by an "attachment belt" which apparently covers its entire perimeter and which is characterized by close association of the apposed cell membranes and symmetrical densification of the underlying cytoplasmic matrix over considerable distances. In these regions the intercellular gap is reduced to 100 A or less, and is frequently bisected by a faint intermediate line, representing the fused outer leaflets of the apposed cell membranes. It has, therefore, the characteristics of a "tight junction" (10).

### 2. DEEP CELLS

In contrast to the superficial endothelium, the deep cells are not usually in contact with the lumen (except through occasional pseudopodia, as described below). In many sections, as shown in Figs. 3 and 4, these cells appear to be located "between" two capillary lumina from which they are separated by an incomplete layer of "spongy material," followed by a cytoplasmic layer of variable thickness which represents the superficial endothelium. From these commonly encountered appearances and relationships, it is difficult if not impossible to reconstruct the exact distribution and topography of the deep cells. Occasionally favorably oriented sections, such as that shown in Fig. 5, reveal, however, that these cells are intracapillary elements irregularly interposed between

the basement membrane and the superficial endothelium, and partially separated from the latter by an incomplete layer of spongy material (see below). The two lumina of Figs. 3 and 4 represent cross-sections through either the same bent capillary or through a branching vessel. The

fact that longitudinal sections, such as that shown in Fig. 5, are infrequently encountered can be explained by the extreme tortuosity of the glomerular capillaries and their multiple, complex branchings from the afferent arteriole. Indeed the deep cells appear to spread from the

---

*Abbreviations for Figures*

<i>B</i> , basement membrane	<i>a</i> , adhesion plate
<i>CP</i> , capillary lumen	<i>ce</i> , centriole
<i>D</i> , deep cell	<i>d</i> , dense body
<i>EN</i> , superficial endothelial cell	<i>er</i> , endoplasmic reticulum
<i>EP</i> , epithelium	<i>f</i> , endothelial fenestrae
<i>R</i> , red blood cell	<i>g</i> , Golgi membranes
<i>S</i> , spongy areas of the axial regions	<i>m</i> , mitochondria
<i>US</i> , urinary space	<i>mv</i> , multivesicular body
	<i>n</i> , nucleus
	<i>p</i> , foot process of epithelium
	<i>ps</i> , pseudopod of deep cell
	<i>sp</i> , spinous process of deep cell

All the figures except Figs. 3, 14, and 18 are from kidney tissues fixed in osmium tetroxide and embedded in methacrylate. Sections were stained 15 to 30 minutes with lead hydroxide and "sandwiched" with carbon. Figs. 3, 14, and 18 are from kidney tissue embedded in Epon, and stained with lead hydroxide.

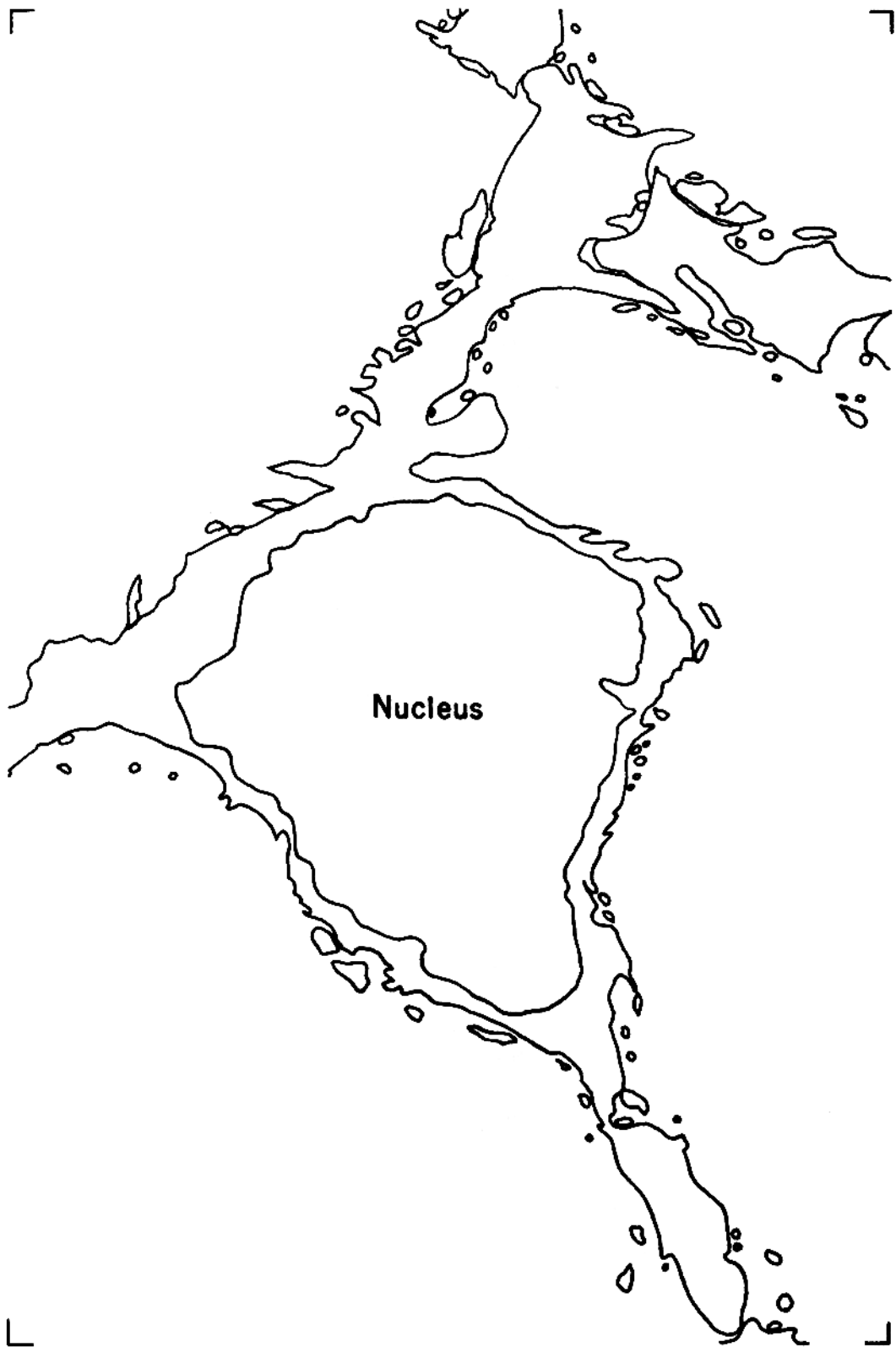
Figs. 5, 7, 12, 13, and 16 were taken with an RCA-EMU 2B electron microscope, and the remainder were taken with a Siemens Elmiskop I.

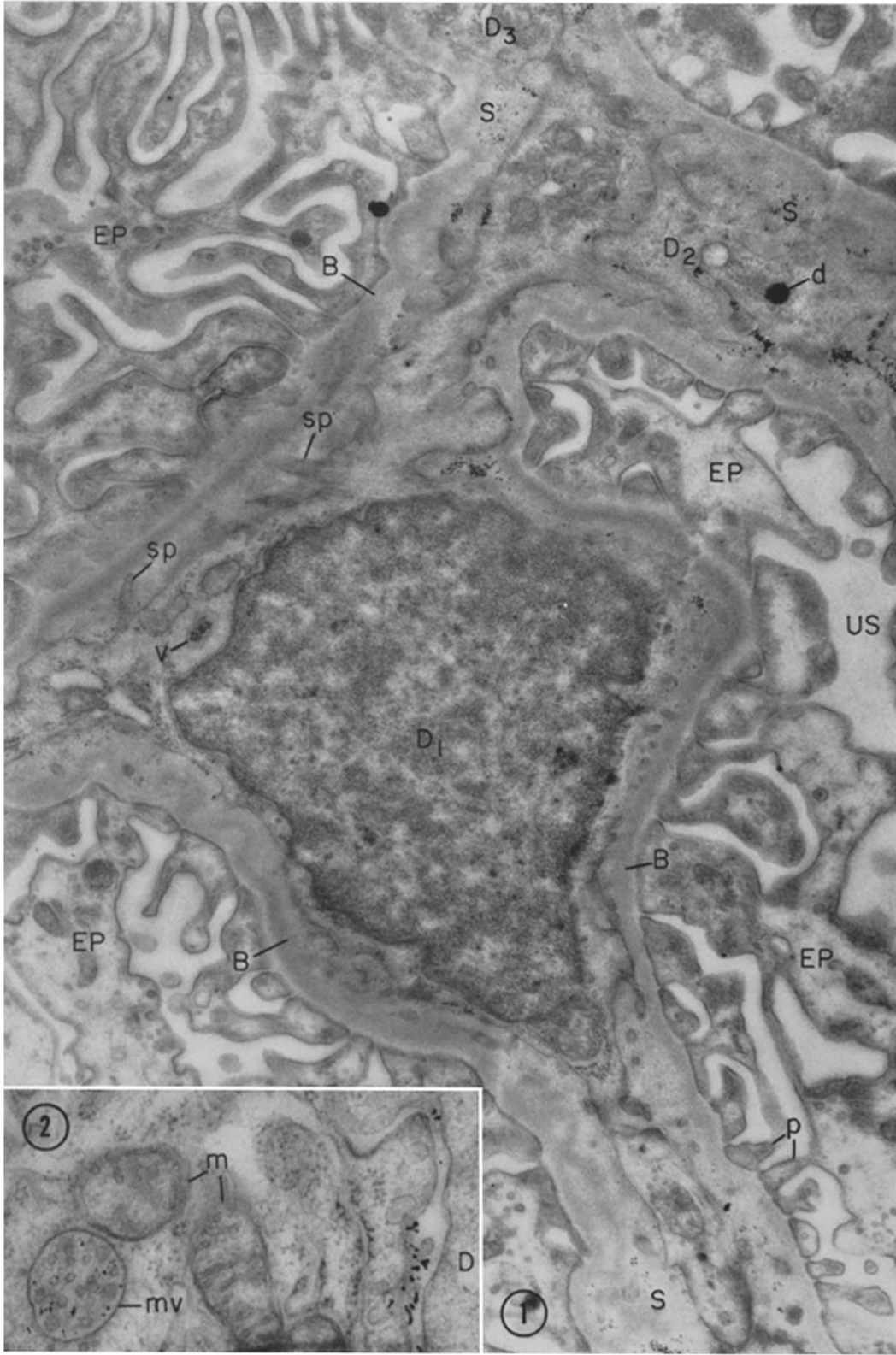
**FIGURE 1**

Relatively low power view of a deep cell ( $D_1$ ) 30 minutes after injection of colloidal gold, demonstrating many of the fine structural characteristics of the "third cell" of the glomerulus. It is clearly located on the luminal side of the basement membrane (*B*) which separates it from the epithelium (*EP*). In most sections of normal glomeruli, the deep cells appear rather small, but favorably oriented sections, such as this, reveal their stellate shape and their long, slender cytoplasmic arms (trabeculae) which may extend for considerable distances in several directions within the glomerular capillary wall. The outlines of the cell are traced in the overlay where the many pointed processes are shown. "Spongy" areas (*S*), which generally resemble the basement membrane but appear less compact, are interposed between the margins of the deep cell and the basement membrane. The external contours of the deep cell are very irregular due to the presence of numerous small pointed or spinous processes (*sp*) cut at various levels, which project into the spongy areas. These processes appear faintly fibrillar and are somewhat denser than the remaining cytoplasmic matrix (see also Fig. 7).  $D_2$  and  $D_3$  probably represent trabeculae of other deep elements. Particles of colloidal gold can be made out in the spongy areas and in a small vacuole (*v*) and a dense body (*d*) in the deep cell cytoplasm.  $\times 21,000$ .

**FIGURE 2**

Portion of a superficial endothelial cell in an animal 30 minutes after administration of colloidal gold, showing the segregation of gold particles within a multivesicular body (*mv*). Note that the particles are for the most part located within the large cavity of the body rather than within the small vesicles it contains. Other gold particles can be seen to the right in the intercellular space between the superficial endothelium and a deep cell (*D*).  $\times 62,000$ .





points where the capillaries branch from the intraglomerular extension of the afferent arteriole or converge on the efferent arteriole, and the branching vessel they follow is seldom in the same plane as its stem.

It should be stated at the outset that the deep cells represent a heterogeneous population with a predominant cell type whose characteristic features will be described. In most sections the deep cells belonging to this type appear rather small with a relatively scant amount of perinuclear cytoplasm (Figs. 5, 8, 10 and 11). Favorably oriented sections reveal the essentially stellate form of these elements (Fig. 1) which are provided with long cytoplasmic arms or trabeculae extending in several directions for considerable distances along the inner surfaces of the basement membrane (Figs. 1, 3 and 12). Such trabeculae may become more numerous and extensive when the cell is appropriately challenged (see below). The outline of those portions of the deep cell which face the basement membrane is quite irregular due to the presence of numerous small spinous or pointed pseudopodia (Figs. 1, 3, 7, 11, 12 and 13) which typically appear considerably denser and more fibrillar in texture than the remaining cytoplasm, a feature particularly well illustrated in Fig. 7.

Interposed between the pseudopodia and the basement membrane are barbs and fronds of a spongy-appearing material, which resembles the basement membrane but appears less compact and more distinctly fibrillar (*e.g.*, Figs. 1, 4, 6, and 7). Similar spongy material also fills part of the intercellular spaces between the superficial endothelium and the deep cells (Figs. 4, 7, and 11). Sometimes pockets, containing such material and connected to the periphery of the cell by a narrow

neck or channel, are found deeply invaginating the cytoplasm of the deep cells (Figs. 5, 7, 8, 16, and 17).

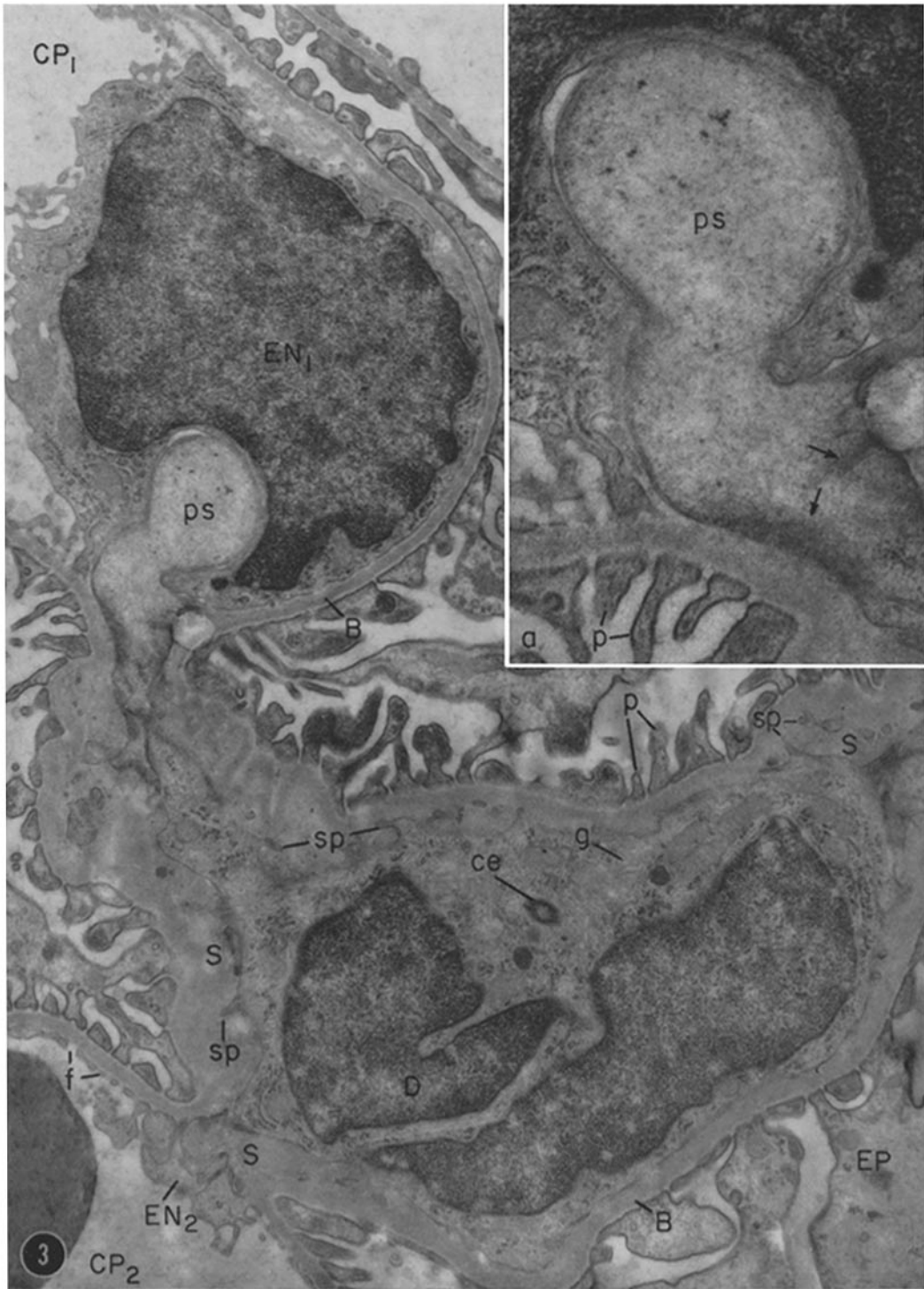
In addition to the small spinous pseudopodia which project into the spongy areas, less frequent broader bulbous or tongue-like expansions are seen pushing aside the superficial endothelium (Figs. 3 and 4) and occasionally reaching and projecting into the capillary lumina (Fig. 9). These intraluminal pseudopodia are, as a rule, composed of a light cytoplasmic matrix devoid—or nearly so—of organized elements. The neck of the pseudopod which pushes through the endothelium and establishes its continuity with the cell body is usually quite narrow (Fig. 9). Hence many sections cut only through the “head” of the pseudopod, thus giving the impression that seemingly isolated masses of cytoplasm occur free in the lumen (Figs. 4 and 10).

In regard to their internal organization, these cells typically show an indented nucleus (Figs. 3 and 10) and a cytoplasmic matrix which frequently appears finely fibrillar (Figs. 4, 7, and 9). The density of the cytoplasmic matrix as well as the number of organelles present is, however, highly variable: in some the cytoplasm is light with only a few organized elements (Figs. 4, 5, and 9), while in others it appears dense and more richly endowed with organelles (Figs. 1, 8, 16, and 17). All these cells have an endoplasmic reticulum, which varies in amount and is provided with both rough and smooth surfaced elements, some free RNP particles, mitochondria, and small vesicles of the “pinocytic” type. A prominent Golgi zone composed of piles of flattened cisternae and clusters of small vesicles is regularly present near the “hof” of the infolded nucleus (Figs. 3, 10, and 17). One or more multivesicular bodies

---

### FIGURE 3

Low power view showing a deep cell (*D*) and a superficial endothelial cell (*EN*<sub>1</sub>) of the glomerulus. In many sections, such as seen in this figure and in Fig. 4, the deep cells appear located “between” two capillary lumina (*CP*<sub>1</sub>, *CP*<sub>2</sub>) from which they are separated by the superficial endothelium (*EN*<sub>1</sub>, *EN*<sub>2</sub>). A striking feature of the deep cell shown here is its large tongue-like pseudopod (*ps*) that pushes against the superficial endothelial cell, indenting its nucleus. This relatively thick section emphasizes the low density of the matrix and lack of organized elements in the pseudopod. The latter is enlarged in the inset where opposing areas of increased density can be seen in the cytoplasm along the cell membranes (arrows). Fine cytoplasmic filaments appear to converge on these dense areas. The “vacuolar” profile to the right of the arrows represents a hole in the supporting film.  $\times 19,000$ . Inset,  $\times 46,000$ .





and dense bodies and one or two centrioles (Figs. 3 and 10) are commonly found in sections through the same region.

Another feature of these cells is the frequent occurrence of areas of increased cytoplasmic density immediately beneath the plasma membrane where the latter faces the spongy areas (Figs. 4 and 7). Frequently bundles of cytoplasmic filaments seem to converge on these dense areas in a manner reminiscent of the attachment bodies described in the smooth musculature of arteries (11). These bundles are frequently disposed perpendicular to the long axis of the cell and are occasionally seen to cross the cell body as they run between opposite spinous pseudopodia (Fig. 7).

It is of interest that typical "adhesion plates" are not usually found between the deep cells and the superficial endothelium (Figs. 3 to 6, and 11); they are occasionally encountered between adjoining deep cells (Figs. 4, 9, and 15). Such structures, normally present along the surfaces of contact between adjoining cells in various epithelia (12), are usually considered to represent areas of strong cell-to-cell attachment. The fact that they are missing from many of the deep cell junctions suggests that these elements are relatively mobile.

Although most of the cells in the axial regions belong to the type described, occasionally other cell types, believed to be wandering elements (*i.e.* monocytes, transitional forms to macrophages,

and fully developed macrophages) of hematogenous origin, are encountered therein (Fig. 10). The macrophages can be identified by their relatively smooth external contours devoid of filiform processes or spinous pseudopodia, by the disposition of their endoplasmic reticulum, and by the presence of small phagocytic vacuoles containing heterogeneous materials.

### 3. RELATIONSHIP BETWEEN BASEMENT MEMBRANE AND SPONGY MATERIAL

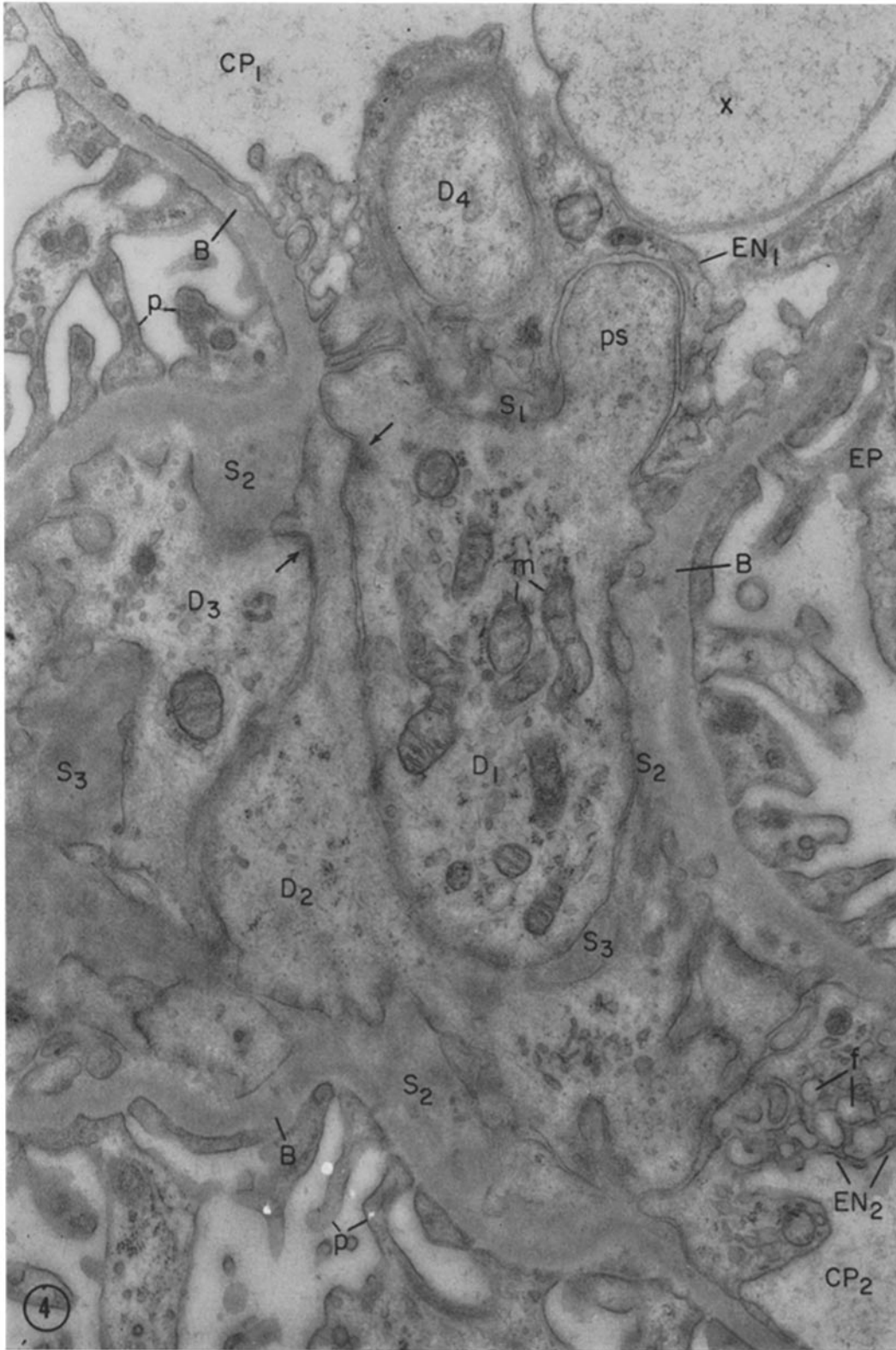
As indicated above the relatively extensive and complicated spaces that separate the deep cells from one another, from the basement membrane, and from the superficial endothelial cells are occupied by a material which, in density and general appearance, resembles basement membrane substance. Yet, in many cases, the material in question can be distinguished from the basement membrane proper by its looser texture and by the presence of small bundles of fine fibers ( $d \approx 100 \text{ \AA}$ ) embedded in its feltwork of finer fibrils (3). The basement membrane proper, which is a continuous layer underlining the array of epithelial foot processes, has a more compact texture and frequently appears noticeably denser than this spongy material. Although the latter is concentrated in the axial regions, it also occurs as a discontinuous, irregular layer apposed to the basement membrane in the peripheral segments of glomerular capillaries. In either location the basement membrane and spongy material are

---

FIGURE 4

Part of a glomerulus showing the orientation of the deep cells as seen in most sections. The deep cells appear to be located between two lumina ( $CP_1$ ,  $CP_2$ ) from which they are separated on either side by an incomplete layer of spongy material ( $S_1$ ), followed by a cytoplasmic layer which represents the superficial endothelium ( $EN_1$  and  $EN_2$ ). Here portions of the cytoplasm of several deep elements ( $D_1$  to  $D_4$ ) (or different arms of the same cell) are seen. Spongy material is also present between the limiting membranes of the deep cells and the basement membrane ( $S_2$ ), and partially interposed between the deep elements along the intercellular spaces ( $S_3$ ).

The portion of the cell marked  $D_1$  shows a rounded or tongue-like pseudopod ( $p_s$ ) which pushes aside the superficial endothelium and projects toward (but in this case does not reach) the lumen. The pseudopod is notably devoid of cytoplasmic organelles. The profile seen at  $D_4$  probably represents a cross-section of another similar pseudopod whose connection to the cell body is not evident in the plane of this section. The apparently isolated mass of cytoplasm seen in the lumen at "x" may represent a section through the "head" of an intraluminal pseudopod such as that illustrated in Fig. 9. In several places (arrows), dense areas are seen along the cell membrane of the deep cells and faint cytoplasmic filaments seem to converge on these areas. Such dense areas are seen to better advantage in Fig. 7.  $\times 29,000$ .



M. G. FARQUHAR AND G. E. PALADE *Third Cell Type in Renal Glomerulus* 63

contiguous, and frequently the transition from the compact to the spongy texture is gradual. For these reasons, the two materials are considered to be related, and, as in the past (3, 5), we shall describe the spongy material adjacent to the basement membrane, especially the discontinuous layer found in the peripheral segments of the capillaries, as "inner, loose layer of the basement membrane."<sup>2</sup> This interpretation is of course tentative and remains subject to revision as information on the exact chemical nature and morphogenetic relationship of the two materials becomes available.

### Tracer Experiments

#### 1. NORMAL ANIMALS GIVEN FERRITIN

In animals sacrificed at short time intervals (2 minutes to 1 hour) after ferritin administration, tracer molecules were found: (a) at high concentration in the capillary lumina and freely penetrating the endothelial fenestrae; (b) in small numbers within vesicles and multivesicular bodies in the cytoplasm of the superficial endothelial cells; (c) in slightly larger numbers in the intercellular spaces between superficial and deep endothelial cells, in the spongy areas between the latter and the basement membrane, and within membrane-limited bodies in the deep cell cytoplasm (see below); (d) at low concentration in

<sup>2</sup> An internal (and external) layer of lighter density has been described in the basement membrane by Rhodin (59), Pease (60), and Latta *et al.* (29). According to Pease and Latta *et al.* this layer consists of a cement substance, and according to Latta and his coworkers the postulated cement substance "merges imperceptibly" with the intercellular substance of the axial regions.

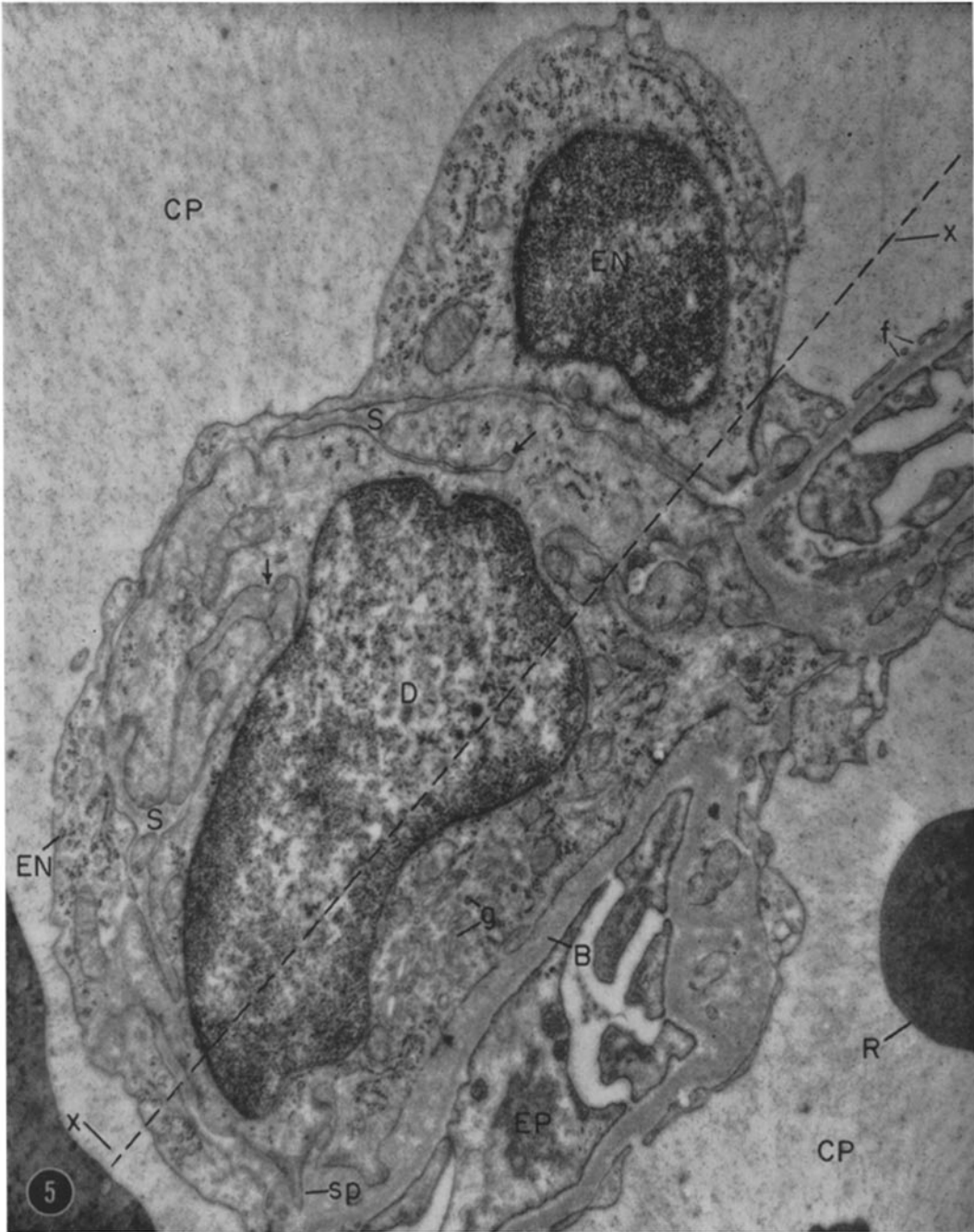the basement membrane proper; (e) in very small numbers in the epithelium where they were located within membrane invaginations or small cytoplasmic vesicles. As far as the relationship of the ferritin to the deep cells is concerned (Fig. 7), at these intervals ferritin molecules were found: within pockets or channels formed between the pointed processes of the deep cells; within small vesicles or vacuoles located in the cytoplasm close to the base of the channels; and within multivesicular bodies and larger membrane-limited dense bodies located deeper in the cytoplasm, frequently in the Golgi region. Such appearances suggest successive stages in a phagocytic process by which accumulated ferritin is engulfed in small pockets of the cell membrane, which subsequently become intracellular vesicles, and eventually merge into multivesicular bodies and dense bodies. The sequence of events in the incorporation process and the means involved therein, *i.e.* the channels between processes or "ruffles" and the size of the membrane pockets, are comparable to those encountered in the phagocytic process as it occurs elsewhere (*e.g.*, during the uptake of India ink particles by the alveolar macrophages of the lung (13)).

During the period from 4 to 24 hours there was a gradual decline in the concentration of ferritin molecules seen in the lumen and endothelial fenestrae accompanied by a progressive piling of ferritin molecules against the basement membrane.<sup>3</sup> The accumulation was moderate in

<sup>3</sup> As already shown (3), the relatively small amount of ferritin that leaks through the basement membrane over these intervals accumulates within the epithelium within various membrane-limited bodies (vesicles, vacuoles, multivesicular bodies, and dense bodies).

FIGURE 5

This figure shows a section through the wall of a glomerular capillary, and illustrates the topography of a deep cell (*D*) and its relationship to the lumen (*CP*), endothelium (*EN*), and basement membrane (*B*). Occasionally favorably oriented sections such as this indicate that these cells represent *intracapillary* elements irregularly interposed between the basement membrane and the superficial endothelium, being partially separated from the latter by an incomplete layer of spongy material (*S*). In several places (arrows) the deep cell cytoplasm is indented and spongy material occurs along the indentation. Sections taken at other levels through these cells, such as that indicated by the dotted line (*x-x*), would give the impression—frequently gained in micrographs (*e.g.* Figs. 3 and 4)—that the deep cells are located between two lumina. Actually the "two" lumina represent sections through the same lumen or that of a branching vessel.  $\times 32,000$ .



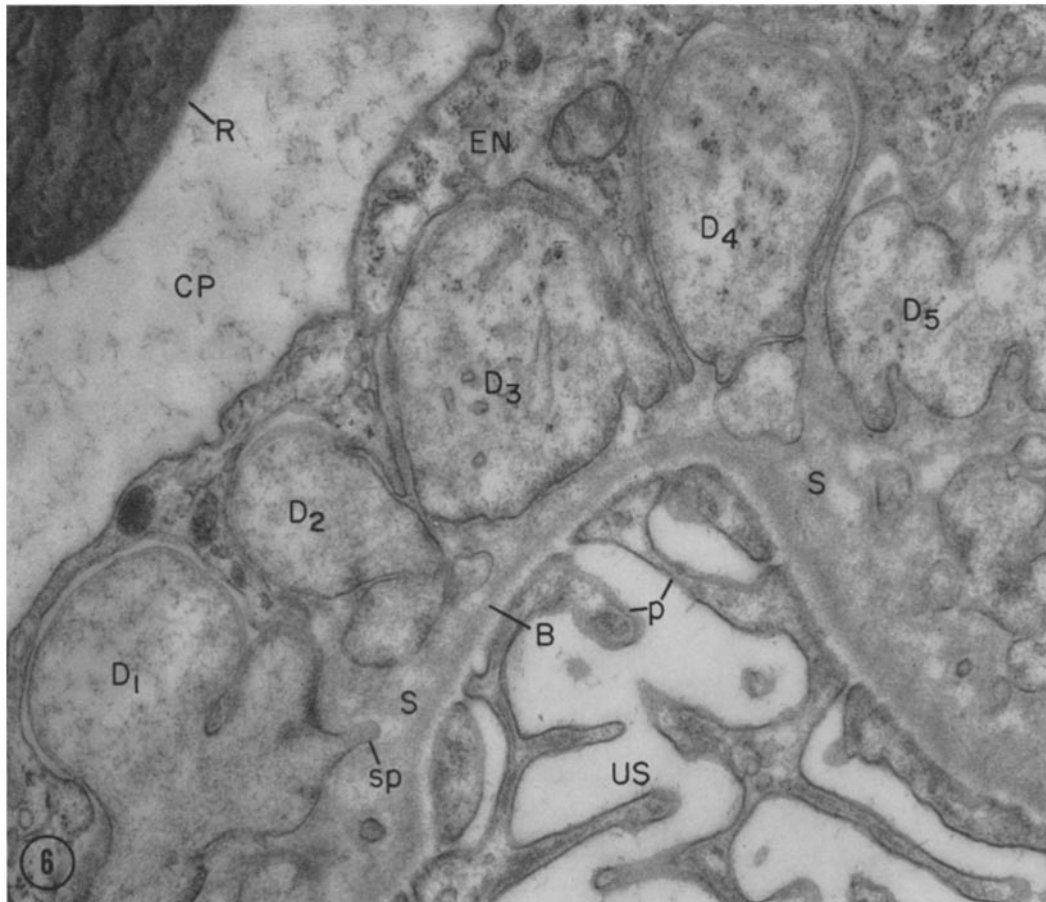


FIGURE 6

Here the plane of section cuts through five apparently isolated processes ( $D_1$  to  $D_5$ ) of one or more deep cells. The processes are separated near the lumen by penetrating expansions of the endothelium ( $EN$ ) and towards the basement membrane by spongy material ( $S$ ). It is presumed that these processes are formed in the manner shown in Fig. 5 (*i.e.* by indentation of the cytoplasm of a given cell) and that at least some of these processes belong to the same cell. Note that no adhesion plates occur between the deep cells and the superficial endothelium.  $\times 32,000$ .

the peripheral portions of the capillaries and pronounced in the spongy areas of the axial regions. There was considerable variation from one vessel to another in the number of accumulated particles, but in many fields the marker was seen distributed throughout the spongy areas from the cell membrane of the deep cells down to the basement membrane proper (Fig. 8). There was a striking contrast between these large accumulations and the few molecules present in the spongy area after short intervals. It should be emphasized that although ferritin particles seemed to penetrate freely the relatively loose, spongy

areas, their concentration fell off sharply at the level of the basement membrane proper (Fig. 8). In the latter they occurred at relatively low concentration in both the axial and the peripheral segments of the capillaries. The relationship of the tracer to the deep cells was similar to that found at earlier intervals except that, in addition to small pockets and channels, ferritin marked relatively large pockets which were partly filled with spongy material, invaginated deeply the cytoplasm, and were sometimes connected to the cell surface by a narrow neck. During this period there was also a progressive increase in the number of ferritin-

containing bodies present in the deep cell cytoplasm, and in some of these the marker appeared more concentrated than at earlier intervals. Each cell in a given field usually contained several bodies with ferritin at different concentrations: from some with a content comparable to the extracellular deposits to others with a content concentrated to a high density (Fig. 8). In addition, the concentration of ferritin within the same pocket or early absorption droplet varied considerably (Fig. 8). These findings suggest: that the incorporation of part of the spongy material precedes the piling of the tracer (or that tracer deposition is uneven); that the uptake of the ferritin masses in the spongy regions is a recurrent process, spread over a relatively long time; and that after incorporation the marker undergoes progressive concentration within the vacuoles of the deep cells. Along with their increased activities in the incorporation of ferritin, the deep cells showed other evidence of heightened activity: they appeared larger than at earlier intervals with longer cytoplasmic arms, and more frequent bulbous intraluminal pseudopodia (Fig. 9). In addition, cells identified as wandering elements (*i.e.* macrophages) were more often found in the glomerular capillary lumina or penetrating between the deep cells (Fig. 10).

At intervals of 2 to 10 days after ferritin injection, tracer molecules were seldom seen within the capillary lumen, or basement membrane, or piled against the basement membrane in the peripheral segments of the capillaries. Some molecules were still present within the spongy areas of axial regions, but during this period the amount of ferritin found therein progressively decreased (Fig. 11) so that by 10 days these regions were essentially "cleared." At these intervals membrane-limited bodies packed with ferritin molecules still occurred in the cytoplasm of the deep cells, and with the passage of time the content of increasing numbers of these bodies appeared more concentrated (Fig. 11) and more heterogeneous than at earlier intervals. In addition, some ferritin molecules appeared free in the cytoplasmic matrix. At the same time the deep cells showed unusually large numbers of RNP particles both "free" and attached to the membranes of the endoplasmic reticulum. The only other ferritin present within the glomerular capillary wall at these intervals occurred in the

epithelium, either within dense bodies or free within the cytoplasmic matrix.

## 2. NEPHROTIC ANIMALS GIVEN FERRITIN

The results of our study on ferritin transfer in the nephrotic rat were thoroughly treated in a separate paper (5). Here we will describe only those findings which pertain to the axial regions.

In the nephrotic glomerulus increased numbers of cells are characteristically found in these regions, due to an increase in the number of deep elements. Wandering cells are also more often interposed among the axial elements than is normally the case. In addition, the spongy areas between the basement membrane and the deep cells and among the latter are more voluminous and complex.

Within 5 to 15 minutes after ferritin administration large numbers of ferritin molecules were already found within these spongy areas. At 1 to 3 hours the axial ferritin deposits were extensive (Figs. 12 and 13), their size and concentration far exceeding those seen at any period in the normal. Furthermore, membrane-limited bodies packed with ferritin molecules were more numerous in the cytoplasm of the deep cells (Fig. 13) than at similar intervals in the normal animal.

Up to 44 hours after the injection of the tracer, the axial deposits of ferritin became progressively more extensive and more concentrated: they literally filled the voluminous spongy areas from the cell membrane of the deep cells down to the basement membrane proper (Fig. 14). (This is in contrast to normal animals in which ferritin deposits were maximal at 24 hours.) Concomitantly, the number of vacuoles, multivesicular bodies (Fig. 18), and dense bodies containing ferritin at varying concentrations increased within the cytoplasm of the deep cells (Fig. 14). Frequently a whole range of phagocytic vacuoles occurred in the same cell—from some with a ferritin concentration comparable to that of the extracellular deposits of the spongy areas to others in which the marker was highly condensed and tightly packed. As in the normal, these appearances suggest successive steps in the phagocytosis of the ferritin masses by the deep cells, only in this case the ferritin deposits were more massive and the process of incorporation typically occurred on a much larger scale—*i.e.*, by engulfment in very large pockets up to 2  $\mu$  in diameter.

By 4 days the size of the axial ferritin deposits

had begun to decline, and by 7 days the spongy areas were largely cleared. At these time points numerous dense bodies packed with ferritin were present in the deep cells. In some cases they were so numerous that they literally filled the cytoplasm, leaving little room for other organized elements. The content of many of these bodies appeared more concentrated and more heterogeneous than at earlier intervals. During the same period increasing numbers of ferritin molecules were found lying free in the cytoplasm of the deep cells; their actual numbers varied considerably from cell to cell, but frequently they were distributed throughout the matrix at relatively high concentration.

Thus, the findings after ferritin administration to nephrotic animals were similar to those in normals, except that the accumulations of the tracer were more massive, reached a peak at a later time (44 hours instead of 24 hours), and usually persisted longer.

### 3. NORMAL ANIMALS GIVEN COLLOIDAL GOLD AND THOROTRAST

We have also used colloidal gold (1) and thorotrast as tracers, but have found them less satisfactory than ferritin. Although both solutions

contain a suitable range of particle sizes (~50 to 200 Å) the micelles lack a definite recognizable structure. The concentration of colloidal gold particles achieved within the glomerular capillary lumina was, on the average, not nearly so high as in the case of ferritin, and the concentration of circulating particles declined much more rapidly. With thorotrast, the luminal concentrations were usually high, but intravascular precipitates or thrombi composed of thorium dioxide particles and finely fibrillar material (fibrin?) frequently occurred within the capillary lumina. Such intravascular deposits have been described previously after intravenous thorotrast injection (14). Regardless of these difficulties, the distribution of the colloidal gold and thorotrast in spongy areas and in the deep cells paralleled that of ferritin in normal animals, hence the findings are briefly described.

As early as 5 to 15 minutes after administration of either tracer, some particles were seen in the intercellular spaces between the superficial endothelium and the deep cells, or located in the spongy areas of the axial regions even in those animals with relatively low intraluminal concentrations of the tracer.

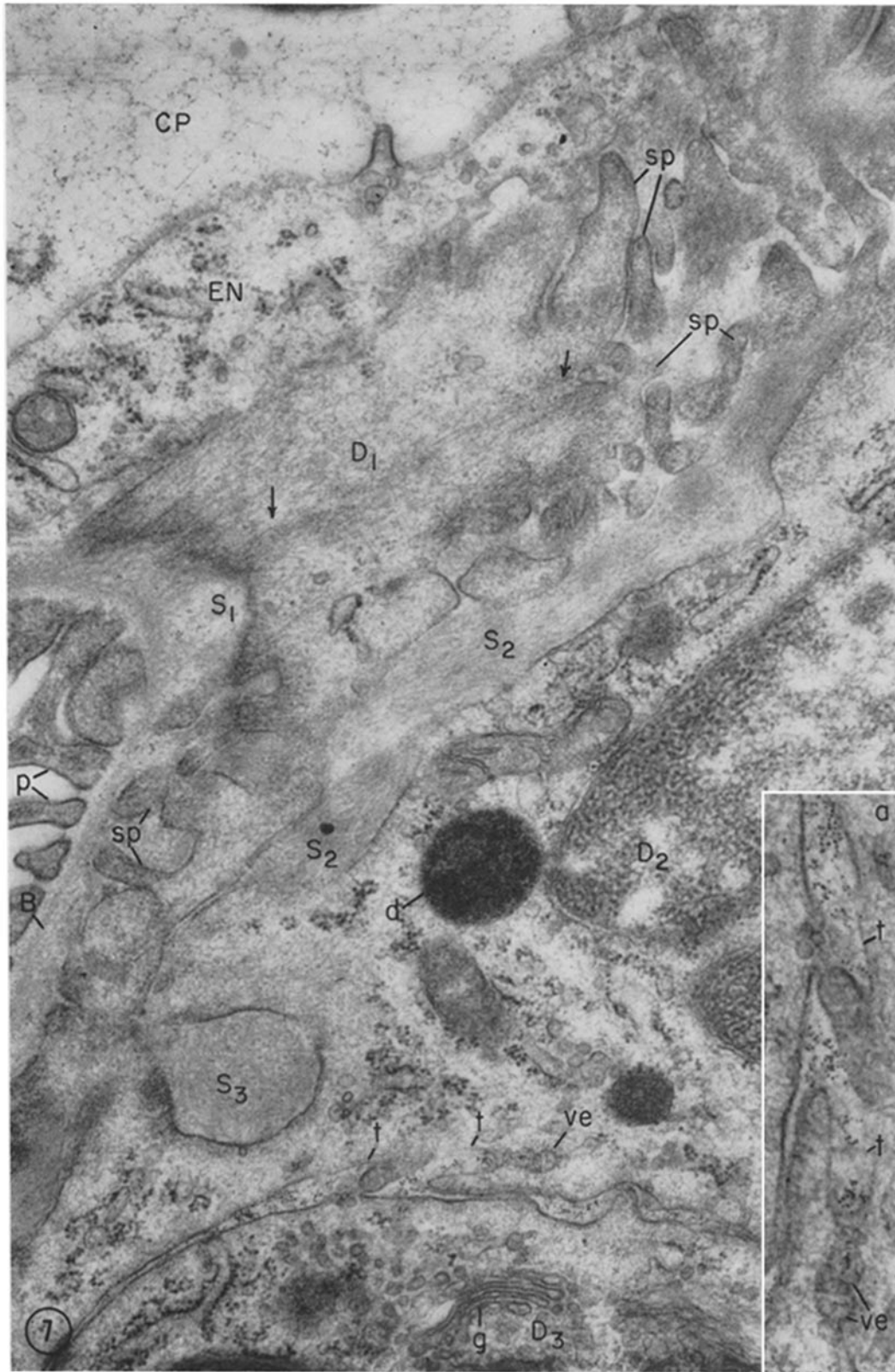
The principal new findings at intervals of 30

FIGURE 7

Glomerular capillary in a normal rat, 1 hour following ferritin administration. The lumen is located on the upper left and a cytoplasmic layer derived from the superficial endothelium (*EN*) is interposed between the lumen and portions of several deep elements (*D*<sub>1</sub> to *D*<sub>3</sub>) present below. The cell margins between *D*<sub>1</sub> and the superficial endothelium are indistinct due to the obliquity of the section. Spongy material is seen between the deep cells and the basement membrane (*S*<sub>1</sub>) and along the intercellular space (*S*<sub>2</sub>) between *D*<sub>1</sub> and *D*<sub>2</sub>. This material resembles the basement membrane but appears less compact and more distinctly fibrillar, as is evident at *S*<sub>2</sub>. Another spherical mass of spongy material (*S*<sub>3</sub>) deeply indents the cytoplasm of *D*<sub>2</sub>. *D*<sub>1</sub> shows numerous pointed processes (*sp*) which project into the spongy areas. These spinous processes appear considerably denser and more fibrillar than the remaining cytoplasm. At the arrows bundles of filaments are disposed perpendicular to the long axis of the cell as they run between opposite spinous pseudopodia.

Ferritin molecules are scattered throughout the spongy areas between the deep cells and the basement membrane (*e.g.*, to the left of *S*<sub>1</sub>). A number are also present in the intercellular space between *D*<sub>2</sub> and *D*<sub>3</sub>. The inset shows an enlargement of this area where some molecules are found in the channels (*t*) formed between the pointed processes of the deep cell, and a few occur within small vesicles (*ve*) located in the cytoplasm of this cell close to the base of the channels. Finally, many are condensed within a cytoplasmic dense body (*d*). These appearances suggest successive steps in a phagocytic process by which ferritin is engulfed in small pockets of the cell membrane, which become intracytoplasmic vesicles and finally merge into dense bodies (see also Fig. 8). × 36,000. Inset, × 61,000.





M. G. FARQUHAR AND G. E. PALADE *Third Cell Type in Renal Glomerulus* 69



minutes to 4 hours were the increased numbers of tracer particles in the axial intercellular spaces and spongy areas, and the frequent occurrence of thorotrast or gold particles within membrane-limited bodies (vesicles, vacuoles, multivesicular bodies, or dense bodies) in the cytoplasm of the deep cells (Figs. 1, 15–17). A few tracer particles were also found within the superficial endothelium located within small vesicles or within multivesicular bodies (Fig. 2). In the case of thorotrast there was a noticeable clumping of particles to form large aggregates (Fig. 17).

After 1 to 3 days, the only significant aggregations of gold particles in the glomerular capillary wall were located within membrane-limited bodies in the deep cells. Similarly, in animals given thorotrast, except for the massive intraluminal precipitates, tracer particles occurred only in cytoplasmic dense bodies in the deep cells. At these intervals many of the large, initially intraluminal deposits appeared to be intramural rather than intravascular, for they were partly or entirely surrounded by a thin layer of endothelium. The endothelium had apparently “grown over” the deposits, thereby isolating them from the lumen and facilitating their disposal by the deep cells.

#### 4. INCORPORATION OF TRACERS BY THE SUPERFICIAL ENDOTHELIUM

It should be stressed that in normal as well as in nephrotic animals all the tracers tested were also

incorporated by the superficial endothelial cells in which they occurred within small pinocytic vesicles, multivesicular bodies, and dense bodies. The presence of marked vesicles and multivesicular bodies was relatively frequent; that of dense bodies was less common. In all cases, however, this activity appeared to be so low as to be negligible, by comparison with that of the deep cells.

## DISCUSSION

### *The Third Type of Glomerular Cell*

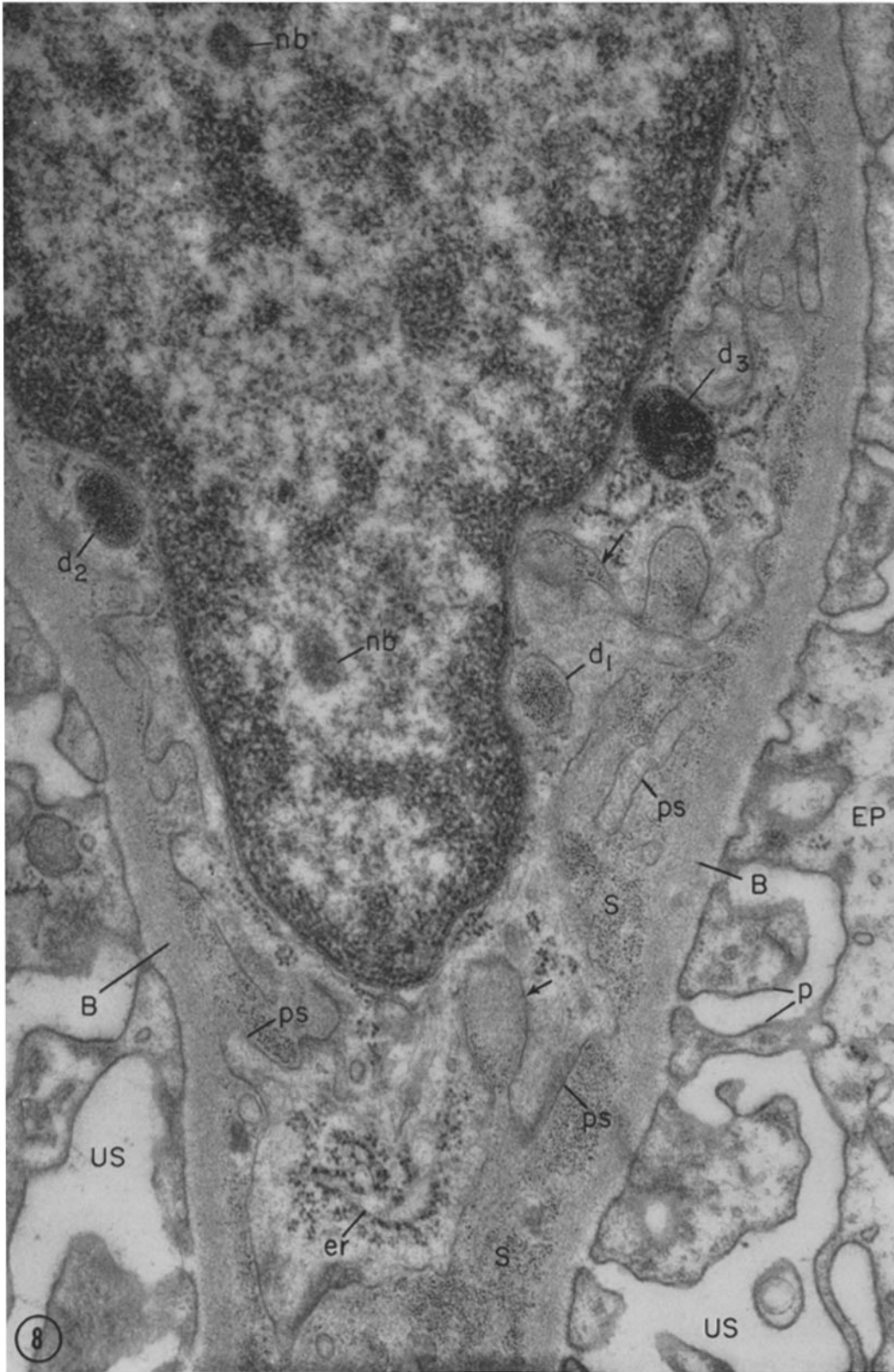
#### 1. HISTORY

Our observations have a direct bearing on the long and animated controversy regarding the number of cell types present in the renal glomerulus. Many researchers (*cf.* 15) believe that only two cell types—endothelial and epithelial—exist therein, but the presence of a third type has been repeatedly claimed (*cf.* 16, 15). A comprehensive and extensively discussed study of this third type was carried out on mammalian glomeruli by Zimmermann (17, 18), who concluded that the corresponding cells are fibroblasts which, together with their surrounding connective tissue stroma, form the mesangial stalk of the glomerulus. He described these mesangial cells as reaching the inner surface of the basement membrane and as being provided with pseudopodia or “Intrakapillarhockerchen” which protrude into the

---

FIGURE 8

Deep cell in a normal rat 1 day after ferritin administration. Ferritin molecules literally fill the spongy areas between the basement membrane and the deep cell, while their concentration falls off sharply in the basement membrane proper where they occur at relatively low concentration. The contours of the deep cell appear ruffled due to the presence of numerous processes (*ps*) of varied form. The spongy material packed with ferritin fills the space between the processes; some (arrows) deeply indent the cytoplasm and are connected to the cell surface by a narrow channel. Within the deep cell cytoplasm a whole spectrum of dense bodies can be seen: from some (*d*<sub>1</sub>), in which the ferritin appears at the same concentrations as in the extracellular deposits, to others in which the tracer is markedly concentrated (*d*<sub>2</sub>, *d*<sub>3</sub>), suggesting that the ferritin residues incorporated by the deep cells undergo progressive condensation within these bodies. The fact that some of the spongy masses deeply indenting the deep cell cytoplasm are partially free of ferritin suggests that the spongy material is incorporated in a manner similar to the ferritin residues (see also Fig. 7). Note that in many places a zone of ~100 Å along the surface of the cell membrane or along the membrane bounding the phagocytic pockets is free of ferritin. The bodies marked (*nb*), frequently encountered in the nuclei of deep cells, are distinct from nucleoli; their significance is unknown. × 43,000.



M. G. FARQUHAR AND G. E. PALADE *Third Cell Type in Renal Glomerulus* 71

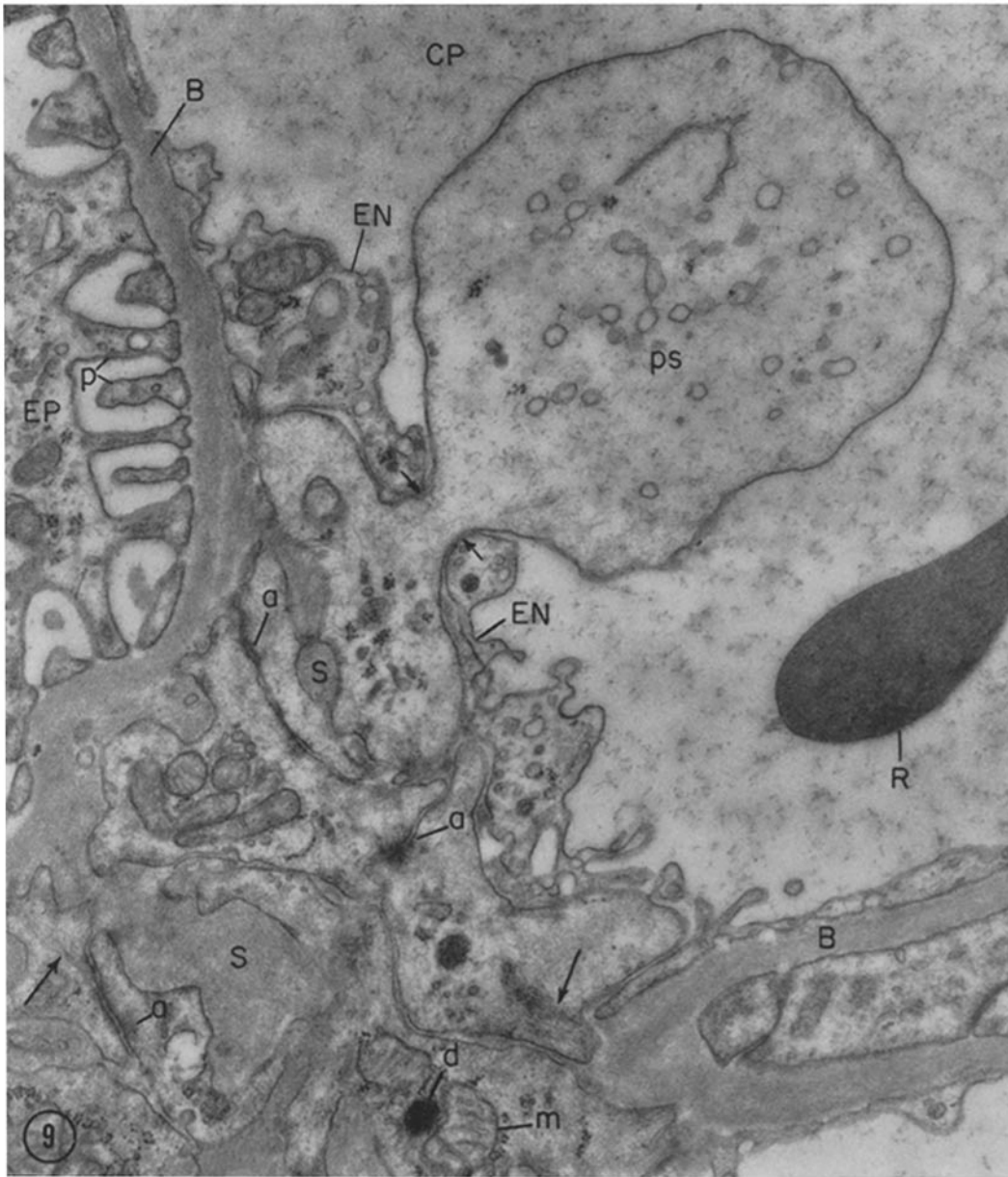


FIGURE 9

Part of a glomerular capillary in a normal animal 1 day after ferritin administration. A large, bulbous pseudopod from a deep cell projects through the superficial endothelium and reaches the circulating plasma. It is apparent that the short and narrow neck (marked by opposed short arrows) of such an intraluminal pseudopod will be missed in most sections, and its head will appear as a free intraluminal mass of cytoplasm (see Figs. 4 and 10). Several adhesion plates (*a*) are seen between adjoining deep cell processes on the lower left (see also Fig. 15). Faint filaments are seen throughout the deep cell cytoplasm and some of these appear to converge on the adhesion plates and on areas of increased density found along the cell membrane (long arrows).  $\times 28,000$ .

capillary lumina. With partial reservations, von Möllendorff (19, 20) accepted the existence of fibroblasts in the glomerulus. Further work indicated that the mesangium is more developed in avian and reptilian glomeruli (see von Möllendorff (20)).

Zimmermann's concept had considerable influence in embryology (*cf.* 16) and more recently in pathology where a number of workers—notably MacCallum (21), Kimmelstiel and Wilson (22), McManus (23), Jones (24), and Grishman and Churg (25)—localized to the mesangium the initial reactions of the glomerulus in a number of diseases (*e.g.*, diabetic glomerulosclerosis, glomerulonephritis, preeclampsia). However, neither the mesangial concept nor the associated concept of intercapillary disease gained general acceptance.

In recent years many aspects of the organization of the mammalian glomerulus have been clarified as a result of electron microscopic studies, and in the process some of the basic tenets of the original mesangial concept have been invalidated. For example, the contention that glomerular development proceeds by capsular invagination has been refuted, for it was found that all cells of the glomerular tuft develop *in situ* from primitive mesenchymal elements (26–28). It has also been established that there is only one glomerular basement membrane (not an endothelial and an epithelial basement membrane as had been suggested<sup>4</sup>), and that, accordingly, there is no residual intercapillary space. It was further shown that the epithelium is the only cell type which occurs outside the glomerular basement membrane, all other cells being *intracapillary* in the sense that they are located within the spaces bounded by the glomerular basement membrane. Notwithstanding these developments, the controversy about the third cell type remained unsettled (*cf.* 15 and 16), a situation explained by the fact that, in spite of some claims to the con-

<sup>4</sup> On the basis of light microscopic observations it was commonly believed (*e.g.* 18, 24, 25) that the glomerular basement membrane was comprised of two components: an endothelial basement membrane which was continuous with the internal elastic membrane of the afferent arteriole, and an epithelial basement membrane continuous with the basement membrane of Bowman's capsule. Normally these two elements were presumed to be fused into a single broad layer which could be split or spread apart in disease.

trary, there are no clear cut morphological differences between the cellular elements located on the luminal side of the basement membrane (4, 29). Moreover, until now there has been little direct evidence (*cf.* 29) to suggest any functional differences among these elements in the normal glomerulus. As a result, until a few years ago the majority of electron microscopists, including one of us (30, 31), regarded all elements located on the luminal side of the basement membrane as endothelial.<sup>5</sup> More recently, however, the view that a third cell type (or two types of endothelial cells) exists in the glomerulus has gained increasing support (5, 26, 28, 29, 35–38) on the basis of morphological studies. In addition, in uranyl nitrate-treated animals, Bencosme *et al.* (39) noted the development of collagen fibrils in close association with intercapillary cells and concluded on this basis that these cells are not only anatomically, but also functionally, distinct.

Our results convincingly demonstrate that one group of cells—those we have characterized topographically as deep cells—can be distinguished by their extensive phagocytic activity which strikingly exceeds that of the typical superficial endothelia. On the basis of their general morphology and their location within the glomerulus, these active phagocytes correspond in all probability to cells variously called “mesangial” (17, 18), “intercapillary” (22), “interstitial” (24), or “intraluminal” (16) by others.

## 2. MORPHOLOGY

Even among those electron microscopists who have postulated or affirmed that a distinctive third cell type does exist in the glomerulus (16, 28, 29, 32–38) there are differences of opinion about the morphology of these cells and their relationship to the lumen and basement membrane. We have therefore defined in some detail our morphological and topographical findings on this third element, recognizing that many of the fine structural features described have already been observed by others. For example, the usual isolation of the third cell from the lumen by the interposed superficial endothelium was described by Yamada (34), Pak-Poy (35), Suzuki (28), Benedetti and Marinozzi (36), Latta *et al.* (29), and Michaelson (38), and

<sup>5</sup> For a few exceptions see references 32–34. Mueller (15) can be consulted for a complete review of the literature up to 1958.

the presence of numerous, complicated cytoplasmic projections was recognized by all these workers. Although the intraluminal pseudopodia were clearly described and illustrated by Yamada under the name of "intracapillary colliculi" (after the Intrakapillarhöckerchen of Zimmermann (18)), and more recently by Michaelson (38), their presence has not been recognized by most investigators. Bergstrand and Bucht (40) have published micrographs illustrating cross-sectional views of the pale pseudopodia, but have assumed that they represent vesicles in the process of being discharged from the endothelium into the capillary lumen. We have observed that the intraluminal pseudopods occur more frequently after tracer injections. They are also more numerous under pathological conditions (unpublished observations). The fine fibrillar texture of the cytoplasmic matrix of the deep cells has been mentioned by others (34, 29), but the observation that the fibers are concentrated in the spinous pseudopodia and usually appear disposed perpendicular to the long axis of the cell is a new finding, as far as we are aware. Under normal conditions, structures connected with the phagocytic activity of the cell (*i.e.* vesicles, multivesicular bodies, vacuoles, and dense bodies) are present but not conspicuous. They dominate the scene when the cell is challenged. The barbs and fronds of spongy material found in the axial areas have most often been regarded as extensions of the basement membrane or basement membrane-like material. The distinctive nature of this material was previously recognized by Suzuki (28) under the name of "mesangial matrix" and by Pak Poy (35) and Latta *et al.* (29) who regarded it as "intercellular material" and "intercellular substance," respectively.<sup>6</sup> The spongy

<sup>6</sup> Actually Jones (41) had previously observed in

material is not only different in texture from the basement membrane, but it is also markedly more permeable to tracer particles than the latter, as shown by Latta *et al.* (29), and confirmed and extended by our results. Yet a clear cut distinction between the two formations is not entirely justified as long as the exact chemical nature and morphogenetic relationships of the two substances remain unknown, for both may essentially consist of the same material in two different states of packing. The fact that both basement membrane and spongy material are stained by periodic acid-silver methenamine methods (41-43) and probably also by PAS (*cf.* 29) suggests that the two substances are related. Moreover, since the contiguity of spongy material and basement membrane is general and the transition from compact to spongy texture is frequently gradual, the view (29) that the basement membrane of the glomerular capillaries never splits or branches in the axial regions seems unwarranted.

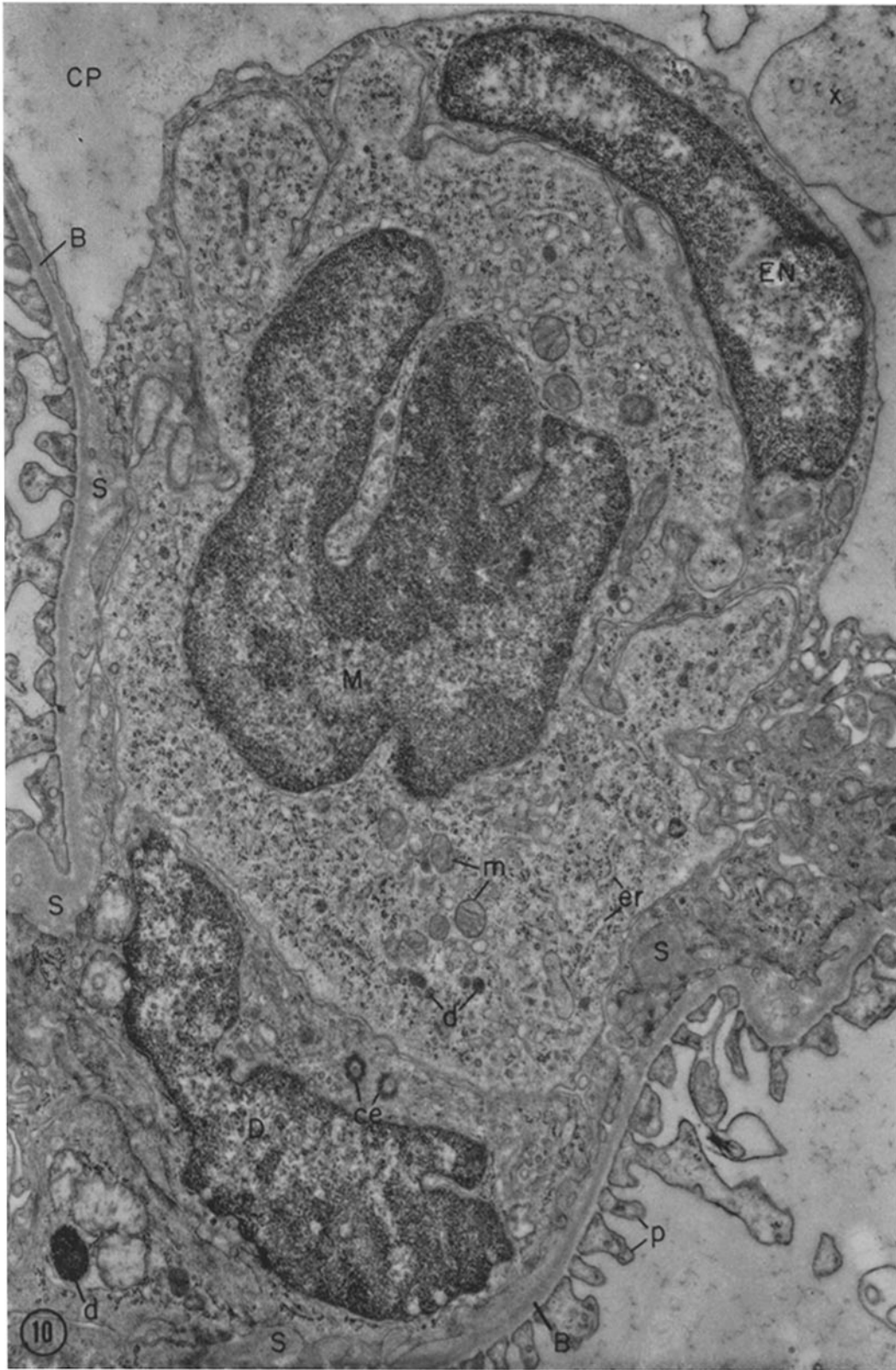
### 3. PHYSIOLOGY

Our observations indicate that in normal animals injected tracers—ferritin molecules or micelles of gold or thorotrast—gradually accumulate (within 30 to 60 minutes) in the less compact, inner strata of the basement membrane and in the spongy areas of the axial regions of the glomerular capillaries. The deep cells of these regions subsequently incorporate the residues together with the spongy material in which they are embedded. This phagocytic activity, characteristic of the

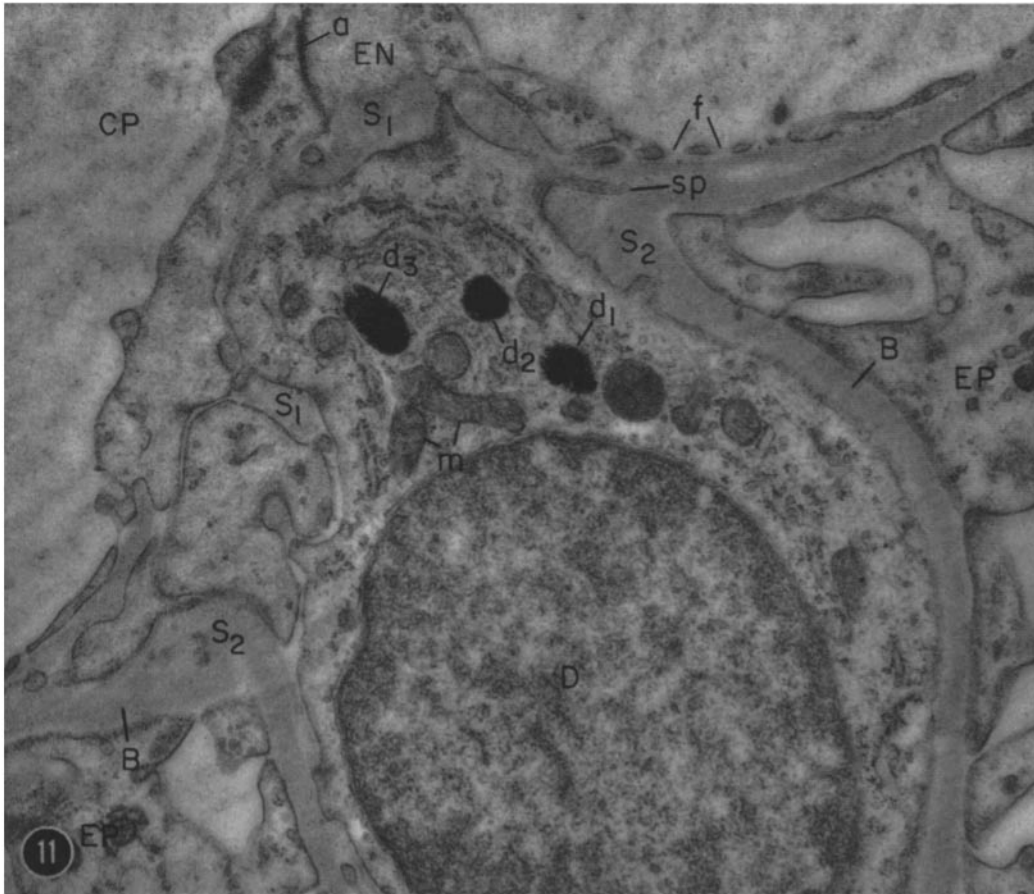
sections stained with periodic acid-silver methenamine and studied by light microscopy that the mesangial cells were surrounded by a fibrillar tissue ("fibromucin") which stained like the basement membrane but was of a "more irregular, spongy nature."

#### FIGURE 10

Axial region of a glomerulus in a normal rat 1 day after ferritin administration. A large cell (*M*) is insinuated in the intercellular space between a superficial endothelial cell above and a deep cell below, thereby compressing them. This cell represents an extrinsic, probably hematogenous element, for it can be identified as a monocyte or a transitional form to a macrophage, by virtue of its broad cytoplasmic ruffles, relatively smooth external contours (devoid of filiform or spinous processes) and the form and distribution of its cytoplasmic components. The mass of cytoplasm seen at *x* probably represents an intraluminal pseudopod of a deep cell whose connection to the cell body is not evident at this level (see Fig. 9).  $\times 21,000$ .



M. G. FARQUHAR AND G. E. PALADE *Third Cell Type in Renal Glomerulus* 75



**FIGURE 11**

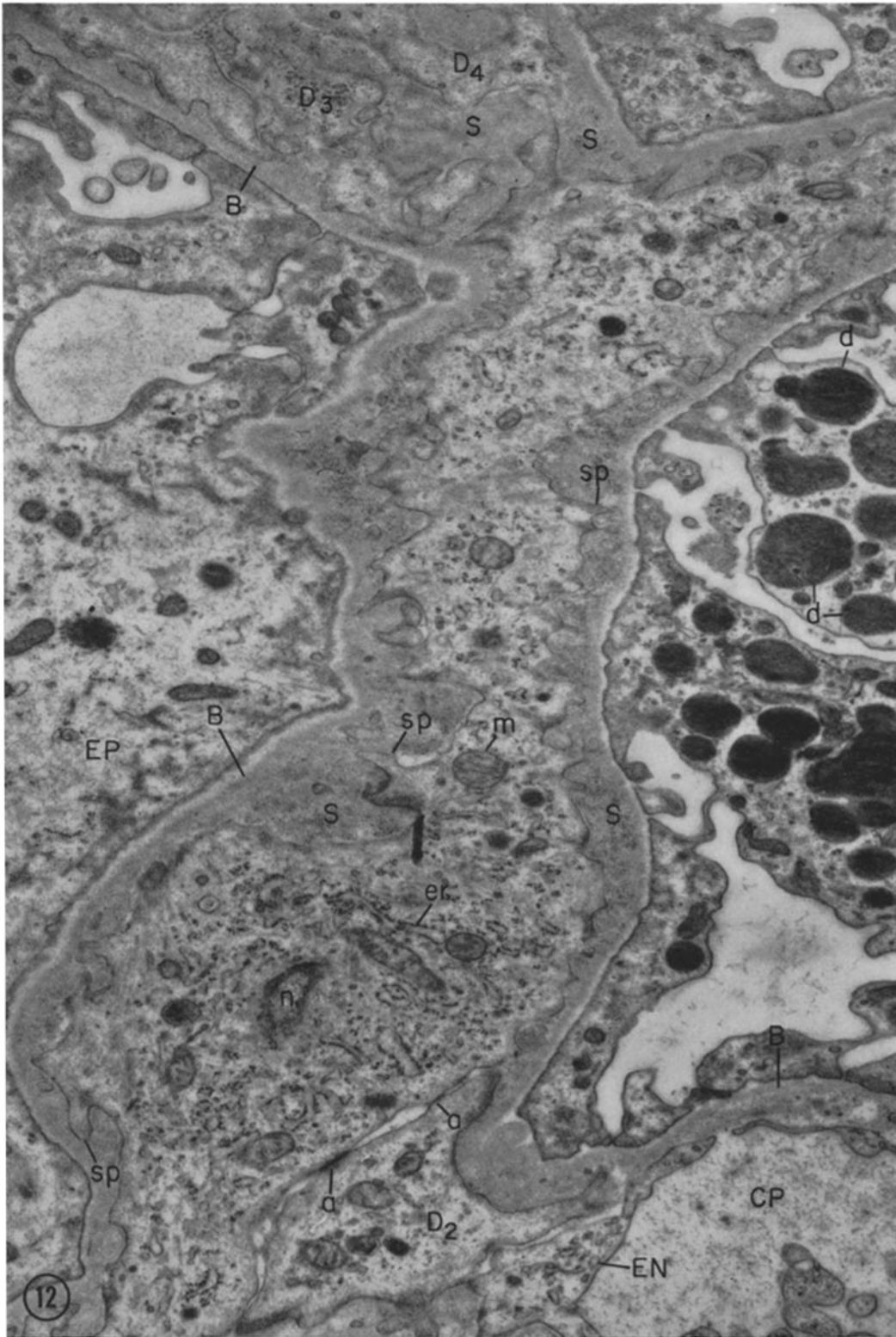
Deep cell in a normal rat 4 days after ferritin administration. No ferritin is present in the spongy areas ( $S_1$ ) found between this cell and the endothelium ( $EN$ ) or in similar areas ( $S_2$ ) located between it and the basement membrane ( $B$ ), but several dense bodies packed with ferritin ( $d_1$  to  $d_3$ ) are still present in the cytoplasm of the deep cell. The ferritin in the dense bodies appears more concentrated than at earlier intervals.  $\times 25,000$ .

**FIGURE 12**

Field from the glomerulus of a nephrotic rat 1 hour after ferritin. The cell body of a deep cell containing a small segment of the nucleus ( $n$ ) is present near the lower part of the field, and an exceptionally long cytoplasmic arm (trabecula) can be followed, extending from the region of the cell body up into the upper right corner. The contours of the deep cell are extremely irregular due to the presence of numerous cytoplasmic processes ( $sp$ ) of varied, mostly spinous, form. Spongy material ( $S$ ) containing numerous ferritin molecules occupies the area between the deep cell margins and the basement membrane. Two adhesion plates ( $a$ ) can be seen between the large cell and a branch of another deep cell ( $D_2$ ) present below. Trabeculae ( $D_3$ ,  $D_4$ ), probably belonging to other deep cells, appear in the upper left corner.

The epithelium in this figure and Figs. 14 and 15 shows several changes associated with the nephrotic condition: loss of its foot processes with concomitant reduction in the number of intervening slits, and accumulation of dense bodies ( $d$ ) in the cytoplasm.  $\times 12,000$ .





M. G. FARQUHAR AND G. E. PALADE *Third Cell Type in Renal Glomerulus* 77



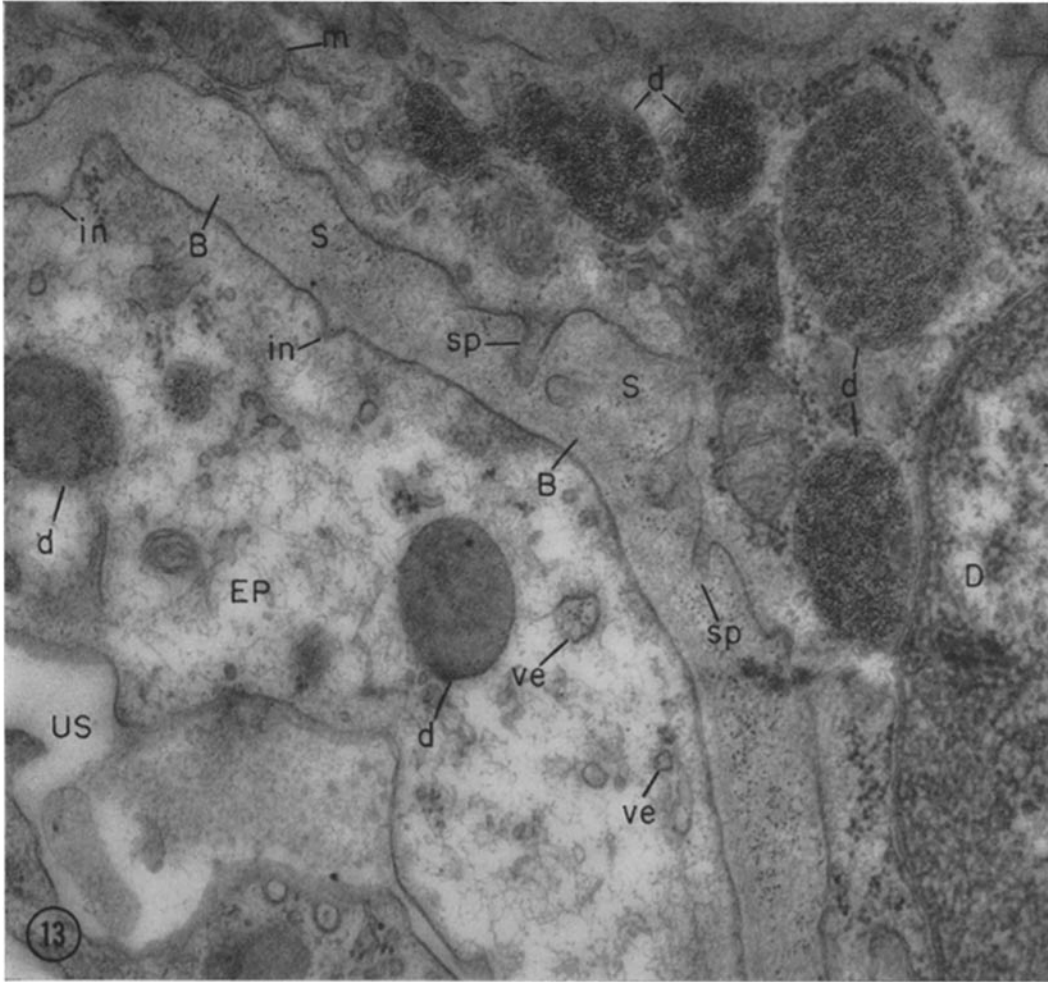


FIGURE 13

Part of the glomerular capillary in a nephrotic rat 1 hour after ferritin administration. A deep cell (*D*) appears above and to the right and a portion of an epithelial cell (*EP*) is present on the lower left. Large amounts of ferritin occur in the spongy areas (*S*) between the basement membrane (*B*) and the deep cell, and numerous ferritin-containing dense bodies with heterogeneous content (*d*) are present within the cytoplasm of the deep cell. Some ferritin is also seen within the epithelium: within small invaginations (*in*) of the plasmalemma facing the basement membrane, within small cytoplasmic vesicles (*ve*), and within several dense bodies (*d*).  $\times 49,000$ .

deep cells, becomes manifest a few minutes after the injection of the tracer, reaches a peak within a few hours, and starts declining after 1 to 2 days. By 4 days practically all residues are cleared from the spongy areas of the basement membrane.

In normal animals the tracer is incorporated into the deep cells primarily by means of small membrane invaginations which, as in the incorporation cycle in other cells (2, 5, 44), coalesce

into large vacuoles. Less frequently the tracer is incorporated in larger pockets which become internalized forming intracellular vacuoles. Some of these pockets remain for a time connected to the surface through long narrow channels, reminiscent of the pinocytic channels described in amoebae (45). In either case the resultant cytoplasmic vacuoles subsequently undergo progressive condensation into "dense bodies." The con-

densation phase is strikingly demonstrated by the progressive increase in the intravacuolar concentration of the marker. In the case of ferritin, the only tracer studied over a relatively long period, the dense bodies marked by the tracer decrease in number after 4 days and are less frequently encountered by the 10th day. The fate of the incorporated ferritin cannot be determined with certainty. However, the occurrence after several days of dense bodies with a heterogeneous content and the appearance of free ferritin in the cytoplasmic matrix of the deep cells by day 4 suggest that ferritin is "digested" or degraded and its iron reutilized in newly synthesized ferritin molecules. A similar sequence of events apparently occurs in the glomerular epithelial cells (5).

In nephrotic animals the sequence of events is generally the same except that the ferritin deposits are considerably larger, their incorporation proceeds predominantly by means of larger pockets, 1 to 2  $\mu$  in diameter, and their clearance from the spongy areas is slower. The occurrence of larger deposits in nephrotic animals and their persistence in the spongy areas for longer periods may result either from an increase in the rate of accumulation of ferritin residues (*i.e.*, increased filtration)<sup>7</sup> or a decrease in their rate of removal. In regard to the latter possibility it is conceivable that the puromycin-aminonucleoside used to induce this syndrome interferes with the metabolism of the deep cells and depresses their activity,\* for this substance is known to inhibit protein synthesis (*cf.* 5)). With the information at hand, however, it is impossible to decide which of these two alternatives is more likely. The change from the predominantly microphagic activity in the normal to the macrophagic activity exhibited by the deep cells in nephrotic glomeruli probably represents a response to the magnitude of the challenge.

On the basis of our findings it may be assumed that other filtration residues, such as plasma proteins, lipid droplets (see Fig. 15) and antigen-antibody complexes (46), which accumulate against the glomerular basement membrane under normal or pathological conditions, are handled by the deep cells in the same way as our experimental tracers. Indeed, observations on

<sup>7</sup> In this case the increase in filtration rate should be large enough to offset increased leakage through the basement membrane (5).

human renal biopsies suggest that the "fibrinoid" material deposited against the basement membrane in certain diseases (*e.g.* preclampsia (47)<sup>8</sup> and disseminated lupus erythematosus (unpublished observations)) is removed from the capillary wall in a similar manner.

Our results suggest, therefore, that the deep cells—by removing residues of filtration—continually unclog and recondition the basement membrane or principal glomerular filter (3, 5). In addition we have noted that along with the filtration residues the deep cells incorporate the material which forms the less compact inner layers of the basement membrane and fills the spongy areas of the axial regions. Apparently they ingest such material in both normal and nephrotic animals even in the absence of visible deposits. Hence our observations further suggest that the deep cells normally operate at the removal end of a turn-over process by which the glomerular filter is continually renewed.

An uncertain point in our interpretation concerns the mechanisms involved in transport of residues from the peripheral regions of the capillaries, where they first appear, to the deep regions where spectacular accumulations develop. The usually continuous endothelium and the intricate system of intercellular spaces in these regions may help in trapping tracer particles, but with the information at hand it cannot be decided whether blood currents or the fenestrated part of the endothelium sweeps the tracer "under the rug."

The demonstration of the extensive phagocytic activity of the deep cells can be correlated with earlier observations carried out by light microscopy which describe the accumulation of thorotrast (14), colloidal iron oxide (48) and colloidal carbon (49), in the glomerulus presumably by endothelial phagocytosis. A paper by Bencosme *et al.* (39) suggests that, in addition to the phagocytic activity noted here, the deep cells are involved in the deposition of collagen in the glomerulus under certain conditions. More recently Latta (50) has shown that a small number of collagen fibrils can be demonstrated in the vicinity of intracapillary cells by PTA staining in

<sup>8</sup> At the time this article was written the distinctive nature of the deep cell was not recognized and the removal of the dense deposits was attributed to the endothelium as a whole.

apparently normal rats.<sup>9</sup> This question bears directly on the nature and origin of the deep cells.

#### 4. NATURE OF THE THIRD CELL TYPE

As already stated, the deep cells represent a cell population which is neither homogeneous nor stable. Moreover, under appropriate conditions cellular elements of hematogenous origin can gain access to the intercellular spaces of the axial regions. It is clear, however, that normally the dominant type in this population, described in detail in this study, is not a fibroblast, as assumed in the older literature (17-20). The lack of an extensively developed, rough surfaced endoplasmic reticulum characteristic of fibroblasts (*cf.* 51, 52) and the intensity of phagocytosis are the main arguments supporting this conclusion. The rather mixed morphological features of the cell explain why it has been variously considered an endothelial (16) or smooth muscular (34, 38)<sup>10</sup> element in recent electron microscopic studies. Our observations render rather improbable such derivations, primarily because of the extent of

<sup>9</sup> Collagen fibrils had previously been noted in frog glomeruli by Yamada (61), but were generally assumed to be absent from normal mammalian glomeruli (*cf.* 29).

<sup>10</sup> According to our observations, which are by necessity limited, on the normal arrangement at the vascular pole of the glomerulus, smooth muscle cells, clearly recognizable as such, stop at the point of penetration of the afferent and efferent vessels into the corpuscle.

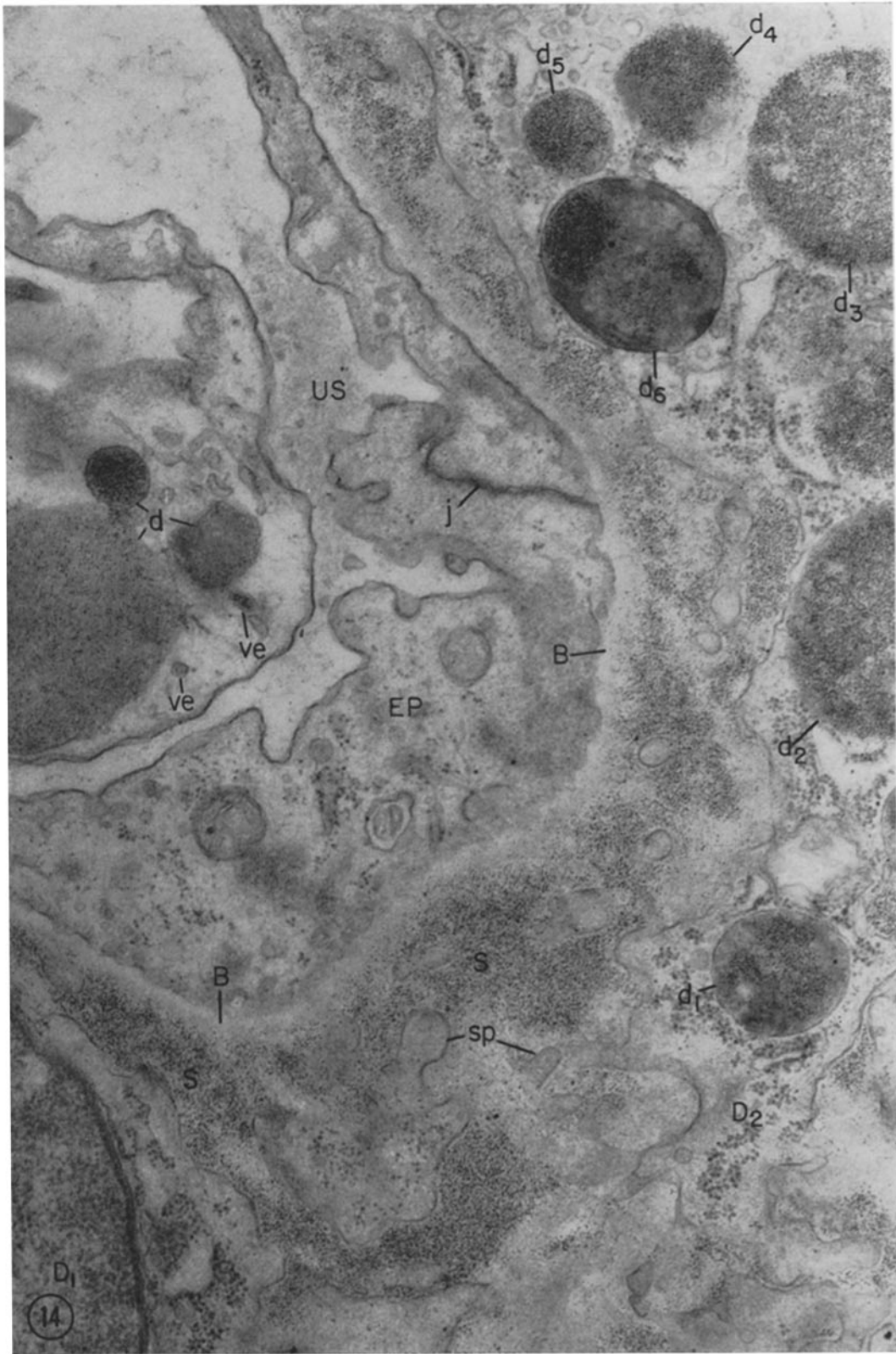
the phagocytic activity. Moreover, they indicate that the cell type in question is, in many respects, similar to a fixed pericyte (53). Indeed, it has in common with such cells: (*a*) a characteristic relationship with the endothelium and the basement membrane: it is located between leaflets of basement membrane or related material which separate it completely from the adventitia (epithelium in this case) and only partially from the endothelium; (*b*) a particular cytoplasmic texture characterized by fine fibrils in the cytoplasmic matrix which converge within spinous (or filiform) pseudopodia; and (*c*) considerable phagocytic activity when challenged. Yet the analogy is not complete: the leaflets which separate the deep cells from the endothelium are more tenuous and of looser texture than their counterparts in other capillaries (*cf.* 8), and the phagocytic activity of the deep cells is noticeably greater than that of usual pericytes. Moreover no intracapillary colliculi have been described so far for the pericytes of other capillary vessels.

As previously indicated, among the minority elements in the deep cell population, monocytes, transitional forms to macrophages, and fully developed macrophages can be recognized with some confidence. Migratory elements, such as lymphocytes and granulocytes, may be encountered under pathological conditions. Typical fibroblasts have not been seen in our material. The possibility that they may represent a small, difficult to detect minority in the deep cell population cannot be ruled out. Alternatively collagen

FIGURE 14

Axial region of a glomerulus in a nephrotic rat 12 hours after ferritin administration, showing massive deposits of the tracer in the spongy areas of an axial region and segregated within numerous large dense bodies of heterogeneous composition ( $d_1$  to  $d_6$ ) in the cytoplasm of a deep cell. Several deep cells ( $D_1$ ,  $D_2$ ) showing numerous complicated cytoplasmic processes are seen to the right and below. A continuous epithelial layer interrupted only by a single cell junction ( $j$ ) is seen to the left covering the outer surface of the basement membrane. Note that while the ferritin seems to penetrate freely the relatively loose spongy areas, its concentration falls off sharply at the level of the basement membrane proper ( $B$ ). Several small vesicles ( $ve$ ) and dense bodies ( $d$ ) containing ferritin are also present in the epithelial cytoplasm.

Note also the heterogeneity of the dense bodies in the deep cell as well as those in the epithelium (see also Fig. 13). The tracer concentration varies not only from one dense body to another, but also within the same dense body (*e.g.*,  $d_1$ ,  $d_6$ ). Moreover, in many of these there are masses of material partially or completely free of ferritin. The findings suggest that such composite or heterogeneous bodies arise as a result of fusion of absorption droplets of different ages, some of them antedating the incorporation of the tracer.  $\times 30,000$ .



M. G. FARQUHAR AND G. E. PALADE *Third Cell Type in Renal Glomerulus* 81

synthesis may be a liminal or rarely expressed activity of the deep cells.

The deep cells respond to stimulation in two distinct ways: (a) by an increase in phagocytic activity which, in our experiments, roughly parallels the accumulation of tracer particles in spongy areas, and (b) by an increase in total population. A similar response can probably be elicited by other filtration residues such as antigen-antibody complexes (46), globulins (54, 55) and fibrin (55), which are deposited in the glomerulus. Thus the hypertrophy and increase in number of these cells upon challenge could explain, at least in part, the glomerular hypercellularity and increased prominence of axial regions associated with many renal diseases. With the information at hand it is not possible to decide whether this cellular increase is due entirely to a migration of wandering elements or whether local cell multiplication may also contribute.

### General Cytological Implications

In addition to the problems of special interest already discussed, there are, in our observations, a few points of wider cytological import which deserve to be mentioned: the first concerns the indication that cell differentiation is more diverse and more finely graded than currently assumed,

as exemplified by our difficulty in classifying the third cell type found in the glomerulus.

The second point relates to the wide-spread phenomenon of incorporation of matter "in bulk" by various cells: there are three types of cells in the glomerulus and each exhibits this activity to some degree. Moreover, a given cell type (*i.e.* the deep cell) can shift, under certain conditions, from incorporation by small pockets ( $d = 700 \text{ \AA}$ ), currently described as "micro-pinocytosis," to incorporation by large pockets ( $d \geq 2 \mu$ ), usually termed "phagocytosis." Since in both cases the same marker is involved, the finding emphasizes again (see (2) and (45)) the arbitrary distinction between pinocytosis and phagocytosis and indicates the desirability of appropriate adjustments in concepts and terminology.

The third and final point of general cytological interest is more specific: it concerns the finding that the so-called "multivesicular bodies" (56), structures of wide-spread occurrence among animal cells, are rapidly and regularly marked by all the tracers used in our experiments. The segregation of tracers within multivesicular bodies is a finding which applies not only to the third cell type but also to glomerular endothelial (Fig. 2) and epithelial cells (3, 5). It has also been

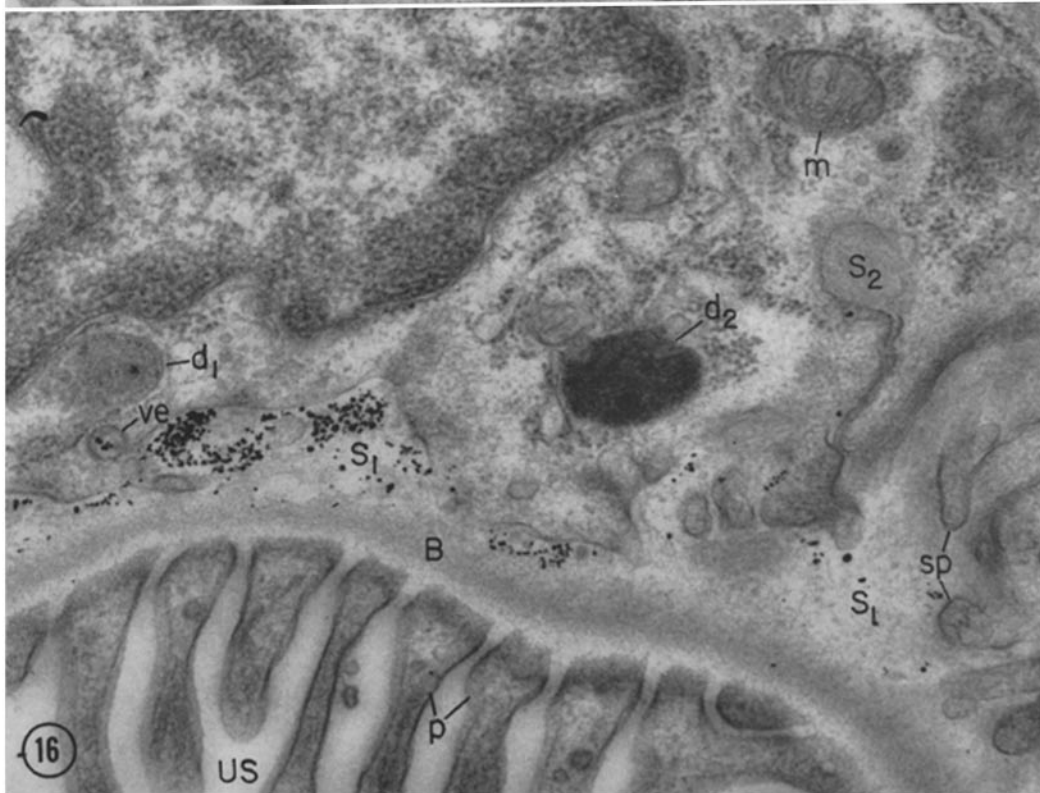
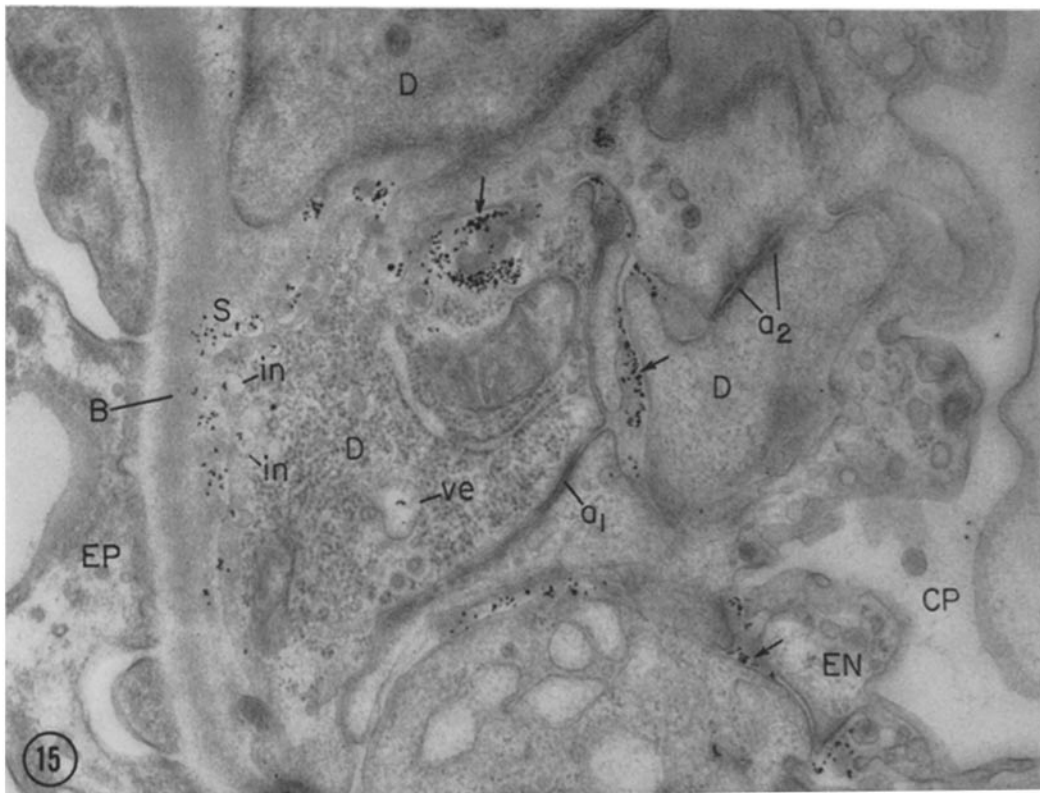
---

FIGURE 15 AND 16

Fields from the glomeruli of a rat 30 minutes after an I.V. injection of colloidal gold.

In Fig. 15 the lumen occurs to the right and the basement membrane and epithelium to the left. Particles of colloidal gold are found along the intercellular spaces between the superficial endothelium (*EN*) and deep elements (lower arrow); along similar intercellular spaces between deep elements (central and upper arrows); and in the spongy regions (*S*) between the basement membrane and deep cell membrane. A few particles are also seen within invaginations (*in*) of the deep cell membrane or apparently segregated into small vesicles (*ve*) in the deep cell cytoplasm. Several large ( $\sim 600 \text{ m}\mu$ ) globules—presumed to represent larger lipoprotein elements of the plasma—are also found in the spongy areas and intercellular spaces (upper arrow). Several adhesion plates (*a*<sub>1</sub>, *a*<sub>2</sub>), characterized by increased density of the apposed cell membranes and immediately subjacent cytoplasmic matrix, can be seen along the intercellular spaces between adjoining deep elements. Delicate cytoplasmic filaments are seen to converge on the adhesion plate labeled *a*<sub>2</sub>.  $\times 33,000$ .

In Fig. 16 the cell body of a deep cell is shown above and the basement membrane and a row of epithelial foot processes is present below. Gold particles are found in the spongy areas (*S*<sub>1</sub>) between the deep cell processes and the basement membrane, and within the deep cell segregated into a small vesicle (*ve*) and a dense body (*d*<sub>1</sub>). Another dense body (*d*<sub>2</sub>) with a heterogeneous content not marked by gold particles is also present in the cytoplasm. At *S*<sub>2</sub> a spongy area occurs in an indentation of the deep cell cytoplasm.  $\times 37,000$ .



noted in the endothelia of other capillaries (8). The functional role of the multivesicular bodies has remained highly speculative. It has been variously suggested that they may participate in the formation and liberation of cytoplasmic vesicles (56); that they may be involved in the formation of secretion droplets (57, 58); or that they are related to lysosomes (57, 44). Our observations show that these bodies (like phagocytic vacuoles and various cytoplasmic dense bodies) are connected with the circuit by which matter is incorporated into the cell in bulk. The marker is apparently transported from the surrounding medium to the multivesicular bodies by small vesicles formed at the expense of the cell membrane. In this connection it should be mentioned that the tracer particles usually occur within the general cavity of the body rather than within the contained vesicles. Our findings suggest that the multivesicular bodies eventually become "absorption droplets" by progressive accumulation and condensation of imported materials and

possibly by mergence with other dense bodies, but the exact mechanism of this transformation as well as the ultimate fate of these bodies remain to be properly established.

*Note Added in Proof.* A general depression of phagocytic activity (see asterisk, p. 79) can be associated with the adrenal hypertrophy recently reported by Reinhardt (*Anat. Rec.*, 1962, 142, 271) in aminonucleoside nephrosis. Cortisone, expected to be produced in excess by hypertrophic adrenals, is known (Heller, *Endocrinology*, 1955, 56, 80) to depress the phagocytic activity of reticulo-endothelial cells.

Part of this work was presented at the First Annual Meeting of the American Society for Cell Biology, Chicago, November 2 to 4, 1961.

We gratefully acknowledge the technical assistance of Mrs. Jacqueline Mach and Miss Sally Westerhoff.

This investigation was supported by a research grant (H-5648) from the National Institutes of Health, United States Public Health Service.

*Received for publication, December 15, 1961.*

#### REFERENCES

1. FARQUHAR, M. G., and PALADE, G. E., Behavior of colloidal gold particles in the glomerulus, *Anat. Rec.*, 1959, 133, 378.
2. FARQUHAR, M. G., and PALADE, G. E., Segregation of ferritin in glomerular protein absorption droplets, *J. Biophysic. and Biochem. Cytol.*, 1960, 7, 297.
3. FARQUHAR, M. G., WISSIG, S. L., and PALADE, G. E., Glomerular permeability. I. Ferritin transfer across the normal glomerular capillary wall, *J. Exp. Med.*, 1961, 113, 47.
4. FARQUHAR, M. G., round table discussion on the morphological basis of glomerular ultrafiltration, in *Proceedings, First International Congress of Nephrology* (G. Richet, editor), Basel, S. Karger, 1961, 357.

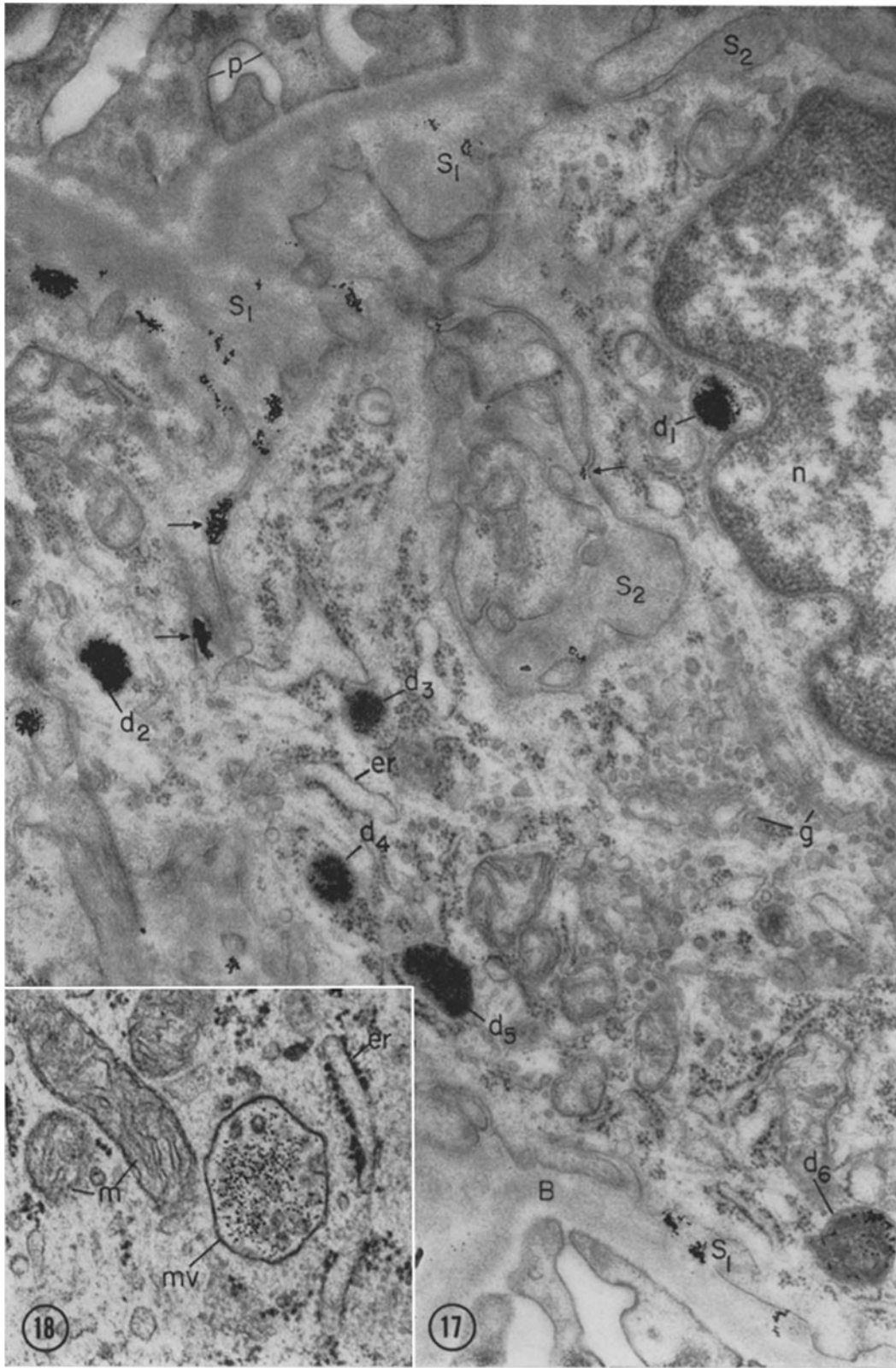
FIGURE 17

Deep cell and associated structures in a normal rat 4 hours after an I.V. injection of thorotrast. Part of the nucleus is present on the upper right, and the centrosphere region with numerous piles of smooth surfaced Golgi membranes (*g*) and vesicles is shown on the lower right. A cytoplasmic trabecula extends from the Golgi region to the left and above. Clumps of thorotrast particles are present along clefts in the deep cell cytoplasm (arrows). They are also scattered along the spongy regions (*S*<sub>1</sub>) between the deep cell and the basement membrane, on the upper left and lower right. Numerous thorotrast particles are also concentrated within dense bodies (*d*<sub>1</sub> to *d*<sub>6</sub>) of various sizes in the deep cell cytoplasm. One of these (*d*<sub>6</sub>) has a more heterogeneous content than the others. *S*<sub>2</sub> marks masses of spongy material located in deep infoldings of the cell membrane. × 41,000.

FIGURE 18

Multivesicular body (*mv*) from a deep cell in a nephrotic rat (12 hours after ferritin administration). Numerous ferritin molecules occur within the body, primarily within its general cavity rather than within the small vesicles it contains. × 77,000.





M. G. FARQUHAR AND G. E. PALADE *Third Cell Type in Renal Glomerulus* 85



5. FARQUHAR, M. G., and PALADE, G. E., Glomerular permeability. II. Ferritin transfer across the glomerular capillary wall in nephrotic rats, *J. Exp. Med.*, 1961, 114, 699.
6. LUFT, J. H., Improvements in epoxy resin embedding methods, *J. Biophysic. and Biochem. Cytol.*, 1961, 9, 409.
7. BENNETT, H. S., LUFT, J. H., and HAMPTON, J. C., Morphological classifications of vertebrate blood capillaries, *Am. J. Physiol.*, 1959, 196, 381.
8. PALADE, G. E., Blood capillaries of heart and other organs, *Circulation*, 1961, 24, 368.
9. FARQUHAR, M. G., Fine structure and function in capillaries of the anterior pituitary gland, *Angiology*, 1961, 12, 270.
10. FARQUHAR, M. G., and PALADE, G. E., Tight intercellular junctions, Abstracts of papers presented at the First Annual Meeting of the American Society for Cell Biology, Chicago, November 2 to 4, 1961, 57.
11. PEASE, D. C., and MOLINARI, S., Electron microscopy of muscular arteries; pial vessels of the cat and monkey, *J. Ultrastructure Research*, 1960, 3, 447.
12. FAWCETT, D. W., Intercellular bridges, *Exp. Cell Research*, 1961, suppl. 8, 174.
13. KARRER, H. E., Electron microscopic study of the phagocytosis process in lung, *J. Biophysic. and Biochem. Cytol.*, 1960, 7, 357.
14. McCLUSKEY, R. T., ZWEIFACH, B. W., ANTOPOL, W., BENACERRAF, B., and NAGLER, A. L., Pathogenesis of experimental shock. I. Absence of morphologic evidence for bacterial endotoxemia, *Am. J. Path.*, 1960, 37, 245.
15. MUELLER, C. B., The structure of the renal glomerulus (review), *Am. Heart J.*, 1958, 55, 304.
16. KURTZ, S. M., and McMANUS, J. F. A., A reconsideration of the development, structure, and disease of the human renal glomerulus, *Am. Heart J.*, 1959, 58, 357.
17. ZIMMERMANN, K. W., Über den Bau des Glomerulus der menschlichen Niere *Z. mikr.-anat. Forsch.*, 1929, 18, 520.
18. ZIMMERMANN, K. W., Über den Bau des Glomerulus der Säugerniere. Weitere Mitteilungen, *Z. mikr.-anat. Forsch.*, 1933, 32, 176.
19. VON MÖLLENDORFF, W., Über Deckzellen und Bindegewebe im Glomerulus der menschlichen Niere, *Z. Zellforsch. u. mikr. anat.*, 1930, 11, 16.
20. VON MÖLLENDORFF, W., Handbuch der mikroskopischen Anatomie des Menschen, Berlin, J. Springer, 1930, 7, part 1.
21. MACCALLUM, W. G., Glomerular changes in nephritis, *Bull. Johns Hopkins Hosp.*, 1934, 55, 416.
22. KIMMELSTIEL, P., and WILSON, C., Intercapillary lesions in the glomeruli of the kidney, *Am. J. Path.*, 1936, 12, 83.
23. McMANUS, J. F. A., Medical Diseases of the Kidney, Philadelphia, Lea and Febiger, 1950.
24. JONES, D. B., Inflammation and repair of the glomerulus, *Am. J. Path.*, 1951, 27, 991.
25. GRISHMAN, E., and CHURCH, J., Acute glomerulonephritis. A histopathologic study by means of thin sections, *Am. J. Path.*, 1957, 33, 993.
26. HALL, B. V., and ROTH, L. E., Preliminary studies on the development and differentiation of cells and structures of the renal corpuscle, Proceedings Stockholm Conference on Electron Microscopy, New York, Academic Press, Inc., 1957, 176.
27. KURTZ, S. M., The electron microscopy of the developing human renal glomerulus, *Exp. Cell Research*, 1958, 14, 355.
28. SUZUKI, Y., An electron microscopy of the renal differentiation. II. Glomerulus, *Keio J. Med.*, 1959, 8, 129.
29. LATTA, H., MAUNSBACH, A. B., and MADDEN, S. C., The centrolobular region of the renal glomerulus studied by electron microscopy, *J. Ultrastructure Research*, 1960, 4, 455.
30. FARQUHAR, M. G., VERNIER, R. L., and GOOD, R. A., An electron microscope study of the glomerulus in nephrosis, glomerulonephritis, and lupus erythematosus, *J. Exp. Med.*, 1957, 106, 649.
31. FARQUHAR, M. G., HOPPER, J., JR., and MOON, H. D., Diabetic glomerulosclerosis: electron and light microscopic studies, *Am. J. Path.*, 1959, 35, 721.
32. POLICARD, A., COLLET, A., and GILTAIRE-RALYTE, L., Recherches au microscope électronique sur la structure du glomérule rénal des mammifères, *Arch. anat. micr.*, 1955, 44, 1.
33. SAKAGUCHI, H., Fine structure of the renal glomerulus, *Keio J. Med.*, 1955, 4, 103.
34. YAMADA, E., The fine structure of the renal glomerulus of the mouse, *J. Biophysic. and Biochem. Cytol.*, 1955, 1, 551.
35. PAK POY, R. K. F., Electron microscopy of the mammalian renal glomerulus. The problems of intercapillary tissue and the capillary loop basement membrane, *Am. J. Path.*, 1958, 34, 885.
36. BENEDETTI, E. L., and MARINOZZI, V., Sulla fine struttura del tessuto intercapillare nel glomerulo di Malpighi, *Fisiopatologia Clinica e Terapeutica*, 1958, 30, 1.
37. ROBERTSON, D. M., and MORE, R. H., Structure of glomerular axial region in normal and nephritic rabbits, *Arch. Path.*, 1961, 72, 331.
38. MICHAELSON, P., Contribution à l'étude du

- tissue intercapillaire, in Proceedings, First International Congress of Nephrology, (G. Richet, editor), Basel, S. Karger, 1961, 657.
39. BENCOSME, S. A., STONE, R. S., LATTA, H., and MADDEN, S. C., Acute reactions with collagen production in renal glomeruli of rats studied electron microscopically, *J. Ultrastructure Research*, 1959, 3, 171.
  40. BERGSTRAND, A., and BUCHT, H., Anatomy of the glomerulus as observed in biopsy material from young and healthy human subjects, *Z. Zellforsch.*, 1958, 48, 51.
  41. JONES, D. B., Nephrotic glomerulonephritis, *Am. J. Path.*, 1957, 33, 313.
  42. MARINOZZI, V., Silver impregnations of ultrathin sections for electron microscopy, *J. Biophysic. and Biochem. Cytol.*, 1961, 9, 121.
  43. SUZUKI, T., and SEKIYAMA, S., Application of methenamine silver stain for electron microscopy, *J. Electronmic.*, 1961, 10, 36.
  44. NOVIKOFF, A. B., Lysosomes and related particles, in *The Cell*, (J. Brachet and A. E. Mirsky, editors), New York, Academic Press Inc., 1961, 2, 423.
  45. HOLTER, H., Problems of pinocytosis, with special regard to amoebae, *Ann. New York Acad. Sc.*, 1959, 78, 523.
  46. DIXON, F. J., FELDMAN, J. D., and VASQUEZ, J. J., Experimental glomerulonephritis. The pathogenesis of a laboratory model resembling the spectrum of human glomerulonephritis, *J. Exp. Med.*, 1961, 113, 899.
  47. HOPPER, J., JR., FARQUHAR, M. G., YAMAUCHI, H., MOON, H. D., and PAGE, E. W., Renal lesions in pregnancy: clinical observations and light and electron microscopic findings, *Obst. and Gynec.*, 1961, 17, 271.
  48. ELLIS, J. T., Glomerular lesions and the nephrotic syndrome in rabbits given saccharated iron oxide intravenously, *J. Exp. Med.*, 1956, 103, 127.
  49. BENACERRAF, B., MCCLUSKEY, R. T., and PATRAS, D., Localization of colloidal substances in vascular endothelium. A mechanism of tissue damage. I. Factors causing the pathologic deposition of colloidal carbon, *Am. J. Path.*, 1959, 35, 75.
  50. LATTA, H., Collagen in normal rat glomeruli, *J. Ultrastructure Research*, 1961, 5, 364.
  51. PORTER, K. R., and PAPPAS, G. D., Collagen formation by fibroblasts of the chick embryo dermis, *J. Biophysic. and Biochem. Cytol.*, 1959, 5, 153.
  52. KARRER, H. E., Electron microscope study of developing chick embryo aorta, *J. Ultrastructure Research*, 1960, 4, 420.
  53. PALADE, G. E., The fine structure of blood capillaries, 1962, in preparation.
  54. MELLORS, R. C., ORTEGA, L. G., and HOLMAN, H. R., Role of gamma globulins in pathogenesis of renal lesions of systemic lupus erythematosus and chronic membranous glomerulonephritis, with an observation on the lupus erythematosus cell reaction, *J. Exp. Med.*, 1957, 106, 191.
  55. VASQUEZ, J. J., and DIXON, F. J., Immunohistochemical analysis of lesions associated with "fibrinoid change," *Arch. Path.*, 1958, 66, 504.
  56. SOTELO, J. R., and PORTER, K. R., An electron microscope study of the rat ovum, *J. Biophysic. and Biochem. Cytol.*, 1959, 5, 327.
  57. PALAY, S. L., The fine structure of secretory neurons in the preoptic nucleus of the goldfish (*Carassius auratus*), *Anat. Rec.*, 1960, 138, 417.
  58. DAVIS, R., and ENDERS, A. C., Light and electron microscope studies on the parathyroid gland, in *The Parathyroids*, (R. O. Greep and R. V. Talmage, editors), Springfield, Illinois, Charles C. Thomas, 1961.
  59. RHODIN, J. G., Electron microscopy of the glomerular capillary wall, *Exp. Cell Research*, 1955, 8, 572.
  60. PEASE, D. C., Fine structures of the kidney seen by electron microscopy, *J. Histochem. and Cytochem.*, 1955, 3, 295.
  61. YAMADA, E., Collagen fibrils within the renal glomerulus, *J. Biophysic. and Biochem. Cytol.*, 1960, 7, 407.