

CYTOLOGICAL AND CYTOCHEMICAL STUDIES
OF GREEN MONKEY KIDNEY CELLS
INFECTED *IN VITRO* WITH SIMIAN VIRUS 40

ROBERT LOVE, M.D., and MARIO V. FERNANDES, V.M.D.

From the Department of Pathology, Jefferson Medical College, and The Wistar Institute, Philadelphia

ABSTRACT

Cytological and cytochemical studies of green monkey kidney cells infected with SV40 virus indicated that the type of lesion produced was influenced by the multiplicity of infection and that the lesions appeared later and progressed more slowly when the inoculum was diluted. The earliest change consisted of enlargement of ribonucleoprotein-containing spherules in the nucleolus (nucleolini). This was followed by rarefaction, with or without condensation, of the chromatin and the appearance of one or more homogeneous masses of inclusion material containing DNA, RNA, and non-histone protein which eventually filled the nucleus. In some instances the chromatin appeared to be directly transformed into inclusion material. In the later stages of infection, the ribonucleoprotein of the nucleolini was no longer stainable and material resembling the nucleoprotein of the intranuclear inclusions was found in the nucleolar vacuoles and in the cytoplasm. The nucleic acids in the inclusions were stained by toluidine blue, toluidine blue-molybdate, the Feulgen stain, and by methyl green. The stainable material was extractable by nuclease digestion or by hot trichloroacetic acid. Green or yellowish green staining by acridine orange was apparently due to binding of dye by protein and not by nucleic acids since the staining reaction was not reduced by extraction of nucleic acids by hot trichloroacetic acid. Extraction with pepsin in combination with ribonuclease or deoxyribonuclease removed practically all the inclusions from the cells; consequently they could not be stained with acridine orange. The cytochemical studies suggest that the use of pepsin together with nuclease is not a meaningful technique.

INTRODUCTION

Several reports of the cytological, cytochemical, and immunochemical changes produced by infection of green monkey kidney cells *in vitro* with SV40 virus (34) have been published (2, 5, 11, 12, 16, 19, 27, 28, 31, 36). The present study combines more extensive cytochemical investigations with observations by phase-contrast microscopy and immunofluorescent techniques and reveals some new aspects of the cytopathology. In particular, the cytochemical changes in the nu-

cleolus and the nature of the inclusion material in the nucleus have been elucidated and the effect of variable multiplicity of the viral inoculum on the evolution of the lesions has been determined.

MATERIALS AND METHODS

Virus

The virus was kindly provided by Dr. M. R. Hilleman and maintained by passage in green

monkey (*Cercopithecus aethiops*) kidney cultures at the Wistar Institute. The preparation of virus pools and the method of infecting monolayers have been described (30). The pool used in the present experiments contain $10^{5.6}$ TCID₅₀ per 0.1 ml. Replicate cultures were infected with undiluted virus (high multiplicity), or 10^{-3} and 10^{-5} (low multiplicity) dilutions of the pool. The undiluted inoculum corresponded to an approximate input multiplicity of 1 TCID₅₀ per cell.

Cells

Primary monolayer cultures of African green monkey kidney cells from Microbiological Associates, Bethesda, Maryland, were subcultured into 60 mm Petri dishes containing coverslips and grown at 37°C in a humid atmosphere of approximately 5 per cent carbon dioxide in air. The medium was Eagle's basal medium (6) containing 2 mM glutamine and 10 per cent filtered calf serum with added bicarbonate (5.6 per cent NaHCO₃, 25 ml per liter) and antibiotics (penicillin, 10^5 units; and streptomycin, 10^5 µg, or aureomycin, 5×10^4 µg, per liter). Coverslips were removed for examination at 4 and 24 hours and at daily intervals up to 18 days after infection.

Cytological and Cytochemical Studies

Infected and uninfected cultures were observed by phase-contrast microscopy, ordinary, and ultraviolet light microscopy. The following cytochemical techniques were employed: the Feulgen reaction, periodic acid-Schiff (PAS) (29), toluidine blue-molybdate (TBM, methods A, B, C, D, and E) (25), dilute toluidine blue after nitrosation for 18 hours (22), acridine orange as described by Mayor *et al.* (28) a modification of Pauly's method for tyrosine and histidine (32), the ninhydrin-Schiff and dinitrofluorobenzene methods for protein-bound amino groups (3), and the alkaline fast green method for histones (1). The methods of fixation were those described in the references, except that a mixture of two parts ethanol to one part glacial acetic acid was substituted for the regular Carnoy fixative in the acridine orange procedure. There was no difference in staining or in response to procedures for extraction of nucleic acids between preparations fixed in this manner and those fixed in Carnoy's. Preparations fixed in Carnoy's were more readily detached from the glass by combinations of pepsin treatment and nuclease digestion, so that analysis of the effects of these procedures was impossible. Preparations were also fixed for 10 minutes at 37°C in formol sublimate and, after treatment with Lugol's iodine solution and sodium thiosulfate (25), stained with pyronin-methyl green (29). Various types of pretreatment after fixation and before staining were employed as

described in the results. Deoxyribonuclease (DNase, crystallized, Worthington Biochemical Corporation, Freehold, New Jersey) and ribonuclease (RNase, 5 times crystallized, Worthington) were used as 0.01 per cent solutions in 0.02 M trishydroxymethylamino-methane (Tris) buffer containing 0.045 M MgCl₂·6H₂O and 5 mM CaCl₂, anhydrous, brought to pH 7.3 by addition of 1 N HCl (22). Preparations were digested for 2 hours at 37°C. Pepsin (3 times crystallized, Nutritional Biochemical Corporation, Cleveland) was used as a 0.2 per cent solution in 0.02 N HCl for 10 minutes at 20 to 25°C (28). Control preparations were treated with buffer or HCl for the same time and at the same temperature as the enzyme-treated preparations. Cells were also treated for 30 minutes at 90°C with 5 per cent trichloroacetic acid to remove nucleic acids (33).

Immunofluorescence

Preparations were rinsed briefly in acetone at 4°C, followed by fixation in acetone for 30 minutes at -20°C and stored at this temperature until stained. Rabbit anti-SV40 gamma globulin, labeled with fluorescein isothiocyanate, was kindly provided by Drs. W. and G. Henle, of the Children's Hospital, Philadelphia. The method of staining has been described (30).

RESULTS

Morphological Changes

Despite the fact that specific changes were observed in almost every cell in the later stages of infection of cultures inoculated with a high multiplicity (undiluted) inoculum, the rate of development of the lesions varied considerably from cell to cell in the same culture (Figs. 6, 8, 9 and 16). The pathogenesis was, therefore, assessed in part from the time sequence of events, but also by analysis of increasing disorganization of nuclear structure in living cells under the phase microscope and in fixed preparations stained to demonstrate the nucleoproteins of the cell. It should be noted that, by virtue of the type of DNP or RNP that they contain, certain structures are optimally stained by each of the five TBM methods (25). Thus, the morphology of the cell appears to be different in each preparation. The structure of the nucleolus in preparations stained by method C is essentially the negative image of that stained by method B (*cf.* Figs. 3 and 6). In preparations of uninfected green monkey kidney cells stained by method B, the nucleolini appeared to be solid spherical bodies embedded in the lightly staining

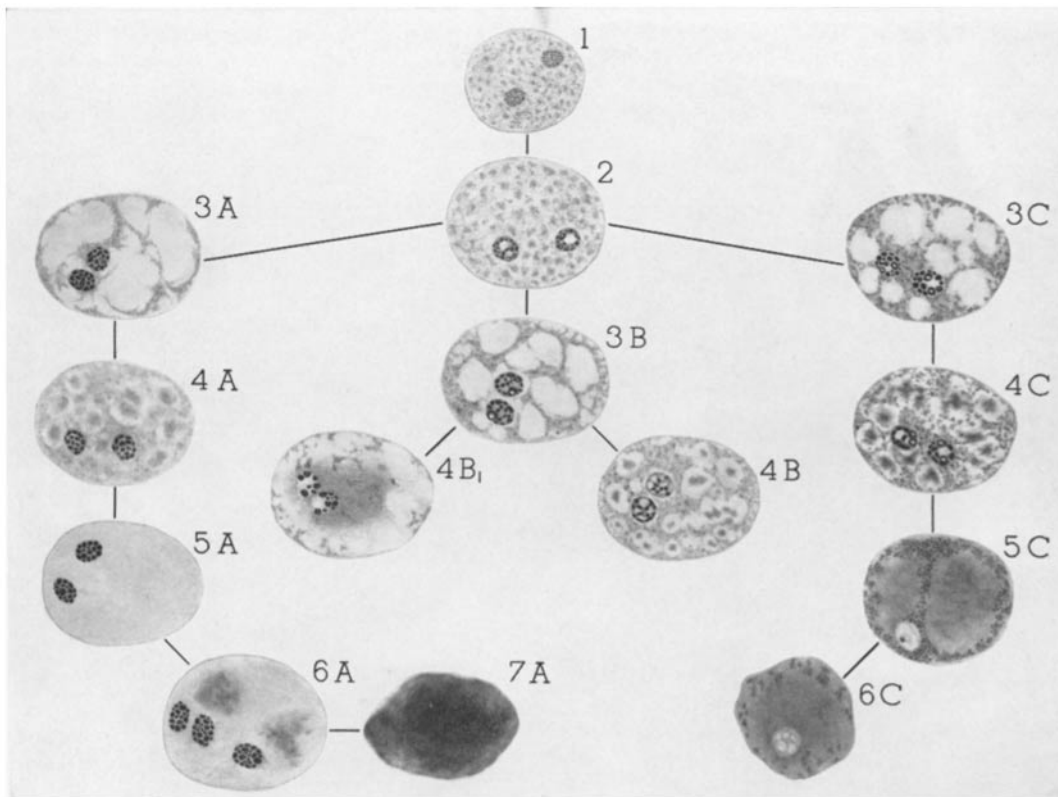


FIGURE 1 Changes in the nuclei of green monkey kidney cells infected with SV40 virus. The drawings represent a composite picture of preparations stained to demonstrate nucleolini by TBM method B and chromatin and inclusions by TBM method C. After the initial nuclear change (2), the lesions evolve along three different pathways, A, B, and C.

pars amorpha of the nucleolus. In method C preparations, the pars amorpha was intensely stained and the nucleolini were lightly stained vacuoles. These vacuoles could also be seen as light spheres in living cells by dark-phase microscopy. Similarly, the chromatin of cells in interphase was not stained metachromatically by method B, but was intensely stained by method C (*cf.* Fig. 2 and the normal cell in Fig. 8). In order to give a composite picture of the morphological changes in the various structures containing DNP and RNP demonstrable by different TBM methods, the drawings of Fig. 1 have been made. The changes observed in the TBM preparations of the virus-infected cells were essentially those described in electron micrographs and in other stained preparations (11, 16, 28, 31, 36). The earliest detectable abnormality consisted of enlargement of the nucleolini (Figs. 1 to 5). In

preparations stained to demonstrate the RNP of the nucleolini (method B), the center of some of the enlarged nucleolini was devoid of stainable material (Fig. 4). The enlarged nucleolini appeared light under the phase microscope (Fig. 5). The size of the nucleolus increased, presumably as a result of the enlargement of nucleolini. The nucleus of the affected cell also increased in size. The subsequent development of the lesions appeared to depend upon the rates at which two different processes occurred. One process was the appearance of a newly formed homogeneous material in the nucleus. The other process involved the chromatin and consisted of three types of change: (a) rarefaction, (b) condensation, and (c) replacement by the newly formed homogeneous material. The evolution of the lesions varied according to which of the three types of chromatin change was predominant and also depended upon

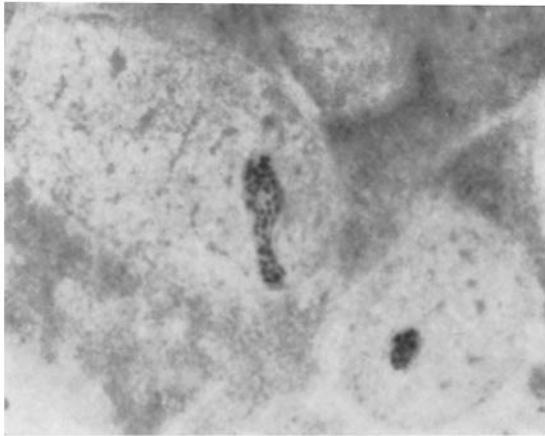


FIGURE 2 Two uninfected green monkey kidney cells stained to demonstrate nucleolini, which appear black in the photograph. TBM, method B. $\times 1700$.

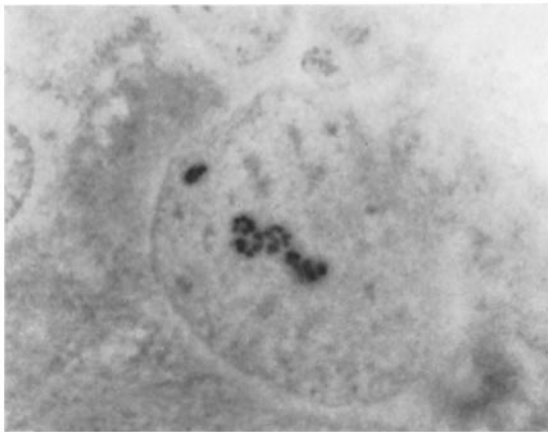


FIGURE 3 Enlarged nucleolini in a virus-infected cell. TBM, method B $\times 1700$.

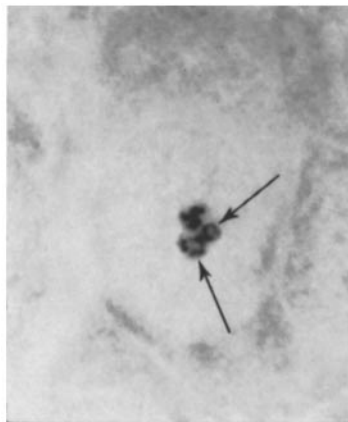


FIGURE 4. Enlarged nucleolini in a virus-infected cell. Arrows mark the unstained centers of two nucleolini. TBM, method B. $\times 1700$.

whether the chromatin changes proceeded more quickly or contemporaneously with the appearance of the new homogeneous material in the nucleus. In one series of lesions (Fig. 1, series A), rarefaction of the chromatin was accompanied by replacement of the remaining chromatin by material that appeared to be homogeneous under the phase microscope and in suitably stained preparations (Fig. 1, 3A, and Fig. 6). As the lesions progressed, increasingly dense homogeneous material appeared in the rarefied areas (Fig. 1, 4A, and Fig. 7) and the transformation of chromatin continued until the entire nucleus (with the exception of the nucleolus) was homogeneous (Fig. 1, 5A, and Fig. 6). Subsequently, the homogeneous material became more dense and stained more intensely at first in localized areas (Fig. 1, 6A; and Figs. 5 and 8) and finally throughout the entire nucleus

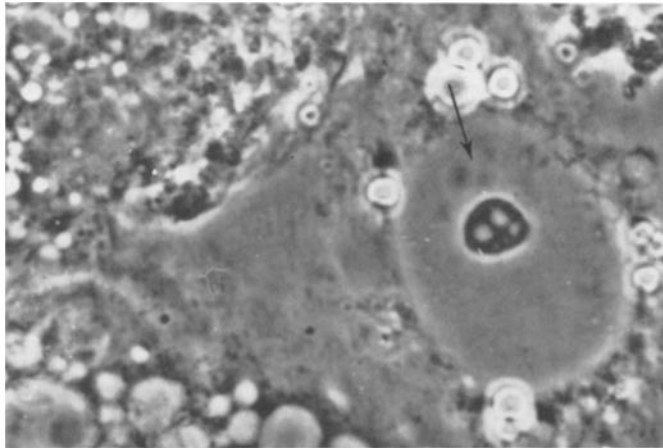


FIGURE 5 Phase-contrast photograph of an infected cell. The enlarged nucleolini appear as less dense structures in the nucleolus. Note three small ill defined dense inclusions (arrow) near the nucleolus and extensive cytoplasmic vacuolation. $\times 1600$.

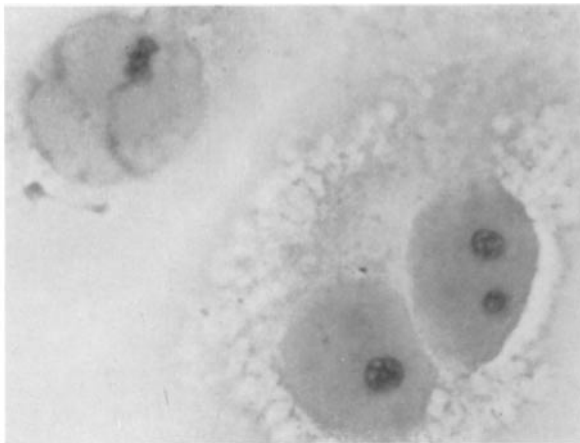


FIGURE 6 Two stages in the transformation of chromatin into homogeneous inclusion material. The chromatin of the cell on the left has lost its normal granularity and the rest of the nucleus is uniformly rarefied. The chromatin of the two other cells is no longer recognizable and the nucleoplasm appears structureless. The enlarged nucleolini are very weakly stained in this preparation and appear as vacuoles in the nucleolus. TBM, method C. $\times 1000$.

(Fig. 1, 7A, and Fig. 9). While these changes were occurring, the enlarged nucleolini appeared to fuse and became less numerous (Fig. 10). In the final stage that preceded karyorrhexis (Fig. 1, 7A, and Fig. 9), the deeply staining homogeneous nuclei shrank, the characteristic stainable material of the nucleolini was no longer detectable, and a vacuolated pars amorpha persisted. This series of changes was more frequent in the low multiplicity infections where the onset of detectable cytological changes was delayed to 96 hours, and the lesions evolved more slowly than with high multiplicity infection.

In a second series of lesions (Fig. 1, series C), the appearance of localized or widespread areas of

rarefaction in the nucleus was accompanied by granular condensation of the remaining chromatin (Fig. 1, 3C, and Fig. 11). Homogeneous material, usually with an ill defined periphery, but occasionally quite circumscribed, appeared in the areas of rarefaction (Fig. 1, 4C, and Fig. 12) and subsequently increased in amount (Fig. 1, 5C, and Fig. 13). Further progression of these changes led to irregular margination and condensation of the chromatin and the production of shrunken nuclei filled with deeply staining homogeneous material (Fig. 1, 6C, and Fig. 14). The changes in the nucleolini were similar to those in the A series of lesions except that the enlargement was more irregular. One or two nucleolini were often dis-

proportionately enlarged, with apparent displacement of the others (Fig. 1, 3C and 4C, and Figs. 15 and 16). In the later stages (Fig. 1, 5C and 6C), the nucleolini fused and, finally, were no longer stainable by method B. Fragments of pars amorpha usually persisted (Fig. 14) until disintegration of the cell by karyorrhexis. This pattern of cytopathic change was characteristic of high multiplicity infection and was first detectable 24 hours after application of virus. The changes in

the cells also progressed fairly rapidly and advanced lesions (Fig. 1, 5C and 6C) were observed before the earliest detectable abnormality in the low multiplicity infection.

A third series of changes (Fig. 1, series B), which appeared to be intermediate between A and C, was also observed. Following the usual stage of enlargement of nucleolini, localized or widespread areas of rarefaction of the chromatin were seen. The remaining chromatin was not

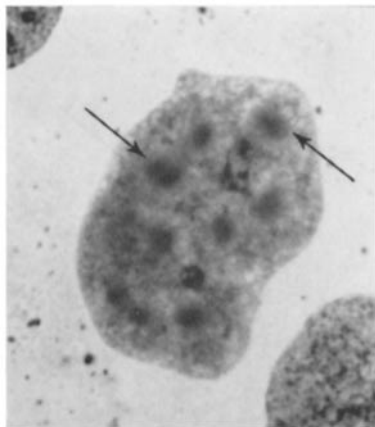


FIGURE 7 Numerous ill defined inclusions (arrows) in a nucleus in which the remaining chromatin is undergoing transformation into homogeneous material. TBM, method C, after ribonuclease digestion. $\times 1500$.

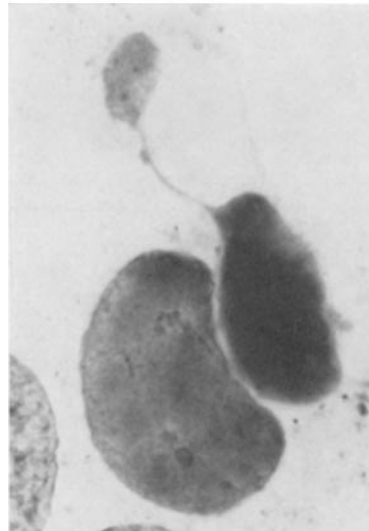


FIGURE 9 Two stages in the A series of lesions. The larger nucleus is almost homogeneous and the smaller one is filled with densely staining inclusion material. The pedunculated extrusion suggests a possible manner in which nuclear contents could be separated to form a cytoplasmic inclusion. TBM, method C, after ribonuclease digestion. $\times 1200$.

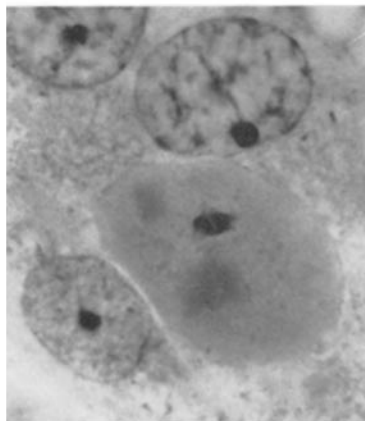


FIGURE 8 Denser inclusion material in a nucleus that is filled with homogeneous material. One adjacent nucleus appears normal and another shows rarefaction and condensation of chromatin. TBM, method C. $\times 1400$.

condensed (Fig. 1, 3B, and Fig. 11). Masses of homogeneous material then appeared in the areas of rarefaction (Fig. 1, 4B, and Fig. 17) and, in some instances, around, or adjacent to, the nucleoli (Fig. 1, 4B, and Fig. 18). It was not possible to distinguish any separate series of cells indicating a further specific type of progression of these changes. It must be assumed that, as the amount of homogeneous material increased, the chromatin was replaced or condensed and the cells underwent the late changes of series A or C. The B series of nuclear disorganization was found in high, intermediate, and low multiplicity infections.

There was little evidence for extrusion of material from the nucleolus into the nucleoplasm, similar to that which has been described with other viruses (23, 26). Occasional ribonucleoprotein bodies in the nucleoplasm with cytochemical properties similar to those of the nucleolini were observed rarely, although more frequently in the infected than in uninfected control preparations. Protrusions of nucleolini from the body of the nucleolus were not seen.

vice versa (Fig. 14). Cytoplasmic vacuolation was invariably associated with the formation of syncytia. In the later stages of infection, cytoplasmic inclusions that were cytochemically indistinguishable from the homogeneous intranuclear material were frequently seen (Figs. 13, 17, and 19). A possible origin of some of these inclusions by some form of nuclear budding is suggested by the appearance of the nucleus shown in Fig. 9.

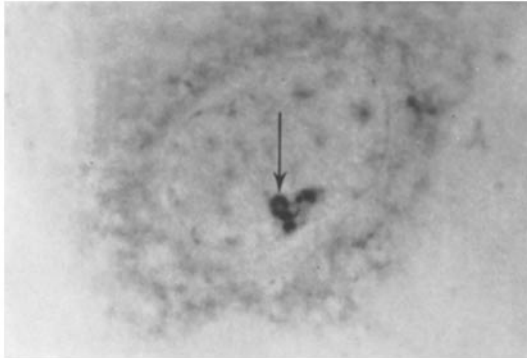


FIGURE 10 Reduced number of enlarged nucleolini in an infected cell. Note the light staining center (arrow) of one of the nucleolini. TBM, method B. $\times 1400$.

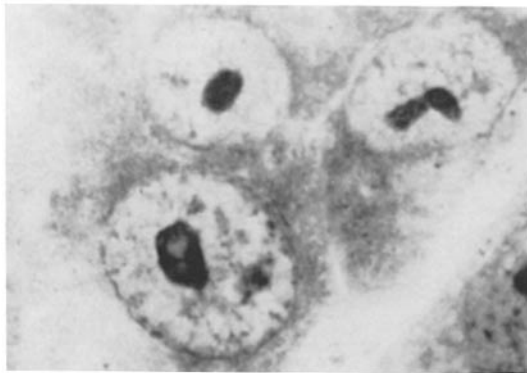


FIGURE 11 Rarefaction of the chromatin with some irregular condensation around the nuclear membrane and elsewhere in the nucleus of the largest cell. Note the large vacuoles in the nucleolus. There is widespread rarefaction of the chromatin of the two smaller cells, without condensation of the chromatin. TBM, method C. $\times 1500$.

The characteristic cytoplasmic vacuolation that was the first indication of the existence of infection of monkey kidney cells with SV40 virus (34) was noted in the virus-infected cultures (Fig. 5). It was also found, although less commonly and to a lesser degree, in the control cultures that had not been exposed to virus. The degree of cytoplasmic vacuolation bore no relationship to the development of the nuclear changes, and striking cytoplasmic vacuolation was frequently observed without any detectable nuclear abnormality, and

Cytochemistry

The results of cytochemical staining procedures with and without appropriate extraction procedures are summarized in Tables I and II. The chromatin and the intranuclear homogeneous material (inclusions) were stained positively by the Feulgen method and colored purple by TBM, method C, greenish blue by toluidine blue and TBM, method B, and green by pyronin-methyl green (Table I). Staining of the chromatin and

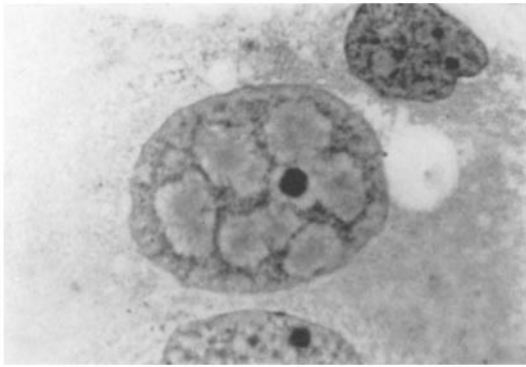


FIGURE 12 Multiple inclusions inside areas of rarefaction with some condensation of the remaining chromatin. TBM, method C. $\times 1100$.

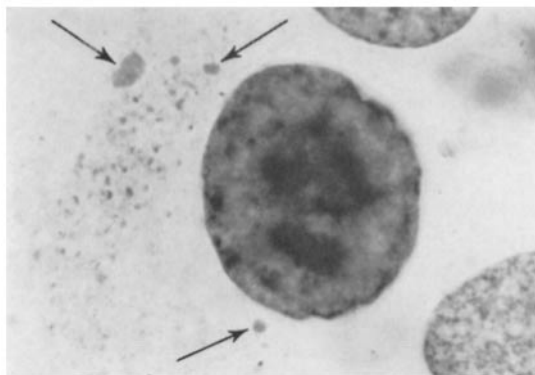


FIGURE 13 Large, ill defined intranuclear inclusions and irregular condensation of the chromatin; arrows mark cytoplasmic inclusions. TBM, method C, after ribonuclease digestion. $\times 1200$.

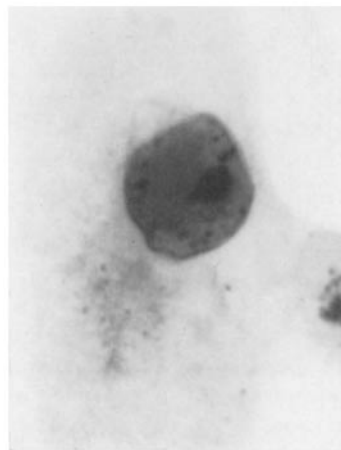


FIGURE 14 Shrunken nucleus filled with inclusion material and remnants of granular chromatin. This cell is not in a syncytium and the cytoplasm does not show the massive vacuolation that is commonly found in the infected cultures. TBM, method C. $\times 1700$.

inclusions by these methods was due to the presence of DNA since they could not be stained after digestion with DNase. Hydrolysis by hot trichloroacetic acid prevented all staining, except for weak pink coloration by the pyronin-methyl green procedure (Table I). Digestion with RNase led to a slight reduction in the intensity of staining of the chromatin by TBM (method C). An accurate assessment of any slight reduction in the intensity of staining of the inclusions by TBM was impossible because of the considerable variability in staining from one cell to another in the same preparation. The presence of RNA in the inclusions was none the less established by the fact that digestion with RNase prevented staining by TBM, method B, and by dilute toluidine blue after nitrosation (Table I). Nothing was stained by TBM after digestion with RNase and DNase.

In almost all procedures involving the use of pepsin, alone or in combination with nucleases, the results were variable, not only from one

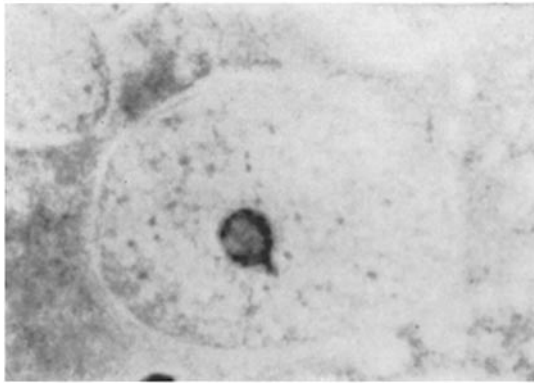


FIGURE 15 A large lightly stained vacuole in the nucleolus, surrounded by slightly enlarged nucleolini. TBM, method B. $\times 1700$.

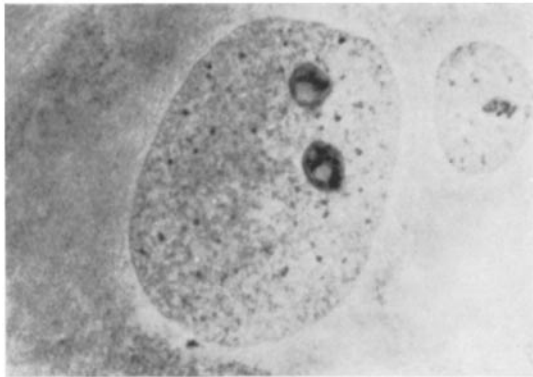


FIGURE 16 One large vacuole surrounded by enlarged nucleolini in each of two nucleoli. A normal nucleus (right) is included for comparison. TBM, method B. $\times 1700$.

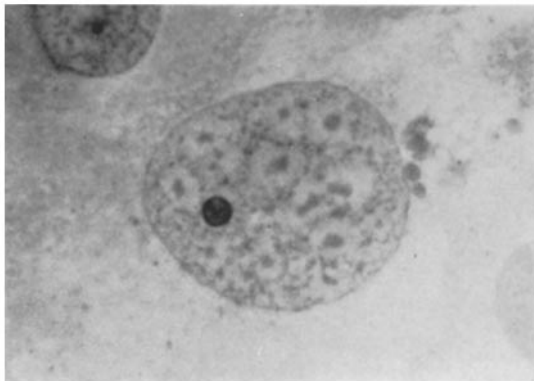


FIGURE 17 Multiple intranuclear inclusions in areas of rarefaction without condensation of the remaining chromatin. Inclusions are also present in the cytoplasm. TBM, method C. $\times 1100$.

experiment to another, but also from one area or cell to another, in the same preparation. This was particularly true when pepsin was used in combination with a nuclease (Tables I and II), and in many experiments the cells were considerably distorted or disrupted by the enzyme treatment. Digestion with pepsin resulted in a change in distribution of nuclear chromatin with

blurring of the outline of the chromatin and the inclusions, suggesting that some diffusion of stainable material had taken place. Pretreatment with pepsin gave rise to a variable reduction in the intensity of staining of the chromatin and the inclusions by the Feulgen method. Pepsin followed by RNase removed most of the cells from the glass. There was, again, variable weak staining of

TABLE I
Cytochemical Properties of Chromatin and SV40 Virus-Induced Inclusions

Pretreatment	Staining methods	Chromatin	Inclusions
None or buffer	Feulgen, TBM, TB, PMG	+++	+++
DNase	Feulgen, TBM, TB, PMG*	0	0
RNase	Feulgen, PMG	+++	+++
RNase	TBM	++	See text
RNase	TB	0	0
Hot trichloroacetic acid	Feulgen, TBM, TB, PMG*	0	0
DNase, RNase, and <i>vice versa</i>	TBM	0	0
Pepsin	Feulgen	Variable ++	Variable ++
Pepsin, RNase	Feulgen	Variable +‡	Variable +‡
RNase, pepsin	Feulgen	++	++
Pepsin	TBM	++++	++++
Pepsin, RNase, and <i>vice versa</i>	TBM	Variable +	0§
0.2 N HCl	Feulgen, TBM	+++	+++
Pepsin, DNase	TBM	0	0
DNase, pepsin	TBM	Absent or 0	Absent

TBM, toluidine blue-molybdate, method C; TB, dilute toluidine blue after nitrosation; PMG, pyronin-methyl green; DNase, deoxyribonuclease; RNase, ribonuclease, 0, unstained. + to ++++ reflects intensity of staining.

* Pale pink color persisted.

‡ Most of the cells were removed from the glass.

§ A very occasional inclusion was weakly stained.

chromatin and inclusions. When pepsin was used after RNase, the intensity of staining by the Feulgen method was reduced more uniformly (Table I). Treatment with pepsin led to an increase in staining by TBM, as previously reported (21). Digestion with pepsin and ribonuclease, irrespective of the order of use, produced a variable reduction in staining of the chromatin by TBM and prevented staining of almost all the inclusions. No significant effect was produced on staining by the Feulgen or TBM methods by treatment with 0.2 N HCl. The effects of pepsin were, therefore, due to activity of the enzyme and not to the hydrochloric acid in which it was dissolved. Pepsin and DNase in any order prevented staining of the chromatin and the inclusions by TBM. When the pepsin treatment followed the DNase, all the inclusion material and most of the chromatin disappeared and could no longer be seen by phase microscopy. The inclusions were not stained by TBM, methods A, D, and E. The inclusions stained green to greenish-yellow by acridine orange, as described by others (28). The chromatin of the nuclear membrane and that

associated with the nucleolus appeared to stain more yellow than the inclusions. If the preparations were kept for some time in the light, the red color faded and the chromatin then lost the apparent yellow tinge and was colored green. The yellowish green color of the chromatin would appear therefore to be, at least in part, due to the superimposition of green upon red. After the various extraction procedures, the amount of yellow in the green-stained structures was variable and no constant agreement on the color could be reached by four independent observers. For this reason, the varying shades of yellowish-green are referred to as green in Table II. It was, however, unanimously agreed that after extraction of both nucleic acids with hot trichloroacetic acid the color of the acridine orange-stained material was yellowish green.

The results of the various extraction procedures on staining with acridine orange are summarized in Table II. Digestion with nucleases clearly indicated that staining of the chromatin was in part due to DNA. After pretreatment with DNase, the chromatin was colored very weakly red.

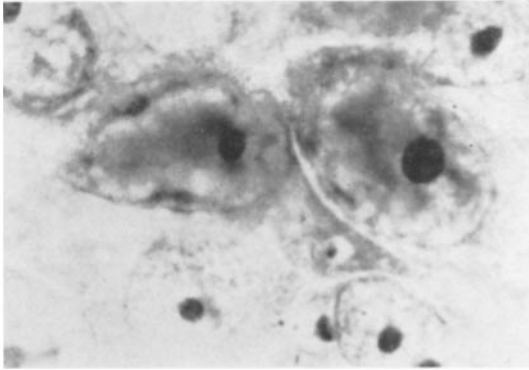


FIGURE 18 Juxtannucleolar masses of inclusion material. TBM, method C. $\times 1500$.

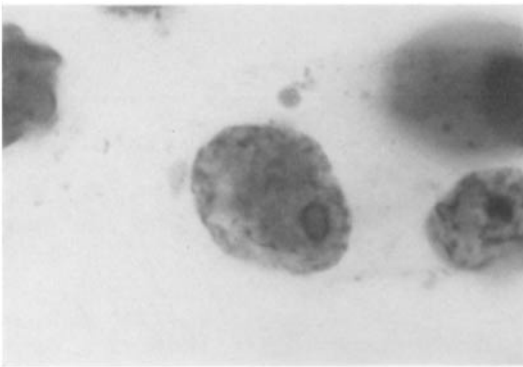


FIGURE 19 Nucleus containing a large, ill defined inclusion and granular remnants of chromatin. Two inclusions are present in the cytoplasm. There is a large vacuole in the nucleolus containing DNA. TBM, method C, after ribonuclease digestion. $\times 1500$.

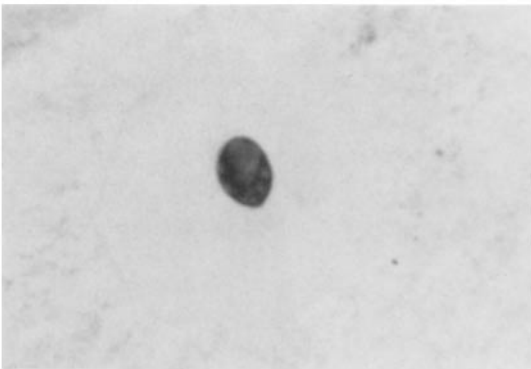


FIGURE 20 An infected cell treated with deoxyribonuclease and stained by TBM, method C. There is no staining of chromatin or inclusion material. Vacuoles in the nucleus contain homogeneously staining RNA. $\times 1700$.

Subsequent digestion of such preparations with RNase resulted in weak green staining of chromatin. Extraction of both nucleic acids with hot trichloroacetic acid had the same effect as digestion with both nucleases. The results of digestion with RNase indicated that the red coloration of the cytoplasm and the nucleolus was due to the presence of RNA. In contrast to the normal con-

stituents of the cell, the intensity of staining of the inclusions was not reduced by any of the procedures designed to remove one or both nucleic acids. Extraction with hot TCA did not produce any fluorescence in preparations that were not immersed in acridine orange.

Procedures involving digestion with pepsin suffered from the disadvantages that have been

TABLE II
Staining of Green Monkey Kidney Cells and SV40 Virus-Induced Inclusions with Acridine Orange

Pretreatment	Chromatin	Inclusions	Cytoplasm	Nucleolus
None or buffer	Green +++*	Green +++	Red +++	Red ++
DNase	Red +	Green +++	Red +++	Red ++
RNase	Green +++	Green +++	Green +	Green +++‡
Hot trichloroacetic acid	Green ++	Green +++	Green +	Green ++
RNase, DNase, and <i>vice versa</i>	Green ++	Green +++	Green +	Green +++‡
Pepsin	Green +++	Green +++	Red +++	Red +++
Pepsin, RNase	Green +	Absent	Green +	Green +++‡
RNase, pepsin	Variable green	Absent§	Variable green	Variable green
Pepsin DNase	Variable green or red	Absent	Red +++	Red ++
DNase, pepsin	Absent	Absent	Red +++	Red ++
0.2 N HCl	Green +++	Green +++	Red +++	Red ++

Abbreviations as in Table I.

* The green color often appeared to have a yellowish tinge (see text).

‡ Probably due to nucleolar-associated chromatin.

§ Rarely present and stained green +.

described previously. Pepsin and hydrochloric acid alone did not produce much detectable change in staining with acridine orange. Treatment with pepsin followed by RNase caused the inclusions to disappear. In the reverse order, a very occasional inclusion persisted and was stained green. Digestion with pepsin and DNase also removed the inclusions. When the DNase was used after pepsin the chromatin was stained green or red. When the enzymes were employed in the reverse order, the chromatin was removed.

The fact that the inclusions were not stained metachromatically by toluidine blue suggests that residual staining by acridine orange after extraction of nucleic acid was not due to acid mucopolysaccharide. The inclusions did not stain by the alkaline fast green method for histones. They were stained by all other methods used for protein-bound groups.

The cytochemical properties of the enlarged nucleolini in the virus-affected cells were no different from those of the control preparations and those of other infected and uninfected cells described elsewhere (22, 25, 26). They contained ribonucleoprotein in close association with DNA. When stained by TBM, method C, lightly stained vacuoles in the pars amorpha appeared to correspond to the enlarged nucleolini stained by

methods A and B. In the early stages of infection, the contents of the vacuoles no longer stained after digestion with RNase, but were not significantly affected by DNase (Fig. 20). In the later stages of infection, the contents of the largest vacuoles became Feulgen-positive and assumed the same cytochemical properties as the inclusion material in the rest of the nucleus; they were digested by DNase but staining by TBM, method C, was not detectably altered by RNase (Fig. 19).

Immunofluorescence

The results of immunofluorescent staining were essentially similar to those described by Mayor *et al.* (28), Diderholm (5), and Levinthal and Shein (19) and need not be described in detail. Considerable asynchrony was noted in the development of the antigen. Thus, diffuse nuclear staining, perinucleolar staining and staining of the cytoplasm were sometimes observed in the same preparation. Antigen was observed in particulate form in the nucleolus in the late stages of infection, when DNA became detectable in the nucleolar vacuoles.

DISCUSSION

The changes in the nucleolus correspond very closely to those observed by Granboulan *et al.* (12)

by electron microscopy and by Prunieras (31) by time-lapse cinematography. Nucleolar changes are illustrated diagrammatically in Fig. 2 of the paper by Granboulan *et al.* (12). The less dense vacuolar structures in the nucleoli that are surrounded by a zone of denser material correspond to the nucleolini. These vacuoles become larger in the infected cells and the amount of dense material increases and is often somewhat eccentrically placed at the edge of the vacuole, *cf.* Fig. 15 and 16 of this paper. Later in the infection Granboulan *et al.* found virus in the less dense vacuoles at the time when the vacuoles observed in the present study contained material that was identical to that of the inclusions. The likelihood of virus being responsible for the DNA-containing material in the nucleolar vacuoles is suggested by the present observations, and by those of others (5, 19, 28) that antigen is seen in small particulate points in the nucleolus. The observation of antigen and inclusion material around the nucleolus in occasional cells also suggests that virus may be formed there and subsequently pass outwards into the nucleoplasm. A process of extrusion of material from the nucleolus has been observed by Prunieras (31), whose studies envisage the transportation of material from nucleolus to cytoplasm. Extrusion of RNP from enlarged nucleolini into the nucleoplasm has been observed with herpes and polyoma virus where large RNP bodies or "B-bodies" were formed in the nucleoplasm (23, 26). This was only rarely observed with SV40 virus. On the other hand, there was no suggestion of extrusion of DNA-containing material from the nucleoli of cells infected with polyoma or herpes virus (23, 26), nor is there definite evidence for the formation of virus or antigen in the nucleoli of cells infected with these viruses (13, 37).

An increase in the size of nucleolini has been observed with all intranuclear DNA virus infections that have been studied (23). In electron micrographs, dense bodies which appear to correspond to enlarged nucleolini have been noted in cells infected with varicella (35) polyoma (2) and SV40 viruses (12). The nucleolini were unaffected in cells infected with vaccinia or Newcastle disease virus (23). Enlargement was also noted when DNA synthesis was inhibited by treatment with 5-fluorodeoxyuridine (FUDR) (24). The changes produced by FUDR can be prevented by incorporation of thymidine in the FUDR-containing medium (24). Thus, when the conversion

of deoxyuridylic to thymidylic acid was by-passed by the introduction of exogenous thymidine, DNA synthesis could take place and the resultant changes in the RNP of the nucleolini were prevented. The factor common to all the circumstances in which enlargement of nucleolini occurs is some abnormality of DNA metabolism, most probably either a focal or general inhibition of synthesis. The exact mechanism by which a disturbance of DNA metabolism results in changes in the RNP of the nucleolini is not yet clear. It is of interest, however, that there is some evidence that the nucleolini may reflect the presence of a DNA-RNA hybrid, or at least that the structural integrity of the nucleolini is dependent upon the presence of intact DNA (22).

The results of cytochemical studies using toluidine blue, TBM, pyronin-methyl green and the Feulgen method, and selective extraction procedures for nucleic acids are quite clear. The inclusions in the virus-infected cells contain DNA and RNA. They also contain non-histone protein. The DNP and RNP of the inclusions respond in the same way as cellular nucleoprotein to digestion with nucleases and extraction with hot TCA. As reported by others (28), the inclusions were colored green or greenish yellow by acridine orange and their staining properties were unaffected by digestion by nucleases. The inclusions also stained after extraction of both nucleic acids by hot TCA. The procedures for nuclease digestion must have been effective since they removed all nucleic acids stainable by the TB, TBM, Feulgen and pyronin-methyl green methods. Residual green staining of cellular structures and the inclusions after extraction or digestion was not therefore due to the staining of nucleic acids. In the absence of acid mucopolysaccharides which stain metachromatically with TB, or which, by virtue of accompanying sugars, are PAS-positive (18), the residual staining by acridine orange must be attributed to binding of the dye by carboxyl groups of protein that were charged at pH 4.0. Herrman *et al.* (14) have shown that, under the conditions of their experiment, the basic dye toluidine blue binds protein as well as nucleic acid above pH 4.2. However, the pH above which a basic dye will bind the carboxyl groups will vary with the type of fixation (17), concentration of dye, temperature, and many other factors (21). Green staining of the inclusion body in tissue culture cells infected with rabies virus

and stained with acridine orange has also been shown to be due to protein and not to the presence of nucleic acids (20). Since digestion with pepsin and nuclease produced extensive cell damage, diffusion of material within the nucleus and green or even red staining of chromatin such digestion procedures would seem to be of doubtful value. Furthermore, there was no selective specificity of nuclease action since DNase and RNase, in combination with pepsin, were almost equally effective in removing the inclusions or preventing their coloration by dye. Furthermore, treatment with pepsin produced a reduction in the intensity of staining of DNA by the Feulgen method and, in combination with RNase, still further reduced the intensity of staining.

There is considerable evidence that the nucleic acid of unfixed viruses is not susceptible to digestion with nucleases (4, 10). The biological activity and therefore the nucleic acid of a number of unfixed riboviruses is not affected by digestion with ribonuclease (4). Furthermore, the nucleic acid phosphoryl groups, which bind cationic dyes such as toluidine blue or acridine orange, are often masked in unfixed preparations of cells or viruses (21, 27). After suitable fixation, however, the nucleic acid core of riboviruses (7) and

deoxyriboviruses (8, 9) becomes susceptible to digestion with nucleases. Similarly, some viruses stain more strongly with acridine orange after fixation (27). Digestion with nucleases prevents staining of fixed purified virus preparations containing RNA or double or single-stranded bacteriophage DNA. However, the yellow-green staining of fixed virus preparations containing double-stranded DNA is not prevented by digestion with DNase unless the preparation has been previously treated with pepsin (27). Epstein has shown that the core of adenovirus and herpes virus, two viruses containing double-stranded DNA, is susceptible to digestion by deoxyribonuclease after fixation by permanganate (8, 9). In the light of these observations and those reported here, it seems unlikely that acridine orange staining of the SV40 virus-induced inclusions was due to binding of dye by the DNA of the virus.

The authors wish to thank Joyce Sills Shahn for the drawings, and Oksana Bohachevsky and Kathy Wannemacher for valuable technical assistance.

This work was supported by United States Public Health Service Grants CA-05402-04, RG-813-03, A-102954-05, and CA-04534-06.

Received for publication, July 28, 1964.

REFERENCES

- ALFERT, M., and GESCHWIND, I. I., *Proc. Nat. Acad. Sc.*, 1953, **39**, 1991.
- BERNHARD, W., FEBVRE, H. L., and CRAMER, R., *Compt. rend. Acad. Sc.*, 1959, **249**, 483.
- BURSTONE, M. S., *J. Histochem. and Cytochem.*, 1955, **3**, 32.
- COLTER, J. S., *Progr. Med. Virol.*, 1959, **1**, 1.
- DIDERHOLM, H., *Acta Path. et Microbiol.*, 1963, **3**, 348.
- EAGLE, H., *J. Exp. Med.*, 1955, **102**, 595.
- EPSTEIN, M. A., *Nature*, 1958, **181**, 1808.
- EPSTEIN, M. A., and HOLT, S. J., *Nature*, 1963, **187**, 1050.
- EPSTEIN, M. A., *Nature*, 1962, **194**, 116.
- GARD, S., and MAALE, O., in *The Viruses*, (F. M. Burnet and W. M. Stanley, editors), New York, Academic Press, Inc., 1959, 359.
- GAYLORD, W. H., and HSUING, G.-D., *J. Exp. Med.*, 1961, **114**, 987.
- GRANBOULAN, N., TOURNIER, P., WICKER R., and BERNHARD, W., *J. Cell Biol.*, 1963, **17**, 423.
- HENLE, G., DEINHARDT, F., and RODRIGUEZ, J., *Virology*, 1959, **8**, 388.
- HERRMAN, H., NICHOLAS, J. S., and BORICIOUS, J. K., *J. Biol. Chem.*, 1950, **184**, 321.
- HINZ, R. N., BARSKI, G., and BERNHARD, W., *Exp. Cell Research*, 1962, **26**, 571.
- HSUING, G.-D., and GAYLORD, W. H., *J. Exp. Med.*, 1961, **114**, 975.
- KELLEY, E. G., *J. Biol. Chem.*, 1939, **127**, 55.
- LEBLOND, C. P., GLEGG, R. E., and EIDINGER, D., *J. Histochem. and Cytochem.*, 1957, **5**, 445.
- LEVINTHAL, J. D., and SHEIN, H. M., *Proc. Soc. Exp. Biol. and Med.*, 1963, **112**, 405.
- LOVE, R., and FERNANDES, M. V., *Proc. Soc. Exp. Biol. and Med.*, 1964, **116**, 560.
- LOVE, R., and LILES, R. H., *J. Histochem. and Cytochem.*, 1959, **7**, 164.
- LOVE, R., and RABOTTI, G., *J. Histochem. and Cytochem.*, 1963, **11**, 603.
- LOVE, R., RABSON, A. L., and WILDY, P., *Acta, Unio Internat. Contra Cancer*, 1964, **20**, 1384.
- LOVE, R., and WALSH, R. J., *Nature*, 1963, **197**, 795.
- LOVE, R., and WALSH, R. J., *J. Histochem. and Cytochem.*, 1963, **11**, 188.
- LOVE, R., and WILDY, P., *J. Cell Biol.*, 1963, **17**, 237.

27. MAYOR, H. D., *Prog. Med. Virol.*, 1962, 4, 70.
28. MAYOR, H. D., STINEBAUGH, S. E., JAMISON, R. M., JORDAN, L. E., and MELNICK, J. L., *Exp. and Molec. Path.*, 1962, 1, 397.
29. PEARSE, A. G. E., *Histochemistry, Theoretical and Applied*, Boston, Little Brown and Co., 2nd Edition, 1960, 998.
30. PONTEN, J., JENSEN, F., and KOPROWSKI, H., *J. Cell. and Comp. Physiol.*, 1963, 61, 145.
31. PRUNIERAS, M., CHARDONNET, Y., and SOHIER, R., *Ann. Inst. Pasteur*, 1964, 106, 1.
32. REAVAN, E. P., and COX, A. J., *J. Histochem. and Cytochem.*, 1963, 11, 782.
33. SCHNEIDER, W. C., *J. Biol. Chem.*, 1945, 161, 293.
34. SWEET, B. H., and HILLEMANN, M. R., *Proc. Soc. Exp. Biol. and Med.*, 1960, 105, 420.
35. TOURNIER, P., CATHALA, F., and BERNHARD, W., *Presse Med.*, 1957, 65, 1230.
36. TOURNIER, P., GRANBOULAN, N., and BERNHARD, W., *Compt. rend. Acad. Sc.*, 1961, 253, 2283.
37. WILLIAMS, M. G., and SHEININ, R., *Virology*, 1961, 13, 368.