

## POSTSYNAPTIC BODIES IN THE HABENULA AND INTERPEDUNCULAR NUCLEI OF THE CAT

MONIQUE MILHAUD and GEORGE D. PAPPAS. From the Department of Anatomy, Columbia University, College of Physicians and Surgeons, New York. Dr. Milhaud's permanent address is Laboratoire de Microscopie Electronique, Hôpital de la Salpêtrière, Paris, France

The morphological characteristics of synapses do not differ greatly, regardless of their location in the mammalian central nervous system (Palay, 1954; De Robertis, 1964). The two principal types of synaptic junctions, axodendritic and axosomatic, are characterized by certain specializations such as: (a) discrete clusters of vesicles and often mitochondria in the presynaptic process, (b) varying amounts of dense material closely associated with both the apposing pre- and postsynaptic membranes, and (c) extracellular material in the distinct space or cleft, about 200 to 250 Å wide, between the pre- and postsynaptic components (Van der Loos, 1963; De Robertis, 1964; Pappas and Purpura, 1966). Although specializations have been noted occasionally in the presynaptic process at various sites (Sjöstrand, 1958; Gray, 1963), postsynaptic specializations, with the exception of dense material closely associated with the postsynaptic membrane, are missing or very rare (cf. Colonnier, 1964; Taxi, 1961; Gray, 1962). However, in studying the synaptic organization of the habenula and interpeduncular nuclei of adult cats, it was found that discrete postsynaptic bodies are of common occurrence in both axosomatic and axodendritic junctions.

### MATERIAL AND TECHNIQUES

The brains of six adult cats were perfused with 2.5% glutaraldehyde phosphate buffered at pH 7.4. The habenula and interpeduncular nuclei were removed and postfixed with osmium tetroxide. The tissue was embedded in Epon, and sections prepared in the usual manner were examined with an RCA-EMU-3F microscope.

### RESULTS

Discrete postsynaptic bodies are present in  $\frac{1}{3}$  of the axosomatic (Fig. 1) and axodendritic junctions in both the habenula and interpeduncular nuclei (Figs. 2 to 7). These bodies are also found in association with synapses which contain not only clusters of clear vesicles but also some larger vesicles with dense cores in their presynaptic pro-

cesses (Fig. 1). The postsynaptic bodies are round and about 200 to 250 Å in diameter. They are regularly arranged, appearing in a single line in the micrographs. They are located about 500 Å from the postsynaptic membrane and are distinct from the postsynaptic dense material. Their shape is assumed to be spherical, as they present the same circular profile in longitudinal and cross-sections (Figs. 2 and 3). Furthermore, since a linear array of these bodies is present in both longitudinal and cross-sections, there must be more than a single row at a given synaptic junction. In a thick tangential section, shown in Fig. 5, there is evidence of two rows of postsynaptic bodies (at arrows). Profiles of 2 to 10 postsynaptic bodies have been found and their number apparently does not vary with the size of the junction as determined by the presence of the postsynaptic dense material there. These postsynaptic bodies are more frequently found in junctions in which the postsynaptic membrane has a greater accumulation of dense material than the presynaptic one. They are composed of fine dense granular material and are irregular in outline and not bounded by a membrane. They are arranged at regular intervals of about 175 to 200 Å, as measured from center to center of the bodies. If a postsynaptic body is missing from this regular line-up, there is a proportional increase of interbody space (cf. Fig. 4). In less than optimally thin sections, the interbody space also contains some granular material which may obscure the periodicity.

The postsynaptic bodies are present not only in axosomatic and in large axodendritic junctions, but also in dendritic spines. The occurrence in connection with spine synapses is very striking. Dendrites of the habenula and the interpeduncular nuclei are often seen to have spinous projections but without a spine apparatus (Gray, 1959, 1963). The spine is surrounded by synapses. There are axons forming synapses on the neck of the spine but not at the bulbous tip. At these sites, a single row of the regularly arranged dense bodies forms the central axis of the neck of the club-shaped spine

(Figs. 6 and 7). Being in the center of the spinous neck, this row is about 500 Å from the postsynaptic membrane, as in other axodendritic and axosomatic synapses. In the bulbous terminal, many vesicles or vacuoles of various calibres are present (Fig. 7). Occasionally a single large vacuole containing a few vesicles is found, as shown in Fig. 6.

#### COMMENT

The dense material closely associated with the postsynaptic membrane has been called "the subsynaptic web" (De Robertis, 1964) and the "subs synaptic organelle" (Van der Loos, 1963). However, the postsynaptic bodies are dense, discrete, and not attached to the postsynaptic thickenings or fibers. In this way, they resemble the postsynaptic bars described by Taxi (1961) in the autonomic ganglia of the frog. Similar structures have been seen in the spinal cord (Gray, 1962) and cerebral cortex (Colonnier, 1964). Recently we found the same structures in the thalamus, although their occurrence is quite rare. It is their widespread presence in the habenula and the interpeduncular nuclei, and not their uniqueness, which is to be emphasized. On the other hand, their appearance in the club-shaped dendritic

spines, in which they form the axis of the neck, is distinctive. Finally, it is interesting to note their common occurrence in two areas remarkable for their high content of monoaminoxidase (Smith, 1963; Schimizu et al., 1959; Bouchaud et al., 1965), a substance known to limit the activity of cerebral amines.

This study was supported in part by Public Health Service grants from the National Institute of Neurological Diseases and Blindness (NB-02314-07 and NB-03448-05) and the United Cerebral Palsy and Educational Foundation.

Dr. Pappas is the recipient of a Public Health Service research career award (1-K3-NB-21,947-01) from the National Institute of Neurological Diseases and Blindness.

Dr. Milhaud is an Attachée de Recherche à L'Institut National de la Santé et Recherches Médicales (INSERM) (France). Supported in part by a NATO Fellowship.

Received for publication 7 March 1966.

#### REFERENCES

- BOUCHAUD, CL., COUTEAUX, R., and GAUTRON, J., 1965, L'inhibition des monoamineoxydases du cerveau du rat par la  $\beta$ -phenyl-isopropylhydrazine l'pharmaline-etude histochemique de l'action de ces

---

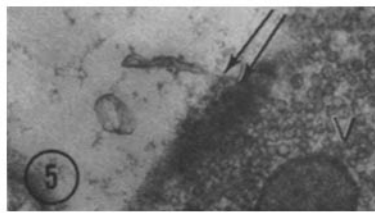
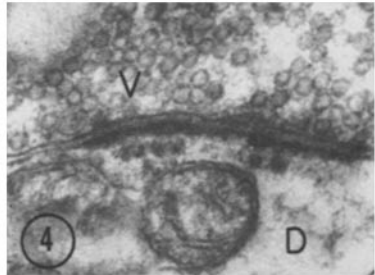
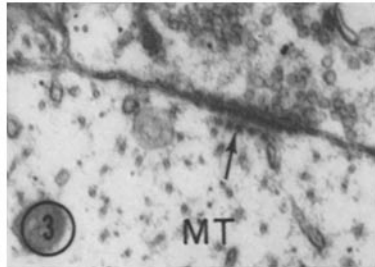

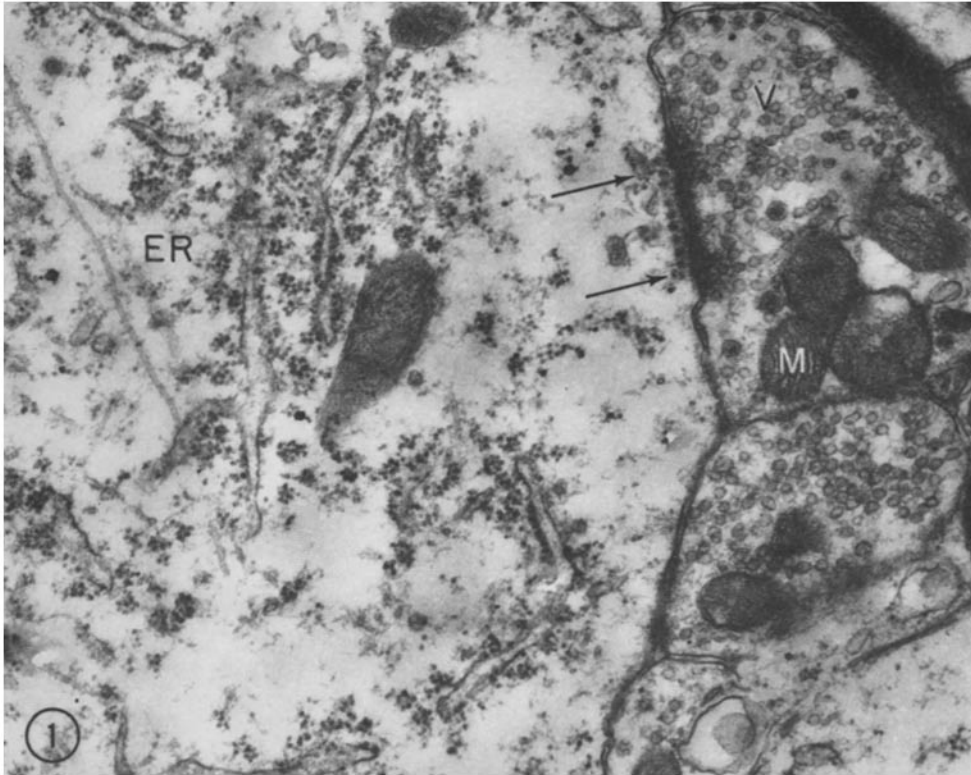
FIGURE 1 Electron micrograph of a portion of a neuron in the medial habenula nucleus of a cat. An axosomatic synapse is formed on the surface. Vesicles (*V*) of both the small clear type and larger ones with dense cores, as well as clusters of mitochondria (*M*), are present in the axon. In the soma, a linear array of postsynaptic bodies can be found (at arrows). These dense bodies are about 500 Å from the postsynaptic membrane. Elements of the endoplasmic reticulum (*ER*) are found in the cell body.  $\times 28,000$ .

FIGURE 2 A portion of an axon in the habenula. Two synaptic junctions (at arrows) with a dendrite are shown in longitudinal section. Extended arrays of microtubules (*MT*) are present in the dendrite. Both synaptic junctions have evenly spaced postsynaptic bodies in a linear array. *MV*, multivesicular body; *V*, presynaptic vesicles.  $\times 31,000$ .

FIGURE 3 A section similar to that of Fig. 2, showing an axodendritic synapse. The dendrite in this case is cut in cross-section since circular profiles of microtubules (*MT*) can be seen. As in longitudinal views, a linear arrangement of the postsynaptic bodies (arrow) is shown.  $\times 26,000$ .

FIGURE 4 Axodendritic synapse in interpeduncular nucleus. The postsynaptic bodies in the dendrite (*D*) are arranged in regular intervals of 175 to 200 Å. The absence of two of these bodies in this micrograph results in the proportional increase of the space. *V*, presynaptic vesicles.  $\times 42,000$ .

FIGURE 5 A tangential section of an axodendritic synapse of the habenula. Two rows of postsynaptic bodies are shown at arrows. *V*, presynaptic vesicles.  $\times 30,000$ .



- inhibiteurs et de leur antagonisme, *Compt. rend. Acad. sc.*, **260**, 348.
- COLONNIER, M., 1964, Experimental degeneration in the cerebral cortex, *J. Anat.*, London, **98**, 47.
- DE ROBERTIS, E., 1964, *Histophysiology of synapses and neurosecretion*, New York, Pergamon Press.
- GRAY, E. G., 1959, Electron microscopy of synaptic contacts on dendrite spines of the cerebral cortex, *Nature*, **183**, 1592.
- GRAY, E. G., 1962, Electron microscopy of synaptic organelles of the central nervous system, Proceedings of the 4th International Congress of Neuro-pathology, München, 1961, (H. Jacob, editor), Georg Thiem Verlag, Stuttgart, **2**, 57.
- GRAY, E. G., 1963, Electron microscopy of presynaptic organelles of the spinal cord, *J. Anat.*, London, **97**, 101.
- GRAY, E. G., and GUILLERY, W., 1963, A note on the dendritic spine apparatus, *J. Anat.*, London, **97**, 3, 389.
- PALAY, S. L., 1954, Electron microscope study of the cytoplasm of neurons, *Anat. Rec.*, **118**, 336.
- PAPPAS, G. D., and PURPURA, D. P., 1966, Distribution of colloidal particles in extracellular space and synaptic cleft substance of mammalian cerebral cortex, *Nature*, **210**, 1391.
- SHIMIZU, N., MORIKAWA, N., and OKADA, M., 1959, Histochemical studies of MAO of the brain of rodents, *Z. Zellforsch. u. Mikr. Anat.*, **49**, 389.
- SJÖSTRAND, F. S., 1958, Ultrastructure of retinal rod synapses of the guinea pig eye as revealed by three-dimensional reconstructions from serial sections, *J. Ultrastruct. Research*, **2**, 122.
- SMITH, B., 1963, MAO in pineal, neurohypophysis and brain of the albino rat, *J. Anat.*, London, **97**, 81.
- TAXI, J., 1961, Etude de l'ultrastructure des zones synaptiques dans les ganglions sympathiques de la grenouille, *Compt. rend. Acad. sc.*, **252**, 174.
- VAN DER LOOS, H., 1963, Fine structure of synapses in the cerebral cortex, *Z. Zellforsch. u. Mikr. Anat.*, **60**, 815.

---

FIGURE 6 A dendritic spine in the habenula. In this micrograph, the axons (A) form synapses on both sides of the neck of the spine. A single row of regularly arranged dense bodies (at arrows) forms the central axis of the neck of the club-shaped spine. The distance from the postsynaptic bodies to the postsynaptic membrane is about 500 Å, as in other axodendritic and axosomatic synapses. In the bulbous terminal of the spine, a large vacuole containing a few vesicles can be seen.  $\times 36,000$ .

FIGURE 7 A longitudinal section of dendritic spine in the habenula. As shown in Fig. 6, spines in the habenula and the interpeduncular nuclei are characterized by having synapses surrounding the neck region of the bulbous spine. A single row of regularly arranged postsynaptic bodies is present in the core of the neck of the spine (at arrows). The extracellular synaptic gap substance is arranged or condensed in striae perpendicular to the pre- and postsynaptic membranes. In the bulbous terminal some small vesicles are present. A, axons.  $\times 48,000$ .

