

# FETAL RAT INTESTINAL ABSORPTION OF HORSERADISH PEROXIDASE FROM SWALLOWED AMNIOTIC FLUID

DONALD ORLIC and ROBERT LEV

From the Departments of Anatomy and Pathology, New York Medical College,  
Valhalla, New York 10595

## ABSTRACT

Horseradish peroxidase (HRP) injected into amniotic fluid is swallowed by rat fetuses and within 3–6 h reaches the gut lumen. This macromolecular protein is then absorbed by the columnar lining cells via a system of apical cytoplasmic tubules formed by invaginations of the plasma membrane. From cytoplasm subjacent to the brush border HRP is transported, within vacuoles, to the supranuclear region, where some is retained for at least 18 h, and to interepithelial spaces. Extracellular enzyme is then found throughout the epithelial basement membrane and between connective tissue cells of the mucosal and submucosal layers. Finally, HRP can be detected within lumina of blood and lymphatic capillaries, strongly suggesting that it is transported from the intestine to the circulation.

## INTRODUCTION

Rat fetal intestine on days 19–21 of pregnancy is known to display a level of structural development comparable to that observed in the neonate (Dunn, 1967), before the first feeding. It is characterized by villi lined with a single layer of columnar epithelial cells which demonstrate, on their absorptive surface, a well-defined brush border and, from day 20, pinocytotic vesicles (Hayward, 1967).

Despite this degree of morphologic maturity, little is known regarding intestinal function *in utero*. However, it is now clear that the luminal surface of fetal rat gut is presented, near term, with swallowed amniotic fluid which is subsequently absorbed (Brambell and Halliday, 1956; Williams and Beck, 1969). In primates (Seeds, 1965), this fluid consists of a variety of substances ranging from small electrolytes to macromolecules, but it

is still uncertain to what extent macromolecules in amniotic fluid are absorbed by intestine and/or utilized in fetal development.

The present work tests the hypothesis that macromolecules in swallowed amniotic fluid can be absorbed by jejunum and ileum during late gestation, extending our earlier findings (Lev and Orlic, 1972). For this we utilized horseradish peroxidase (HRP, mol wt  $\sim$ 40,000), a cytochemical marker widely applied in electron microscope studies, to demonstrate the pathway of epithelial uptake of macromolecular protein in gut (Cornell et al., 1971; Hugon, 1971; Rhodes and Karnovsky, 1971).

## MATERIALS AND METHODS

Pregnant Holtzman rats (Holtzman Co., Madison, Wis.) were utilized on days 19–21. While under ether

anesthesia, their uteri were surgically exposed by an abdominal incision. 2 mg HRP (Sigma Chemical Co., St. Louis, Mo., type VI) in 0.1 ml saline were injected into the amniotic cavity of several fetuses in each rat. Control fetuses received saline. The incisions were then sutured and the animals allowed to recover. At each of the following time intervals after injection, 1, 3, 6, 10, and 18 h, a total of four to eight fetuses were obtained upon reopening the uterine cavities. From each fetus a portion of jejunum was removed and in some fetuses at each time point ileal tissue was also obtained. Stomach and colon were also taken from some fetuses sacrificed at 6 and 18 h after injection of peroxidase. These two organs (which do not absorb peroxidase) were examined for recirculating intestinally absorbed peroxidase.

Tissues were fixed in 3% paraformaldehyde-glutaraldehyde in 0.1 M cacodylate buffer at pH 7.4 (Karnovsky, 1965) for 2–3 h and washed overnight in cacodylate buffer. Sections 40–60  $\mu\text{m}$  thick were prepared on a Smith-Farquhar tissue sectioner. These were incubated for 30–60 min at room temperature in a medium containing 10 ml of 0.05 M Tris buffer, pH 7.6, 5 mg of 3,3'-diaminobenzidine tetrahydrochloride, and 0.1 ml of 1% hydrogen peroxide (prepared from 30%  $\text{H}_2\text{O}_2$ ) (Graham and Karnovsky, 1966). Some sections were incubated in incomplete medium lacking either 3,3'-diaminobenzidine or hydrogen peroxide.

After incubation, the tissue slices were postfixed in phosphate-buffered osmium tetroxide, pH 7.4, for 90 min, dehydrated in a series of graded alcohol solutions and propylene oxide, and embedded in Epon 812. Thick, 0.5  $\mu\text{m}$  plastic sections for light microscopy were not counterstained with toluidine blue; thin sections were examined in a Siemens-Elmiskop I electron microscope after lead citrate staining.

Some specimens of jejunum and ileum taken 6 and 18 h after peroxidase injection were fixed overnight in 10% formalin containing 30% sucrose at 4°C and then washed overnight in 30% sucrose at 4°C. Frozen sections (10–12  $\mu\text{m}$  thick) of these specimens were subsequently incubated for both acid phosphatase and peroxidase (Straus, 1964) or for each enzyme alone. Controls for acid phosphatase consisted of sections incubated without substrate; peroxidase control sections were incubated in diaminobenzidine alone.

## RESULTS

### *Fetal Swallowing of Peroxidase*

Although the pregnant rats recovered within 10–15 min after the operative procedures, it was unclear whether fetal swallowing was interrupted

by these procedures. In any event, the enzyme did not label the intestine of any fetus during the 1st h after intra-amniotic injection. At 3 h, however, peroxidase reached the level of the jejunum in two of four fetuses, and specimens of jejunum and ileum obtained at later intervals, 6, 10, and 18 h, were generally positive for exogenous enzyme.

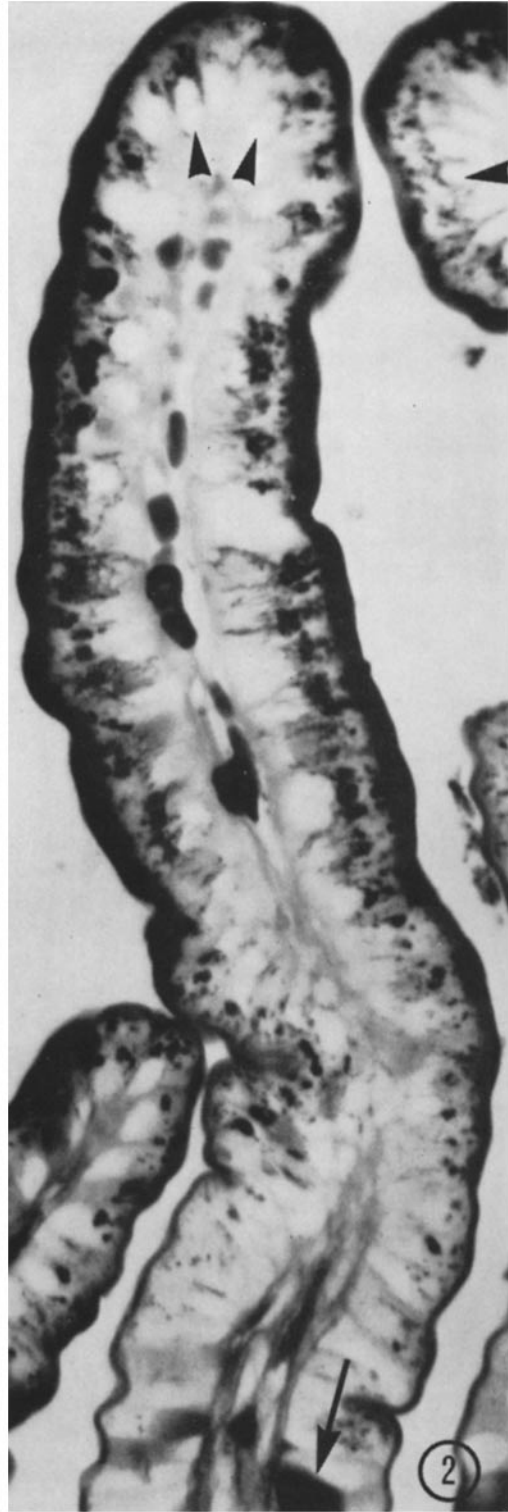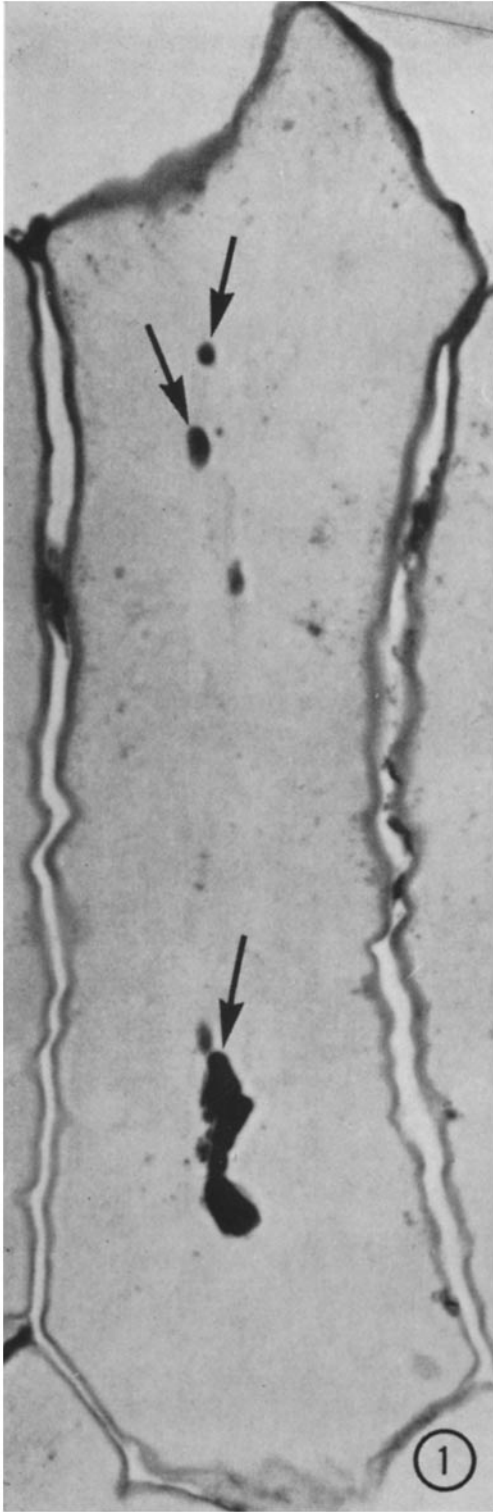
### *Intestinal Absorption of Peroxidase*

**LIGHT MICROSCOPY.** Thick (0.5  $\mu\text{m}$ ), plastic-embedded sections of intestine were examined by phase and ordinary light microscopy. The intestine in saline-injected control fetuses was devoid of reaction product except for granulocytes containing myeloperoxidase and erythrocytes, in which hemoglobin exhibits a peroxidatic activity. When incubated in incomplete medium these samples and those from peroxidase-injected fetuses were totally negative.

Specimens obtained 1 h after injection of peroxidase were indistinguishable from saline-injected controls. At 3 h, however, the epithelium in some specimens was clearly stained (Fig. 1). Reaction product was observed on the luminal surface, or brush border, of the columnar absorptive cells, only trace amounts of the enzyme were present within the cytoplasm.

Intestine removed at 6 h after treatment demonstrated a considerably higher level of absorbed peroxidase than did earlier specimens. When villi obtained at this time were viewed longitudinally, it was noted that the intensity of staining was most pronounced in the apex and midregion and that it dropped markedly from the midregion to the base (Fig. 2). This was observed with respect to both brush border and intracellular labeling. Within epithelial cells reaction product was viewed as discrete apical cytoplasmic granules, except in a very few, possibly injured cells, where reaction product was diffusely distributed throughout the cytoplasm. Exogenous enzyme was also localized in underlying connective tissue spaces of lamina propria and submucosa, and, in some instances, within vessel lumina.

Jejunum and ileum obtained at 10 h demonstrated a labeling pattern virtually identical with that observed in 6-h specimens. Several notable changes occurred, however, at 18 h. In these specimens, the brush border was less intensely stained



and the apical cytoplasm displayed a single, large supranuclear granule approximately 1–2  $\mu\text{m}$  in diameter

Frozen sections stained for both acid phosphatase and peroxidase showed a superimposed reaction for both enzymes in the apical cytoplasm of the absorptive cells lining the villi in the same sites normally occupied by lysosomes. The brush border and subjacent cytoplasm stained only for peroxidase. Stomach and colon (obtained at 6 and 18 h) were negative for exogenous peroxidase.

**ELECTRON MICROSCOPY** Specimens from fetuses removed at 3, 6, 10, and 18 h after treatment were examined by electron microscopy. At 3 h, horseradish peroxidase was observed on the brush border, but virtually no reaction product occurred within the cell. In gut obtained at later intervals (6 and some 10 h specimens), exogenous enzyme was observed at several sites extending from the brush border of epithelial cells to lumina of vessels in underlying connective tissues (Figs 3–12). In these specimens, ultrastructural analysis revealed that HRP was localized on the epithelial cell membrane including the external surface of microvilli (Fig 3). It was not observed within either the core of microvilli or the tight junctional complex. Within intestinal absorptive cells, reaction product occurred in the cytoplasm immediately beneath the microvillous border, in the supranuclear region, and along the lateral cell margins (Figs. 4–6).

From alternate thick and thin sections (Figs 5, 6) light microscope observations on the distribu-

tion of exogenous peroxidase were correlated with those obtained by electron microscopy. Sites that demonstrated reaction product were analyzed at several magnifications (Figs 6–8). In the cytoplasm underlying the brush border, reaction product was present within an extensive system of branching or anastomosing canaliculi (Fig 7) which appeared to represent invaginations of the plasmalemma. Small vacuoles, possibly representing phagosomes, 0.05–0.25  $\mu\text{m}$  in diameter, dispersed throughout this area were thought to be expanded, and perhaps separated, portions of the terminal ends of canaliculi.

The supranuclear peroxidase-positive vacuoles were of various sizes, ranging approximately from 0.05 to 0.8  $\mu\text{m}$  in diameter. In a few instances, Golgi cisterna were present within this region of the cell (Fig. 8), but it was not clear whether this organelle was involved in the accumulation of peroxidase in this fetal epithelium. The larger vacuoles, possibly phagolysosomes, were apparently retained in the supranuclear cytoplasm, where in cells of 10- and especially 18-h specimens, they were replaced by a single large (1–2  $\mu\text{m}$  diameter) vacuole. Smaller vacuoles were, in addition, observed in the lateral cytoplasm of these absorptive cells at the level of the nucleus (Fig 9). Their fusion with the lateral cell membrane was observed in some instances (Fig 10), and it was felt that this represented the site where peroxidase was released into the intercellular channels.

Peroxidase in interepithelial cell spaces was restricted mainly to the basal region of the epithe-

---

FIGURE 1 Light micrograph, plastic section. Jejunum from 21-day rat fetus obtained 3 h after intra-amniotic injection of HRP. This villus, in longitudinal section, displays a gradient of reaction product within the brush border. Heavy staining occurs in the apical and midregion of the villus, where the microvilli are more highly developed. Although individual absorptive cells cannot be identified (the section is stained only for peroxidase), trace amounts of enzyme are apparent within the cytoplasm near the brush border. Red blood cells in capillaries of the lamina propria are heavily stained (arrows).  $\times 625$ .

FIGURE 2 Light micrograph, plastic section. Jejunum from 21-day rat fetus obtained 6 h after intra-amniotic injection of HRP. Enzyme labeling is very extensive at this time and, as at 3 h, there is a gradient of HRP from the apex to the base of the villus. Large granular deposits of reaction product occupy the supranuclear cytoplasm of absorptive cells. In these peroxidase-stained sections, nuclei (arrowheads) are evident as clear areas rimmed by reaction product which extends along the lateral margins of the cells. Diffuse cytoplasmic staining characterizes a few cells at the base of the villus (arrow).  $\times 575$ .

lial layer. Peroxidase was observed within the basement membrane, which it penetrated, and between cells of the underlying connective tissue (Fig. 11). In the lamina propria and submucosa, reaction product was localized within the basement membrane and lumen of blood capillaries (Fig. 12). The protein also occurred in lymphatics of the gut. In these vessels, however, reaction product was limited to the luminal surface of endothelial cells and was not present within the lumen (Fig. 13).

## DISCUSSION

### *Absorption by Rodent Fetal Intestine*

There is some morphologic evidence for *in utero* uptake of low molecular weight compounds by fetal rat intestine (Williams and Beck, 1969). However, the only histologic indication of macromolecular absorption in rodents is the immunofluorescent work of Anderson and Leissring (1961) on serum protein absorption in fetal guinea pig intestine. Our work demonstrates the absorption of HRP and provides an ultrastructural basis for the mechanism by which this protein, and possibly normally occurring macromolecules in swallowed amniotic fluid, might be absorbed and transported by fetal intestine.

### *Mechanism of Absorption and Transport*

The incorporation of intact proteins by the absorptive cells of newborn rat jejunum is well documented. Several important studies using various

macromolecular substances, including antibodies, (Clark, 1959; Kraehenbuhl and Campiche, 1969; Rodewald, 1970) have established the intracellular route by which these macromolecules traversed the epithelial layers. HRP appears to follow a similar pathway in fetal rat jejunum.

Tight junctional complexes of jejunal epithelium are established in 19–21-day rat fetuses. The tight junctional complexes apparently block the passage of luminal peroxidase to the apical intercellular spaces, and it therefore seems likely that the tubular invaginations of the plasmalemma represent the only route by which peroxidase enters the absorptive epithelium. This finding concurs with earlier work demonstrating the significance of these apical canaliculi in macromolecular absorption by neonatal rat jejunum (cited above) and ileum (Wissig and Graney, 1968, Graney, 1968; Cornell and Padykula, 1969).

Transfer of the enzyme seemed to occur in vacuoles from cytoplasm beneath the brush border to the supranuclear regions. The enzyme accumulated there with apparently little or no degradation, since large deposits of reaction product could still be readily observed in this region at 18 h after intra-amniotic administration. The relationship between these supranuclear vacuoles and the acid phosphatase-positive material, presumably lysosomal, observed by the Straus method, is not clear, i.e., phagolysosomes could not be unequivocally identified by the techniques employed here.

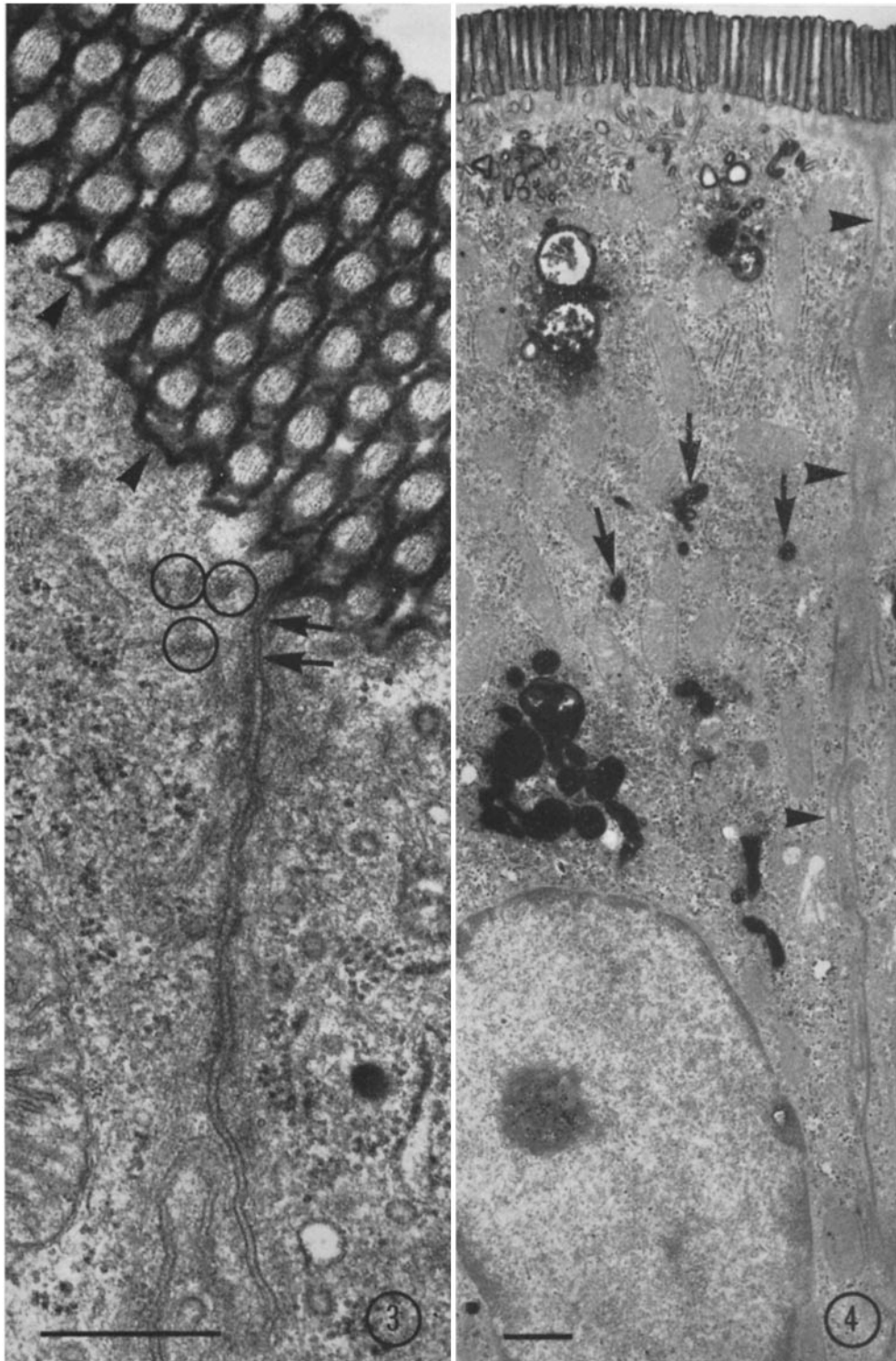
Subsequent transport of peroxidase involved the movement of vacuoles to the lateral cell regions. Our observations of vacuole fusion with the lateral

---

FIGURES 3-13 Jejunum from 21-day rat fetuses removed 6 h after intra-amniotic injection of HRP. All figures are from thin sections counterstained with lead citrate except Fig. 5 which is a thick section for light microscopy that was not counterstained.

FIGURE 3 An oblique section through the brush border and subjacent cytoplasm of two jejunal absorptive cells. The plasmalemma (arrowheads) and microvilli are labeled. Filaments within microvilli extend into the apical cytoplasm (circles). The tight junction (arrows) prevents passage of luminal HRP to the intercellular space.  $\times 63,000$ . Scale marker  $0.5 \mu\text{m}$ .

FIGURE 4 Longitudinal section through a columnar absorptive cell. HRP is found in the brush border, apical cytoplasm, and supranuclear region. Several vacuoles (arrows) may represent HRP being transported to the supranuclear site. The intercellular region is again negative (arrowheads).  $\times 9800$ . Scale marker  $1 \mu\text{m}$ .



plasmalemma, a phenomenon described earlier in adult jejunal transport of peroxidase (Cornell et al, 1971) and ferritin-conjugated immunoglobulin in newborn rats (Rodewald, 1970), suggested that peroxidase release to the intercellular spaces occurred by exocytosis. Extracellular peroxidase diffused readily through the epithelial basement membrane to the lamina propria where it entered microvessels.

HRP absorbed by the gut of newborn and adult rats is known to reach the general circulation (Walker et al, 1971; Warshaw et al, 1971), presumably the same occurred in fetuses utilized in the present study. However, light microscope examination of stomach and colon, which do not absorb HRP, failed to reveal any enzyme in vessel lumina, indicating that recirculation is minimal or absent. Also, circulating exogenous enzyme is known to enter the basal cytoplasm of absorptive cells, in mice, as granular material (Hampton and Rosario, 1967), but in the present study the basal portion of jejunal cells is virtually devoid of reaction product.

It should be noted that rat visceral yolk sac apparently does not transport absorbed HRP to the fetus via vitelline vessels (Beck et al, 1967), unlike mouse (Robertson et al, 1971) and guinea pig visceral yolk sac (King and Enders, 1970). Therefore it seems likely that little, if any, peroxidase leaking across the amnion could reach the fetal circulation via this route.

#### *Significance of Intestinal Absorption for the Fetus*

It has heretofore been believed that the swallowing and intestinal resorption of amniotic fluid are

concerned primarily with fluid balance (Seeds, 1965). We would like to suggest that the fetal intestine, via its capacity to absorb solutes contained within swallowed amniotic fluid, may serve as an alternate pathway for the transfer of a wide spectrum of substances from mother to fetus, and not solely antibodies as proposed by Brambell (1958). This pathway might be most useful concerning macromolecular transport in view of the current demonstration of the ability of the fetal intestine to absorb those compounds and the known inability of most substances larger than mol wt 1000 to traverse the placenta (Schultz, 1970).

One function that might be subserved by this alternate route is fetal nutrition. It has been reported that labeled amino acids (Sugawa et al., 1963) and fatty acids (Koren and Shafrir, 1964) injected into rat amniotic fluid are absorbed and utilized by the fetus.

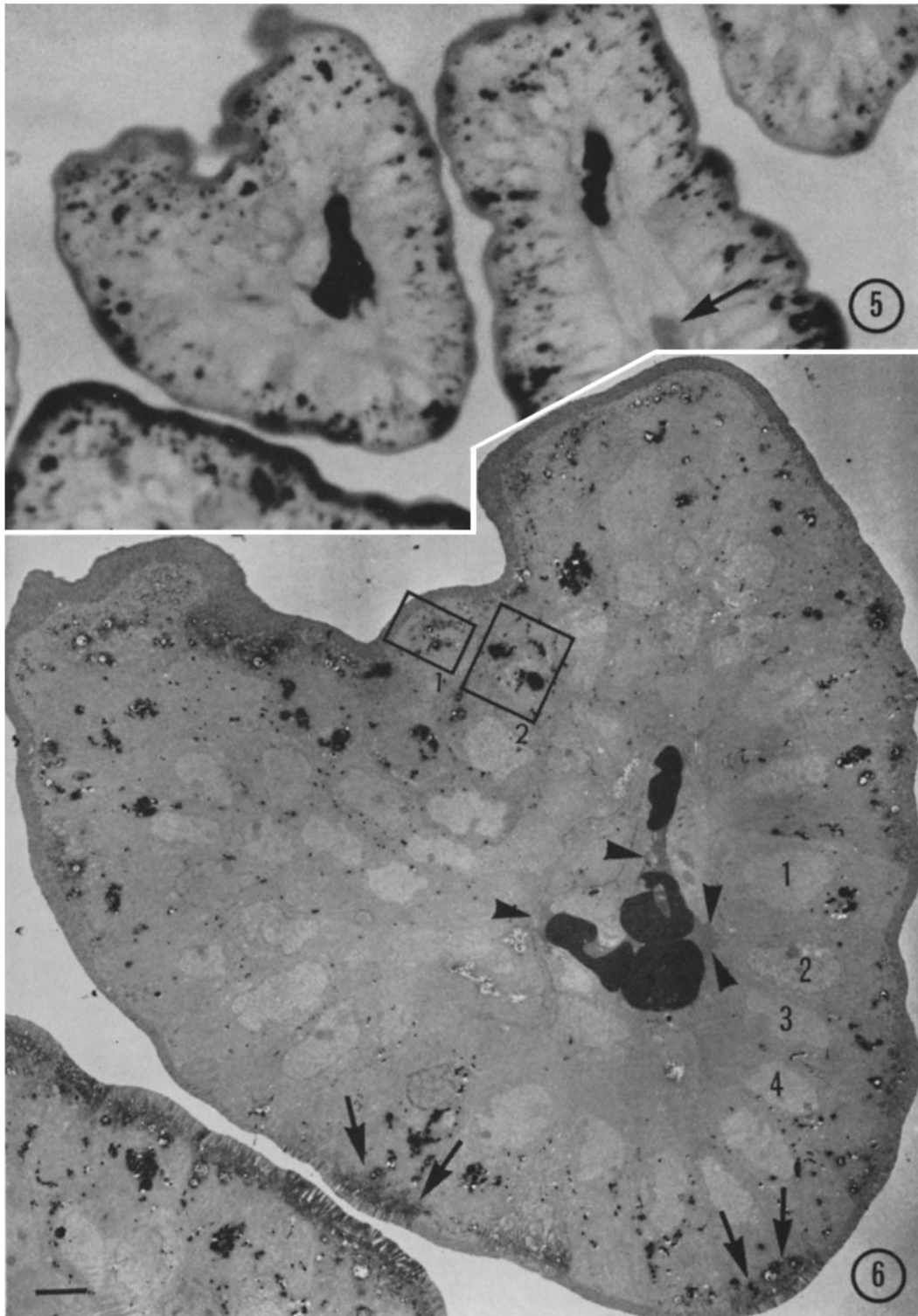
The authors are indebted to Dr. Ralph Strelbel for assistance with the intra-amniotic injections during the early stages of the study, to Miss Margarita Schmid and Miss Lillian Bedell for their skillful technical assistance throughout the course of this study, and to Miss Carol Schuh for typing the manuscript. Drs. P. Jokelainen and F. Giacomelli kindly reviewed the manuscript.

This work was supported by research grant 5 R01 HD-01666-05 from the National Institute of Child Health and Human Development, National Institutes of Health, United States Public Health Service, and by research grant 5 R01 AM-13269-03 from the National Institute of Arthritis and Metabolic Diseases, National Institutes of Health, United States Public Health Service. This study was also supported in part by GRS Grant RR-5398-11 from the General Re-

---

FIGURE 5 Light micrograph, plastic section. Section through several villi. The degree of HRP staining varies in adjacent villi. The lumen of a vessel in the lamina propria of one villus (arrow) is filled with reaction product. From an adjacent thin section one villus (upper left), photographed in the electron microscope, appears in Fig. 6.  $\times 800$ .

FIGURE 6 In this oblique section through the distal portion of a villus it is evident that within individual cells HRP is distributed throughout the cytoplasm beneath the brush border, in the supranuclear zone, and at the lateral margin of the cell near the nucleus. In cells sectioned longitudinally (several are indicated 1, 2, 3, 4), it is apparent that virtually no HRP-positive vacuoles occur in the basal cytoplasm. A few cells (arrows) demonstrate diffuse staining within the core of microvilli and adjacent cytoplasm (the significance of this is not clear). Traces of reaction product occupy the capillary lumen (arrowheads). Areas within rectangles are viewed at higher magnification in Figs. 7 and 8.  $\times 1700$ . Scale marker 5  $\mu\text{m}$ .





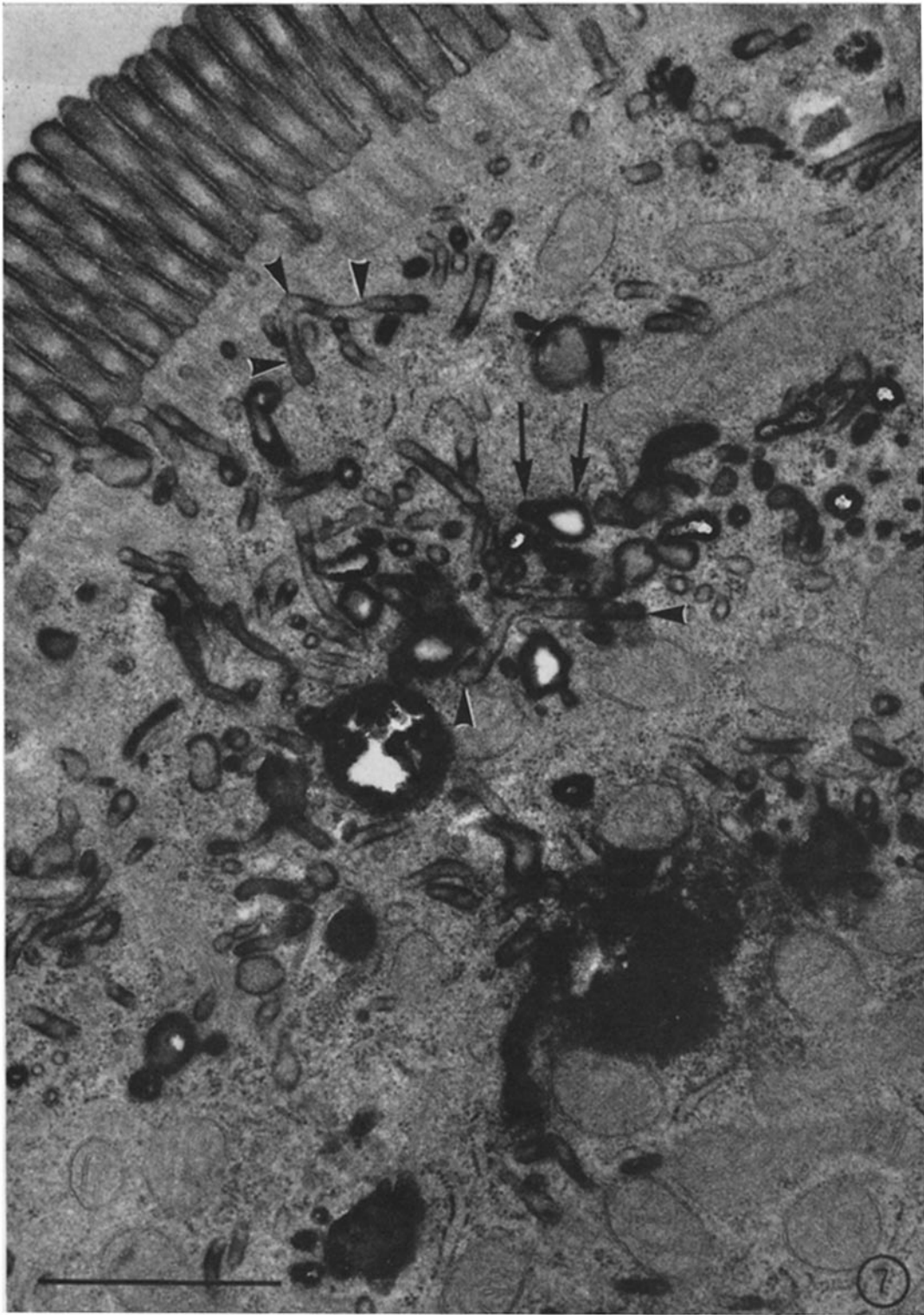


FIGURE 7 A higher magnification view of the area within rectangle 1 in Fig. 6. This region near the brush border is characterized by branching tubules (arrowheads). Their terminal ends are thought to expand (arrows) and form vacuoles which may then transport the exogenous peroxidase away from this site of initial absorption.  $\times 74,000$ . Scale marker  $0.5 \mu\text{m}$ .

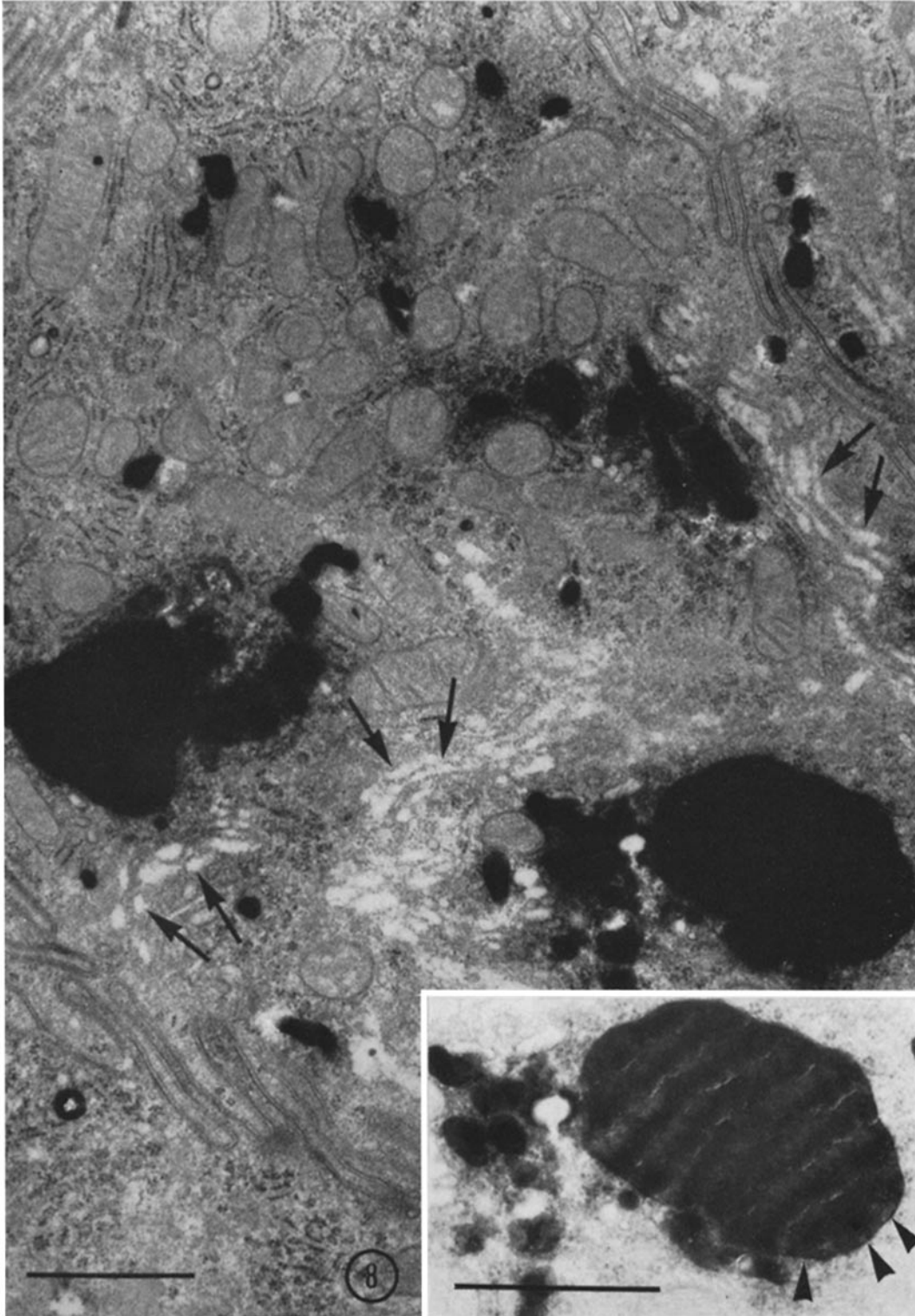
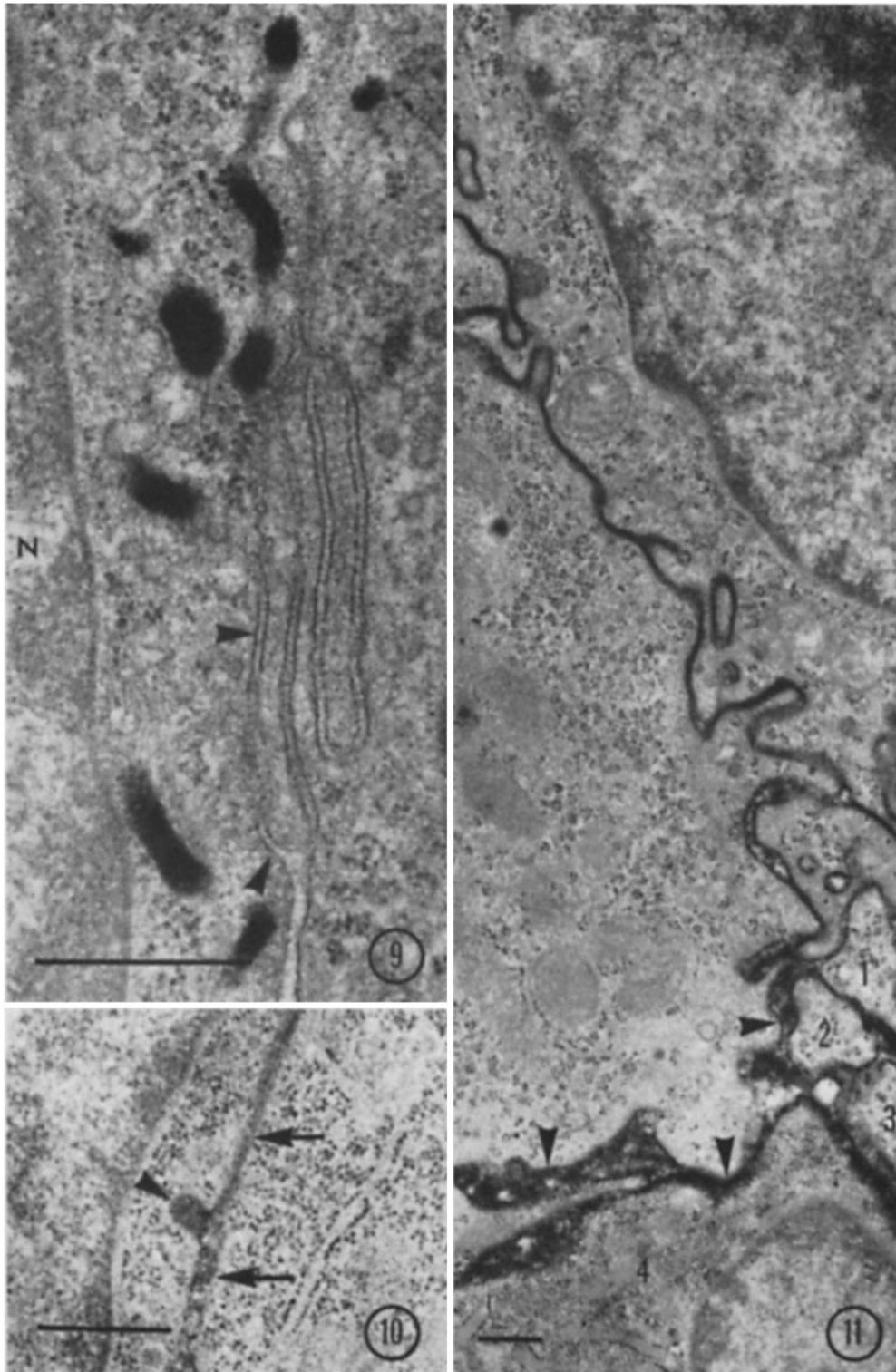


FIGURE 8 A higher magnification view of the area within rectangle 2 in Fig. 6. Deposits of HRP are abundant in the supranuclear region. Although stacks of Golgi cisterna (arrows) are found in this micrograph, this organelle is generally inconspicuous and may not be involved in the accumulation of HRP at this site. The vacuoles are of various size and shape; one is seen in the *inset*. When the density of the vacuole is reduced photographically, it is possible to distinguish the limiting membrane (arrowheads).  $\times 52,000$ . Scale marker  $0.5 \mu\text{m}$ . (*Inset*  $\times 64,000$ . Scale marker  $0.5 \mu\text{m}$ .)



search Support Branch, Division of Research Facilities and Resources, National Institutes of Health.

Received for publication 26 June 1972, and in revised form 31 August 1972.

## REFERENCES

- ANDERSON, J. W., and J. C. LEISSRING. 1961 The transfer of serum proteins from mother to young in the guinea pig. II. Histochemistry of tissues involved in prenatal transfer. *Am J Anat* **109**:157.
- BECK, F., J. B. LLOYD, and A. GRIFFITHS. 1967 A histochemical and biochemical study of some aspects of placental function in the rat using maternal injection of horseradish peroxidase. *J. Anat* **101**:461.
- BRAMBELL, F. W. R. 1958. The passive immunity of the young mammal. *Biol. Rev. (Camb.)* **33**:48.
- BRAMBELL, F. W. R., and R. HALLIDAY. 1956 The route by which passive immunity is transmitted from mother to foetus in the rat. *Proc. Roy. Soc. Ser. B* **145**:170.
- CLARK, S. L., JR. 1959. The ingestion of proteins and colloidal materials by columnar absorptive cells of the small intestine in suckling rats and mice. *J. Biophys. Biochem. Cytol* **5**:11.
- CORNELL, R., and H. A. PADYKULA. 1969. A cytological study of intestinal absorption in the suckling rat. *Am J. Anat* **125**:291.
- CORNELL, R., W. A. WALKER, and K. J. ISSELBACHER. 1971. Small intestinal absorption of horseradish peroxidase. A cytochemical study. *Lab Invest* **25**:42.
- DUNN, J. S. 1967. The fine structure of the absorptive epithelial cells of the developing small intestine of the rat. *J. Anat* **101**:57.
- GRAHAM, R. C. JR., and M. J. KARNOVSKY. 1966 The early stages of absorption of injected horseradish peroxidase in the proximal tubules of the mouse kidney ultrastructural cytochemistry by a new technique. *J. Histochem. Cytochem.* **14**:291.
- GRANEY, D. O. 1968 The uptake of ferritin by ileal absorptive cells in suckling rats. An electron microscope study. *Am J Anat* **123**:227.
- HAMPTON, J. C., and B. ROSARIO. 1967 The passage of exogenous peroxidase from blood capillaries into the intestinal epithelium. *Anat Rec* **159**:159.
- HAYWARD, A. F. 1967. Changes in fine structure of developing intestinal epithelium associated with pinocytosis. *J. Anat* **102**:57.
- HUGON, J. S. 1971 Absorption of horseradish peroxidase by the mucosal cells of the duodenum of mouse II. The newborn mouse. *Histochemie* **26**:19.
- KARNOVSKY, M. J. 1965 A formaldehyde-glutaraldehyde fixative of high osmolality for use in electron microscopy. *J. Cell Biol.* **27**:137 A.
- KING, B. F., and A. C. ENDERS. 1970. Protein absorption and transport by the guinea pig visceral yolk sac placenta. *Am J. Anat.* **129**:261.
- KOREN, Z., and E. SHAFRIR. 1964 Placental transfer of free fatty acids in the pregnant rat. *Proc. Soc. Exp. Biol. Med.* **116**:411.
- KRAEHNBUHL, J. P., and M. A. CAMPICHE. 1969. Early stages of intestinal absorption of specific antibodies in the newborn. An ultrastructural, cytochemical, and immunological study in the pig, rat, and rabbit. *J. Cell Biol.* **42**:345.
- LEV, R., and D. ORLIC. 1972 Protein absorption by the intestine of the fetal rat *in utero*. *Science (Wash. D. C.)* **177**:522.
- RHODES, R. S., and M. J. KARNOVSKY. 1971 Loss of macromolecular barrier function associated with surgical trauma to the intestine. *Lab Invest* **25**:220.
- ROBERTSON, T. A., J. M. ARCHER, J. M. PAPADIMITRIOU, and M. N. I. WALTERS. 1971. Transport of horseradish peroxidase in the murine placenta. *J. Pathol.* **103**:141.
- RODEWALD, R. 1970 Selective antibody transport in the proximal small intestine of the neonatal rat. *J. Cell Biol.* **45**:635.

---

FIGURE 9 HRP-positive vacuoles located in the lateral cytoplasm between the nucleus (N) and cell membrane (arrowheads). Extrusion of vacuole-contained material is not evident here and the intercellular space is negative for peroxidase.  $\times 64,000$  Scale marker  $0.5 \mu\text{m}$ .

FIGURE 10 The vacuole seen here (arrowhead) has fused with the cell membrane. Exocytosis of vacuole-bound HRP may represent a mechanism by which intercellular channels (arrows) become filled with enzyme.  $\times 40,000$ . Scale marker  $0.5 \mu\text{m}$ .

FIGURE 11 The basal region of two adjacent absorptive cells. Reaction product in the space between these cells traverses the basement membrane (arrowheads) and diffuses between connective tissue cells (1, 2, 3, 4) of the lamina propria.  $\times 19,000$ . Scale marker  $0.5 \mu\text{m}$ .

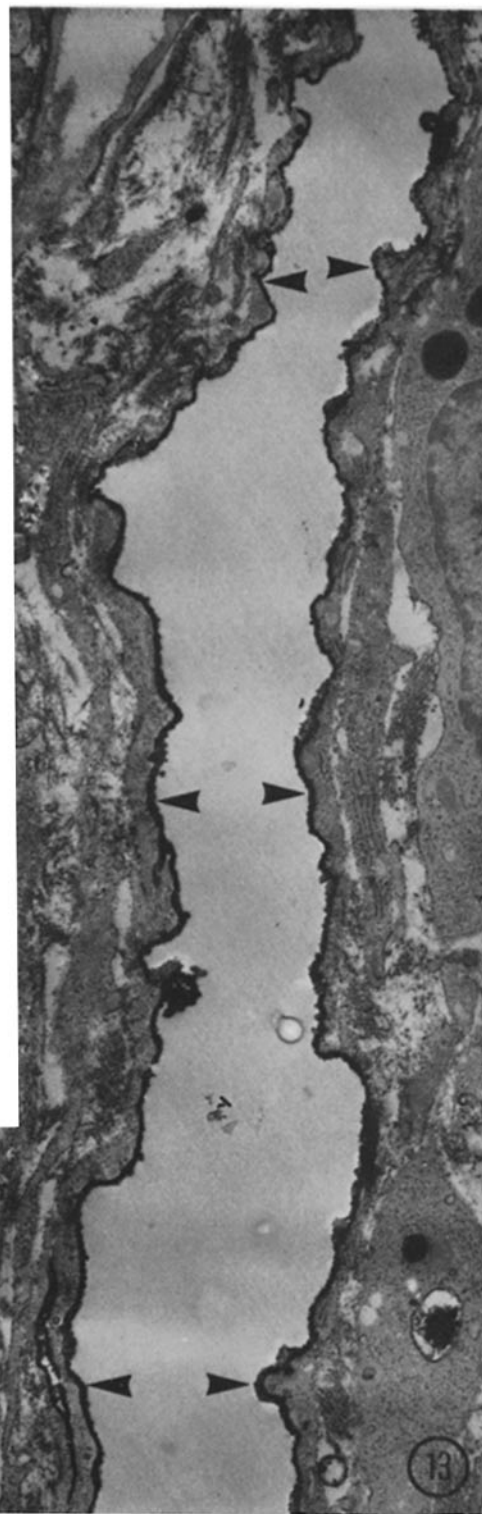
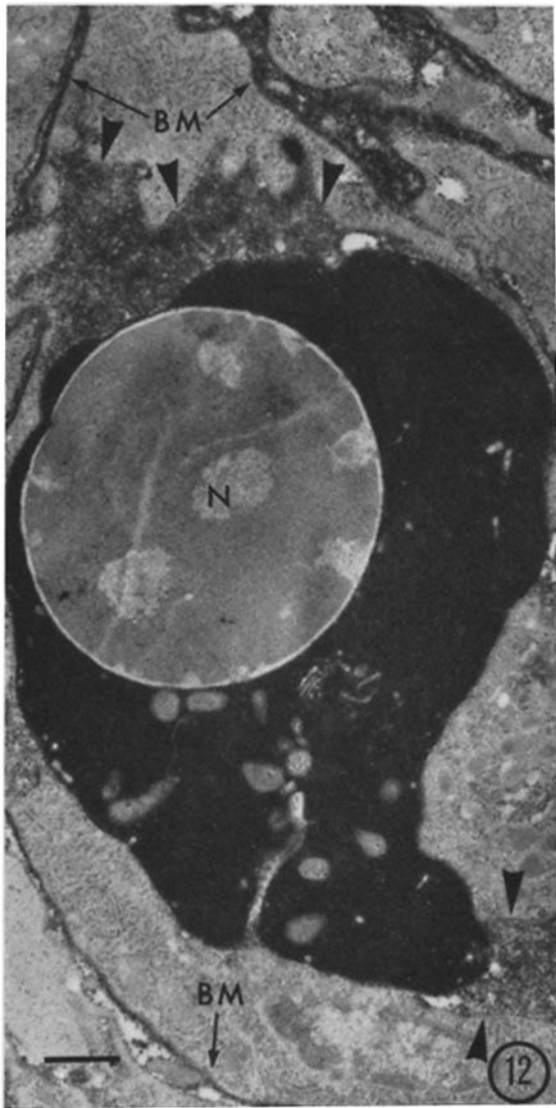

FIGURE 12 A capillary within the lamina propria. The lumen contains a circulating, nucleated red cell. Its nucleus (*N*) is devoid of reaction product, whereas its cytoplasm demonstrates endogenous peroxidatic activity. HRP is distributed throughout the remaining spaces of the capillary lumen (arrowheads) and is observed in the basement membrane (*BM*).  $\times 10,000$ . Scale marker  $1 \mu\text{m}$ .

FIGURE 13 Adjacent vascular and lymphatic microvessels. In the former a red cell is heavily stained, but no HRP is observed within the lumen or endothelium. However, the endothelial lining of the lymphatic is coated with HRP reaction product (arrowheads).  $\times 8600$ . Scale marker  $1 \mu\text{m}$ .

- SCHULTZ, R. L. 1970 Placental transport: a review. *Obstet. Gynec.* **25**(Survey):979.
- SEEDS, A. E. 1965 Water metabolism of the fetus. *Am. J. Obstet. Gynecol.* **92**:727.
- STRAUS, W. 1964 Factors affecting the state of injected horseradish peroxidase in animal tissue and procedures for the study of phagosomes and phagolysosomes. *J. Histochem. Cytochem.* **12**:470.
- SUGAWA, T., K. NAKAMURA, and M. OZAKI. 1963. Studies on the amino acid and protein metabolism in fetal growth. III Dynamics of free amino acids in the amniotic fluid and its nutritive role in the fetus. *J. Jap. Obstet. Gynecol.* **10**:1.
- WALKER, W. A., A. F. WARSHAW, R. CORNELL, and K. J. ISSELBACHER. 1971. Intestinal transport of macromolecules mechanism of absorption of horseradish peroxidase. *Gastroenterology* **60**:808 (Abstr.)
- WARSHAW, A. F., W. A. WALKER, R. CORNELL, and K. J. ISSELBACHER. 1971. Small intestine permeability to macromolecules. Transmission of horseradish peroxidase into mesenteric lymph and portal blood. *Lab. Invest.* **25**:675.
- WILLIAMS, R. J., and F. BECK. 1969. A histochemical study of gut maturation. *J. Anat.* **105**:487.
- WISSIG, S. F., and D. O. GRANLEY. 1968. Membrane modifications in the apical endocytic complex of ileal epithelial cells. *J. Cell Biol.* **39**:564.