

SHORT REPORT

Risk factors for early visual deterioration in temporal arteritis

Tobias Loddenkemper, Pankaj Sharma, I Katzan, Gordon T Plant

J Neurol Neurosurg Psychiatry 2007;**78**:1255–1259. doi: 10.1136/jnnp.2006.113787

Background: Despite corticosteroid treatment, patients with temporal arteritis may continue to lose vision. However, predictors of progressive visual loss are not known.

Methods: We retrospectively reviewed 341 consecutive patients with suspected temporal arteritis who underwent temporal artery biopsy. 90 patients with biopsy proven temporal arteritis were included in our study.

Results: Twenty-one patients (23%) experienced continuous visual symptoms despite steroid therapy and 14 among these suffered persistent visual deterioration. Based on univariate analysis, visual loss on presentation was associated with disc swelling and a history of hypertension. Risk factors for progressive visual loss included older age, elevated C reactive protein and disc swelling.

Conclusion: Although corticosteroid therapy improves the visual prognosis in temporal arteritis, steroids may not stop the progression of visual loss. Our study reliably establishes the risk factors for visual loss in this serious condition. Whether addressing these risk factors early in their presentation can alter the visual outcome remains unknown. Individual risk anticipating treatment regimens and strategies might improve the visual prognosis in temporal arteritis in the future.

Left untreated, temporal arteritis (TA) frequently results in blindness. Treatment requires immediate high dose steroids. Risk factors for initial and progressive visual loss, despite appropriate treatment, have not been extensively characterised, making selection of patients at risk for progressive visual loss difficult.

We retrospectively reviewed clinical findings in patients with biopsy proven TA in order to assess risk factors for visual loss during the first days of steroid therapy.

METHODS

A retrospective chart review of 341 patients with suspected TA undergoing temporal artery biopsy during 15 consecutive years at the National Hospital for Neurology and Neurosurgery, London, UK, was performed.

Biopsies were performed on the side of predominant symptoms. Biopsies were deemed positive for TA if the histological specimen demonstrated arteritis, characterised by mononuclear cell arterial wall infiltration and interruption of the internal lamina elastica. Additional evidence included media degeneration or intima thickening.¹ Visual acuity was expressed as a decimal (20/20 = 1.00; finger counting = 0.012; hand motion = 0.006; light perception = 0.001; no light perception = 0).² In order to compare steroids among patients, the doses in patients receiving a steroid other than hydrocortisone were converted according to the following dosing scheme: 1 mg dexamethasone = 30 mg hydrocortisone; 1 mg methylprednisolone = 5 mg hydrocortisone, 1 mg prednisone = 4 mg hydrocortisone.

SPSS10.0 was used for statistical analysis. A p value of <0.05 was considered statistically significant.

RESULTS

Ninety-three (27%) out of 341 biopsy results confirmed TA. Ninety patients (67 females; mean age 74.6 (SD 7.8); range 59–93) were included. The remaining three notes were lost.

Onset of symptoms prior to admission ranged from 2 days to 7 years (median 125 days). It took a median of 8 days (0–242 days) from referral until admission. Median duration of hospital stay was 11 days (0–53). Ninety-one per cent of biopsies were performed within 5 days of admission; 71% were biopsied within 5 days after starting steroids. Five patients underwent temporal artery biopsy prior to initiation of steroids. All 90 biopsies were suggestive of TA. Fifty-six (62%) biopsies showed giant cells.

Eighty-nine patients received corticosteroids. One patient presented 3 weeks after blindness had occurred and was not treated. Thirty-three patients initially received intravenous corticosteroid treatment (hydrocortisone, methylprednisolone or prednisolone). Fifty-six patients were initially treated with prednisone by mouth. Doses were converted to hydrocortisone strength for comparison. The average initial corticosteroid dose consisted of 495 mg of hydrocortisone (range 0–5000). The average time until first dose taper was 21 days. In 31 patients, initial corticosteroid dose was increased in order to control symptoms completely.

Twenty-one (23%) patients showed progressive visual symptoms despite corticosteroid therapy. A total of 20 patients suffered visual loss. Thirteen patients suffered persistent loss of acuity or field loss and one additional patient presented with a hemiparesis and diplopia (table 1). Deterioration occurred usually within the first days of treatment. Seven additional patients had transient visual impairment.

Of the seven patients with transient visual impairment despite corticosteroids, four patients had transient visual loss, one patient had an episode of left sided weakness and left visual loss, one patient complained about visual teichopsia and one patient developed disc swelling. All symptoms resolved after an increase in steroid dose.

The presence of disc swelling, history of hypertension and older age were significantly associated with visual loss on presentation. A trend of higher odds for initial visual loss was also seen in patients with polymyalgia, diabetes and jaw claudication (table 2). Patients with visual loss on presentation had a higher systolic blood pressure on presentation (table 3).

Risk factors for progressive visual loss included older age, elevated C reactive protein (CRP) and disc swelling (tables 4 and 5). Fourteen patients with early progressive visual loss despite corticosteroid therapy were, on average, 79.4 years old. Seventy-six patients without progressive visual loss were, on average, 73.7 years old and therefore significantly younger ($p < 0.05$, t test value 2.2). The CRP of patients with progressive visual loss was, on average, significantly higher (57.4; $n = 7$) than that of patients without visual loss (22.1; $n = 12$; $p < 0.02$, t test value –3.0). Other factors significantly ($p < 0.05$) associated with progressive visual loss were disc swelling (odds ratio (OR)

Abbreviations: ACR, American College of Rheumatology; CRP, C reactive protein; TA, temporal arteritis

Table 1 Fourteen patients with loss of visual acuity/fields despite corticosteroid therapy

Patient No	Sex	Age (years)	History of present illness	Visual acuities on admission		Therapy prior to deterioration	Outcome of visual acuities		Time after therapy started (days)	2 eyes involved
				OD	OS		OD	OS		
1	F	78	Visual loss OS since 2 days	0.25	0.033	60 mg PD po	0.012	0.006	5	Yes
2	F	79	Smearly vision OS since 4 days	0.66	0.5	200 mg HC iv, 40 mg PD po	0.66	0.006	1	No
3	F	88	Visual loss OS same day	0.333	0.006	100 mg HC iv, 60 mg PD po	0.333	0	1	No
4	F	82	Visual loss OS same day	0.1	0.001	200 mg HC iv, 60 mg PD po	0.1	0	2	No
5	F	88	Visual loss OU same day	0	0.166	8 mg DM iv, 80 mg PD po	0	0.001	1	Yes
6	F	82	Previous PMR 3 years ago, off steroids, OD blind 3 weeks ago, OS misty since 3 days	0.001	0.001	200 mg HC iv, 500 mg MP iv x 3 days; then 80 mg PD po	0	0	6	Yes
7	M	64	Sensory loss right forearm 3 weeks ago, double vision since 2 weeks, mild right hemiparesis since 1 day	0.666	0.666	80 mg PD po	0.333	0.666	2	No
						500 mg MP iv	0.25	0.666	5	
						120 mg PD po	0.166	0.666	8	
						80 mg PD po			12	Hemiparesis deteriorated
8	F	92	Loss of vision OD 14 days ago	0.001	0.666	60 mg PD po	0	0.666	1	No
9	F	75	Visual loss OD since 1 day	0.5	1.0	60 mg PD po	0.001	1.0	2	No
10	M	87	Visual loss OD 6 days ago	0.006	1.0	500 mg MP iv x 3 days; then 80 mg PD po	0.001	0.012	3	Yes
11	F	80	Visual loss OD 2 weeks ago, blurred vision OS since 4 days	0.001	0.666	80 mg PD po	0.012	0	9	
						500 mg MP iv x 3 days; then 80 mg PD po	0.012	0.001	1	Yes
12	F	75	OS blind 6 days ago, visual loss OD same day	0.05	0	80 mg PD po	0	0	10	Yes
						1000 mg MP iv x 3 days; then 80 mg PD po	0	0	3	Yes
13	F	59	Black spot OS since 2 days, visual loss OS same day	1.2	0.006	80 mg PD po	0.666;	0.012	2	Yes
						80 mg PD po	0.666;	0.012	27	scotoma enlarged scotoma
14	F	77	PMR since 3.5 years, visual loss OS 6 months ago, visual loss OD 2 weeks ago	0.016	0.166	1000 mg MP iv x 3 days; then 80 mg PD po	0.012	0.1	7	Yes

DM, Dexamethasone; HC, hydrocortisone; iv, intravenous; MP, methylprednisolone; OD, right eye; OS, left eye; OU, both eyes; PD, prednisolone; PMR, polymyalgia rheumatica; po, by mouth.

5.3 (95% CI 1.4 to 20.7)) and administration of steroids intravenously (OR 5.6 (95% CI 1.6 to 19.9)) (tables 4 and 5). Men had reduced odds of visual loss progression (OR 0.24 (95% CI 0.05 to 1.2)), approaching statistical significance ($p = 0.06$) (tables 4 and 5).

Median follow-up duration was 7 months (range 11 days to 16 years). Two year follow-up was available for 28 patients. Four patients without previous visual symptoms had visual loss (unilateral permanent visual loss in two and unilateral temporary visual loss in two). Visual loss occurred, on average, 24 months

Table 2 Risk factors for initial visual loss: dichotomous variable

Dichotomous variable	Sign present (%)	Symptoms/sign absent (%)	χ^2 p value	OR	CI
Disc swelling	97.6	47.9	0.000	44.56	5.66–350.7
Hypertension	81.8	60.9	0.028	2.89	1.10–7.62
Polymyalgia	84.2	67.6	0.156	2.56	0.68–9.66
Diabetes mellitus	75	70.9	0.86	1.23	0.12–12.39
Jaw claudication	72.3	69.8	0.788	1.13	0.46–2.82
Diplopia	70	71.4	0.901	0.93	0.31–2.77
Giant cells on biopsy	69.6	73.5	0.693	0.83	0.32–2.14
Cholesterol	100	78.6	0.605	0.79	0.6–1.03
Muscle tenderness	67.6	73.6	0.535	0.75	0.30–1.88
Male sex	66.7	73.7	0.479	0.714	0.281–1.82
Stroke	60	71.8	0.573	0.59	0.09–3.76
Systemic features	63.6	78.3	0.126	0.49	0.19–1.23
Temple tenderness	63.6	78.3	0.126	0.49	0.19–1.23
Smoker	60.5	78.8	0.058	0.41	0.16–1.04
Headache	67.5	92.3	0.068	0.17	0.02–1.41

Table 3 Risk factors for initial visual loss: continuous variables

Continuous variable	Mean value in patients with visual loss (n)	Mean value in patients without visual loss (n)	t test p value	OR	CI
Blood glucose (mg/dl)	160 (59)	144 (22)	0.272	1.22	1.02–1.46
Age (y)	76.6 (64)	69.5 (26)	0.000	1.15	1.07–1.24
Systolic BP (mm Hg)	156 (64)	145 (26)	0.056	1.02	1.0–1.04
ESR at referral (mm)	75 (54)	66 (18)	0.213	1.01	0.99–1.04
Onset (days)	140 (63)	88 (26)	0.51	1.0	0.998–1.00
Platelets at presentation	457 (50)	448 (17)	0.831	1.0	0.997–1.0
Corticosteroid dose (mg HC)	672 (64)	245 (26)	0.004	1	1.00–1.00
Time referral to admission (days)	9 (61)	6 (24)	0.289	1.00	0.98–1.02
ESR at presentation (mm/h)	70 (26)	68 (63)	0.779	0.996	0.98–1.01
Diastolic BP (mm Hg)	82 (64)	84 (26)	0.422	0.99	0.95–1.03
Duration of hospital stay	12 (64)	9 (26)	0.363	1.03	0.97–1.09

BP, blood pressure; ESR, erythrocyte sedimentation rate; HC, hydrocortisone.

after initial presentation. All four patients were on a tapering dose of oral prednisone at that time (on average 14 mg daily).

DISCUSSION

Continuous visual symptoms despite steroid therapy were seen in 23% of patients, and 16% suffered visual deterioration during therapy. Risk factors for visual loss on presentation were disc swelling and hypertension. Risk factors for

progressive visual loss included older age, elevated CRP and disc swelling.

Fifty-eight patients (3.1%) with visual loss after initiation of corticosteroid therapy were found among 1296 patients with TA in the literature (table 6) ranging from 0%³ to 38.9% in prospective series.⁴ In a meta-analysis of 39 retrospective^{4–24} and prospective studies (table 6), we found a highly significant correlation (Pearson's correlation coefficient 0.604; $p < 0.0001$) between the

Table 4 Odds ratios for progressive visual loss: dichotomous symptoms

Symptom (dichotomous)	Symptom in patients with progressive visual loss (%)	Symptom in patients without progressive visual loss (%)	χ^2 p value	OR	95% CI
IV steroids	30.3	7.1	0.004	5.65	1.6–19.91
Disc swelling	26.2	6.3	0.009	5.32	1.37–20.66
Stroke	40	14.1	0.121	4.06	0.61–26.86
Headache	16.9	7.7	0.398	2.44	0.29–20.42
Scalp tenderness	20.5	10.9	0.21	2.11	0.65–6.81
Diabetes mellitus	25	15.1	0.498*	1.87	0.18–19.41
Systemic symptoms	18.2	13.0	0.501	1.48	0.47–4.68
Hypertension	18.2	13	0.501	1.48	0.47–4.68
Muscle tenderness	16.2	15.1	0.885	1.09	0.34–3.45
Polymyalgia	15.8	15.5	0.609*	1.02	0.25–4.11
Cholesterol by history	0	14.3	0.867*	0.86	0.69–1.06
Giant cells on biopsy	14.3	17.6	0.67	0.78	0.24–2.47
Jaw claudication	12.8	18.6	0.445	0.64	0.2–2.02
Diplopia	10	17.1	0.35*	0.537	0.11–2.63
Smoker	7.9	21.2	0.086	0.32	0.08–1.24
Male sex	6.1	21.1	0.059	0.242	0.051–1.16

*Fisher's exact test.

Table 5 Odds ratios for progressive visual loss: continuous symptoms

Symptom (continuous)	Mean value in patients with progressive visual loss (n)	Mean value in patients without progressive visual loss (n)	t test p value	OR	95% CI
CRP on presentation	57.43 (7)	22.17 (12)	0.016		
Age (y)	79.41 (14)	73.7 (76)	0.042	1.1147	1.0208–1.2171
Glucose (mg/dl)	155.8 (14)	154.5 (67)	0.297	1.0699	0.9009–1.2707
Diastolic BP (mm Hg)	86.79 (14)	82.25 (76)	0.066	1.0371	0.9839–1.0932
Systolic BP (mm Hg)	159.64 (14)	152.15 (76)	0.305	1.0118	0.9894–1.0347
ESR at referral (mm/h)	77.92 (13)	71.90 (59)	0.466	1.01	0.99–1.03
Time referral to admission (days)	18.29 (14)	6.18 (71)	0.497	1.0093	0.9941–1.0247
ESR at presentation (mm/h)	70.79 (14)	67.70 (76)	0.671	1.0044	0.9830–1.0263
Platelets at presentation	463.36 (11)	453.79 (56)	0.854	1.0004	0.9962–1.0047
Steroid dose (mg HC)	780 (14)	479.21 (76)	0.437	1.0002	0.9998–1.0007
Onset of symptoms (days)	109.36 (14)	128.35 (75)	0.681	0.9997	0.9975–1.0020
Length of hospital stay	21.57 (14)	9.13 (76)	0.005	1.1044	1.0403–1.1725

BP, blood pressure; CRP, C reactive protein; ESR, erythrocyte sedimentation rate; HC, hydrocortisone.

*Fisher's exact test.

Table 6 Visual loss during corticosteroid therapy (prospective studies)

Author	Year	Study design (cases)	n	Positive biopsy	Patients with visual loss (%)	Patients with ocular deterioration during therapy (%)
Birkhead ³³	1957	Prospective	55	55 (100%)	21 (38%)	2 (3.6%)
Palm ³⁴	1958	Prospective	31	13 (21%)	31 (100%)	4 (12.9%)
Parsons-Smith ³⁵	1958	Prospective	50 (13 treated)	NR	13/55; all 13 treated (24%)	1 (7.7%)
Russell ³⁶	1959	Retrospective (8)	35 (21 treated)	11 (31%)	16/35 with visual symptoms (46%)	6 (28.6%)
Mosher ⁴	1959	Prospective (27) Retrospective	32 (18 treated)	23 (72%)	20 with eye symptoms (62.5%)	7 (38.9%)
Whitfield ³⁷	1963	Prospective	72	NR	40 (55%)	1 (1.4%)
Cullen ³⁸	1967	Prospective	25	25 (100%)	25 (100%)	1 (4%)
Fauchald ³⁹	1972	Prospective	94	61 (65%)	5 ocular symptoms (5%)	1 (1.1%)
Hunder ⁴⁰	1975	Prospective	60	60 (100%)	3 (5%)	0 (0%)
Bengtsson ⁴¹	1981	Prospective	27	17 (63%)	NR	2 (7.4%)
Jones ⁴²	1981	Prospective	85	22 (26%)	6/22 (27%) permanent	1 (1.2%)
Behn ³	1983	Prospective	68	25 (37%)	10 (15%)	0 (0%)
Boesen ⁴³	1987	Prospective	21	11 (52%)	NR	0 (0%)
Caselli ⁴⁴	1988	Prospective	166	166 (100%)	14 permanent (8.4%) 17 transient 8 scotoma	1 (0.6%)
Kyle ⁴⁵	1989	Prospective	35	NR	NR	1 (2.9%)
Myles ⁴⁶	1992	Prospective	96 TA 210 PMR	48/78 (61.5%) NR	NR	4/96 (4%) 3/210 PMR (1.4%)
Aiello ⁴⁷	1993	Prospective	245	204 (83%)	34 (14%)	5 (1.6%)
Duhaur ⁴⁸	1999	Prospective	292	207 (71%)	31 (55%)	14 (6.8%)
Kupersmith ⁴⁹	1999	Prospective	22	19 (86%)	7 (32%)	2 (9%)
Chevalier ⁵⁰	2000	Prospective	164	128 (78%)	NR	1 amaurosis (0.6%)
Kupersmith ²	2001	Prospective	20	20 (100%)	4 (20%)	0 (0%)
Liozon ²⁹	2001	Prospective	174	147 (85%)	48 (28%) visual symptoms; 23 (13%) permanent	4 (2.3%)
Danesh-Meyer ²⁵	2005	Prospective	34	34 (100%)	34 (100%)	(27% of eyes during the first 6 days)
SUM			1838	1296 (70.5%)	362 (19.7%)	58 (3.1%)

GC, Giant cells; NR, not reported; PMR, polymyalgia rheumatica; TA, temporal arteritis.

percentage of patients with visual loss on presentation and visual loss under corticosteroid therapy (fig 1). Visual loss on presentation may therefore predict visual deterioration under corticosteroid therapy, as also seen in our patients.

Visual deterioration occurs in two peaks. The first peak manifests as progression of the ongoing flare on an unchanged steroid dose, typically during the first 6 days.²⁵ The second peak occurs after weeks or months of tapering treatment. Relapses increase with reduction of corticosteroid therapy and were seen in 19% of patients within 1 year.²⁶

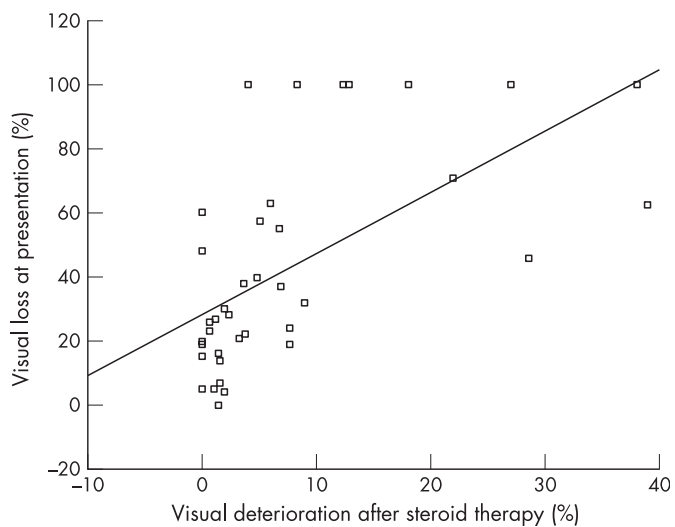


Figure 1 Visual deterioration in relationship to visual loss on presentation, in per cent, based on retrospective and prospective series with complete data from the literature.

Reasons for progression of visual loss despite treatment may include hypoperfusion of the optic disc, treatment delay, inadequate steroid dose, quick taper or hypercoagulability with retinal artery infarction, possibly due to steroid therapy. Continuation of arteritis despite adequate corticosteroid dose may be considered part of the spectrum of TA or may even be a separate disease entity.

Differential diagnoses mimicking TA include systemic lupus erythematosus, Sjögren's syndrome, rheumatoid arthritis, Behcet's disease, antiphospholipid antibody syndrome, polyarteritis nodosa, Churg–Strauss syndrome, Wegener's granulomatosis and other rheumatic conditions presenting with granulomatous vasculitis such as Takayasu arteritis.²⁷ Sarcoid, primary angiitis of the central nervous system, non-arteritic AION, neoplastic conditions as well as viral infections (varicella zoster, human parvo virus B19, human herpes virus 6, herpes simplex) and nocardiosis should also be considered.

Risk factors for initial visual loss include transient visual ischaemic symptoms, increased platelet count, jaw claudication and HLA-DRB1 phenotype.^{20–28} Constitutional symptoms and elevated liver enzymes are associated with a lower risk of visual loss.^{28–29} Risk factors for permanent visual loss include amaurosis fugax and cerebrovascular accidents.²⁰

Risk factors for progressive visual loss may include occlusive strokes, possibly due to steroid therapy itself.³⁰ Late recurrence of visual loss was associated with female sex, older age, worse initial visual acuity, oral (as compared to intravenous) initial steroid treatment and higher erythrocyte sedimentation rate.²⁴ HLA DRB1 alleles were also associated with progressive symptoms.³¹

Intravenous or high dose oral corticosteroids remain the standard of care for patients at risk for visual loss.²⁵ A retrospective review of 166 patients demonstrated better outcome in patients on low dose aspirin at the time of symptom

onset.³² Aspirin may therefore decrease the rate of visual loss and strokes in patients with TA. Further research is on the way to determine effectiveness. Some authors also use heparin, in particular in patients with progressive visual loss.²⁵ Additional steroid sparing agents during the long term treatment period have been tried but no positive randomised placebo controlled prospective trials are available.

Limitations of our study include the retrospective design and referral bias at a tertiary treatment centre. Our literature review attempted to compensate for these variations by comparing our data with previous studies in different settings.

The 1990 American College of Rheumatology (ACR) Criteria for the Classification of Giant Cell (Temporal) Arteritis¹ were not applied to all 341 patients seen in our clinic because of the retrospective study design. We limited our study population to the gold standard of diagnosis prior to establishment of these criteria, a positive temporal artery biopsy. Nevertheless, all included patients met the 1990 ACR criteria. By making the positive biopsy a prerequisite, we likely applied more sensitive inclusion criteria. Stricter inclusion criteria may also have led to a selection bias towards more active cases. Our data are therefore valid for patients over 50 years old and in whom the biopsy is positive and at least one additional diagnostic ACR criterion is present. A prospective study on progressive visual loss according to ACR standards is needed.

CONCLUSION

Progression of visual loss despite steroid therapy occurs in a significant minority of patients with TA. In most patients, deterioration occurs within the first 3 days after initiation of steroid therapy. Individual risk anticipating treatment strategies might improve visual prognosis in TA.

Authors' affiliations

Tobias Lodenkemper, National Hospital for Neurology and Neurosurgery, London, UK

Gordon T Plant, University Department of Clinical Neurology, Institute of Neurology, London, UK

I Katzan, Department of Neurology, The Cleveland Clinic Foundation, Cleveland, OH, USA

Pankaj Sharma, Department of Clinical Neuroscience, Hammersmith Hospitals and Imperial College, London UK

Competing interests: None.

Correspondence to: Dr Tobias Lodenkemper, Department of Neurology, S51, The Cleveland Clinic Foundation, 9500 Euclid Ave, Cleveland, OH 44195, USA; lodent@ccf.org

Received 20 December 2006

Revised 7 April 2007

Accepted 12 April 2007

Published Online First 15 May 2007

REFERENCES

- Hunder GG, Bloch DA, Michel BA, et al. The American College of Rheumatology 1990 criteria for the classification of giant cell arteritis. *Arthritis Rheum* 1990;**33**:1122-8.
- Kupersmith MJ, Speira R, Langer R, et al. Visual function and quality of life among patients with giant cell (temporal) arteritis. *J Neuroophthalmol* 2001;**21**:266-73.
- Behn AR, Perera T, Myles AB. Polymyalgia rheumatica and corticosteroids: how much for how long? *Ann Rheum Dis* 1983;**42**:374-8.
- Mosher HA. Prognosis in temporal arteritis. *Arch Ophthalmol* 1959;**62**:641-4.
- Meadows SP. Temporal arteritis and loss of vision. *Trans Ophthalm Soc UK* 1954;**74**:13-24.
- Meadows SP. Temporal or giant cell arteritis. *Proc R Soc Med* 1966;**59**:329-33.
- Healey LA, Wilske KR. Manifestations of giant cell arteritis. *Med Clin North Am* 1977;**60**:261-71.
- Sorensen PS, Lorenzen I. Giant-cell arteritis, temporal arteritis and polymyalgia rheumatica. *Acta Med Scand* 1977;**201**:207-13.
- Huston KA, Hunder GG, Lie JT, et al. Temporal arteritis. A 25-year epidemiologic, clinical and pathologic study. *Ann Int Med* 1978;**88**:162-7.
- Calamia RJ, Hunder GG. Clinical manifestations of giant cell (temporal) arteritis. *Clin Rheum Dis* 1980;**6**:403.

- Fernandez-Herlihy L. Duration of corticosteroid therapy in giant cell arteritis. *J Rheumatol* 1980;**7**:361-4.
- Graham E, Holland A, Avery A, et al. Prognosis in giant-cell arteritis. *Br Med J* 1981;**282**:269-71.
- Bengtsson BA. Eye complications in giant cell arteritis. *Acta Med Scand* 1982;**656**:S38-43.
- Delecoeuillierie G, Joly P, Cohen de Lara A, et al. Polymyalgia rheumatica and temporal arteritis: a retrospective analysis of prognostic features and different corticosteroid regimens (11 year survey of 210 patients). *Ann Rheum Dis* 1988;**47**:733-9.
- Chmielewski WL, McKnight KM, Agudelo CA, et al. Presenting features and outcomes in patients undergoing temporal artery biopsy. *Arch Intern Med* 1992;**152**:1690-5.
- Liu GT, Glaser JS, Schatz NJ, et al. Visual morbidity in giant cell arteritis. *Ophthalmology* 1994;**101**:1779-85.
- Meli B, Landau K, Gloor BP. The bane of giant cell arteritis from an ophthalmological viewpoint. *Schweiz Med Wochenschr* 1996;**126**:1821-8.
- Font C, Cid MC, Coll-Vincent B, et al. Clinical features in patients with permanent loss due to biopsy-proven giant cell arteritis. *Br J Rheumatol* 1997;**36**:251-4.
- Bahlas S, Ramus-Remus C, Davis C. Clinical outcome of 149 patients with polymyalgia rheumatica and giant cell arteritis. *J Rheumatol* 1998;**25**:99-104.
- Gonzalez-Gay MA, Garcia-Porrúa C, Llorca J, et al. Visual manifestations of giant cell arteritis. Trends and clinical spectrum in 161 patients. *Medicine (Baltimore)* 2000;**79**:283-92.
- Wenkel H. Bilateral amaurosis in 11 patients with giant cell arteritis confirmed by arterial biopsy. *Klin Monatsbl Augenheilkd* 2001;**218**:658-61.
- Chan CC, Paine M, O'Day J. Steroid management in giant cell arteritis. *Br J Ophthalmol* 2001;**85**:1061-4.
- Hayreh SS, Zimmerman B. Management of giant cell arteritis. Our 27-year clinical study: new light on old controversies. *Ophthalmologica* 2003;**217**:239-59.
- Chan CC, Paine M, O'Day J. Predictors of recurrent ischemic optic neuropathy in giant cell arteritis. *J Neuroophthalmol* 2005;**25**:14-17.
- Danesh-Meyer H, Savino PJ, Gamble GG. Poor prognosis of visual outcome after visual loss from giant cell arteritis. *Ophthalmology* 2005;**112**:1098-103.
- Hoffman GS, Cid MC, Hellmann DB, et al. A multicenter, randomized, double-blind, placebo-controlled trial of adjuvant methotrexate treatment for giant cell arteritis. *Arthritis Rheum* 2002;**46**:1309-18.
- Wilke WS. Large vessel vasculitis (giant cell arteritis, Takayasu arteritis). *Baillieres Clin Rheumatol* 1997;**11**:285-313.
- Gonzalez-Gay MA, Blanco R, Rodriguez-Valverde V, et al. Permanent visual loss and cerebrovascular accidents in giant cell arteritis: predictors and response to treatment. *Arthritis Rheum* 1998;**41**:1497-504.
- Liozon E, Herrmann F, Ly K, et al. Risk factors for visual loss in giant cell (temporal) arteritis: a prospective study of 174 patients. *Am J Med* 2001;**111**:211-17.
- Staunton H, Stafford F, Leader M, et al. Deterioration of giant cell arteritis with corticosteroid therapy. *Arch Neurol* 2000;**57**:581-4.
- Rauzy O, Fort M, Nourashemi F, et al. Relation between HLA DRB1 alleles and corticosteroid resistance in giant cell arteritis. *Ann Rheum Dis* 1998;**57**:380-2.
- Nesher G, Berkun Y, Mates M, et al. Low-dose aspirin and prevention of cranial ischemic complications in giant cell arteritis. *Arthritis Rheum* 2004;**50**:1332-7.
- Birkhead NC, Wagener HP, Shick RM. Treatment of temporal arteritis syndrome with adrenal corticosteroids. *JAMA* 1957;**163**:821-7.
- Palm E. The ocular crisis of the temporal arteritis syndrome (Horton). *Acta Ophthalmol* 1958;**36**:208-43.
- Parson-Smith G. Sudden blindness in cranial arteritis. *Br J Ophthalmol* 1959;**43**:204-16.
- Russell RWR. Giant cell arteritis. A review of 35 cases. *Q J Med* 1959;**112**:471-89.
- Whitfield AGW, Bateman M, Cooke WT. Temporal arteritis. *Br J Ophthalmol* 1963;**47**:555-66.
- Cullen JF. Ischaemic optic neuropathy. *Trans Ophthalm Soc UK* 1967;**87**:759-74.
- Fauchald P, Rygvold O, Oystese B. Temporal arteritis and polymyalgia rheumatica. *Ann Intern Med* 1972;**77**:845-52.
- Hunder GG, Sheps SG, Allen LA, et al. Daily and alternate-day corticosteroid regimens in treatment of giant cell arteritis. *Ann Intern Med* 1975;**82**:613-18.
- Bengtsson BA, Malmvall BE. The epidemiology of giant cell arteritis including temporal arteritis and polymyalgia rheumatica. Incidences of different clinical presentations and eye complications. *Arthritis Rheum* 1981;**24**:899-904.
- Jones JG, Hazleman BL. Prognosis and management of polymyalgia rheumatica. *Ann Rheum Dis* 1981;**40**:1-5.
- Boesen P, Sorensen SF. Giant cell arteritis, temporal arteritis, and polymyalgia rheumatica in a Danish county. *Arthritis Rheum* 1987;**30**:295-9.
- Caselli RJ, Hunder GG, Whisnant JP. Neurologic disease in biopsy-proven giant cell (temporal) arteritis. *Neurology* 1988;**38**:352-9.
- Kyle V, Hazleman BL. Treatment of polymyalgia and giant cell arteritis. I. Steroid regimens for the first two months. *Ann Rheum Dis* 1989;**48**:658-61.
- Myles AB, Perera T, Ridley MG. Treatment of blindness in giant cell arteritis by corticosteroid treatment. *Br J Rheumatol* 1992;**31**:103-5.
- Aiello PD, Trautmann JC, McPhee JT, et al. Visual prognosis in giant cell arteritis. *Ophthalmology* 1993;**100**:550-5.
- Duhaut P, Pinede L, Bornet H, et al. Biopsy proven and biopsy negative temporal arteritis: differences in clinical spectrum at the onset of the disease. Groupe de Recherche sur l'Arterite a Cellules Geantes. *Ann Rheum Dis* 1999;**58**:335-41.
- Kupersmith MJ, Langer R, Mitnick H, et al. Visual performance in giant cell arteritis (temporal arteritis) after 1 year of therapy. *Br J Ophthalmol* 1999;**83**:796-801.
- Chevalot P, Barrier JH, Pottier P, et al. A randomized, multicenter controlled trial using intravenous pulses of methylprednisolone in the initial treatment of simple forms of giant cell arteritis: a one year followup study of 164 patients. *J Rheumatol* 2000;**27**:1484-91.