

ON HÆMORRHAGIC CYSTS OF THE THYROID GLAND.

By W. I. BRADLEY, B. A., M. D., M. R. C. S.

*(From the Pathological Laboratory of the Royal Victoria Hospital, and the
Molson Pathological Laboratory, McGill University, Montreal.)*

PLATE XV.

It is generally taught that the most frequent form of enlargement of the thyroid gland is the parenchymatous goitre, or bronchocele, a form in which, by the overproduction or retention of colloid material within the vesicles in general, there is brought about a very considerable increase in the size of one lobe or in that of the whole organ. There is, however, another form of cystic enlargement, not generalized, but localized, in which the enlargement is due not to multiple retention cysts, but to the development of large isolated, cystic swellings, either solitary or not exceeding three or four in number. The size of these cysts greatly exceeds that of the individual distended follicles in the most extreme cases of parenchymatous goitre, and the walls as well as the contents are of a wholly different nature.

Judging from the material which I have had the opportunity of studying, this in Canada constitutes quite the most frequent form of unilateral and considerable enlargement of the thyroid presenting itself for operation. Out of eighteen cases of bronchocele operated upon by Dr. Shepherd at the General Hospital in Montreal, the material from eight of which came into my hands, no less than nine, if not ten, were of this nature,* a proportion much larger than I had been prepared to encounter. A study of the literature bearing upon the morbid histology of the gland has convinced me that, relatively, very little attention has been paid to the nature and characters of these

* Of these eighteen, one was a case of generalised parenchymatous goitre, four were definitely "colloid cysts" (adenomatous nodules with retention), nine were definitely of the type here described, the remaining four being of doubtful nature.

large cysts; and, though it may be true that elsewhere they do not form so large a percentage of the cases of goitre operated upon as they do here in Dr. Shepherd's practice, nevertheless since surgical literature shows that they are very common, and now that operative interference with the thyroid is becoming increasingly frequent and increasingly successful, it may be opportune to draw more attention to their structure and characters than has hitherto been accorded to them.

Dr. Shepherd has described the surgical features of his cases in detail in the *Annals of Surgery*.* It will, therefore, be only necessary to append here a table of the cases, giving a brief epitome of the main points in connection with each.

Case.	Name.	Age.	Size, position, and contents of tumour.	Duration.
I.	Mrs. S.	56	Two cysts in the right lobe—one the size of a Tangierine orange, the other that of a walnut. <i>Contents</i> : a thick, reddish-brown material.	Ten years ago, when crossing the Atlantic, she was violently seasick. Lump on right side of neck was noticed shortly afterward. This continued to grow steadily, and had increased in size considerably during the last thirteen months.
II.	Mrs. G.	25	Two cysts in right lobe, the larger more superficial. <i>Contents</i> : a thick, greenish-brown fluid.	Noticed for six years. Growth at first small, slowly increased until a year before operation; then grew rapidly, the position becoming somewhat altered.
III.	Miss L.	23	Solitary cyst the size of a lemon in the right lobe. <i>Contents</i> : grumous, containing cholesterine crystals; extensive papillomatous projections into cyst.	Present for three years; very slow enlargement until a year before operation, when there was a sudden increase in size.
IV.	Miss C.	21	Solitary cyst the size of a hen's egg in the left lobe. <i>Contents</i> : dark, yellowish-brown fluid with clots of blood.	Gradual enlargement noticed for a year; then sudden increase in size three months before operation.
V.	Mrs. J.	30	Solitary cyst the size of a small orange in the left lobe. <i>Contents</i> : straw-coloured fluid.	Noticed for twelve years.
VI.	Miss McL.†	19	Single enormous cyst the size of a turnip in the left lobe. <i>Contents</i> : dark brown, thickish fluid.	Present for six years; more rapid enlargement a few months before operation.
VII.	Miss McP.†	19	Large solitary cyst the size of a grape-fruit in the right lobe, extending beneath the sternum. <i>Contents</i> : dark-yellow fluid.	Two years; had enlarged rapidly during the six months preceding operation.

* F. J. Shepherd, *Annals of Surgery*, September, 1895.

† Cases VI and VII were operated upon shortly after Dr. Shepherd's article in the *Annals of Surgery* had gone to press, and consequently are not referred to in that article.

Before speaking generally upon the subject of these cysts, it will be advisable to record briefly the results of the microscopical examination in each case:

CASE I.—In this there were two cysts in the right lobe, whose contents were reported by Dr. Shepherd to be of the nature of a reddish-brown fluid. The cyst wall did not come into my possession, the material supplied to me being an ingrowth into the cyst. It presented the characters of somewhat modified glandular tissue; the average diameter of the vesicles appeared to be 15 μ , the largest measuring 60 μ .

Owing to the great variation in the size of the follicles, it is only possible to give a rough approximate statement of the average size of the vesicles. Although these figures have been reached by estimating the diameters of fifty or more neighbouring follicles, it is not pretended that they represent more than a general approximation to the average size.

The majority of the collections of gland cells had no lumen, and were simply clumps of nucleated cells. Some of the vesicles contained a dense colloid material, deeply stained as though by blood pigment, and here and there the colloid masses showed a definite concentric appearance. In some, in the middle of the colloid, it was possible to recognise one or more clear transparent crystals, varying in shape from a square to an oblong, and in longitudinal diameter from 10 μ to 55 μ (Plate XV, Fig. 1). As to the exact nature of these crystals, I am not in a position to make any statement; they were unaffected by all the ordinary media employed in hardening and fixation, such as alcohol, Müller's fluid, and the essential oils. It must be added that the crystals were only present where there was surrounding interstitial hæmorrhage, with a degenerated condition of the epithelium.

Corresponding with the irregularity in the size and contents of the vesicles, their epithelium showed great variation in depth. There was periarteritis and also extravascular (interstitial) hæmorrhages; the capillaries were dilated, and the vesicles widely separated. This presence of dilated capillaries and of hæmorrhages is worthy of note in connection with the reddish-brown character of the fluid contained in the cyst.

The above case is unsatisfactory to this extent, that the relationship of this intracystic growth to the cyst wall could not be made out,

and because the absence of the cyst wall prevented a fuller study of the case. In the remaining cases the material sent fortunately included the cyst walls, and thus gave a far more satisfactory insight into the nature of the cysts themselves.

CASE II.—(Two cysts of the right lobe, the second removed through the posterior wall of the cavity left by removal of the first.)

The cyst wall in this case consisted of several irregular overlapping and not perfectly concentric layers of dense fibrous tissue, with interspersed occasional short imperfect layers, characterized by the presence of numerous small nuclei. Some of the outermost of these imperfect nucleated layers appeared to merge into more perfect gland tissue; they represented evidently the remains of atrophied lobules or collections of vesicles. Upon the inner surface of the cyst, section showed here and there accumulations of well-developed vesicles 50 μ to 200 μ in diameter, possessing a somewhat flattened epithelium; here and there several vesicles appeared to have run together into a common chamber.

There were, in addition, small areas of fibrosis and of calcareous deposits. The fluid filling the main cyst contained cholesterine crystals and large, round cells filled with fatty globules. The fluid had a glairy, yellowish-brown appearance.

CASE III.—(Single cyst of right lobe.)

As in the case last mentioned, the cyst wall was formed of several layers of fibrous tissue, with intermediate partial layers of atrophied gland tissue. From the wall there projected inward large, firm masses of gland tissue, with vesicles varying in diameter between 50 μ and 400 μ , having a thin, low epithelium and very little tissue between the individual vesicles. The fluid contents of the cyst were grumous, and contained cholesterine crystals.

CASE IV.—(Single cyst of left lobe, the size of a hen's egg.)

The cyst wall possessed the same features as those in the last two cases, except that it was not quite so dense, and that here and there in it could be observed flattened masses of colloid. Greatly elongated vesicles could also be seen gradually losing their epithelium, and passing into what might possibly be lymph channels (vide Plate XV, Fig. 4). Both on the outer and on the inner side of the cyst wall there was typical gland tissue, the diameter of the vesicles varying between 40 μ and 125 μ . In these masses of gland tissue protruding into the lumen of the

cyst were unmistakable signs of old hæmorrhages (deposits of pigment and cells containing pigment granules). The contents of this cyst were reported by Dr. Shepherd to consist of a yellowish-brown fluid, with blood clots.

CASE V.—(Single cyst of left lobe, the size of a small orange.)

The wall of the cyst in this was much thicker than in the preceding case, and was almost entirely fibrous, though there were evidences of contained atrophied gland tissue. Externally, the gland tissue showed a chronic interstitial thyroiditis, and in places merged imperceptibly into the cyst wall. In addition, the capsule exhibited patches of calcareous degeneration; in the middle of one such patch the remains of an artery showing obliterating endarteritis could be distinguished. The papilloma-like ingrowths into the cyst showed dilated vesicles filled with a clear homogeneous colloid material; the vesicular epithelium was greatly flattened, and exhibited areas of atrophy with communication between the vesicles. There were the remains of old hæmorrhages with pigment deposits, and more recent hæmorrhages causing rupture of the vesicular epithelium, so that the blood was both intravesicular and extravascular. The contents of the cyst were reported by Dr. Shepherd to consist of a straw-coloured fluid.

CASE VI.—(Single enormous cyst of the left lobe of the size of a turnip.)

The wall of this cyst, which had of late grown rapidly, was comparatively thin, and in its immediate neighbourhood was found normal thyroid tissue, the vesicles averaging about 25μ in diameter. All around the inner aspect of the wall was similar tissue in fair quantities forming an inner lining, and showing here and there a hæmorrhagic focus. At one place a large papillomatous mass projecting inward showed thyroid tissue of a similar nature, with, however, much fibrous tissue and great compression of the vesicles. According to Dr. Shepherd's report, the contents consisted of a dark-brown, thickish fluid, and from the posterior wall there projected several papilloma-like patches the size of walnuts.

CASE VII.—(Large soft cyst of right lobe, extending beneath the sternum over the vessels arising from the arch of the aorta; the cyst in consequence could not be shelled out in its entirety.)

The wall of the cyst was very similar to that of the preceding case. From the inner aspect there was thyroid tissue projecting, with vesi-

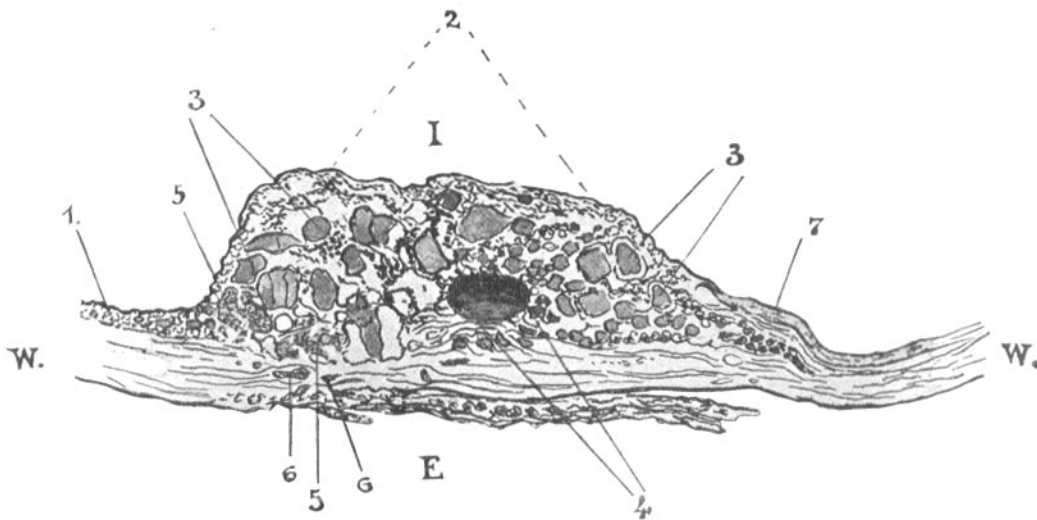
cles generally large, varying from 40 μ to 250 μ , the average diameter being calculated to be about 75 μ . Here the interstitial fibrous tissue was much increased, the colloid in the follicles was shrunken, and there were marked evidences of multiple hæmorrhages, both intravesicular and extravescicular. The contents of the cyst were reported by Dr. Shepherd to consist of a dark-yellow fluid. One large mass of gland tissue projected from the posterior or internal wall.

CASE VIII.—The eighth specimen received from Dr. Shepherd was of a different nature. While at the operation the case appeared to be one of multiple large cysts with colloid contents affecting both lobes, upon microscopic examination of the dense colloid material enucleated, it was found that this was made up of thyroid tissue, with vesicles ranging from 25 μ up to 630 μ in diameter, the average being about 50 μ . The vesicular epithelium was greatly flattened, and consisted of little more than small rounded nuclei. Thus the case was one of multiple nodular or lobular overgrowths, or, more correctly, aberrant growths of the gland tissue. I have since received a similar specimen removed by Dr. J. Bell from a patient in this hospital.

Taking into consideration all of the various features presented by these large fluid cysts, it will be seen that the contents differ markedly from those of the ordinary vesicles of the thyroid gland. They are fluid, and in general present evidences of containing blood or derivatives from the blood; they vary from a straw-coloured fluid (as in Case V), through greenish brown (Case I), to a dark-brown, grumous fluid (as in Case VI); or, again (as in Case IV), actual blood clots may be present. It is of importance to note that when, as in Case VI, the growth immediately before the operation had been rapid and the cyst wall was thin, there was found the most abundant evidence of recent effusion of blood; when, on the other hand, as in Case V, the wall was thick and, judging from the calcareous deposits within it, the cyst was of long standing and quiescent, the contents showed least evidence of admixture with blood, consisting simply of a thin straw-coloured fluid.

With regard to the nature of the cyst wall, this is of a somewhat peculiar character. Although very definitely fibrous in composition, its nature is not sharply defined. The layers composing it are not

truly concentric; here and there between them occur masses of small cells, which, by comparison with the tissue immediately outside the wall, are seen to be clearly the atrophied remains of gland tissue (vide Plate XV, Fig. 4). These features explain why it is that in enucleation the cysts are found not to be sharply defined from their surroundings, and permit successive irregular layers to be partially peeled off. The wall, in fact, passes gradually into the bands of interstitial tissue running between the surrounding collections of vesicles, and



Portion of the capsule of the thyroid cyst removed from Case V. $\times 10$.

E, external aspect; I, internal aspect; W, W, cyst wall of varying thickness. 1, Fine layer of thyroid tissue covering inner wall of cyst; 2, 2, mass of thyroid tissue projecting into lumen of cyst; 3, 3, large and healthy thyroid vesicles; 4, dense fibroid mass (atheromatous) with some calcification; 5, 5, small areas of hæmorrhage with pigmentation; 6, atrophied glandular tissue included between the layers of the cyst wall; 7, fibrous band or layer passing from the cyst wall to partially cover the projecting mass of thyroid tissue.

evidently represents not so much a new formation of fibrous tissue around the cyst as a compression of the surrounding thyroid tissue. In the older cysts, judging from the thickness of the wall, it would appear that there had been a certain amount of new fibrous tissue formation.

Upon its inner aspect also the wall differs widely from that of

an ordinary retention cyst; it is not lined either with well-developed epithelium or with the remains of such tissue, while between the contained fluid and the fibrous envelope is to be found irregularly distributed a greater or less amount of intact gland tissue.

The appearances here presented differ widely from what is to be observed in the ordinary parenchymatous goitre. In the latter the cysts are generally distributed through the substance, and, while individual cysts are often clearly recognisable with the naked eye, they do not attain to any great size. It is easy to follow the stages in their formation—that is to say, an examination of sections taken from cases of parenchymatous or colloid goitre reveals a series of modifications of the vesicles which can not but represent successive stages of the process. In the first place, the vesicles in general may be enlarged and distended with colloid material; later, as is well shown in Wölfler's figures of injected thyroids, where two distended vesicles are in close apposition, the vessels in between become compressed, and become atrophied—a result which is followed by atrophy of the neighbouring epithelium and of the interstitial substance. The next change is in all respects comparable with what obtains in the emphysematous lung under similar conditions. The atrophied tissue becomes completely absorbed, and the two vesicles fuse into one, small projections being left jutting into the common cavity, and indicating the site of the previous partition. This process of fusion may continue so that finally numerous vesicles may thus form one common chamber. The characters of such cysts are constant; they have a clear, sharply cut wall, covered by a continuous layer of epithelium, which is more or less flattened in different cases, according to the amount of pressure exerted by the contents. The walls of the cysts outside the epithelium are thin and indefinite. They are comparable, on the one hand, with the retention cysts to be met with in the various acinous glands—in the kidney, the mamma, the pancreas, and the liver—and, on the other, as above stated, with areas in the emphysematous lung. As with other retention cysts, in these there may occur secondary papillomatous ingrowths.

The whole appearance of the large cysts here referred to is that

of an accumulation in a lobule of the thyroid, the accumulation being associated with some destruction of gland tissue; not all the gland tissue of the lobule has been destroyed; some is left, and it is this that forms the characteristic irregular coating of the internal wall of the cyst. In support of this opinion is the fact that the large masses frequently found projecting into the cysts most commonly spring from the inner or medial aspect of the cyst, from the region where the lobules are not sharply cut off the one from the other.

It must be remembered that the thyroid is an imperfectly lobulated organ; toward the periphery the gland substance is seen to be partitioned off by fibrous septa, running in somewhat irregularly from the surface. These septa, however, become broken up and indefinite in the more central and deeper areas of the organ. But, apart from the character of the lobulation of the gland, it is to be noticed that in any case of accumulation of fluid in the interstices of the thyroid the tendency would evidently obtain for destruction and rupture of the tissue to occur in an outward direction—in the direction of least resistance. Thus, any advancing destruction of thyroid tissue would be most marked toward the exterior.

If this be so, and if these cysts be due primarily to destruction of thyroid tissue and accumulation of fluid in a space bordered by destroyed or partially destroyed vesicles, what is the cause at work leading to such destruction?

According to Wölfler, the main cause is an oversecretion of colloid in the vesicles, with consequent rupture of these, infiltration of the interstitial substance with colloid material, atrophy of the infiltrated tissue, and subsequent continued excretion of colloid from such of the epithelial cells of the ruptured vesicles as remain undestroyed. He devotes two pages to a consideration of the successive steps in such a process.*

So far as I have been able to determine, this view has been generally accepted, and no other explanation has been brought forward by more recent workers to explain the development of these cysts.

* Wölfler, Ueber die Entwicklung und den Bau des Kropfes, Berlin, 1883, p. 192.

Among recent French writers, Rivière,* in a treatise of one hundred and fifty pages, while discussing various diseases of the gland and pointing out that hæmorrhage into the vesicles may lead to a true hæmatocele, has nothing further to say with regard to the relationship between such hæmorrhages and cyst formation beyond the bare notice of the occurrence of hæmorrhagic cysts, and of the liability on the part of intra-acinous papillary growths to give rise to intracystic hæmorrhage. In English and American literature, descriptions of the removal of gross solitary cysts of the gland, evidently similar to those about to be described, are not infrequent, but the surgical features are in general dwelt upon to the entire exclusion of the histological characters. The only full and exact description that I have met with in English or American literature is in an article by Dalziel upon a case described as one of cystic adenoma.† His description tallies entirely with that given by me, and he is careful to draw attention to the very extensive hæmorrhages both into and around the vesicles, and to the evidence that in part, at least, these are of old standing.

But it would seem that against the theory of Wölfler there is not a little to be said. Rupture of a secreting organ or of the follicles of a secreting organ as a result of overactivity is most rare, even in the acini of glands which possess efferent ducts. When these ducts are obstructed, and retention cysts developed, the (at times) enormous expansion of the secreting surface in the cysts does not lead to spontaneous rupture. This certainly may be laid down as a rule to which there exist only peculiarly rare exceptions. Wölfler states that, in the thyroid, areas of such bursting of the vesicles can be recognised. While I am most ready to admit that he has examined a very much larger number of thyroids than has come into my hands, I feel it right to say that in more than twenty-five separate specimens of this organ which I have recently studied, the majority presenting one or other morbid condition, I have not seen any sign of this bursting of dilated vesicles, although I have carefully sought for it; or, to state

* Rivière, Contribution à l'étude anatomique du corps thyroïde et des goitres, Lyons, 1893.

† Dalziel, *Glasgow Medical Journal*, xli, 1894, p. 227.

the case more exactly, where I have found hæmorrhage in the thyroid, with associated rupture of the vesicles, I have been unable to determine that this rupture was at the same time primary and spontaneous, associated with extreme distention.

Again, the nature of the contents of these cysts furnishes a strong argument in opposition to the above theory. If these were essentially the specific secretion from such of the epithelial cells of ruptured vesicles as remain undestroyed, we should expect to find them characteristically thick and colloid. But this is not the case. The peculiarity of the contents consists in the presence of cholesterine, of leucocytes loaded with fatty globules, and of a colour ranging from pale brownish yellow to the pronounced purple of hæmorrhagic effusion. The contents, it is true, are in general glairy, viscid, and albuminous, and contain, in all probability, some colloidal material; but this is greatly diluted, and altogether the specific secretion contained in the fluid appears to be of secondary importance. The so-called colloid cysts of the thyroid, from which upon enucleation thick, clear, semisolid matter is removed, are of a totally different nature from the cases to which here I would draw attention. According to my own observations upon two such "colloid cysts" (to one of which I have already referred), and the notes of a third case recently occurring under Dr. Bell at the Royal Victoria Hospital and reported to me by Dr. Adami, hardening and section of such enucleated colloid material show that it is not homogeneous, but is composed of numerous greatly distended vesicles with very thin walls. The material is, in fact, modified thyroid tissue, and the condition is one of cyst-adenoma, with localized overgrowth and retention of the colloid within the vesicles.

The examination of a series of thyroid glands obtained both from the post-mortem room and from the operation theatre has made very evident to me the frequency with which these organs become the seat of hæmorrhage. In case after case received from Dr. Shepherd and from Dr. Bell there have been indications not merely of recent hæmorrhages, which might have been accounted for by operative interference, but also of old extravasations of blood with the presence of

deposits of modified blood pigment, or again of large cells containing the characteristic modified hæmoglobin.

In Plate XV, Fig. 2, is shown one of these hæmorrhages. The section was obtained from the upper part of the left lobe of the thyroid of a patient who died in the Royal Victoria Hospital some weeks after drinking a large dose of potash lye, taken apparently with suicidal intent. In the region indicated was a roughly spherical tumour, a little over two centimetres in diameter, of comparatively firm consistence and of a rich red colour. Sections through the tumour showed that the hæmorrhage, which must have been comparatively recent, inasmuch as the red corpuscles were in general well preserved, was limited in extent to one lobule of the organ. Around it was a well-defined margin, formed of the connective tissue separating the lobule containing it from the surrounding lobules. In the affected lobule not all the tissue was the seat of hæmorrhage, sundry follicles and the surrounding interstitial tissue being entirely free from extravasated blood (Plate XV, Fig. 2, d). But, in general, there was clearly marked evidence of hæmorrhage. The blood had passed into the vesicles, and also into the interstitial substance. Many of the vesicles were very greatly distended with blood, and presented a thin, flattened epithelium; in one place an area was clearly distinguishable where there had been rupture of a small vessel, with a pouring out of blood both into the follicle and into the interstitial tissue. It was interesting to notice that in many places follicles distended with blood could be recognised, around which there was not the slightest sign of interstitial hæmorrhage. The appearance suggested strongly that the follicles communicate with each other, and that hæmorrhage had taken place into the follicles of one or more communicating systems, while other systems had remained free. Whether such communication is normal or acquired I will not venture to state. In several of the sections the communications between the injected follicles could be recognised; they were undistinguishable from what might have been produced by pressure atrophy, though, at the same time, natural and not acquired communications might present a similar appearance.

In this case, then, we have an example of a hæmorrhage limited to and distending one lobule of the thyroid and of rupture of the vessels resulting in distention of the follicles with interstitial disturbance. Of actual cyst formation the specimen showed no sign.

Plate XV, Fig. 3, represents a much further advanced condition. The case from which this was taken was one of parenchymatous goitre in a woman of twenty years, with diffuse hypertrophy of the organ most marked upon the right side. For four or five years the growth had been slow; during the last twelve months it had been more rapid.

Examined microscopically, the vesicles were found to vary greatly in size (from $15\ \mu$ to $300\ \mu$ in diameter, the average appearing to be from $25\ \mu$ to $30\ \mu$). The larger vesicles were relatively rare, and occurred mainly in the deeper, more central portion of the gland. The contents of the vesicles had a shrunken appearance, and their epithelium was of well-formed columnar type. There was a certain amount of hyaline change in the interstitial tissue.

The enlarged gland presented several hæmorrhages, and upon a closer study of these under the microscope some vesicles were seen filled with blood, as in the previous case. There had, however, been more abundant extravasation into the interstitial substance, and, following upon this, a rupture of numerous follicles. In this way spaces had been produced filled with blood, and showing here and there along their edges layers of columnar epithelial cells, the remains of the burst follicles. Small collections of cells and masses of dislocated tissue could be recognised here and there in the blood-stained fluid, filling these rents in the thyroid. The hæmorrhages were not entirely recent, for in the interstitial substance and in some of the vesicles large pigment-containing cells could be seen.

Two series of changes might reasonably be expected to occur in connection with a lesion such as has been described. Either the epithelium of the ruptured follicles might undergo atrophy, the effused blood might become absorbed, and, through simple inflammatory and reparative processes, the lesion be eventually represented by a small mass of fibroid cicatricial tissue containing more or less blood pigment. In other regions of the specimen last described patches of

fibroid tissue of this nature were observed, and their presence would seem to indicate that small hæmorrhages had been frequent in this case. Or, on the other hand, where the hæmorrhage has been very extensive, there might be developed in the thyroid, as in the brain, a hæmorrhagic cyst, the contents of which, according to the age of the cyst, might, as in other hæmorrhagic cysts, vary from almost pure blood, with some admixture of the destroyed tissue of the part, to a straw-coloured fluid.

Such would seem to be the nature of the cysts here described. The two would possess features in all respects similar. Hæmorrhagic cysts of the nature I have indicated would tend to be limited by the interlobular connective tissue; within the boundary wall there would be not only fluid contents, but a lining of glandular tissue representing those portions of the lobule not destroyed at the time of the original hæmorrhage, and gaining a collateral circulation from the vessels of surrounding lobules.

Whether or not the remaining epithelium of the burst follicles continue to be well nourished and to pour out its excretion is a matter of possible doubt. For myself, I have never in a well-developed cyst seen the slightest indication of even a localized presence of an internal layer of thyroid epithelium; on the other hand, it must be acknowledged that the contents are at times very glairy, and strongly suggest some admixture of dilute colloid material. I regret to say that I did not at the time test the contents of any of the cysts for the presence of colloidal bodies.

On the theory of rupture and destruction of thyroid tissue, there is an anatomical basis for the frequent presence of large masses of thyroid tissue projecting into the cyst from its medial aspect. To this must be added the fact that the macroscopical and microscopical appearances of these ingrowths are wholly against the supposition that they are neoplastic; their surface is covered with a fairly dense layer of fibrous tissue, continuous with the internal layers of the cyst wall; their peduncles are, in general, broad, and pass imperceptibly into a layer of tissue containing thyroid vesicles, which, on the one hand, merges into the layer of glandular tissue lining the inner surface of

the cyst wall, and, on the other hand, did not in any specimen examined by me appear to be sharply differentiated from the surrounding and deeper thyroid tissue; in short, the vesicles in these papillæ resemble the vesicles of the tissue surrounding the cyst. I have already pointed out the many ways in which the contents of these cysts differ from ordinary thyroid secretion, and approach in character to hæmorrhagic products.

I am led, therefore, to regard these large solitary or rare cysts of the thyroid gland as being hæmorrhagic in origin, and I would speak of them as hæmorrhagic or post-hæmorrhagic cysts of the organ.

Many circumstances combined would seem to render the thyroid gland an organ peculiarly liable to be the seat of hæmorrhages. There is, in the first place, the peculiarly vascular character of the organ; in the second, its relatively exposed situation; and, in the third, there may be mentioned, as tending to explain the greater frequency of hæmorrhages, both small and large, in this organ in the female, the changes, apparently to a large extent vascular, which occur in connection with sexual disturbances. It is, however, clear, from the description given to me by Dr. Shepherd and recorded by him in his article in the *Annals of Surgery*, that in most, if not all, of the cases these gross cysts do not develop in healthy thyroids, but that there would seem to have been already some pre-existing morbid condition of the gland predisposing to their production. Judging from the portions of tissue surrounding the cysts that were sent to me, the condition most frequently associated with their development is that of a more or less advanced parenchymatous goitre.

As I have pointed out, in the parenchymatous goitre, even if there be no definite cyst production of a gross type, there may be numerous hæmorrhages; and when it is remembered how delicate are the walls of the distended cysts in this condition, and how abundant at the same time is the vascular supply of the organ and the network of capillaries immediately surrounding the distended vesicles, it is not difficult to realize why it is that such hæmorrhages occur, more especially when the relatively exposed situation of the enlarged gland is taken into

account. Here, in short, exists the most favourable combination of circumstances for the production of extensive hæmorrhages and of hæmorrhagic cysts of the thyroid.

There is one feature of these large cysts which is certainly difficult to explain. I refer to the frequent history given of progressive enlargement, more especially in the early stages. Unfortunately, the clinical histories of my cases are not of a detailed nature. In only one case is it definitely stated that the tumour appeared with comparative suddenness—after violent seasickness—and, when once developed, the patients have yielded no definite information as to whether the earlier growth was gradual, periodic, or irregular. In the later stages, in five out of the seven histories, it is noted that there was sudden or rapid increase. The grumous and blood-stained contents would seem clearly to indicate that this later and sudden increase in size is due to repeated hæmorrhages. In Cases II and VII the thyroid enlargement had been noticed for ten and six years respectively; nevertheless, the contents gave evidence of relatively recent effusion of blood. It is remarkable how frequent were the evidences of hæmorrhage in the projecting masses and surrounding tissue. Possibly the earlier growth is due to a like cause, but, as I have said, the clinical histories do not throw light upon this point.

The progressive enlargement can not be due to secretion from the epithelium lining ruptured vesicles, for in none of the cases of well-developed cysts have I encountered any sign of even localized epithelial lining.

It is possible that the cysts occur in and replace nodular parenchymatous hypertrophies or adenomata of the gland tissue, and that in some of the cases the progressive enlargement noticed in the earlier stages was due to the gradual growth of such nodules, which later became the seat of hæmorrhage and cyst formation. The material at my disposal, which consisted of the enucleated cysts and their contents, is incapable of deciding this question one way or the other.

That the growth, if gradual and cystic from the onset, is due to effusion or imbibitions of serous and colloid fluid from the surrounding vessels and lymphatics is but a remote possibility.

The most I can venture to state with any degree of certainty is that the more rapid and sudden enlargements of the cysts in the later stages can be ascribed to repeated hæmorrhages. I must leave to others possessing fuller opportunities the explanation of the nature of the gradual growth which, from the patients' reports, would seem to be the rule at the onset.

The view here enunciated may involve, it is true, only a slight modification of Wölfler's theory; nevertheless, it seems to me important to recognise the distinction between such spontaneous rupture of distended thyroid vesicles, as is urged by him, and the more inherently probable traumatic rupture with hæmorrhage, as here suggested.

CONCLUSIONS.

1. All the features peculiar to the gross cysts of the thyroid gland which possess fluid contents appear to indicate that they are essentially of hæmorrhagic origin.

2. While these gross cysts would seem more especially to occur in glands which already present the features of parenchymatous goitre, the theory of Wölfler that they originate as a consequence of spontaneous rupture of the vesicles is unsatisfactory.

3. It would seem more probable that these large cysts are due to rupture, traumatic or otherwise, of some of the vessels of the organ. The frequent signs of small hæmorrhages in cases of parenchymatous goitre without evidence of associated gross change in the surrounding vesicles, the structure of the organ and its exposed position, all appear to favour this view.

Finally, I beg to express my indebtedness to Dr. Shepherd for his kindness in affording me, while working mainly in the pathological department of the Royal Victoria Hospital, the material from the Montreal General Hospital, which has formed the groundwork of this paper. I beg to thank also Dr. James Bell for the rest of my material, and Prof. Adami, at whose suggestion I undertook this research, and to whom I am indebted for advice throughout its course.

DESCRIPTION OF PLATE XV.

Fig. 1.—From a hæmorrhagic area in one of the masses projecting into the cysts in Case I. Magnified 250 diameters.

The hæmorrhages in the projecting masses in this case were extensive but entirely interstitial, but the colloid contents, a a, of the vesicles had imbibed the blood-colouring matter and possessed a deep-brown colour, while in addition (in these hæmorrhagic areas only) there were to be seen the large intravesicular crystals, b b. The vesicular epithelium presented numerous fine vacuoles and other indications of degeneration. c c, blood effused between the vesicles.

Fig. 2.—From the interlobular hæmorrhage in the thyroid of Mrs. C. to show interstitial and intravesicular effusion of blood. Magnified 200 diameters.

a. Interstitial hæmorrhage. b. Vesicles filled with blood; disappearance of colloid material and very great distention, with flattening of epithelium. c. Region of rupture. d. Intact vesicles with colloid contents. f. Large pigmented wandering cells.

Fig. 3.—From an extensive hæmorrhage, very recent, in a case of parenchymatous goitre, Mrs. F., aged twenty years. Magnified 200 diameters. The figure shows rupture of the thyroid tissue. The effused blood is bordered in part by the epithelium of large ruptured vesicles, in part by interstitial tissue. (The former condition was only exceptionally observed in the sections.)

a. Intact vesicles of medium size. b. "Embryonal" masses of glandular tissue. c. Epithelium of large ruptured vesicles bordering upon the hæmorrhage. d. Broken-down thyroid tissue. f. Effused blood.

Fig. 4.—Section through the wall of one of the cysts, from Case IV. Magnified 250 diameters.

The section has been taken through a region where there was a low projection of thyroid tissue into the cyst, and the figure only includes the external portion of this and is not continued to the outermost portion of the cyst wall, where it passed into the surrounding thyroid tissue (beyond h).

a. Healthy vesicles lying along the inner wall of the cyst. b. Terminal portion of a long vesicle lying along the main fibrous tissue of the cyst wall. This contained blood, and, as shown in the figure here and there, along its outer aspect there was an absence of epithelium, this being replaced by a layer of flattened cells. c. Undeveloped gland tissue. d. Lymph space (?). f. Simple connective tissue forming the cyst wall. g. Undeveloped and compressed gland tissue in the thickness of the cyst wall. h. Lymph spaces, or vesicles that are atrophied and devoid of epithelium, filled with homogeneous colloid material. m. Corpuscles containing blood pigment. n. Epithelium of a vesicle tinged with blood pigment.

[All the figures have been drawn by means of a Zeiss's camera lucida. Fig. 3, taken from a somewhat thick section rich in deeply stained nuclei, while correct in its outlines, has its details rendered purposely in a slightly conventional manner.]

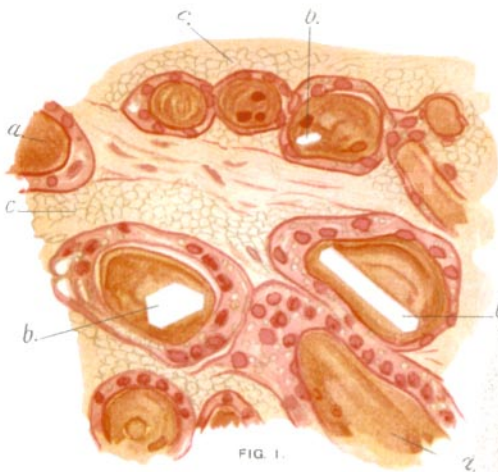

FIG. 1.

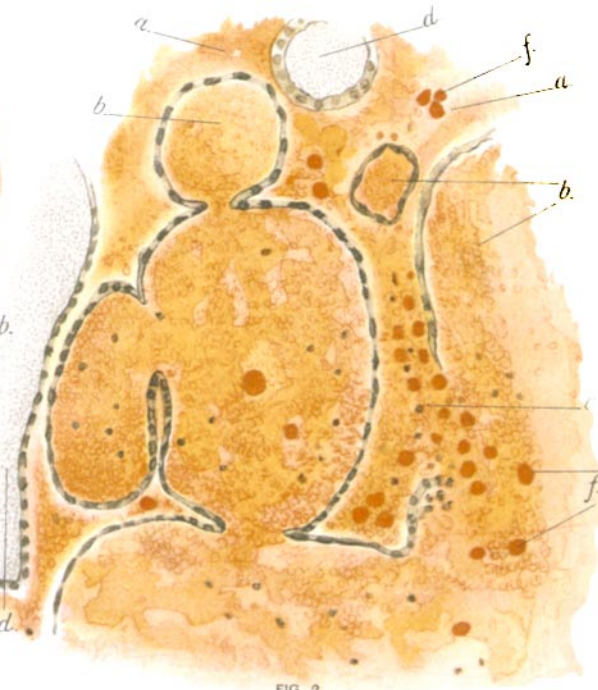


FIG. 2.

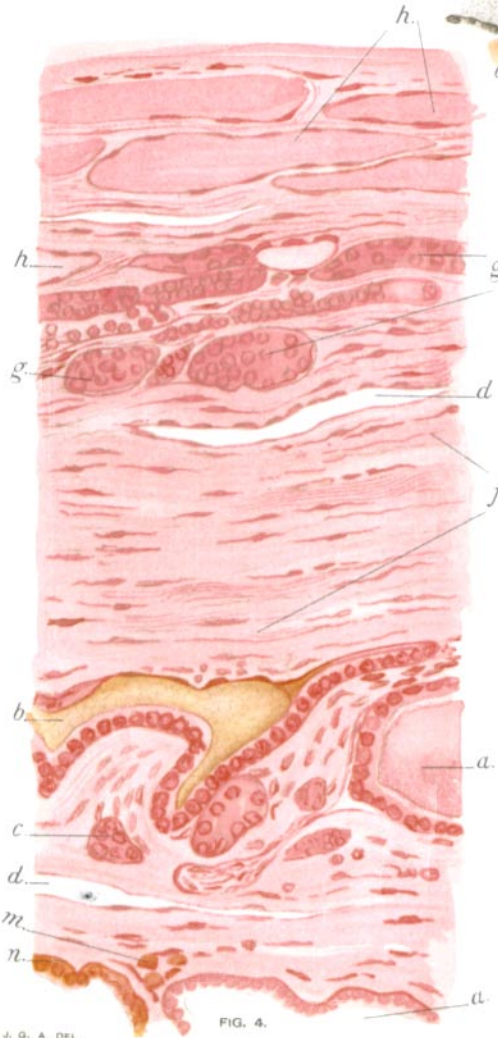


FIG. 4.

J. G. A. DEL.

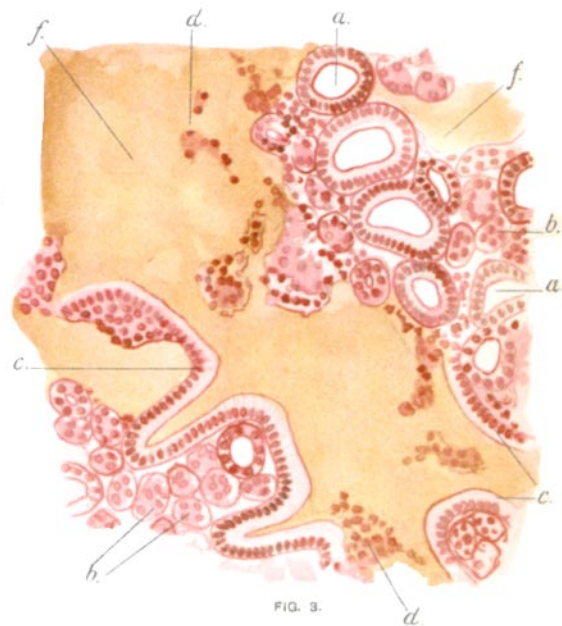


FIG. 3.

A. HOEN & CO.