

REGENERATION OF NERVE FIBRES IN THE CENTRAL NERVOUS SYSTEM.

BY W. L. WORCESTER, M. D., ASSISTANT PHYSICIAN AND PATHOLOGIST,
DANVERS LUNATIC HOSPITAL.*

PLATE LII.

The tendency of the peripheral nerves to regeneration and restoration of function after division is well known. There would seem to be no reason, *a priori*, why the processes of the neurones within the central nervous system, so similar to the peripheral fibres in structure and function, should not conduct themselves in a like manner; but it is notorious that such is not, at least commonly, the case. Whether the interruption of continuity is due to traumatism or to disease, the rule seems to be that there is no attempt at repair of damage.

In view of this well known fact, it seemed to me that a case coming under my observation, in which there is, in my judgment, beyond reasonable doubt, a growth from interrupted fibres in the central nervous system, deserves to be placed on record. I have been able to find in the literature of the subject but little lending countenance to the belief that such regeneration ever takes place.

Brown-Séguard (1) reported in 1851 a fairly complete restoration of sensibility and partial restoration of movement in a guinea-pig after section of the spinal cord. Microscopical examination of the cord, by himself and Laboulbène, showed very numerous medullated fibres extending through the cicatrix.

Eichhorst and Naunyn (2) in 1874, experimenting on new-born puppies, in which they destroyed the spinal cord by pressure with a blunt instrument without opening the dura, found evidence of restoration of function in some cases, beginning from the third to the fifth week after operation. In from seven to nine weeks the puppies were able to walk on all fours ten or fifteen feet. The movements were very awkward and

* Read at the meeting of the American Neurological Association, New York, May 28, 1898.

ataxic. These observers thought they got some evidence of restoration of sensibility, but admitted that it was very slight. No further improvement took place; on the contrary, there was generally retrogression after ten or twelve weeks. The histological examination showed in the cicatricial tissue connecting the segments of the cord small numbers of medullated nerve fibres, resembling rather those of the peripheral nerves than of the spinal cord.

Schiefferdecker (3) criticized the foregoing paper severely. Although he did not dispute the presence of newly formed nerve fibres in the cicatrix, he believed that the authors had mistaken reflex for voluntary movements, and denied that there was any restoration of function. His own experiments made on dogs several months old all gave entirely negative results. In consequence of Schiefferdecker's criticisms, Eichhorst (4) took up the subject again. He operated as before on newborn puppies, but isolated the cord and lifted it out of the canal, so that there could be no question of its complete division. He obtained a positive result in only one of three puppies. This one began to move the hind legs at the end of the fourth week; began to walk on the 26th day, and on the 35th day walked continuously a distance of about 180 feet. No evidence of return of sensibility could be found. The animal was killed at that time, and the continuity of the cord was found to be restored by a tissue containing very numerous nerve fibres.

Sgobbo (5) and Marinesco (6) in their experiments by division of the spinal cord both failed to get any evidence, whether functional or anatomical, of regeneration. Popoff (7), in studying the lesions of multiple sclerosis, satisfied himself that the naked axis cylinders found in the lesions were not, as has been generally supposed, remnants of the original constituents of the cord, but, in many instances at least, newly-formed fibres. He claims to have seen the division of a single axis cylinder into a number of fine fibres.

Stroebe (8), experimenting by section of the spinal cord in rabbits, found what he considered unquestionable evidence of growth of nerve fibres into the scar from the posterior nerve roots. In the anterior and lateral columns he found fine medullated fibres in the zone of degeneration, often presenting a contorted, confused course, which he judged to be newly formed. They never passed the line of incision. He concludes that there is an effort at regeneration, but that it never comes to a restoration of continuity in the nervous structure.

Borst and Nicolaier (9), in a case of fracture of the vertebral column in the lower thoracic region in which the patient had survived the injury for three years, found numerous medullated fibres, resembling those of

the peripheral nerves, in the region of both the posterior and anterior nerve roots, from which he considers them to be outgrowths, comparing them to the amputation neuromata.

The case to which I ask attention is that of a married woman, aged 41 at the time of her admission to the Danvers Lunatic Hospital, September 28, 1885. Very little information was furnished in regard to her antecedents beyond the fact that she had suffered from repeated attacks of maniacal excitement. At the time of her admission she was much demented; there is no history of any subsequent maniacal outbreak. During her stay in the hospital she had two parietic attacks, both affecting the left side, leaving permanent impairment of motion and sensation, with paræsthesia, which gave rise to delusions that her left side was maltreated in various ways. After the second attack she was confined to her bed until her death, nearly two years afterward.

When she came under my observation in the spring of 1895 there was very marked impairment both of motion and of sensation in all its modes in the entire left side with the exception of the face. She complained of pain in that side, which she attributed to "people throwing things on her." On September 21, 1895, she had an epileptiform convulsion from which she never rallied, dying September 27.

At the autopsy both right corpora quadrigemina were found to be much smaller than normal and of a yellowish brown color. The bodies, together with the pons and medulla oblongata, were hardened in a solution of bichromate of potassium and cut in serial sections for the purpose of studying the secondary degenerations. It then appeared that there was also a large focus of softening in the right side of the pons, involving the pyramidal tract extensively and encroaching on the lemniscus. With the secondary changes from these lesions I am not at present concerned.

On examination of the sections the first-mentioned lesion was found to involve the whole of the right corpora quadrigemina, passing a little beyond the median line above the aqueduct and extending downward laterally to the border of the pes pedunculi. It did not

extend below the central gray matter surrounding the aqueduct (see Plate LII, Fig. 1). Microscopically it was seen to consist of a dense felt-work of neuroglia fibres, rather sparsely supplied with vessels.

In the anterior corpus quadrigeminum, approximately in the centre of the diseased area, I found a group of medullated nerve fibres (Plate LII, Fig. 1, *a*) which I at first supposed to be a normal tract which had escaped the destruction that had befallen the surrounding tissue. On tracing it through successive sections, however, I found that the number of fibres diminished in each direction, and that it finally disappeared at each end, without any apparent connection, either proximally or distally, with any normal tissue. On comparing it with the corresponding region on the opposite side, no group of fibres could be found presenting an arrangement at all resembling it. The appearance at the largest portion of the tract can be seen in Fig. 2; near its proximal and distal extremities in Figs. 3 and 4 respectively.

The tract consists of a number of bundles of fibres, showing an irregular, convoluted arrangement, without any apparent order or system. Careful examination of specimens, stained in various ways, failed to reveal any nerve cells in or about this area. In a number of sections, however, small bundles of fibres could be seen extending between it and the zone of white substance surrounding the red nucleus (Plate LII, Fig. 5, *b*). This was the only connection that I could trace between it and normal tissue and must, I think, be the origin of the group in question.

Such are the facts in the case. As to the interpretation to be put upon them, I can see no reasonable hypothesis other than that the fibres in question are outgrowths from neurones that were interrupted in their course by the lesion. That they are not simply a remnant of the original structure seems certain from the fact that nothing at all resembling them can be found in normal specimens from the same region.

Moreover, it will, I think, be evident to any one who studies the specimens that it is entirely improbable that such a tract could be preserved in the very centre of the focus of disease. The appearance

of these irregular, contorted bundles of fibres, so strikingly similar to that of an amputation neuroma, is also, to my mind, strongly confirmatory of this view.

If this is the correct interpretation of the facts, it would appear that nerve fibres in the central nervous system, after solution of continuity, may be capable of growth. Of course, in this case, there is no question of regeneration in the sense of restoration of the original structure or function. In the present state of our knowledge this finding must be considered rather as a curiosity than a matter of practical importance.

REFERENCES.

1. Brown-Séguard.—*Gaz. méd. de Paris*, 1851.
2. Eichhorst and Naunyn.—*Arch. f. exper. Pathol. u. Pharmakol.*, ii, 1874.
3. Schiefferdecker.—*Virchow's Archiv*, lxxvii.
4. Eichhorst.—*Zeitschr. f. klin. Med.*, i, 284.
5. Sgobbo.—*La Psichiatria*, 1890.
6. Marinesco.—*Centralbl. f. Nervenheilk.*, Oct., 1894.
7. Popoff.—*Neurol. Centralbl.*, May 1, 1894.
8. Stroebe.—*Ziegler's Beiträge z. path. Anat.*, xv, 1895.
9. Borst.—*Berichte über Arbeiten aus dem Path.-anat. Institut der Universität Würzburg*, 1. Folge, p. 34. Würzburg, 1897.

DESCRIPTION OF PLATE LII.

Fig. 1.—Section through corpora quadrigemina, $\times 2$. Newly formed fibres at *a*.

Fig. 2.—Fibres at *a* in preceding figure, $\times 40$.

Fig. 3.—Newly formed fibres near proximal end, $\times 40$.

Fig. 4.—Same, near distal end, $\times 40$.

Fig. 5.—Same, thickest portion of tract. Bundle of fibres connecting it with tegmentum at *b*.

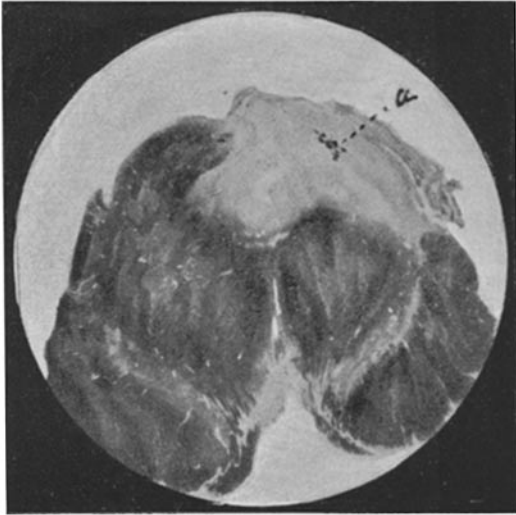


FIG. 1.

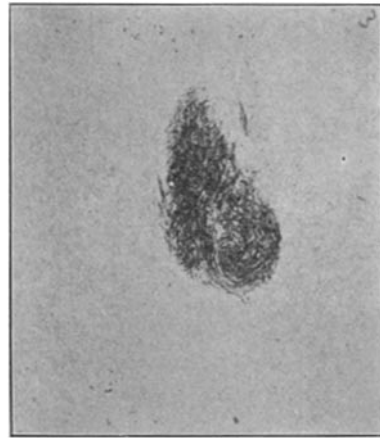


FIG. 3.

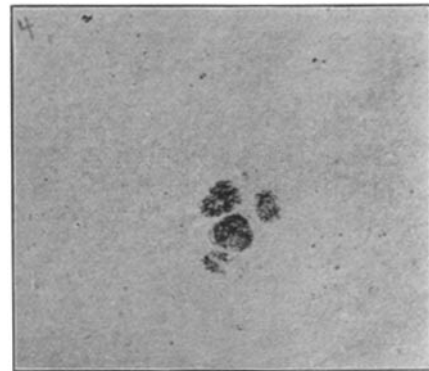


FIG. 4.

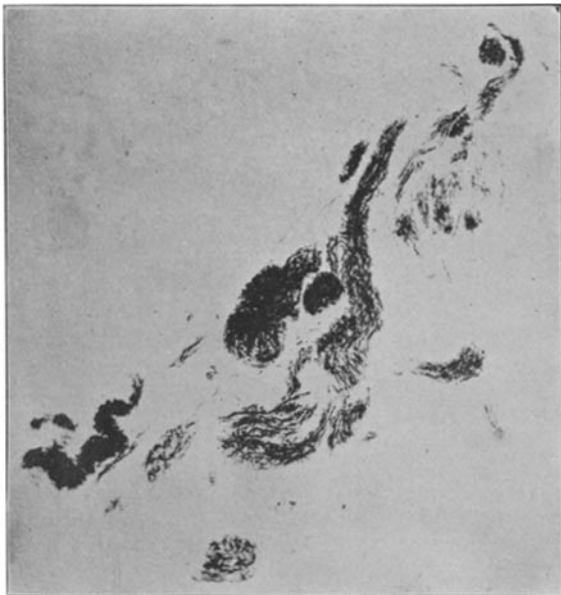

FIG. 2.

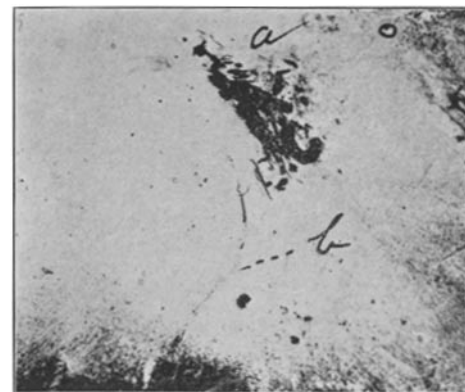


FIG. 5.