

THE RELATION OF DIABETES MELLITUS TO LESIONS  
OF THE PANCREAS. HYALINE DEGENERATION OF  
THE ISLANDS OF LANGERHANS.

BY EUGENE L. OPIE, M. D.

*Instructor in Pathology, Johns Hopkins University.*

*(From the Pathological Laboratory of the Johns Hopkins University and Hospital.)*

PLATE XXXIII.

Embedded in the substance of the pancreas are the peculiar bodies described by P. Langerhans and usually designated islands of Langerhans. They are composed of polygonal cells arranged in irregular columns, between which are wide tortuous anastomosing capillaries. The cells are of epithelial type and have the same origin as those of the ducts and secreting acini with which, at an early period of development, the cell columns are in continuity. The lumen of the ducts does not penetrate among the cells of the island, which is, therefore, not concerned in the elaboration of the pancreatic juice. These bodies resemble in architecture other ductless structures, such as the parathyroid bodies, the carotid and coccygeal glands, and less closely the suprarenal capsules, the pituitary body and the thyroid gland.

The intimate relation of columns of epithelial cells to a rich capillary network has suggested that they furnish some substance to the blood—the hypothetical internal secretion of the pancreas. Abundant experimental research, inaugurated by von Mering and Minkowski, having shown that the pancreas exerts some very important influence on carbohydrate metabolism, several writers—Laguesse, Schäfer, Diamare—have suggested that the islands of Langerhans perform this function. The only experimental evidence in support of this suggestion is furnished by Ssobolew, who, in a brief preliminary communication, states that after feeding animals with carbohydrates in considerable quantity the cells of the islands become

more granular than usual. He finds that the chronic interstitial pancreatitis, which in dogs follows ligation of the pancreatic ducts, spares the islands of Langerhans; this fact, he thinks, explains the absence of glycosuria.

In the preceding number of this JOURNAL<sup>1</sup> I have described alterations undergone by the islands of Langerhans in various forms of chronic interstitial pancreatitis, and have discussed the relation of these lesions to the disease of carbohydrate metabolism, diabetes mellitus.

Two forms of chronic inflammation of the gland are distinguishable: (1) interlobular pancreatitis, characterized by proliferation of fibrous tissue between the lobules, which are invaded from the periphery, and (2) interacinar pancreatitis, where the new-formed fibrous tissue is more diffusely distributed within the lobules and between individual acini. With the first type the islands of Langerhans are implicated only when the sclerotic process has reached a very advanced grade. To this variety belongs the chronic inflammation which follows occlusion of the pancreatic duct; though the secreting tissue of the gland is in very great part destroyed and replaced by dense fibrous tissue, the interacinar islands are not affected and persist for a long time as isolated cellular structures almost completely unchanged, though surrounded by scar-like tissue. They suffer only when the process is far advanced. With the interacinar type of inflammation, on the other hand, the islands are affected as are the other elements of the gland, and coarse strands of fibrous stroma following the capillary vessels separate the columns of atrophied cells.

Of eleven instances of chronic pancreatitis of the interlobular type, in only one was diabetes present. Here the inflammation which followed obstruction of the pancreatic duct had reached a very advanced

<sup>1</sup> Opie. On the relation of chronic interstitial pancreatitis to the islands of Langerhans and to diabetes mellitus. *Journal of Experimental Medicine*, 1901, v, p. 397. References to the authors cited are here given. See also *Journal of the Boston Society of the Medical Sciences*, June, 1900, iv, p. 251. W. Schulze (*Arch. f. mikr. Anat.*, August 31, 1900, lvi, p. 491) has recently shown that the islands of Langerhans are not implicated in the chronic interstitial inflammation which follows obstruction of the pancreatic duct in guinea pigs.

grade and the islands of Langerhans, isolated in the dense stroma, had undergone alterations. The accompanying glycosuria had been of only slight severity and had disappeared when the patient was upon a diet poor in carbohydrates. In two of three instances of interacinar pancreatitis diabetes mellitus was present. In the third case the lesion was slight and the organ weighed 170 grammes. Though the number of cases is small they indicate that where diabetes accompanies a lesion of the pancreas the islands of Langerhans are implicated in the disease.

In the same report I described a case of diabetes mellitus in which the pancreas was the seat of a very remarkable lesion. In sections from all parts of the organ were small areas in which the parenchymatous cells were replaced by hyaline material located immediately outside the walls of the capillaries. These areas, which were most abundant in the tail of the gland, frequently corresponded in size to islands of Langerhans, but were often much larger. Self-digestion of the gland in many places prevented the satisfactory study of the lesion, but even where the tissue was well preserved islands of Langerhans were not recognizable. Although the change began apparently in these structures, it had extended beyond their limits.

I have recently had the opportunity of studying the specimens from a case of diabetes in which the causal relation of a lesion of the islands of Langerhans to the disease is more clearly demonstrable than in those previously described. These bodies are the seat of a degenerative change which has left unaltered the secreting parenchyma of the gland.

*Synopsis of Clinical History.*—Female, negro, aged 54 years. The patient was admitted to the Johns Hopkins Hospital in the service of Dr. Osler, complaining of cough. Her family and personal history are unimportant. Her present illness began about eleven months before her admission, when, she states, she had a severe cold which became steadily worse. The cough has been accompanied by profuse expectoration. She has lost much weight. Several months after the onset of cough her urine increased greatly in quantity, so that for a time she was compelled to get up almost every hour during the night to void it. The urine was pale in color. At this time she experienced great hunger

and thirst and ate and drank enormously. These symptoms lasted during part of the spring and summer and disappeared some months before her admission to the hospital. She had recently voided the usual amount of urine and there was no excessive hunger or thirst.

When admitted the patient was thin but moderately well nourished. The mucous membranes were pale. The percussion note over the front of the chest and in the axillary region was hyperresonant; over the upper part of the back on the right side the note was dull, while elsewhere over the back there was flat tympany. The breath-sounds over the first and second interspaces on the right side in front were intensely tubular, while on the left side above the fourth interspace they had an amphoric quality and were almost cavernous. There was modified tubular breathing over the left back, amphoric over the upper part of the scapula. Numerous fine and coarse moist râles were heard throughout both lungs. A friction rub was audible in the lower left axilla. The sputum was abundant, yellowish green, muco-purulent in character, and contained numerous tubercle bacilli. The hæmoglobin was 62 per cent. The stools were of normal color and contained no fat.

The patient gradually became weaker. Cough was almost constant and large quantities of muco-purulent material were expectorated. The temperature was irregular, and until the day preceding death ranged between 98.8° and 102° F. Death occurred on the seventh day after admission and was not preceded by a period of coma.

The specific gravity of the urine varied between 1025 and 1035. It contained sugar in abundance; neither albumin nor casts were found. On the fourth day after admission 880 cc. were collected, the specific gravity was 1028 and 4 per cent of sugar was present. On the following day the amount was 1200 cc., the specific gravity 1035 and the quantity of sugar 5.4 per cent.

*Autopsy.*—Performed 51 hours after death. The body is that of a sparsely nourished woman; the arms and legs are very thin and the abdomen is retracted. Subcutaneous fat is present in small amount.

The heart-muscle is pale, and upon the intima of the mitral valve are opaque, yellow patches of fatty degeneration. Within the coronary arteries near their orifices are a few slightly raised yellow sclerotic patches.

The left lung is very voluminous and is almost universally bound by fibrous adhesions to the chest wall. Immediately below the pleura, occupying the upper part of the upper lobe, is a large, irregular cavity, the walls of which are covered by yellowish necrotic material. The re-

mainder of the lobe is consolidated, dull yellowish red, mottled with areas of caseation and riddled with small cavities. The upper part of the lower lobe is very thickly studded with groups of confluent partly caseous tubercles. The right lung is also voluminous and bound at the apex to the chest wall by fibrous adhesions. Upon the pleura are sparsely scattered gray tubercles. At the apex below the pleura is a cavity, which in size and appearance resembles that of the left lung. The remainder of the lobe is in great part consolidated by numerous caseous tubercles; the tissue is tough in consistence and contains much fibrous tissue. Caseous tubercles are abundant in the middle and lower lobes. Upon the mucosa of the larynx near the posterior extremities of the vocal cords and upon the surface of the epiglottis are a few very superficial ulcers, the largest about 3 mm. in diameter.

The liver is pale and its lobulation is marked by gray-yellow and red mottling. Upon the cut surface are seen rather conspicuous yellowish points of minute size. The spleen is not enlarged.

The kidneys are of large size and weigh together 400 grammes. The surface, after removal of the capsule, is smooth and pale. The cortex, which has an average thickness of 5.5 mm., is of a grayish-red color. The left kidney has two separate pelves, from which arise two ureters opening by separate orifices into the bladder.

The mucous membrane of the stomach is normal in appearance. In the lower part of the ileum are a few scattered superficial ulcers about 0.5 cm. in diameter with irregular, slightly raised edges. On the peritoneal surface opposite one of them are several gray nodules which are just visible. A few similar ulcers are present in the large intestine.

The pancreas weighs 80 grammes and measures 23 x 5 x 1 cm. It can be readily dissected from the surrounding tissues. It is soft in consistence, and on section has a gray-yellow color.

The intima of the aorta, though fairly smooth, is studded with irregular, slightly raised plaques. The arteries at the base of the brain are normal in appearance. No lesion of the brain is found; the floor of the fourth ventricle presents nothing unusual. In the lower part of the right lateral lobe of the thyroid gland is a round firm nodule about 1 cm. in diameter. Its cut surface has a bright yellow color and is mottled with red and translucent gray.

*Microscopic Examination.*—In sections of the pancreas prepared for histological study is found no generalized increase of the interstitial tissue, but here and there, particularly in the tail of the organ, the

fibrous stroma shows some proliferation, and there are occasional irregular strands of tissue between the acini, though these are almost universally separated by delicate septa. This scanty, new-formed interstitial tissue, where it occurs, is poor in cells; about some of the medium-sized interlobular blood-vessels are small accumulations of scattered lymphoid cells, together with an occasional plasma cell. Mononuclear cells with eosinophile granulations are not infrequently seen in the interlobular and interacinar tissue. In the head and the body of the organ are small areas of post-mortem self-digestion, where nuclei no longer stain and the tissue takes with hæmatoxylin a diffuse blue tint. The glandular tissue elsewhere is well preserved. In many acini, centro-acinar cells are numerous. The ducts are not dilated and appear to be normal. There are no alterations of the veins or arteries.

The islands of Langerhans are the seat of a very remarkable change (Plate XXXIII). In varying amount within almost every island is a homogeneous material which stains with eosin. Only rarely is found an unaltered island. Those which are least changed contain a few scattered masses of hyaline material, of which the smallest are irregularly polygonal in shape and correspond in size to the cells of the island. The larger particles are rounded. This hyaline substance at times lies in the midst of groups of cells, but is usually in contact with the walls of the capillaries penetrating the island, or next the peripheral fibrous tissue, and is therefore usually between the remaining cells and the capillary walls. Increasing in amount, it replaces the cells and, where it is abundant, the cells which still persist are small and contain small nuclei, staining deeply with hæmatoxylin. They do not appear compressed or distorted.

Where hyaline material is abundant it forms conspicuous masses in contact with capillaries, the endothelium of which is well preserved. It does not form a uniform zone about them, but it occurs as scattered groups of irregular, rounded, often globular masses (Plate XXXIII, Fig. 2). The cells of the island have been in large part replaced, and between the hyaline particles is seen only an occasional compressed, fusiform or irregular nucleus.

The hyaline substance may occupy almost the entire area of the island, and besides a few endothelial cells are found only small scattered groups or rows of atrophic epithelial cells. The island is represented by a sharply circumscribed, hyaline structure, composed of particles of homogeneous material, giving the impression of broken, twisted columns, between which are the capillary walls. The nuclei of the capillary endothelium persist after destruction of the epithelial cells, but finally disappear. The lumen of the capillary remains patent and red blood-corpuscles are seen between the hyaline masses, although the endothelium no longer contains nuclei. The hyaline metamorphosis is limited strictly to the islands of Langerhans, the glandular acini remaining intact.

Lesions similar to those of the pancreas are not present in other organs. In the heart-wall are a few small areas where the interstitial tissue is increased, and in places the muscle-cells are fragmented, but other changes are not found. Sections from the lung show the histological pictures of conglomerate tubercles and of gelatinous and caseous pneumonia. The blood-vessels of the liver, spleen and kidney are apparently unaltered and there is no formation of hyaline material in these organs. Miliary tubercles are present in the liver, whose cells contain much fat.

The nodule observed at autopsy in the thyroid gland consists of altered parenchyma circumscribed by a thin circular capsule of fibrous tissue. The alveoli composing it vary greatly in size, some being very small and containing no colloid material, while others are large and irregular and distended with this material. The interstitial tissue of the nodule has an almost uniform hyaline appearance, when stained with eosin, and contains only very few scattered nuclei. The epithelium of the dilated alveoli is often much flattened. In places it is broken and the colloid within is continuous with the homogeneous substance replacing the interstitial tissue. Treated with Van Gieson's stain, the contents of the greater number of alveoli stain only with picric acid and assume a bright yellow color; but occasionally this material is colored by fuchsin and becomes deep orange red. The hyaline material immediately outside the alveoli and continuous, where the epithelial lining is broken, with that within, takes the same yellow stain and is doubtless extravasated colloid. Where it infiltrates the interstitial tissue midway between adjacent alveoli, it contains those constituents of the

fibrous stroma which have an affinity for fuchsin and, therefore, assumes a reddish color. The thyroid alveoli outside the nodule are far less irregular in size, and the stroma does not show the same uniform hyaline transformation, but here and there extravasation of colloid material has occurred into the interstitial tissue.

The peculiar transformation affecting the islands of Langerhans in this case belongs to the varied and ill-defined group of degenerative processes whose common characteristic is the formation of a homogeneous or hyaline material which stains with acid dyes, such as eosin and picric acid, but does not give the reactions of amyloid substance, though it resists the action of a variety of chemical substances, as strong acids and alkalis. These characteristics have been used by von Recklinghausen<sup>2</sup> to group together products of cell degeneration occurring in widely different tissues and doubtless representing a variety of essentially different processes, which even yet have received no satisfactory classification.

Under the heading of colloid transformation von Recklinghausen has included amyloid, hyaline and mucous degenerations—processes whose common character is the formation of a substance insoluble in the tissue juices. He recognized that the chemical and physical peculiarities ascribed to hyaline material do not serve to identify it as a true chemical compound, but he has grouped together as the products of related processes the hyaline substances which are formed in many different situations. These include the hyaline formed in the choroid of the eye, in certain tumors of the connective tissues and of the lymphatic apparatus; the homogeneous substances which are formed by certain glandular cells as products of secretion or of degeneration, namely, the contents of thyroid alveoli, hyaline renal casts, etc.; material formed on the surface and in the superficial layer of mucous membranes as the chief constituent of diphtheritic membranes; the so-called waxy or pseudo-waxy material formed by acute degeneration of smooth and striated muscle-fibres; the hyaline thrombi formed in the blood-vessels and in the heart.

Klebs<sup>3</sup> has attempted to classify more precisely these heterogeneous

<sup>2</sup> *Handbuch der allgemeinen Pathologie des Kreislaufs und der Ernährung*, p. 404. Stuttgart, 1883.

<sup>3</sup> *Die allgemeine Pathologie*, Theil ii, p. 100. Jena, 1889.



processes and to define more clearly certain long-accepted terms which have been applied to them. He reserves the name "colloid" for those albuminous substances which resemble the colloid of the thyroid gland and, like it, are elaborated by secreting cells, though not necessarily preformed within them. As "hyaline" he designates the firm, refractive and homogeneous albuminous material which does not give the reactions of amyloid and is formed in connective tissue and in other derivatives of the mesoderm. The hyaline material formed in and outside the cardiovascular system from constituents of the blood, the hyaline thrombi and hyaline exudates he distinguishes from the tissue hyaline produced by transformation of connective tissue.

By means of staining reactions, P. Ernst<sup>4</sup> attempts to demonstrate that the various substances grouped together by von Recklinghausen as hyaline are not chemically identical. Hyaline material from different sources, when treated with Van Gieson's mixture, exhibits in its affinity for acid fuchsin and picric acid differences which he attributes to peculiarities of chemical composition. That which is derived from epithelial cells stains orange yellow with the mixture of the two dyes, being colored by the picric acid and only tinted by fuchsin. Examples of this form of hyaline are the colloid of the thyroid gland and many renal casts. The second variety is formed in connective tissue or from coagulated material derived from the blood and stains intensely with fuchsin. Such hyaline occurs in the interstitial tissue of the thyroid gland, in certain tumors, as the hyaline remnants of the corpora lutea of the ovary, and as hyaline glomeruli in the kidney.

Lubarsch<sup>5</sup> regards the staining reactions of Ernst as an uncertain means for the identification of different hyaline substances and points out discrepancies between the criteria proposed by Klebs and by Ernst. Hyaline thrombi, which, according to Ernst, should stain red are usually yellow and only rarely stain deeply with fuchsin. The renal casts, which stain by Weigert's method for the demonstration of fibrin, stain orange yellow, though they are, as Ernst himself thinks, hyaline fibrin and, therefore, of parablasic origin. The colloid contents of the thyroid alveoli (as in the nodule described above), occasionally stain deep red, although this substance is undoubtedly of epithelial origin. Although Lubarsch discards the classification of Ernst, he admits that the method employed indicates in many cases the origin of hyaline

<sup>4</sup> Virchow's *Archiv*, 1892, cxxx, p. 377.

<sup>5</sup> *Ergebnisse der allgemeinen Pathologie und pathologischen Anatomie. Herausgegeben von Lubarsch u. Ostertag*, 1895, ii, p. 200.

material. Its advantage, he believes, lies in the fact that by it we can recognize whether hyaline contains a constituent derived from connective tissue. Normal fibrous tissue is stained intensely red by acid fuchsin and the substances which determine its affinity for the dye are present in the degenerate tissue. Pure hyaline, whatever its origin, Lubarsch suggests, always stains in the same way, while differences in staining reaction are dependent upon the admixture of other substances.

Hyaline material formed by a variety of processes from different tissues and exudates doubtless differs in chemical composition. That which is produced by coagulative necrosis from the protoplasm of parenchymatous cells and by the so-called pseudo-waxy degeneration of muscle-fibres is not identical with the hyaline of thrombi and of hæmatogenous exudates. The hyaline transformation of connective tissue in various situations, in certain tumors, in the walls of capillaries, in altered renal glomeruli, represents a longer continued process and is more closely related to amyloid degeneration. Since we have at present no means of determining the nature of these substances, their source and their methods of production can alone be used as a basis of classification. Following Lubarsch, we may distinguish hyaline of epithelial and of conjunctival origin, and again we may recognize that, like the colloid of the thyroid gland, formed outside of cells presumably by a process of secretion, and that formed by transformation of the cell protoplasm.

The material which in the case herewith described partly or completely replaces the islands of Langerhans, was tested with a variety of agents which have been used in the study of hyaline substances. It stains deeply with acid dyes, like eosin and picric acid, but shows little affinity for nuclear stains, as, for example, hæmatoxylin and methylene blue. With basic fuchsin and water blue, by the method which Unna<sup>6</sup> has used for the demonstration of basiphilic hyaline, it is stained only by the acid dye. The tissue available for study after discovery of the lesion had been hardened in Zenker's fluid. The methods employed by Pianese<sup>7</sup> in studying the hyaline degeneration occurring in cancer cells require in great part special methods of fixation and were not used.

<sup>6</sup> *Monatshefte für prakt. Dermatol.*, 1894, xix, p. 663.

<sup>7</sup> *Ziegler's Beiträge z. path. Anat.*, Suppl. Heft, 1896, p. 684.

The reactions of amyloid were not obtained with iodine, nor with gentian violet, methyl violet nor iodine green. The material did not stain by Weigert's method for the demonstration of fibrin.

Of much interest, in view of the study of Ernst, is the behavior of the substance toward picric acid and acid fuchsin. It stains with picric acid, but shows no marked affinity for acid fuchsin. The result varies slightly when varying proportions of the two substances are used. With a mixture of 3 parts of concentrated aqueous solution of acid fuchsin and 150 parts of concentrated aqueous solution of picric acid (Van Gieson-Ernst) the hyaline is stained yellow tinted with red. Using the two stains, as employed by Unna, a pure yellow results; the minute strands of fibrous tissue which penetrate the island stain deep red, while the hyaline material in contact with them is yellow.

This material, therefore, conducts itself toward Van Gieson's stain as does, according to Ernst, hyaline of epithelial origin, and in its staining reaction resembles the colloid material which is present in the greater number of thyroid alveoli and which in the thyroid nodule described has found its way into the interstitial tissue. Accepting the interpretation of the reaction suggested by Lubarsch, it does not contain the constituent of fibrous tissue upon which depends an affinity for acid fuchsin. It may be here noted that in the thyroid nodule, where extravasated colloid has infiltrated the fibrous tissue between adjacent alveoli, it has assumed a reddish color.

The staining reactions of this homogeneous substance present in the islands of Langerhans, interpreted with reserve, indicate its epithelial origin. Finding it in irregular masses in contact with the cells, I was at first inclined to believe that it was formed by a process resembling secretion. It was pointed out to me by Dr. Welch, who examined my specimens, that transitions occurred between the cells and the hyaline masses. In slightly altered islands one finds small masses of material which resemble the hyaline substance, but, like the cell protoplasm, have a granular aspect. They correspond in size to the adjacent cells of the island but contain no nuclei.

By the use of certain stains, phosphomolybdic acid hæmatoxylin

by the method of Ribbert for white fibrous tissue or aniline blue, as employed by Mallory,<sup>8</sup> for the demonstration of white fibres and reticulum, the hyaline material acquires a deep blue color and becomes very conspicuous. In the islands are not infrequently found slightly enlarged cells which, though still containing nuclei, exhibit a reaction similar to that of the hyaline material. The cell protoplasm, though granular, has assumed a diffuse blue color.

The degenerative process first manifests itself by an increase in the size of the cell and an alteration of its protoplasm. With the death of the cell its nucleus disappears and the protoplasm which stains with acid dyes remains for a time granular, but subsequently becomes homogeneous. The small particles of hyaline fuse with one another and form larger masses which lie in contact with the fibrous septa of the island. After complete transformation of the cells the island is represented by a hyaline mass penetrated by the remains of altered capillaries.

In the preceding number of this JOURNAL<sup>9</sup> I described, with an illustrative drawing, a case of diabetes in which hyaline material was present in circumscribed areas throughout the pancreas. The staining reactions of this substance resembled those observed in the present case. Amyloid reactions were not obtained, nor did it stain by Weigert's method for the study of fibrin. With the various modifications of Van Gieson's mixture, it showed little affinity for acid fuchsin. With the methods of Ribbert and of Mallory previously mentioned, it assumed a deep blue color. The deposition of calcium salts within it gave evidence that the process was of long standing. Unlike that of the present case, this substance was deposited in fairly compact tortuous columns; the areas of hyaline transformation frequently corresponded in size to islands of Langerhans, but in many cases had evidently extended beyond their limits; transitions between the epithelial cells and the hyaline substance were not noted. Owing to the poor preservation of the tissue, it was not possible to study the early stages of the condition. It is nevertheless not improbable that the lesions in the two cases are of similar nature.

<sup>8</sup> *Journal of Experimental Medicine*, 1900, v, p. 15.

<sup>9</sup> *Op. cit.*, p. 419.

Varied experiments performed upon the pancreas of animals have conclusively shown that this organ is essential to normal carbohydrate metabolism, and abundant clinical and pathological observation has demonstrated that the conclusions based upon these experiments are applicable to man. In my previous study I have briefly summarized the experimental and clinical evidence which establishes the causal relationship of certain destructive lesions of the pancreas to diabetes mellitus.

Impaired pancreatic function is doubtless not the only cause of diabetes, and in many instances of this disease no alteration of the organ has been demonstrable. On the other hand, diabetes is present in only a limited number of the cases where pancreatic disease has existed. It was the object of my preceding article to show that, where diabetes is caused by a lesion of the pancreas, the lesion is of such a character as to destroy or injure the islands of Langerhans, and that where, though the organ is diseased, diabetes is absent, the interacinar islands are relatively unaffected. In the cases (Nos. XIV and XV) of chronic interacinar pancreatitis, accompanied by diabetes, sclerosis of the organ was so slight that it was definitely recognized only by the microscope, while in instances (Nos. XI and XII) where the lesion followed obstruction of the pancreatic duct, diabetes was absent, though the organ was in great part converted into fibrous or fatty stroma. In the former cases the lesion affected the islands of Langerhans, while in the latter they were spared, though the surrounding secreting tissue was destroyed. In no instance were the islands destroyed, while the secreting structures remained intact.

Structures so embedded as are these islands in the substance of the gland cannot by any means now at our disposal be subjected to experimental alterations without injury to the surrounding alveoli. In the pancreas which has been described in this article, a lesion of obscure etiology has destroyed the cells of the islands of Langerhans, while those of the secreting acini, as well as those of other organs, are unaffected. The most successful experiment could not more accurately have selected these bodies. The association of diabetes mellitus with this lesion affords, I believe, convincing proof of the inferences drawn from the preceding series of cases.

Destruction of the pancreas in animals and in man is accompanied by diabetes; in the present case destruction of the islands of Langerhans has been accompanied by this disease. Since diabetes is absent when, as the result of duct obstruction, the secreting portion of the gland undergoes great alteration, though the islands are spared, the conclusion is justified that it is those structures which influence carbohydrate metabolism. What has been learned concerning the relation of the pancreas to diabetes is the relation of the islands of Langerhans to this disease.

DESCRIPTION OF PLATE XXXIII.

Fig. 1. Drawing made with low magnification (Leitz Oc. 3; Obj. 3) showing hyaline transformation of islands of Langerhans.

Fig. 2. Drawing made with a higher magnification (Leitz Oc. 3; Obj. 6) showing an island whose cells are partly transformed into hyaline material.

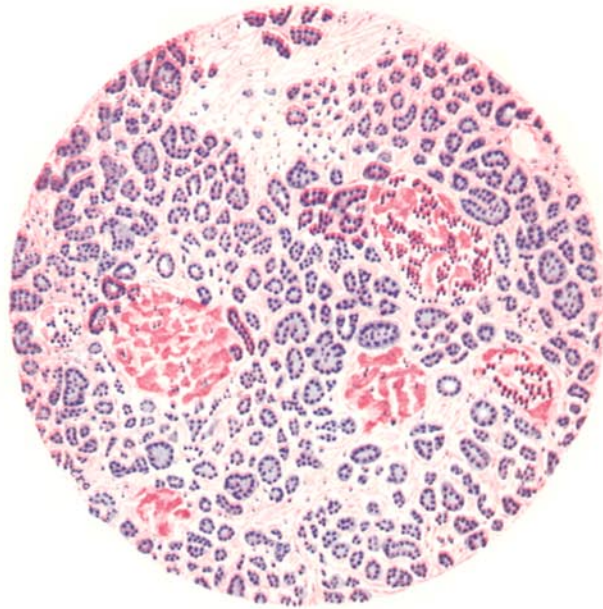


FIG. 1.

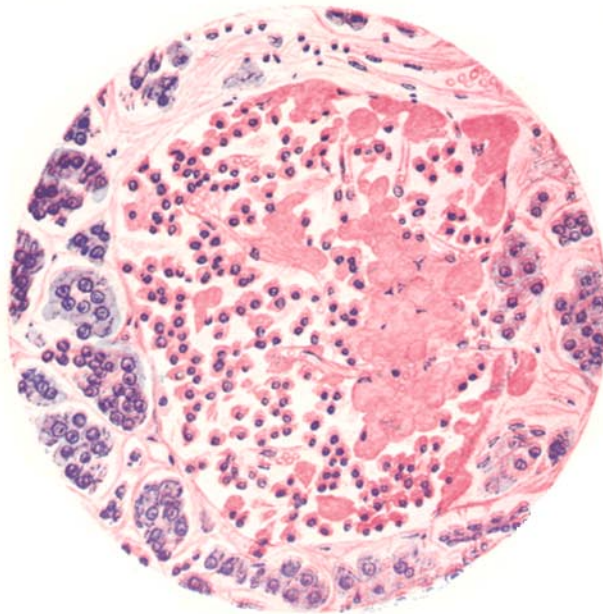


FIG. 2.