

Recent studies have shown that these complements are viable and not altogether very uncommon in man, and the discrepancies observed in the tumours under consideration might be produced by one or more errors of mitosis such as non-disjunction or anaphase lagging of the sex chromosomes at the inception of the tumour or soon afterwards.

In some cases the discrepancy between nuclear sex and inferred sex-chromosome complement of the tumour and of the patient may be more apparent than real. Both Carpentier *et al.* (1956) and Hienz (1961) have described dysgerminomata in chromatin-negative women with ovarian dysgenesis. Hunter and Lennox (1954) described the case of a boy with a chromatin-positive pineal teratoma who was later shown to have chromatin-positive Klinefelter's syndrome (Lennox, 1960), and W. M. Davidson (personal communication 1962) has recently seen a further patient with Klinefelter's syndrome and a chromatin-positive teratoma.

#### Summary

Sex-chromatin discrepancies were found in 8 out of 50 teratomata and 4 out of 49 other embryonic tumours

studied. It is suggested that sex-chromatin discrepancies in these tumours may be the expression of abnormal sex-chromosome complements such as XO, XXY, XY/XXY, produced by one or more errors of mitosis such as non-disjunction or anaphase lagging at or soon after the inception of the tumour.

The work referred to in this communication is part of a Ph.D. thesis approved by the University of London. The study was undertaken in the Department of Morbid Anatomy, Hospital for Sick Children, Great Ormond Street, London. The provision of material and facilities and the encouragement and advice of Dr. Martin Bodian are gratefully acknowledged. I also thank Mr. J. L. Hamerton and Professor P. E. Polani for their advice and constructive criticism.

#### REFERENCES

- Carpentier, P. J., Stolte, L. A. M., and Visschers, G. P. (1956). *Lancet*, **1**, 386.  
 Hienz, H. A. (1961). *Geburtsh. u. Frauenheilk.*, **21**, 144.  
 Hunter, W. F., and Lennox, B. (1954). *Lancet*, **2**, 633.  
 Lennox, B. (1960). *Recent Advances in Pathology*, edited by C. V. Harrison, p. 278. Churchill, London.  
 — (1961). *Die Intersexualität*, edited by C. Overzier, p. 463. Thieme, Stuttgart.  
 Maltzoff, N., and Sacco, O. (1958). *Lav. Ist. Anat. Univ. Perugia*, **18**, 69.  
 Myers, L. M. (1959). *J. Path. Bact.*, **78**, 43.  
 Tavares, A. S. (1955). *Lancet*, **1**, 448.

## BERYLLIOSIS: REPORT OF TWO CASES, WITH SPECIAL REFERENCE TO THE PATCH TEST

BY

G. F. NORRIS, M.B.

Late House-physician and late Medical Registrar, St. Margaret's Hospital, Epping, Essex

MARY C. PEARD, M.B., D.C.H.

[WITH SPECIAL PLATE]

In Germany, in 1933, Weber and Engelhardt published the first description of a disease due to beryllium, and subsequently various papers appeared in European literature, including a report of 46 cases in Russia by Berkovits and Izrael (1940). Van Ordstrand *et al.* (1945) described a chemical pneumonia in workers in Ohio who were extracting beryllium from beryllium ore: since then many cases have been reported in the United States, and the historical, industrial, and clinicopathological features have been fully reviewed by Hardy and Stoeckle (1959) and in a report of the symposium on beryllium disease held at the Massachusetts Institute of Technology in 1958 (Symposium, 1959). In 1952 a beryllium case registry was established at the Massachusetts General Hospital, and by 1958 this contained the records of 601 patients with berylliosis.

The respiratory system is primarily involved in all cases of beryllium disease, and in some the clinical picture is confined to the lungs, when the term "beryllium lung" is used. There may also be evidence of systemic involvement, when, in addition to pathological changes in the lungs, there are lesions in the liver, spleen, lymph nodes, and skin, with alteration in the serum proteins and a raised sedimentation rate. When such systemic disease is present the term "berylliosis" may be used.

Although many papers have been published in the United States describing cases of berylliosis and surveying the industrial environment, relatively few have appeared in the British literature. Agate (1948) published the first account of beryllium disease occurring in this country, and since then other cases have been described by Lederer and Savage (1954), Sneddon (1955,

1958), Rogers (1957), Jordan and Darke (1958), Wood *et al.* (1958), Sita-Lumsden (1959), and McCallum *et al.* (1961). We now describe the cases of two men with beryllium disease who presented with respiratory symptoms in the out-patient department of a general hospital. One of them demonstrates the picture of berylliosis with systemic manifestations as well as pulmonary changes. The other man has chronic beryllium lung disease with the process apparently confined to the lungs.

These patients presented in an interesting manner. The first man (Case 1) was referred to the medical clinic with a history of dyspnoea gradually increasing over the previous 12 months. A radiograph of the chest showed generalized mottling suggestive of tuberculosis or sarcoidosis, and he was admitted for further investigation. As the sedimentation rate was normal and tests for tuberculosis were negative, a provisional diagnosis of sarcoidosis was made; the patient was observed as an out-patient. Shortly afterwards the second man (Case 2) presented with dyspnoea of rapid onset, and a history of recent exposure to beryllium was readily obtained. Radiographs of the lungs showed appearances similar to that seen in the previous patient, and further questioning of the first man revealed that both patients worked in the same factory. The detailed industrial histories were obtained from both men, and subsequently the diagnosis of berylliosis was established. We stress this rather unusual presentation because the first patient might well have remained undiagnosed had not the second man presented at the same time.

#### Case 1

A man aged 41 presented in July, 1959, with a one-year history of dyspnoea on exertion and a history for many

years of a non-productive cough. His shortness of breath on exertion had increased in the previous six months.

**Occupational History.**—From 1932 to 1938 he worked at the coal-face in a pit in South Wales. When aged 20 he first worked annealing alloys in an electric furnace. Metals used were copper, brass, aluminium, and cadmium. When he was 28 his first contact with beryllium was annealing 2% beryllium-copper alloys. For the previous five years he had been in the metal-drawing shop, using this alloy in tube form at 800° C.

On examination he was well covered, plethoric, slightly cyanosed, not clubbed. He was slightly dyspnoeic at rest and more so on exertion. The percussion note was impaired over both upper zones anteriorly, and there was generalized diminution of air entry with scattered rhonchi. All other systems were normal.

On admission chest x-ray examination showed bilateral mottling with denser shadowing in the left upper zone, suggesting fibrosis. A tomogram showed no evidence of cavitation in the left upper zone. General investigations are summarized in Table I. Lung-function studies, kindly performed by Dr. G. Kazantzis at the Department for

Research in Industrial Medicine, London Hospital, are summarized in Table II.

**Progress and Treatment.**—There was no improvement on rest alone and he was given prednisone 20 mg. daily for three months; thereafter the dose was reduced to 10 mg. daily. As there was still doubt about whether there was an underlying tuberculous lesion, isoniazid 300 mg. daily and para-aminosalicylic acid 12 g. daily were given with the steroids and continued for eight months. After 21 days of the above treatment the physical signs in the chest had improved and there was an improvement in exercise tolerance. This was shown in subsequent radiographs.

**Complications.**—Nine months after the beginning of treatment he presented as an acute abdominal emergency with signs of peritonitis. Laparotomy was performed; a gangrenous appendix was found, the offending organ was removed, and the appendicular abscess was drained. The post-operative course was satisfactory and he has since resumed work, his general health being good.

**Case 2**

A man aged 34 presented in August, 1959, with a five-weeks history of shortness of breath on exertion, cough, and minimal mucoid sputum.

**Occupational History.**—In the war years he was a Royal Navy sea-diver (indicating that his pulmonary function was then excellent). In 1950-9 he worked in a foundry using many metals other than beryllium, although in a different part of the same foundry beryllium was in use. His work was changed from use of a gas-burning to that of an oil-burning furnace, and he was then engaged in the manufacture of 2% beryllium-copper alloy. During the time he was at work on the furnace the exhaust ventilation was not in operation. One week after this first contact his symptoms began. His exposure to beryllium lasted less than two weeks. Five weeks later he presented in the out-patient department.

On examination he was obese, with no abnormal signs apart from those in the lungs. The percussion note was impaired and air entry was reduced at both bases with a few crepitations over the lower lobes. Chest x-ray examination on admission showed generalized fine reticulation and mottling, particularly in the middle and lower zone of both lung fields. There was slight hilar lymphadenopathy (Special Plate, Fig. 1). General investigations are summarized in Table I and lung-function studies in Table II.

TABLE I

	Case 1	Case 2
Place of work .. ..	Foundry and metal-drawing shop	Oil-burning furnace
Symptoms .. ..	Increasing dyspnoea on exertion	Increasing dyspnoea on exertion, cough and sputum
Length of exposure to beryllium	13 years	2 weeks
Duration of symptoms	12 months	5 weeks—starting one week after exposure
Sedimentation rate ..	2 mm. in 1 hr. (Wester-gren)	28 rising to 58 mm. in 1 hr.
White-blood-cell count	11,000/c.mm. (polys 52%, lymphs 48%)	5,800 c.mm. (polys 60%, lymphs 40%)
Haemoglobin .. ..	120% (17.8 g./100 ml.)	100% (14.8 g./100 ml.)
Mantoux .. ..	Negative to 100 units	Negative to 10 units. Weakly positive to 100 units
Kveim test (Nelson antigen)	Negative	Negative
Patch test—1% beryllium sulphate	Strongly positive	Strongly positive
Beryllium patch test 3 weeks after starting prednisone	Transient erythematous response	Negative
Sputum .. ..	Negative for A.F.B.	Negative for A.F.B.
Beryllium in urine ..	Nil	0.027 µg./l.

Liver-function tests, serum protein electrophoretic curve, serum calcium and inorganic phosphate, and electrocardiograms were all normal.

TABLE II.—Lung-function Studies

	Case	Predicted Value	1959 Sept.	1960						1961	
				Jan.	Mar.	June	Sept.	Nov.	Dec.	Jan.	June
Subdivisions of lung volume:											
Vital capacity (litres)	1	4.01	3.05	2.85	3.1	3.25	3.25	—	—	2.86	2.71
	2	4.51	2.6	3.1	3.2	3.23	2.55	—	—	2.7	—
Residual volume (litres)	1	2.17	—	—	—	—	—	—	—	2.14	2.33
	2	2.11	—	—	—	—	—	1.06	0.98	0.88	—
Total lung capacity (litres)	1	6.19	—	—	—	—	—	—	—	5.0	5.04
	2	6.63	—	—	—	—	—	4.02	3.84	3.59	—
R.V./T.L.C.%	1	34.8	39	51	37	36	38	—	—	43	46
	2	32	31	35	28	33	25	26	26	24	—
Mechanical function:											
F.E.V. <sub>1</sub> %	1	77-64	59	55	63	58	57	—	—	58	61
	2	79-65	80	85	84	76	81	75	77	77	80
Expiratory peak flow rate (Wright & McKerrow) (litres/min.)	1	542-386	—	337	337	312	262	—	—	274	268
	2	535-383	—	427	427	440	425	413	415	414	—
M.V.V. at 70 r.p.m. (litres/min.)	1	131-78	80	80	63	80	83	—	—	82	77
	2	139-84	120	129	112	126	108	112	117	117	119
Diffusing capacity for carbon monoxide (ml./mm. Hg/min.)	1	28.5	13.5	22.5*	13.5	15	14.5	—	—	16	17
	2	26.4	11	24.5*	16	17.5	13	16.5	13.5	12	13
Prednisone therapy	1		+	+	+	+	+	+	+	+	+
	2		+	+	+	+	+	+	+	+	+

R.V./T.L.C. = Residual volume/total lung capacity, expressed as a percentage. F.E.V.<sub>1</sub>% = Forced expiratory volume in one second, expressed as a percentage of the expiratory forced vital capacity. M.V.V. = Maximum voluntary ventilation at 70 respirations per minute.

\* These results are probably inaccurate.

*Progress.*—During the period of observation and while under investigation his condition deteriorated, his sedimentation rate rising from 28 to 58 mm. in one hour, and at this time his spleen became palpable. Treatment with prednisone 20 mg. daily was begun, after which there was a definite improvement in symptoms and the chest x-ray picture returned to normal (Special Plate, Fig. 2). This improvement was confirmed by the lung-function studies, and within two months he became symptom-free.

As this was considered to be a case of subacute berylliosis the prednisone was tailed off and after nine months was discontinued. Five months later his dyspnoea on exertion had recurred and the sedimentation rate had risen from 18 to 41 mm. Chest x-ray examination at this time showed increased shadowing on both sides, right more than left, and was similar in appearance to when first seen.

Subsequently prednisone was recommenced, and within two weeks he showed symptomatic improvement; two months later his chest x-ray picture was almost clear.

### Beryllium Patch Test

The beryllium patch test was described by Curtis (1951). He used solutions of salts of beryllium (fluoride, chloride, sulphate, and nitrate) and beryllium acetyl acetonate to demonstrate a positive skin response in patients with berylliosis, but obtained negative responses in the controls and when using powdered metallic beryllium or small disks of the metal. Each material, moistened if necessary, was applied as a patch test to the skin for 48 hours and the reaction read at 48 and 72 hours. Biopsy of the skin at the site of the patch test showed intradermal vesiculation, spongiosis, subepidermal oedema, and moderately dense perivascular infiltration with lymphocytes and occasional polymorphonuclear leucocytes.

We would like to give a word of warning from our experience—a very small amount of beryllium sulphate 1% solution on a small piece of gauze is all that is necessary. When first performed by us each square of lint was used well saturated with 1% beryllium sulphate and then bandaged on the forearm. The result was that an erythematous area the size of the bandage was produced. In both cases the patch test was strongly positive (Special Plate, Fig. 3). (Note circumscribed area because too much of the solution was used.) The immediate response was erythematous and nodular. Four weeks after application a skin biopsy was performed and histology was described as follows (Dr. I. Tuck, St. Margaret's Hospital).

*Case 1.*—The skin biopsy shows several early epithelioid follicles in the corium similar to those seen in sarcoidosis. This distribution extends from just beneath the epidermis down to the sweat-gland level. There are no giant cells. Lesions are not yet large enough to produce the central necrosis so often seen in berylliosis.

*Case 2.*—The skin biopsy shows the fully developed features of berylliosis—for example, epithelioid follicles with multinucleate giant cells, the follicles tending to aggregate and to develop central necrosis. The lesions extend from just beneath the epidermis down to the sweat-gland layer, often in a solid mass (Special Plate, Fig. 4).

Repetition of the beryllium patch test during the course of steroid therapy was negative macroscopically and microscopically in Case 2. The repeat patch test in Case 1 showed a transient erythematous response only, and histologically there was no abnormality.

*Skin Reaction in Old Scars.*—In Case 2, on the forearm used for the beryllium patch test, there were old scars from furnace burns which antedated the first exposure to beryllium. The local application of beryllium sulphate solution for the patch test in no way involved these scars, but it was noted that some small nodules had recently appeared in the scar. These nodules were also biopsied but showed no evidence of granulomata.

### Lung-function Studies

*Method.*—Dr. Kazantzis, who carried out the lung-function studies, also commented on the results as below. The predicted normal values for the tests of mechanical function were calculated from the results of a group of 168 normal foundry-workers who were examined by him. The normal values for subdivisions of lung function are those of Needham *et al.* (1954). The functional residual capacity was estimated by the closed-circuit helium-dilution technique of Bates and Christie (1950), and the results were expressed at ambient pressure and room temperature so as to be comparable with the normal values of Needham *et al.* The forced expiratory spirometers and maximum voluntary ventilation at 70 respirations per minute were recorded on a light-weight spirometer of the type described by Bernstein *et al.* (1952). The results represent the means of three separate estimations. The diffusing capacity for carbon monoxide was estimated using the technique described by Ogilvie *et al.* (1957), and the predicted value was based on surface area. The terminology used is that of Gandevia and Hugh-Jones (1957). The results are summarized in Table II.

*Comment.*—In Case 1 there is evidence of increased airway resistance as illustrated by the low F.E.V.<sub>1</sub>%, M.V.V., and expiratory peak flow. In the absence of asthma or chronic bronchitis this increased airway resistance probably indicates emphysema. In addition there is an alveolar-capillary diffusion defect which is typical of berylliosis. In Case 2 the results demonstrate the characteristic diffusion defect. There is no evidence of increased airway resistance, but the total lung capacity and residual volume are low and diminish progressively; these results suggest that there is increasing pulmonary fibrosis.

### Discussion

The diagnosis of beryllium disease of the lungs may be based on a number of criteria—for example, a history of exposure to beryllium, symptoms of increasing dyspnoea with non-productive cough, radiological pulmonary changes which may be indistinguishable from sarcoidosis, a positive beryllium patch test, and, on lung-function studies, evidence of an alveolar-capillary block. In both the above cases these criteria have been fulfilled. There has also been some discussion on the diagnostic importance of demonstrating beryllium in the tissues, either by lung biopsy or on examination of the urine; however, minute amounts of beryllium may be found in the tissues of persons without berylliosis (Hall *et al.*, 1959), and there may be no demonstrable beryllium in the urine of a proved case (Rogers, 1957; McCallum *et al.*, 1961). Thus we do not believe that the absence of beryllium from the urine in one of our cases detracts from the diagnosis.

There is an acute form of beryllium disease in which chemical pneumonitis (Van Ordstrand, 1945) follows a short exposure to beryllium, with rapid onset of pulmonary manifestations and possibly conjunctivitis and

nasopharyngitis. This acute form may terminate rapidly in death, but if the patient recovers it has been said that he may have a better prognosis than in the more usual chronic form of the disease. Unfortunately, while some patients with the acute pulmonary lesion appear to recover spontaneously or progress well with steroids, many will later develop chronic berylliosis, often without further exposure to beryllium. In the Massachusetts Beryllium Registry 39% of cases were acute (Hardy and Stoeckle, 1959), but in recent years the proportion of acute cases has fallen considerably with control of contamination. Case 2 had a short exposure to beryllium fumes with a rapid onset of pulmonary manifestations but had no upper respiratory complications. He had, however, enlargement of the spleen, raised sedimentation rate, and radiological changes of hilar adenopathy, with bilateral hilar and nodular shadowing. He does not fit strictly into the description of the acute form and thus might be regarded as a subacute case of berylliosis. Case 1 shows the more chronic beryllium lung disease without evidence of systemic manifestations. In comparison with the more acute form, it illustrates the variations which can occur both in the duration of exposure and in the interval between the first exposure and onset of symptoms.

Pathologically, berylliosis is a granulomatous process identical with that in sarcoidosis, and Scadding (1960) considers that it may properly be termed "beryllium sarcoidosis." There is non-specific chronic inflammatory infiltration by lymphocytes and plasma cells which accumulate to form the characteristic granulomata. This reaction results in cellular thickening of the alveoli and development of a diffusion block between the alveoli and the capillaries. Like sarcoidosis in its more acute form there may be generalized systemic changes in berylliosis, particularly in the liver, spleen, and skin. In sarcoidosis, granulomatous lesions may appear in old scars (Scadding, 1960), but, in contradistinction in berylliosis, skin lesions seem to occur only where there has been injury to the skin with beryllium-containing material, or contact with the skin as in the beryllium patch test. Although nodules did appear in an old scar in Case 2, these did not show granulomatous change.

As the disease progresses in the lungs, pulmonary function is grossly impaired and cor pulmonale eventually supervenes. Steroid therapy is the only treatment which has been shown to be of any value in influencing the course of the disease. Most cases will show some improvement with steroids, but response is difficult to assess in view of the natural variations in the course of berylliosis.

Nevertheless from the data in the Massachusetts General Hospital Beryllium Registry during 1952-8 Seeler (1959) showed that the mortality was reduced from 39% to 16% with steroid therapy. The response to steroids in our subacute case was more dramatic than in the chronic, but it is of interest to note that after what was a good response subjectively and radiologically there was a relapse when steroids were discontinued, despite the fact that there was no further contact with beryllium. It therefore seems that steroids should be continued, probably indefinitely. In this respect Seeler commented that he had insufficient data to reach definite conclusions on the length of treatment advisable, dosage, and relative merits of continuous or interrupted therapy; but he suggested that most of the failures were due to late commencement or an inadequate course of treat-

ment. Although the subacute case described responded well to steroids clinically and radiologically, improvement in the overall lung-function studies was slight. Some minimal improvement was seen in the diffusing capacity for carbon monoxide, but this deteriorated again when steroids were discontinued. Similar observations were made by Gaensler *et al.* (1959), who also noted that there was no long-term improvement in diffusing capacity but that none of their cases showed serious deterioration during the period of treatment (up to four years).

There is now support for the view that berylliosis is a hypersensitivity response to beryllium, with individual susceptibility (Jordan and Darke, 1958). This hypothesis is supported by the experiments of Curtis (1951), in which he patch-tested the skin with various salts of beryllium and demonstrated that the beryllium ion possessed antigenic capacity. The hypothesis of hypersensitivity would explain why few of the population at risk develop berylliosis and why the disease may manifest itself many years after the last exposure to beryllium. It could explain also why there is no correlation between the amount of beryllium found in the tissues and the development of granulomata (Curtis, 1959). If we accept that this disease is due to hypersensitivity to beryllium, then presumably the positive patch test is an indication of that hypersensitivity, and steroid therapy may be effective by suppressing this reaction. This hypothesis is supported by the findings in these cases where good clinical response was associated with reversion of the patch test to negative. Sneddon (1955) described deterioration in his patient after the application of beryllium to the skin in the patch test, but this was not observed in either of our patients. From our present evidence we would consider the patch test to be a valuable aid to establishing the diagnosis of berylliosis, and regard the repetition of the patch test during treatment with steroids as a useful guide to assessing the suppression of the body's hypersensitive response to beryllium.

#### Summary

We report two cases of beryllium disease in men who presented in the out-patient department of a general hospital. In one man the disease was relatively acute, with short exposure to beryllium, rapid onset and progression of dyspnoea, and evidence of systemic disturbance—that is, he showed the picture of berylliosis closely resembling sarcoidosis. The other man had been exposed to beryllium intermittently for many years, and presented the typical picture of "chronic beryllium lung." The investigation and treatment of these two cases are described. The diagnostic criteria of berylliosis are discussed, including the beryllium patch test; the latter is described in detail and note is made of the reversal to a negative response during steroid therapy. The pathology of berylliosis with its similarity to sarcoidosis is presented. Abnormalities in the lung-function studies are described, particularly the alteration in diffusing capacity for carbon monoxide which illustrates the alveolar capillary block typical of berylliosis. The difficulties in assessing the long-term results of steroid therapy are discussed, but it is concluded that steroids are the only useful means of treatment and may have to be continued indefinitely.

We should like to acknowledge the help and encouragement given by Dr. H. Kopelman, and to thank him for his

permission to publish these cases. We are grateful to Dr. I. Tuck, pathologist, St. Margaret's Hospital, Epping, who performed and reported on the histology. Dr. G. Kazantzis carried out the lung-function studies at the Department for Research in Industrial Medicine, London Hospital, and we are grateful to him and the department for giving us much help. Subsequently the department carried out a clinical and environmental survey in the foundry in which these men worked, and this forms the basis of a separate paper on beryllium disease in Britain (G. Kazantzis, 1960).

## REFERENCES

- Agate, J. N. (1948). *Lancet*, **2**, 530.  
 Bates, D. V., and Christie, R. V. (1950). *Clin. Sci.*, **9**, 17.  
 Berkovits, M., and Izrael, B. (1940). *Klin. Med.*, **18**, 117.  
 Bernstein, L., D'Silva, J. L., and Mendel, D. (1952). *Thorax*, **7**, 255.  
 Curtis, G. H. (1951). *Arch. Derm.*, **64**, 470.  
 — (1959). *Arch. industr. Hlth*, **19**, 150.  
 Gaensler, E. A., et al. (1959). *Ibid.*, **19**, 132.  
 Gandevia, B., and Hugh-Jones, P. (1957). *Thorax*, **12**, 290.  
 Hall, T. C., Wood, C. H., Stoeckle, J. D., and Tepper, L. B. (1959). *Arch. industr. Hlth*, **19**, 100.  
 — and Stoeckle, J. D. (1959). *J. chron. Dis.*, **9**, 152.  
 Jordan, J. W., and Darke, C. S. (1958). *Thorax*, **13**, 69.  
 Kazantzis G. (1960). Proceedings of the 13th International Congress of Occupational Health, New York.  
 Lederer, H., and Savage, J. (1954). *Brit. J. industr. Med.*, **11**, 45.  
 McCallum, R. I., Rannie, I., and Verity, C. (1961). *Ibid.*, **18**, 133.  
 Needham, C. D., Rogan, M. C., and McDonald, I. (1954). *Thorax*, **9**, 313.  
 Ogilvie, C. M., Forster, R. E., Blakemore, W. S., and Morton, J. W. (1957). *J. clin. Invest.*, **36**, 1.  
 Rogers, W. N. (1957). *Lancet*, **2**, 267.  
 Scadding, J. G. (1960). *Brit. med. J.*, **2**, 1617.  
 Seeler, A. O. (1959). *Arch. industr. Hlth*, **19**, 164.  
 Sita-Lumsden, E. G. (1959). *Proc. roy. Soc. Med.*, **52**, 1045.  
 Sneddon, I. B. (1955). *Brit. med. J.*, **1**, 1448.  
 — (1958). *Postgrad. med. J.*, **34**, 262.  
 Symposium on Beryllium Disease (1959). *Arch. industr. Hlth*, **19**, p. 100 et seq.  
 Van Ordstrand, H. S., Hughes, R., De Nardi, J. M., and Carmody, M. G. (1945). *J. Amer. med. Ass.*, **129**, 1084.  
 Weber, H. H., and Engelhardt, W. E. (1933). *Zib. Gewerbehyg.*, **10**, 41.  
 Wood, C. H., Ball, K. P., and Teare, N. D. (1958). *Brit. J. industr. Med.*, **15**, 209.  
 Wright, B. M., and McKerrow, C. B. (1959). *Brit. med. J.*, **2**, 1041.

---

## Medical Memoranda

---

### Cardiac Damage after Radiotherapy

[WITH SPECIAL PLATE]

Since the advent of supervoltage radiotherapy dosage is no longer dependent on skin tolerance and substantial doses are being delivered to structures at a depth. A programme of preoperative irradiation for bronchogenic carcinoma was instituted at Green Lane Hospital, Auckland, in 1961, following the report of Bloedorn and Cowley (1960), the field including the mediastinum. Surgery has been deferred a further two months because of the increased risk of bronchus stump fistula in the early weeks after radiotherapy as reported by Bromley and Szur (1955).

Thus far we have not encountered symptoms of cardiac disturbance during the course of radiotherapy nor in the waiting period, but the following case history records a fatal complication of surgery believed to be the result of myocardial damage from radiation.

### CASE REPORT

A man aged 62 presented with a nine-months history of a persisting cough after an influenza-like illness. His chest x-ray film showed collapse of the right lower lobe. Sputum cytology was positive for neoplastic cells, and a biopsy taken at bronchoscopy from a tumour in the right-lower-lobe bronchus was reported as undifferentiated squamous-cell carcinoma.

An estimated tumour dose of 4,800 r was delivered by daily fractions over four weeks, using supervoltage therapy (4 MeV). The field (Special Plate, Fig. 1) was mainly vertical with the patient supine. It is estimated that the portion of myocardium in the field would receive between 4,000 r posteriorly and 5,250 r anteriorly. The patient had some anorexia for a start, but there were no other ill effects. No electrocardiogram was taken during his course of radiotherapy nor in the two months prior to surgery. On the day before his operation he was walked up six flights of stairs and was noticeably less breathless than the attendant house-surgeon.

*Operation.*—Numerous fresh pleural adhesions were found on opening the chest, and in proximity to the pericardium they were oedematous to the extent of containing loculated fluid. Hard glands could be palpated in the subcarinal region, and it was decided that a radical intrapericardial pneumonectomy should be performed. The pericardium was opened in front of the lung hilum. The pericardial space was free over the right atrium but obliterated posteriorly by adhesions. As the posterior aspect of the pulmonary veins was being freed by gentle dissection there was a sudden gush of dark blood from a tear on the anterior aspect of the interatrial groove into the right atrium. A large swab was pressed over the area to control the bleeding, but this tore open the entire interatrial groove. The situation was irretrievable.

The heart was quite flabby in appearance and felt grossly abnormal. A coroner's necropsy was performed, the pathologist's report being as follows. "Blocks of tissue were examined from various areas in the myocardium. The changes seen were present in all but were of varying severity. The muscle fibres showed patchy degenerative changes, including fibre swelling, with eosinophilia of cytoplasm, granularity, and vacuolation. A few focal areas of necrosis were seen (Special Plate, Fig. 2). Inflammation was negligible. Blood-vessels showed variable lesions. Endothelial and fibroblastic proliferation was evident in some (Special Plate, Fig. 3), while others were affected by fibrinoid necrosis. No occlusive lesions were seen. Sections from the main coronary arteries showed moderately severe atheroma, but in addition the media and adventitia were quite densely infiltrated by lymphocytes and macrophages. The pericardium was thickened, due to deposition of hyaline collagen, and was also infiltrated by chronic inflammatory cells. The lesions described are attributed to irradiation effects."

### COMMENT

The techniques used in modern supervoltage therapy are by no means uniform. The use of a single vertical field as in this case has the advantage of accurate delivery of a maximum tumour-dose. The field is sharply defined and radiation scatter is minimal. Nevertheless a portion of the heart in this field will be receiving a dose of from 4,000 to 6,000 r.

### Electrocardiography

Several authors have reported arrhythmias and T-wave changes in the electrocardiogram of patients receiving radiation for intrathoracic neoplasms, but opinion is divided regarding their interpretation. Leach (1943) considered the E.C.G. changes to be positional and not the result of myocardial disease. Whitfield and

G. F. NORRIS AND MARY C. PEARD: BERYLLIOSIS

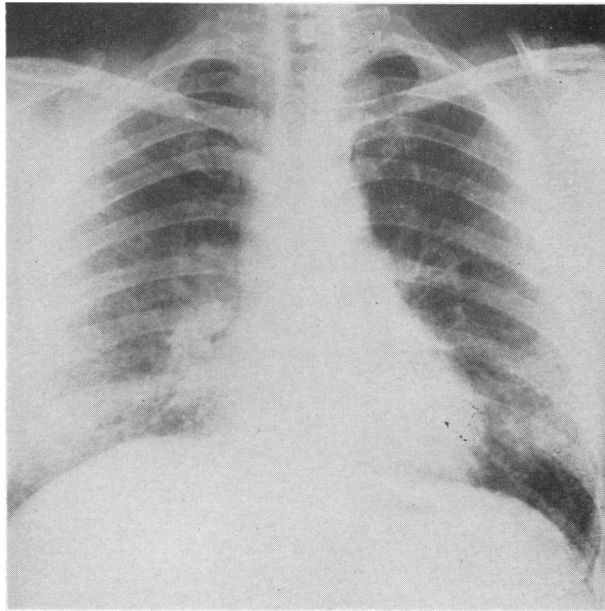


FIG. 1.—Case 2. Radiograph of chest, August, 1959, before treatment, showing extensive bilateral miliary and fine nodular shadowing.

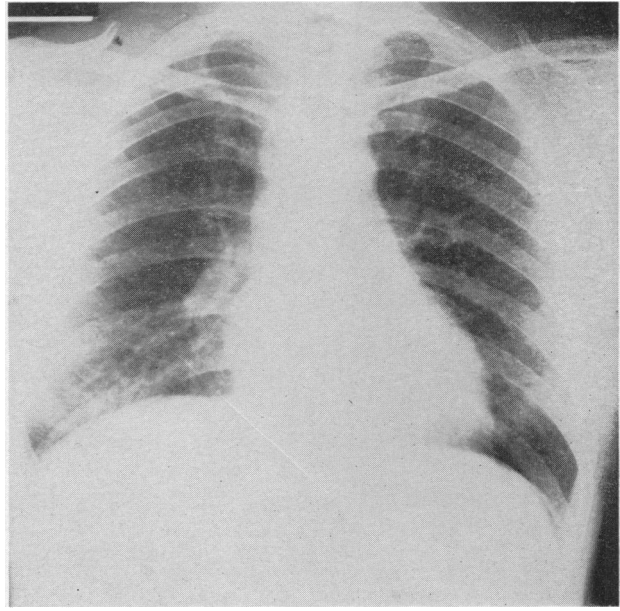


FIG. 2.—Case 2. Radiograph of chest, December, 1959, after four months' treatment with prednisone.

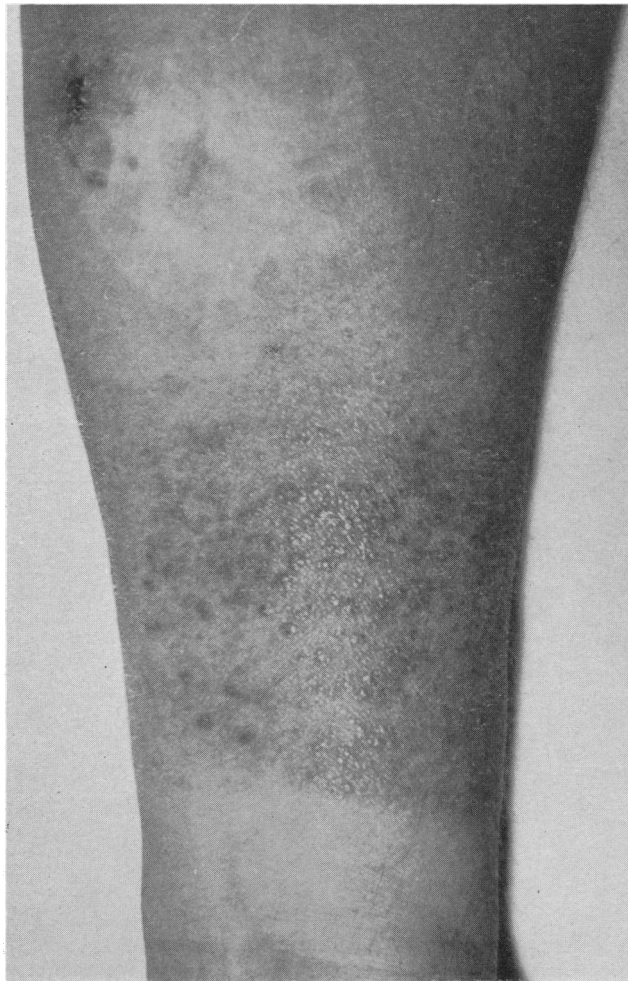

FIG. 3.—Case 2. Forearm, showing strongly positive reaction to beryllium patch test, and burn scar above with nodules and biopsy scar.

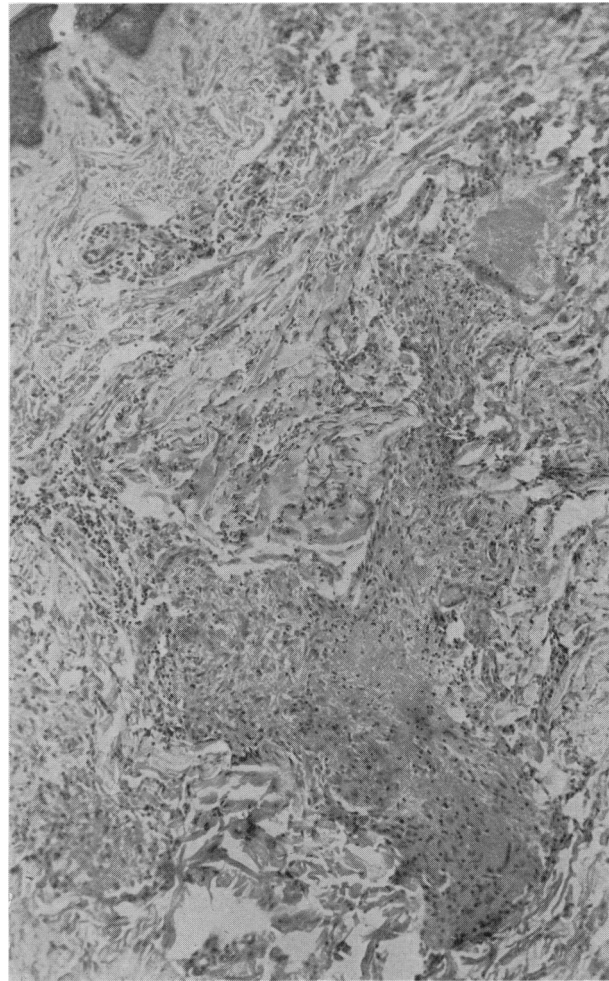


FIG. 4.—Case 2. Histology of beryllium patch test showing granulomatous reaction (see text).