

NEUROCYTOMA OR NEUROBLASTOMA, A KIND OF TUMOR NOT GENERALLY RECOGNIZED.¹

BY JAMES HOMER WRIGHT, M.D., S.D.

*Director of the Pathological Laboratory, Massachusetts General Hospital, and
Assistant Professor of Pathology, Harvard Medical School, Boston.*

PLATES XLIV-XLVI.

The object of this paper is to call attention to a group of tumors, the nature of which has hitherto escaped general recognition, and to point out their distinguishing characteristics. These tumors are rich in cells which may vary much in size and shape. They may be pervaded by connective tissue by which the cells are arranged in more or less definite alveoli. Blood vessels accompanied by connective tissue are also present. The essential cells of the tumor are considered to be more or less undifferentiated nerve cells or neurocytes or neuroblasts, and hence the names neurocytoma and neuroblastoma. They are considered to be neurocytes or neuroblasts for the following reasons:

1. The cells, at least in places, are associated with delicate fibrils, often of considerable length, which do not stain like neuroglia, collagen or fibroglia fibrils by Mallory's methods, and which are like the fibrils occurring in the "anlage" of the sympathetic nervous system.

2. The cells associated with these fibrils have the same morphology as the cells from which the sympathetic nervous system and the medulla of the adrenal develop, and which are regarded by embryologists as arising from migrated primitive nerve cells. They are generally small, with round nuclei rich in chromatin, and have a relatively small or imperceptible amount of cytoplasm. Some of them may be of piroform shape and their cytoplasm may be prolonged into filamentous processes like the fibrils referred to above.

3. The cells and fibrils are arranged in places in ways more or

¹Received for publication May 19, 1910.

less like the ways in which the neurocytes and fibrils are arranged, both in the sympathetic nervous system at certain periods of its development and in the "anlage" of the adrenal.

Thus the fibrils may be arranged parallel to one another in bundles which are intimately associated with masses of the cells, as are the fibrils with the neurocytes in the "anlage" of the adrenal of a human fetus in the fourth or fifth month (compare Fig. 11 with Fig. 12). Moreover, the bundles of fibrils may extend into masses of the tumor cells as do the fibrils into the mass of neurocytes constituting the "anlage" of a sympathetic ganglion. The connective tissue stroma may more or less completely demarcate masses of cells with their associated bundles of fibrils and such masses of cells and fibrils may be very like the sympathetic ganglia of a human embryo of about the sixth week. This will be clear by comparison of Figs. 1, 2, 9 and 10 with Figs. 3 and 8.

Another mode of arrangement of the cells and fibrils is that of ball-like aggregations about forty micra or more in diameter, enclosing a small mesh-work of fibrils and of filamentous processes of the cells which do not stain like neuroglia or connective tissue fibrils by Mallory's specific staining methods. If the section passes through the equatorial plane of one of these ball-like cell masses, it appears as a circular mass formed of one or more rows of cells surrounding a central mass of fibrils and filamentous cell processes. These have been called "rosettes." These ball-like aggregations are like the ball-like aggregations of neurocytes, both in morphology and staining reactions, which occur in the sympathetic ganglia and in the adrenal as well as in the connective tissue about these structures at certain periods of fetal life (compare Fig. 4 with Figs. 5, 6 and 7).

The characteristic fibrils of these tumors may be present only in restricted areas of the tumor tissue. By degeneration or post-mortem changes they may become more or less transformed into hyaline or granular material and thus escape recognition. This is especially true of the fibrils in the central parts of the "balls" of cells, both of the tumor and of the fetus.

Thus two characteristic modes of arrangement of the cells and fibrils may be distinguished, namely, the arrangement of the fibrils

in bundles associated with masses of the cells and the ball-like formations above described. Both modes of arrangement are not found in every case.

The cases of tumor formation of the nature here described, which I have personally observed or have been able to recognize in the literature, may be summarized as follows:

CASE I. Reported by N. Dalton (1). Tumors of liver and left adrenal in a male child, 6 weeks old. From the description and drawing of the microscopical appearances of the adrenal tumor, it is plain that the characteristic ball-like arrangement of the cells and fibrils were present. Thus the author states that the small cells "are mingled with a peculiar, finely granular and, in places, perhaps slightly fibrillated substance." "In some places the round cells are scattered uniformly through this material. In others, they are arranged around the borders of a small mass of it, something like the nuclei of a giant cell." "This material is stained deeply by picro-carmin and may possibly be the degenerated reticulum of a lymphomatous growth."

CASE II. Reported by F. Marchand (2). Tumor of right adrenal in a female child, 9 months old. The tumor is described as consisting of a tissue like that of the "anlage" of a sympathetic ganglion, and drawings accompanying the paper confirm the description. This is the first time that the true nature of a tumor of this kind was recognized.

CASE III. Reported by S. Amberg (3). Tumors of both adrenals and of liver in a female child, 2 months old. The author's description leaves little doubt that the tumor tissue showed the ball-like aggregations of tumor cells with hyaline transformation of the central fibrils, but their significance was apparently not recognized. He noted, however, a striking resemblance of the tumor cells to the cells in the medulla of the adrenal of a six month fetus.

CASE IV. Reported by H. Küster (4). Tumors of both adrenals and of liver in a child 14 weeks old, sex not given.

CASE V. Reported by H. Küster (4). Tumor of adrenal in an adult male. The tumors in this and the preceding case contained the characteristic ball-like aggregations of the cells and fibrils. They were regarded by the reporter and by Prof. Ribbert as closely allied to glioma. J. Wiesel (5), however, later pointed out that in his opinion the tumors were composed of undifferentiated cells of the sympathetic nervous system, which he had shown to invade regularly the "anlage" of the adrenal and to give rise to the chromatin cells and ganglion cells of the medulla of that organ.

CASE VI. Reported by O. Richards (6). Tumors of the adrenal and liver in a male child, 2 weeks old. The tumor was described as a small, round cell sarcoma. The author states that "In part the cells of the tumor are arranged around the edges of small masses of homogeneous substance of uncertain nature." From this description it seems right to infer that the tumor showed the characteristic ball-like arrangement of the cells enclosing hyaline degenerated central fibrils.

CASE VII. Reported by A. Lapointe and P. Lecène (7). Tumors of right adrenal, retro-peritoneal tissue and mediastinum in a female child, 19 months old.

The tumor was regarded by the reporters as a glioma. This diagnosis was also made by Prof. Ribbert, who examined some of their preparations. Their drawings and description of the cells and fibrils show beyond reasonable doubt that the tumors belong to the group here described.

CASE VIII. Reported by W. Tileston and S. B. Wolbach (8). Tumors of right adrenal and in cranium, involving adjacent soft tissue and lymph nodes in a male child, 16 months old. For material from this case I am indebted to Dr. Wolbach. The ball-like arrangement of the cells and fibrils is a prominent feature of the tumor tissue which was considered to be of a lymphomatous nature (Fig. 4).

CASE IX. Tumors of both adrenals in a still-born male child. I am indebted to Dr. S. R. Haythorne for preparations from this case and for permission to refer to it here. The microscopical characters of the tumor tissue are shown in Fig. 11 (compare Fig. 12).

CASE X. Large tumor in hilum of lung and multiple tumors in liver in a male adult. (I am indebted to Dr. R. Kinnicutt for this case. The characteristic fibrils are found only in the tumor of the lung and only in places in it. (The most characteristic area is shown in Fig. 2.) The cells of this tumor are very variable in size, some of them being very large. At one place they are of columnar shape and disposed radially about blood vessels or about lumen-like spaces.

CASE XI. Tumor of the cerebellum. This was removed at operation by Dr. Harvey W. Cushing, to whom I am indebted for permission to refer to it here. I am also indebted to Dr. F. B. Mallory for calling it to my attention and for the opportunity of examining microscopical preparations from it. The tumor tissue shows the characteristic ball-like arrangement of cells and fibrils in places.

CASE XII. Multiple tumors of skull, mediastina, retro-peritoneal tissue with involvement of pelvis, liver, and some other situations in a female child, 16 months old. (Autopsy No. 227, Massachusetts General Hospital. The tumor tissue in this case presents in places the appearance of being composed of aggregations of more or less atypical embryonic or fetal sympathetic ganglia bound together by connective tissue stroma (Figs. 1, 9 and 10). The tumor tissue in the skull contains considerable bone in the stroma and the masses of cells often enclose or border upon cystic cavities.

I have also seen microscopical preparations of two other cases of small-cell tumor of the head, which clearly show the ball-like arrangement of the cells and fibrils.

The occurrence of these tumors in such a variety of situations is accounted for not only by metastasis but also by the generally accepted teaching that undifferentiated nerve cells migrate from the embryonic central nervous system to form the nerves and ganglia as well as the sympathetic system. Therefore, theoretically, these tumors may occur in any region of the body. Their occurrence in the adrenal is explained by the now generally accepted doctrine of the invasion of the "anlage" of the cortex of that organ by undif-

ferentiated cells of the sympathetic nervous system, or so-called formative cells of the sympathetic, to form the cells of the medulla, as was first clearly shown by J. Wiesel (9). This doctrine also accounts for the apparent medullary origin of some of the tumors. The involvement of the adrenal in such a large proportion of the cases, with simultaneous involvement of the liver or of the cranium, in some cases, strongly supports the belief that other small-cell tumors of the adrenal that have been reported in man and the ox, and other cases of simultaneous small-cell tumor involvement of the adrenal and liver or cranium among those collected and reported by R. Hutchinson (11), by W. Pepper (10) and by W. Tileston and S. B. Wolbach (8), are also cases of neurocytoma in which the characteristic fibrils have not developed or have been overlooked. Essentially the same view for the simultaneous sarcomas of the adrenal and liver was expressed by R. Kretz (12) some years ago, when he suggested that such tumors came from the formative cells of the sympathetic system.

Moreover, it seems reasonable to believe that certain other small-cell tumors without the characteristic fibrils, occurring in various situations, are also of this nature.

The fact that five of the new cases have been recognized within a year seems to show that neurocytoma is not a very rare tumor and that tumors of this kind will be found to constitute an important group among the tumors now called glioma, sarcoma, lymphoma or lymphosarcoma.

BIBLIOGRAPHY.

1. *Trans. of the Path. Soc. of London*, 1885, xxxvi, 247.
2. *Festschr.*, R. Virchow, Berlin, 1891, 578.
3. *Arch. of Pediat.*, 1904, vi, 582.
4. *Virchow's Arch.*, 1905, clxxx, 117.
5. *Virchow's Arch.*, 1905, clxxx, 553.
6. *Guy's Hospital Reports*, 1905, lix, 328.
7. *Arch. de méd. expér.*, 1907, ix, 69.
8. *American Jour. of the Med. Sciences*, 1908, cxxxv, 871.
9. *Anat. Hefte*, Abt. I., 1901, xvi, 115; 1902, xix, 481.
10. *American Jour. of the Med. Sciences*, 1901, cxxi, 287.
11. *Quart. Jour. of Med.*, 1907, i, 33.
12. *Ergebn. der allg. Path. u. path. Anat.*, 1902, viii,² 532.

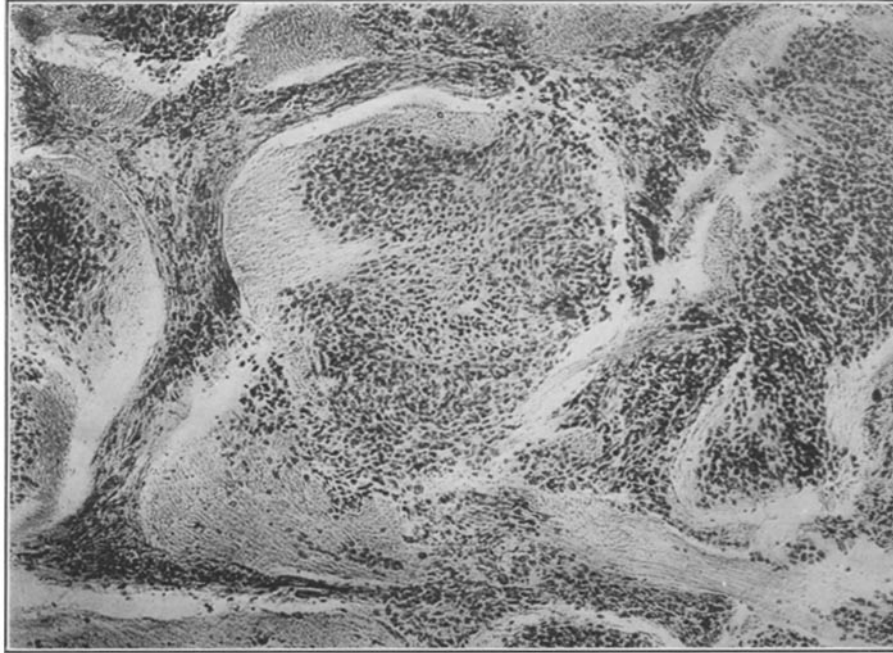


FIG. 1.

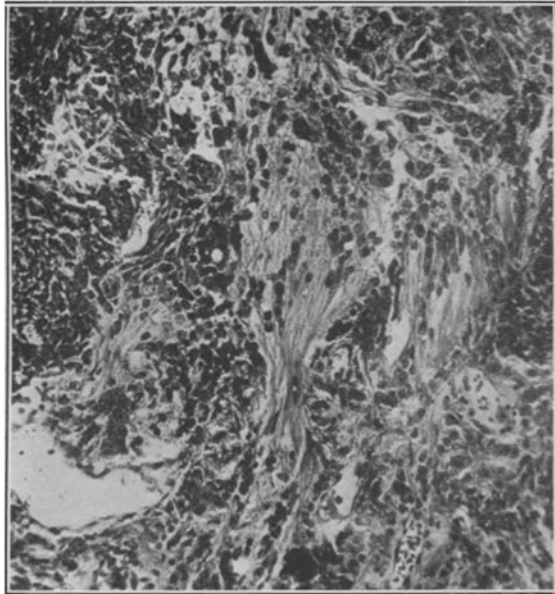


FIG. 2.

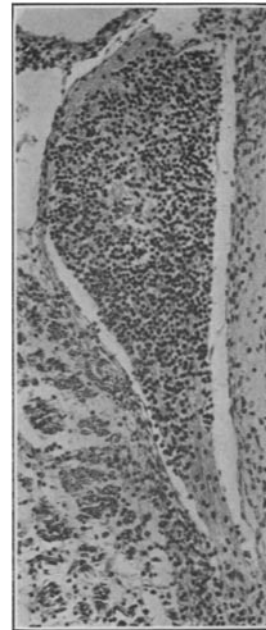


FIG. 3.

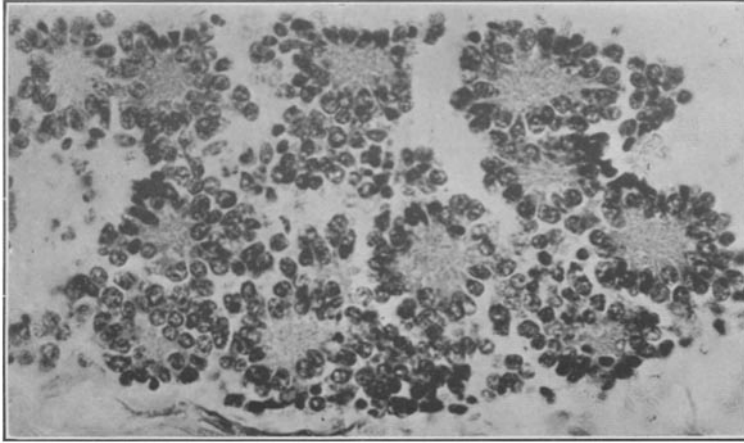


FIG. 4.

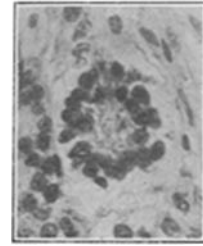


FIG. 5.

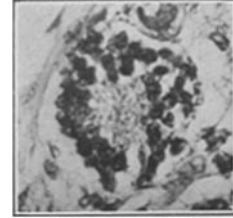


FIG. 6.

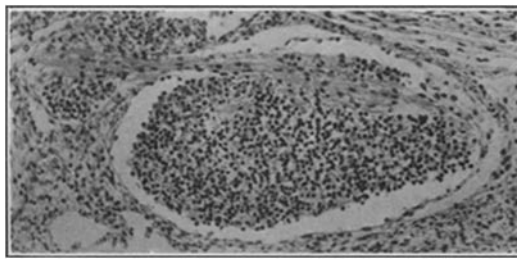


FIG. 8.

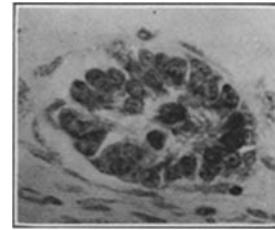


FIG. 7.

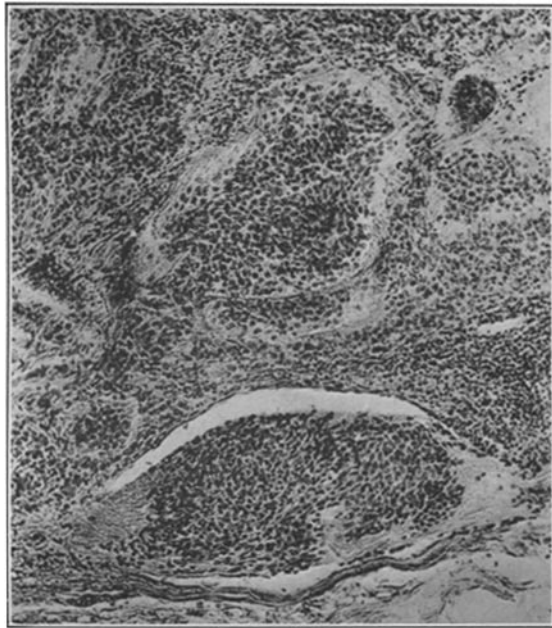


FIG. 9.

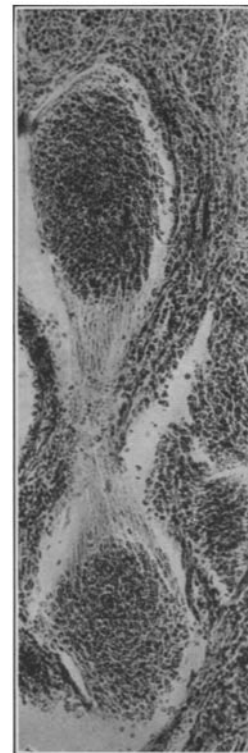


FIG. 10.

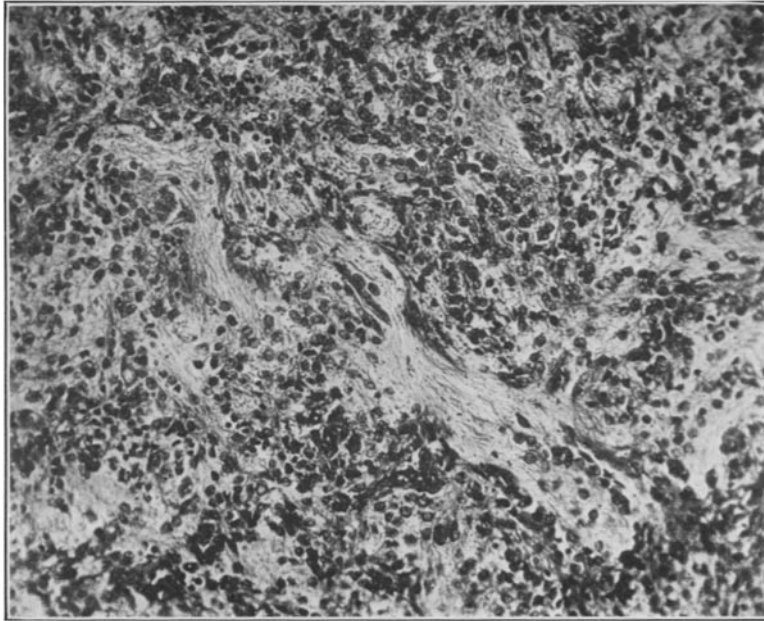


FIG. 11.

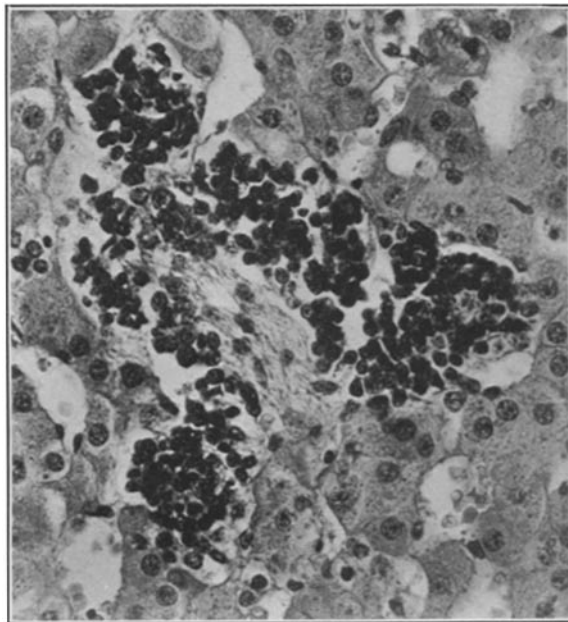


FIG. 12.

EXPLANATION OF PLATES.²

PLATE XLIV.

FIG. 1. A characteristic area in the metastasis of a tumor in a lymph node of Case XII, showing the arrangement of the fibrils in bundles associated with masses of small cells.

FIG. 2. A characteristic area in the tumor of the lung of Case X, showing the fibrils arranged in bundles as in the embryonic sympathetic ganglion.

FIG. 3. "Anlage" of a sympathetic ganglion of a human embryo of about the sixth week, showing the arrangement of the cells and fibrils.

PLATE XLV.

FIG. 4. An area in the tumor of Case VII, showing the characteristic ball-like arrangement of the cells. The fibrils in the centers of the cell balls are obscure, probably from degenerative changes in them. Some of the cells are of piroform shape and some of the fibrils may be seen to be processes of the cells.

FIGS. 5, 6 and 7. Showing the ball-like aggregations of neurocytes enclosing the fibrils in their central portions in the "anlage" of the human adrenal or in the connective tissue about it. Fig. 7 shows the piroform shape of the cells and their fibril-like processes.

FIG. 8. "Anlage" of a sympathetic ganglion of a human embryo of about the sixth week showing the arrangement of the cells and fibrils.

FIGS. 9 and 10. Characteristic areas in metastases in lymph nodes of Case XII. Showing the resemblance of some of the masses of cells and bundles of fibrils and associated bundles of fibrils to the "anlage" of a human sympathetic ganglion (compare Fig. 8).

PLATE XLVI.

FIG. 11. Characteristic area in the tumor of the adrenal of Case 9, showing arrangement of the fibrils in bundles (compare Fig. 12).

FIG. 12. A mass of Neurocytes with an associated bundle of fibrils in the "anlage" of the adrenal cortex of a human fetus of about the fifth month.

² Photomicrographs by Mr. L. S. Brown, Pathological Laboratory, Massachusetts General Hospital.