

# EXPERIMENTAL YAWS IN THE MONKEY AND RABBIT.<sup>1</sup>

By HENRY J. NICHOLS.

*Captain, Medical Corps, U. S. A.*

*(From the Laboratories of the Rockefeller Institute for Medical Research, New York.)*

PLATES LIII AND LIV.

## INTRODUCTION.

Yaws or frambesia has always been of particular interest on account of its possible relation to syphilis, and since the discovery of its cause it has been studied with renewed activity. The discovery of *Treponema pertenui*, by Castellani (1) in 1905, was a direct sequel to Schaudinn's work on syphilis, and both Schaudinn and Castellani considered the organisms of the two diseases morphologically identical. More recently, minute differences in form have been pointed out by Prowazek (2) and Russell (3); but whether or not they are to be accepted as sufficient for differentiation, there is no doubt, on the basis of immunity experiments on monkeys (4) and man (5), that the two diseases are distinct. In Castellani's words, "Yaws is not syphilis any more than leprosy is tuberculosis."

In the recent study of syphilis, a great advance has been made by Parodi (6) and Uhlenhuth and Mulzer (7), who have demonstrated the possibility of producing a syphiloma in the testicle of the rabbit. As Uhlenhuth and Mulzer say, this lesion gives us a convenient and rich source of spirochetæ, in pure culture, with which cultivation and immunity experiments can be carried out.

Several months ago, I undertook some work on syphilis in the rabbit's testicle and, as a case of yaws was under my observation

<sup>1</sup>Read (by invitation) at the annual meeting of the American Society of Pathologists and Bacteriologists, Washington, D. C., May 5, 1910. Received for publication June 1, 1910.

at the time, I thought it worth while to attempt to infect rabbits with the spirochetæ of yaws as well as with those of syphilis. This attempt has been successful and I have been able to observe a parallel series of infections.

The spirochetæ of yaws came from a colored soldier returning from the Philippines (8). This soldier, forty years of age, had a well-marked case of yaws consisting of three separate general eruptions and marked joint symptoms. Spirochetæ in small numbers were found in the serum from the yaws on two occasions with the dark field microscope (Plate LIII, Fig. 1).

#### EXPERIMENTS.

On Dec. 17, 1909, a monkey (*Macacus rhesus* 1) was inoculated by rubbing an excised piece of a yaw into an abraded surface of the right eyebrow. The abrasion healed completely in a few days. On Jan. 7, 1910, 24 days after inoculation, a red and slightly scaly patch was noticed on the right eyebrow, and in a few days a well-marked red and edematous ridge of tissue developed. Spirochetæ in small numbers were repeatedly found in fluid expressed from this lesion. The growth invaded the upper eyelid, ulcerated, and on Feb. 2 showed a typical yellow crust formed by the rich serous discharge from fungoid granulations (Plate LIV, Fig. 2).

Three rabbits were inoculated in the testicle with serum from the lesion in the monkey. All became infected as follows: Jan. 27, the unbroken surface of the edge of the monkey's yaw was slightly abraded, a drop of clear serum was expressed, taken up in a capillary pipette and expelled by air pressure into the substance of the right testicle of a large white rabbit, A. Weekly examinations were made and no change was noticed until Feb. 24, 28 days after inoculation, when the right testicle was found uniformly increased in size so that it could not be retracted; it was firm throughout but more resistant at the upper part. On Feb. 25, the resistant area was punctured with a sterile capillary pipette and a drop of clear gray fluid obtained which, under the dark field microscope, showed a great number of long active spirochetæ of the *pertenuis* or *pallida* type. The second rabbit, A', inoculated in the same way, showed an enlarged testicle containing a small round nodule rich in spirochetæ after 43 days. The third rabbit, C, became infected after 52 days.

With material from the first rabbit, A, the disease was *reproduced in the monkey and continued in a second generation in rabbits.*

March 9, a drop of serum from the testicle of Rabbit A, rich in spirochetæ, was rubbed into the eyebrow of a monkey (*Macacus rhesus* 2). In 16 days a red papular area appeared and soon became markedly elevated, edematous and slightly scaly. Spirochetæ were readily found in the expressed fluid.

Feb. 25, 8 rabbits were inoculated with fluid from the testicle of Rabbit A; 3 with undiluted fluid and 5 with fluid diluted with 3 parts of salt solution. One of the 5 died after 14 days of rabbit septicemia, and there was no change

in the testicle and no spirochetæ were found. Two of the rabbits inoculated with undiluted fluid developed lesions rich in organisms 32 and 42 days after inoculation. One of the 4 remaining showed an infection after 52 days. All these rabbits were undersized and gray or brown.

For the third generation larger animals were selected. March 29, 2 large white rabbits were inoculated in the right testicle by syringe with about .5 c.c. of a mixture of about 3 parts of salt solution and one part of fluid from a nodule in the testicle of Rabbit 7 (second generation). April 18, after 20 days, one showed an enlarged testicle with a distinct nodule very rich in active spirochetæ. April 22, after 24 days, the other showed the same. March 31, Rabbit 7, of the second generation, was castrated under ether anesthesia; a white edematous tumor was found occupying the middle of the testicle. Small pieces of this tumor were introduced in the testicles of 4 large brown rabbits with a trochar and canula; on April 22, after 22 days, Rabbit 14 showed a definite nodule rich in spirochetæ. Two other animals, Nos. 15 and 17, showed lesions after 36 and 22 days.

Thus the spirochetæ of yaws have been transferred from man to the monkey and from the monkey through three generations in rabbits. Eight out of sixteen rabbits used in this series have become infected. The incubation period averaged forty-one days in the first generation, forty and a half days in the second generation and twenty-four and eight-tenths days in the third generation, thus showing a shortening of sixteen days in the third passage. The series is being continued and, by using care in the selection of animals, can probably be continued indefinitely. Large animals are more suitable than small and in case of both syphilis and yaws the order of susceptibility seems to be white, gray, brown and black. I do not know yet which is the best medium for transfer, undiluted serum, salt solution, citrate solution or the bits of tissue: all have been successful. Inoculation in the anterior chamber of the eye has as yet failed of results. In tapping the testicle, if the point of a moderately strong capillary pipette is guided into the nodule, spirochetæ, in pure culture, can be obtained in myriads; in the testicle away from the nodule they are found in small numbers. They are readily stained by Giemsa's method (Plate LIV, Fig. 3). The dark field microscope is almost indispensable in handling a large number of animals. Swelling of the testicle and edema of the tunica vaginalis may result from frequent tapplings, but no mixed infections of the testicles have occurred. The general health of the rabbits does not seem to suffer.

*The Lesion of Yaws in the Rabbit's Testicle.*—Three rabbits were castrated, under ether, thirty-four, forty-eight and sixty days after inoculation and the tissue used for histological study. If the testicle is examined soon after a nodule is palpable, the nodule is found to be a whitish edematous tumor fairly well differentiated from the rest of the testicle which appears normal. On incision, the edges of the growth roll back and a good deal of serum escapes. The tissue appears homogeneous. Sections show a picture of an interstitial orchitis; the tubules are small, disintegrating or replaced by an edematous connective tissue containing an infiltration of small round and endothelial cells. New polymorphonuclear cells are seen. In sections stained by Levaditi's method spirochetæ are found in large numbers in and around the tubules and in the interstices of the connective tissue (Plate LIV, Fig. 4). In the testicles examined after forty-eight days the infiltrating cells had for the most part disappeared and after sixty days the connective tissue was more fully organized and no spirochetæ were found. Repeated tapping of these testicles may have somewhat changed the natural history of the lesions but apparently the lesion resolves in time, leaving an atrophied organ.

*Serum Reactions.*—The complement fixation reaction has been tried on the yaws rabbits and has been positive in several cases.

1 c.c. of serum heated at 56° C. for 15 minutes, acetone insoluble liver extract as antigen, and the human corpuscle and rabbit serum hemolytic system were used.

White Rabbit No. 6, second generation. Feb. 25, inoculated with undiluted serum from Rabbit A. March 1, serum negative; April 8, nodule palpable (42 days), spirochetæ present; April 9, serum negative; April 19, serum positive (53 days).

In the second case a positive reaction led to a reëxamination and the finding of spirochetæ.

Gray Rabbit No. 3. Feb. 25, inoculated with diluted serum from Rabbit A. Serum negative; April 18, testicle increased in size; no definite nodule (52 days); April 19, spirochetæ not found in one slide with dark field microscope; April 20, serum taken on April 19, positive, April 21, spirochetæ found (55 days).

The patient's blood was negative on four examinations, November 20, December 14, February 23 and March 15, after the second and third eruptions and after treatment with potassium iodide. Both monkeys have failed as yet to give the reaction. There are

two examples of the reaction in yaws on record, in both of which it was positive. Bruck (9) gives the case of a thirty-year-old Malayan who had yaws five years before. Hoffman (10) records a case of a native of Suaheliland with a positive reaction at the time of the eruption. The diagnosis was doubted by Ziemann. If, as seems probable, this reaction is not a specific immunity reaction, but rather a result of the breaking down of certain kinds of tissue, a good deal may possibly be learned from the study of the reaction in closed lesions in such a specialized organ as the testicle.

*Syphilis in the Rabbit's Testicle.*—A comparison of yaws with syphilis in the rabbit brings out several points of importance. January 27, a patient with mucous patches of the mouth and anus, untreated for three months, and with a clear history of a primary sore and a secondary eruption, was secured through the kindness of Dr. Seay. A patch on the lower lip was cleaned, aspirated with a suction apparatus and a few drops of serum containing numerous spirochetæ was injected with a capillary pipette into the left testicle of five large rabbits.

Feb. 28, testicle of Rabbit E enlarged; cannot be retracted; nodule felt; spirochetæ numerous (32 days).

Two other rabbits showed infection after 35 and 56 days.

Jan. 31, 5 rabbits inoculated from mucous patch; 2 were infected after 45 and 64 days. One of these rabbits is especially interesting as the infection travelled over to the uninoculated testicle and the Wassermann reaction appeared, disappeared and reappeared.

Jan. 31, large gray rabbit, G, inoculated right testicle from mucous patch; March 17, nodule felt in epididymis (46 days); March 18, spirochetæ present; March 19, castrated, circumscribed syphiloma size of an olive involving epididymis and testicle. March 29, serum positive, .50 and .15 c.c.; March 30, left testicle slightly enlarged, punctured, spirochetæ not found. April 4, serum negative, 1 c.c.; April 8, left testicle punctured, spirochetæ not found; April 9, serum negative, .1 c.c.; April 11, left testicle punctured, spirochetæ not found; April 15, left testicle: small nodule, spirochetæ not found; serum positive, .1 c.c., 29 days after appearance of lesion in *inoculated* testicle. April 22, left testicle; definite nodule in epididymis, *spirocheta plentiful*.

The route of infection in this case was probably by the lymphatics, but may have been by the blood, as Truffi (11) has recorded an infection of the anterior chamber of the eye following an inoculation of the scrotum. One of the yaws rabbits has also shown this migration of spirochetæ to the opposite testicle; the lesion developed thirty days after castration of the inoculated testicle.

*Treponema pallidum* has also been carried through a second and third generation in rabbits.

March 9, grey rabbit, Q, inoculated left testicle, with serum from testicle of Rabbit E (first generation); April 14, nodule in testicle (36 days); April 15, spirochetæ present, April 15, serum positive, .1 c.c.; March 8, white rabbit, L, inoculated with serum from testicle of Rabbit G (first generation) in 2 per cent. citrate solution; April 15, testicle enlarged, nodule, spirochetæ present (31 days); serum negative.

One other rabbit of this generation became infected after forty-three days; three rabbits failed to take the infection.

Three rabbits of the third generation have become infected with an average incubation period of twenty-four days. The fourth generation is under observation. The average incubation period for the first generation was forty-four days, and for the second generation thirty and seven-tenths days.

*Treponema pallidum transferred from the Rabbit to the Monkey.*—March 9, monkey (*Macacus rhesus* 3): left eyebrow abraded and serum from testicle of Rabbit E rubbed in; spirochetæ present, first generation in rabbit from mucous patch.

April 5, slightly red area on left eyebrow; April 6, lesion very scaly, spirochetæ present (28 days); April 11, flat red area covered with fine scales; April 21, serum negative.

#### COMPARISON OF THE LESIONS.

The difference in the lesion of syphilis and yaws in the monkey seems to be the surest way to differentiate the organisms. In yaws the incubation period is two to three weeks, the lesion is elevated, slightly scaly, and very edematous; in syphilis the incubation period is about four weeks, the lesion is flat, dry and very scaly. According to Prowazek and Russell, *Treponema pertenui* is slightly thicker than *Treponema pallidum*, less rigid, less regular in its twists. With an abundance of material at hand, comparative observations have been made with the dark field microscope. *Treponema pallidum* seems quite constantly to show more active corkscrew motion; the twists seem more regular and not so sharp and deep; but occasionally an unknown specimen has been classified wrongly on these points and no other differences seem more reliable. The lesion in the rabbit seems to differ only in degree; the nodules in syphilis seem larger and have a necrotic center; histologically, there is evidence of a more active inflammation.

## SUMMARY.

1. Rabbits can be infected in the testicle with the spirochetæ of yaws as well as with those of syphilis and the infection can be continued through successive generations in pure culture.

2. The infection shows itself by enlargement of the testicle and the presence of a nodule varying in size from that of a pea to that of an olive. The infection consists in a necrosis of the tubules, an infiltration of round cells and the new formation of an edematous connective tissue.

3. The complement fixation reaction occurs in rabbits infected with the spirochetæ of yaws as well as in those infected with the spirochetæ of syphilis.

4. This lesion makes possible the investigation of the problems of cultivation, of immunity and of treatment.

## BIBLIOGRAPHY.

1. Castellani, *Jour. Brit. Med. Assn., Ceylon Branch*, 1905, vii, pt. I, 54; *Brit. Med. Jour.*, 1905, ii, 1280, 1330, 1430; *Jour. of Trop. Med.*, 1905, viii, 253; 1906, ix, 1-4.
2. Prowazek, *Arb. a. d. k. Gsdhtsamte.*, 1907, xxvi, 28.
3. Russell, *Arch. of Internal Med.*, 1906, ii, 74.
4. Neisser, Baermann and Halberstädter, *Münchener med. Woch.*, 1906, xxviii, 1337; *Arb. a. d. k. Gsdhtsamte.*, 1907, xxvi, 47.
5. Charlouis, *Vierteljahrsschr. f. Derm. u. Syph.*, 1881, viii, 431.
6. Parodi, *Cent. f. Bakt., Orig.*, 1907, xlv, 428.
7. Uhlenhuth and Mulzer, *Arb. a. d. k. Gsdhtsamte.*, 1909, xxxiii, 12.
8. Nichols, *Proc. of the New York Path. Soc.*, 1910, x, 1.
9. Bruck, *Die Serodiagnose der Syphilis*, Berlin, 1909, p. 50.
10. Hoffman, *Berliner klin. Woch.*, 1908, xlx, 568.
11. Truffi, *Med. Klinik*, 1910, vii, 269.

## EXPLANATION OF PLATES.

## PLATE LIII.

FIG. 1. Colored soldier with yaws; second eruption.

## PLATE LIV.

FIG. 2. Monkey I, ulcerating yaw on eyebrow and eyelid, 47 days after inoculation from patient.

FIG. 3. *Treponema pertenui* from Rabbit A, Giemsa's stain,  $\times 1,000$ .

FIG. 4. *Treponema pertenui* in rabbit's testicle, Levaditi stain,  $\times 1,500$ .

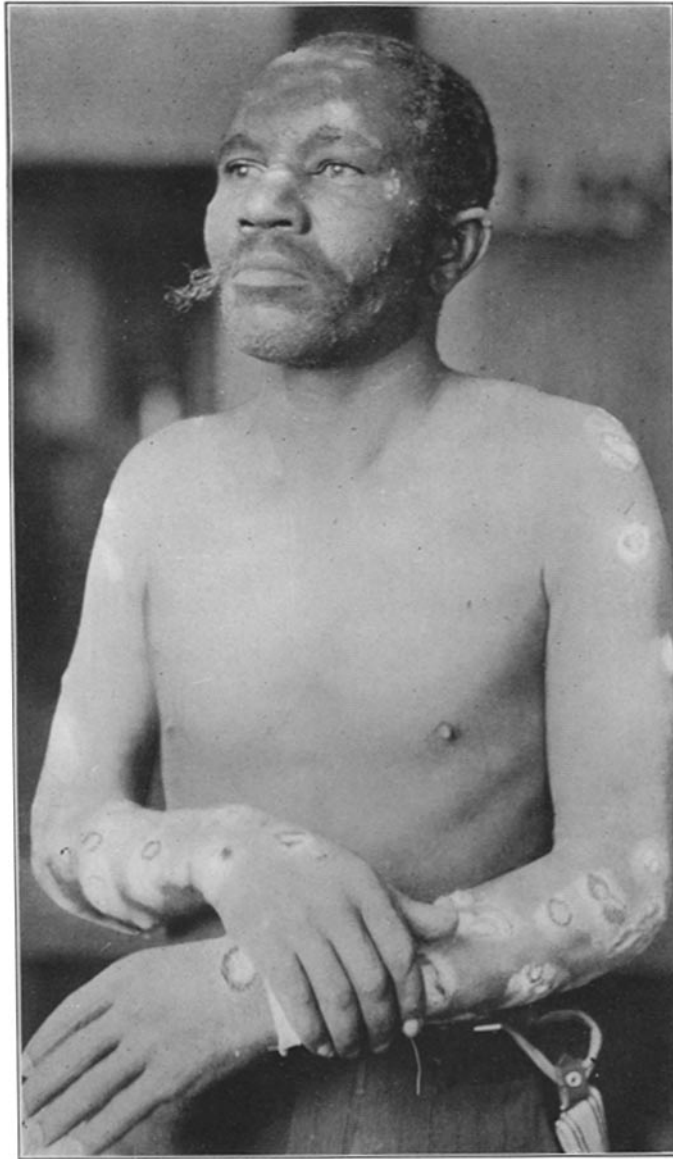


FIG. 1.





FIG. 2.

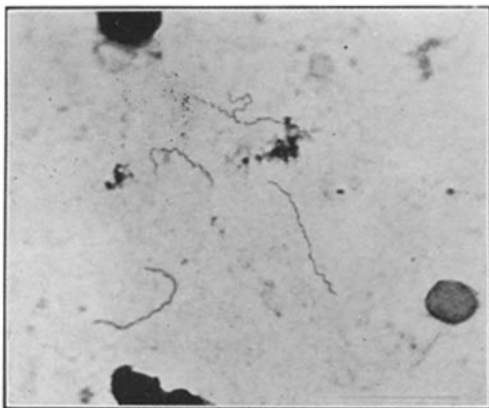


FIG. 3.

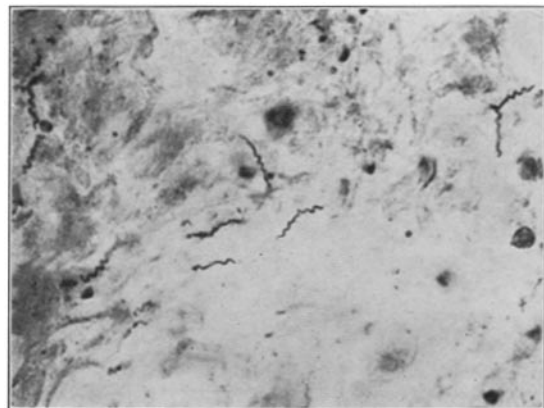


FIG. 4.