

A SARCOMA OF THE FOWL TRANSMISSIBLE BY AN AGENT SEPARABLE FROM THE TUMOR CELLS.*

BY PEYTON ROUS, M.D.

(From the Laboratories of the Rockefeller Institute for Medical Research,
New York.)

PLATES XLVII-LII.

A transmissible sarcoma of the chicken has been under observation in this laboratory for the past fourteen months,¹ and it has assumed of late a special interest because of its extreme malignancy and a tendency to wide-spread metastasis.² In a careful study of the growth, tests have been made to determine whether it can be transmitted by a filtrate free of the tumor cells. Attempts to so transmit rat, mouse, and dog tumors have never succeeded; and it was supposed that the sarcoma of the fowl would not differ from them in this regard, since it is a typical neoplasm. On the contrary, small quantities of a cell-free filtrate have sufficed to transmit the growth to susceptible fowls.

EXPERIMENTS.

For the first experiments on this point, ordinary filter paper was used, and the ground tumor was suspended in Ringer's solution. It was supposed that the slight paper barrier, which allows the passage of a few red blood cells and lymphocytes, would suffice to hold back the tumor and render the filtrate innocuous. Such has been the experience of other workers, with rat, mouse, and dog tumors. But in the present instance characteristic growths followed the inoculation of small amounts of the watery filtrate, or of the fluid supernatant after centrifugalization of a tumor emulsion.

These results led to more critical experiments, which will be here detailed. Tumors of especially rapid growth, and young, well-grown fowls of the variety in which the tumor originally occurred, namely, the barred Plymouth Rock, were used throughout.

* Received for publication, February 9, 1911.

¹ Peyton Rous, *Jour. Exper. Med.*, 1910, xii, 696.

² Peyton Rous, *Jour. Am. Med. Assn.*, 1910, lv, 1805; 1911, lvi, 198.

Experiment I.—Tumor material from the breast of chicken 92 (tumor generation, 6th A) was ground with sterile sand, suspended in a considerable bulk of Ringer's solution, and shaken for twenty minutes in a machine. The sand and tumor fragments were separated out by centrifugalization in large tubes for five minutes at 2,800 revolutions per minute. Of the supernatant fluid a little was pipetted off and centrifugalized anew for fifteen minutes at over 3,000 revolutions per minute. From the upper layers sufficient fluid for inoculation was now carefully withdrawn. The pure-bred fowls were injected in one breast with 0.2 c.c. of the fluid, in the other with a small bit of tumor tissue. All developed sarcoma at the site of this latter inoculation, and in seven the same growth slowly appeared at the point where the fluid had been injected.

Experiment II.—Tumor from chicken 90 (tumor generation, 6th A) was ground, suspended, and shaken as before. After one centrifugalization the fluid was passed through a Berkefeld filter (No. 2, coarse). Before filtration, it was pinkish yellow, cloudy; afterwards, faintly yellow, limpid. Nine fowls were inoculated with 0.2 c.c. of the filtrate in each breast, and twenty-two more received filtrate in one breast, a bit of tumor in the other. Of the nine, one slowly developed a sarcoma in each breast, and microscopic growths were later found in its lungs. Of the twenty-two receiving both filtrate and tumor, five developed sarcoma where the filtrate had been injected, and these five showed especially large growths from the tumor bit.

The Berkefeld filter employed was afterwards found to be slightly pervious to *Bacillus prodigiosis*. The tumor developing in the fowl injected only with filtrate has been successfully transplanted to another individual.

Experiment III.—The filtrate was similarly prepared except that a small Berkefeld filter (No. 5, medium) was used, impermeable, under the conditions, to *Bacillus prodigiosis*. As before, the filtration was done at room temperature. Fowl 124 (7th generation, A) furnished the material. Twenty chickens were inoculated in each breast with the filtrate, but none have developed tumors.

Experiment IV.—In this experiment the material was never allowed to cool. About fifteen grams of tumor from chicken 140 (7th generation, B) was ground in a warm mortar with warm sand; mixed with 200 c.c. of heated Ringer's solution; shaken for thirty minutes within a thermostat at 39° C.; centrifugalized; and the fluid passed through a filter similar to that used in experiment III. Both before and after the experiment, this filter was tested and found to hold back *Bacillus prodigiosis*. The filtration of the fluid was done at 38.5° C., and its injection followed immediately. In four of ten fowls inoculated into the muscle of each breast with 0.2 to 0.5 c.c. of the filtrate, there developed a sarcoma at one of the points of inoculation; and though the growths required several weeks to appear, their subsequent enlargement was of average rapidity. Pieces removed at operation showed the characteristic structure, and transplantation into other chickens proved successful. Three of the hosts have died, and in two profuse metastases were found. One of the growths furnished the material for experiment V.

Experiment V.—The tumor used resulted from the injection into fowl 180 (8th generation, B) of 0.5 c.c. of the filtrate of experiment IV. Just as in this experiment, the material was ground, suspended, and shaken in the warm, but 300 c.c. of Ringer's solution were used to eleven grams of tumor, and the shaking

was continued only twenty minutes. After centrifuging, the filtration was done at 40° C., through a new Berkefeld filter (No. 5, medium), impermeable, under the same conditions, to *Bacillus prodigiosus*. Ten young hens were inoculated in each breast with 0.5 to 1.0 c.c. of the filtrate; and eleven days later a tumor nodule was just palpable in two of them. One of these growths was at once removed by operation. It took the form of a small raised disc, firm, grayish, and translucent, on the outer surface of the pectoral sheath, presumably at the point penetrated by the injection needle. Its greatest diameter was one and one-half millimeters. In the other fowl the nodule lay deep in the muscle, and seemed little, if at all, larger than that described. In control fowls inoculated with bits of the neoplastic tissue from No. 180, growths measuring from 1.3 to 2.7 cm. in diameter had developed at this time. Twenty-eight days after inoculation, eight of the ten fowls given the filtrate showed tumor nodules, some of them still very small.³

Thus the tumor resulting from injection of a filtrate itself furnished material capable of producing tumors after injection.

The importance of the above results depends on the characters of the growth employed. These will now be discussed in detail.

STRUCTURE AND MODE OF GROWTH.

The original tumor was found in the subcutaneous tissue of the breast of an adult, pure-bred hen. The other individuals of the small stock were healthy; and though susceptible normal chickens and chickens with the tumor have been kept together for long periods, no instance of spontaneous transmission of the growth has occurred. The characters of the original mass have been detailed elsewhere.⁴ A more general description of the tumor as it has appeared on transplantation will here be given.

Histologically the growth has always consisted of one type of cells, namely, spindle cells, usually in bundles, with a slight vascularizing framework (figure 1). Cell division is usually by amitosis, but mitosis is frequent. Small giant cells, due to the division of the nucleus without corresponding fission of the cytoplasm, are occasionally seen, especially about regions where the growth is degenerating. There is considerable variation in the size of the cells and in the staining qualities of their nuclei, but the growth has not changed in general histological character during its propagation

³ Later work in this laboratory, by Dr. James B. Murphy, has demonstrated that the tumor can be transmitted by means of the dried and powdered neoplastic tissue, kept at room temperature for many days. The tumors resulting from its injection do not appear for several weeks.

⁴ Peyton Rous, *Jour. Exper. Med., loc. cit.*

to the tenth tumor generation. Tumors of the eighth generation, resulting from a cell-free filtrate, resemble the original, except that their cells are plumper, less regular in size, and much more invasive in tendency (figure 2). Figure 3, a drawing from the edge of a growth in the breast that followed injection of a filtrate (experiment IV), illustrates the replacement of striated muscle fibres by tumor cells. Here most of the neoplastic cells are oval, as yet undifferentiated to the spindle form seen in older portions of the growth. Under some conditions, the cells become widely separated by mucigenous ground substance (figure 4). The picture is always that of a spindle-celled sarcoma or myxosarcoma.

Following implantation of a bit of the neoplastic tissue into the breast muscle of a susceptible fowl, a circumscribed nodule shortly becomes evident. It is very firm and definite on palpation, but on section proves unencapsulated, though distinct in appearance from the normal tissue. In general, the neoplastic tissue is gristly and grayish white, with a fine striation on the cut surface. Less often, it is soft, grayish pink, semitranslucent, and friable, or even gelatinous. In the last instance, it may contain much true mucin. As the mass grows large, its scanty, thin-walled blood vessels prove insufficient, and at its center a wide-spread coagulative necrosis, or cystic change takes place, the latter not infrequently as the result of hemorrhage. The cysts are filled with serous or ropy fluid, often colored with blood pigment; and polypoid extensions into them of the tumor are not rare. Continuing to grow, the mass extends to the muscle-sheath and perhaps through this to connective tissue and skin. Infiltrating the latter, it may spread rapidly *en cuirasse*; but ulceration is seldom seen. Soon the whole of the inoculated breast is occupied by a bulging, rounded, firm growth (figure 5); and the host rapidly emaciates, becomes cold, somnolent, and dies. In many cases the viscera, especially the lungs, heart, and liver, are the site of discrete metastases, gristly and firm, like the primary growth. Those on the surface of the liver may be umbilicated (figure 6).

TUMORS RESULTING FROM A FILTRATE.

The tumors which result from the injection of a cell-free filtrate take much longer to appear. The inoculation into the breast muscle

of a bit of tumor tissue one millimeter in diameter may give rise in the course of a week to a growing nodule 1.5 centimeters broad; whereas, following the injection of a filtrate, not the slightest trace of tumor is palpable for from ten days to three weeks. Then one or two minute, shotty bodies can be felt, and soon the characteristic mass develops. At first it is ovoid or spherical in shape, just as though it had arisen from an introduced bit of neoplastic tissue. In one case a flat, irregularly branching mass, flame-shaped, so to speak, developed in the sheath of the pectoral muscle at the point injured by the injecting needle. Many of the injected fowls in which no growth appeared in the breast muscle have been carefully examined at autopsy for tumors elsewhere, but none have been found. Some with a growth in the breast have developed after a time others in the viscera, probably the usual metastases, to judge from size and distribution. Careful note has been kept as to whether the tumors resulting from a filtrate injection grow more slowly than usual. This has been found to be the case. Following their tardy appearance, a considerable proportion of them grow slowly as compared with control tumors resulting from implantation.

INFLUENCE OF THE HOST.

The stock in which the original tumor occurred consisted of fowls of one pure-bred variety, the barred Plymouth Rock. The first transplantation was made to chickens from the same setting of eggs as the individual with the tumor, and the next successful one to less closely related members of the same stock. Bits of the growth were placed in the breast muscle by means of a trocar, a procedure adopted as the routine. Repeated unsuccessful attempts were made to transfer the growth to chickens resembling the tumor stock, and of similar variety, but obtained from another source, and probably not pure-bred (chart 1). Attempts at this time to transfer it to chickens of another variety and to pigeons and guinea pigs also failed. Recently the sarcoma has increased in malignancy and has gained the power to grow in chickens of other kinds. Yet in them it develops slowly, or long remains stationary; and it has never been successfully transmitted to other species, although pigeons, ducks, rats, mice, guinea pigs,

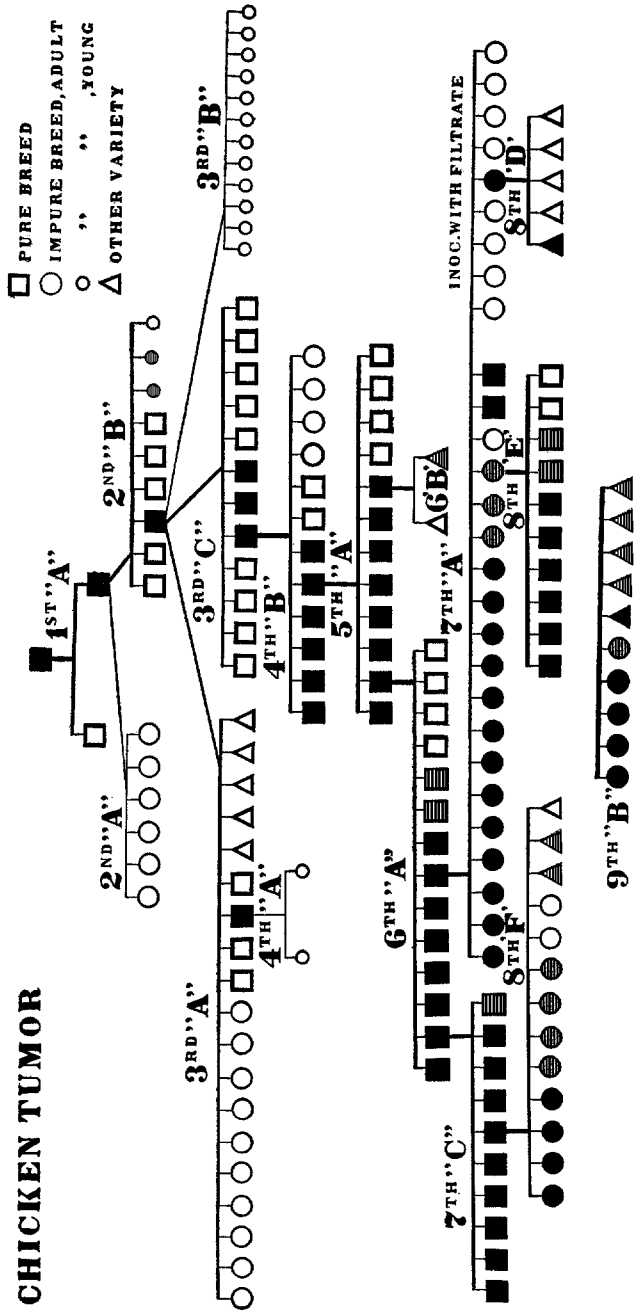


CHART I. This chart of the first eight generations of the sarcoma illustrates the influence of the variety of the host. The blackened symbols represent those hosts in which the tumor grew, the cross-barrred ones those in which it appeared, but remained stationary, or retrogressed. The fowls used were barred Plymouth Rocks of pure breed, barred Plymouth Rocks bought at random and hence presumably not pure-bred, and other chickens of heterogeneous sort and appearance. All were inoculated with bits of the tumor, except nine individuals of 7th generation A, which received portions of a Berkeley filtrate. A number of the series of the 7th and 8th generations are omitted from the chart, because in them the conditions were irregularly modified. The chickens of 9th generation B were inoculated with material from a member of one of these series. Here the importance of the host's variety is still evident, though the cross-barring of the symbols now means that the tumor grew slowly, not that it remained stationary or retrogressed.

and rabbits have recently been inoculated. At present it grows in 80 to 100 per cent. of barred Plymouth Rock fowls and is especially active in young ones. Retrogression of a developed nodule, fairly frequent at first, is now rare, save when the host is sick. Intercurrent illness of the host may check the further development of a nodule two or three centimeters in diameter, and may even cause its retrogression (chart 2). Should the host's health return, the tumor may reappear and grow rapidly. Retrogression in the healthy host confers resistance, so that further inoculation with active material does not result in growths. A fowl which has once failed to develop a tumor usually proves resistant on later inoculation. Resistance, therefore, is both induced and, apparently, natural also.

EFFECTS OF TRANSPLANTATION.

The original tumor had been under observation for two months before it was brought to the laboratory, and had grown slowly during that period. With repeated transmission the rate of growth, as well as the percentage of successful transplantations, has increased; and the period which elapses between implantation and the appearance of the new sarcoma as a palpable mass has been reduced from about four weeks to four or five days. The tumor obtained from the first inoculation required seventy-one days to reach a size of 5.0 by 3.3 centimeters, and to affect seriously the health of the host. But in later generations, produced by a similar method of inoculation, the appearance and development of the tumor have become progressively more rapid. Growths ten or twelve centimeters in length by six in width are now found three weeks after inoculation of a bit of neoplastic tissue, two millimeters in diameter; and often death of the host ensues within twenty-six to thirty days, all told.

Repeated transplantation has also greatly increased the frequency, extent, and rapidity of metastasis formation. The death of the original fowl was hastened by a successful intraperitoneal implantation with its own growth, and the autopsy did not disclose any nodule suggesting a metastasis. The tumor fowl of the first generation was killed after seventy-two days, and had, in its heart, one small secondary growth. Metastasis did not take place in the second

No.	XI/20	XI/25	XI/1	XI/4	XI/12	XI/22	1/3	1/6	1/16	METAS.
112					K					VERY MANY
128					K					VERY FEW
127					D					NONE
115					D	D				FEW
107					D					MANY
128					13. x 5.9	K				ONLY ONE
114					D					VERY MANY
117					D	D				" "
109					D					" "
110										" "
SICK										
121					15.3 x 5.8	D				NOT NOTED
111						D	D			VERY FEW
108						D	D			NONE
118										
125										
120										

CHART 2. The effect upon the tumor's growth of intercurrent illness of the host. The figures in the first vertical column are the serial numbers of the

fowls, those in the first transverse column refer to the dates on which the tumors were measured. In the last vertical column, record is made of the visceral metastases at autopsy. "D" or "K" indicates that the fowl died or was killed.

The fowls (7th generation A) were all inoculated with the same material, and the first measurements were taken eight days later. Within two weeks, six of the hosts had fallen ill of an intercurrent disease, characterized by rhinitis, conjunctivitis, and marked depression and emaciation. Tumors had already developed in all six, but now retrogressed in four, completely disappearing in two. The fowls were placed under better conditions and three recovered health. In two, the tumor reappeared and grew rapidly.

tumor generation; but in the third it was frequent; and in the later ones it has been present in a majority of hosts dying of the growth. In the seventh generation the average time required after inoculation for the dissemination and development of secondary nodules was approximately half that demanded in the third. Metastasis takes place first and most often to the lungs (figure 7). In the earlier generations the heart was especially effected (figure 8), though nodules were found in the liver, much less frequently in the kidneys (figure 9), and occasionally in the intestine, mesentery, pancreas, gizzard (figure 10), gall-bladder, and lymph-glands. Of late the heart has held fewer nodules, and they have been frequent in the liver. The spleen was exempt from them until the seventh generation, when in two cases out of twenty-five it contained nodules. In these two cases the tumor showed itself in other ways especially malignant. The spleen has since been often affected.

MODE OF METASTASIS FORMATION.

The question as to how metastasis of the chicken sarcoma takes place has great importance. For it might be supposed that the agent which suffices, independent of the cells, to transmit the tumor to new individuals would itself cause secondary masses in the host. Perhaps sometimes it does act alone to produce such masses, though we have met no instance in which this can be affirmed. On the contrary, the findings all indicate, as with the sarcomata of man, that the metastases result from a distribution of tumor cells, usually by way of the blood. As has been said, the relations of the sarcoma to the blood stream are very intimate; quite large vessels walled with only a layer of endothelium exist within the growth, and in their

neighborhood cell proliferation is at its height. Instances in which the neoplastic tissue has penetrated a vessel wall are frequent (figure 9), and sometimes a strand of the growth, quite bare of endothelium, extends for a considerable distance in the blood stream (figure 8). The secondary growths in the viscera are first evident as small, approximately spherical groups of cells with a blood-vessel in the midst, occluded by tumor tissue (figure 7). The cells are of one type, in active mitotic and amitotic division, unsurrounded by inflammatory reaction. This is true of metastases consisting of only three or four cells. To recognize a single neoplastic cell lodged in a capillary has thus far proved impossible because the morphology of the single cell does not sufficiently identify it; yet what would appear to be such emboli are frequent in the pulmonary tissue. The question of the transplantability of the tumor cells has been settled in the affirmative by an examination of grafts of the neoplastic tissue removed shortly after implantation.

Metastasis by way of the lymph-stream occasionally occurs: the glands along the great vessels above the heart have been found enlarged and entirely replaced by sarcomatous tissue. Contact metastasis is very frequent. For example, a mass in the breast may penetrate the sternal membrane and give rise to nodules on the liver surface opposite. In the viscera the tumor preserves its histological character, but its arrangement is influenced to a certain degree by preëxisting structures. In the lung the pattern of the alveoli may be perpetuated in tumor cells, as is true also of the striped muscle (figure 3). The skin may be infiltrated and tightly stretched. Frequently the growth recurs in wounds made to remove subcutaneous grafts, and here its presence need not greatly impede healing. The early stages in the development of a sarcoma caused by a cell-free filtrate are difficult to obtain. When such a growth becomes palpable, it is already one to two millimeters in diameter, and histologically no more enlightening than a metastasis or a graft of the neoplastic tissue would be.

THE TUMOR CELLS ARE TRANSPLANTABLE.

A study of many grafts removed at short intervals from the connective tissue has shown conclusively that the inoculation of a

bit of the sarcoma into a susceptible fowl results in an actual transplantation of the neoplastic cells and growth from them. For the first two or three days after implantation, the graft is unattached to the host tissues, but then it unites with them, is vascularized, and begins to enlarge and to invade the surrounding parts (figure 11). Usually a few small mononuclear cells (lymphocytes) collect at its edge, but no other cellular reaction follows that is due to the initial trauma. Indeed, about metastases a cellular reaction is often completely absent. Unless the graft is very small its central part dies before vascularization can take place. There remains, however, a living periphery distinct from the normal tissues of the host, and soon this is vascularized and strands of the spindle-shaped cells can be seen growing out from it. The findings do not in the least suggest that the tumor is transmissible apart from its cells. Certainly it is transplanted easily and is, at present, best propagated by this means.

The death of grafts of the tumor in fowls with a natural or acquired resistance takes place in one of two ways. The implanted tissue may fail entirely to be vascularized, and its death results after some days, during which a zone of living cells persists at its periphery (figure 12). Or it may be vascularized and grow for a brief period, dying at last in the midst of an accumulation of lymphocytes. The first process is seen especially in regions poor in connective tissue and blood-vessels, and may occur there even in susceptible hosts. The second process is the one found at the edge of retrogressing tumors. A more detailed account of the fate of early grafts has been reserved for another paper. The findings here briefly described are those made familiar to tumor workers by a study of rat, mouse, and dog tumors.

Cultures from the growth upon many media have repeatedly been taken; but with the exception of a large post-mortem bacillus once obtained, they have remained sterile as regards bacteria. Portions of the filtrate and fresh smears from the tumor surface have been examined with the dark-field microscope, but neither this nor the various histological procedures applied to the neoplastic tissue has disclosed anything which can be recognized as a parasitic organism.

DISCUSSION.

It is evident from the foregoing description that our tumor of the fowl possesses to a marked degree those characters of morphology and behavior which distinguish the true malignant neoplasms, especially the sarcomata. It is formed of a single type of cells, only slightly differentiated, resembling young connective tissue cells, and possessed of an enormous proliferative energy which is exercised to the detriment of the surrounding tissues and eventually of the entire host. Growth takes place through infiltration and replacement of normal structures, as well as through expansive enlargement. Metastasis by way of the blood stream is common, rarer by the lymphatics; and, to judge from histological evidence, the transportation, lodgment, and growth of tumor cells is wholly responsible for the secondary nodules. Indeed, a general histological study of the sarcoma would not lead one to suspect that it can be transmitted by another means than a transplantation of cells. When a small bit of the neoplastic tissue is placed in a new and susceptible host, most of its cells survive, are vascularized, and by their proliferation give rise apparently to all of the growth. In a resistant host, the graft soon dies and no tumor follows. One would suppose that the sarcoma developed only "aus sich heraus," to use Ribbert's phrase. But histological pictures are not decisive upon this point. Since the growth is transmissible by a cell-free filtrate, it seems not unlikely that in its neighborhood the connective tissue cells of the host undergo a neoplastic change.

A feature of the transmissible tumors, which has largely drawn the attention of cancer workers and has modified current theories of cancer origin, is their striking dependence for a successful transplantation on the character and condition of the individual host. It is a dependence similar to that shown by transplanted normal tissue, and apparently the same laws largely influence both. This trait of tumors is illustrated exceptionally well by the chicken sarcoma. During a considerable period, it could be propagated only in fowls of precisely the sort in which the original growth occurred (chart 1); and even now it succeeds best in these. It has never been successfully transmitted to birds of other species, or to mammals. Young fowls are the most favorable hosts; and healthy,

well-nourished ones proves more susceptible than the thin and ill. Indeed, intercurrent illness of the host may cause the sarcoma transiently to disappear (chart 2).

The above traits have figured largely in current discussions on cancer etiology, and most of them have been regarded as evidence against a specific cause for the disease, extrinsic of the cells. Such evidence is void, now that a growth has been found possessing the traits mentioned, yet transmissible independently of its cells. This fact, and not the problem of how to classify the growth, merits attention. Nevertheless, a passing reference should perhaps be made to the ill-defined group of pathological products called granulomata, with which this neoplasm of the fowl may by some be classed, owing to its transmission by an agent separable from the tissue cells. None of the granulomata has the tumor characters, and none is known to be transplantable. The present growth fails to resemble any granuloma thus far described; whereas it fulfills all the conditions for identification as a tumor.

The first tendency will be to regard the self-perpetuating agent active in this sarcoma of the fowl as a minute parasitic organism. Analogy with several infectious diseases of man and the lower animals, caused by ultramicroscopic organisms, gives support to this view of the findings, and at present work is being directed to its experimental verification. But an agency of another sort is not out of the question. It is conceivable that a chemical stimulant, elaborated by the neoplastic cells, might cause the tumor in another host and bring about in consequence a further production of the same stimulant. For the moment we have not adopted either hypothesis.

The ultimate significance of these unusual findings can hardly be well discussed until more data are obtained through experiment, especially through carefully devised experiment with the tumors of other species of animals. For it is quite possible that the failure to separate from these growths an agent causing them may be traceable to some interference with the conditions under which this supposititious agent can exist alone, or reproduce the growth in new hosts. Work along the line indicated is under way in this laboratory.

EXPLANATION OF PLATES.

Unless otherwise indicated, the sections are stained with Delafield's hematoxylin and eosin. In each case the tumor generation and series are given, followed by the number of fowl from which the specimen came; thus, 7th A, No. 117.

PLATE XLVII.

FIG. 1. An area in the original growth. Necrosis is present at one side.

FIG. 2. 8th B, No. 177. Part of a tumor in the left breast, resulting from the injection of the filtrate of experiment IV. The muscle fibres are largely invaded and replaced by tumor cells. Methylene-blue and eosin.

PLATE XLVIII.

FIG. 3. 8th B, No. 177. A drawing which further illustrates the invasion and replacement of muscle fibres by tumor cells. The preparation is from the same growth as Fig. 2.

FIG. 4. 8th B, No. 173. Myxomatous growth caused by the filtrate of experiment IV.

PLATE XLIX.

FIG. 5. 5th A, No. 82. Growth in the left breast of a chicken, resulting from the implantation of a small bit of tumor tissue fifty-two days previously. The skin and connective tissue covering have been removed. The length of the mass is fourteen centimeters. In the right breast is a nodule that resulted from injection of the fluid supernatant after centrifugalization of a tumor emulsion.

FIG. 6. 7th A, No. 117. Metastases from a growth in the left breast. The chest, and abdominal wall, and about half of the breast tumor have been cut away to expose the viscera. The lungs, much enlarged, are crowded with discrete tumor nodules. The metastases on the surface of the liver are umbilicated and surrounded by a zone of dilated blood-vessels. The duration of the disease was thirty-seven days.

PLATE L.

FIG. 7. 6th A, No. 102. A small metastasis in the lung, with an occluded blood-vessel at its center. The tumor cells have only short, blunt processes, a variation that is not infrequent. The picture is complicated by the presence of many nucleated red cells.

FIG. 8. 4th B, No. 63. Growth of a tumor of the heart wall into the ventricular blood. A tongue of myxomatous tumor here extends between two trabeculae of heart muscle. The dark mass at its end consists of nucleated erythrocytes. The transverse rent in the heart muscle above the tumor is an artefact.

PLATE LI

FIG. 9. 4th B, No. 63. Kidney. Extension of the tumor through the wall of a vein.

FIG. 10. 7th A, No. 116. Margin of a metastasis in the muscle of the gizzard. At one corner some uninvaded tissue is seen. Note the complete absence of any cellular reaction about the tumor.

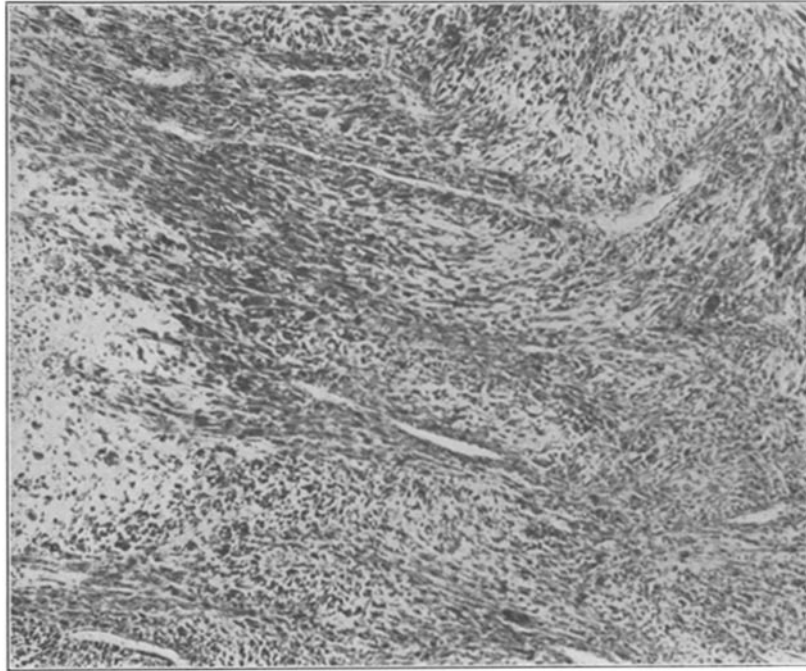


FIG. 1.

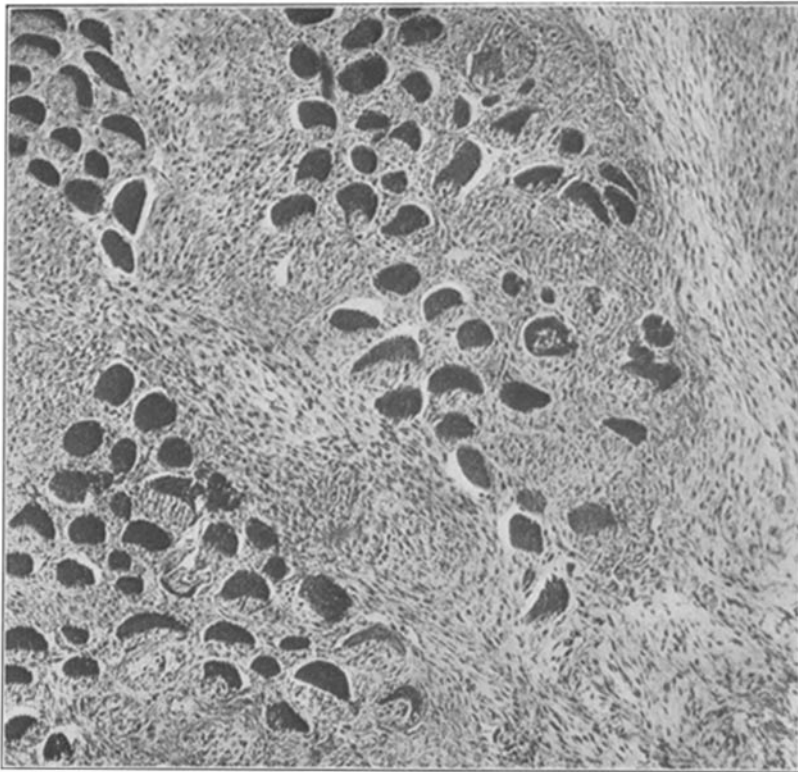


FIG. 2.

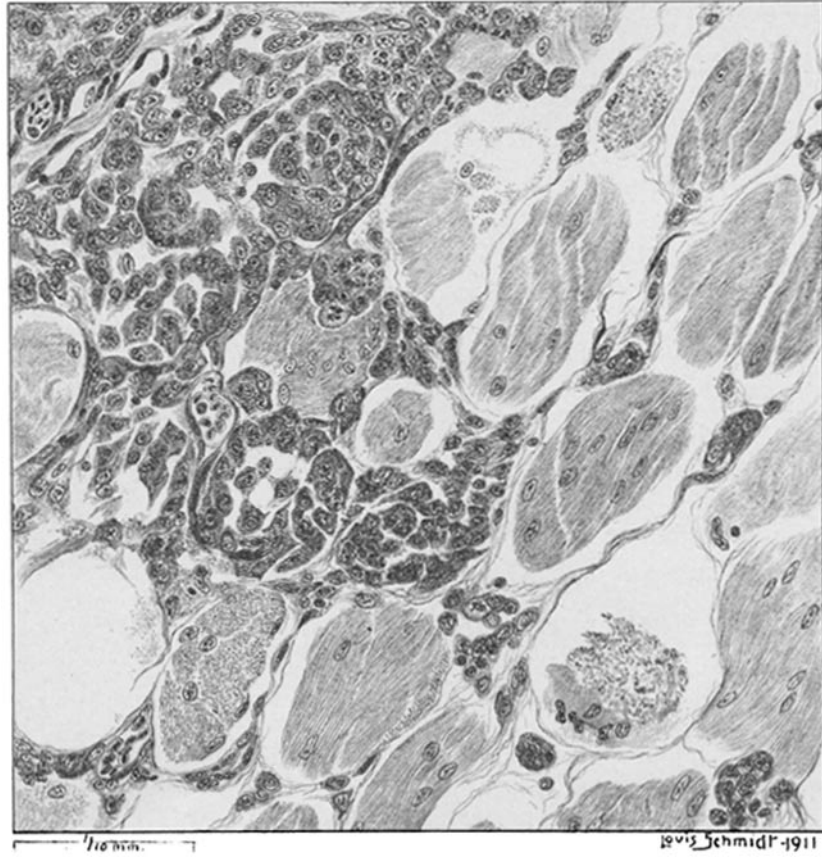


FIG. 3.

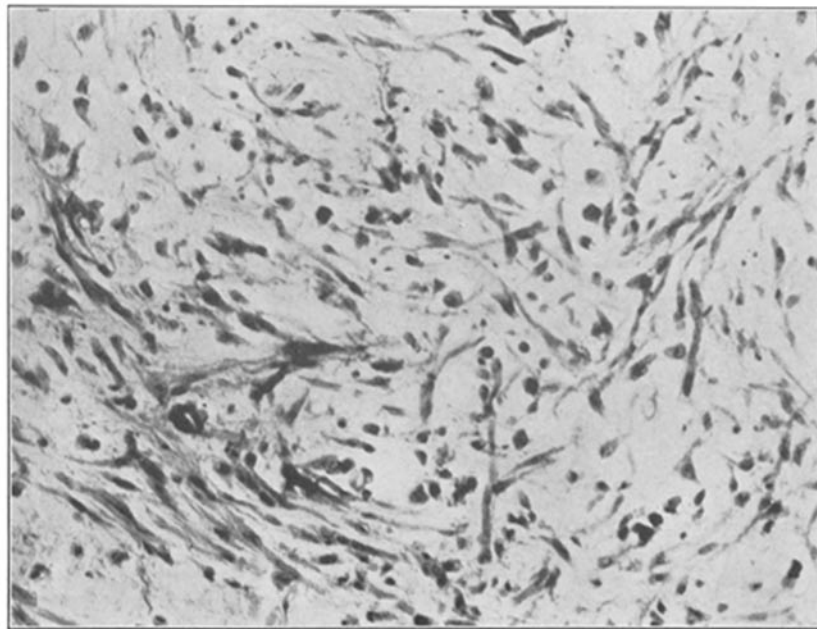


FIG. 4.

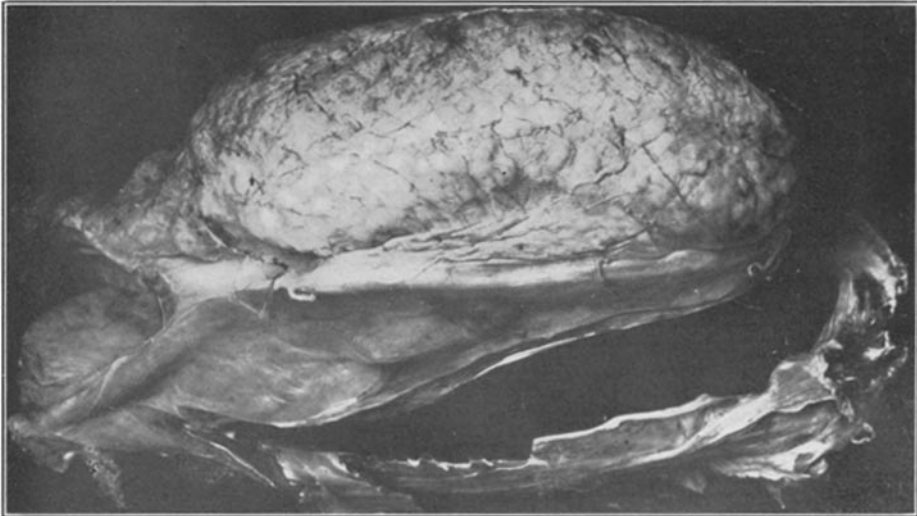

FIG. 5.

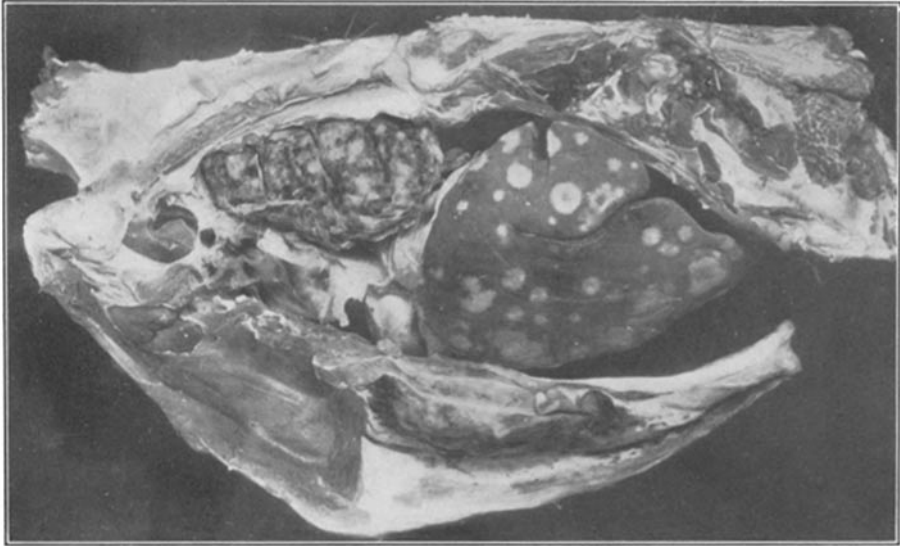

FIG. 6.

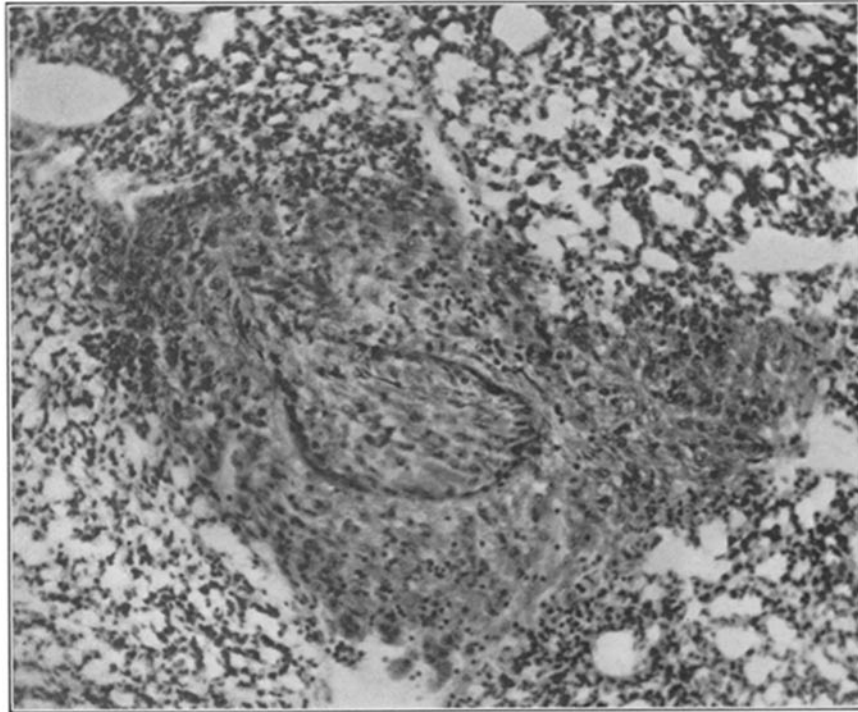


FIG. 7.

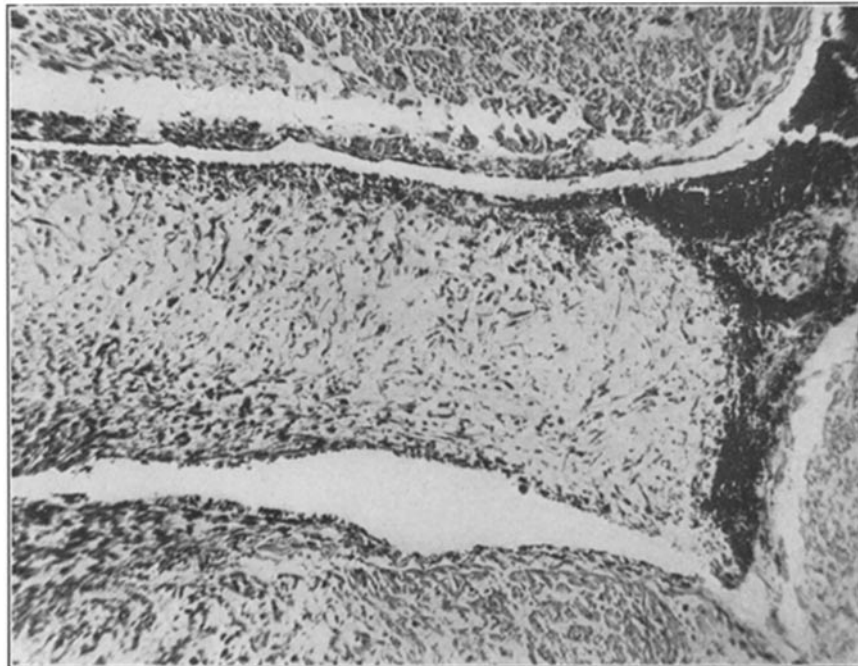


FIG. 8.

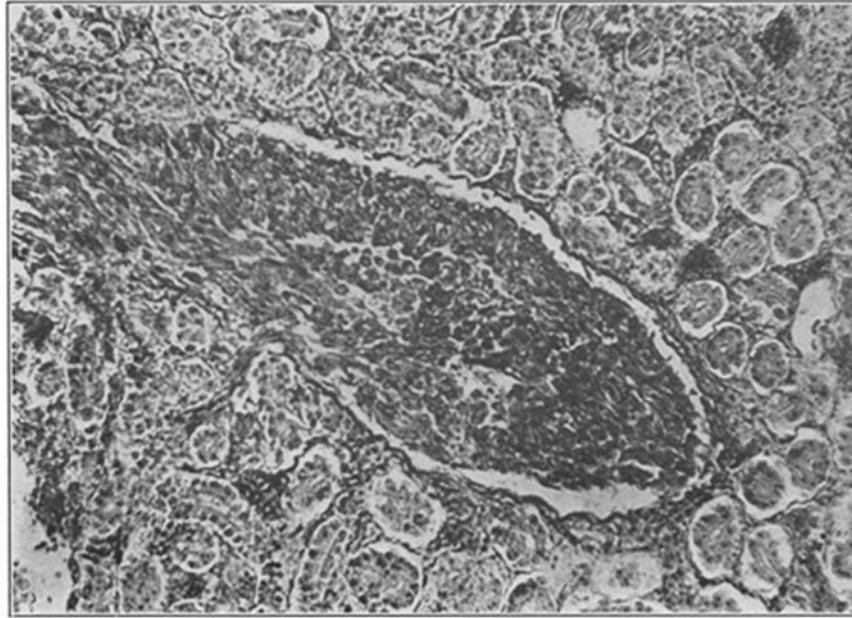


FIG. 9.

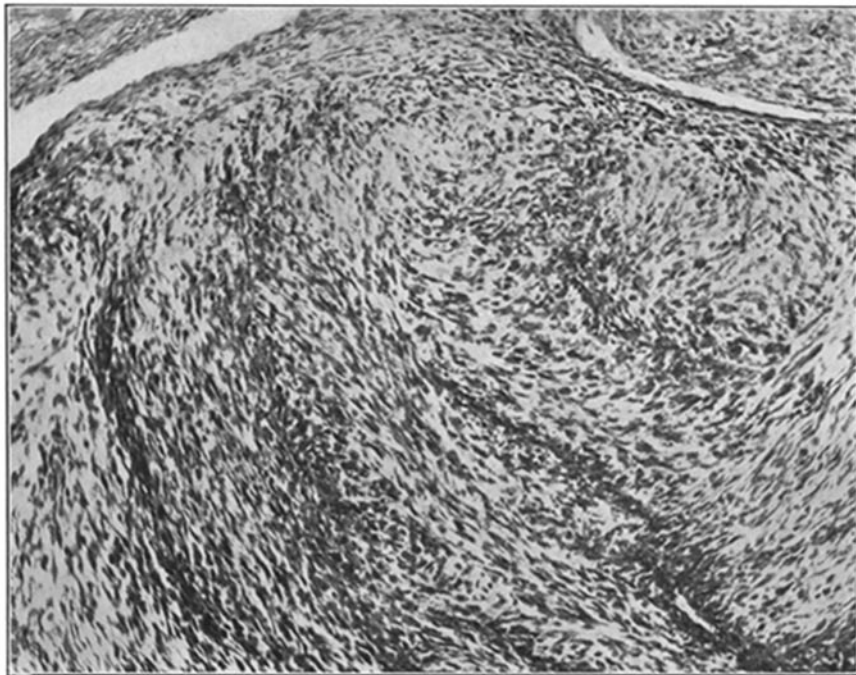


FIG. 10.

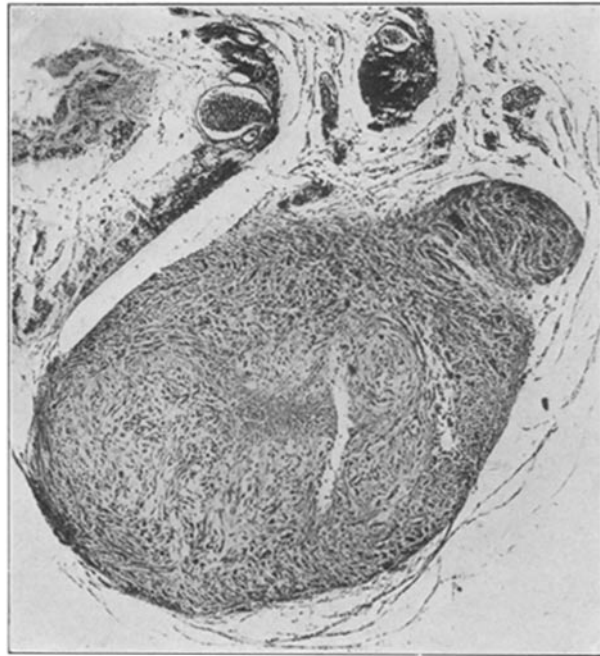


FIG. 11.

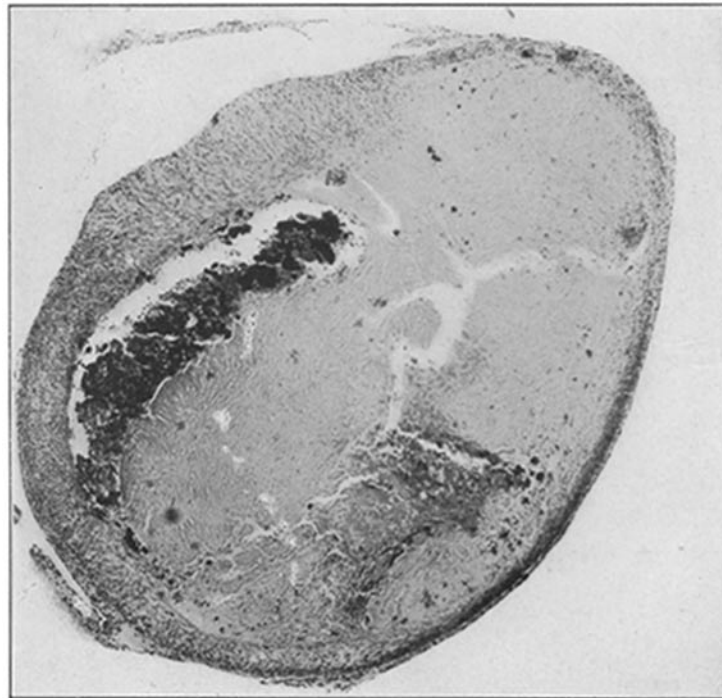

FIG. 12.

PLATE LII.

FIG. 11. A graft of the sarcoma removed with the surrounding tissue four days after implantation in a susceptible host. Already it has united at two points with the host tissue and vascularization is in progress, though too late to prevent necrosis at the center of the graft.

FIG. 12. A similar graft removed from a resistant host nine days after implantation. Despite the long period, the graft is joined to the host only by two thin strands of connective tissue shown at either end. It is unvascularized and necrotic save for a thin peripheral zone of the characteristic cells, which is considerably infiltrated by lymphocytes.