

ULTIMATE RESULTS OF AORTIC TRANSPLANTATIONS.*

By ALEXIS CARREL, M.D.

(From the Laboratories of The Rockefeller Institute for Medical Research,
New York.)

PLATE 58.

The purpose of this article is to describe the ultimate result of the transplantation of vascular segments upon the thoracic and abdominal aortas. It is known that a severed artery can be efficiently repaired by segments of autogenic, homogenic, or heterogenic vessels in a condition of active or latent life, by devitalized arteries, by pieces of peritoneum, and even by pieces of rubber. It is now important to ascertain whether or not these repairs are lasting.

In several cats and dogs in which portions of the abdominal or thoracic aortas have been replaced by segments from other vessels, I have observed a normal circulation after two, three, and four years. As two of the animals died a few months ago, the anatomical results of the transplantations could be examined.

Experiment 1. Transplantation of a Human Artery upon the Abdominal Aorta of a Dog.—A young, small sized black bitch was used. On May 6, 1907, under ether anesthesia, a transverse semicircular laparotomy was made which was followed by a dissection of the abdominal aorta below the renal arteries, and ligation of four collateral lumbar branches. During temporary hemostasis, the aorta was cut and a short segment resected, a segment of the upper part of a human popliteal artery being interposed between the cut ends of the aorta. This segment was 2.5 centimeters long, and had a diameter which was more than one third greater than that of the aorta. It was normal in appearance. Nevertheless, the wall had partially lost its elasticity. The vascular ends were sutured by the ordinary method, the circulation was reestablished, and the abdominal wall was closed by four planes of sutures.

The segment had been extirpated on April 11, 1907, from a limb amputated on April 10 at the Presbyterian Hospital by Dr. Ellsworth Eliot. The limb was from a young man who had an osteosarcoma. Through the kindness of Dr. Eliot, the leg was put in the ice box on April 10, and sent to the Rockefeller Institute on April 11, 1907. The popliteal artery and the lower part of the

*Received for publication, February 24, 1912.

femoral artery were extirpated. Before being used in this experiment, the upper part of the popliteal artery had been put in isotonic salt solution, and preserved for twenty-four days in a refrigerator at a temperature slightly above the freezing point.

Following the operation, the femoral pulse of the dog was normal and the animal remained in good health.

October 18, 1907. The animal was in excellent health. A median laparotomy under anesthesia was made, and the pulsation of the abdominal aorta was found to be normal. There was no dilatation of the inserted segment, which was very much larger than the aorta, and no change in the consistency of its wall.

During the years 1908, 1909, 1910, and 1911, the animal remained in excellent health and became very fat. She was pregnant several times, and had normal pups. In June, 1911, the animal died during labor, and the body was preserved in formalin until it could be carefully examined.

Autopsy.—In October, 1911, the lower part of the body was examined. The peritoneal cavity and the abdominal organs were normal. The abdominal aorta was dissected and removed.

Macroscopical Examination.—In the middle portion of the abdominal aorta, a dilated segment was seen (figure 1). The dilatation was not very much greater than at the time of the transplantation. On opening the aorta and the transplanted segment longitudinally, the anastomoses were easily seen. The length of the segment was 2 centimeters. From above downward, the circumferences of the artery and segment at their anastomoses were as follows: upper part of artery, 11 mm.; upper part of segment, 12 mm.; lower part of segment, 10 mm.; lower part of artery, 8 mm. The circumference of the middle part of the transplanted segment was 20 mm. The scar of the upper anastomosis was linear, while that of the lower anastomosis was thicker. The internal surface of the segment was white and glistening, but just below the upper anastomosis, this surface had a cicatricial appearance. The wall of the transplanted segment was generally thicker than that of the aorta. Its consistency was harder, and in certain regions it seemed calcified.

Microscopical Examination.—The vessel wall was cut transversely and the sections were stained by hematoxylin and eosin, by Van Gieson's method, and with Weigert's elastic tissue stain. The wall was composed exclusively of connective tissue, which, in a few places, showed hyaline degeneration. No elastic fibers or muscle cells were seen.

Experiment 2. Transplantation of a Segment of a Dog's Vein upon the Thoracic Aorta of a Dog.—On November 5, 1909, a white female fox terrier was etherized by the Meltzer-Auer method, and a left transverse thoracotomy was followed by dissection of the descending aorta and ligation of four collateral branches. During a temporary hemostasis, a section of the thoracic aorta was removed and between the cut ends was interposed a segment of the external jugular vein extirpated from a large dog on November 4, and kept for twenty-four hours in cold storage. This segment was sutured to the ends of the aorta by the ordinary method, and the circulation was reestablished after an interruption of seventeen minutes. The thoracic cavity was closed by four planes of sutures.

November 7. In the afternoon, the animal was in excellent condition, but the posterior limbs were stiff and hyperextended. The dog could stand up, although she was not able to walk. The femoral pulse was normal.

November 9. The animal walked, but the posterior limbs were still in hyperextension.

November 14. The condition of the dog was normal, and the animal could run, although the posterior legs were still stiff.

In May, 1910, the animal was sent to the farm, but was brought back to the Institute in October, 1910. She became pregnant and had several pups in October, 1911.

On January 10, 1912, the animal was infected with myelitis which was epidemic. She became paralyzed and died on January 16.

Autopsy.—The thoracic and abdominal organs were in normal condition. The posterior part of the left lung was slightly adherent to the thoracic wall. The lung was normal. On dissecting the aorta, no evidence of the previous operation was seen. Nevertheless, the location of the transplanted segment was detected by a slight increase in the diameter of the aorta. The descending aorta and the transplanted segment were then extirpated and opened longitudinally.

Macroscopical Examination.—The transplanted segment was about 4.5 centimeters below the arch of the aorta. It was 2.5 centimeters long and its diameter was slightly larger than that of the aorta (figure 2). Its internal surface was white and glistening and resembled the internal surface of the aorta. Two valves of the jugular vein had persisted and presented the same appearance as at the time of the transplantation (figure 3). The anastomoses of the artery and the transplanted segment were almost invisible, as at the place of juncture neither contraction nor dilatation had occurred; but the wall of the transplanted segment was thinner, more translucent, and harder than that of the aorta.

Microscopical Examination.—A small piece of the middle part of the transplanted segment was cut and stained with hematoxylin and eosin, with Van Gieson's and with Weigert's stains. The wall was apparently composed of a normal adventitia and of a media in which neither elastic fibers nor muscle cells could be seen. On its internal surface, endothelial cells were observed.

SUMMARY.

In the first experiment, a segment of popliteal artery, extirpated from the leg of a young man and preserved for twenty-four days in cold storage, was transplanted upon the abdominal aorta of a small bitch. The animal lived in excellent health for four years and two months, became pregnant several times, and finally died during labor. The abdominal aorta was normal, but the human arterial segment was slightly dilated, and its wall was composed of connective tissue only.

In the second experiment, a segment of dog's jugular vein, pre-

served for twenty-four hours in cold storage, was transplanted upon the thoracic aorta of a fox terrier. In spite of slight lesions of the cord due to interruption of the aortic circulation during the operation, the animal remained in excellent health. After two years and two months, the dog died of an epidemic disease. The descending aorta was normal. The transplanted segment had about the same caliber as that of the aorta, but its wall was composed of connective tissue, with no evidence of muscular or elastic tissues.

In these two experiments, the walls of the transplanted segments contained neither muscle nor elastic tissue fibers and were not thicker than those of the artery. Nevertheless, they were able to withstand the pressure of the blood without undergoing any marked dilatation.

If death due to accident had not brought these two experiments to an end, it is probable that the transplanted segment would have successfully resisted the pressure of the blood for a much longer time. As it is, the result shows that, in one experiment after four years and in the other after two years, the segments transplanted upon the abdominal and thoracic aortas were still efficient.

EXPLANATION OF PLATE 58.

- FIG. 1. The transplanted arterial segment and the adjacent part of the aorta.
- FIG. 2. The descending aorta with the transplanted venous segment.
- FIG. 3. The transplanted venous segment and its valves.

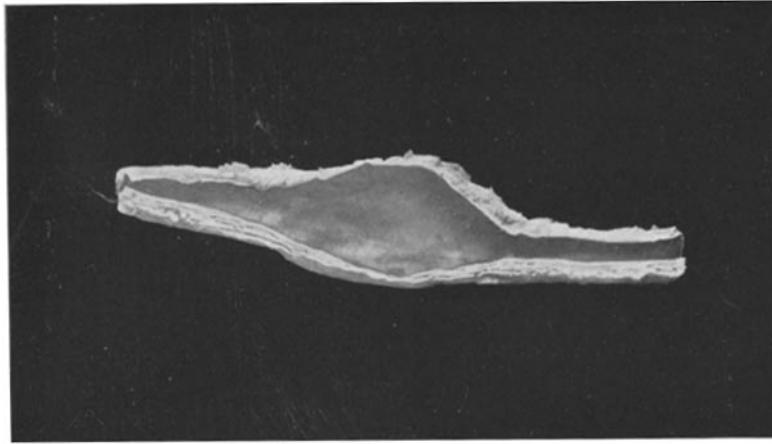


FIG. 1.

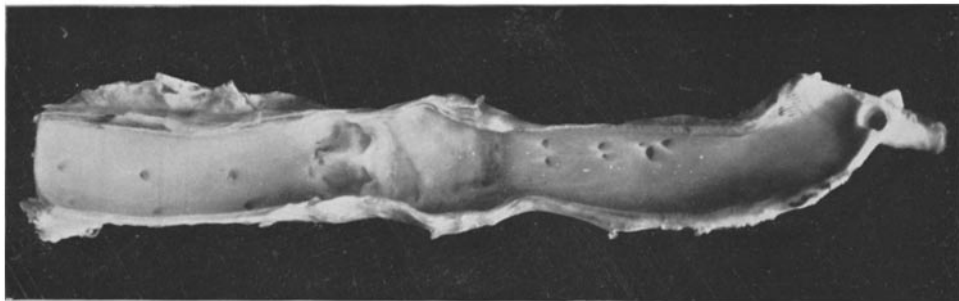

FIG. 2.

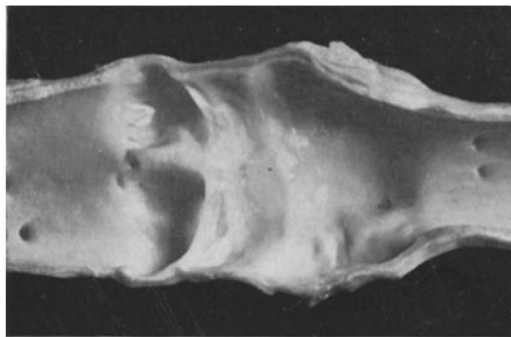


FIG. 3.