

ON THE SIGNIFICANCE OF THE SUBMILIARY MYO-
CARDIAL NODULES OF ASCHOFF IN
RHEUMATIC FEVER.*

By WILLIAM THALHIMER, M.D., AND M. A. ROTHSCHILD, M.D.

(From the Pathological Laboratory of the Mount Sinai Hospital, New York.)

PLATES 46 TO 48.

Aschoff, in 1904, described what he considered a specific microscopic lesion in the myocardium of cases of acute rheumatic fever. Previously Romberg and his pupils had noted that interstitial changes and inflammatory foci occur in the myocardium of cases succumbing either to the acute fever or to chronic valvular disease of rheumatic origin. Aschoff called the focal lesions "submiliary nodules of rheumatic fever," and stated that they occur near the small or medium sized vessels, to the adventitia of which they often have close relation. The lesions consist of large cells with one or more large polymorphous nuclei, the cells being arranged in the form of a fan or rosette. The central portion of the nodule is composed of faintly staining, apparently necrotic masses of protoplasm. The giant cells, so called, resemble the large cells of certain sarcomatous or pseudoleukemic growths. The nodules include also large and small lymphocytes and polymorphonuclear leucocytes. The small lymphocytes are numerous at the periphery. Aschoff believes that the giant cells arise as a result of swelling from the adventitial "*Wanderzellen*." These cells give the cell masses their characteristic appearance.

Geipel studied seven cases of rheumatic myocarditis, of which one was complicated by staphylococcus abscesses in the myocardium, and another by gonococcus endocarditis. The nodules occurred in the intermuscular connective tissue, especially about the blood vessels. He describes their origin as follows: "There is first an increase in the size of the connective tissue cells, both the nuclei and the cytoplasm taking part in the process. Later the nuclei subdivide and in some cases the cells become confluent. As a result, giant cells, 15 to 23 microns in size, develop, and these assume a peripheral arrangement about the connective tissue fibers, the latter staining faintly in the center of the nodules." Geipel's view of the origin of the nodules, namely from the interstitial connective tissue, is in contradistinction to Aschoff's view of their origin from the adventitial "*Wanderzellen*."

Geipel also made a study of the blood vessels in other organs and failed to find any lesions resembling the Aschoff bodies. He believes that the rheumatic virus exerts a characteristic effect upon the cardiac interstitial tissue, that the

* This work was done under the tenure of a George Blumenthal, Jr., Fellowship. Received for publication, February 3, 1914.

latter undergoes a certain degree of necrosis, followed by a form of productive inflammation which exhibits itself in the formation of the Aschoff bodies. He does not admit, however, that the Aschoff bodies are specific for rheumatic myocarditis, for he claims to have observed similar nodules in the heart of a case of chronic interstitial nephritis. But as adherent pericardium coëxisted, there is the possibility, as suggested by Aschoff, of a previous rheumatic infection.

Coombs demonstrated the bodies in several series of cases, chiefly in the wall of the left ventricle. They were absent from non-rheumatic cases. Wächter reported a case in which the bodies were abundant, and Bracht and Wächter later found the nodules in three cases of acute articular rheumatism. However, in a fourth case, giving a rheumatic history, the bodies were absent. In two of the cases a *Streptococcus mitis*¹ type of organism was cultivated from the heart's blood post mortem. They failed to reproduce the lesions in animals. Saigo observed the bodies in five hearts from persons giving a previous history of rheumatism. In one instance, a woman, dying of sarcoma of the uterus, who had suffered from acute articular rheumatism twenty-seven years previously, scars with an occasional giant cell were present, a finding which he considered sufficient proof of a previous rheumatic infection. Takayasu and Löw each found the nodules in one case. Fraenkel, in order to test the specificity of the Aschoff bodies, made post-mortem studies of twenty cases in which blood cultures had been made *intra vitam*. He demonstrated the value of the Unna-Pappenheim methyl-green pyronin stain for differentiating them from other foci. Eight of his twenty cases had given a rheumatic history. In seven cases no history was available and five subjects had not suffered from rheumatism. One instance was similar to one of ours, there being a superadded vegetative endocarditis due to an infection by *Streptococcus mitis*. Of the eight cases in which a definite history of rheumatism was obtainable, five showed Aschoff bodies. In the remaining three cases the attack of rheumatism occurred three, seven, and twenty years respectively before death. However, fibrous scars occurred with a few characteristic cells in a case eighteen years after an attack of acute rheumatic fever. He calls attention to the occurrence in old cases of fibrous scars which infiltrate the myocardium. In the five cases in which there was no history of rheumatism, the nodules were absent in two, characteristic cells were found in two, and the cells and nodules in one. The fifth case was one of chorea without joint manifestations, and the characteristic nodules were present. In seven cases of verrucous endocarditis, without history, Aschoff bodies or their remains were present in six. Fraenkel believes that even in the absence of a history of rheumatism the finding of Aschoff bodies is strong presumptive evidence of a preceding rheumatic infection. In the hearts of patients dying from infection of the endocardium by the streptococcus, staphylococcus, pneumococcus, *Bacillus aerogenes*, or the diphtheria bacillus, Aschoff bodies could not be demonstrated.

Douglas found the bodies in one case of acute rheumatic fever, and Huzella found them in six cases of acute rheumatic fever, and in one case of chorea. Using the Unna-Pappenheim or other method of staining, the various authors in general confirm Aschoff's statement as to the appearance and composition of the

¹This term is synonymous with *Streptococcus mitior seu viridans* (Schottmüller), *Streptococcus viridans*, *Streptococcus salivarius*, and *Streptococcus fecalis*.

foci and their relation to the blood vessels, but some share the opinion of Geipel, that the giant cells arise from the fixed cells of the adventitia.

MATERIAL.

The material studied consists of the following: three cases of acute rheumatic fever; three cases of chorea without rheumatic history; one case of combined verrucous and subacute bacterial endocarditis without rheumatic history; fourteen cases of subacute bacterial endocarditis in the active stage of the disease; five cases of subacute bacterial endocarditis in the bacteria-free stage; five cases of chronic valvular disease without rheumatic history; five cases of acute streptococcus endocarditis; one case of pneumococcus; three of gonococcus; and three of staphylococcus endocarditis.

CASES SHOWING ASCHOFF BODIES.

Cases 1, 2, and 3 of our series were cases of typical acute articular rheumatism. Blood cultures, made *intra vitam*, in case 1 were negative; in cases 2 and 3 a search for microorganisms in the heart was unsuccessful. Case 1 had three attacks of acute articular rheumatism and finally developed an acute pericarditis. Careful study of the heart showed that each attack had left its imprint in the myocardium. We found scars with an occasional giant cell of the Aschoff type,—a healed or healing lesion. A more recent stage was also present, showing an intermingling of Aschoff cells and fibroblasts. In addition very recent bodies were found in the myocardium, probably depending upon the last rheumatic manifestation, namely, pericarditis.

Case 2 shows the most extensive involvement of the myocardium in our series. Several Aschoff bodies are found in each microscopical field. Case 4 corresponds to a case which Fraenkel reported (case 9) in which there was no definite history of rheumatism. Blood cultures during life showed *Streptococcus mitis*; however, post-mortem examination showed both verrucous and vegetative endocarditis. The mitral valve and myocardium showed numerous bodies in the stage of fibrosis; besides this, lesions identical with those produced experimentally by Bracht and Wächter are present.² We would interpret this as a rheumatic process with an

² Thalhimer, W., and Rothschild, M. A., *Jour. Exper. Med.*, 1914, xix, 429.

added bacterial involvement, as previously damaged valves are prone to secondary infections. The fact that the bodies were not present in any of the fourteen cases of subacute bacterial endocarditis reported in this paper leads us to agree with Fraenkel that even in the absence of a history of rheumatism, the finding of the bodies is strong presumptive evidence of a previous rheumatic infection.

Cases 5, 6, and 7 had a history of chorea and are of interest because the pathological lesion proves the theory which clinicians have long held, that rheumatism and chorea are closely related. None of the cases had any articular manifestations. The myocardium in case 5 showed numerous bodies with a considerable fibrosis and in addition a diffuse infiltration with Aschoff cells. The sudden cardiac death in this case might possibly be explained by the diffuse invasion of the myocardium. Cases 6 and 7 showed only a few small bodies. In none of these cases have we been able to demonstrate bacteria in the lesions with either the Gram-Weigert, cresyl-violet, or Unna-Pappenheim stains.

*Case 1.*³—C. R., age 17 years, had been a patient in Mount Sinai Hospital three times previously with acute articular rheumatism and a valvular defect. The patient returned to the hospital with dyspnea, palpitation, and fever.

Autopsy. Anatomical Diagnosis.—Verrucous endocarditis of mitral and aortic valves; aortic stenosis and insufficiency; cardiac hypertrophy and dilatation; old and recent fibrous pericarditis; fibrous pleurisy (left). Heart weighed 810 gm. The tricuspid orifice is slightly thickened and along its line of closure there are scattered numerous small verrucæ varying from 1 to 3 mm. in size. The mitral valve is dilated and presents numerous verrucæ; mitral ring calcified; the cusps of the aortic valve are markedly thickened and along the free edge of the cusps are numerous verrucous projections.

Microscopical Examination. Heart.—Section stained with methyl-green pyronin. Great numbers of Aschoff bodies and diffuse fibrosis of the myocardium. The bodies are found in the wall of the left ventricle, left papillary muscles, interventricular septum, about the calcified mitral ring, beneath the endocardium, and in the mitral valve, but not in the auricles.

Three main types of this lesion occur: (1) Collections of a few typical cells not more than eight to ten in number, closely packed against one another, immediately around small blood vessels. (2)

³ Case 1 was studied through the kindness of Dr. Alfred Meyer, of Mount Sinai Hospital.

Large collections of cells, numbering thirty or forty, arranged in a loose network of fibroblasts and young connective tissue cells. These occur mainly about the arteries, usually those of large or medium size, and beneath the endocardium. Some of the collections resemble a rosette in form, but most of them are fusiform accumulations in the adventitia of the blood vessels, and many may be found on both sides of the blood vessel as though completely encircling it. (3) A small number of perivascular foci made up of dense fibrous tissue with a few large typical giant cells at their center.

The greatest number of the bodies are found about the mitral ring, where in the midst of a dense fibrous tissue, which is infiltrated with calcium, are found typical discrete collections and large masses of scattered cells. Many plasma cells and large mononuclear leucocytes and a few polymorphonuclear leucocytes are found here and elsewhere about the bodies, together with numerous fibroblasts which take a bright red stain somewhat different from that of the giant cells, some of which are drawn out, flattened, or fusiform in shape. The mitral valve itself shows a number of the bodies mainly of the second type described, and in addition a dense fibrosis, fibroblasts, and mononuclear and plasma cells. The blood vessels everywhere, especially the small and medium sized ones, show a moderate intimal thickening while in some places there seems to be a narrowing of the lumen opposite the Aschoff bodies.

*Case 2.*⁴—R. H., age 17 years; negro, male. Admitted to the City Hospital, February 17, 1913; died, February 23, 1913. Patient complained of pain and swelling of ankles and knees. *Past history.*—Rheumatism five years ago with swelling of joints. *Present illness.*—Began about a week before admission with pain and swelling of ankles, later of both knees.

Autopsy.—Fibrous hypoplastic aorta; lymphatic hyperplasia of spleen and mesenteric lymph nodes; persistent thymus; fibrous pericarditis. *Heart.*—Weight 300 gm. The whole heart is encased in a dry, fibrinous exudate; valves normal. Left ventricle measures 9 mm. in thickness. On section the myocardium is normal in color, and shows no areas of sclerosis. Coronary arteries normal; aorta narrow, and free from arteriosclerosis.

Microscopical Examination. Heart.—Section stained with methyl-green pyronin. The heart contains a great number of Aschoff

⁴Case 2 was studied through the kindness of Dr. John Larkin, of the City Hospital, New York.

bodies, there being several in almost every microscopic field. Practically all the bodies are large, containing twenty to forty cells; they are arranged beneath the endocardium, in the adventitia of the blood vessels, and between the muscle fibers apparently independently of blood vessels. About half the cells are of the large multinuclear type, of which some contain five or six nuclei. The arrangement is loose, not densely packed together as in case 1. Between some of the cells is a pink staining matrix which contains many fine fibrils (fibrin?). In other bodies the cells are separated by a fibroblastic kind of tissue.

*Case 3.*⁵—J. S., age 23 years; white, female; married. Admitted to the City Hospital, January 23, 1913; died, March 5, 1913. Patient complained of headache, pain in joints and chest. *Past history.*—Scarlet fever when a child; typhoid one year ago. *Present illness.*—Began about three months before admission. The patient died forty-one days after admission to the hospital. Cardiac murmur remained present and unchanged with the exception of pericardial friction rub which appeared for a few days and then disappeared. Patient developed dullness on both sides of the chest posteriorly about two weeks before death. The chest was tapped and large quantities of clear fluid were removed on two occasions. This fluid was cultured twice, and cultures and spreads were negative. Three blood cultures were taken and all were negative. Wassermann reaction was negative.

Autopsy.—Only a partial autopsy was obtained. *Heart.*—Slightly hypertrophied and showed a slight chronic thickening of all its valves, and a few typical small pin-head verrucæ along their edges.

Microscopical Examination.—Section stained with methyl-green pyronin. The heart contains only a few typical Aschoff bodies in the adventitia about several medium sized or larger arteries. The bodies contain from six to ten typical cells, some of which are large and multinuclear; most of them are slightly larger than large mononuclear leucocytes and contain a single nucleus. The cells which are chiefly elongated have no definite arrangement and are separated from one another by the connective tissue of the adventitia; they lie with their long axis parallel to the direction of the blood vessel.

*Case 4.*⁶—M. W., age 17 years. Admitted to Mount Sinai Hospital, June 16, 1913; died, June 23, 1913. Onset of illness six weeks before admission, with headache, epistaxis, vomiting, generalized pain. Satisfactory history unobtainable. *Streptococcus mitis (viridans)* was recovered by blood culture.

⁵ Case 3 was studied through the kindness of Dr. John Larkin, of the City Hospital, New York.

⁶ Case 4 was studied through the kindness of Dr. J. Rudisch, of Mount Sinai Hospital.

Autopsy. Anatomical Diagnosis.—Subacute aortic and mitral bacterial endocarditis; verrucous mitral endocarditis and mitral stenosis; infarcts in the spleen and kidney; embolic glomerular lesions. *Heart.*—Normal in size; wall of left auricle increased in thickness; mitral valve is narrowed; the flaps are thickened and fibrous and continue downward onto the chordæ tendinæ for a slight distance, forming a funnel-shaped orifice, the free edge ending in a slight projecting shelf beyond the chordæ. Along the free edge of this shelf-like projection, very close to one another, are many smooth, pin-head verrucæ which are translucent in appearance. They are firm and crush with difficulty. On the ventricular surface of the aortic flap of the mitral valve are two large pedunculated cauliflower-like vegetations about half a centimeter in width and projecting for a distance of one centimeter. They are mixed red and gray in color and are friable. The cusps of the aortic valve show a slight irregular fibrous thickening. The ventricular surface of the cusps contains numerous small warty vegetations similar to those around the base of the large mitral vegetation. One of the cusps of the aortic valve, which is covered by vegetations, comes in contact with the large mitral vegetation when in the closed position.

Smears from the large mitral vegetation and those on the aortic valve show a moderate number of minute gram-positive cocci, which in culture proved to be *Streptococcus mitis (viridans)*. Smears and cultures, from crushed verrucæ on the mitral valve, were negative.

Microscopical Examination.—Sections stained with hematoxylin and eosin. Section of auricular-ventricular junction, mitral valve, left ventricle, and papillary muscle. The section shows diffuse round cell infiltration, slight edema, and patchy increase in interstitial tissue. Within the fibrous patches and between the muscle fibers, focalized collections of round cells giving the same picture as the lesions produced experimentally by Bracht and Wächter occur, including atrophy and degeneration of muscle fibers. In the adventitia of a number of the large and medium sized vessels and also in the myocardium between the muscle fibers are seen a moderate number of irregular nodular collections of cells, three to four times the size of large mononuclears, of which some are elongated and others multinuclear. The nuclei are vesicular, the protoplasm is finely granular, while between some a material which is either coagulated serum or fibrin occurs. The mitral valve shows fibrosis, slight round cell infiltration and small, irregular projections corresponding to the verrucæ, which are composed of more recent fibrous tissue. The blood vessels are thickened and show round cell infiltration.

In sections stained with methyl-green pyronin the nodular collections of cells just described take a brilliant dark red stain and are

seen to be typical Aschoff bodies. Others occur beneath the endocardium, and a few in the papillary muscle. The verrucæ at the edge of the mitral valve are made up of young connective tissue network. Throughout these small rounded projections are seen brilliant, dark red staining cells, the protoplasm of which is either homogeneous or finely granular. The cells are either fusiform, and three to four times the size of large mononuclear cells, or present long, interlacing, streamer-like processes. The nuclei are large and poor in chromatin. The first cells are suggestive of the cells of the Aschoff bodies, the latter having the appearance of fibroblasts.

*Case 5.*⁷—F. B., age 10 years. History of chorea at the age of 7; three attacks before the present admission; child died with symptoms of meningitis; clear cerebrospinal fluid.

Autopsy.—The pericardium is densely adherent to the sternum and when opened a large quantity of seropurulent fluid escaped. Parietal and visceral layers are rough, granular, and congested. *Heart.*—Both ventricles are hypertrophied; near the free margins of the tricuspid, mitral, and aortic valves are numerous small vegetations.

Microscopical Examination.—Section stained with methyl-green pyronin. The heart contains a few atypical Aschoff bodies. Many of the medium sized arteries show irregularly distributed thickening of the intima. In these arteries, diffusely scattered through the intima and extending into the adventitia are found cells resembling young fibroblasts and proliferating endothelial cells; but in the adventitia many of the cells have the typical appearance of Aschoff cells of which a number contain two or three nuclei.

*Case 6.*⁸—Female, age 12 years. Two weeks before the present illness the patient had tonsillitis and later complained of pain in arms and legs. One week later symptoms of chorea developed; movements became extremely violent and child became delirious, passing into coma and dying forty-eight hours later. Examination showed a few fibrous nodules along the tendons of the palms of the hands.

Autopsy. Anatomical Diagnosis.—Acute vegetative mitral endocarditis; bronchopneumonia of right lung; congestion of the pia mater. *Heart.*—Weight

⁷ Case 5 was studied through the kindness of Prof. E. L. Opie, of George Washington University, and Prof. John Howland, of Johns Hopkins Medical School.

⁸ Case 6 was studied through the kindness of Prof. E. L. Opie, of George Washington University, and Prof. John Howland, of Johns Hopkins Medical School.

172 gm.; endocardium normal, except at the line of closure of the mitral cusps on which is a continuous line of firmly attached vegetations.

Microscopical Examination.—Section stained with methyl-green pyronin. The heart contains a moderate number of typical Aschoff bodies present only in the adventitia of the arteries. They are made up of collections of six to forty cells which in a few instances are densely packed. In most cases the cells occur in the midst of the connective tissue, and are slightly separated from one another. The cells, of which one third are mononuclear, appear to be young, and many of them resemble fibroblasts.

*Case 7.*⁹—E. S., age 16 years. Admitted to Mount Sinai Hospital, Sept. 28, 1907; died, Oct. 27, 1907. Diagnosis, acute endocarditis. Gave a previous history of measles; chorea four years ago; no articular symptoms or sore throat; no history of rheumatism. For two months before admission had dyspnea and palpitation on exertion; cough, worse at night; headache.

Autopsy. Heart.—Enlarged; small areas of thickening of pericardium; walls of ventricles and auricles markedly hypertrophied. All cavities considerably dilated. Hypertrophy of papillary muscles of left ventricle. Mitral valve admits two fingers. All flaps markedly thickened. Free edges of flaps show irregular small verrucous vegetations. On the wall of the left ventricle, about two centimeters below the aortic orifice, there is a line of minute vegetations. All cusps are markedly thickened and retracted; about the free edge there are verrucous vegetations, some of which are five millimeters in diameter. The tricuspid valve admits two fingers; many vegetations occur along the thickened free edges of the cusps. The heart shows myocarditis, particularly in the left ventricle.

Microscopical Examination.—Section stained with methyl-green pyronin. The heart shows throughout numerous Aschoff bodies, most of which are large and contain as many as a hundred cells, and large, irregular areas of fibrosis in which a moderate diffuse round cell infiltration and a few polymorphonuclear leucocytes exist. The Aschoff bodies occur almost entirely in the adventitia of the medium sized and small arteries and in the midst of the areas of fibrosis. The bodies are loose collections of typical cells largely separated from one another by connective tissue fibers and containing in the center between the cells pink staining granular material. Some of the cells contain six nuclei.

⁹ Case 7 was studied through the kindness of Dr. J. Rudisch, of Mount Sinai Hospital.

CASES IN WHICH ASCHOFF BODIES WERE NOT PRESENT.

We have examined the hearts of fourteen cases of subacute bacterial endocarditis,¹⁰ of which disease descriptions have been given by Osler, Schottmüller, Horder, Libman, and others. The specimens were obtained from cases which Dr. Libman has reported. Blood cultures during life were positive in all, the invading organism being *Streptococcus mitis*. Ten of the cases gave no history of rheumatism. In none of these could Aschoff bodies be demonstrated. In only one of the four cases in which a history of rheumatism existed did we find any evidence of Aschoff cells. These cells characteristic of the bodies were few and occurred in the fibrous scars about the small vessels. This patient had suffered from an attack of acute articular rheumatism eleven years and again one year before death. Two other cases had "rheumatism" five and seven years, respectively, before death. The fourth patient had "rheumatism" with valvular disease fourteen years before admission. At the time of admission he had joint pains and was evidently suffering from a superadded bacterial infection involving his previously damaged valves. It is difficult to distinguish the arthritic manifestations in bacterial endocarditis from those of acute rheumatic fever. We have also examined the hearts of five cases of subacute bacterial endocarditis in the bacteria-free stage, as first described by Dr. Libman. Only one gave a history of "rheumatism," the attack antedating death by five years. None showed Aschoff bodies. In all these hearts lesions occurred similar to those produced experimentally by Bracht and Wächter with *Streptococcus mitis*. We have also examined with negative results the hearts of five patients that had had chronic valvular disease without rheumatism. In five cases of acute streptococcus endocarditis, one case of suppurative pericarditis accompanied by pneumococcus endocarditis, two cases of gonococcus endocarditis, and three cases of staphylococcus endocarditis, we failed to find the presence of Aschoff bodies in the heart.

CONCLUSIONS.

1. In rheumatic myocarditis, foci, termed submiliary nodules of Aschoff, are present which are characteristic of the rheumatic infection.

¹⁰ A large series of cases is being studied and will be reported later.

2. They are most frequently found in the walls of the left ventricle, the auricles usually escaping.
3. The nodules were found in three cases of chorea without joint manifestations, proving the close relation of this condition to rheumatism.
4. They were absent in fourteen cases of subacute bacterial endocarditis due to *Streptococcus mitis*.
5. They were not found in infections of the endocardium with the gonococcus, staphylococcus, streptococcus, or pneumococcus.
6. Even in the absence of a rheumatic history we believe, in accordance with Fraenkel, that the presence of Aschoff bodies signifies a previous rheumatic infection.
7. Aschoff bodies are not always found in rheumatic carditis, where the infection antedates death by a long period, but the healed remains, represented by sclerotic patches ("Schwielen"), are present.
8. We suggest that the cases of arthritis characterized by the presence of the submiliary nodules of Aschoff in the myocardium be placed in one group and called for the time being "rheumatism"; and the cases with articular manifestations, yielding positive bacteriological findings and no Aschoff bodies, should be classified according to the infecting microorganisms concerned, and not as rheumatism.

BIBLIOGRAPHY.

- Aschoff, L., *Verhandl. d. deutsch. path. Gesellsch.*, 1904, viii, 46.
 Aschoff, L., *Brit. Med. Jour.*, 1906, ii, 1103.
 Bracht, E., and Wächter, *Deutsch. Arch. f. klin. Med.*, 1909, xcvi, 493.
 Coombs, C., *Brit. Med. Jour.*, 1907, ii, 1513; *Quart. Jour. Med.*, 1908-09, ii, 26; *Lancet*, 1909, i, 1377; *Jour. Path. and Bacteriol.*, 1910-11, xv, 489; *St. Mary's Hosp. Gaz.*, 1913, xix, 22.
 Douglas, M., *Jour. Path. and Bacteriol.*, 1913, xviii, 119.
 Fraenkel, E., *Beitr. z. path. Anat. u. z. allg. Path.*, 1912, lii, 597.
 Geipel, P., *Deutsch. Arch. f. klin. Med.*, 1905, lxxxv, 75; *München. med. Wchenschr.*, 1909, lvi, 2469.
 Horder, T. J., *Quart. Jour. Med.*, 1908-09, ii, 289; *Report of the Local Government Board, Supplementary Report of the Medical Officer*, London, 1906-07, xxxvi, 279.
 Huzella, T., *Virchows Arch. f. path. Anat.*, 1913, ccxiii, 389.
 Libman, E., and Celler, H., *Am. Jour. Med. Sc.*, 1910, cxl, 516; *Tr. Assn. Am. Phys.*, 1910, xxv, 5.
 Löw, J., *Beitr. z. path. Anat. u. z. allg. Path.*, 1910, xlix, 1.

- Osler, W., *Brit. Med. Jour.*, 1885, i, 467, 522, 577, 607; *Practitioner*, 1893, 1, 181; *Quart. Jour. Med.*, 1908-09, ii, 219.
- Romberg, E., *Deutsch. Arch. f. klin. Med.*, 1891, xlviii, 369; 1894, liii, 141.
- Saigo, Y., *Beitr. z. path. Anat. u. z. allg. Path.*, 1908, xlv, 296.
- Schottmüller, H., *München. med. Wchnschr.*, 1910, lvii, 617; 1903, 1, 849, 909.
- Takayasu, R., *Deutsch. Arch. f. klin. Med.*, 1909, xcvi, 270.
- Wächter, *München. med. Wchnschr.*, 1908, lv, 1101.

EXPLANATION OF PLATES.

PLATE 46.

FIG. 1. Aschoff bodies, situated in the adventitia of a medium sized artery, showing typical morphology. Stained with hematoxylin and eosin. $\times 80$.

FIG. 2. Aschoff body, situated in the adventitia of a small artery. Stained with methyl-green pyronin. $\times 160$.

PLATE 47.

FIG. 3. Left auricle with subendocardial Aschoff bodies and thickened endocardium. Stained with methyl-green pyronin. $\times 40$.

FIG. 4. Aschoff bodies in interstitium of left ventricle. Stained with methyl-green pyronin. $\times 72$.

FIG. 5. Aschoff body, showing multinuclear cells. Stained with methyl-green pyronin. $\times 224$.

PLATE 48.

FIG. 6. Aschoff body in interstitium of left ventricle, from case of chorea. Stained with methyl-green pyronin. $\times 104$.

FIG. 7. Interstitial lesion of fibrous type (Bracht and Wächter) in heart showing both subacute bacterial endocarditis and verrucous endocarditis. Stained with methyl-green pyronin. $\times 16$.

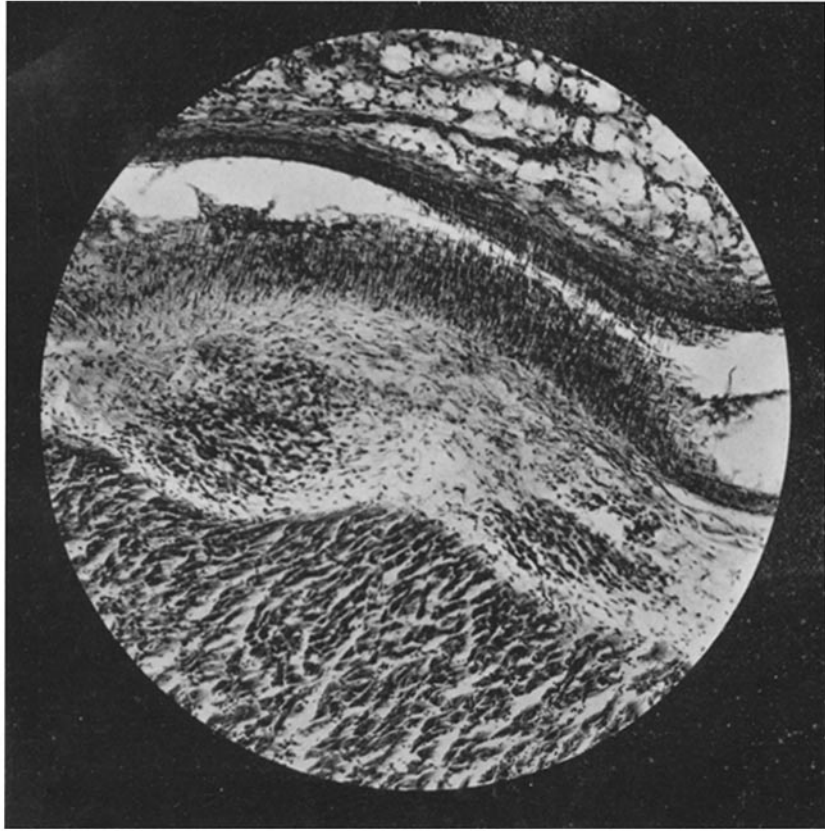

FIG. 1.

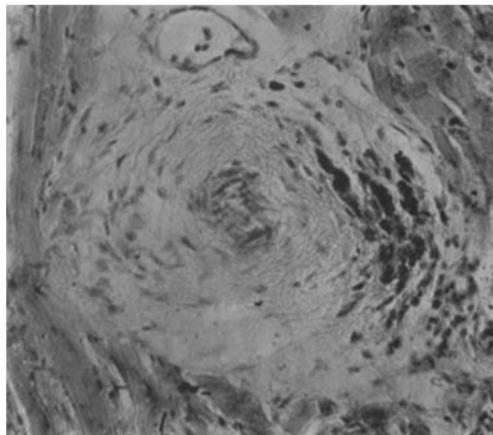


FIG. 2.

(Thalhimer and Rothschild: Nodules of Aschoff.)

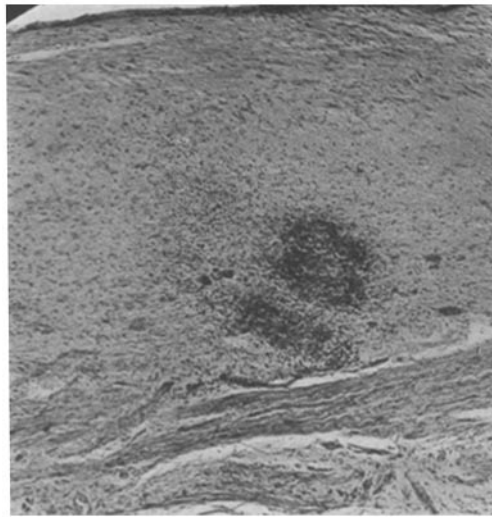


FIG. 3.




FIG. 4.

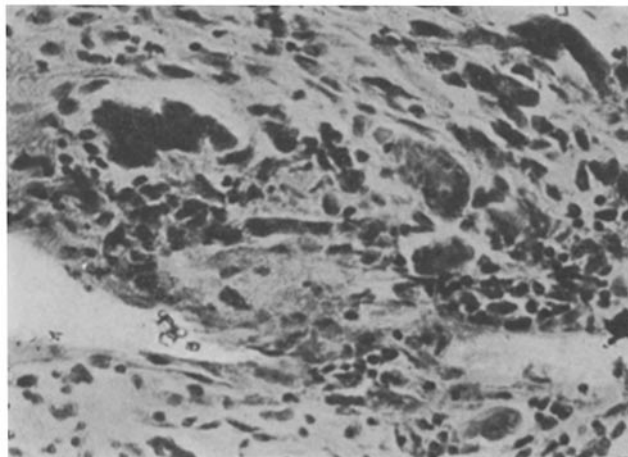


FIG. 5.

(Thalheimer and Rothschild: Nodules of Aschoff.)

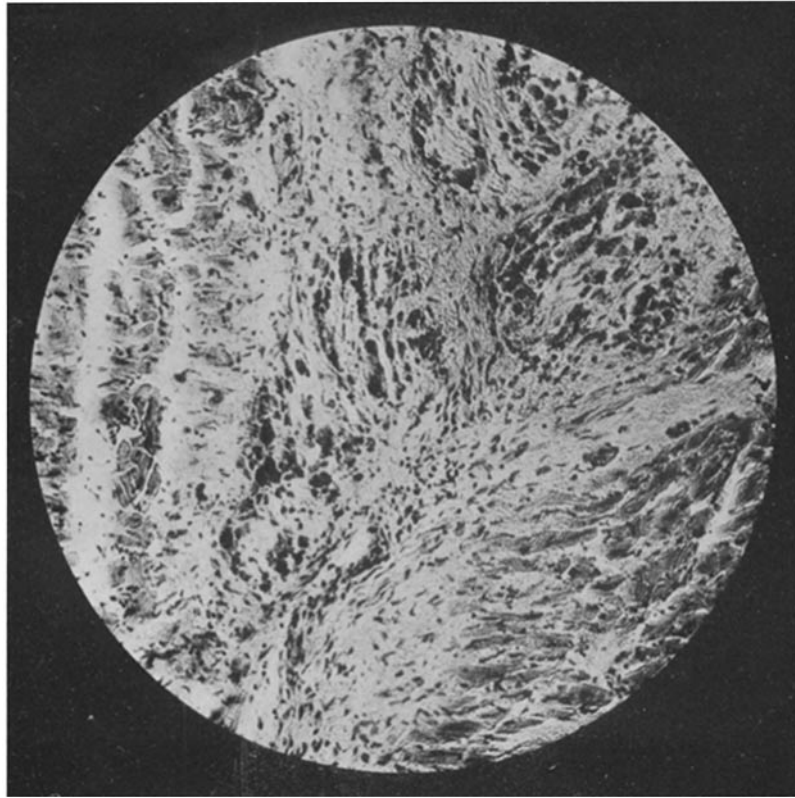


FIG. 6.

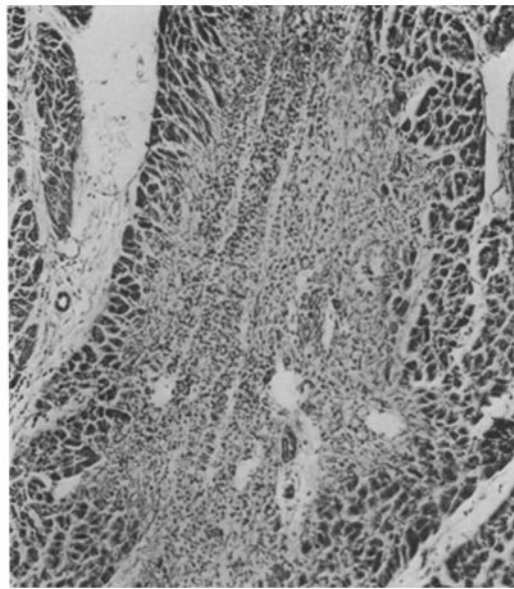


FIG. 7.

(Thalhimer and Rothschild: Nodules of Aschoff.)