

STUDIES ON X-RAY EFFECTS.

VI. EFFECT OF THE CELLULAR REACTION INDUCED BY X-RAYS ON  
CANCER GRAFTS.\*

BY JAMES B. MURPHY, M.D., RAYMOND G. HUSSEY, M.D., WARO NAKA-  
HARA, PH.D., AND ERNEST STURM.

(From the Laboratories of The Rockefeller Institute for Medical Research.)

PLATES 18 TO 20.

(Received for publication, October 19, 1920.)

The theory that cancer tissue in general is more susceptible to injury by x-rays than is normal tissue has been the subject of extensive investigation.<sup>1</sup> As far as we have been able to determine from the literature there have been no conclusive proofs brought forward that this theory is correct. Cancer cells can undoubtedly be killed by x-rays, but judging from our experiments the amount of x-rays which can safely be given to man, without causing burns and other deleterious effects, is not sufficient to kill the cancer cell *in vitro*.<sup>2</sup>

In general it may be said that the x-rays have given almost uniformly beneficial results in the treatment of human cancer in only one type of malignant disease; namely, skin cancer, particularly of the basal cell epithelioma type. Many explanations have been brought forward to account for the fact that these growths are so easily affected, while other cancers, lying just beneath the skin and therefore almost as accessible to the rays, yield less uniform results. The belief among x-ray workers is that the difference depends on dosage, and their tendency has been to endeavor to increase the amount of x-rays delivered to the diseased area. Even very large doses of x-rays have failed to give uniformly good results in any but the super-

\* This investigation was carried out by means of funds from the Rutherford Donation.

<sup>1</sup> Colwell, H. A., and Russ, S., Radium, x-rays and the living cell, London, 1915, 270.

<sup>2</sup> Hill, E., Morton, J. J., and Witherbee, W. D., *J. Exp. Med.*, 1919, xxix, 89.

ficial cancers, although sometimes there is a slowing down of the progress or even a cessation of growth for a period; rarely has actual retrogression taken place. In the vast majority of instances the treatment may be said to have had no effect, and even in the few cases in which there is improvement the benefit is only temporary.

Aside from skin cancer the only other tumors greatly affected by x-rays are the sarcomata arising from the testicle, and certain lymphoid tumors. It is of interest to note that the tissues from which these tumors arise are the most sensitive of the normal tissues to x-rays. Here again it is doubtful whether the malignant tissue is any more sensitive than the normal tissue from which it arose. Some of those who question whether the cancer cell is more susceptible than normal tissue to x-rays have advanced theories to explain their results. The two which have received most attention are (a) the idea that the dividing cell has an increased susceptibility to x-rays, and (b) the theory that the effect obtained from x-ray therapy arises from the induced obliteration of the blood vessels which diminishes the nutrition delivered to the new growth. If the first of these explanations is correct, we should expect that the best method of treating a skin cancer would be by very frequent small doses of x-rays so as to destroy the cells as they reach the dividing stage. Experience has shown that this method does not give the desired result. If the obliteration of the blood vessels be the cause of the occasional retrogression, we should expect a more uniform result than is at present obtained, for blood vessel changes are quite constant.

In the past, investigators in this field have attempted to establish the efficacy of x-ray therapy by exposing tumors *in situ*. The results viewed from the experimental side have one fallacy; namely, that they do not take into account the effect of x-rays on the animal in general and the local tissue reaction induced by this agent. Other experimenters have exposed tumor grafts *in vitro* to x-rays and then inoculated them into animals. In most instances when destruction of the cancer grafts resulted, the doses used were not comparable to the amount of x-rays that can safely be given to a living animal. When no definite destructive action on the cancer grafts was noted with amounts of x-rays comparable to the dose which can safely be given to man, the view was put forward that as only one dose of

x-rays was administered in this case, while in the usual treatment of man repeated exposures are given, no conclusions can be drawn from the failure. We have recently reported a series of experiments in which the attempt was made to treat a transplantable mouse cancer *in vitro*, as nearly as possible in the same manner as that employed in the treatment of human cancers, with the exception that the dosage was magnified.<sup>2</sup> The cancer growths were removed at intervals of from 5 to 6 weeks, exposed to x-rays, and replanted in a new series of animals. The outcome of the experiment was at first to reduce slightly and transitorily the growth energy of the tumor, while the later treatments were without effect either on the number of takes or the rate of growth of the tumor.

Hence it may be assumed that considerable doubt still exists that x-rays in a dose suitable for a living animal, *i.e.* an amount which will not produce a burn, will exert a very great destructive action on the cancer cell. The question arises why uniformly good results should follow the treatment of skin cancer and almost as uniformly poor results be obtained in the treatment of cancers in only slightly deeper tissues. The problem involved is the immediate basis of the experiments to be described in this paper.

The studies carried out by workers in this laboratory, extending over several years, have emphasized the close relation existing between the lymphocytes and resistance or susceptibility to cancer growths.<sup>3</sup> They have also shown that the lymphocyte is greatly affected by x-rays, since it is possible either to stimulate by small doses the production of these cells or by larger ones practically to destroy all the lymphoid tissues of the body.<sup>4</sup> In looking for an explanation of the results of the treatment of human cancer with x-rays, in the light of the findings described above, we have noted two interesting observations in the literature—first, that in treating cancer of the skin the

<sup>2</sup> Murphy, Jas. B., and Morton, J. J., *J. Exp. Med.*, 1915, xxii, 204, 800. Murphy, Jas. B., and Sturm, E., *J. Exp. Med.*, 1919, xxix, 25, 31. Murphy, Jas. B., and Nakahara, W., *J. Exp. Med.*, 1920, xxxi, 1.

<sup>4</sup> Taylor, H. D., Witherbee, W. D., and Murphy, Jas. B., *J. Exp. Med.*, 1919, xxix, 53. Nakahara, W., *J. Exp. Med.*, 1919, xxix, 83. Thomas, M. M., Taylor, H. D., and Witherbee, W. D., *J. Exp. Med.*, 1919, xxix, 75. Nakahara, W., and Murphy, Jas. B., *J. Exp. Med.*, 1920, xxxi, 13.

method found to be best is the one in which a dose sufficient to produce a so called x-ray erythema is given, the dose not being repeated until this erythema has subsided;<sup>5</sup> and second, that the so called x-ray erythema, when studied histologically, consists, besides the dilation of the blood vessels, etc., of a lymphoid infiltration of the skin layers,<sup>1</sup> which, however, does not extend to the subcutaneous or deeper tissues. Hence, it seemed not impossible that this important difference might account for the discordant results of the treatment of cancers of the skin and of the deeper tissues. The following experiments were planned to test this point.

#### EXPERIMENTAL.


*Intracutaneous Inoculation 7 Days after Exposure to X-Rays.*—The region extending from the upper abdomen down to and including both groins was shaved carefully in healthy young mice. These animals were secured on a small board and the entire body was covered with sheet lead. An opening 15 by 20 mm. was cut in the lead so as to expose a region in the left groin extending to the midline, and this area was then exposed to x-rays in the following dose: 3 inch spark-gap, 10 milliamperes, 6 inch distance from target, and 2½ minutes exposure. About 7 days later the skin showed a mild erythema with some scaliness. At this period small grafts of young healthy tumor from the Bashford adenocarcinoma, No. 63 series, were inoculated intracutaneously in the center of the x-rayed area and also in the corresponding position of the protected right groin. On account of the thinness of the skin, considerable caution was necessary to avoid thrusting the grafts through into the subcutaneous tissue, but occasionally this accidentally occurred. Weekly observations and measurements were made. The results of the individual experiments are shown in Table I and Text-figs. 1 and 2.

Thus it appears that there is a decided difference in the number of takes from cancer grafts inoculated into the skin of an area previously exposed to an erythema dose of x-rays, as compared to the

<sup>5</sup> Knox, R., *Radiography, x-ray therapeutics, and radium therapy*, New York, 1916.

TABLE I.

Experiment No.	No. of animals.	Growth in x-rayed area.	Growth in protected area.
		<i>per cent</i>	<i>per cent</i>
1	10	40.0	90.0
2	18	33.3	94.4
3	20	40.0	100.0
4	9	44.5	100.0



TEXT-FIG. 1. The growth of cancer grafts inoculated intracutaneously in an area 7 days after an x-ray exposure, compared to the growth of similarly inoculated grafts in an untreated area in the same animals.

number when the grafts are inoculated in the same manner into the same animal, but in an area protected from x-rays (Fig. 1). The next question to arise was whether the difference can be explained by the mechanical interference with the blood supply in the x-rayed area, from the induced changes in the blood vessels. To determine

this point a number of animals from this series were killed with ether and skinned. The skin was held before a light, by which means a clear definition of the vessels is secured. The vessels in all instances were found to be distended and numerous around the grafts in both areas, and whenever a difference was noted it was in favor of the x-rayed side. Moreover, another series of animals was injected with

EXPERIMENT 3						
Intracutaneous inoculation 7 days after x-rays						
	Normal		X-rayed		Normal	
	X-rayed		X-rayed		X-rayed	
1	●	+?	●	●?	●	-
2	●	-	●	-	●	-
3	+!	+?	●	+?	●	-
4	●	+?	●	-?	●	-
5	●	+?	●	-	●	-
6	●	-?	●	-?	●	-
7	●	-?	●	+	●	-
8	●	+?	●	-	●	-
9	●	-?	●	-	●	-
10	●	-?	●	●?	●	-
11	●	-?	●	-	●	-
12	●	●?	●	+?	●	-
13	●	-?	●	+?	●	●
14	●	+?	●	+?	●	Ulcer
15	●	●?	●	●	●	●
16	●	●?	●	+	●	●
17	●	+?	●	-?	●	●
18	●	+?	●	+	●	●
19	●	+?	●	●	●	●
20	●	-?	●	●	●	Ulcer
Weeks	1		2		3	

TEXT-FIG. 2. A repetition of the experiment shown in Text-fig. 1.


India ink into the heart, whereby a satisfactory injection of the superficial vessels was obtained. No essential difference in the number of patent vessels on the two sides was detected.

We return now to the second possibility. If the induced cellular reaction in the skin accounts for results obtained in the treatment of human cancer, we should expect no difference in the number of takes and the rate of growth of the cancer grafts in mice inoculated under the skin rather than into the skin of an x-rayed area. The following experiments were planned to test this point.

*Subcutaneous Inoculation 7 Days after Exposure to X-Rays.*—A series of mice was shaved in the same manner as those described in the preceding experiments and an area on the left side of the abdomen was exposed to x-rays in the same dose, the rest of the body being completely protected. A week later a cancer graft was inoculated into the x-rayed area, but just under the skin in the loose connective tissue. Another graft was inoculated in the same manner on the opposite side of each animal, in the area protected from x-rays. The results are shown in Table II and Text-fig. 3.

TABLE II.

Experiment No.	No. of animals.	Growth in x-rayed area.	Growth in protected area.
		<i>per cent</i>	<i>per cent</i>
5	19	89.5	84.2
6	9	88.9	88.9



TEXT-FIG. 3. A graphic representation of the results of subcutaneous inoculations of cancer grafts into x-rayed areas as compared with the subcutaneous inoculations into untreated areas.

From the foregoing data it will be seen that the cancer graft inoculated into an x-rayed area, but under the skin instead of into the skin, grows equally as well as does a graft in a protected area inoculated in the same manner. It would seem, therefore, that whatever change is induced by x-rays which renders a tissue unsuitable for the growth of cancer is confined to the skin and does not extend even to the loose connective tissue just below it. The histological changes induced by the x-rays were next studied.

*Histological Examination of Tissues of Animals Inoculated Intracutaneously after Exposure to X-Rays.*—A series of mice was shaved and treated with x-rays in the same manner as in the foregoing experiments. Some of these were killed on the 3rd day and others on the 7th day after treatment. The remaining mice were inoculated intracutaneously with a graft of Bashford Tumor No. 63 in the center of the x-rayed area and in a corresponding location in the protected groin. These last animals were killed off in groups for histological study 48 hours, 4 days, and 7 days after inoculation.

The histological examination showed that 3 days after exposure to the x-rays the skin was practically normal, while 7 days after treatment a marked accumulation of lymphoid varieties of cells was present, particularly in the stratum papillare of the corium in the x-rayed area (Fig. 2), whereas the untreated area remained entirely normal (Fig. 3).

The tumor grafts in the specimens taken after inoculation were found to lie in the tela subcutanea, just beneath the stratum reticulare. In the instances in which the graft was not completely destroyed in the x-rayed area, there was a marked lymphoid reaction about it (Fig. 4), in striking contrast to the practical absence of reaction around the graft in the normal area (Fig. 5). After the destruction of the tumor graft was complete, the lymphoid infiltration in the x-rayed area of the skin was less marked.

The next experiments were made to ascertain the period of maximum effect of the changes induced in the skin by x-rays.

*Exposure to X-Rays 20 Hours after Intracutaneous Inoculation.*—A series of mice was shaved over the abdomen and inoculated intracutaneously in both groins as in the previous experiments. 20 hours after the tumor inoculation the graft in the left groin with an area



around it was exposed to x-rays in a dose governed by the following factors: spark-gap 3 inches, milliamperes 10, distance from target 6 inches, and time  $2\frac{1}{2}$  minutes, a dose previously determined to be insufficient to destroy the cancer cell. The animals were examined weekly and measurements made of the tumors with the results shown in Table III and Text-fig. 4.

TABLE III.

Experiment No.	No. of animals.	Growth in x-rayed area.	Growth in protected area.
		<i>per cent</i>	<i>per cent</i>
7	7	14.4	83.4
8	11	10.0	63.7
9	20	15.0	85.0
10	18	50.0	83.4

As a control to the above observations a 3 weeks old cancer from the same series as that used for the preceding experiments was cut up into 48 small bits. These were then divided into two lots, each containing twenty-four pieces, and one lot was exposed to a dose of x-rays in the same amount as that given in the previous experiment to the area of skin in the groin. The x-rayed particles of tumor were then inoculated intracutaneously in the left groin of twenty-four mice and at the same time one of the untreated tumor particles was inoculated intracutaneously into the right groin of each mouse. At the end of 3 weeks eighteen of the twenty-four untreated grafts had produced tumors and sixteen of the twenty-four x-rayed grafts had grown. There was no appreciable difference either in the time of appearance or the rate of growth of the tumors in the two sides.

*Histological Study.*—Ten normal white mice were inoculated intracutaneously in both right and left groins with the strain of transplantable cancer used before. 24 hours later x-rays, governed by the same combination of factors as before, were given on the left groin over the skin area in which the cancer graft had been implanted. The right groin was left untreated for comparison. The mice were killed in groups of two, immediately, after 24 hours, 48 hours, 4 days, and 7 days after x-ray exposure.

EXPERIMENT 9						
Intracutaneous inoculation						
X-rayed 20 hours after inoculation						
	Normal		X-rayed		Normal	
	X-rayed	Normal	X-rayed	Normal	X-rayed	Normal
1	-?	+?	-	-	-	-
2	-?	-?	-	-	-	-
3	•?	-?	-	-	-	-
4	•	-?	•	-	•	-
5	•	-	•	-	•	-
6	•	+?	•	-	•	-
7	•	+?	•	-	•	-
8	•	-?	•	-	•	-
9	•	+?	•	-?	•	-
10	•	+?	•	-	•	-
11	•	+	•	-	•	-
12	•	-	•	-	•	-
13	•	-?	•	-	•	-
14	•	+?	•	-	•	-
15	•	•?	•	-	•	Died
16	•	+	•	-	•	-
17	•	-	•	-	•	-
18	•	+?	•	•?	•	•
19	•	+	•	•	•	•
20	•	•	•	•	•	•
Weeks	1		2		3	

TEXT-FIG. 4. The result of an experiment in which a cancer was inoculated intracutaneously into each groin of twenty mice and 20 hours later a dose of x-rays was given over the left groin so as to include the cancer graft and the surrounding tissue.

No detectable histological difference was found in the skin of the two sides of animals killed during the first three periods. The moderate cell infiltration about the graft in the treated, as well as the untreated side, consisted chiefly of polymorphonuclear leucocytes.

Beginning with the 4 day period an extensive lymphoid infiltration in the skin, especially about the graft on the treated side, appeared, while the graft on the untreated side was well established and attended by a moderate cell infiltration, in which polymorphonuclear cells were taking the more prominent part.

By the 7th day the tumor graft had disappeared in the treated side, but an intense lymphoid infiltration of the skin was present. In the untreated side a growing tumor was found, accompanied by some cell infiltration, although the adjacent skin showed only slight invasion.

EXPERIMENT 12									
Intracutaneous inoculation 2 hours after x-rays									
Normal X-rayed			Normal X-rayed			Normal X-rayed			
1	•	-?	-	-	-	-	-	-	-
2	+	•	-	-	-	-	-	-	-
3	•?	+?	-	-?	-	-	-	-	-
4	-	+?	+?	-?	-	-	-	-	-
5	+	+?	-	-	-	-	-	-	-
6	•	-?	•	-?	•	•	•	•	•
7	•	+	•	-?	•	•	•	•	•
8	•	-?	•	-	•	•	•	•	•
9	+?	+?	•	-	•	•	•	•	•
10	•	-?	•	-?	•	•	•	•	•
11	•	•	•	+?	•	•	•	•	•
12	•	•?	•	-?	•	•	•	•	•
13	•	+?	•	-?	•	•	•	•	•
14	•	•	•	+?	•	•	•	•	•
15	•	•	•	-?	•	•	•	•	•
16	•	+?	•	-?	•	•	•	•	•
17	•	+?	•	-?	•	•	•	•	•
18	•	•	•	+?	•	•	•	•	•
19	•	•	•	-?	•	•	•	•	•
20	•	•	•	-?	•	•	•	•	•
21	•?	•	•	-?	•	•	•	•	•
22	•?	•?	•?	•	•	•	•	•	•
23	•	•	•	+?	•	•	•	•	•
24	•?	+?	•	+	•	•	•	•	•
Weeks	1		2		3				

TEXT-FIG. 5. The growth of cancer grafts inoculated intracutaneously in an area of skin 2 hours after the skin had been exposed to x-ray treatment compared to the fate of similarly inoculated grafts in an untreated area in the same animals.

While this dose of x-rays has been shown to be incapable of destroying tumor cells *in vitro*, the objection to this result as a confirmation of our first experiments is obvious, as the cancer cells in the latter experiments were exposed to the direct action of the x-rays. The following experiments were planned with the idea of avoiding this

objection and yet availing ourselves of the full time of the effect produced by the x-rays in the skin.

*Intracutaneous Inoculation 2 Hours after Exposure to X-Rays.*—Mice were shaved over both groins and then given the same dose of x-rays over the left groin as that given in the preceding experiments. 2 hours later intracutaneous inoculations of cancer grafts were made into the x-rayed area of the left groin and in the corresponding locality in the right groin, the latter having received no x-rays. The results 3 weeks after these inoculations are given in Table IV and Text-fig. 5.

TABLE IV.

Experiment No.	No. of animals.	Growth in x-rayed area.	Growth in protected area.
		<i>per cent</i>	<i>per cent</i>
11	18	38.9	88.9
12	24	12.5	75.0

It will be seen from these last two groups of experiments that when the inoculation is made either just before or just after the administration of x-rays, the results are only slightly if any better than when the cancer inoculation is made when the reaction in the skin is at its height.

## DISCUSSION AND CONCLUSIONS.

We shall not attempt to discuss the complex question of the amount of x-rays required to kill the cancer cell, for this has been dealt with extensively in recent literature.<sup>6</sup> Certain facts stand out which cannot be satisfactorily explained by the direct action theory; namely, that in man skin metastases are often easily influenced by x-rays while the primary growth or even metastases in the subcutaneous tissue are resistant. We have seen such a case in our clinic at the Hospital of The Rockefeller Institute, in which numerous skin metastases disappeared under mild doses of x-rays while metastases in the superficial glands of the neck and axilla showed no retrogression even under large doses. The amount of x-rays delivered to the cancer cells in the latter instances was many times greater than that given to the skin metastases. The experiments reported in this paper

<sup>6</sup> For a review of recent literature see Wood, F. C., and Prime, F., *J. Am. Med. Assn.*, 1920, lxxiv, 308.

offer a plausible explanation of this phenomenon. When the metastases or primary growth is in the skin, the x-rays induce a condition which renders it an unsuitable soil for survival of the tumor but this change does not extend as far beyond the skin layers as the subcutaneous tissue. The x-rays bring about a marked cellular reaction confined to the skin layers. It seems probable, therefore, that the explanation of the x-ray action in rendering an area unsuitable for cancer growth is the local cellular reaction induced in this tissue. Thus this effect is brought into harmony with the observations already published by us on the relation of lymphoid cell reaction and resistance to tumor growth. Certain studies recently published by Ewing<sup>7</sup> on the effect of radium in the treatment of human cancers indicate that a similar mechanism plays a part in the beneficial effects obtained by this mode of treatment.

Another explanation which has been proposed by many observers is that the good effect of x-rays depends on the induced blood vessel changes with a resultant deficiency of nutrition to the tumor cells. Our experiments covering this point showed that at no stage of the erythema or later during the retrogression of the tumor could any evidence of obstruction to the local blood supply be detected. In the light of the previous experiments on the relation of the lymphoid reaction to cancer immunity and the present experiments on the lymphoid cell reaction induced by x-rays and the failure of the growth of tumors in such areas, this central fact must be taken into consideration in accounting for the therapeutic action of x-rays in cancer. In this connection we desire to state that we do not regard the results obtained in the treatment of testicular sarcoma and certain lymphoid tumors as covered by this explanation, for like their parent tissues the cells of these respective tumors are particularly sensitive to the direct action of x-rays.

There remain to be considered the occasional beneficial results obtained with x-rays in metastatic cancer in lymph glands. This question is not a simple one. For example, in regions draining an area affected by cancer, the lymph glands often become more numerous and much larger than normal. Such glands are often regarded

<sup>7</sup> Ewing, J., *J. Am. Med. Assn.*, 1917, lxviii, 1238.

as metastatic, and yet pathologists who have examined the extirpated glands often fail to find cancer cells. These hypertrophic glands would, of course, melt away under x-rays. There is another series of events which may also give a false impression of retrogression of cancer metastases under x-rays. We have seen such an instance in the case of a large gland in the neck of a patient suffering from cancer of the breast. The nodule was exposed to vigorous x-rays and promptly retrogressed to a point where it was just palpable. The small nodule was removed at operation at this period with another involved gland which had not been subjected to the x-rays. In the latter, or untreated gland, there was a small metastasis with a fairly abundant supply of lymphoid tissue, the two making up a fair sized nodule, while in the treated gland the metastasis was found to be made up of healthy tumor cells showing no evidence of deleterious effects from the x-rays. We believe that in this case the apparent retrogression of the nodule was due simply to the destruction of the lymphoid elements of the gland with no effect whatever on the cancer cells. Finally, examples are known of definite retrogression of metastatic nodules in the superficial glands resulting from x-ray treatment to which the above explanations do not apply. Whether these are to be explained by an occasional reaction induced in the deep tissues by x-rays, or whether they represent occasional examples of tumor tissue hypersensitive to x-rays, future studies will have to determine. In view, however, of the doubt surrounding the opinion that cancers in general are more sensitive to x-rays than is normal tissue, we wish to question the advisability of the present tendency to increase greatly the dose of x-rays. We make this point since our previous studies have shown that it is possible in mice to break down the general mechanism of resistance against cancer by overwhelming doses of x-rays.<sup>8</sup>

#### SUMMARY.

Small areas of the skin in the groin of mice were subjected to an erythema dose of x-rays and a week later a cancer graft was inoculated intracutaneously into the area and at the same time a like graft was

<sup>8</sup> Murphy, Jas. B., and Taylor, H. D., *J. Exp. Med.*, 1918, xxviii, 1.

inoculated in the same manner in the opposite groin protected from x-rays. The graft in the x-rayed area showed a low percentage of takes, while that in the normal skin gave the usual high percentage. When the graft was introduced into the subcutaneous tissues it grew equally as well in the x-rayed area as in the protected area.

Histological examination shows the skin layers, a few days after x-ray treatment, to be markedly infiltrated with round cells of the lymphoid type. The reaction did not extend deeper than the skin layers. It is suggested that this local lymphoid reaction induced by the x-rays controls the graft made into the skin, while its absence in deeper tissues accounts for the growth of the grafts more deeply implanted.

#### EXPLANATION OF PLATES.

##### PLATE 18.

FIG. 1. The result of an intracutaneous inoculation of cancer grafts in an area previously exposed to x-rays (left side) compared with the result of a similar inoculation in an untreated area (right side).

##### PLATE 19.

FIG. 2. X-rayed area of the skin of a mouse 7 days after the treatment.

FIG. 3. Untreated area of the skin of the same mouse.

##### PLATE 20.

FIG. 4. Cancer graft in an x-rayed area.

FIG. 5. Cancer graft in an untreated area.

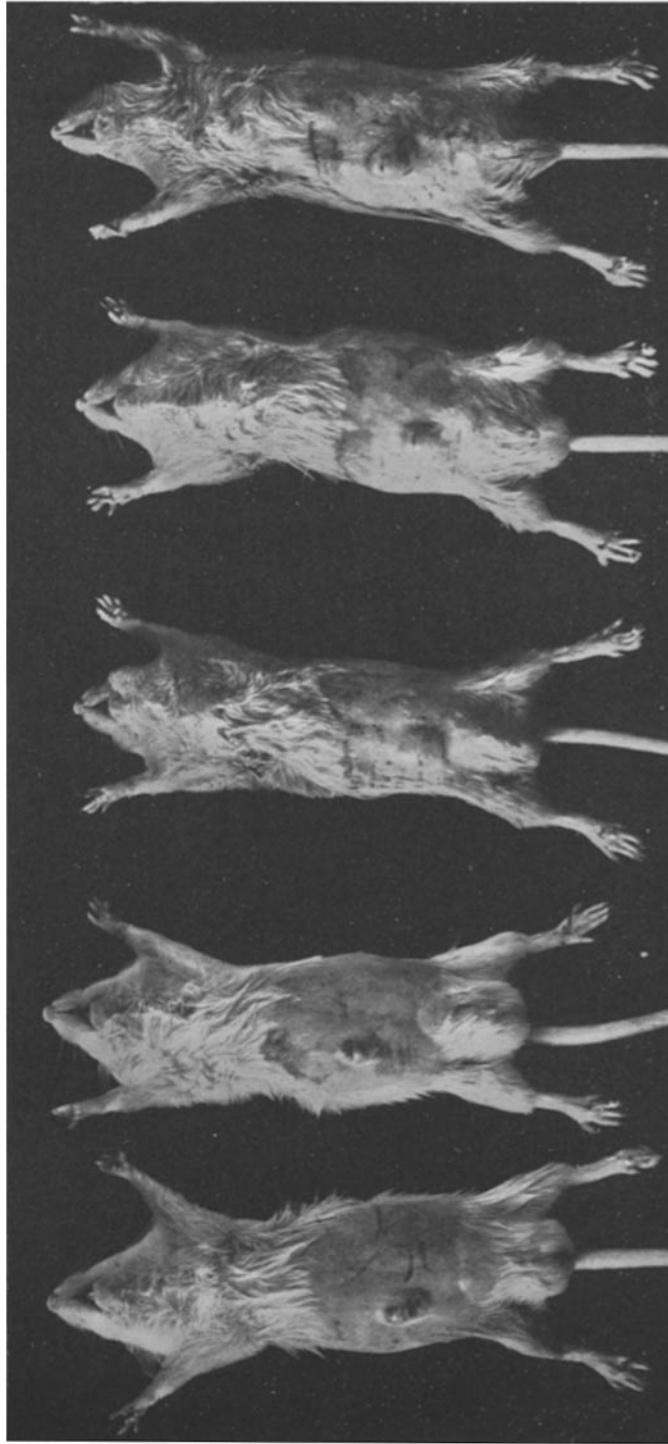


FIG. 1.

(Murphy, Hussey, Nakahara, and Sturm: X-ray effects. VI.)



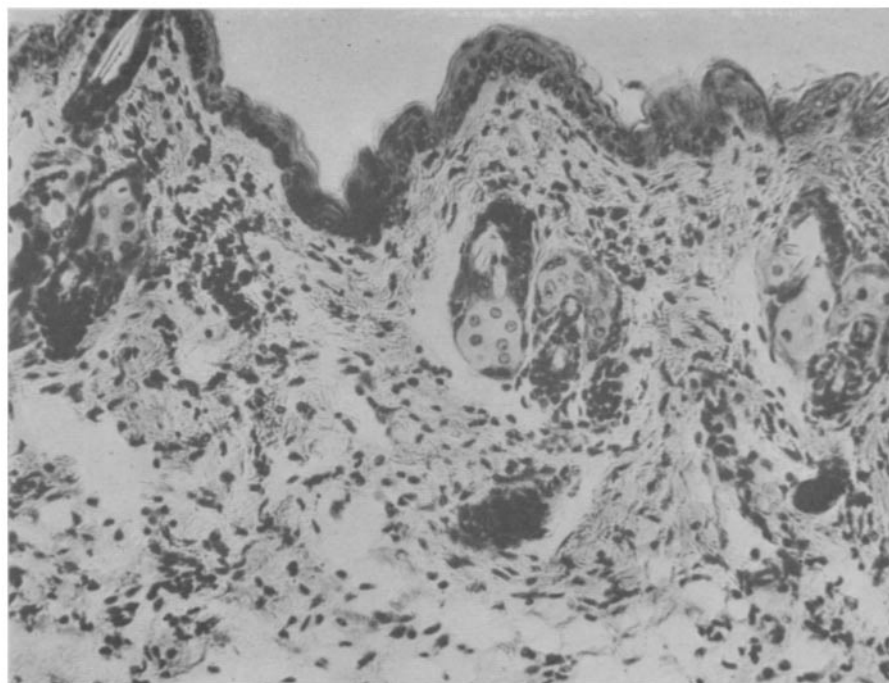


FIG. 2.

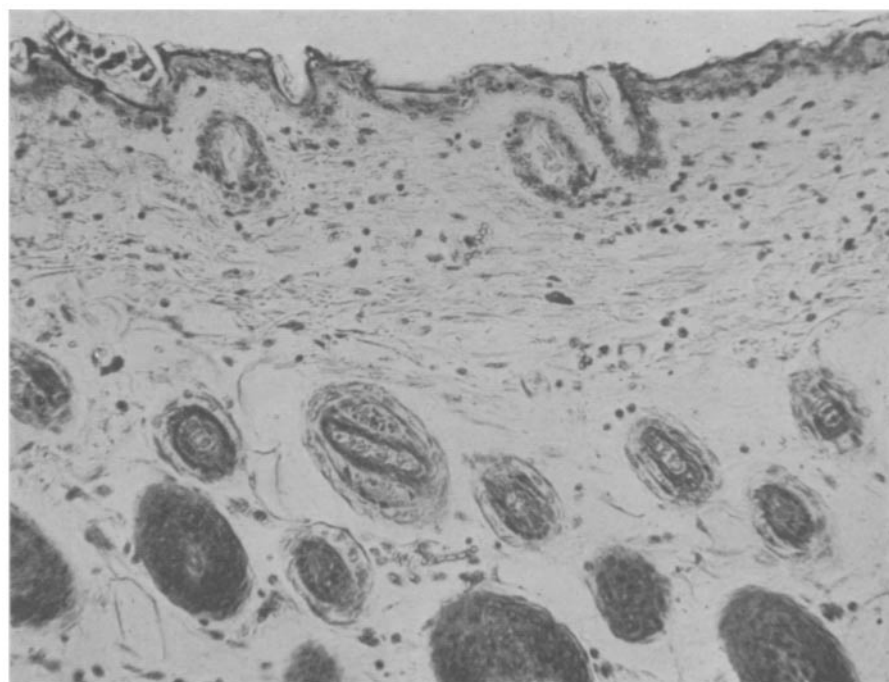


FIG. 3.

(Murphy, Hussey, Nakahara, and Sturm: X-ray effects. VI.)

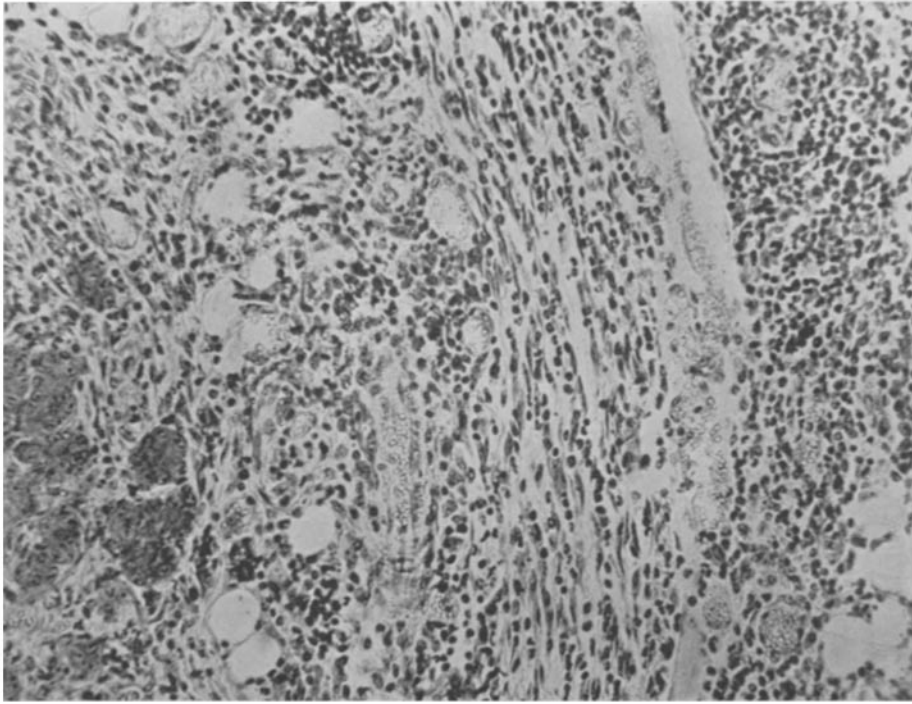


FIG. 4.

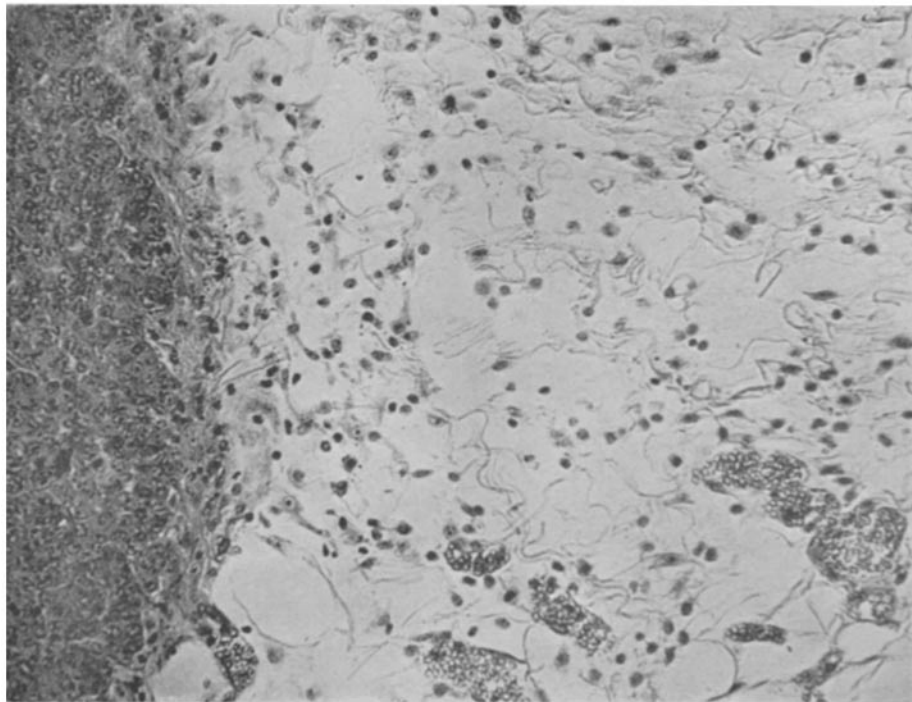


FIG. 5.

(Murphy, Hussey, Nakahara, and Sturm: X-ray effects. VI.)